Cancer Gene Therapy (2006) 13, 792–797
© 2006 Nature Publishing Group All rights reserved 0929-1903/06 $30.00
www.nature.com/cgt

ORIGINAL ARTICLE

Expression of the coxsackievirus- and adenovirus receptor in gastrointestinal cancer correlates with tumor differentiation

WM Korn[1,2,3], M Macal[1,4], C Christian[1], MD Lacher[1], A McMillan[3], KA Rauen[3,5], RS Warren[3,6] and L Ferrell[7]

[1]*Division of Gastroenterology, Department of Medicine, University of California San Francisco, San Francisco, USA;* [2]*Division of Medical Oncology, Department of Medicine, University of California San Francisco, San Francisco, USA;* [3]*Comprehensive Cancer Center, University of California San Francisco, San Francisco, USA;* [4]*San Francisco State University, San Francisco, USA;* [5]*Department of Pediatrics, University of California San Francisco, San Francisco, USA;* [6]*Department of Surgery, University of California San Francisco, San Francisco, USA and* [7]*Department of Pathology, University of California San Francisco, San Francisco, USA*

Modified adenoviruses represent a new approach to treatment of gastrointestinal cancer. However, their uptake by cells in many cases requires the major receptor for adenoviruses, the coxsackievirus and adenovirus receptor (CAR). Thus, lack of CAR expression is a potential cause of intrinsic resistance of tumor cells to this type of treatment. To evaluate this, we studied the localization of CAR protein in normal and malignant gastrointestinal tissues. In normal tissues, CAR was concentrated at sites of cell–cell interaction, in particular at the apico-lateral cellular surface. Expression was particularly strong around bile and pancreatic ducts, which is in agreement with CAR's physiological function as a tight-junction protein. In GI malignancies (esophageal, pancreatic, colorectal and liver cancer), expression of the receptor varied substantially. Loss of CAR expression at cell–cell junction was evident in many samples. A significant correlation between CAR expression and histological grade was found, with moderately to poorly differentiated tumors most frequently demonstrating loss or reduction of CAR expression. These data indicate that CAR expression is frequently altered in gastrointestinal malignancy, potentially reducing the efficacy of adenovirus-based therapies.
Cancer Gene Therapy (2006) **13,** 792–797. doi:10.1038/sj.cgt.7700947; published online 21 April 2006

Keywords: CAR; gastrointestinal cancer; adenovirus-based therapies; cell adhesion; tumor differentiation

Introduction

Gastrointestinal cancers continue to be among the leading causes of cancer-related deaths worldwide.[1] This is in part due to the limited efficacy of non-surgical treatment, despite recent development of small molecule or antibody-based molecularly targeted agents. Therapeutic adenoviruses represent a new therapeutic modality that can be designed to specifically replicate in and kill cancer cells. Clinical studies demonstrate that such viruses can safely be administered locally, regionally and systemically[2] and that these agents have efficacy in gastrointestinal cancer, in particular when administered by intrahepatic arterial infusion.[3] However, objective tumor responses were observed in only a small number of the patients. A variety of potentially limiting factors has been postulated, in particular, limited uptake of the virus by the target cells. The host immune response, virus distribution, replication, and propagation also may play a role.

For successful cellular entry, efficient attachment of the adenovirus capsid proteins to cell surface proteins is essential. Binding of the viral fiber–knob protein to its cellular high-affinity receptor, the coxsackievirus and adenovirus receptor (CAR), represents the first step in this process. Coxsackievirus and adenovirus receptor is a transmembranic protein that physiologically participates in cell–cell adhesions as part of the apical junctional complex.[4,5] Previous studies demonstrated loss of CAR expression in prostate, urothelial and breast cancer,[6–8] suggesting a potential mechanism of intrinsic resistance. Here, we report our studies of CAR expression in the most common human gastrointestinal cancers and demonstrate that loss of CAR expression is a marker of dedifferentiation.

Correspondence: Professor WM Korn, UCSF Divisions of Gastroenterology and Medical Oncology, Department of Medicine, University of California San Francisco, Box 0128, 2340 Sutter St., San Francisco, CA 94143, USA.
E-mail: mkorn@cc.ucsf.edu
Received 29 September 2005; revised 10 December 2005; accepted 8 January 2006; published online 21 April 2006

Materials and methods

Study group

A total of 71 cases of gastrointestinal cancer for which paraffin-embedded tumor material was available at the UCSF Departments of Pathology and Surgery were identified. All tissues had been removed by surgical resection or endoscopic biopsy between 1993 and 2001. The study was approved by the UCSF Committee of Human Research.

Pathological evaluation

The expert gastrointestinal pathologist on the team (LF) confirmed the histological diagnosis of all selected cases. All cases were evaluated for grade of differentiation using the following scale: well, moderately well, moderate, moderately poor and poor. This grading scheme encompassed the spectrum from tumors entirely composed of well-formed glands lined by tall columnar cells (well differentiated) to those with no gland formation (poorly differentiated).

Immunohistochemistry

Coxsackievirus and adenovirus receptor protein expression was detected by immunohistochemical staining of standard 5 μm formalin-fixed, paraffin-embedded tissue sections. The staining protocol has been described before[8] and uses a rabbit-polyclonal antibody (Ab72) directed against full-length CAR protein. During the course of the study, a new rabbit anti-CAR antibody (CAR H300, Santa Cruz Biotechnology, Santa Cruz, CA), became commercially available that showed significantly less unspecific staining than Ab72 in Western blot experiments (data not shown). The study was continued with this antibody at a dilution of 1:50. Semiquantitative assessment of CAR cell-surface expression was performed by two of the investigators (WMK and LF) by estimating the percentage of cells demonstrating CAR protein expression at the cell surface. In two cases, two differently differentiated tumor areas were found. In these cases, separate CAR expression scores were assigned for each tumor area.

Statistical analysis

The correlation between CAR and differentiation was assessed using Spearman's rank correlation. To explore whether the correlation could be due to confounding with type of tissue, we computed a partial Spearman's correlation, adjusting the correlation for four indicator variables (one for each type of tissue). The relative strength of differentiation and type of tissue was further explored by linear regression analysis, using linear scores (1 = well differentiated to 5 = poorly differentiated). Correlations of CAR with differentiation was also computed within types of tissues. The effect of antibody type was similarly evaluated using multiple linear regressions. For the purpose of illustration, a *t*-test was used to evaluate the differences in CAR level between the two antibodies. The *P*-value calculation used the Satterthwaite's method to correct for unequal variances. There were two samples with two separate CAR determinations from distinct and morphologically different tumor areas. The sensitivity of the analysis to the presence of multiple samples from the same patient was assessed by computing a minimum CAR score (CAR_Min) and a maximum score (CAR_Max) per sample.

Results

Sample characteristics

Among the 71 cases in this study, there were 27 colon cancers metastatic to the liver, 10 primary liver cancers, 18 pancreatic cancers and 16 esophageal cancers. For two cases (one pancreatic and one esophageal cancer), regional differences in differentiation were found within the tumor and scored separately. The distribution of grade of differentiation of all tumor samples is shown in Table 1. Moderately differentiated tumors were the single most frequent group, followed by moderately well and moderately poorly differentiated samples.

Immunohistochemical detection of coxsackievirus and adenovirus receptor in normal GI tissues

In all normal tissues evaluated in this study, immunohistochemistry for CAR protein was consistent and reproducible. In sections of normal liver tissue (Figure 1a), CAR staining was concentrated at sites of cell–cell interaction bracketing the apical (bile canalicular) membrane; staining of the basolateral membrane exposed to the space of dissection was not seen. We have described this finding before in the context of hepatotoxicity of an oncolytic adenovirurs.[9] Coxsackievirus and adenovirus receptor staining was strong also at cell–cell junctions of

Table 1 Sample distribution

Differentiation	*Well*	*Moderately well*	*Moderate*	*Moderately to poor*	*Poor*	*Total (%)*
Cancer type						
Liver	0	4	3	3	1	11 (15.1)
Colorectal	1	11	13	1	1	27 (37)
Pancreas	3	3	9	3	1	19 (26)
Esophageal	1	4	8	1	2	16 (21.9)
Total (%)	5 (6.8)	22 (30.1)	33 (45.2)	8 (11)	5 (6.8)	73 (100)

Shown are the numbers of samples examined in this study by tumor type and histological grade. In total, 73 samples from 71 patients were analyzed.

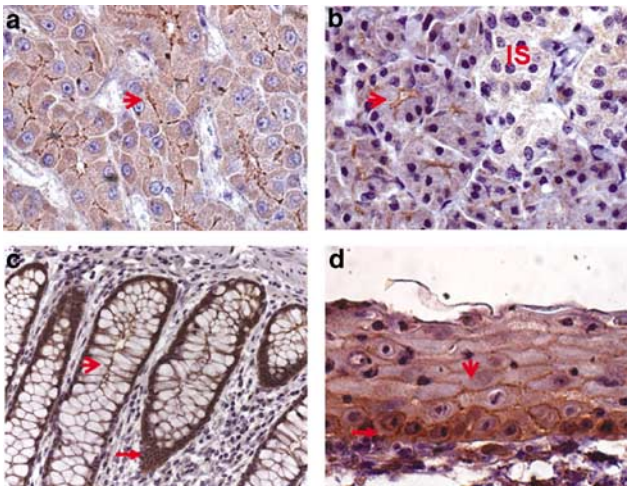

Figure 1 Immunohistochemistry staining for coxsackievirus and adenovirus receptor (CAR) protein on sections from normal human gastrointestinal tissues. Shown are images from liver (**a**) and pancreatic (**b**) tissues as well as colonic (**c**) and esophageal mucosae (**d**). The rabbit polyclonal antibody H300 was used in (**a**, **b** and **d**), while section (**c**) was stained using the rabbit polyclonal antibody Ab72. Open arrows indicate examples of CAR staining at cell–cell junctions. The filled arrows (**c** and **d**) point to the basal epithelial cell layers that show a cytoplasmic signal. All images were obtained at a magnification of $\times 400$ and digitally enhanced.

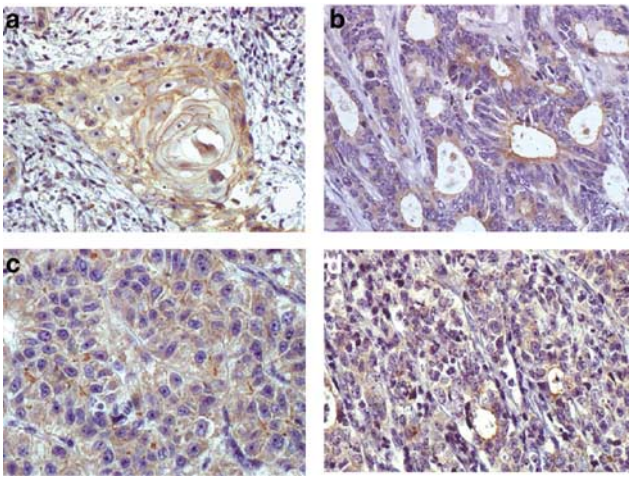

Figure 2 Immunohistochemistry staining for coxsackievirus and adenovirus receptor (CAR) protein in gastrointestinal cancers. Examples of a well-differentiated esophageal squamous cell carcinoma (**a**), a moderately well differentiated colon cancer metastasis (**b**), a moderately differentiated hepatocellular carcinoma (**c**) and a moderately-to-poorly differentiated pancreatic cancer (**d**) are shown. Magnification $\times 400$.

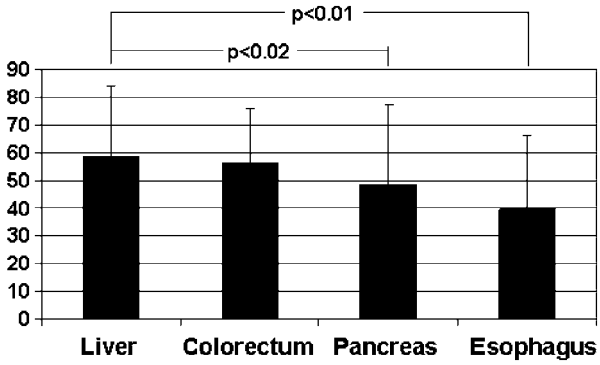

Figure 3 Average proportion of tumor cells with coxsackievirus and adenovirus receptor (CAR) expression at cell–cell junctions for the four tumor types. Levels of statistical significance are indicated for the comparison pancreatic versus liver cancer and esophageal versus liver cancer. CAR expression frequencies in colorectal cancer metastases were not significantly different from liver cancer. Error bars represent one s.d..

biliary epithelial cells (data not shown). In pancreatic tissue (Figure 1b), CAR staining was restricted to acinar and ductal cells, where it again was located at apical sites of cell–cell interaction. Strong staining was also observed in pancreatic ductal epithelium. In contrast, pancreatic islets did not show any CAR staining. In colorectal epithelium, CAR expression was again seen at the sites of cell–cell contact (Figure 1c). Interestingly, basal cells in colonic crypts showed reproducibly strong cytoplasmic staining with both antibodies. A similar pattern was observed in esophageal squamous cell epithelium (Figure 1d) and, in a separate study, in normal prostate tissue (data not shown). Again, basal cells in this tissue showed cytoplasmic staining while CAR protein was restricted to cell junctions in the stratum spinosum and not detectable in the upper layers of the epithelium.

Immunohistochemical detection of coxsackievirus and adenovirus receptor in malignant GI tumors

In contrast to normal tissue, CAR expression by malignant tumors was remarkably variable with regard to the number of cells demonstrating CAR staining at sites of cell–cell interaction, which varied substantially between individual tumors (Figure 2a–d). In addition, when the overall percentage of CAR-positive cells was calculated for the individual tissue types, esophageal cancer and pancreatic tumors showed significantly less CAR-staining than liver cancer (Figures 3 and 4). This continued to be true when the data were compensated for differences in tissue grade (data not shown). There were clear differences in CAR expression between tumors of different histological grade of differentiation. While CAR expression was frequently retained in well- or moderately well differentiated tumors (primarily at sites of cell–cell contact), it was diminished in lesser-differentiated tumors, as depicted in Figure 4. The correlation of CAR expression and grade of histological differentiation, as determined by Spearman's rank correlation analysis, was statistically highly significant ($r = 0.72$; $P < 0.0001$) (Figure 4). It retained statistical significance when the analysis was adjusted for tissue type (P-value < 0.0001). Within types of tissue, the correlation of CAR expression and grade was variable but was always negative and statistically significant in all but the esophageal samples. The lack of significance in the esophageal carcinomas

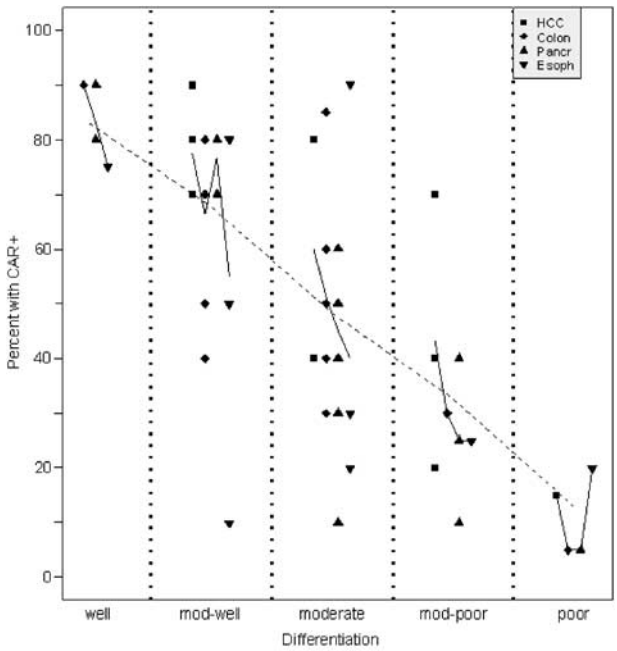

Figure 4 Average proportion of tumor cells with coxsackievirus and adenovirus receptor (CAR) expression at cell–cell junctions in relationship to histological grade. The dotted line represents the calculated regression line. Lines within each category connect the averages of CAR expression for each tumor type.

($P = 0.1050$) may be due to small sample size in this tissue type as contrasted with the entire set of 73 samples. Furthermore, a statistical model allowing for different slopes of the relationship between CAR and histological differentiation in different tissues was developed. The slopes were not statistically different ($P = 0.5636$, data not shown), suggesting that there is no evidence for a different relationship between CAR and differentiation in different tissue types. The data analyzed contained two samples taken from the same patient. Removal of the duplicate sample did not change the inferences substantially (data not shown). Further analysis was performed to determine whether potential differences between the two anti-CAR antibodies used in this study might have been responsible for the findings described above. Fifty-eight sections were stained with the CAR H300 antibody while 15 sections were stained with Ab72, which had been used in previous studies. Both antibodies showed identical patterns of CAR expression in normal tissues, in particular colon mucosa and liver tissue (data not shown). In contrast, frequencies of CAR-positive cells measured in tumors using the H300 antibody were significantly lower than those determined by using Ab72 as determined by Student's *t*-test. However, the correlation between positive CAR staining and tissue differentiation was significant for both antibodies (data not shown). Furthermore, a multi-parametric linear regression model for CAR expression using tissue type, grade of differentiation, and antibody as parameters showed no significant effect of the antibody, indicating that the aforementioned differences may have been related to tissue type and differentiation in the samples evaluated with the two antibodies.

Discussion

Many adenoviral anticancer agents utilize the high-affinity receptor for subgroup C adenoviruses, CAR, to attach to target cells. Presence of the receptor on tumor cells is therefore an important factor determining the antitumor activity of these agents. Previous investigations of CAR expression in breast, urothelial, and prostate cancer suggested that the receptor is frequently lost in these cancer types,[6–8] which likely contributes to resistance to adenovirus infection. Since gastrointestinal tumors represent an important target for adenovirus-based therapies information about the expression of CAR in normal and malignant gastrointestinal tissues is essential for the future clinical development of adenoviral agents. Therefore, we studied the expression of the receptor in the normal gastrointestinal tissues and the most frequent gastrointestinal cancer types, including esophageal, colorectal, liver and pancreatic. In all tumor types we found a significant correlation of CAR expression and histological differentiation.

The four tumor types represented in this study have been subject of clinical trials as potential targets for therapeutic adenoviruses. Two major types of such viruses have been designed: replication-incompetent viruses used for delivery of therapeutic transgenes and replication-competent viruses replicating exclusively in tumor cells with specific molecular characteristics. An example of the former approach used in gastrointestinal cancer is TNFerade, a non-replicating adenovirus expressing TNF-α under the control of the early growth response-1 promoter, which is activated by ionizing radiation. Clinical studies testing intratumoral injection of this virus in combination with chemoradiation therapy are currently ongoing in patients with pancreatic cancer. First results have demonstrated safety and potential clinical activity.[10] Oncolytic adenoviruses such as ONYX-015, which replicates preferentially in cells lacking functional p53, were administered intratumorally, by hepatic artery infusion (HAI), or intravenously.[3,11–16] H101, an analogue of ONYX-015, has recently been approved for the use in head-and-neck cancer in China. Unfortunately, the clinical trials of ONYX-015 in gastrointestinal cancers performed in the United States showed generally low response rates. For example, only 11% of patients with gastrointestinal cancers metastatic to the liver treated with HAI of ONYX-015 (in combination with 5-fluorouracil chemotherapy) experienced objective tumor responses.[3] However, strong evidence for intra-tumoral virus replication was found in a subset of patients.[3] Furthermore, detailed subgroup analysis of the radiologic responses of patients with liver metastases from colorectal cancer who had failed prior chemotherapy showed frequent diseases stabilization following intrahepatic administration of

ONYX-015.[17] While these data provide a promising proof of concept, it has become apparent that host-specific factors might limit the antitumor activity of such viruses.

Our finding of frequent loss of CAR expression in gastrointestinal cancers suggests a possible mechanism underlying the limited clinical activity of therapeutic adenoviruses and are in agreement with findings in prostate, urothelial and breast cancer.[6–8] This is supported by cell line data and preclinical studies suggesting that loss of the receptor leads to reduced susceptibility to adenovirus infection.[4,18–20] Conversely, transgenic mouse models expressing CAR in all tissues allowed for adenovirus infection of previously inaccessible tissue types.[21] However, it is noteworthy, that adenovirus might use alternative receptors for attachment and entry, such as heparan sulfate glycosaminoglycans (see below).

Loss of epithelial cell–cell adhesion molecules during cancer progression is a well-documented phenomenon. For example, expression of the adherens-junction protein E-cadherin is frequently lost in solid tumors, including breast and colon cancers, where it correlates with poor clinical outcome.[22,23] While the exact molecular mechanisms leading to loss of CAR expression remain unclear, data from others and our laboratory suggest mechanisms underlying loss of CAR expression, such as promoter hypermethylation and repression through activation of Raf-MEK-ERK and TGFβ signaling.[24–28] Thus, pharmacological receptor restoration using inhibitors of these pathways may increase the efficiency of adenovirus agents *in vivo*.[25,27] An alternative route to overcome CAR-dependent intrinsic resistance to adenovirus infection has been developed that is based on modifying adenovirus capsid proteins in order to retarget the virus to other receptors that are more consistently expressed on cancer cells. An example of such virus is the Delta-24-arginine–glycine–aspartate (RGD)-adenovirus, which has been engineered to express RGD sequences in the knob protein, resulting in preferred binding to integrins.[29] Clinical trials with this virus are planned.

This study also provides insights into normal patterns of CAR expression in gastrointestinal tissues. The preferential expression of CAR at sites of cell–cell contact of hepatocytes and its absence at the sinusoidal surface suggests that the receptor might not be readily accessible to adenovirus circulating in the bloodstream. This is in agreement with studies in mice that demonstrated CAR-independent uptake of adenovirus by hepatocytes mediated by heparan sulfate glycosaminoglycans.[30] We have described this finding before in the context of the limited hepatotoxicity of systemically administered ONYX-015, which might be influenced by changing accessibility of CAR with repeated virus administrations.[9] In agreement with CAR's function as a tight-junction protein, we found particularly strong expression of the protein around liver canaliculi, bile ducts and pancreatic ducts. Whether alterations of the integrity of protein complexes involving CAR at the cell surface might play a pathogenetic role in the development of chronic inflammatory processes such as cholangitis or pancreatitis is currently unclear and subject of investigation.

In summary, we characterized expression of CAR in normal gastrointestinal tissues and documented frequent loss of CAR expression in gastrointestinal cancer. In contrast to previous studies of CAR expression in different tumor types, we used a commercially available polyclonal antibody directed against CAR that demonstrated expression patterns identical to those observed with the proprietary antibody used in our previous studies.[7,8] Thus, routine assessment for CAR expression in tumor samples in future clinical studies of adenoviral agents expressing the wild-type fiber–knob protein is feasible and recommended for patient stratification.

Acknowledgements

We thank Dr Montgomery Bissell and Tina Korn for critical reading of the manuscript. This work was supported by NIH/National Cancer Institute Grants: P30 CA82103, P30 DK26743, P50CA89520, 5R25GM59298-02 (graduate fellowship to MM), and the UCSF Hellman Family Award.

References

1 Parkin DM, Bray FI, Devesa SS. Cancer burden in the year 2000. The global picture. *Eur J Cancer* 2001; **37**(Suppl 8): S4–S66.
2 Chu RL, Post DE, Khuri FR, Van Meir EG. Use of replicating oncolytic adenoviruses in combination therapy for cancer. *Clin Cancer Res* 2004; **10**: 5299–5312.
3 Reid T, Galanis E, Abbruzzese J, Sze D, Wein LM, Andrews J *et al*. Hepatic arterial infusion of a replication-selective oncolytic adenovirus (dl1520): phase II viral, immunologic, and clinical endpoints. *Cancer Res* 2002; **62**: 6070–6079.
4 Bergelson JM, Cunningham JA, Droguett G, Kurt-Jones EA, Krithivas A, Hong JS *et al*. Isolation of a common receptor for Coxsackie B viruses and adenoviruses 2 and 5. *Science* 1997; **275**: 1320–1323.
5 Cohen CJ, Shieh JT, Pickles RJ, Okegawa T, Hsieh JT, Bergelson JM. The coxsackievirus and adenovirus receptor is a transmembrane component of the tight junction. *Proc Natl Acad Sci USA* 2001; **98**: 15191–15196.
6 Sachs MD, Rauen KA, Ramamurthy M, Dodson JL, De Marzo AM, Putzi MJ *et al*. Integrin alpha(v) and coxsackie adenovirus receptor expression in clinical bladder cancer. *Urology* 2002; **60**: 531–536.
7 Rauen KA, Sudilovsky D, Le JL, Chew KL, Hann B, Weinberg V *et al*. Expression of the coxsackie adenovirus receptor in normal prostate and in primary and metastatic prostate carcinoma: potential relevance to gene therapy. *Cancer Res* 2002; **62**: 3812–3818.
8 Anders M, Hansen R, Ding RX, Rauen KA, Bissell MJ, Korn WM. Disruption of 3D tissue integrity facilitates adenovirus infection by deregulating the coxsackievirus and adenovirus receptor. *Proc Natl Acad Sci USA* 2003; **100**: 1943–1948.
9 Au T, Thorne S, Korn WM, Sze D, Kirn D, Reid T. Minimal hepatic toxicity following infusion of adenoviral vector: spatial restriction of CAR receptor in normal liver. *Cancer Gene Ther* 2006 (in press).

10 Senzer N, Hanna N, Chung T, Nemunaitis J, Rosemurgy A, Javle M *et al*. Updated response and survival data for TNFerade combined with chemoradiation in the treatment of locally advanced pancreatic cancer (LAPC). Paper presented at: Proc Am Soc Clin Oncology, 2005, Orlando.
11 Sangro B, Mazzolini G, Ruiz J, Herraiz M, Quiroga J, Herrero I *et al*. Phase I trial of intratumoral injection of an adenovirus encoding interleukin-12 for advanced digestive tumors. *J Clin Oncol* 2004; **22**: 1389–1397.
12 Venook AP, Warren RS. Therapeutic approaches to metastasis confined to the liver. *Curr Oncol Rep* 2001; **3**: 109–115.
13 Hecht JR, Bedford R, Abbruzzese JL, Lahoti S, Lee M, Kirn DH. A phase I/II trial of intratumoral endoscopic ultrasound (EUS) injection of Onyx-015 with intravenous gemcitabine in unresectable pancreatic carcinoma. Paper presented at: Proc Am Assoc Clin Oncol, 2000.
14 Mulvihill S, Warren R, Venook A, Adler A, Randlev B, Heise C *et al*. Safety and feasibility of injection with an E1B-55 kDa gene-deleted, replication-selective adenovirus (ONYX-015) into primary carcinomas of the pancreas: a phase I trial. *Gene Therapy* 2001; **8**: 308–315.
15 Reid T, Galanis E, Abbruzzese J, Sze D, Andrews J, Romel L *et al*. Intra-arterial administration of a replication-selective adenovirus (dl1520) in patients with colorectal carcinoma metastatic to the liver: a phase I trial. *Gene Therapy* 2001; **8**: 1618–1626.
16 Warren RS, Kirn DH. Liver-directed viral therapy for cancer p53-targeted adenoviruses and beyond. *Surg Oncol Clin N Am* 2002; **11**: 571–588, vi.
17 Reid TR, Freeman S, Post L, McCormick F, Sze DY. Effects of Onyx-015 among metastatic colorectal cancer patients that have failed prior treatment with 5-FU/leucovorin. *Cancer Gene Ther* 2005; **12**: 673–681.
18 Douglas JT, Kim M, Sumerel LA, Carey DE, Curiel DT. Efficient oncolysis by a replicating adenovirus (ad) *in vivo* is critically dependent on tumor expression of primary ad receptors. *Cancer Res* 2001; **61**: 813–817.
19 Li Y, Pong RC, Bergelson JM, Hall MC, Sagalowsky AI, Tseng CP *et al*. Loss of adenoviral receptor expression in human bladder cancer cells: a potential impact on the efficacy of gene therapy. *Cancer Res* 1999; **59**: 325–330.
20 Okegawa T, Li Y, Pong RC, Bergelson JM, Zhou J, Hsieh JT. The dual impact of coxsackie and adenovirus receptor expression on human prostate cancer gene therapy. *Cancer Res* 2000; **60**: 5031–5036.
21 Tallone T, Malin S, Samuelsson A, Wilbertz J, Miyahara M, Okamoto K *et al*. A mouse model for adenovirus gene delivery. *Proc Natl Acad Sci USA* 2001; **98**: 7910–7915.
22 Pedersen KB, Nesland JM, Fodstad O, Maelandsmo GM. Expression of S100A4, E-cadherin, alpha- and beta-catenin in breast cancer biopsies. *Br J Cancer* 2002; **87**: 1281–1286.
23 Kanazawa T, Watanabe T, Kazama S, Tada T, Koketsu S, Nagawa H. Poorly differentiated adenocarcinoma and mucinous carcinoma of the colon and rectum show higher rates of loss of heterozygosity and loss of E-cadherin expression due to methylation of promoter region. *Int J Cancer* 2002; **102**: 225–229.
24 Pong RC, Lai YJ, Chen H, Okegawa T, Frenkel E, Sagalowsky A *et al*. Epigenetic regulation of coxsackie and adenovirus receptor (CAR) gene promoter in urogenital cancer cells. *Cancer Res* 2003; **63**: 8680–8686.
25 Kitazono M, Goldsmith ME, Aikou T, Bates S, Fojo T. Enhanced adenovirus transgene expression in malignant cells treated with the histone deacetylase inhibitor FR901228. *Cancer Res* 2001; **61**: 6328–6330.
26 Bruning A, Runnebaum IB. The coxsackie adenovirus receptor inhibits cancer cell migration. *Exp Cell Res* 2004; **298**: 624–631.
27 Anders M, Christian C, McMahon M, McCormick F, Korn WM. Inhibition of the Raf/MEK/ERK pathway up-regulates expression of the coxsackievirus and adenovirus receptor in cancer cells. *Cancer Res* 2003; **63**: 2088–2095.
28 Lacher MD, Tiirikainen MI, Saunier EF, Christian C, Anders M, Oft M *et al*. TGF-beta receptor inhibition enhances adenoviral infectability of carcinoma cells via up-regulation of CAR in conjunction with reversal of epithelial–mesenchymal-transition. *Cancer Res* 2006; **66**: 1648–1657.
29 Fueyo J, Alemany R, Gomez-Manzano C, Fuller GN, Khan A, Conrad CA *et al*. Preclinical characterization of the antiglioma activity of a tropism-enhanced adenovirus targeted to the retinoblastoma pathway. *J Natl Cancer Inst* 2003; **95**: 652–660.
30 Smith TA, Idamakanti N, Marshall-Neff J, Rollence ML, Wright P, Kaloss M *et al*. Receptor interactions involved in adenoviral-mediated gene delivery after systemic administration in non-human primates. *Hum Gene Ther* 2003; **14**: 1595–1604.