Case 282

Amir H. Davarpanah, MD • *Linton W. Eberhardt, MD*

From the Department of Radiology and Imaging Sciences, Emory University School of Medicine, Emory University Hospital, 1364 Clifton Rd NE, Atlanta, GA 30322. Received February 25, 2019; revision requested April 5; revision received April 22; accepted April 24. **Address correspondence to** A.H.D. (e-mail: *amir.davarpanah@emory.edu*).

Conflicts of interest are listed at the end of this article.

Radiology 2020; 295:733–735 • **https://doi.org/10.1148/radiol.2020190435** • **Content code: GI** • ©RSNA, 2020

History A 63-year-old woman with a history of left mastectomy for breast cancer and partial gastrectomy with Roux-en-Y reconstruction for nonhealing peptic ulcer presented to the emergency department and reported a 1-month history of abdominal distention, fevers, chills, and flu-like symptoms. She was initially suspected of having flu, and she completed a course of oseltamivir; however, she had continued fatigue, fever, chills, abdominal bloating, and loss of appetite. She reported no contact with a sick person or recent travel. At admission, laboratory studies revealed leukocytosis, with a white blood cell count of 15.1 × 10^3/μL (15.1 × 10^9/L) (normal range, 4.0–10.0 × 10^3/μL [4.0–10.0 × 10^9/L]), an elevated sedimentation rate of 100 mm per hour (normal range, 0–30 mm per hour), and a C-reactive protein level of 203.8 mg/L (1940.9 nmol/L) (normal range, ≤10 mg/L [≤95.2 nmol/L]). Liver enzyme levels were elevated, with an alanine aminotransferase level of 48 U/L (0.80 μkat/L) (normal range, 0–29 U/L [0–0.48 μkat/L]), an aspartate aminotransferase level of 98 U/L (1.6 μkat/L) (normal range, 10–37 U/L [0.16–0.62 μkat/L]), an alkaline phosphatase level of 682 U/L (11.4 μkat/L) (normal range, 65–195 U/L [1.1–3.3 μkat/L]), and a total bilirubin level of 1.5 mg/dL (25.7 μmol/L) (normal range, 0.3–1.0 mg/dL [5.1–17.1 μmol/L]). Abdominopelvic CT was performed (Figs 1–3).

2020 Diagnosis Please Learning Objectives

In submitting a diagnosis for this case, participants demonstrate the ability to

- Recognize normal and abnormal findings as presented in the diagnostic images
- Identify pathologic conditions indicated in the diagnostic images
- Use clinical reasoning skills to generate a list of differential diagnoses

Accreditation and Designation Statement

The RSNA is accredited by the Accreditation Council for Continuing Medical Education (ACCME) to provide continuing medical education for physicians. The RSNA designates this journal-based CME activity for a maximum of 1.0 *AMA PRA Category 1 Credit*™. Physicians should claim only the credit commensurate with the extent of their participation in the activity.

Disclosure Statement

The ACCME requires that the RSNA, as an accredited provider of CME, obtain signed disclosure statements from authors, editors, and reviewers for this case. For this educational activity the authors, editors, and reviewers have indicated that they have no relevant relationships to disclose.

Submit Diagnosis

Submit the most likely diagnosis to *http://rsna.org/dxplease* (use only for submission of diagnosis). Select the case from the Active Case List for which you are submitting a diagnosis. Only one case, one name, and one diagnosis per e-mail submission. Multiple diagnoses and multiple submissions will not be considered. ***Deadline:*** Midnight U.S. Central Time, August 10, 2020. Answer will appear in the October 2020 issue. Authors wishing to submit cases for Diagnosis Please should first write to the Editor to obtain approval for the case and further information.

This copy is for personal use only. To order printed copies, contact *reprints@rsna.org*

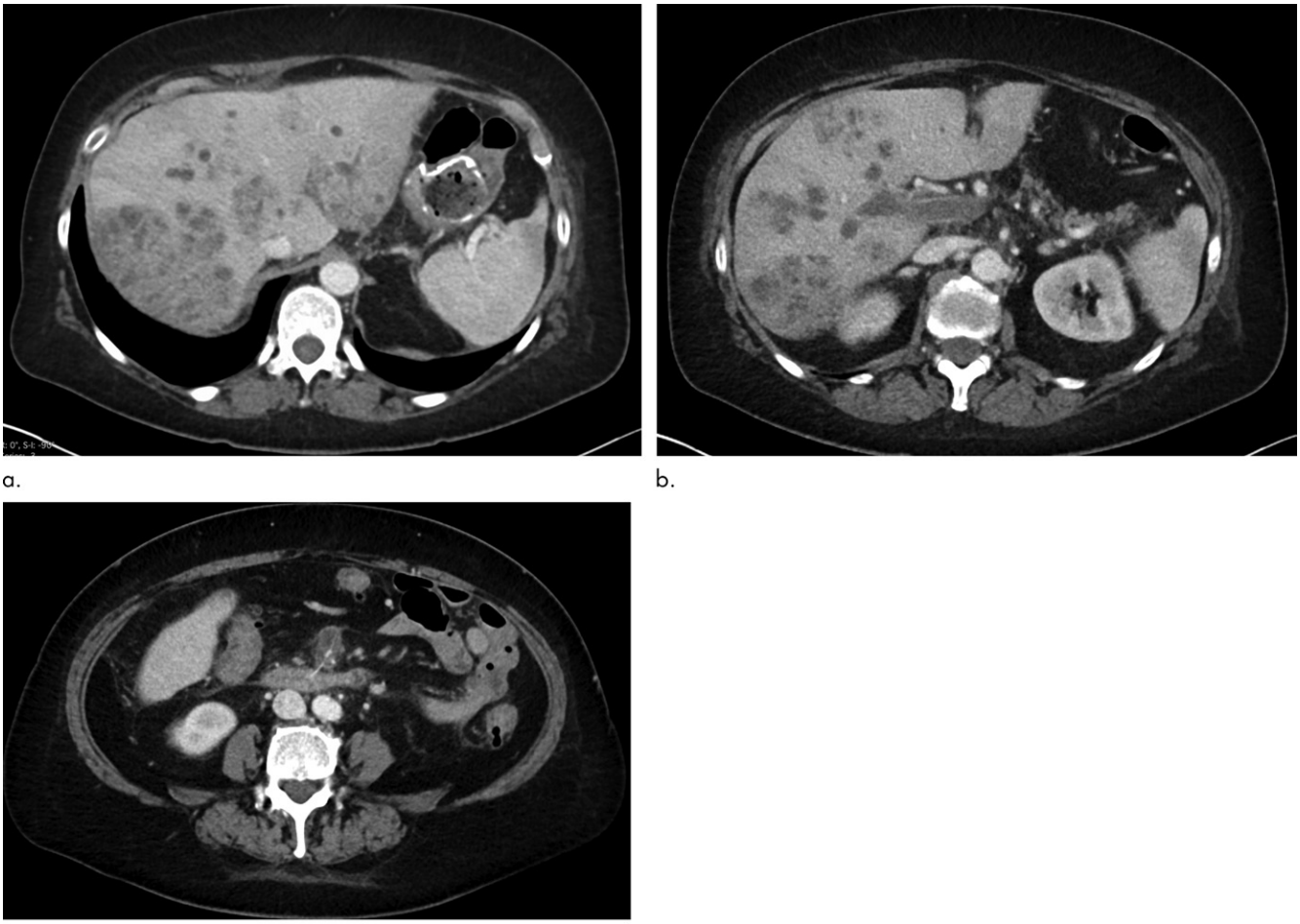

a. b. c.

Figure 1: **(a–c)** Axial contrast material–enhanced (130 mL of Iohexol 350) portal venous phase abdominopelvic CT images.

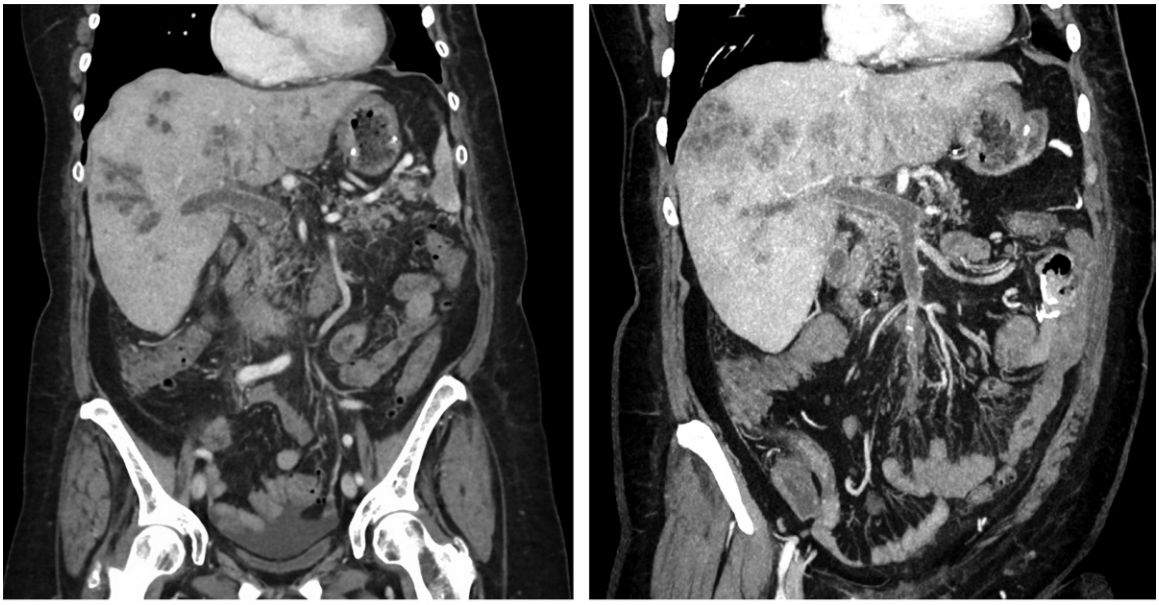

a. b.

Figure 2: **(a, b)** Coronal contrast-enhanced (130 mL of Iohexol 350) portal venous phase abdominopelvic CT images.

Figure 3: Sagittal contrast-enhanced (130 mL of Iohexol 350) portal venous phase abdominopelvic CT image.

Disclosures of Conflicts of Interest: **A.H.D.** disclosed no relevant relationships.
L.W.E. disclosed no relevant relationships.