JAMA Surgery | Review

Diagnosis and Management of Hemodialysis Access Complications
A Review

Mikayla Hurwitz, MD; Quynh-Anh Dang, MD; Salvatore Scali, MD; Nina Bowens, MD; Karen Woo, MD; Christian de Virgilio, MD

IMPORTANCE More than 100 000 patients in the US begin hemodialysis each year. While arteriovenous fistulas (AVFs) have been the preferred dialysis access due to their durability and lower complication rates, contemporary guidelines now emphasize achieving a functional access tailored to individual patient needs. Prosthetic arteriovenous grafts (AVGs) remain a critical alternative for patients with suboptimal autogenous options. Given the essential role of hemodialysis access in patient survival, both surgeons and nonsurgeons must be familiar with the unique challenges of placing and maintaining AVFs and AVGs. This review highlights common complications associated with each access type and evidence-based management strategies.

OBSERVATIONS Complications of arteriovenous (AV) access can manifest at varying time points, ranging from the immediate postoperative period to months or years later due to long-term sequelae of altered hemodynamics and repeated cannulation. Determining whether symptoms, such as pain, weakness, paresthesia, and hand dysfunction, are due to the AV access or simply due to outcomes of kidney failure can be extremely challenging, emphasizing the importance of a detailed patient history, comprehensive physical examination, and duplex imaging. Certain complications, including access-related hand ischemia (ie, steal syndrome), carpal tunnel syndrome, ulnar neuropathy, aneurysms, and pseudoaneurysms, have multiple treatment options that span conservative management, open surgery, and endovascular procedures. Treatment decisions should consider patient comorbidities, anatomical factors, the risk of access site loss, and the availability of alternate access sites. Other complications, such as ischemic monomelic neuropathy, persistent bleeding, and high-output heart failure, require urgent intervention to prevent loss of limb or life.

CONCLUSIONS AND RELEVANCE Patients with upper-extremity AVF and AVG can face a number of access-related complications. Understanding the diagnostic evaluation and treatment options is essential to balance preserving access longevity while minimizing the risk of short and long-term morbidity and mortality.

JAMA Surg. doi:10.1001/jamasurg.2025.4701
Published online November 5, 2025.

CME at jamacmelookup.com

Author Affiliations: Department of Surgery, Harbor-UCLA Medical Center, Torrance, California (Hurwitz, Bowens, de Virgilio); Division of Vascular and Endovascular Surgery, Department of Surgery, Massachusetts General Hospital, Boston (Dang); Division of Vascular Surgery and Endovascular Therapy, Department of Surgery, University of Florida College of Medicine, Gainesville (Scali); Division of Vascular Surgery, Department of Surgery, David Geffen School of Medicine at the University of California, Los Angeles (Bowens, Woo); The Lundquist Institute, Torrance, California (de Virgilio).

Corresponding Author: Mikayla Hurwitz, MD, Department of Surgery, Harbor-UCLA Medical Center, 1000 W Carson St, Torrance, CA 90509 (mhurwitz@dhs.lacounty.gov).

More than 500 000 patients in the US are hemodialysis (HD) dependent, with more than 100 000 initiating treatment annually between 2015 and 2020.[1] Arteriovenous fistulas (AVFs) have been the preferred dialysis access method, but contemporary guidelines now emphasize achieving a functional access tailored to individual patient needs and prosthetic arteriovenous grafts (AVGs) remain a critical alternative for patients with suboptimal autogenous options.[2] Clinicians need to be aware of the more common complications associated with AV access. Generating a comprehensive differential diagnosis and understanding treatment options for issues such as new neurologic hand symptoms, access site bleeding, infection, and aneurysm formation are critical to appropriate management. This review summarizes current knowledge and recommended strategies for managing well-recognized complications associated with AV access.

Hand Pain, Numbness, and Weakness

Following AV access creation, new neurovascular symptoms of the hand, such as coolness, pain, numbness, or weakness, warrant prompt attention. The initial evaluation should include a careful history and neurovascular examination, focusing on peripheral pulses and motor and sensory testing to detect any deficits of the median, ulnar, and radial nerves. The differential diagnosis can include a number of conditions (**Table 1**).

Access-Related Hand Ischemia

Access-related hand ischemia (ARHI), commonly known as dialysis-access associated steal syndrome, occurs in 1% to 20% of patients

© 2025 American Medical Association. All rights reserved, including those for text and data mining, AI training, and similar technologies.

Table 1. Differentiating Between Access-Related Hand Ischemia, Carpal Tunnel Syndrome, and Ischemic Monomelic Neuropathy

Diagnosis	History	Physical examination	Diagnostic tests
Access-related hand ischemia (steal syndrome)	Pain and paresthesia starting in fingertips; can progress to weakness and eventual tissue loss; worse with dialysis/exertion	Decreased/absent distal pulse improves with access compression; hand coolness; tissue loss and gangrene; sensation and motor deficits that start distally	Duplex ultrasound with high flow rates >800 mL/min or reversal of arterial flow; reduced digital pressures and digital-brachial indices that improve with access compression
Carpal tunnel syndrome	Pain and paresthesia in median nerve distribution; worse at night or early morning	Tinel sign (percussing the median nerve at the wrist elicits symptoms); Phalen sign (flexing both wrists and placing dorsal sides of the hands together for 1 min elicits symptoms); atrophy of thenar eminence; weakness in thumb opposition and abduction	Nerve conduction studies confirming prolonged median nerve latencies
Ischemic monomelic neuropathy	Pain, paresthesia and weakness of forearm and hand; occurs within minutes to hours of access creation	Palpable distal pulse, warm and well-perfused extremity; global sensory and motor deficits	Normal hemodynamics (ie, wrist brachial index/finger pressures)
Acute limb ischemia (iatrogenic intraoperative clamp injury, thromboembolism, artery dissection)	Pain, coolness, numbness	Absent distal pulses, poorly perfused hand	Duplex scan or angiography

Table 2. Grades of Access-Related Hand Ischemia

Grade	Symptom	Management recommendation
0	Asymptomatic	No intervention
I	Mild/intermittent symptoms with dialysis/exertion	Surveillance only
II	Symptoms at rest	Intervention if life-style limiting
III	Tissue loss	Intervention required

after AV access creation. About 1% to 9% require surgical treatment.[3-8] Three pathophysiological factors contribute to ARHI—arterial occlusive disease in the inflow (ie, proximal to the AV anastomosis) or outflow (ie, distal to the AV anastomosis) vessels, the increased blood flow through the AV access, and failure of the distal arterial collateral networks to adapt to decreased perfusion. Risk factors include peripheral vascular disease, coronary artery disease, diabetes, advanced age, female sex, brachial artery-based inflow, multiple prior AV access procedures, and history of ARHI.[3,4,8,9]

The risk of ARHI may be mitigated by using strategies that limit inflow, such as minimizing arteriotomy size or avoiding distal brachial artery-based access when feasible.[10,11] The time to onset of ARHI differs between AVFs and AVGs. Symptoms after AVG creation tend to occur early, since the graft already has a large diameter, whereas AVF symptoms are delayed as the vein slowly dilates.[12]

The diagnosis of ARHI is predominantly based on history and physical examination. Symptoms range from extremity coolness and paresthesia to muscle weakness, rest pain, ulceration, and tissue loss.[2,13] Symptoms may be present only during dialysis, exacerbated by dialysis, or be persistent. A simple grading system is used to classify severity (**Table 2**). On physical examination, patients typically have hand coolness, pallor, sluggish capillary refill, diminished or absent distal pulses and dampened Doppler signals, all of which should improve with AV access compression.

Noninvasive diagnostic testing can assist in evaluation and treatment of ARHI. Duplex ultrasonography assesses for arterial stenosis or occlusion and identifies the presence of retrograde flow from the distal artery into the AV access, suggesting ARHI. However, retrograde flow can occur in asymptomatic patients.[14] Duplex also measures whether the circuit is high flow vs normal or low flow. High flows are defined as greater than 800 mL/min in autogenous access and >1200 mL/min in nonautogenous access. Digital plethysmography, digital pressures, and digital-brachial indices, which compares systolic blood pressure in the fingers to the brachial artery, can also facilitate the diagnosis.[6,15-17] A basal digital pressure less than 80 mm Hg and a digital-brachial index less than 0.6 to 0.7 have been found to be associated with ARHI; however, standardized thresholds predicting ischemia are lacking.[17,18] Patients with ARHI may demonstrate decreased digital pressures and dampened waveforms compared to the unaffected limb, which improve with compression of the AV access. Catheter-based angiography latter allows for both visualization and planning potential intervention.

ARHI treatment varies by etiology and symptom severity (**Table 3**[2,3,7,19-28]). Mild cases may resolve spontaneously or remain tolerable with expectant management. Invasive treatment is recommended for lifestyle limiting grade II and all cases of grade III ARHI (**Figure 1**).

If arterial inflow obstruction is found, endovascular angioplasty (with or without stent placement) is preferred. For patients with high-flow ARHI, a simple option is to perform banding or plication. AVF banding involves wrapping a constrictive synthetic cuff around the conduit, while plication uses a running stitch to narrow the vein lumen near the anastomosis. Plication has reported success rates of 92% to 100% in brachial-based AVFs.[19,20] The 30-day mortality is as high as 3.8%, although others using local anesthesia have reported no mortality.[20,29] Since AVGs require increased flow rates compared to AVFs to maintain patency, banding may not be suitable for AVGs.[30] Thus, banding is best for patients with less se-

© 2025 American Medical Association. All rights reserved, including those for text and data mining, AI training, and similar technologies.

Table 3. Surgical Management of Access-Related Hand Ischemia

Revision type	Mechanism	Ideal indication	Symptom resolution, %	Primary patency at 1 y, %	Benefits	Risks
Banding	Narrows vein/graft lumen to decrease flow volume	Poor surgical candidates; less severe steal symptoms; high flow volumes; large dilated arteriovenous fistula	67-81[2,3]	91	Simple and quick procedure using local anesthesia	Overplication may lead to thrombosis (especially with arteriovenous grafts); underplication may not resolve symptoms
Plication			92-100[19,20]	80[7]		
Distal revascularization with interval ligation	Reduced inflow to arteriovenous fistula/arteriovenous grafts; prevention of retrograde flow	Suitable autogenous vein conduit, adequate distal target; severe steal with tissue loss; good operative risk high or normal flow volumes	78-98.5[21-24]	55-95[22-24]	Protects flow of fistula/graft; most likely to relieve symptoms of severe steal	Interrupts native proximal arterial flow; risk of bypass thrombosis with hand extremity ischemia; need to harvest saphenous vein; procedure length; usually requires general anesthesia
Revascularization using distal inflow	Increased circuit resistance; proximal arteries with uninterrupted antegrade flow	Nondiseased radial/ulnar as inflow artery; high flow volumes	90-100[24-26]	58-74[24-26]	Maintains flow native arterial circulation; additional forearm cannulation segment	Bypass thrombosis threatens arteriovenous fistula/arteriovenous grafts patency; small radial/ulnar arteries risk technical errors and thrombosis
Proximalization of arterial inflow	Increased circuit resistance; larger diameter inflow artery increases arterial inflow volume	No suitable vein conduits and preexisting distal arterial disease (precludes distal revascularization with interval ligation); high or normal flow volumes	84-85.9[27,28]	81-87[27,28]	Maintains flow through native arterial circulation	Bypass thrombosis threatens arteriovenous fistula/arteriovenous grafts patency; requires prosthetic graft

Figure 1. Management of Access-Related Hand Ischemia (ARHI)

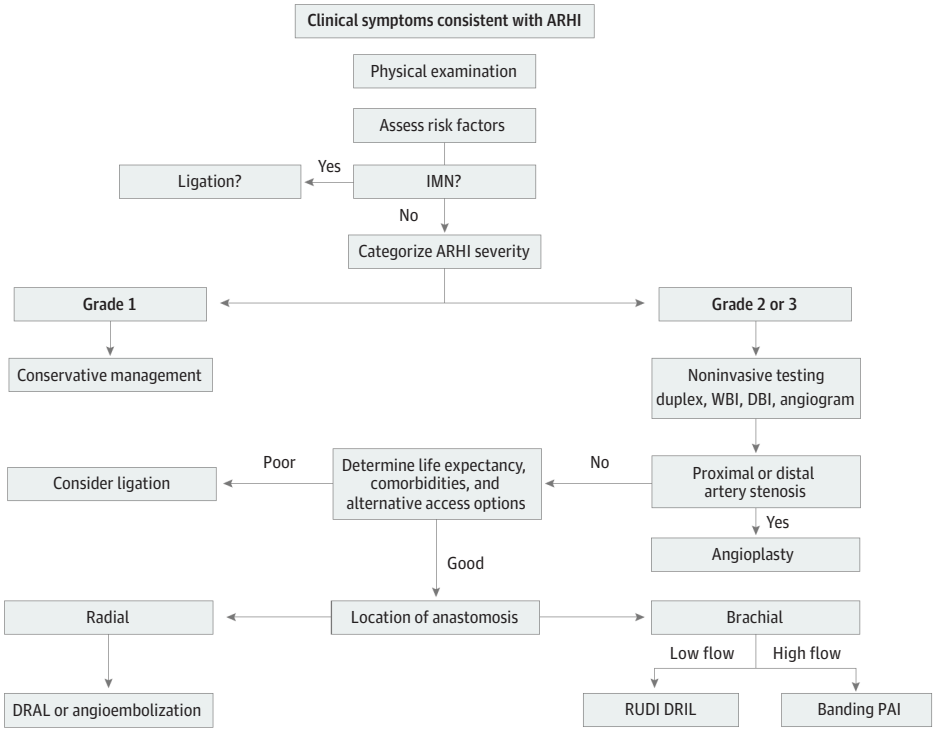

DBI indicates digital-brachial index; DRAL, distal radial artery ligation; DRIL, distal revascularization with interval ligation; IMN, ischemic monomelic neuropathy; PAI, proximalization of arterial inflow; RUDI, revascularization using distal inflow; WBI, wrist brachial index.

vere steal symptoms who have high-flow AVFs. Intraoperative flow monitoring using flowmeters or pulse volume recordings can also be used to better gauge how much to narrow the vein.[19,30]

Several strategies designed to reroute arterial perfusion can be used to treat ARHI. Distal revascularization with interval ligation (DRIL) involves creation of a bypass between arterial segments proxi-

© 2025 American Medical Association. All rights reserved, including those for text and data mining, AI training, and similar technologies.

Figure 2. Distal Revascularization With Interval Ligation (DRIL), Revascularization Using Distal Inflow (RUDI), and Proximalization of Arterial Inflow (PAI)

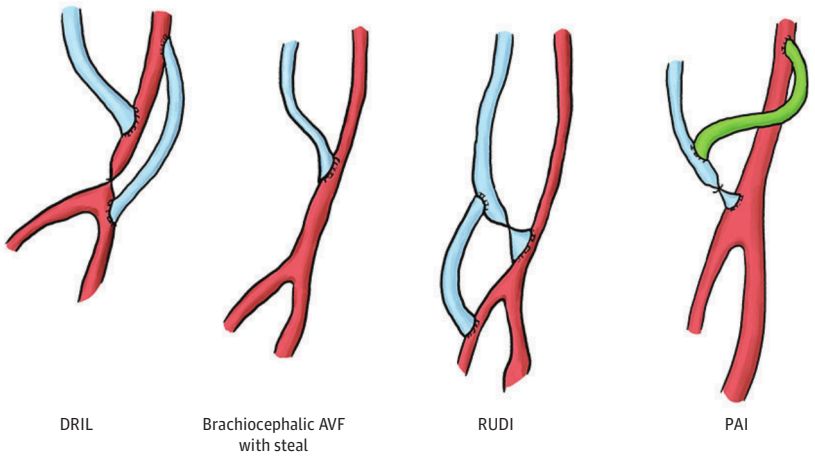

AVF indicates arteriovenous fistula.

mal and distal to the AV anastomosis, with ligation of the native artery between the AV anastomosis and the distal anastomosis of the bypass (**Figure 2**). Patients should have a preoperative angiogram for planning. Reversed saphenous vein is the preferred conduit. Arm vein or prosthetic grafts are viable alternatives if needed, but prosthetic material carries higher risk of thrombosis.[21] The proximal bypass anastomosis should be at least 7 to 10 cm proximal to the AV anastomosis to avoid interaction with the pressure sink from the ligated artery, which can precipitate bypass thrombosis. Primary patency at 1 year has been reported to range from 55% to 95%, with autogenous conduits being associated with improved patency rates.[22-24] Immediate symptom resolution and functional fistula patency is as high as 81% at a median follow-up of 22.2 months. The patient's preoperative risk should be considered, since DRIL is a longer operation and involves vein harvesting. The 30-day mortality after DRIL has been reported as high as 2.0% to 6.8%.[24,29] A theoretical concern with DRIL is hand ischemia if the bypass thromboses. However, prior studies have shown that the rate of upper-extremity ischemia is low.

Revascularization using distal inflow (RUDI) involves the use of a conduit to connect the AVF outflow vein to a more distal artery, with subsequent ligation of the original fistula adjacent to the anastomosis (Figure 2). RUDI increases access length and uses a smaller, lower flow artery for inflow, thus raising resistance and lowering fistula flow. Additionally, RUDI has the added advantage of providing an additional cannulation segment in the forearm, The radial or ulnar artery (if ≥2 mm) is selected based on preoperative duplex, with the dominant vessel spared to preserve uninterrupted antegrade perfusion to distal arterial beds. Autogenous and nonautogenous conduits have shown similar patency rates, with symptom resolution rates of 90% to 100% and primary patency of 58% to 74% at 1 year.[24-26] Thirty-day mortality following RUDI has been reported as 3% to 5%.[24,29] In brachial-based AVFs with grade III steal, RUDI and DRIL show comparable patency, reintervention, and symptom resolution rates.

PAI uses a conduit to reroute inflow proximally and defunctionalizes the original, more distal brachial–based AV anastomosis. Reconstruction typically uses grafts, and a tapered 4- to 7-mm expanded polytetrafluoroethylene conduit is often used, particularly in high-flow ARHI presentations. Saphenous vein can be used when there is hand tissue loss or concern for infection but carries the risk of vein dilatation and increased flow.[27] One-year primary patency rates range from 81% to 87%, with symptom resolution in 84% to 86% of patients.[27,28] In a study comparing surgical management of ARHI, PAI was found to have a 30-day mortality rate of 0%.[29] PAI is a reasonable option for patients with diseased radial and ulnar arteries that are unsuitable for DRIL or RUDI.

For radial artery–based forearm AV access, distal radial artery ligation (DRAL) may be used. This involves ligation of the radial artery distal to the arteriovenous anastomosis to prevent retrograde flow. Prior to DRAL, patency of the palmar arch should be determined dynamically via the Allen test and Doppler signal while compressing the radial artery. Duplex evaluation of the ulnar artery and digit pressures with radial artery compression should also be used to evaluate tolerance of DRAL. A recent retrospective cohort study found that DRAL can result in significant symptom improvement (82.1%) with low risk of access thrombosis (3.2%).[31]

The most radical treatment for ARHI is ligation of the AV access. Ligation is typically reserved for patients with severe grade III steal, failure of the previously discussed surgical treatments, or limited life expectancy.

Ischemic Monomelic Neuropathy

An extremely rare but important complication of dialysis access is ischemic monomelic neuropathy (IMN), a form of ARHI with an estimated incidence of 0.1% to 0.5%.[8,32] Patients with IMN develop severe sensorimotor dysfunction within hours after AV access creation, typically presenting with deep, constant, and severe burning pain in the distal forearm and hand after brachial-based AV access.[32,33] Sensory loss, weakness, and even hand paralysis may occur. IMN is associated with diabetes, peripheral vascular disease, and preexisting peripheral neuropathy.[32] It is thought to be caused by acute shunting of blood from the distal extremity, causing nerve ischemia and axonal loss.[33] Diagnosis is often delayed or missed, as

© 2025 American Medical Association. All rights reserved, including those for text and data mining, AI training, and similar technologies.

distal pulses, hand color, and capillary refill can appear normal, misleading clinicians. Furthermore, symptoms may be misattributed to residual effects of regional nerve blocks, postoperative pain, or preexisting neuropathy. The treatment of IMN is immediate ligation of the AV access.[32] Without prompt intervention, IMN leads to permanent sensorimotor loss affecting the median, ulnar, and radial nerves, causing weakness in wrist extension, intrinsic hand muscles, and thumb opposition.

Carpal Tunnel Syndrome

Carpal tunnel syndrome (CTS) is a median nerve neuropathy caused by compression at the wrist, affecting 4% to 5% of people worldwide, primarily those aged 40 to 60 years. Symptoms include pain, numbness, and tingling in the thumb, index, and middle fingers. Risk factors include obesity, repetitive wrist activity, pregnancy, rheumatoid inflammation, and end-stage kidney disease.[34] CTS is 10 times more common in patients undergoing HD, with a prevalence of 2% to 30% regardless of dialysis type, access conduit, or access configuration.[35] While the exact cause remains unclear, amyloidosis-induced mass expansion within the carpal tunnel causing compression of the median nerve is the most accepted theory. Longer dialysis duration is the strongest risk factor for CTS and the need for surgical release. Need for surgical release appears to increase significantly after greater than 10 years of HD and continues to rise with treatment duration.[35] However, CTS can also develop abruptly after AV access creation, possibly due to ischemia or venous hypertension. Moreover, subclinical ARHI or unrecognized central vein stenosis can exacerbate symptoms by increasing venous congestion and swelling.[36]

Diagnosis begins with a thorough history and physical examination, with Tinel sign (paresthesia in the median nerve distribution when the provider lightly taps over the carpal tunnel at the wrist) and positive Phalen maneuver (pain or paresthesia in the median nerve distribution when the patient flexes their wrists and presses the dorsal surfaces of their hands together for 30-60 seconds). Unlike steal, CTS symptoms are restricted to the first 3 radial digits, worsen at night, and do not cause ischemic signs. A nerve conduction study is the most reliable test. Treatment ranges from wrist splinting and physical therapy to surgical decompression. Patients can present with both CTS and ARHI, in which case concurrent carpal tunnel release and access revision should be considered.[37]

Ulnar Neuropathy

Ulnar neuropathy affects 1% to 19% of patients undergoing HD, and presenting symptoms include distal forearm and hand weakness, sensory changes, and in severe cases, ulnar claw hand with functional impairment. HD increases risk due to prolonged arm extension and pronation during dialysis sessions, which can cause ulnar nerve compression. Arteriovenous shunting may contribute to nerve ischemia, while amyloid deposition further predisposes patients to this condition, as with CTS.[38]

Diagnosis is based on sensory and motor deficits in the ulnar distribution, including paresthesia in the little finger, medial hand pain, first dorsal interosseous atrophy, and finger abduction weakness, confirmed by electromyography. Treatment is typically conservative, involving physical therapy, bracing, or steroid injections, although severe cases may require surgical decompression.[38]

Aneurysms

Aneurysmal dilation of an AVF is relatively common, affecting 40% to 60% of patients undergoing HD.[39,40] AVF aneurysms can lead to difficult cannulation, skin thinning, ulceration, bleeding, and poor cosmetic appearance. The primary risk factors are outflow stenosis and repeated cannulation at the same site, both of which weaken the vascular wall.[41] Additional risk factors include polycystic kidney disease and greater than 6 years undergoing HD using a single access.[42]

Evaluation starts with a thorough history to assess for rapid expansion or prolonged postdialysis bleeding, which may indicate pseudoaneurysm or outflow stenosis, respectively. Worrisome physical examination findings include overlying skin that appears shiny, hypopigmented, ulcerated, or adherent to the fistula. Skin adherence can be assessed by attempting to pinch the skin overlying the aneurysm.

Surgical indications fall into 3 symptomatic groups[43]: patient discomfort; risk of rupture or hemorrhage; and access flow issues, further divided into high-flow (risk of ARHI or high-output heart failure) and low-flow (inadequate dialysis circulation) states. Most repairs are performed for risk of rupture or hemorrhage indications, with skin thinning and ulceration being the most common presentation.

Asymptomatic aneurysms do not require repair. However, in symptomatic patients undergoing surgery, up to 90% have concurrent outflow stenosis.[39,40] Catheter-directed venography is recommended prior to surgical repair to diagnose and treat these stenoses, potentially preventing aneurysm recurrence.

Symptomatic AVF aneurysms can be treated with either open or endovascular repair, with open repair preferred due to lower AVF thrombosis rates, reduced need for central venous catheters (CVCs), fewer secondary interventions, and better long-term function.[40] Endovascular repair, typically with a covered stent, requires suitable nonaneurysmal landing zones but may increase risk of cannulation difficulty, infection, and thrombosis.[41]

Open repair options include aneurysmorrhaphy (resecting part of the wall of the vein), resection with primary anastomosis, or interposition grafting, depending on AVF anatomy. Aneurysmorrhaphy is often preferred for its superior long-term patency.[44] Primary patency at 1 year for aneurysmorrhaphy, resection with primary anastomosis, and interposition grafting have been shown to be 86%, 74%, and 64%, respectively.[44] For patients with multiple aneurysmal segments separated by intact access, a staged repair approach can preserve dialysis function while avoiding temporary CVC placement. Typically, 1 segment is repaired and allowed to heal for 2 to 4 weeks before subsequent segments are addressed as needed. Staged repair has been associated with lower early thrombosis rates, fewer secondary interventions, and reduced need for temporary CVCs.[39,45]

© 2025 American Medical Association. All rights reserved, including those for text and data mining, AI training, and similar technologies.

Pseudoaneurysms

Pseudoaneurysms predominantly occur in AVGs from repeated punctures at the same site, which lead to graft degeneration.[46] The overlying skin and subcutaneous tissue then serve as the only barriers to bleeding, making AVGs more prone to major hemorrhage. For this reason, cannulation at the site of the pseudoaneurysm should be avoided. Small pseudoaneurysms can be observed without intervention. Surgical treatment is indicated if the pseudoaneurysm is enlarging, if multiple pseudoaneurysms are present, if available cannulation sites are limited by the pseudoaneurysms, if the integrity of the overlying skin is threatened, or if the patient has associated pain. Pseudoaneurysms may also indicate underlying graft infection, which requires prompt surgical management.

Repair options include open interposition graft placement or endovascular repair with a covered stent. If there is any concern for infection, graft excision is necessary. Open repair remains the gold standard approach, although stent grafting may be a viable and durable option in select cases where an adequate seal zone exists. Endovascular techniques offer the advantages of avoiding temporary CVC placement and allowing concomitant treatment of venous outflow stenoses. However, stent grafting is associated with increased cannulation difficulty, higher infection risk, and greater risk of access thrombosis.[41]

Bleeding AV Access

Bleeding from an AV access can quickly escalate to life-threatening hemorrhage due to the high blood flow through the circuit. Bleeding may result from pseudoaneurysm rupture, overlying skin ulceration, trauma, or compromised AVG integrity due to repeated cannulation at the same site.[47]

The first step in managing AV access bleeding is achieving hemostasis. Firm, direct pressure should be applied using gauze for at least 30 to 40 minutes. Hemostatic dressings and high elasticity compression bandages can reduce bleeding time compared to standard dressings. A bottlecap method has also been described, where the hollow side of a bottlecap is pressed onto the bleeding site and wrapped with a compression dressing, allowing blood to clot within the cap and tamponade the bleeding.[48]

If manual pressure fails, a blood pressure cuff can be inflated proximal to the graft for temporary hemostasis. A shallow figure-8 or purse-string stitch can be placed just beneath the skin to aid hemostasis, taking care to avoid deep placement that could inadvertently ligate the access. If suturing proves ineffective, a tourniquet may be applied proximal to the bleeding site, although it should not be left in place for long to prevent permanent neuromuscular damage.[49] Patients should be urgently evaluated by an access surgeon. Importantly, the figure-8 stitch is a temporizing measure; definitive treatment depends on the cause: AV access with skin compromise or evidence of infection requires revision or ligation, while persistent cannulation site bleeding often indicates venous outflow stenosis and warrants venography with possible endovascular intervention. Coagulopathy should be corrected using agents such as cryoprecipitate, desmopressin, erythropoietin, estrogen, and tranexamic acid.[50]

Infection

The incidence of infection ranges from 0.56% to 5% in AVF and 4% to 20% in AVG.[51] Infections can occur at the time of access creation, after cannulation for dialysis, or because of secondary sources, such as catheter-related infections, endocarditis, osteomyelitis, or bacteremia. Preexisting complications, such as infected hematomas, thrombosed pseudoaneurysms, or seromas, can also contribute. Skin flora introduced through repeated cannulations commonly includes *Staphylococcus*, *Pseudomonas*, or polymicrobial species. *Staphylococcus* and *Pseudomonas* are particularly virulent and more likely to cause anastomotic disruption.[8,51]

Patients may present with pain, warmth, swelling, erythema, induration, drainage, or pus, as well as fever or leukocytosis. Computed tomography (CT) imaging can identify fluid, fat stranding, or air around the graft and define the extent of the infection. Ultrasonography may similarly demonstrate perigraft fluid. Ultrasonography has reported sensitivity and specificity of 34% and 75%, respectively, while CT has reported sensitivity of 67% and specificity of 63% for graft infection. When CT is nondiagnostic, tagged leukocyte scans—with a sensitivity of 90% and specificity of 80%—can aid in diagnosis.[52,53]

Localized superficial AVF infections are typically treated with broad-spectrum antibiotics. If bleeding or infection occurs near the anastomosis, the AVF typically requires ligation or revision with a biologic conduit. For localized AVG infections, partial graft excision with segmental bypass through a clean field is an option. In 1 series of 17 cases, 94% achieved infection eradication and graft salvage within 30 days, although 5 patients later required reexcision.[54] Long-term follow-up showed that 70% of patients retained functional AVGs at a median of 6 months.

Total graft excision is preferred for extensive infection, anastomotic involvement, access occlusion, or infections caused by highly virulent organisms. It is also indicated in cases of recurrent bacteremia without another identifiable source. During excision, the venous end is ligated, and if the arterial anastomosis is intact, a small graft cuff may be left in place and oversewn. However, if the anastomosis is infected, arterial reconstruction with autogenous patch angioplasty or bypass is required.[51] Studies suggest complete graft excision offers superior source control, with no reported reinfections, while partial excision is associated with reinfection rates ranging from 22% to 57.1%.[55-57]

High-Output Heart Failure

The creation of an AV access reduces systemic vascular resistance, which in turn decreases left ventricular afterload and arterial blood volume while increasing sympathetic tone and cardiac output. In some patients, this results in high-output cardiac failure (HOCF). The true incidence of HOCF is unclear and likely underreported, since heart failure is common in patients with end-stage kidney disease and diabetes. Risk factors include preexisting heart failure, brachial artery-based access sites, anastomotic lengths exceeding 4 to 6 mm, and high-flow volumes.[58] On physical examination, the Nicoladoni-Branham sign (occlusion of the AVF causes transient hypertension and bradycardia) may be elicited.[59]

© 2025 American Medical Association. All rights reserved, including those for text and data mining, AI training, and similar technologies.

In clinical practice, noninvasive evaluation for HOCF includes measurement of atrial natriuretic peptide (ANP) levels, echocardiography, and chest radiography. Studies have found that creation of an AVF may increase ANP levels by up to 48%; however, there is no clear diagnostic or prognostic guidance based on specific ANP levels.[58,60] In patients with HOCF, echocardiography typically demonstrates a hyperdynamic heart with increased ejection fraction, eccentric ventricular remodeling with increased ventricular chamber size, and higher estimated cardiac indexes.[61] Duplex ultrasound is used to assess for high flow volumes at the access site, which are typically greater than 2000 mL/min.

A definitive diagnosis of HOCF due to AV access placement is confirmed only after surgical intervention to reduce circuit flow volume leads to improvements in cardiac function. Treatment options include banding, RUDI, or ligation.[62] Ligation has been shown to prevent adverse left ventricular remodeling and is appropriate for patients who no longer require AV access following kidney transplant.[63]

Conclusions

Patients undergoing HD may present with a wide array of complex complications, often with more than 1 acceptable treatment approach. Management of these complications should prioritize preservation of life and limb while also aiming to salvage the functional access whenever feasible. With the rising prevalence of patients undergoing HD, it is imperative that surgeons caring for this population remain well informed on current treatment guidelines and evidence-based practice.

ARTICLE INFORMATION

Accepted for Publication: August 26, 2025.

Published Online: November 5, 2025. doi:10.1001/jamasurg.2025.4701

Author Contributions: Drs Hurwitz and de Virgilio had full access to all of the data in the study and take responsibility for the integrity of the data and the accuracy of the data analysis.
Concept and design: All authors.
Acquisition, analysis, or interpretation of data: Dang, Scali, Woo.
Drafting of the manuscript: Hurwitz, Dang, Scali, Woo, de Virgilio.
Critical review of the manuscript for important intellectual content: All authors.
Administrative, technical, or material support: Scali.
Supervision: Bowens, Woo, de Virgilio.

Conflict of Interest Disclosures: None reported.

REFERENCES

1. Allon M, Zhang Y, Thamer M, Crews DC, Lee T. Trends in vascular access among patients initiating hemodialysis in the US. *JAMA Netw Open*. 2023;6(8):e2326458. doi:10.1001/jamanetworkopen.2023.26458

2. Lok CE, Huber TS, Lee T, et al; National Kidney Foundation. KDOQI clinical practice guideline for vascular access: 2019 update. *Am J Kidney Dis*. 2020;75(4)(suppl 2):S1-S164. doi:10.1053/j.ajkd.2019.12.001

3. Morsy AH, Kulbaski M, Chen C, Isiklar H, Lumsden AB. Incidence and characteristics of patients with hand ischemia after a hemodialysis access procedure. *J Surg Res*. 1998;74(1):8-10. doi:10.1006/jsre.1997.5206

4. Lazarides MK, Staramos DN, Panagopoulos GN, Tzilalis VD, Eleftheriou GJ, Dayantas JN. Indications for surgical treatment of angioaccess-induced arterial "steal". *J Am Coll Surg*. 1998;187(4):422-426. doi:10.1016/S1072-7515(98)00139-2

5. Haimov M, Baez A, Neff M, Slifkin R. Complications of arteriovenous fistulas for hemodialysis. *Arch Surg*. 1975;110(6):708-712. doi:10.1001/archsurg.1975.01360120026004

6. Odland MD, Kelly PH, Ney AL, Andersen RC, Bubrick MP. Management of dialysis-associated steal syndrome complicating upper extremity arteriovenous fistulas: use of intraoperative digital photoplethysmography. *Surgery*. 1991;110(4):664-669.

7. Davidson D, Louridas G, Guzman R, et al. Steal syndrome complicating upper extremity hemoaccess procedures: incidence and risk factors. *Can J Surg*. 2003;46(6):408-412.

8. Ballard JL, Bunt TJ, Malone JM. Major complications of angioaccess surgery. *Am J Surg*. 1992;164(3):229-232. doi:10.1016/S0002-9610(05)81076-1

9. Valentine RJ, Bouch CW, Scott DJ, et al. Do preoperative finger pressures predict early arterial steal in hemodialysis access patients? a prospective analysis. *J Vasc Surg*. 2002;36(2):351-356. doi:10.1067/mva.2002.125848

10. Turner MA, Mathlouthi A, Patel RJ, Perreault M, Malas MB, Al-Nouri O. Small arteriovenous anastomosis in fistula creation: establishing a functional vascular access while minimizing steal syndrome. *Ann Vasc Surg*. 2024;99:142-147. doi:10.1016/j.avsg.2023.10.002

11. Kudlaty EA, Kendrick DE, Allemang MT, Kashyap VS, Wong VL. Upper extremity steal syndrome is associated with atherosclerotic burden and access configuration. *Ann Vasc Surg*. 2016;35:82-87. doi:10.1016/j.avsg.2016.01.058

12. Lazarides MK, Staramos DN, Kopadis G, Maltezos C, Tzilalis VD, Georgiadis GS. Onset of arterial 'steal' following proximal angioaccess: immediate and delayed types. *Nephrol Dial Transplant*. 2003;18(11):2387-2390. doi:10.1093/ndt/gfg346

13. Malik J, Tuka V, Kasalova Z, et al. Understanding the dialysis access steal syndrome. a review of the etiologies, diagnosis, prevention and treatment strategies. *J Vasc Access*. 2008;9(3):155-166. doi:10.1177/112972980800900301

14. Sivanesan S, How TV, Bakran A. Characterizing flow distributions in AV fistulae for haemodialysis access. *Nephrol Dial Transplant*. 1998;13(12):3108-3110. doi:10.1093/ndt/13.12.3108

15. van Hoek F, Scheltinga MRM, Luirink M, Raaymakers LCJ, van Pul C, Beerenhout CH. Access flow, venous saturation, and digital pressures in hemodialysis. *J Vasc Surg*. 2007;45(5):968-973. doi:10.1016/j.jvs.2006.12.064

16. Ravindhran B, Totty JP, Sidapra M, et al. Long term outcomes of 'Christmas tree' banding for haemodialysis access induced distal ischemia: a 13-year experience. *J Vasc Access*. 2024;25(3):863-871. doi:10.1177/11297298221141497

17. Modaghegh MHS, Roudsari B, Hafezi S. Digital pressure and oxygen saturation measurements in the diagnosis of chronic hemodialysis access-induced distal ischemia. *J Vasc Surg*. 2015;62(1):135-142. doi:10.1016/j.jvs.2015.02.024

18. Papasavas PK, Reifsnyder T, Birdas TJ, Caushaj PF, Leers S. Prediction of arteriovenous access steal syndrome utilizing digital pressure measurements. *Vasc Endovascular Surg*. 2003;37(3):179-184. doi:10.1177/153857440303700304

19. Soo Hoo AJ, Scully RE, Sharma G, et al. Contemporary outcomes of precision banding for high flow hemodialysis access. *J Vasc Access*. 2023;24(6):1260-1267. doi:10.1177/11297298221076581

20. Yaghoubian A, de Virgilio C. Plication as primary treatment of steal syndrome in arteriovenous fistulas. *Ann Vasc Surg*. 2009;23(1):103-107. doi:10.1016/j.avsg.2008.08.009

21. Kordzadeh A, Parsa AD. A systematic review of distal revascularization and interval ligation for the treatment of vascular access-induced ischemia. *J Vasc Surg*. 2019;70(4):1364-1373. doi:10.1016/j.jvs.2019.02.060

22. Scali ST, Chang CK, Raghinaru D, et al. Prediction of graft patency and mortality after distal revascularization and interval ligation for hemodialysis access-related hand ischemia. *J Vasc Surg*. 2013;57(2):451-458. doi:10.1016/j.jvs.2012.08.105

23. Huber TS, Brown MP, Seeger JM, Lee WA. Midterm outcome after the distal revascularization and interval ligation (DRIL) procedure. *J Vasc Surg*. 2008;48(4):926-932. doi:10.1016/j.jvs.2008.05.028

24. Misskey J, Yang C, MacDonald S, Baxter K, Hsiang Y. A comparison of revision using distal inflow and distal revascularization-interval ligation for the management of severe access-related hand ischemia. *J Vasc Surg*. 2016;63(6):1574-1581. doi:10.1016/j.jvs.2015.10.100

25. Minion DJ, Moore E, Endean E. Revision using distal inflow: a novel approach to dialysis-associated steal syndrome. *Ann Vasc Surg*. 2005;19(5):625-628. doi:10.1007/s10016-005-5827-7

26. Loh TM, Bennett ME, Peden EK. Revision using distal inflow is a safe and effective treatment for ischemic steal syndrome and pathologic high flow

© 2025 American Medical Association. All rights reserved, including those for text and data mining, AI training, and similar technologies.

after access creation. *J Vasc Surg*. 2016;63(2):441-444. doi:10.1016/j.jvs.2015.08.098

27. Zanow J, Kruger U, Scholz H. Proximalization of the arterial inflow: a new technique to treat access-related ischemia. *J Vasc Surg*. 2006;43(6):1216-1221. doi:10.1016/j.jvs.2006.01.025

28. Bachmann C, Parker M, Sardana T, Ramsey L, Hashemi H. Proximalization of arterial inflow for treatment of hemodialysis access-induced distal ischemia. *J Vasc Surg*. Published online June, 2024 doi:10.1016/j.jvs.2024.05.045

29. Leake AE, Winger DG, Leers SA, Gupta N, Dillavou ED. Management and outcomes of dialysis access-associated steal syndrome. *J Vasc Surg*. 2015;61(3):754-760. doi:10.1016/j.jvs.2014.10.038

30. Zanow J, Petzold K, Petzold M, Krueger U, Scholz H. Flow reduction in high-flow arteriovenous access using intraoperative flow monitoring. *J Vasc Surg*. 2006;44(6):1273-1278. doi:10.1016/j.jvs.2006.08.010

31. Fitzgibbon JJ, Heindel P, Hentschel DM, Ozaki CK,Hussain MA. Contemporary outcomes of distal radial artery ligation for access related hand ischemia. *J Vasc Access*. 2025;26(1):149-155. doi:10.1177/11297298231195910

32. Thermann F, Kornhuber M. Ischemic monomelic neuropathy: a rare but important complication after hemodialysis access placement—a review. *J Vasc Access*. 2011;12(2):113-119. doi:10.5301/JVA.2011.6365

33. Wilbourn AJ, Furlan AJ, Hulley W, Ruschhaupt W. Ischemic monomelic neuropathy. *Neurology*. 1983;33(4):447-451. doi:10.1212/WNL.33.4.447

34. Larson E, Lancaster T, Pelrine E, Werner B, Deal DN. Carpal tunnel release in the dialysis-dependent population: Incidence and outcomes. *J Hand Microsurg*. 2024;16(3):100056. doi:10.1016/j.jham.2024.100056

35. Kopeć J, Gadek A, Drozdz M, et al. Carpal tunnel syndrome in hemodialysis patients as a dialysis-related amyloidosis manifestation–incidence, risk factors and results of surgical treatment. *Med Sci Monit*. 2011;17(9):CR505-CR509. doi:10.12659/MSM.881937

36. Kwon HK, Pyun SB, Cho WY, Boo CS. Carpal tunnel syndrome and peripheral polyneuropathy in patients with end stage kidney disease. *J Korean Med Sci*. 2011;26(9):1227-1230. doi:10.3346/jkms.2011.26.9.1227

37. Grant Y, Freilich S, Horwitz MD, Shemesh D, Crane J. Carpal tunnel syndrome in patients with arteriovenous fistula for haemodialysis: a narrative review of the current literature. *J Vasc Access*. 2021;22(5):795-800. doi:10.1177/1129729820948690

38. Nardin R, Chapman KM, Raynor EM. Prevalence of ulnar neuropathy in patients receiving hemodialysis. *Arch Neurol*. 2005;62(2):271-275. doi:10.1001/archneur.62.2.271

39. Patel MS, Street T, Davies MG, Peden EK, Naoum JJ. Evaluating and treating venous outflow stenoses is necessary for the successful open surgical treatment of arteriovenous fistula aneurysms. *J Vasc Surg*. 2015;61(2):444-448. doi:10.1016/j.jvs.2014.07.033

40. Yan Q, Davies MG. Comparison of open and endovascular aneurysm repair in native arteriovenous fistulas. *Ann Vasc Surg*. 2024;100:233-242. doi:10.1016/j.avsg.2023.09.102

41. Shah AS, Valdes J, Charlton-Ouw KM, et al. Endovascular treatment of hemodialysis access pseudoaneurysms. *J Vasc Surg*. 2012;55(4):1058-1062. doi:10.1016/j.jvs.2011.10.126

42. Jankovic A, Donfrid B, Adam J, et al. Arteriovenous fistula aneurysm in patients on regular hemodialysis: prevalence and risk factors. *Nephron Clin Pract*. 2013;124(1-2):94-98. doi:10.1159/000355548

43. Baláž P, Rokošný S, Bafrnec J, Whitley A, O'Neill S. Repair of aneurysmal arteriovenous fistulae: a systematic review and meta-analysis. *Eur J Vasc Endovasc Surg*. 2020;59(4):614-623. doi:10.1016/j.ejvs.2019.07.033

44. Chang R, Alabi O, Mahajan A, et al. Arteriovenous fistula aneurysmorrhaphy is associated with improved patency and decreased vascular access abandonment. *J Vasc Surg*. 2023;77(3):891-898.e1. doi:10.1016/j.jvs.2022.10.054

45. Yan Q, Davies MG. Outcomes of one-stage and two-stage aneurysm repair in arteriovenous fistulae. *J Vasc Surg*. 2024;79(3):662-670.e3. doi:10.1016/j.jvs.2023.10.057

46. Dosluoglu HH, Harris LM. Hemodialysis access: nonthrombotic complications. In: Sidawy AN, Perler BA, eds. *Rutherford's Vascular Surgery and Endovascular Therapy*. Vol 10. 2nd ed. Elsevier; 2022. doi:10.1016/b978-1-4160-5223-4.00075-5

47. Ellingson KD, Palekar RS, Lucero CA, et al. Vascular access hemorrhages contribute to deaths among hemodialysis patients. *Kidney Int*. 2012;82(6):686-692. doi:10.1038/ki.2012.185

48. Greenstein R, Nawrocki P, Nesbit C. Bottle it up: prehospital management of an AV fistula bleed using a bottle cap. *Am J Emerg Med*. 2023;67:197.e1-197.e2. doi:10.1016/j.ajem.2023.03.011

49. Hancock HM, Stannard A, Burkhardt GE, et al. Hemorrhagic shock worsens neuromuscular recovery in a porcine model of hind limb vascular injury and ischemia-reperfusion. *J Vasc Surg*. 2011;53(4):1052-1062. doi:10.1016/j.jvs.2010.10.104

50. Milosevic E, Forster A, Moist L, Rehman F, Thomson B. Non-surgical interventions to control bleeding from arteriovenous fistulas and grafts inside and outside the hemodialysis unit: a scoping review. *Clin Kidney J*. 2024;17(5):sfae089. doi:10.1093/ckj/sfae089

51. Padberg FT Jr, Calligaro KD, Sidawy AN. Complications of arteriovenous hemodialysis access: recognition and management. *J Vasc Surg*. 2008;48(5)(suppl):55S-80S. doi:10.1016/j.jvs.2008.08.067

52. Reinders Folmer EI, Von Meijenfeldt GCI, Van der Laan MJ, et al. Diagnostic imaging in vascular graft infection: a systematic review and meta-analysis. *Eur J Vasc Endovasc Surg*. 2018;56(5):719-729. doi:10.1016/j.ejvs.2018.07.010

53. Erba PA, Leo G, Sollini M, et al. Radiolabelled leucocyte scintigraphy versus conventional radiological imaging for the management of late, low-grade vascular prosthesis infections. *Eur J Nucl Med Mol Imaging*. 2014;41(2):357-368. doi:10.1007/s00259-013-2582-9

54. Schwab DP, Taylor SM, Cull DL, et al. Isolated arteriovenous dialysis access graft segment infection: the results of segmental bypass and partial graft excision. *Ann Vasc Surg*. 2000;14(1):63-66. doi:10.1007/s100169910011

55. Liu RH, Fraser CD III, Zhou X, Beaulieu RJ, Reifsnyder T. Complete versus partial excision of infected arteriovenous grafts: does remnant graft material impact outcomes? *J Vasc Surg*. 2020;71(1):174-179. doi:10.1016/j.jvs.2019.03.062

56. Schutte WP, Helmer SD, Salazar L, Smith JL. Surgical treatment of infected prosthetic dialysis arteriovenous grafts: total versus partial graft excision. *Am J Surg*. 2007;193(3):385-388. doi:10.1016/j.amjsurg.2006.09.028

57. Walz P, Ladowski JS. Partial excision of infected fistula results in increased patency at the cost of increased risk of recurrent infection. *Ann Vasc Surg*. 2005;19(1):84-89. doi:10.1007/s10016-004-0139-x

58. Zahra SA, Choudhury RY, Basharat K, et al. Translational sciences in cardiac failure secondary to arteriovenous fistula in hemodialysis patients. *Ann Vasc Surg*. 2021;74:431-449. doi:10.1016/j.avsg.2021.01.071

59. Wattanasirichaigoon S, Pomposelli FB Jr. Branham's sign is an exaggerated Bezold-Jarisch reflex of arteriovenous fistula. *J Vasc Surg*. 1997;26(1):171-172. doi:10.1016/S0741-5214(97)70168-X

60. Iwashima Y, Horio T, Takami Y, et al. Effects of the creation of arteriovenous fistula for hemodialysis on cardiac function and natriuretic peptide levels in CRF. *Am J Kidney Dis*. 2002;40(5):974-982. doi:10.1053/ajkd.2002.36329

61. Reddy YNV, Melenovsky V, Redfield MM, Nishimura RA, Borlaug BA. High-output heart failure: a 15-year experience. *J Am Coll Cardiol*. 2016;68(5):473-482. doi:10.1016/j.jacc.2016.05.043

62. Stern AB, Klemmer PJ. High-output heart failure secondary to arteriovenous fistula. *Hemodial Int*. 2011;15(1):104-107. doi:10.1111/j.1542-4758.2010.00518.x

63. Rao NN, Stokes MB, Rajwani A, et al. Effects of arteriovenous fistula ligation on cardiac structure and function in kidney transplant recipients. *Circulation*. 2019;139(25):2809-2818. doi:10.1161/CIRCULATIONAHA.118.038505

© 2025 American Medical Association. All rights reserved, including those for text and data mining, AI training, and similar technologies.