Janda approach assessment

신경계 개념을 가지고 근골격계 환자를 치료

Dong koog Noh

Upper crossed syndrome

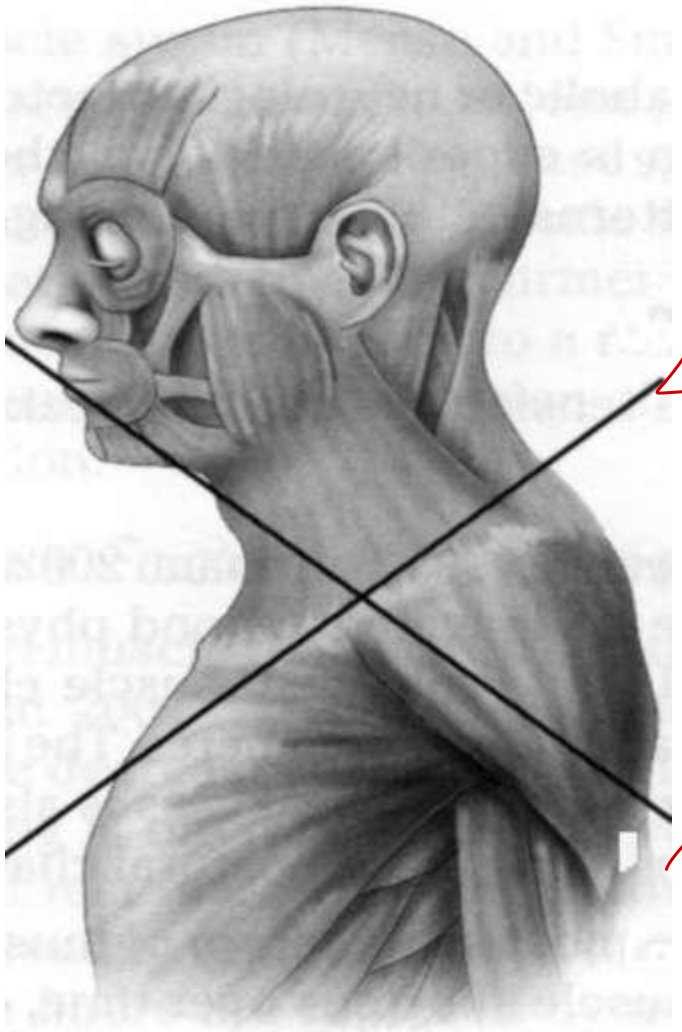

거북목 자세되면
<짧아진다>
upeer trapezius
Levator scapulae

Pack major/minor
SCM

<늘어난다>
romboid major/minor
Lower trapezius

Deep neck flexors(여러근육있는듯)

Lower crossed syndrome

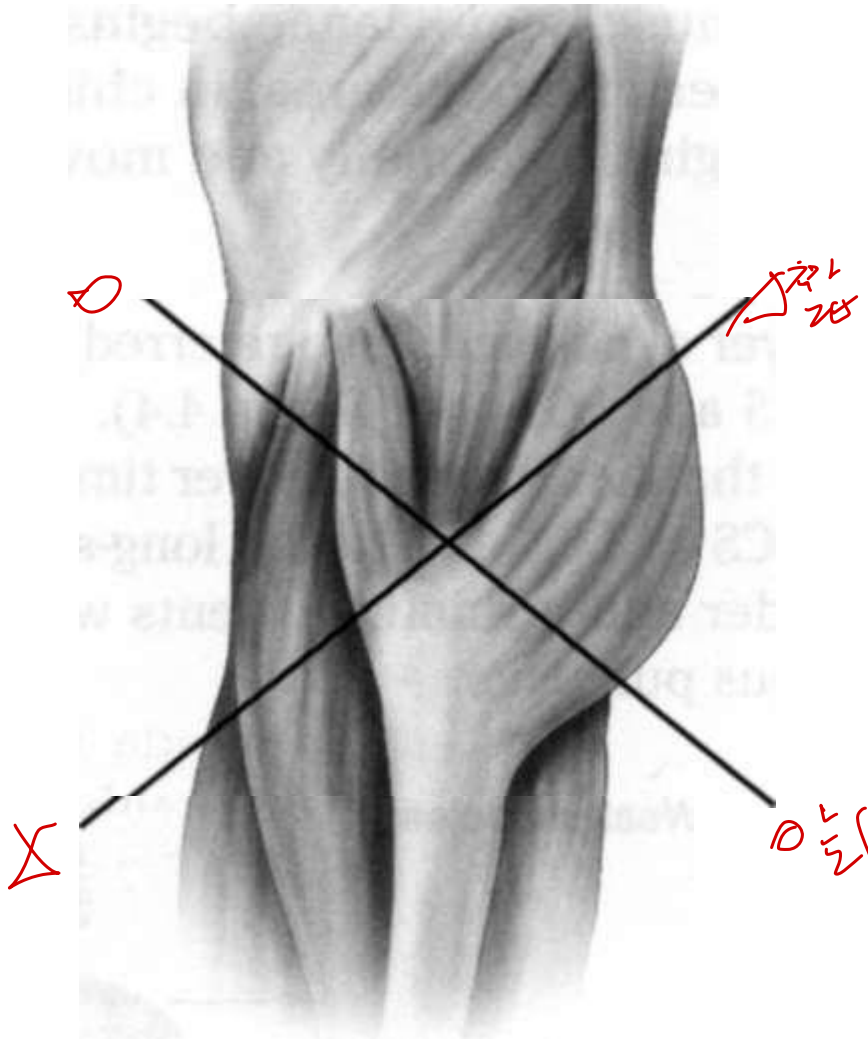

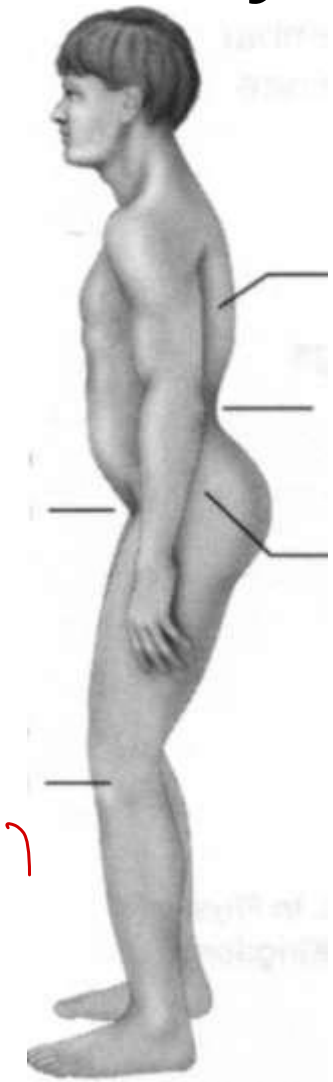

<짧아지는>
Errector spine
Iliopsoas
Rectus femoris

<약해지는>
Gluteus maximus
Hamstring
Abdominal muscle

pelvic의 중립위치는
asis, pubic symphysis - 90도
asis, psis 는 15도까지 중립으로본다

뼈의 돌기가 절대적이진 않다
anterior tilt, posterior tilt를 랜드마크로 볼때
사람마다의 위치가 다를수있기 때문에
분절별로 따로봐야한다

Pelvic position

- Lateral tilt
- Lateral shift
- Rotation
- Ant. tilt
- Post. tilt

tilt 쳐진거
shift 밀린거

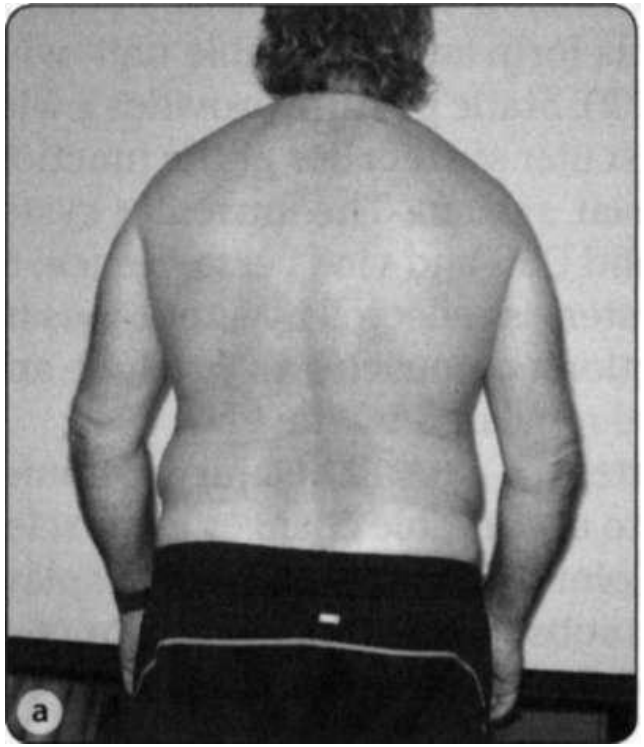

Right lateral tilting
Right lateral shifting

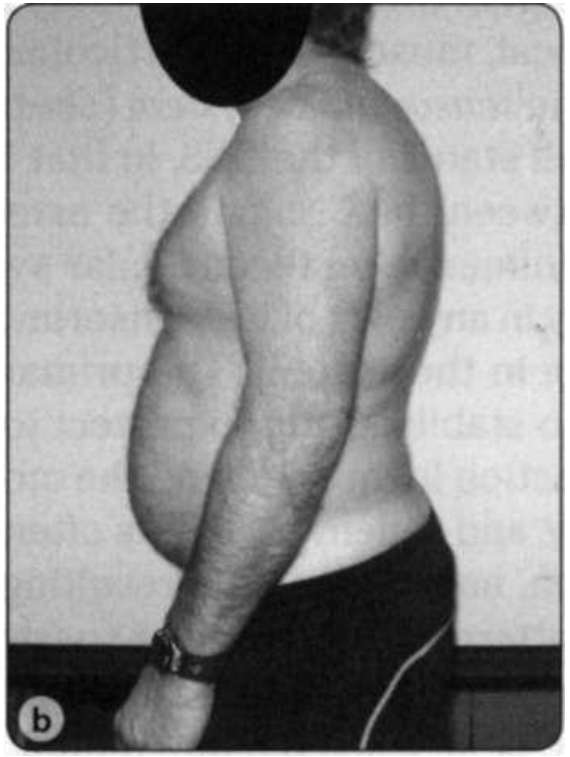

Anterior tilting

anterior tilting된쪽이 걸을때 먼저 멀리나가는 경우가있다(mobility)
반대편은 stability를 채우고
오른발잡이(R anterior tilting-mobility, L posterior tilting-stability)

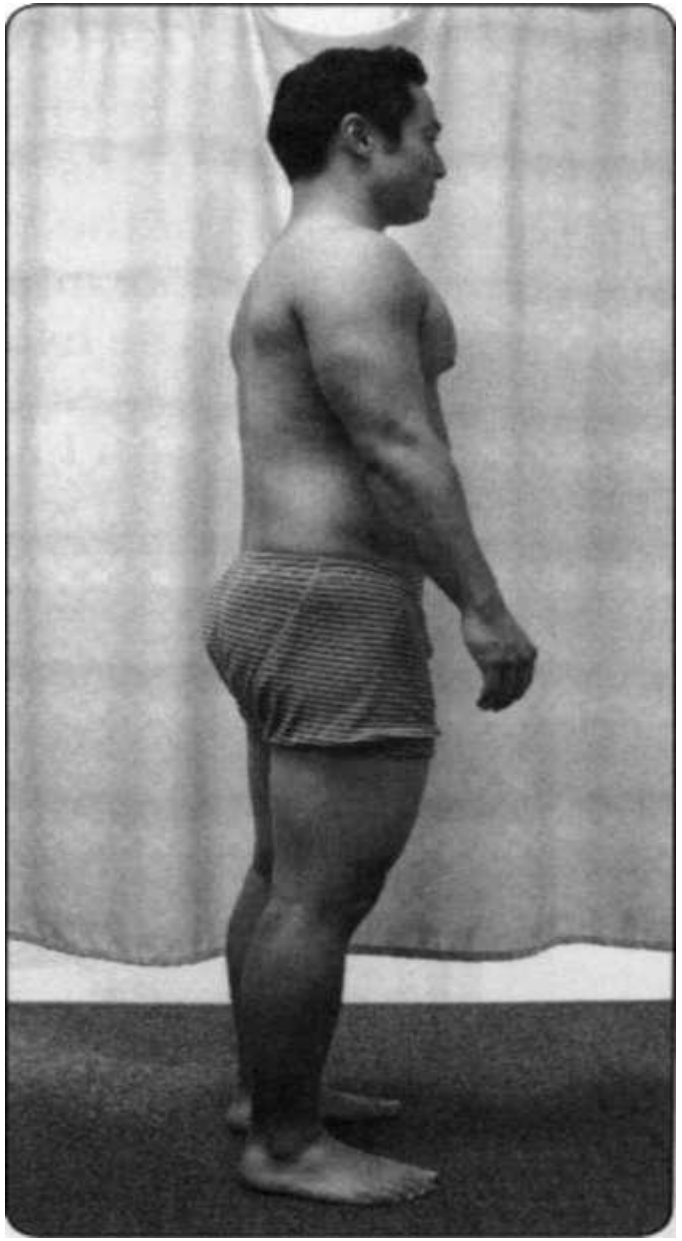

Round shoulder
Plat back(lumbar가 평평한것을 얘기한다) 놀랍게도 등이 아니다^~^
Arm internal rotation(귀에서 sagittal plane으로 내려왔을때 landmark로 확인가능, olecrenon을 보고 확인가능)
Forearm internal roatation
Winging scapulae
COG 앞으로 가있다(hip 후방, knee전방, ankle전방에 있어야 하지에 제대로 받을수있음)
서있을때 무게중심은 S2 전방5cm가 맞다
Back knee
오금에 물이찰수있다(베이커씨낭종)
오금근(popliteus)도 늘어난다
오금근의 중요역할은 screw home motion에 의해서 잠겨있는 무릎을 굽히는 key muscle임
knee extension시Screw home motioin이라 해서 femor에 비해 tibia가 10-15도정도 external rotation
안쪽condyle이 lateral보다 커서 맞아들어가면서 external rotation되는거임

Buttock region

- Lower gluteal fold

낮아진 엉덩주름
pelvic
Anterior tilting되면 주름사라지고
posterior tilting되면 주름생긴고 짙어진다
한쪽이 내려가있으면 posterior tilting되어있네 라고 판단할수도 있음

ASIS와PSIS의 높이를 비교해서
ASIS좌우중 우측이 내려갔다면
PSIS우측은 올라갔을것이다
이를 이용해서
Sagittal plane에서도 앞뒤직경 차이를 확인해 볼수도 있다

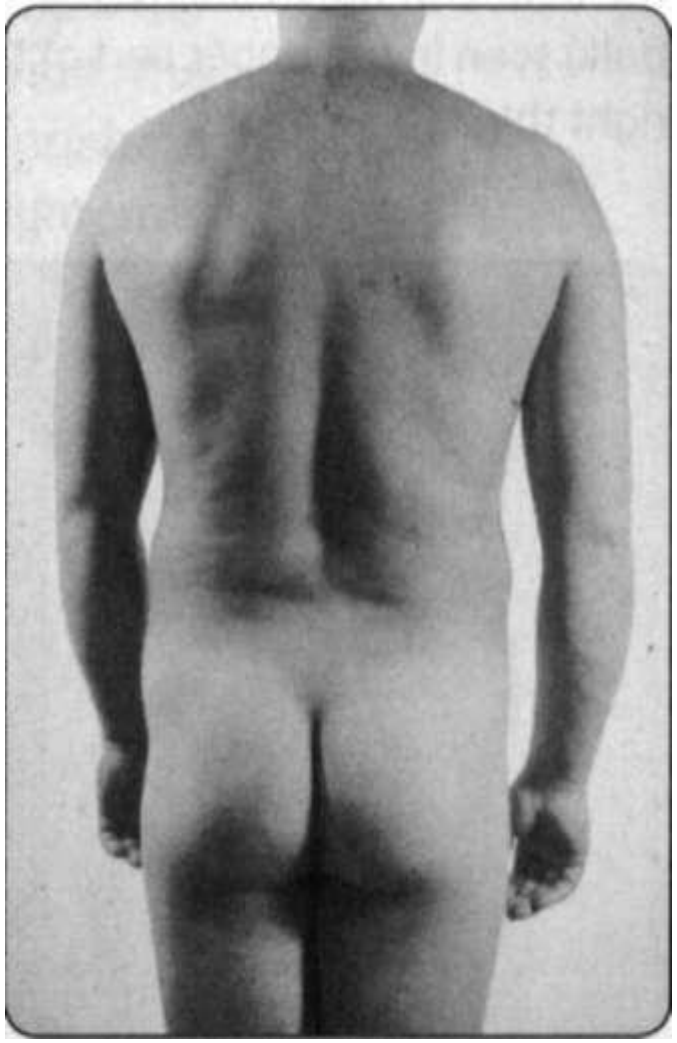

Hamstring

- Hypertrophy of lower two thirds of the belly of the hamstring

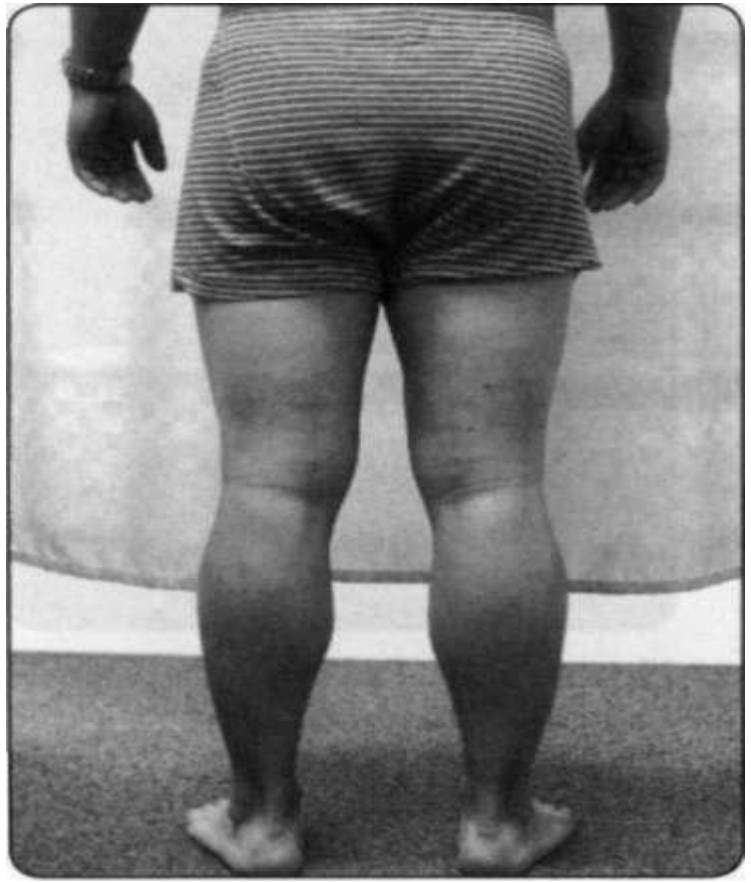

Adductors

- S shape in proximal groin area (adductor notch)
- Bulkier S shape that may be due to shortened pectineus
- Hypertonicity in obliques

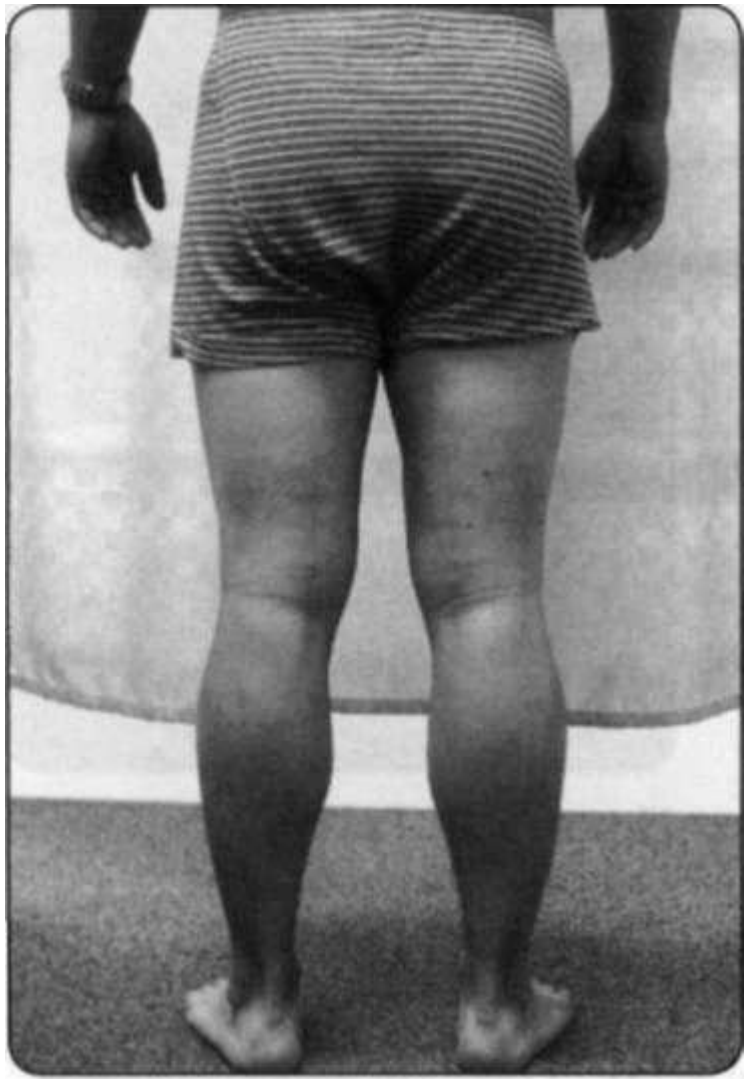

Calf and triceps surae

- Broad and short Achilles tendon
- Prominence of soleus belly

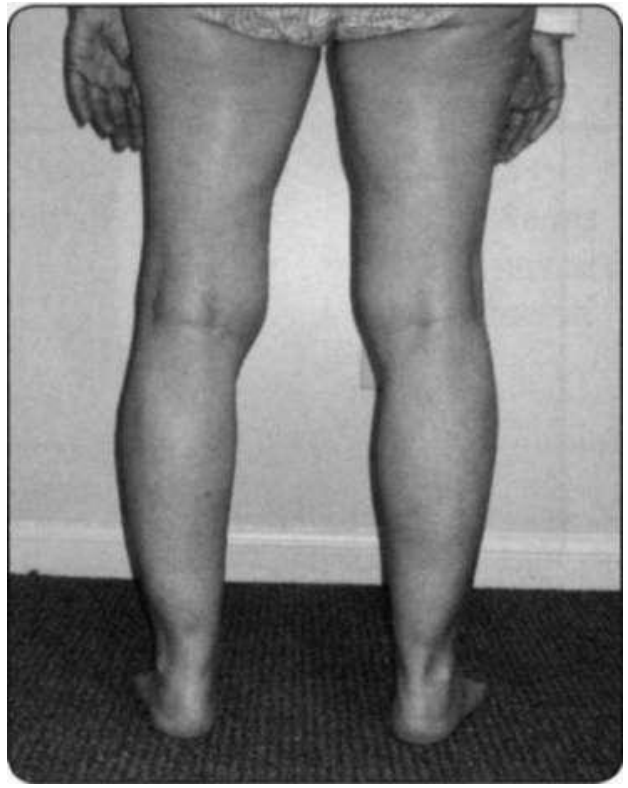

Shape of heel

- Round heel-normal
- Quadratic heel-central mass shifted to posterior
- Pointed heel-central mass shifted to anterior

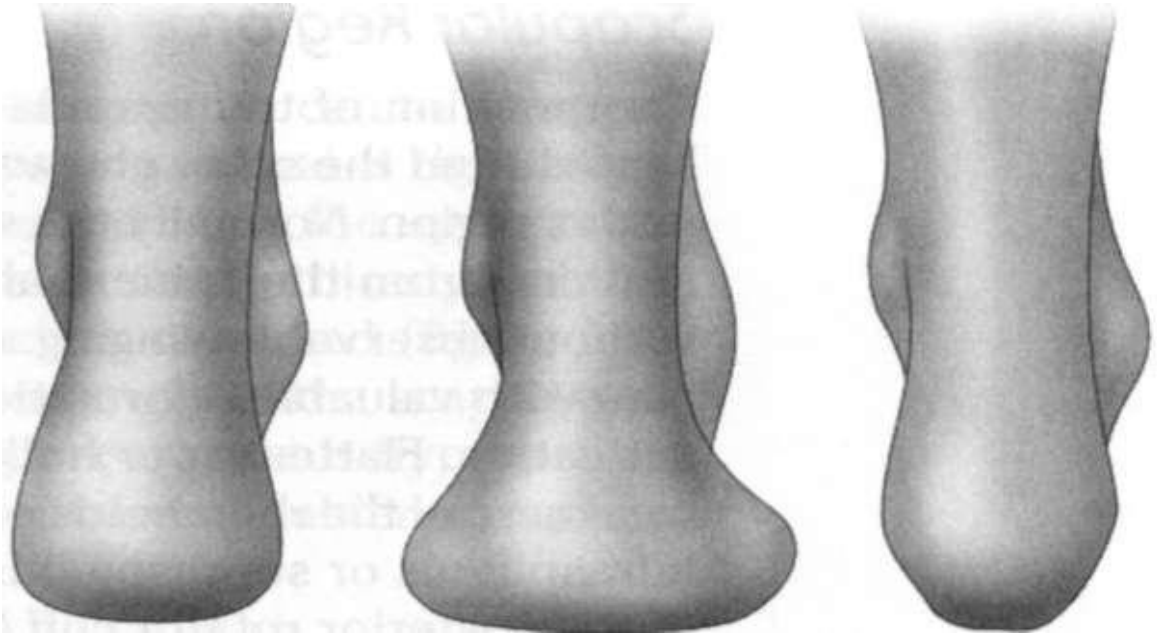

Spinal extensors

- Asymmetrical
- Thoracolumbar paraspinals
- Horizontal groove

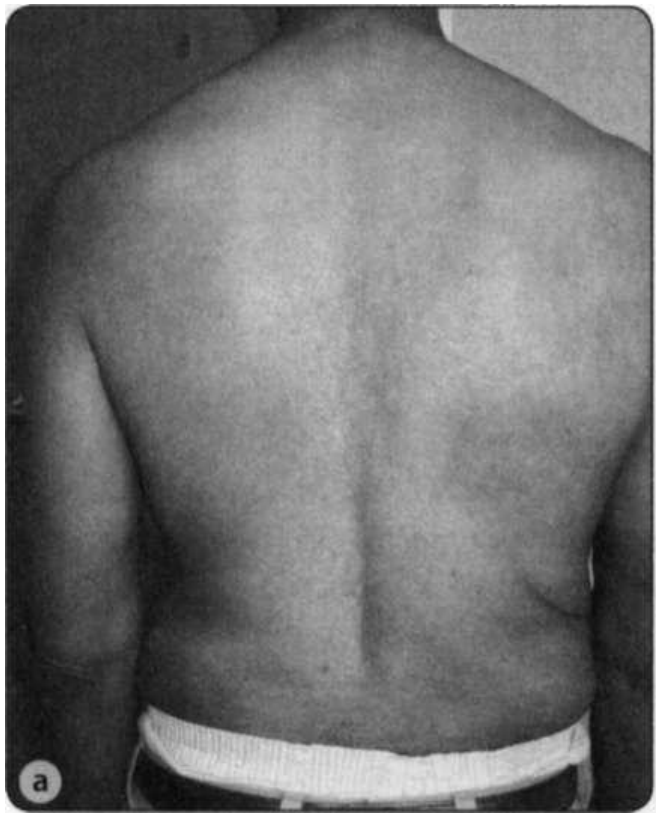

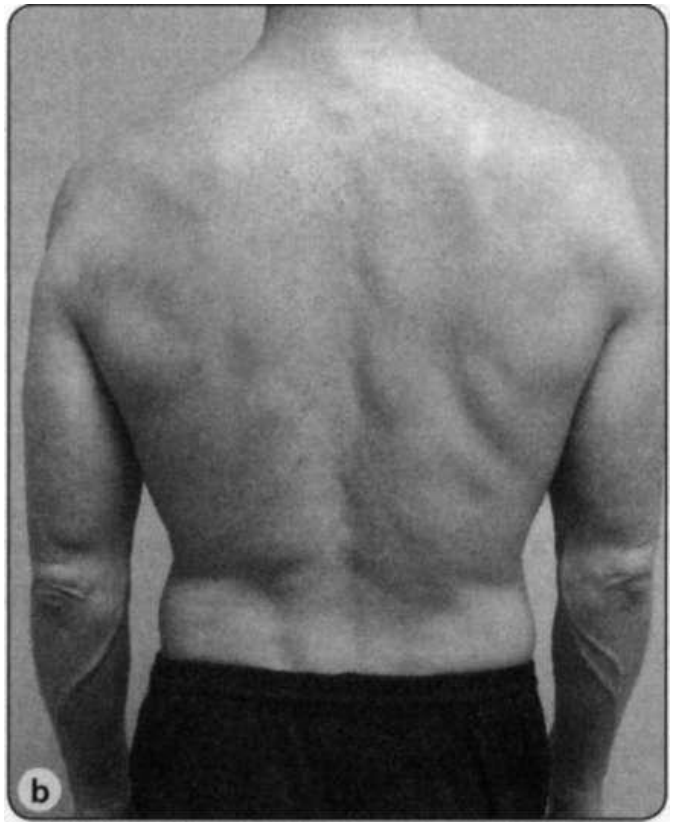

Scapular position

- Height; T2 ~T7
- Abduction; 3 inch (5 cm)
- Clavicle; 15 deg

  → Downward / upward

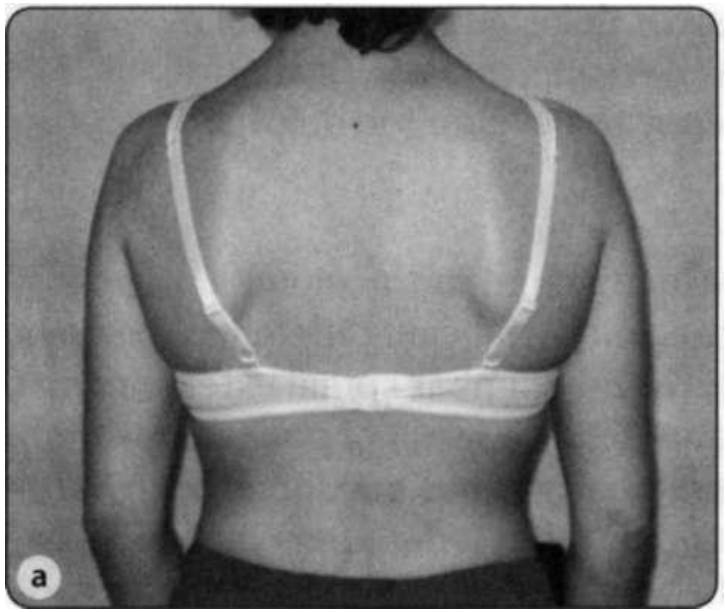
a

b

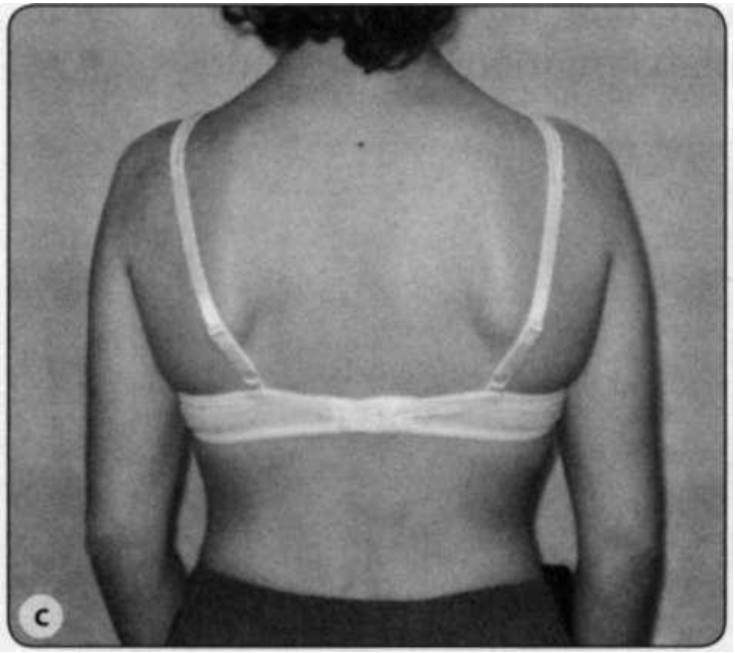
c

d

Gothic shoulder

Levator notch

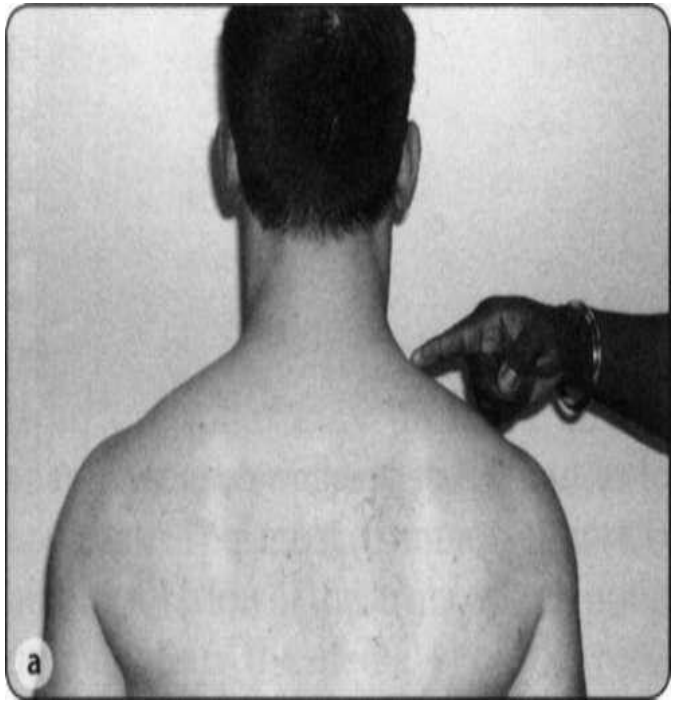

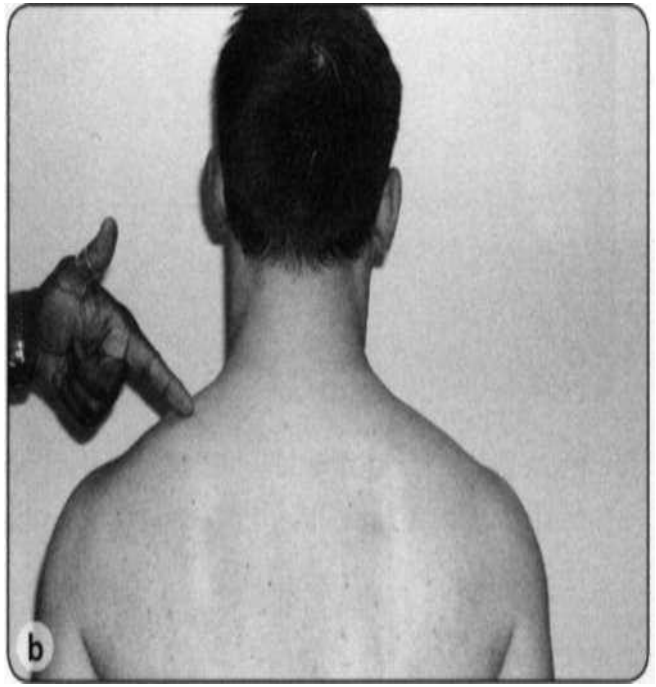

abdominal

- Breathing pattern
- Hypertonic upper versus lower quadrant
- Increased groove of rectus
- Pseudohernia

Ant. Thigh muscle

- Bulk medial to lateral vastus medialis bulk visible or prominent
- Patellar shifting

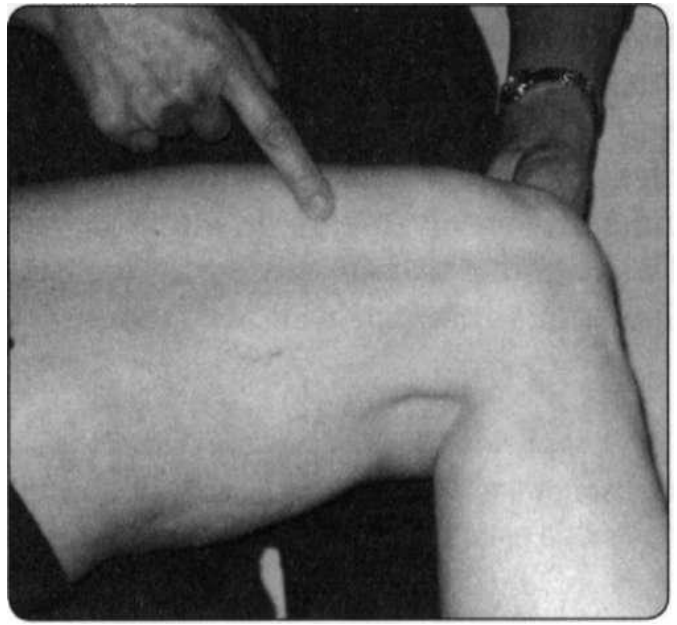

Leg

- Smaller tibialis anterior flattening of L5

Upper extremity

- Contour of deltoids
- Medial rotation of arms
- Arm position in sagittal plane
- Humeral head position

a

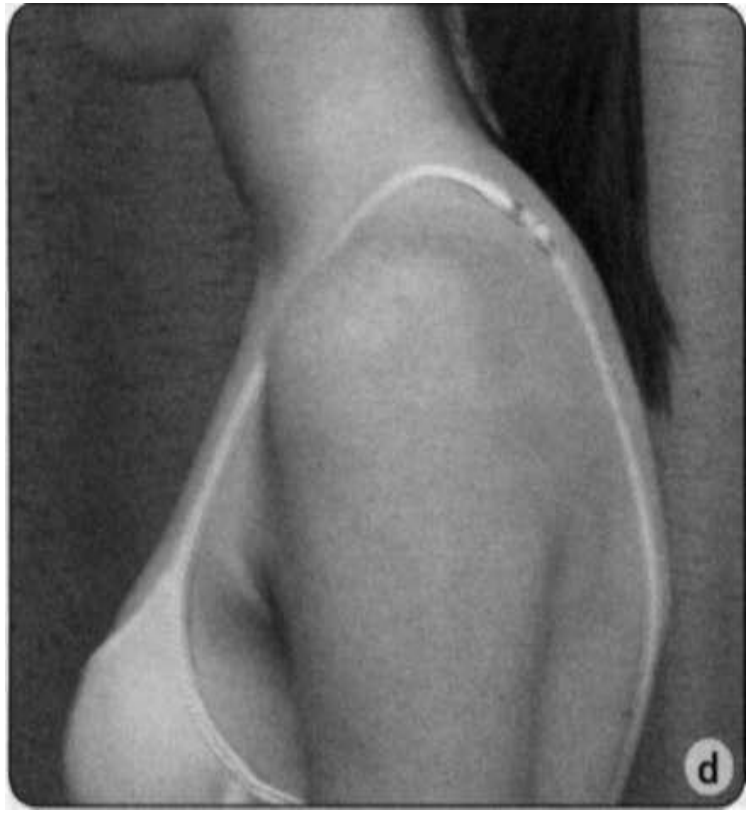
d

pectorals

- Increased bulk
- Nipple face out superiorly of laterally

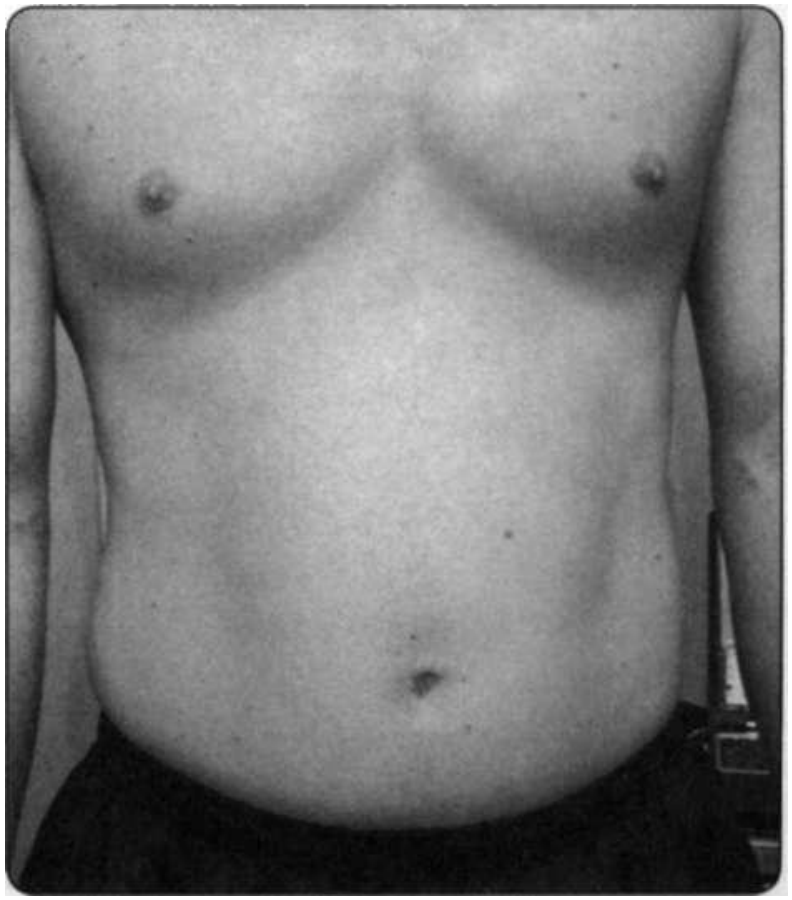

Head

- Forward head
- Groove anterior to SCM
- >90 ° angle btw chin and neck

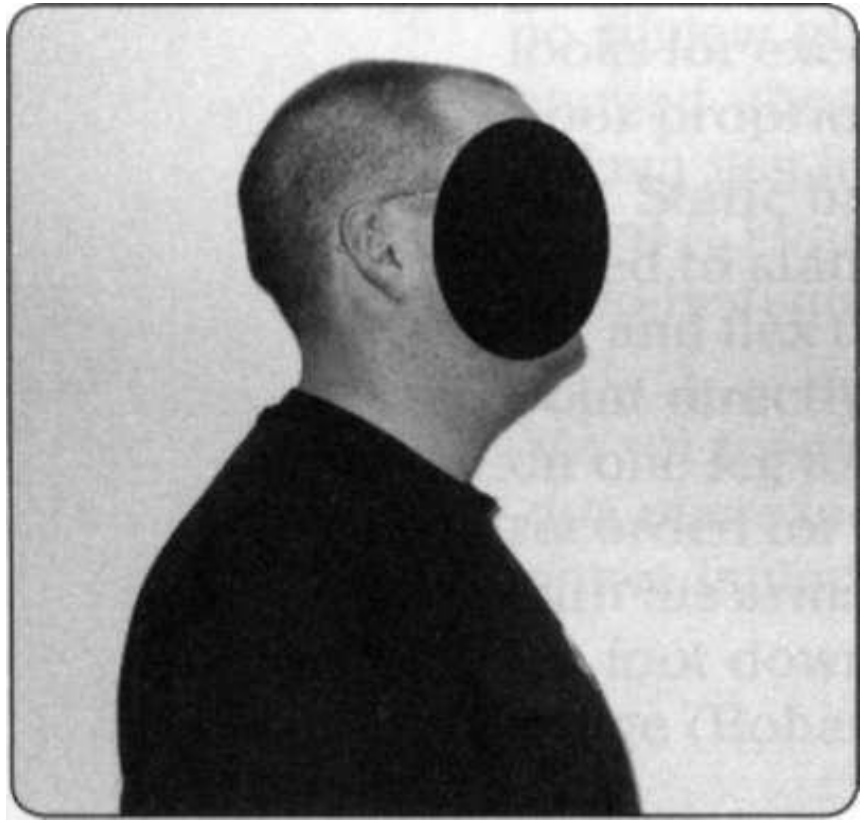

Inspection					반	학번		이름	
View	**Checkpoints**	**Observation**	**Rt**	**Lt**	**View**	**Checkpoints**	**Observation**	**Rt**	**Lt**
Posterior	**Pelvic position**	Lateral tilt (up)			**Posterior**	**Scapular position**	Height (T2-T7) Up		
		Lateral shift					Down		
		Rotation					Abduction >5cm		
		Ant. tilt					<5cm		
		Post. tilt					Clavicle >15˚		
	Lower gluteal fold						<15˚		
	Hamstring hypertrophy						Downward		
	Adductor S shape (pectineus)						upward		
	Calf/triceps surae prominence				**Anterior**	**Abdominal**	Breathing pattern		
							Neck muscle use		
	Heel shape	Round					Rib mobility ↓		
							Rib angle >45˚		
		Quadratic					<45˚		
							Patellar shifting		
		pointed			**Lateral**	**U/E**	Arm Int. rot		
							Forward (>90˚ btw chin and neck)		
	Spinal extensor	Asymmetrical (prominence)			**UCS (upper crossed syndrome)**	**Tight muscle**	SCM		
		Horizontal groove					Scalene		
							Suboccipital		
					LCS (lower crossed syndrome)	**Tight muscle**	Iliopsoas		
							Rectus femoris		
							Low back muscle		