Janda approach assessment

Dong koog Noh

Upper crossed syndrome

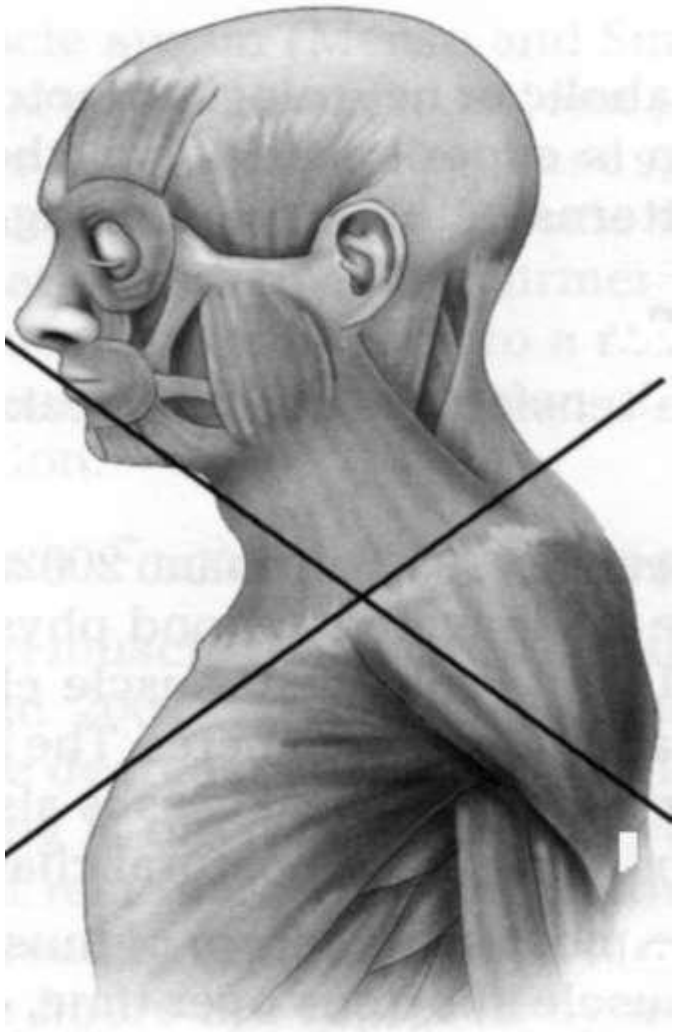

Lower crossed syndrome

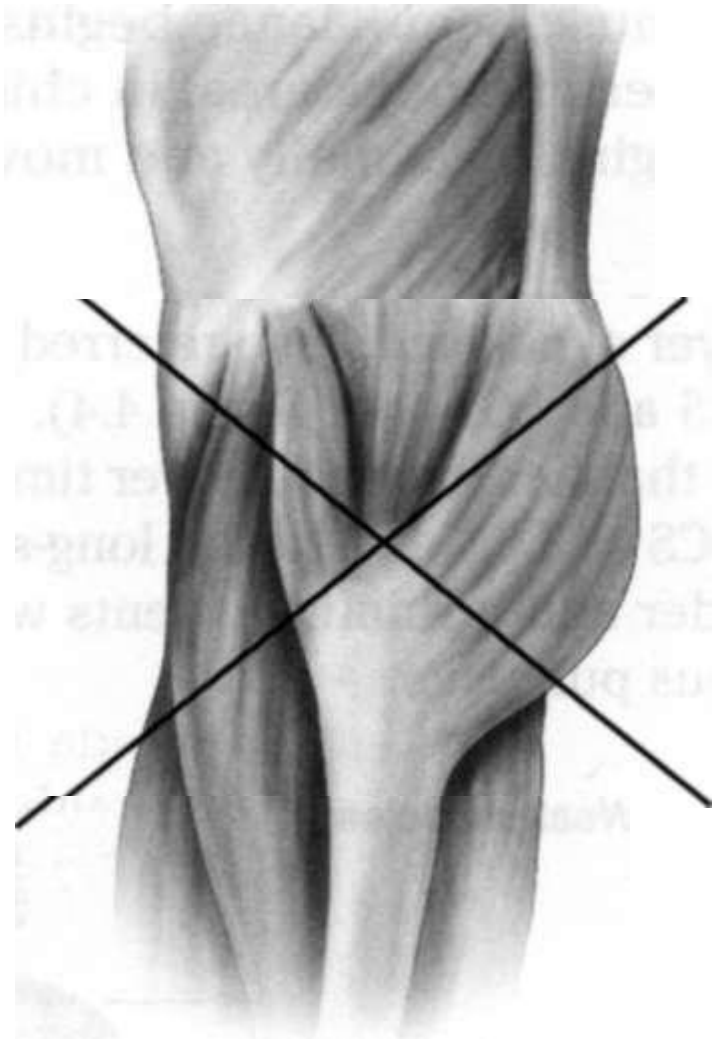

Pelvic position

- Lateral tilt
- Lateral shift
- Rotation
- Ant. tilt
- Post. tilt

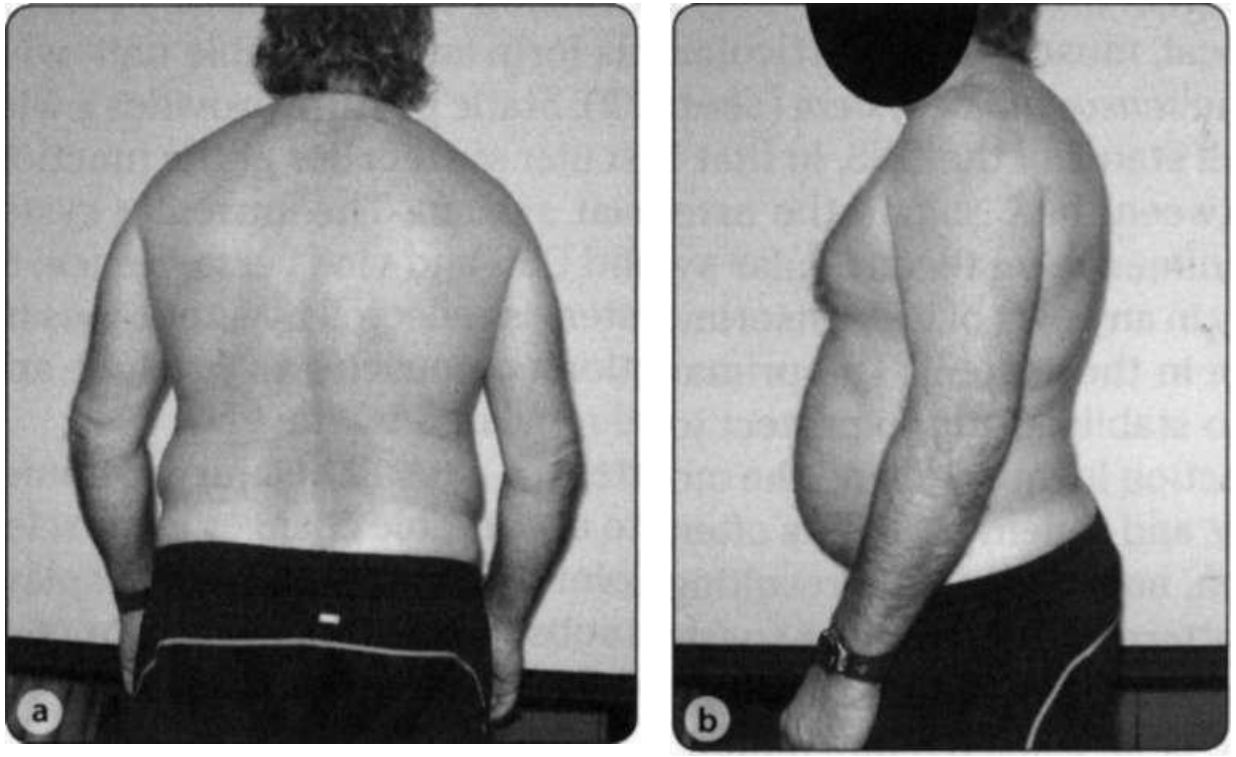

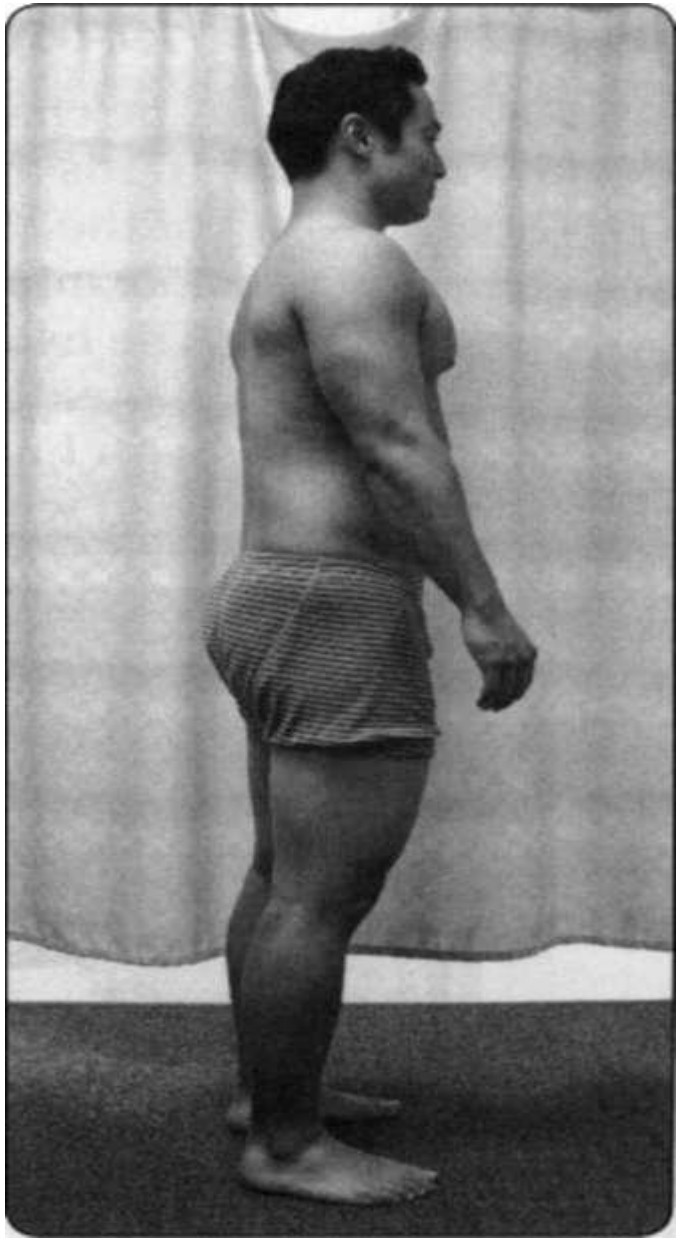

Buttock region

- Lower gluteal fold

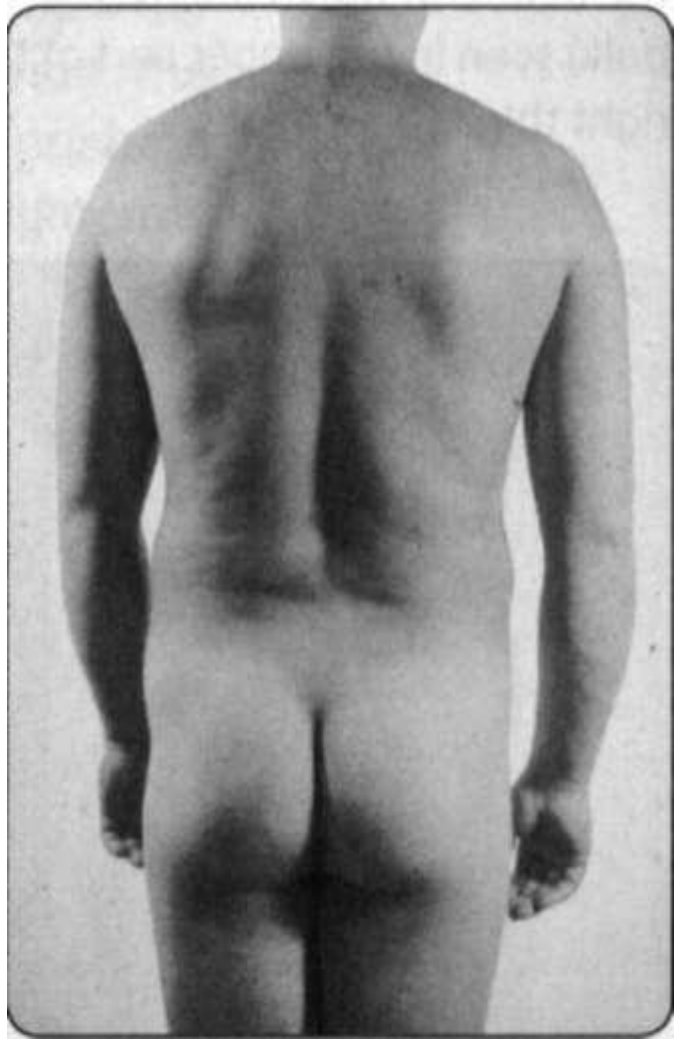

Hamstring

- Hypertrophy of lower two thirds of the belly of the hamstring

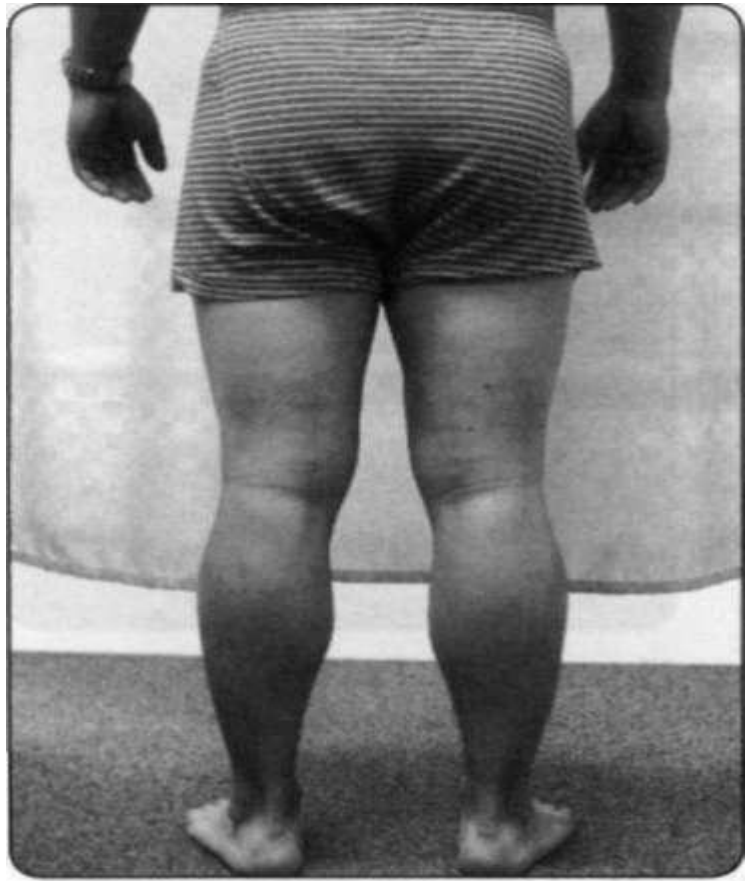

Adductors

- S shape in proximal groin area (adductor notch)
- Bulkier S shape that may be due to shortened pectineus
- Hypertonicity in obliques

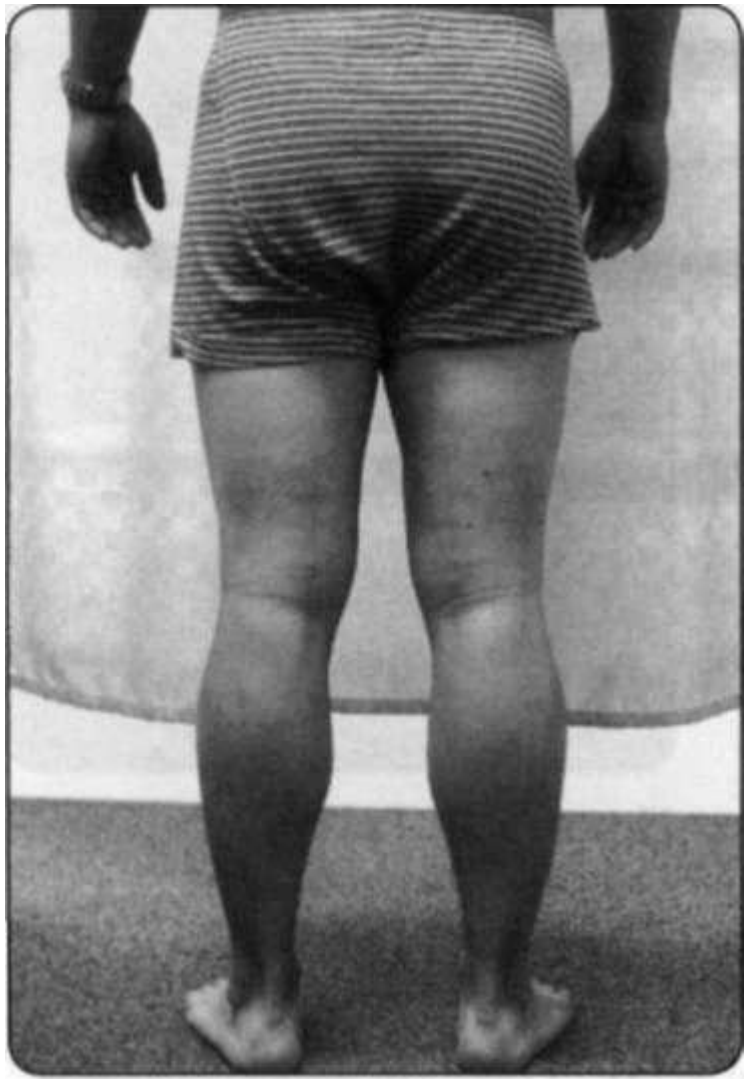

Calf and triceps surae

- Broad and short Achilles tendon
- Prominence of soleus belly

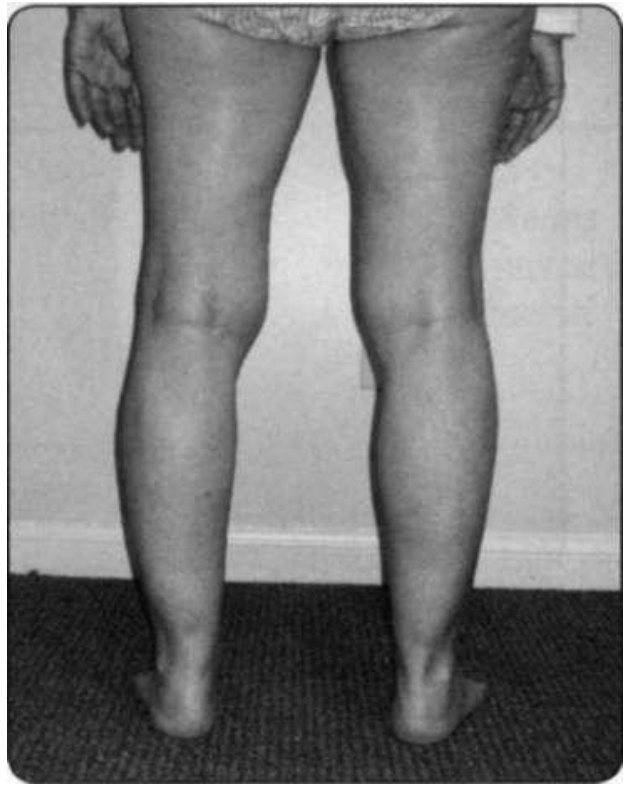

Shape of heel

- Round heel-normal
- Quadratic heel-central mass shifted to posterior
- Pointed heel-central mass shifted to anterior

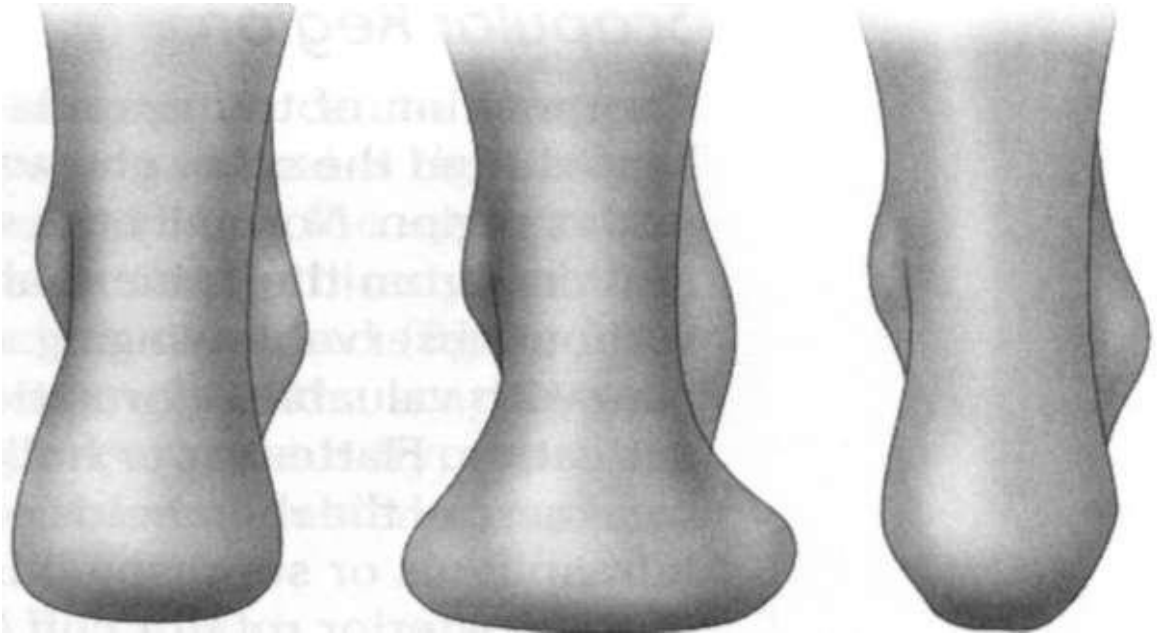

Spinal extensors

- Asymmetrical
- Thoracolumbar paraspinals
- Horizontal groove

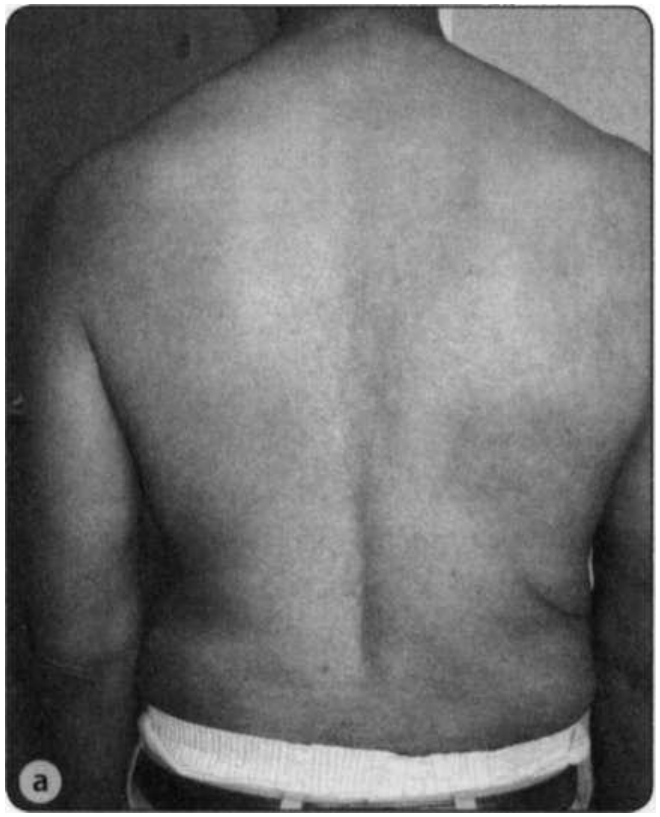

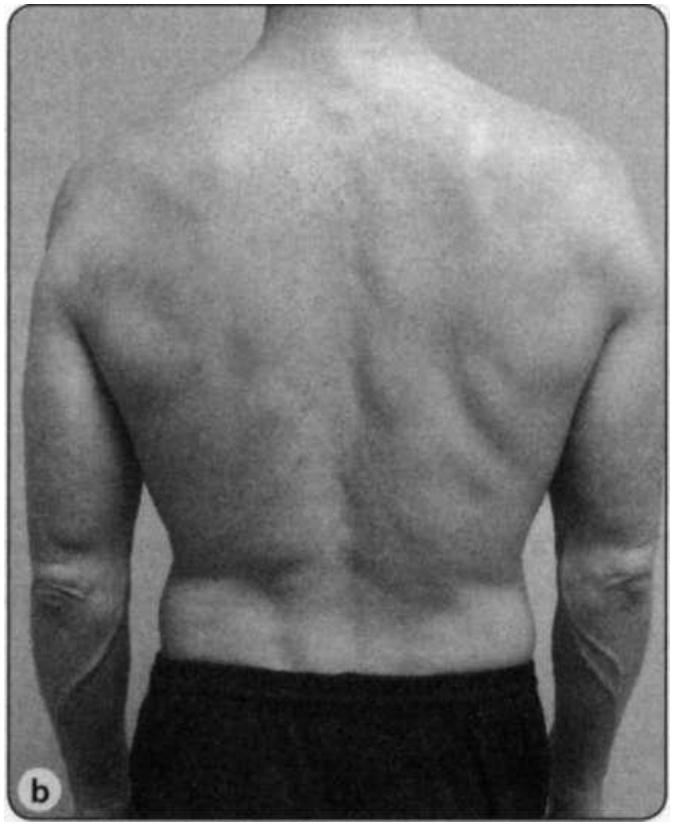

Scapular position

- Height; T2 ~T7
- Abduction; 3 inch (5 cm)
- Clavicle; 15 deg

  → Downward / upward

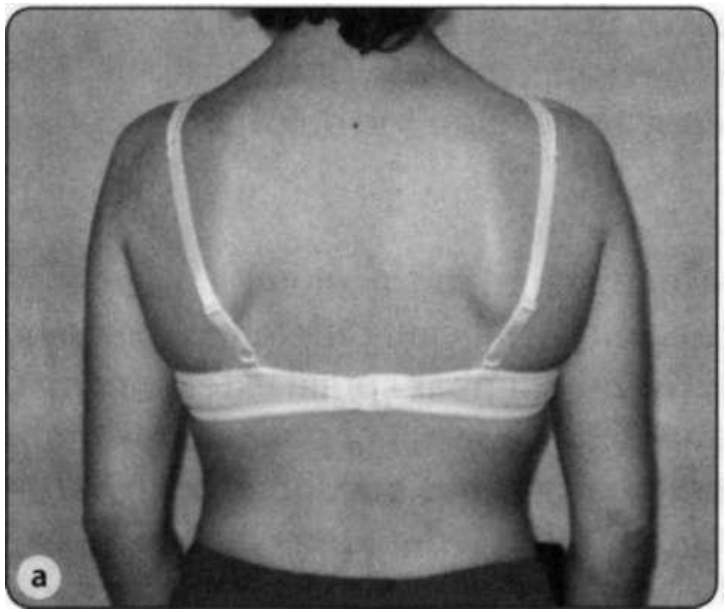
a

b

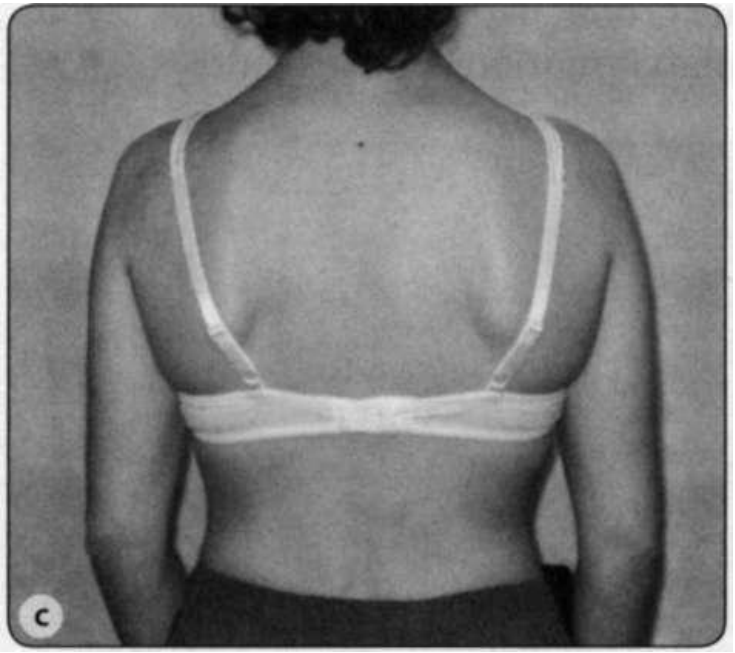
c

d

Gothic shoulder

Levator notch

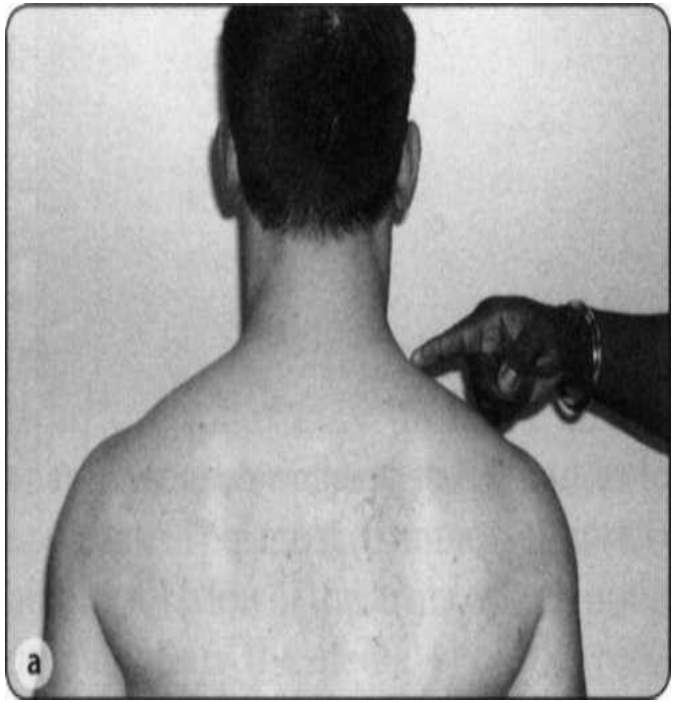

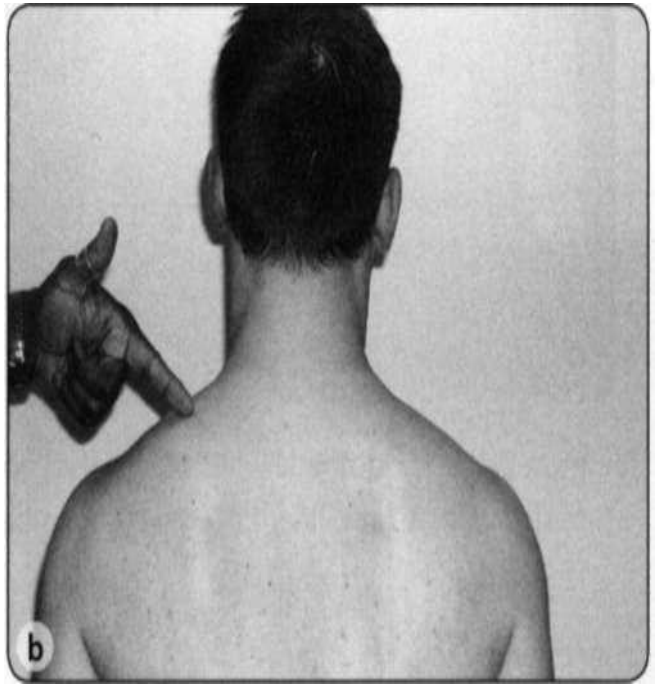

abdominal

- Breathing pattern
- Hypertonic upper versus lower quadrant
- Increased groove of rectus
- Pseudohernia

Ant. Thigh muscle

- Bulk medial to lateral vastus medialis bulk visible or prominent
- Patellar shifting

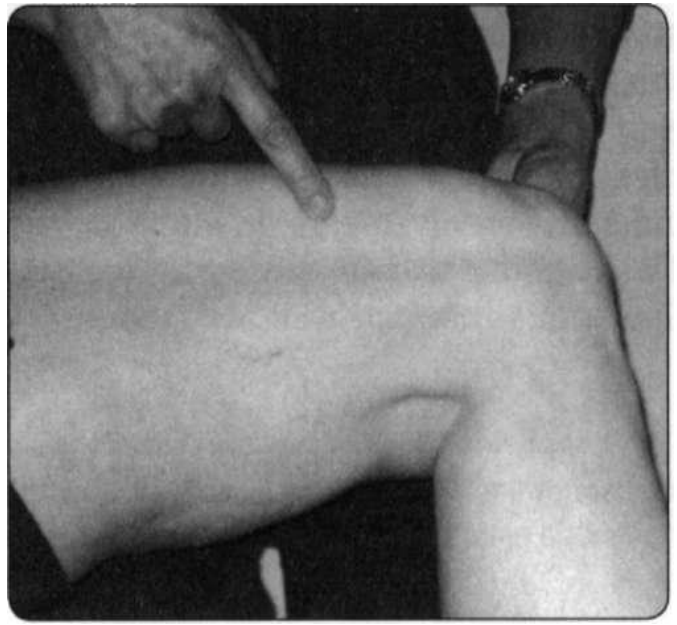

Leg

- Smaller tibialis anterior flattening of L5

Upper extremity

- Contour of deltoids
- Medial rotation of arms
- Arm position in sagittal plane
- Humeral head position

a

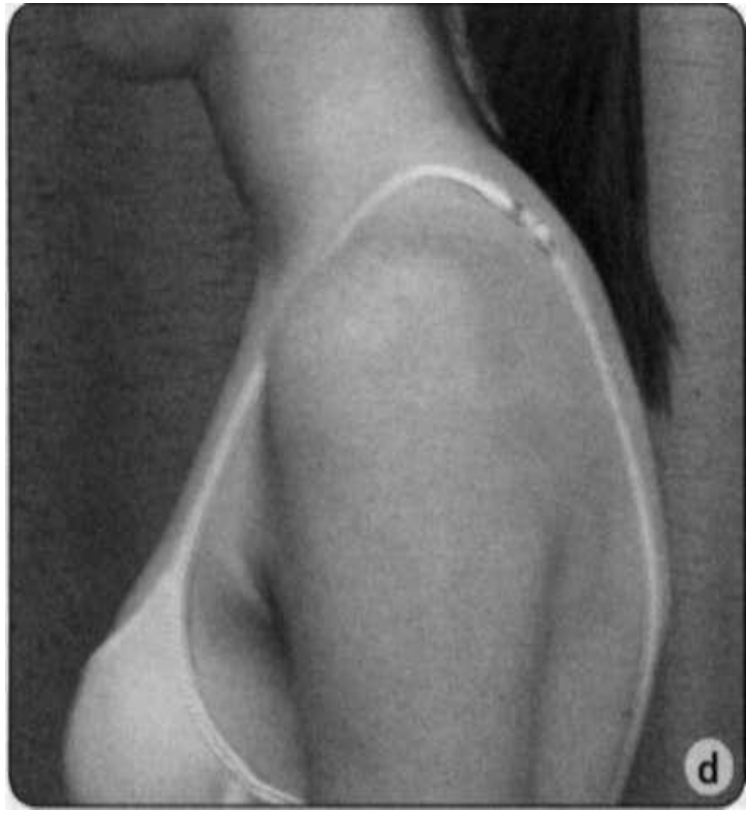
d

pectorals

- Increased bulk
- Nipple face out superiorly of laterally

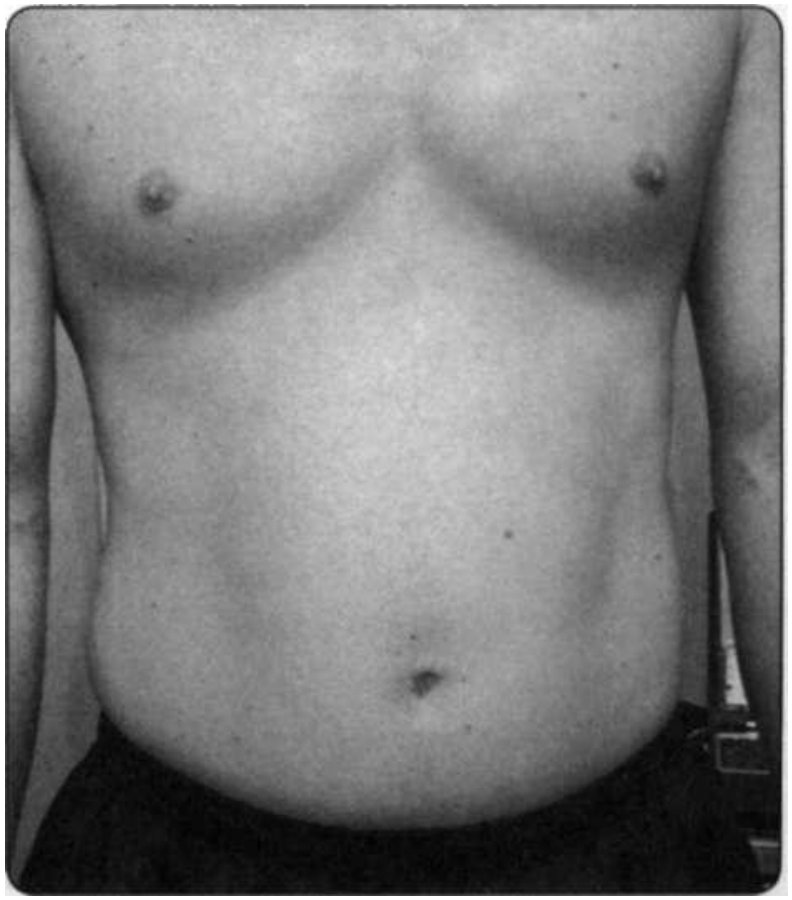

Head

- Forward head
- Groove anterior to SCM
- >90 ° angle btw chin and neck

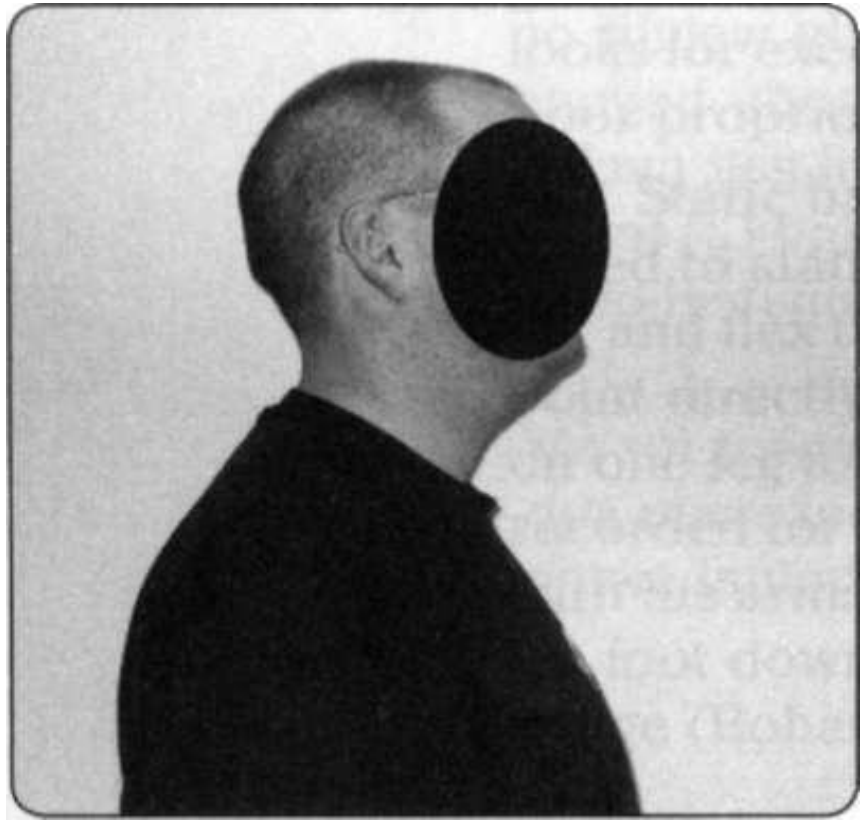

Inspection					반	학번		이름	
View	**Checkpoints**	**Observation**	**Rt**	**Lt**	**View**	**Checkpoints**	**Observation**	**Rt**	**Lt**
Posterior	**Pelvic position**	Lateral tilt (up)			**Posterior**	**Scapular position**	Height (T2-T7) Up		
		Lateral shift					Down		
		Rotation					Abduction >5cm		
		Ant. tilt					<5cm		
		Post. tilt					Clavicle >15˚		
	Lower gluteal fold						<15˚		
	Hamstring hypertrophy						Downward		
	Adductor S shape (pectineus)						upward		
	Calf/triceps surae prominence				**Anterior**	**Abdominal**	Breathing pattern		
							Neck muscle use		
	Heel shape	Round					Rib mobility ↓		
							Rib angle >45˚		
		Quadratic					<45˚		
							Patellar shifting		
		pointed			**Lateral**	**U/E**	Arm Int. rot		
							Forward (>90˚ btw chin and neck)		
	Spinal extensor	Asymmetrical (prominence)			**UCS (upper crossed syndrome)**	**Tight muscle**	SCM		
		Horizontal groove					Scalene		
							Suboccipital		
					LCS (lower crossed syndrome)	**Tight muscle**	Iliopsoas		
							Rectus femoris		
							Low back muscle		