Post-Treatment Brain Tumor Segmentation using MONAI SegResNet Model

Author: Wiley Winters

Date: 2026-03-08

Class: MSDS 692 – Data Science Practicum 1

Introduction and Problem Statement

- Many studies have been conducted on diagnosing brain tumors using various methods. Not many have been conducted on post-treatment follow up images.
- The likelihood of tumor regrowth increases significantly if it is not completely removed; therefore, accurately determining if a tumor has been completely removed is critical for developing the rest of the patient's treatment plan
- This study will train a MONAI SegResNet model using a BraTS-style MR Image dataset to preform brain tumor segmentation. After training, the model will be used to segment a post-treatment brain tumor dataset from the Cancer Imaging Archive

Background Information

In this part of the presentation I will provide background information on the following:

- What is segmentation
- Examples of segmentation
- Example of how segmentation can identify core tumor tissue
- Information about the different modalities used in MR Images

What is Segmentation

- When segmentation is applied to a brain tumor MR Image it identifies the boundaries of the tumor regions within the brain scan
- These boundaries are divided into masks and assigned a label
  - Label 0 – normal brain tissue (non-tumor/background)
  - Label 1 – necrotic/non-enhancing tumor core (NCR/NET)
  - Label 2 – edema (ED)
  - Label 3 – is not used to avoid confusion with binary encoders
  - Label 4 – enhancing tumor (ET)

What Segmentation Provides

Segmentation provides the following:

- **Location**: Identifies exact location of the brain tumor
- **Size and Shape**: Measures the tumor's dimensions and form
- **Heterogeneity**: Reveals different components within the tumor (e.g. solid tissue, necrotic areas)
- **Surrounding Tissue Involvement**: Shows how the tumor interacts with adjacent brain structures
- **Cross-Modality Comparison**: Provides a comprehensive view by comparing different imaging modalities

Visualization of Brain Tumor Segmentation

- Left image is an MRI slice with contrast agent (T1ce)
- Right image is the same slice with segmentation applied.
- The large purple area is normal brain tissue
- Non-enhanced tumor core (NET) is in blue
- Yellow is necrotic tissue and interruptions to the brain-blood barrier
- Green is edema (swelling)



Image is from post-treatment dataset

Brain Tumor Segmentation by Label

- By separating the labels, it becomes easier to identify the tumor's core and edema (swelling)
- In the example below, I have separated out the Labels into their own plots. This makes it easier to identify the residual brain tumor tissue
- The red box outlines the residual tumor material

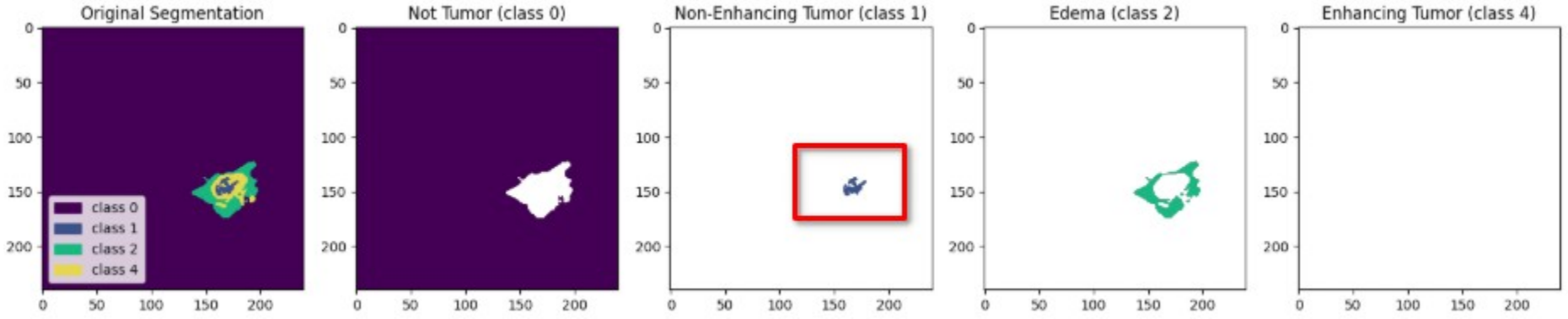

MR Imaging Modalities Used in Segmentation

MRI segmentation is preformed by comparing the results of different MRI sequences (modalities)

SEQUENCE	KEY USE
T1 (Native)	Reveals the structure and composition of various tissue types in the brain
T1ce post-contrast	Similar to T1, but enhanced with a contrast agent which improves the visibility of abnormalities
T2	This modality highlights the fluid content within brain tissue
FLAIR (T2F)	Suppresses the fluid signals, making it easier to identify lesions (tumors) that may not be visible on T1 or T2 images

Examples of the Modalities and Mask

These images are of the same patient post-treatment for a *glioma* brain tumor. All of the modalities are summarized in the Mask (segmentation)

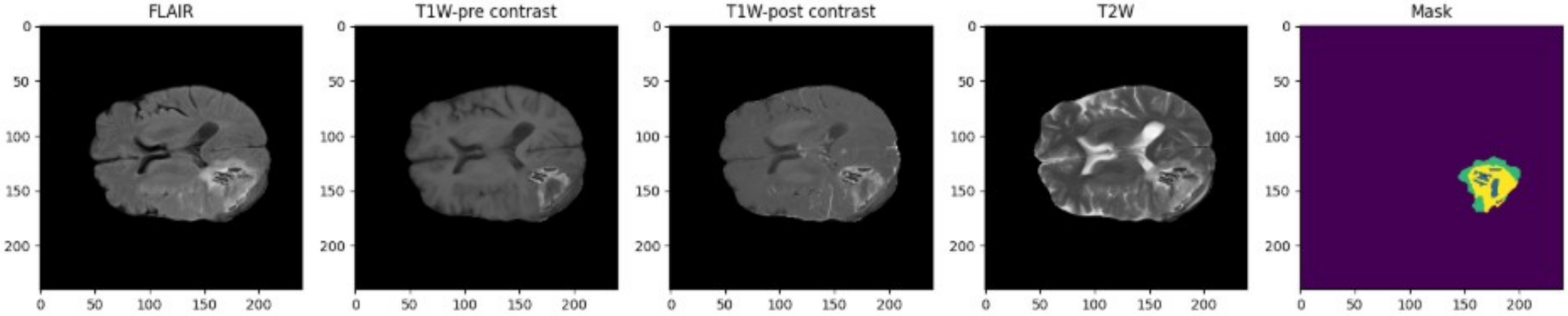

Dataset and Data Preparation

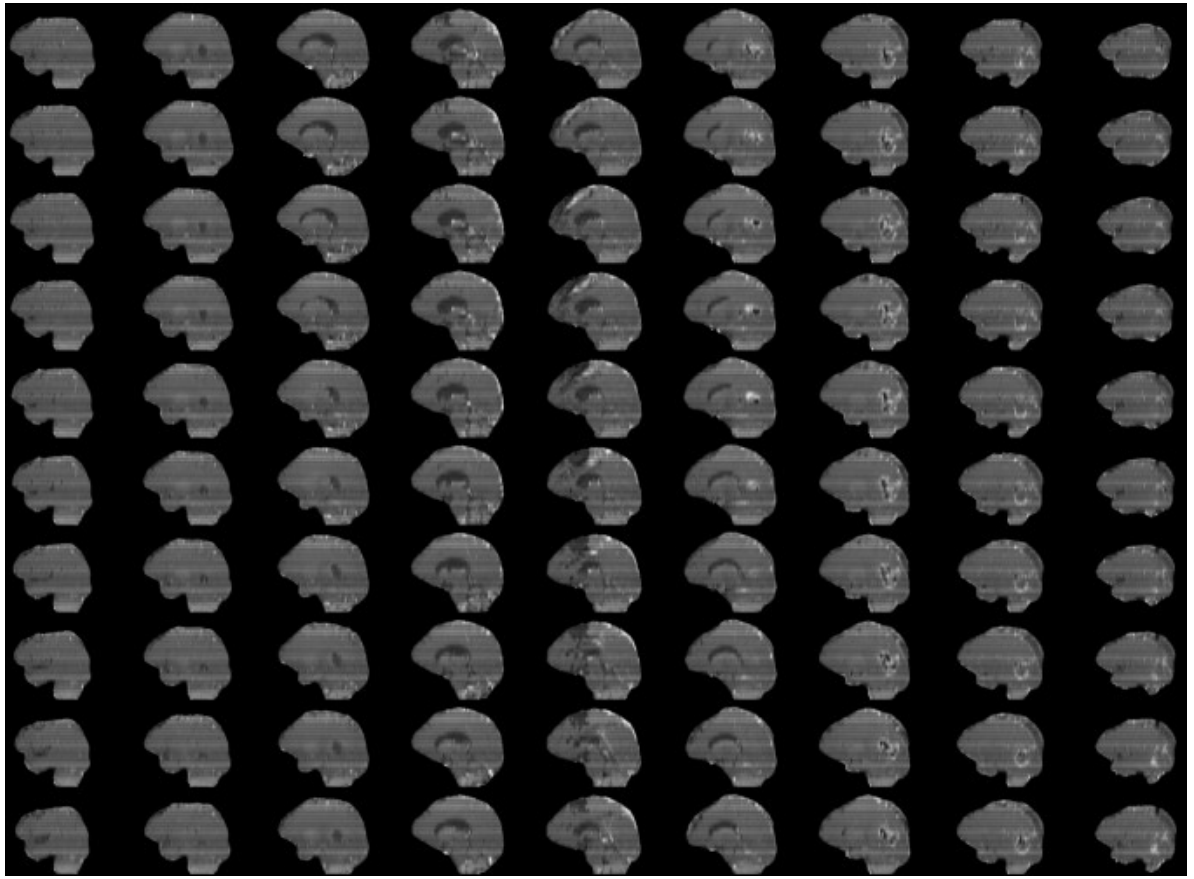

- The training data was obtained from the **Medical Segmentation Decathlon (MSD)** and is a subset of the BraTS 2016-2017 datasets
- This dataset is comprised of 4 structural modalities (T1, T1ce, T2, and T2-FLAIR)
- Consists of 750 multi-parametric MR brain scans from patients with glioblatoma (GBM) or lower-grade glioma (LGG)
- All samples were skull-stripped using various methods and normalized by the MSD organization

Model Selection

The Medical Open Network for Artificial Intelligence (MONAI)'s SegResNet model was chosen for the following reasons:

- It is a residual encoder/decoder CNN designed specifically for 2D/3D medical segmentation
- Uses less GPU resources than a transformer-style model making it a good fit for training with consumer grade GPUs
- Is a top performer in challenges like BraTS
- Is part of the vast MONAI ecosystem
- Uses the u-net architecture as its core building block

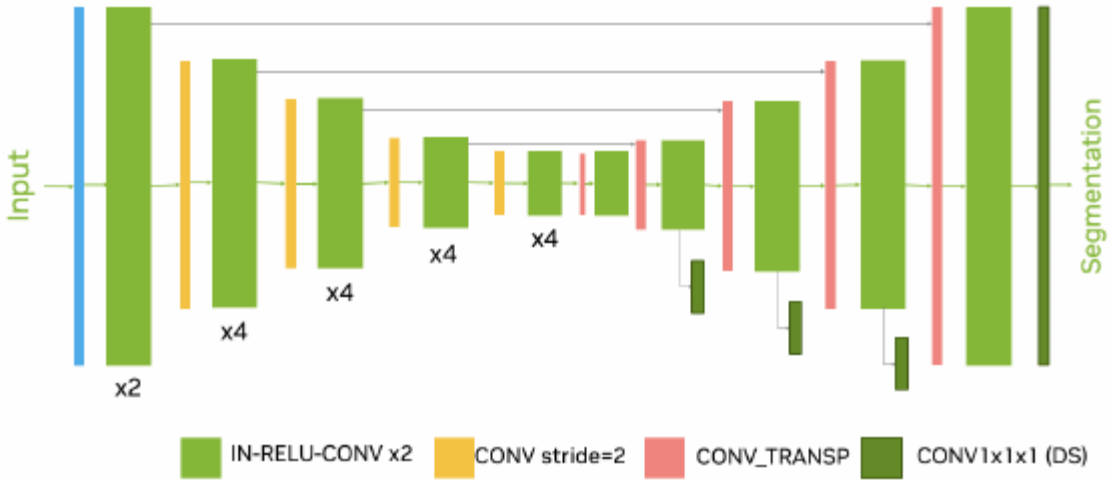

Evaluating Training/Validation Performance

- Evaluating the performance of segmentation models is slightly different from binary and multi-class CNNs
- Validation loss per epoch is still used, but accuracy is replaced with validation mean dice score, which quantifies the average overlap between the model's predicted segmentation masks and the ground-truth (human-annotated) labels across all classes and validation samples.
- For this training run the average loss was 0.42 and mean Dice score 0.70

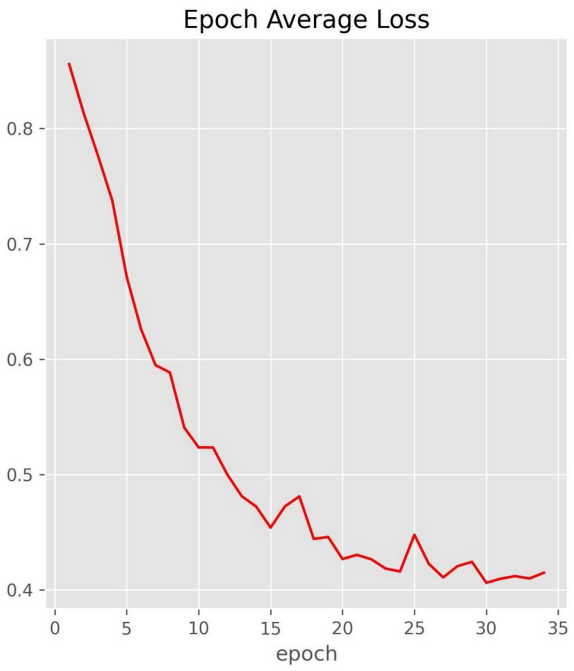

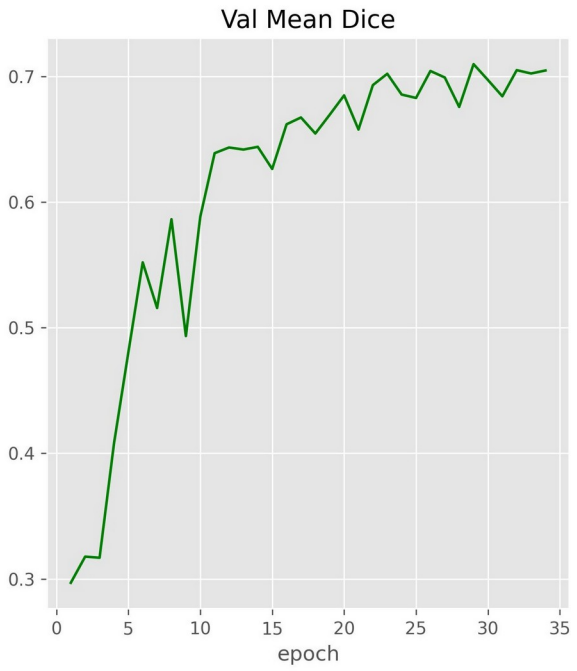

Mean Dice Score Per Region

- Further evaluation can be conducted by examining the Mean Dice Score for the labels of interest. The plots below illustrate the model performs best when segmenting the whole tumor (WT) and worse on enhancing tumor (ET).

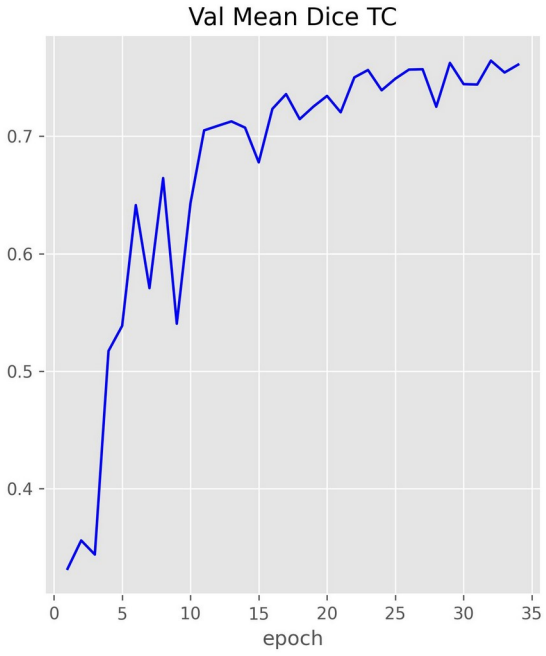

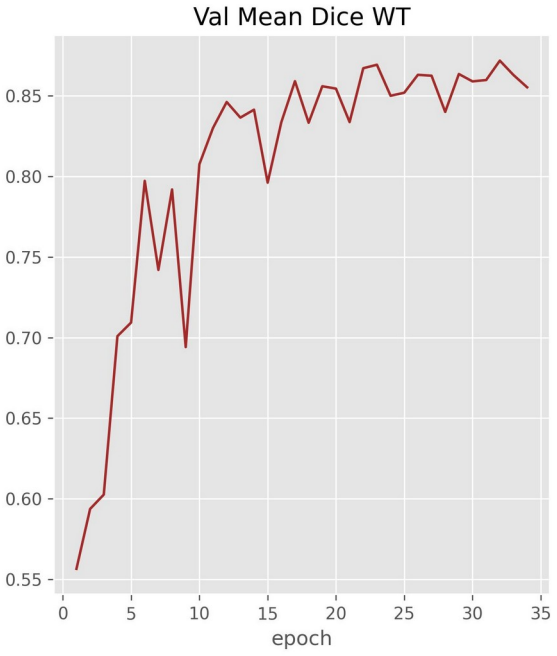

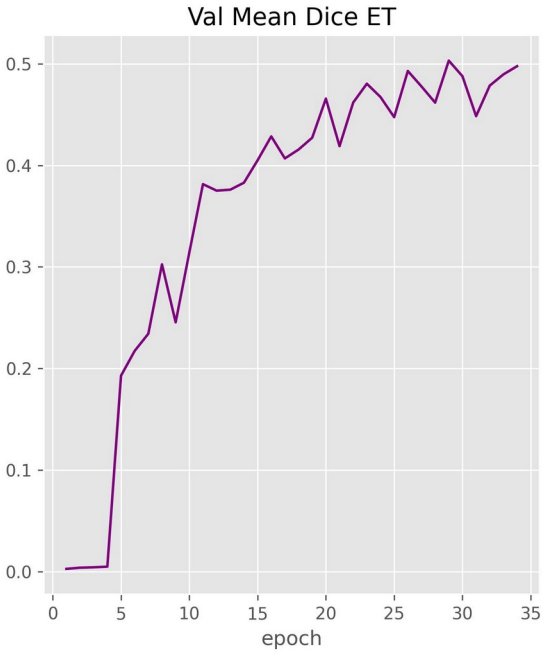

Inference Results

- An image was randomly selected from a post-treatment *glioma* patient dataset, the best training weights were loaded and inference was preformed on four separate channels.
- Results were acceptable and more tuning will have to be completed

METRIC	VALUE
Mean Dice Score	0.61
TC mean Dice Score	0.65
WT mean Dice Score	0.77
ET mean Dice Score	0.42



Conclusions

- Traditional CNN classifiers trained on pre-treatment brain tumor MR Images are not able to accurately classify post-treatment images and segmentation methods should be used
- Performing segmentation on post-treatment MR Images can aid in identifying healthy brain tissue, core tumor residue, abnormalities to the blood-train barrier (BBB), and edema.
- Modern segmentation models based on the U-Net architecture are the standard for segmentation of multi-modal MR data
- International segmentation competitions have provided a platform for citizen data scientist, researchers, and organizations to create and learn segmentation techniques
- From these competitions there has been a handful of self-supervised learning models developed and made publicly available. More research should be conducted in this domain

Challenges Encountered

Challenges

- Attempted to use a pre-trained binary CNN classifier to classify post-treatment brain tumor MRI images. Classifier could not determine if resection cavity was a tumor or not
- Using ***cutting-edge*** models proved to be problematic. Use of pre-trained models from MONAI often broke existing Python Packages
- File path inconsistencies between datasets

Solutions

- Further research indicated this approach was not feasible and many researchers used a encoder/decoder method to preform brain tumor segmentation. Modified my study to follow this path
- Worked around broken packages by paying extra attention to versions. Used different packages when possible
- Created custom data loaders for each dataset

Questions

?