Oral Pathology Clinical Pathologic Correlations

7th Edition

Authors: Joseph Regezi James Sciubba Richard Jordan

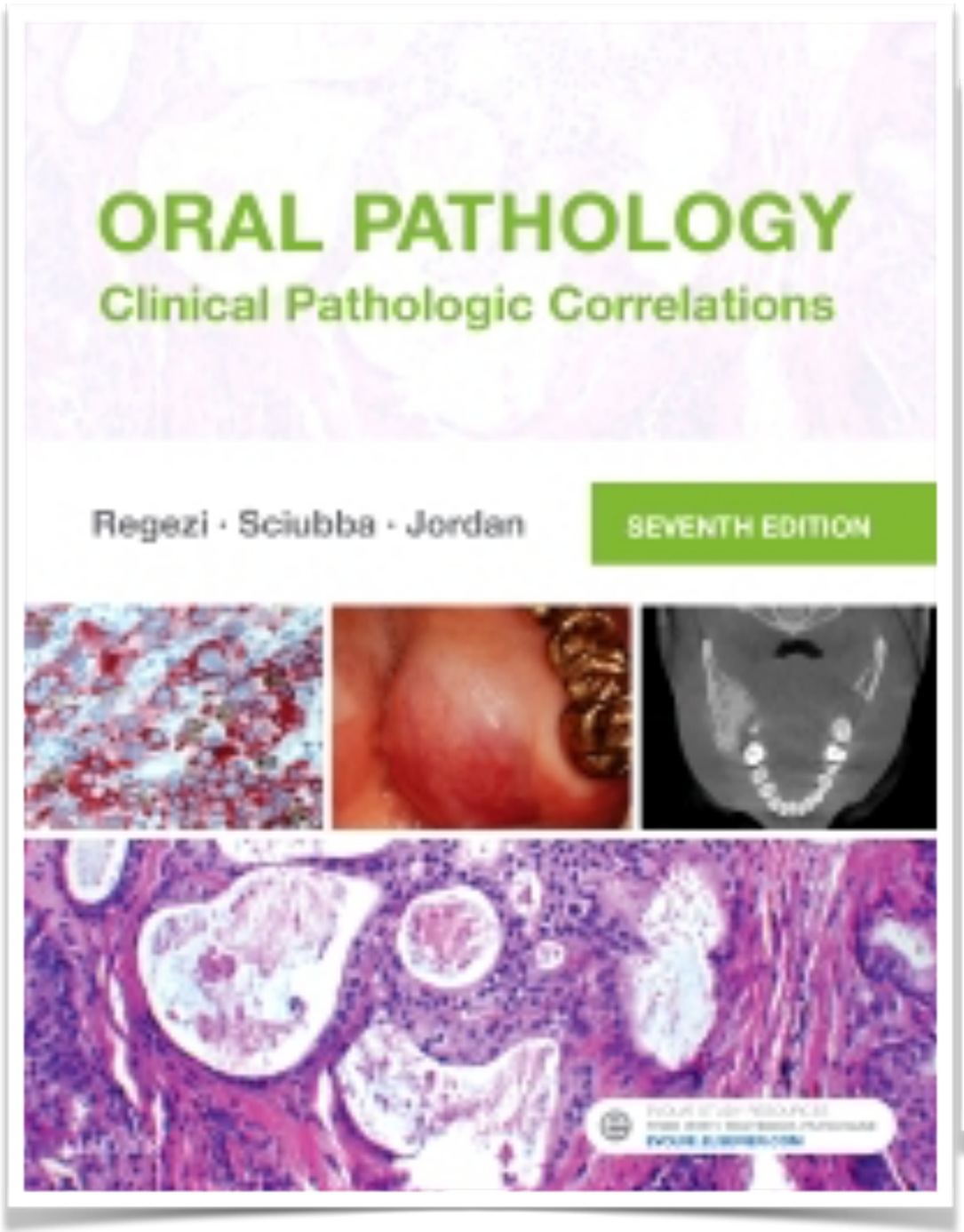

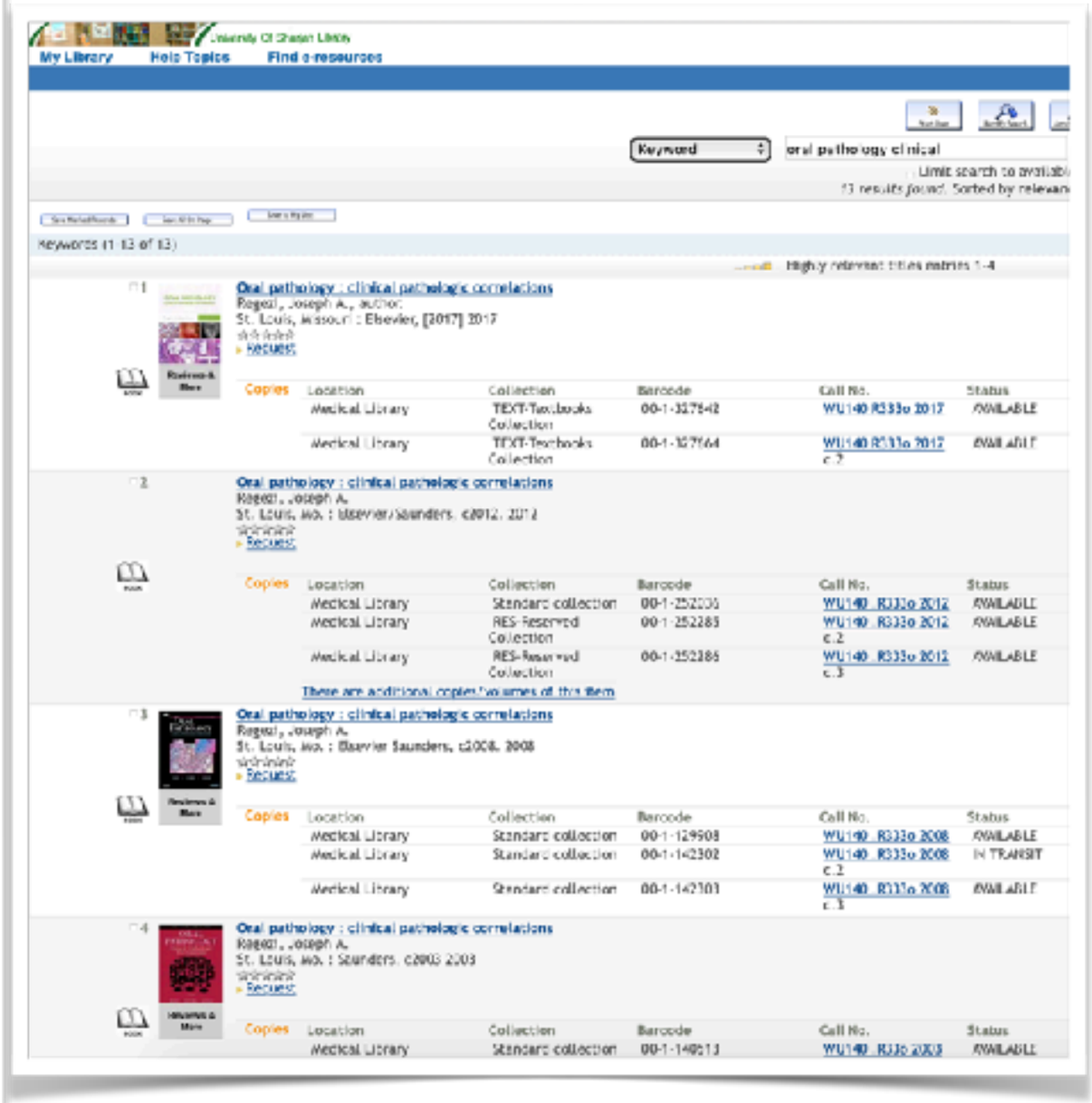

Diagnosis is the investigation of a condition. Identifying and examination. It's important to achieve the correct treatment.
Misdiagnosis leads to wrong treatment and wrong pathway.
Reasons for misdiagnosis: similar signs and symptoms of different diseases
In differential diagnosis: ask about history, take biopsy, do enough examination and order imaging.
You should do a full examination and take full medical history

YOU SHOULDN'T OVER INVESTIGATE BECAUSE IT CAN HARM AND COST MORE FOR THE PATIENT.

Oral Diagnosis

Dr. Suhail Al-Amad

2nd Sept 2019

Follow test practice guidelines and then decided what needs to be done according to that

Steps:

1- [Examination] First when the patient comes in you see the way they walk talk and feel

2- Take history and chief complaint

3- Investigate using a machine or other tests.

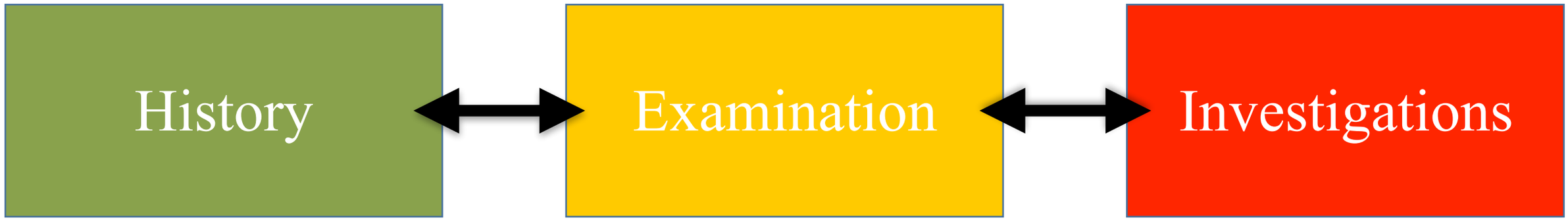

It's a dynamic process, start with history then examination then history when you fine something through the examination. You keep jumping back and forth

EX: You do an investigation (CBCT) and then ask about the history of the anaemia. Go back to history and examination so that investigation results should make sense. Keep doing this until you get the correct diagnosis

History…

It is better to know what kind of patient has the disease, than what kind of disease the patient has.

Sir William Osler

History is a dialogue between two experts.

Communication is very important and establishing a complete image is of greater importance that knowing what kind of disease the patient has.

History…

- History is all about communication
- History is a continuous process throughout the clinical consultation
- Start with open-ended questions and finish with closed-ended questions.

Correlate between features of the patient and disease they have and look for signs while communicating with them.
The patient is the expert of their body and the DR is the expert of the nature of the disease but the misdiagnosis happens due to poor communication.
The comfort of the patient is very important. It's established with the way the communication is handled, and the attention of the dr to the patient's answers and giving the patient the chance to talk and show them that you understand and listening to him.
If you fail to pull out the right info in the right way and didn't give enough time means failed appointment and patient wont be comfortable and won't come again :(

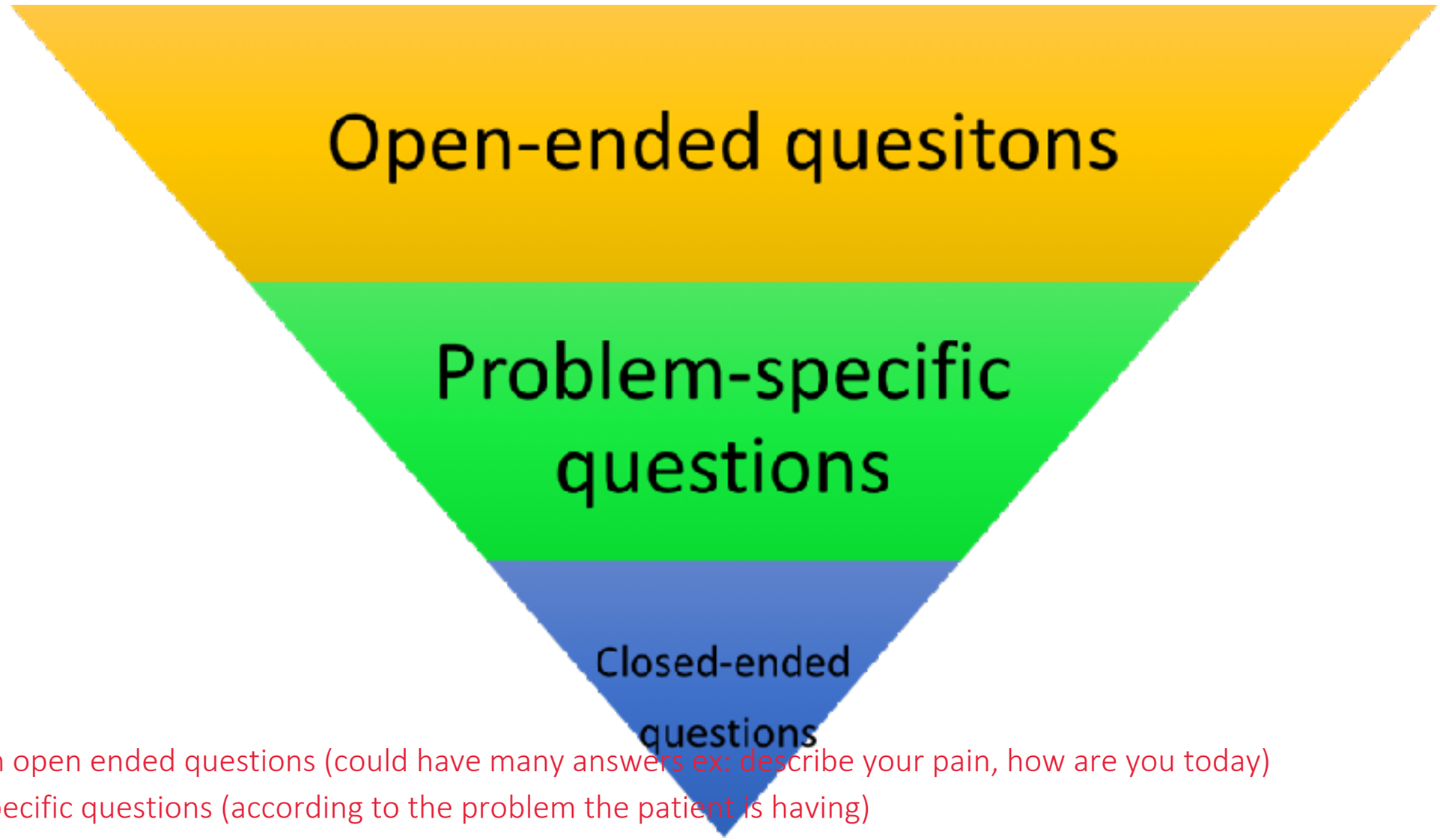

Always start with open ended questions (could have many answers ex: describe your pain, how are you today)
Then problem specific questions (according to the problem the patient is having)
Finish with closes ended questions (yes or no with predicted answers)

- When patients speak up they give you more hints about the diagnosis and more symptoms.
- Dont ask about history until patient is comfortable (upright position) and tray is away from him to reduce anxiety.
- Make sure light is off and clinic is quiet so they feel comfortable.
- At the end repeat briefly what he said. Gives feels that you were listening to them
- Write everything in the patient own words for legal issues and to avoide gaps.

History taking

Avoid arbitrary questions.
Organize your questions in a logical order

- General information
- Presenting complaint
- History of the presenting complaint
- Medical history
- Drug history
- Dental history
- Family history
- Social history

- ***Presenting complaint***

Patient's own words

- ***HPC***

When did this start?

How long does it last for?

Where is it located? Does it change location?

What aggravates it? What relieves it?

What have done about it? (previous consultations, previous tests, previous treatments).

- ***Dental history***

Attendance

Recent dental problems

Recent dental treatments

- ***Family history***

Hereditary and familial conditions

- ***<u>Social history</u>***

Marital status

Residence

Employment

Insurance

Socioeconomic status

Diet

Habits; smoking, alcohol, drug abuse

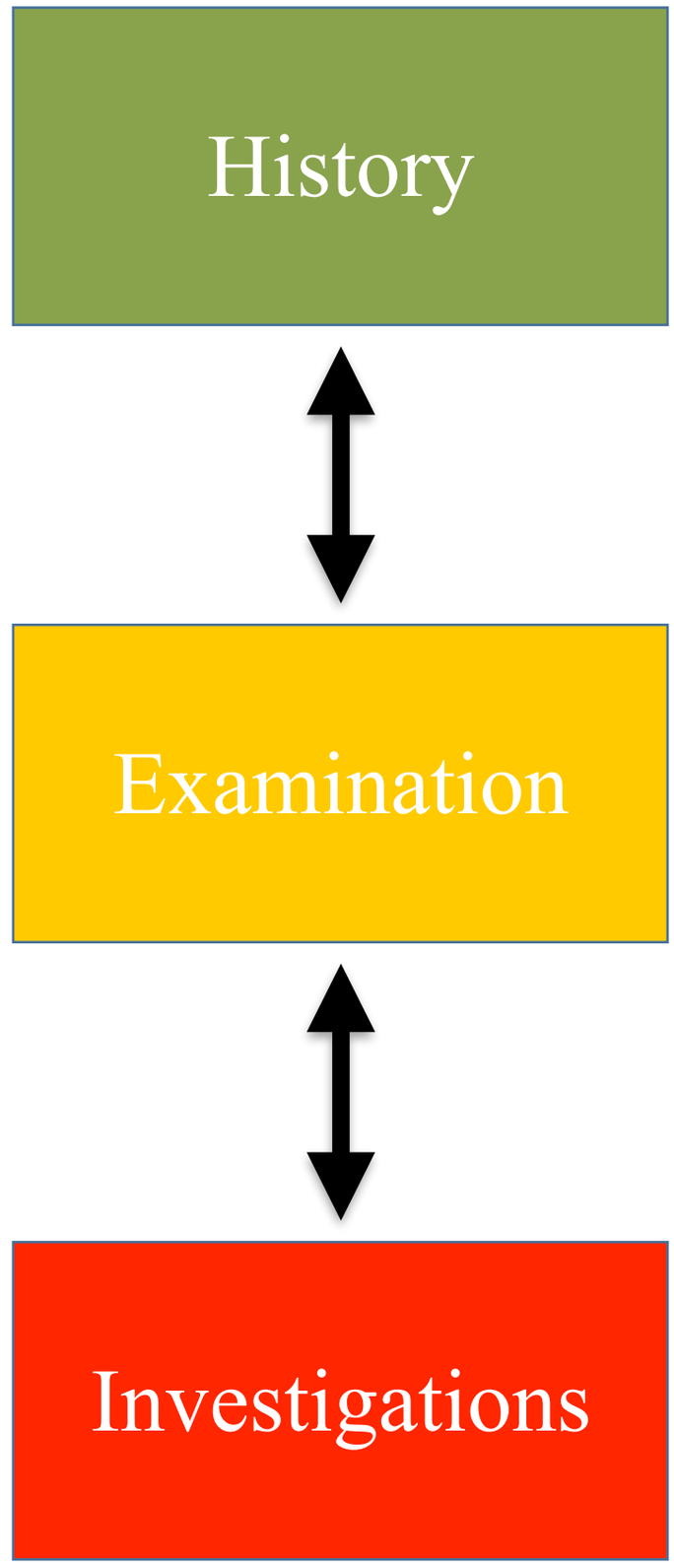
History
Examination
Investigations

- Remove any oral appliances before the examination.
- Use light during examination.
- Examination of the upper and lower labial mucosa is by everting the lip and viewing the labial vestibule.
- Examination of the buccal mucosa is by using two instruments to retract the cheek.
- Examination of the tongue is by retracting the cheek and pulling and rotation the tongue in the opposite direction with a gauze.

Examination

1- Early Nonsystemic Examination (Collect from observation, ex: asymmetry in face)
2- Targeted examination (ask about info from #1)
3- Systemic examination (seeking information, follow precises sequence so you don't miss anything).

- Inspection
- Palpation
- Percussion
- Auscultation

Examination is about picking up the abnormalities which are secondary features that the patient won't provide you with.
If a lesion is there since patient is born then you don't worry but if it's recent then it's a cause to worry.

- Examination begins as the patient walks into the clinic

Use your five senses.

Sight
Smell (halitosis, acetone (DM), alcohol)
Touch (palpate)
Hear (TMJ Clicking)
Ask patient about their taste

Inspection

dont search, just notice

- Intellectual ability and communication skills
- Posture and mobility
- Body build
- Skin color
- Hands, nails
- Facial appearance
- Vital signs

Inspection

- Head and Neck
  - Skin color: pale, yellow, red, blue
  - Skin condition
  - Hair condition
  - Asymmetry

You should always see the whole body because they have manifestation as well.
Screen whole body for manifestations.
The patient might come for a simple thing but you can discover a larger image and a hidden disease since the mouth is a mirror to the body and it's a part that you can see and represents what happen internally

Dont stare at the patient for the asymmetry you can pick it up while talking to them.

Palpation

- Head and Neck
  - Lymph nodes
  - TMJ
  - Masticatory muscles
  - Salivary glands
  - Lesions

- Start with palpation of submental then submandibular lymph nodes (tilt head to gather the tissues under for better examination)
- Then check for SCM Muscle and the lymph nodes under it
- Check for TMJ and ask patient to open and close
- Then check for lip and depth of vestibule (use 2 instruments for better vision, keep moving them so there is nothing hiding/)
- Hold the tongue and rotate it and then ask the patient to touch the upper teeth with the tongue and check the ventral surface of the tongue and use the mirror to reflect light to overcome shadow .
- Check for palate
- Check oropharynx
- Depress tongue and ask patient to say AHH and check softpalate, uvula, tonsils and posterior part of tongue and posterior part of pharynx.

Percussion

- Teeth
- Sinuses

Auscultation

- Teeth
- TMJ

Loss of tissue is either erosion (when only the superficial part of the tissues has been lost (red and inflamed)) or ulceration (when you see the connective tissues with your eyes (like white, gray, yellow) and you should describe the color to make the app. judgement.

If you observe a cyst check whether is it fluid-filled, pus-filled or blood-filled and describe it.

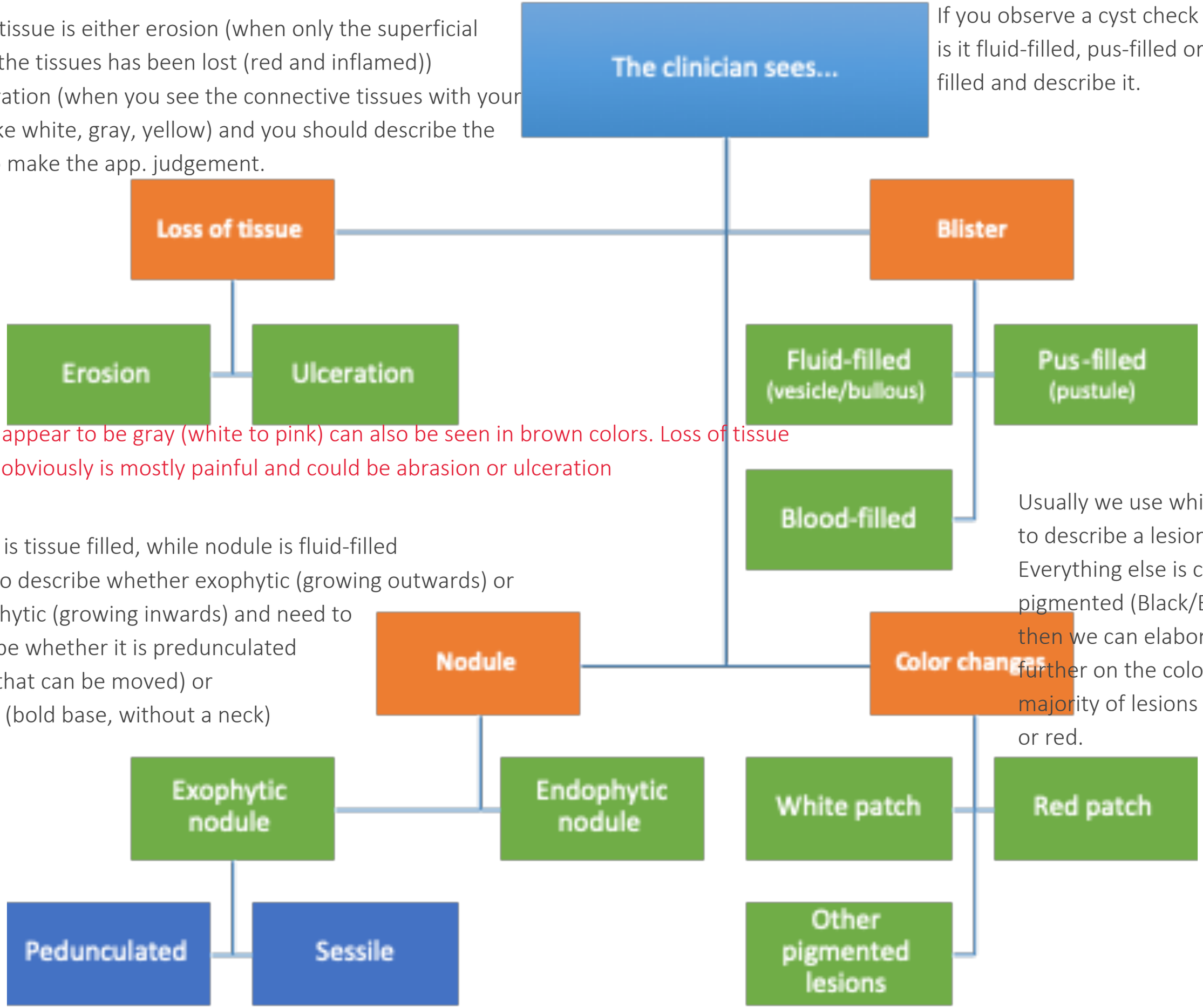

Ulcers appear to be gray (white to pink) can also be seen in brown colors. Loss of tissue that is obviously is mostly painful and could be abrasion or ulceration

Blister is tissue filled, while nodule is fluid-filled need to describe whether exophytic (growing outwards) or endophytic (growing inwards) and need to describe whether it is predunculated (neck that can be moved) or sessile (bold base, without a neck)

Usually we use white or red to describe a lesion. Everything else is called pigmented (Black/Blue) and then we can elaborate further on the color. But majority of lesions are white or red.

[CASE: HEMATOMA]
Worry about blood bleeding disorded (liver disease, clotting factor disturbance, liver cirrhosis and vascular cirrhosis, liver carcinoma, hemophilia, bone marrow metastasis, leukemia, fall, lose consciousness)
If no signs, maybe abuse? Look for social reasons

[CASE: LABIAL LESION WITH EROSION AND CRUSTING (dry blood and fibrin) BLEEDING CONFINED TO THE LIPS AND DOESN'T EXTEND OVER THE VERMILLION BORDER, ONLY MUCOSAL PART OF LIP, HAPPENED AFTER TEMPORARY FILLING]
Could mean allergic reaction type 1, anaphylactic shock (swelling of lip and angio-edema). Crusting indicates contact allergy => Erythema multiforme disease

[CASE: LA ALLERGY (SWELLING)]
This might cause anaphylactic shock causing loss of consciousness and shortness of breath and suffocation.
Call ambulance because this can cause death.

[CASE: CLUBBING FINGER]
This is most probably due to a CVS disease, respiratory disorder, an anomaly that has been there since birth or due to acromegaly

[CASE: SPOON SHAPED NAILES]
Iron-deficiency anaemia (should have been there for months so that there has been a change)

[CASE] FUNGAL INFECTION ON TOE NAILS
Dystrophic changes indicates neglected or poor immunity such as leukemia (most common in children)

[CASE] DROPPING OF THE EYE AND PROTRUSION
Hypothalamus if both eyes || Bells palsy: do examination for cranial nerve || tumor that is causing eye bulging || congenital1

[CASE] SWELLING OF THE UPPER EYELIAD AND REDNESS (ERYTHEMA) AND CRUSTING THAT DOESN'T CROSS MIDLINE
Problem with the nerve (and its related skin) --> Ophthalmic branch of trigeminal nerve is only upper eyelid and forehead.

Investigations categories

- Radiology
- Blood and urine tests
- Tissue samples

Radiology

- Intra-oral radiography
- Ortho-pantomography (OPG)
- Sialography
- Arthrography for tmj
- Angiography

Sialography: contrast material is injected through the duct and radiograph is taken, can cause allergy. Contraindicated for renal failure pts. and patients with salivary gland stones (since by injecting any material you will be pushing the stone inwards). Also contraindicated with patients with sialinitis since it complicates the treatment.

angiography to detect blood vessels in tumors

Radiology

Computed Axial Tomography (CAT scan)

Radiographing inaccessible anatomical areas

Valuable for assessing spread and planning surgery

Very high radiation

Expensive

• Magnetic Resonance Imaging MRI

Good for visualizing soft tissues

Good for imaging the TMJ

Good for assessing bone invasion

Not good for imaging hard tissues

Subject to artifacts

Expensive and inaccessible

Can not be used in patients with implanted electronic devices or metals

Radiology

- Scintiscanning (isotope scan)

  Sodium pertechnetate has affinity to salivary tissues and is taken up following IV injection.

  The reaction can be captured using gamma camera.

  Useful for detecting presence or absence of salivary gland(s) (aplasia), and diagnosing salivary gland disorders.

This is to detece the existence of salivary glands, since some people lack it and it's congenitally missing. These people usually come at an early age with excessive carious lesions and wouldn't know the feeling of a dry mouth, so the first sign is good hygiene but excessive caries.

Blood tests
Haematology

- Full blood count (complete blood count):
- Blood film
- Erythrocyte Sedimentation Rate (ESR)
- Prothrombin time and thromboplastin time

Haematology includes:
- CBC (RBC WBC PLATELETS)
- RBC INDICES (Size-haem, level-hematocrit, ESR-MCV) ===> Elevated reading means RBC is large and decreased means size is small with iron or vitamin B12 problem. Should be followed up with another test for VB12 and iron.
- WBC differential count
- Prothrombin time
- Thromboplastin time (helps in determining bleeding tendency)
- Biochemistry (blood glucose level)
- Electrolytes (Kidney) in patients taking corticosteroids for a long time
- Liver function test (clotting factors to check for their presence before surgery and check that the liver can metabolize medications before use. Also to check for enzymes (Increase if liver cells are damaged since the enzymes will escape to blood leading increase in their blood level). This will never be 0 but an elevation is an indication of frequent death of hepatocytes
- Bone metabolism (opacity/radiolucency) or clinical changes like bone growth, loss of teeth, sudden malocculsion, macromegaly, paget disease, fibro-osseous disease
- Iron studies -- screens for iron deficinecy (if patient has a lot of erosions, glossitis)

Blood tests
Biochemistry

- Blood glucose level
- Electrolytes
- Kidney function test
- Liver function test
- Bone metabolism
- Iron studies

Blood tests

- Vitamin B_{12}
- Folate
- Serology (Antibodies)
- Hormones (GH, PTH, Cortisol…etc)

Interpreting CBC

Test	Interpretation
Erythrocytes	Increased: Polycythemia
	Decreased: Anemia and bleeding
Leukocytes	Increased: Infection and inflammatory processes. Leukemia.
	Decreased: Bone marrow diseases, such as aplastic anemia, infections, tumours. Damages due to radiation of cytotoxic drugs. Some connective tissue diseases, such as SLE, and heamatological deficiencies.
Neutrophils	Increased: Acute bacterial infection. Myocardial and pulmonary infarction. Leukemia
	Decreased: **Known as neutropenia**. Pancytopenia, aplastic anemia. Radiotherapy and Chemotherapy and other drugs suppressing the bone marrow. Malignant infiltration of the bone marrow.
Eosinophils	Increased: Allergy. Parasite infestation. Asthma. Malignancy.
	Decreased: Insignificant
Basophils	Increased: Chronic myeloid leukemia.
	Decreased: Insignificant
Lymphocytes	Increased: Viral infection, including AIDS. Acute and chronic lymphocytic leukemia
	Decreased: HIV and AIDS. Bone marrow suppression after chemotherapy, steroids, MS
Monocytes	Increased: Bacterial infection. Leukemia.
	Decreased: Lymphocytic leukemia. Aplastic anemia.
Platelets	Increased: Exercise. Trauma. Following surgeries and acute haemorrhage. Leukemia.
	Decreased: ITP. Congenitally. Bone marrow suppression. Venom of snakes and insects. Use of NSAIDs, anticonvulsants and aspirin for more than 30 days.
MCV	Increased: Megaloblastic anemia (due to vitamin B_{12} and folic acid deficiency). Chronic alcoholism. Chemo- and radiotherapy.
	Decreased: Iron deficiency. Thalassemia.
MHCH	Increased: Chronic severe dehydration.
	Decreased: Iron deficiency anemia. Overhydration.
ESR	Increased: Infection. Inflammation. Malignancy. Pregnancy.
	Decreased: N/A

Tissue sampling

- A biopsy is indicated when you encounter a:
  - suspicious lesion
  - chronic non-healing lesion
  - lesion interfering with normal daily functions
  - lesions causing anxiety
  - lesion of uncertain aetiology

Tissue sampling

- Biopsies:

  Exfoliative biopsy (cytology) Surface cells only (gynecology)

  Deep exfoliative biopsy (brush biopsy) entire thickness of epithelium (no CT)
  - IN BOTH WE ONLY COLLECT LOOSE CELLS NOT INTACT CELLS

  Fine needle aspiration biopsy (FNA) Fluid inside a specimen

  Punch biopsy collect intact tissue, helps in diagnosis of malignancy

  Scalpel biopsy (incisional and excisional) Incision: remove part of lesion
  excision: remove whole lesion

- Microbiological smears for direct examination and culture.

Biopsy

- A biopsy should be:
  - –Representative
  - –Sufficient
  - –Placed on a piece of paper
  - –Fixed appropriately after collection
  - –Perilesional tissue is only indicated in certain diseases (i.e. auto-immune)

DONT TAKE BIOPSY FROM EDGE OR CENTER (Necrotic)
Don't over-conserve the biopsy
Once biopsy taken, place on a piece of paper and fix properly

take tissue from neighboring normal mucosa is only indicated in certain diseases

- You should know what your are sampling: hard or soft tissue? Fluid-filled? Sessile or pedunculated

Summary of biopsy steps

Steps:
1- Take whitest white, try to include spots
2- Cut edges, do an undercut and hold with tissue forcep very gently from underneath
3- make sure it's intact, sufficient and well oriented.
4- Suture the gap
5- put biopsy on piece of paper so it reaches the lab in same orientation as the one in mouth
6- stabilize it
7- put in fixative solution
8- send to lab

Consent and photo-documentation

Selection of a representative site

Local anaesthesia

Tissue collection

Fixation (chemical or frozen)

Labelling specimens

Suture and haemostasis

Instructions

Aids to select the most representative lesion

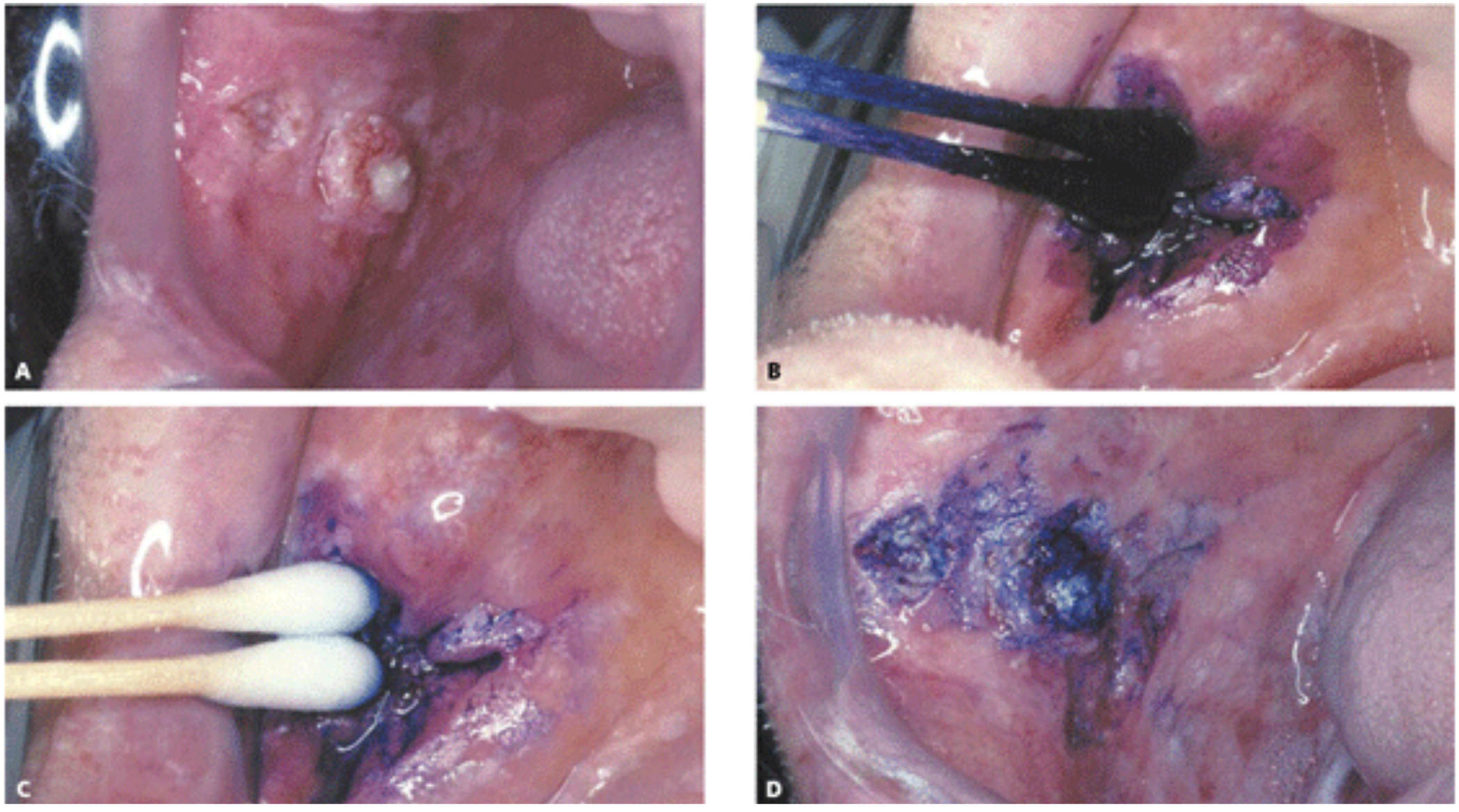

Source: Electronic Pathology Information Exchange
www.dental.wanshington.edu/pralpath

Aids to select the most representative lesion

- Vesilight: bad system
- Toluene blue: acidophilic liquid that has affinity to acid, can find that mainly in DNA, the more DNA the more stain picked up. It's very messy and it's carcinogenic itself.
- Billiscope
- Diascopy is a glass slide that you press on the lesion, if it disappears means angioma since you press and push the blood that is inside into the feeding blood vessels and if didn't go then hematoma (no escape since trapped in tissue)

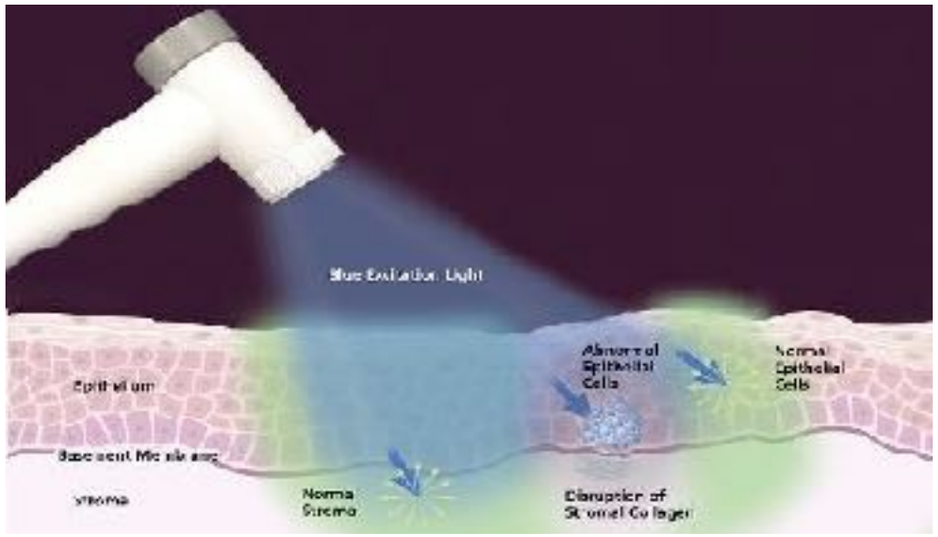

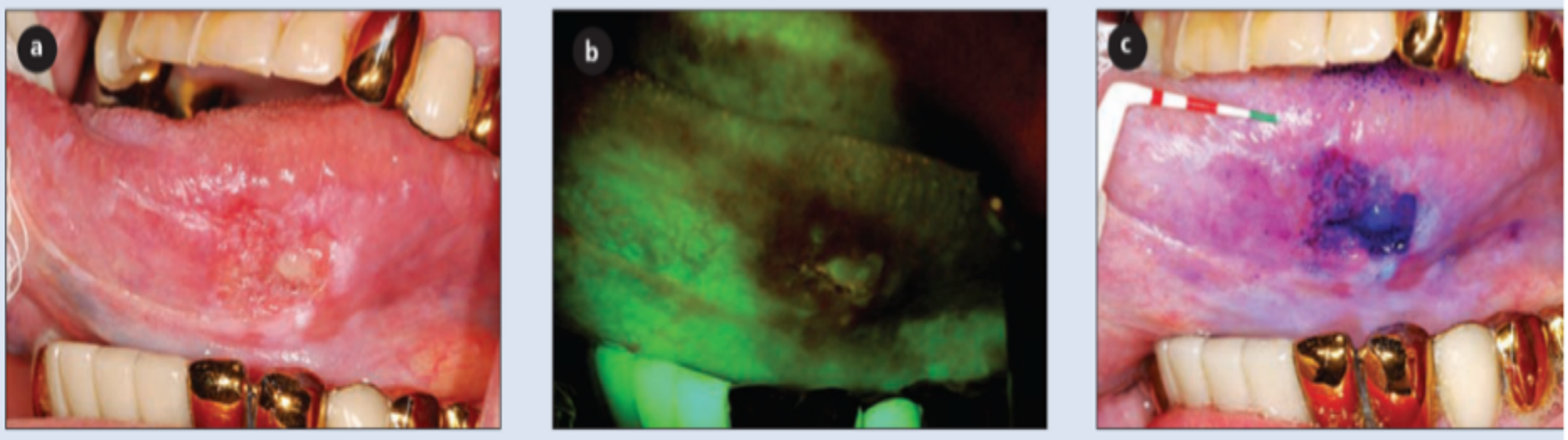

Figure 1: Use of fluorescence visualization and toluidine blue (TB) to select the biopsy site. **(a)** Clinical picture of a nonhomogeneous leukoplakia under white light. **(b)** The same lesion under direct fluorescent visualization. Note that the extent of the lesion, as seen by loss of green autofluorescence, is bigger than the clinical lesion seen by the unaided eye in Fig. 1a. **(c)** The same lesion stained with TB showing TB positivity with varying intensity of TB staining. In our experience, the area of the lesion with strong TB staining usually has worse histologic results than the less stained or negative area of the lesion.

Source: Catherine F. Poh et al, “Biopsy and Histopathologic Diagnosis of Oral Premalignant and Malignant Lesions”. JCDA, www.cda-adc.ca/jcda, April 2008, Vol. 74, No. 3, pg. 283-288.

Fixation

Chemical fixation

- Routine: 10% formalin
- Alternatives
  - 70% alcohol
  - Saline
  - Freeze until formalin or 70% alcohol available

Frozen section

circular blade and push with slight rotation
it will cut along the way

Punch biopsy

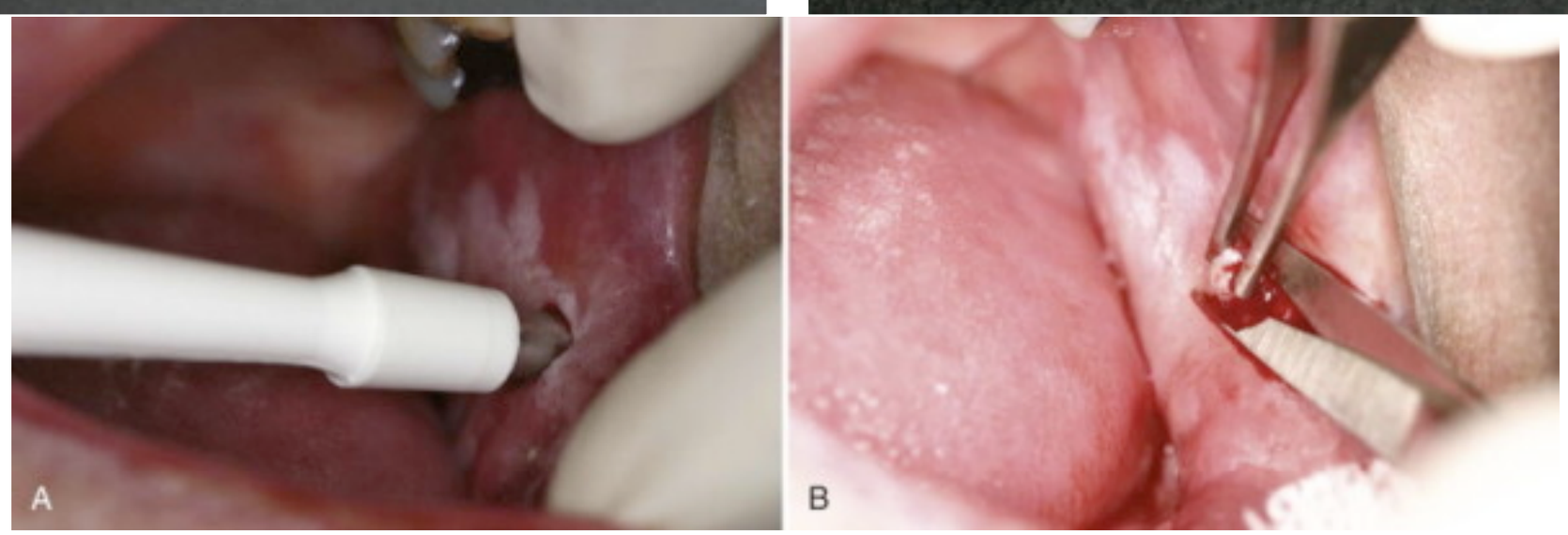

Image source: Woo, Oral Pathology 2012

Frozen sections

fo

- Establish whether tumour is malignant at time of surgery
- Establish whether margins are clear
- Preserve the antigen-antibody interaction in autoimmune diseases

- Distortion of tissue due to freezing artefact
- Definitive diagnosis difficult to establish

Lab preparation of tissues

- Haematoxylin and Eosin (H&E) stain.
- Special stains
- Immuno-histochemistry
- Immuno-flouresence
- Molecular and Genetic studies

Lab preparation of tissues

- Haematoxylin and Eosin (H&E) stain.
  - Most commonly used stains.
  - Haematoxylin stains nuclei, keratin, calcified material blue.
  - Eosin is a counter stain, which stains other parts (cytoplasm) orange.

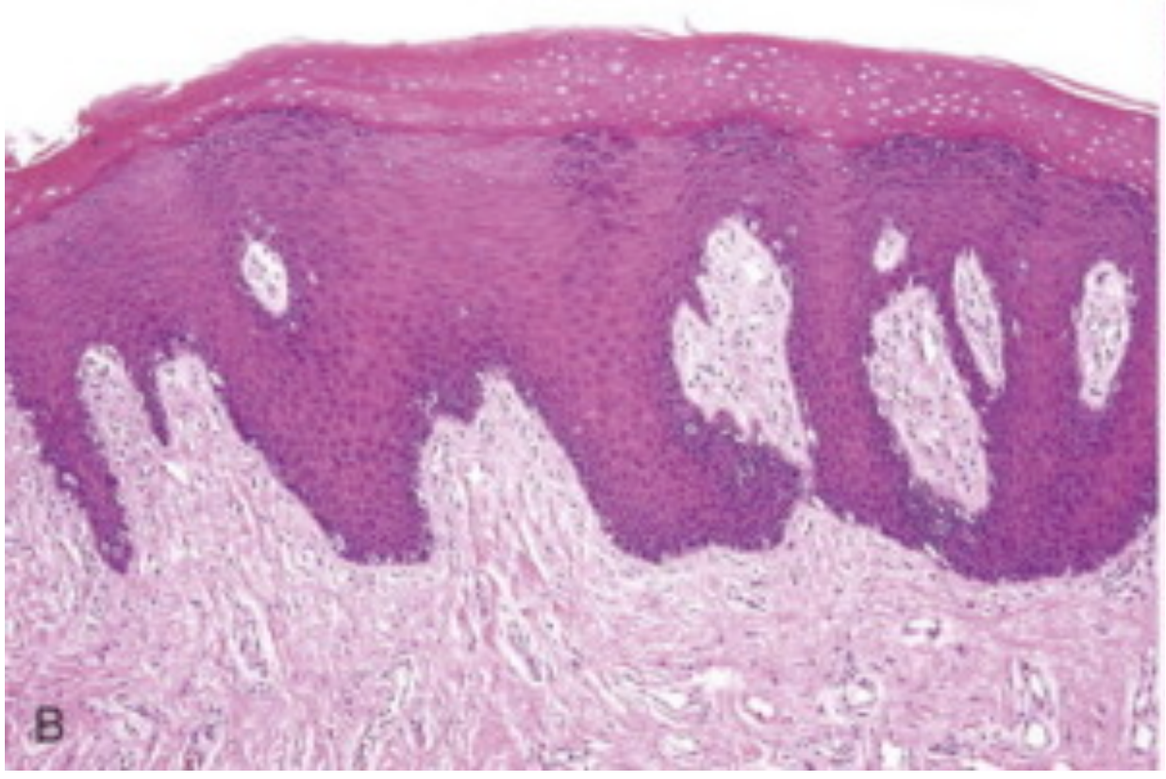

Image source: Woo, Oral Pathology 2012

Lab preparation of tissues

- Special stains
  - Occasionally used.
  - Stains specific material though chemically reacting with them.
  - Most common stains are Periodic Acid Schiff PAS stain and KOH for candida.

Lab preparation of tissues

- Immuno-histochemistry IHC
  - A popular method for studying the expression of various cellular proteins
  - Widely used in diagnosis and research
  - Relatively easy, with reasonable cost
    - The method is based on an antigene-antibody reaction. The antigen is in the lesion and the antibody is previously prepared.
    - IHC is referred to when:
      - The histological nature of the tissue is not known.
      - The investigator is searching for a particular marker to establish the diagnose and prognosis of a lesion.

IHC for prognosis

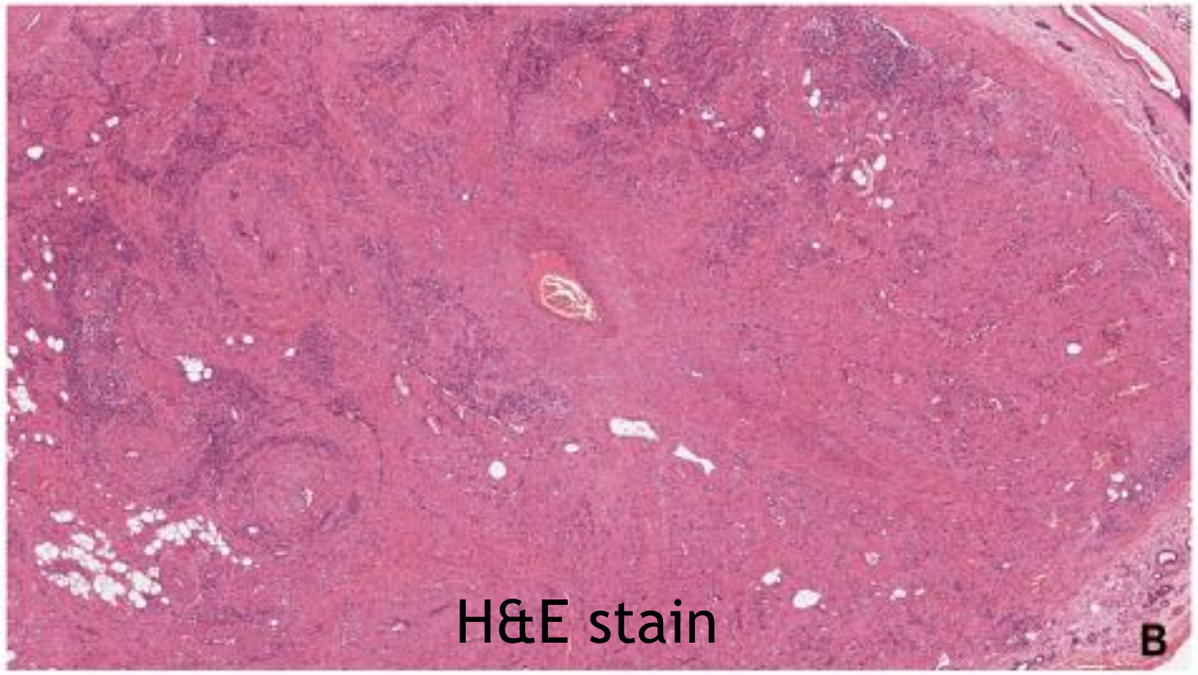

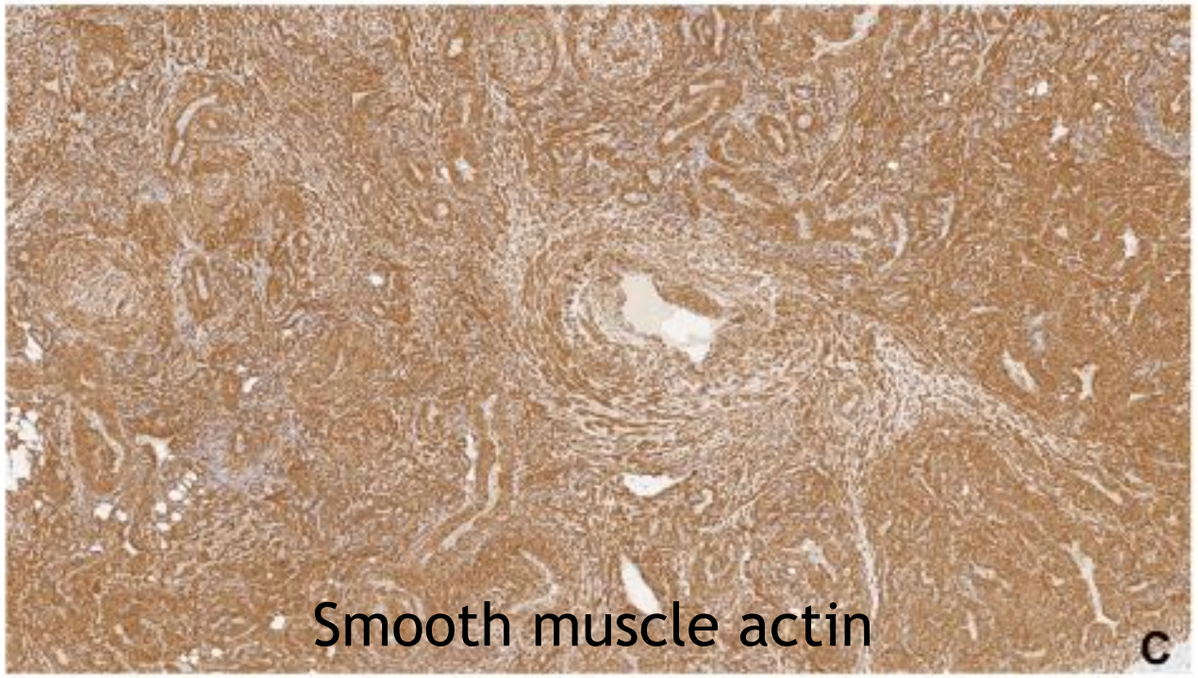

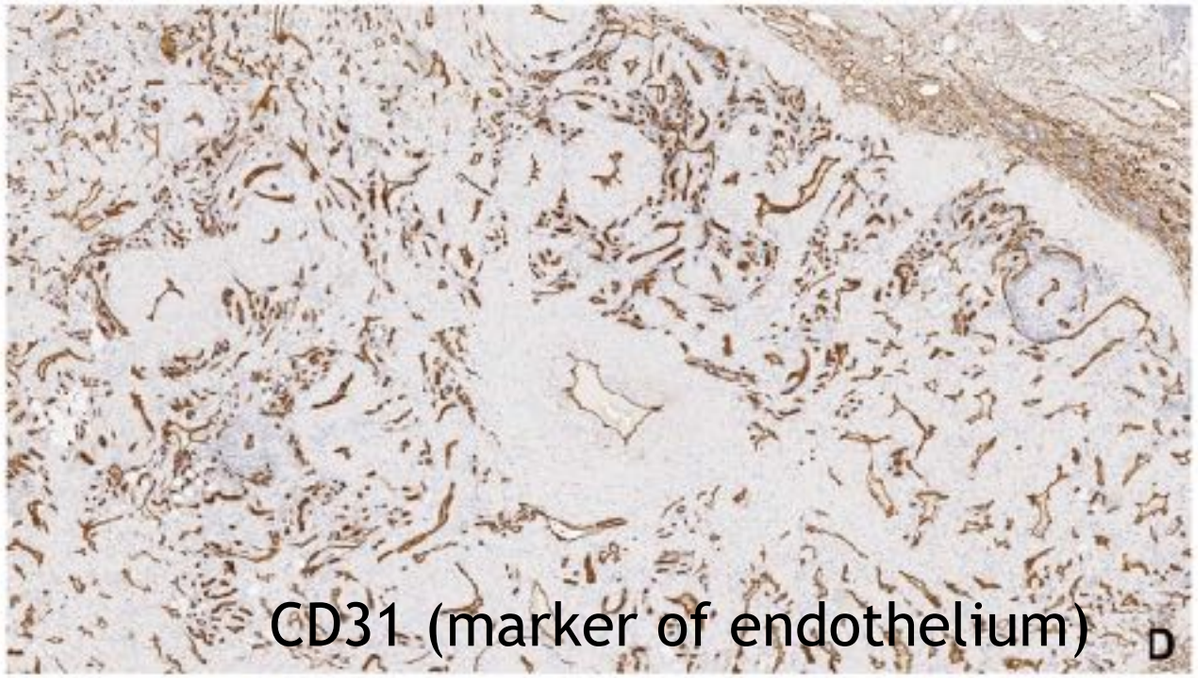

Source: Al-Amad et al. Oral Oncology Extra 2006

Lab preparation of tissues

- Direct immuno-flouresence DIF
- Indirect immuno-flourecence IIF
  - Rely on the detection of an antibody in the tissue by using another fluorescent-labeled antibody.
  - Essential methods in investigating antuimmune diseases.

Dont prescribe iron without confirming the diagnosis first because it can be a manifestation of a serious disease in GIT (cancer) that cause bleeding (occult bleeding: subclinical) and unaware patient which leads to progressive loss of iron in body.
If you see that need to do screening and tests so if you prescribe iron tablets without checking for cause first you would be masking manifestations and signs of the cancer. Once you detect an abnormality assess immediately so if there is any serious disease it won't be delayed.