Deep learning based fundus image analysis for macular degeneration grading

Yamini Joshi*
* Summer Research Intern, Spectrum Lab,
Indian Institute of Science, Bengaluru.

***Abstract*—Age related macular degeneration(AMD) is one of the most common vision issues faced by older adults. Early detection can help the patients in receiving timely treatments and medication which can help in slowing down the process of degeneration. Here we propose the usage of Convolutional Neural Networks(CNN) to grade the severity of AMD in fundus images. Indian Diabetic Retinopathy Image Dataset (IDRID), Messidor-2 and Digital Retinal Images for Vessel Extraction (Drive) datasets totaling up to 627 images were used to train and test the CNN. Required pre-processing and augmentation was done to normalize and balance the data. Augmentation techniques like horizontal and vertical flipping, random rotations, and random cropping were used. The CNN considered in this work is ResNet-101. The model performed the task of multi class classification by classifying the fundus images into 3 classes namely: No AMD, Mild AMD and Severe AMD. The deep learning based convolutional neural network performed the task of multi class classification with an accuracy of 95.34%.**

ADD ABSTRACT

Keywords*—*Age related macular degeneration, Deep Learning, Convolutional neural networks, Fundus images, ResNet-101

I. INTRODUCTION

Age-related macular degeneration (AMD) is a vision disorder that affects the macular region of the retina and causes vision loss [1]. AMD has become one of the primary causes of vision impairment in the senior population in both emerging and developed countries as lifespans have increased. Globally, the number of people with AMD is expected to reach 288 million by 2040, [2]posing a serious public health concern with significant socioeconomic implications.

Macular degeneration can be graded based on the presence/absence of exudates in the retina. Exudate is fluid that spills from blood arteries into the tissues around them. Cells, proteins, and solid materials make up the fluid. Exudate may flow from cuts or from areas of infection or inflammation. The three stages of AMD considered in this study are No AMD, Mild AMD and Severe AMD [3], [4]. No AMD, refers to the fundus images with no visible exudates. Fundus images with presence exudates outside the radius of one disc diameter from the center of the macula come under Mild AMD. Severe AMD refers to fundus images with presence exudates inside the radius of one disc diameter from the center of the macula. The optic nerve links to the retina in a circular region at the rear of the inside of the eye this is referred to as the optic disc. Figures 1, 2 and 3 depict the 3 classes of AMD along with the presence and absence of exudates.

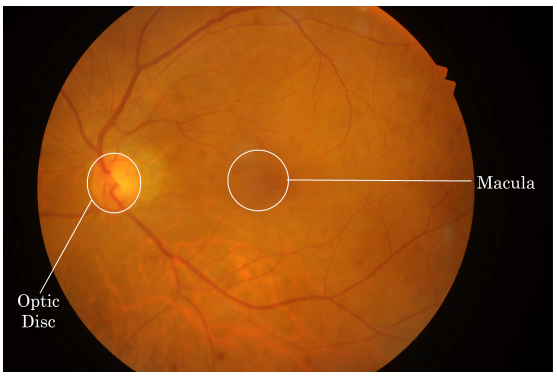

Fig. 1: No AMD: no visible exudates

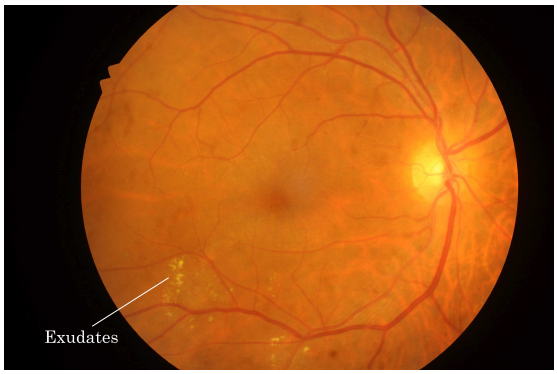

Fig. 2: Mild AMD: visible exudates far from the macula

According to the Age Related Eye Illness Study, certain dietary supplements may help reduce the advancement of the disease from the intermediate to advanced stages [5]. Additionally, intravitreal injections of anti-VEGF medicines can significantly slow the progression of vision loss, reducing the risk of vision loss when compared to no treatment [6] or alternative treatments such as photodynamic therapy with verteporfin [7] or laser [8]. Early identification is crucial: the sooner a patient with wet AMD receives anti-VEGF injections, the lower the risk of vision loss, resulting in better visual acuity for a longer time.

Deep learning, a subset of artificial intelligence (AI), has made a significant contribution in automating the disease detection and related tasks in healthcare including the field of ophthalmology in recent years. As a result, in

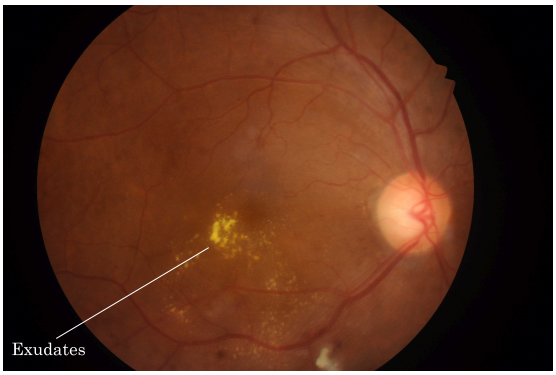

Fig. 3: Severe AMD: visible exudates close to macula

this work we strive to build on previous work in the field of healthcare AI by using deep learning models to analyze fundus images and diagnose the presence of macular degeneration and grade it. This will help in early detection of the presence of macular degeneration which in turn will help the patient get required treatments on time.

The rest of the paper is organized as follows. Related work is reviewed in Section II. The implementation pipeline adopted is described in Section III. The results are discussed in Section IV. Section V concludes the study and provides some directions for future work.

II. RELATED WORKS

Several researchers have worked in this field of macular degeneration detection and grading by leveraging the power of artificial intelligence. This is done to ensure timely detection and help the patients get proper treatment. They have progressed well in the recent past. Here a few articles whose findings were made use of in this work have been summarized briefly.

In [9], they propose the usage of an ensemble of Inception-ResNet-V2 and Xception. The Age-Related Eye Disease Study (AREDS) dataset was considered for this study. Before being fed to the neural network, the images were cropped such that the image was centered at the center of the macula. They also implemented, trained and experemented with CNNs like VGG-16, Inception-ResNet-V2 and Xception other than the ensemble model. At the end of their work they concluded that the ensemble model worked best for them giving a result of 86% for the 4 class classification task. The 4 classes considered were No AMD, Mild AMD, Intermediate AMD, Severe AMD.

In [10], they present a machine learning based fundus image classifier. They made use of the Age-Related Eye Disease Study (AREDS) dataset. This paper proposes the usage of deep convolutional neural networks (DCNN)-derived universal features on the specific automated retinal image analysis (ARIA) problem of AMD categorization. The features of a DCNN are not 'hand-crafted' or uniquely created; rather, they are discovered via training a DCNN. However, in order to train DCNN weights successfully a large number of images are required. This need is not addressed by the ARIA dataset. To address this problem they have made use of transfer learning and accessed the pre-trained weights from the networks which were trained on general-purpose images (ImageNet). The features thus obtained from DCNN are used as the input to machine learning classifiers to perform the task of multi-class (no AMD vs. early stage AMD vs. intermediate stage AMD vs. advanced AMD) classification. The linear support vector machine performed the best for them giving a result of 75.8% accuracy.

This [11] work proposes the usage of a random forest ensemble of 6 CNNs namely: AlexNet, GoogLeNet, VGG, Inception-V3, ResNet-110, Inception-ResNet-V2. They used the fundus images provided by the AREDS dataset. First they normalized the color and local illumination followed by resizing the images to 512x512 pixels resolution. They augmented the images using methods like horizontal and vertical flipping, random cropping, random rotation, adjusting the aspect ratio randomly between 0% and 15%. These images were fed into the random forest ensemble which gave them an accuracy of 63.3%.

Researchers in [12], have also made use of the AREDS dataset to train and test theri methods. They fed the colour fundus images into the classifier. Alomg with the fundus images the sociodemographic parameters factors were also taken into consideration. An ensemble of 5 networks including Inception-V3, Inception-Resnet-V2 and Xception was used to classify the images into no, early, intermediate and severe AMD. The classification was done with an accuracy of 96.1%.

III. METHODOLOGY

Figure 4 represents the implementation pipeline adopted in this work.

A. Dataset Details

The datasets considered for this project consisted of fundus images. The method of obtaining a two-dimensional (2D) depiction of the three-dimensional (3D) semi transparent retinal tissues projected onto the imaging plane is known as fundus imaging. The images obtained from this process are referred to as fundus images. Three different datasets were used in this work namely: Indian Diabetic Retinopathy Image Dataset (IDRID), Messidor-2 dataset and Digital Retinal Images for Vessel Extraction (Drive).

The field view of images captured by the Messidor-2 and the DRIVE dataset was 45^0 and that of IDRID was 50^0. The number of images from IDRID, Messidor-2 and the DRIVE datasets that could be used to train the model totaled up to 627 images.

B. Data Augmentation

Data Augmentation is required in this work to balance the data as well as increase the number of data points for better results. Several commonly used augmentation techniques were considered and used in this work [13].

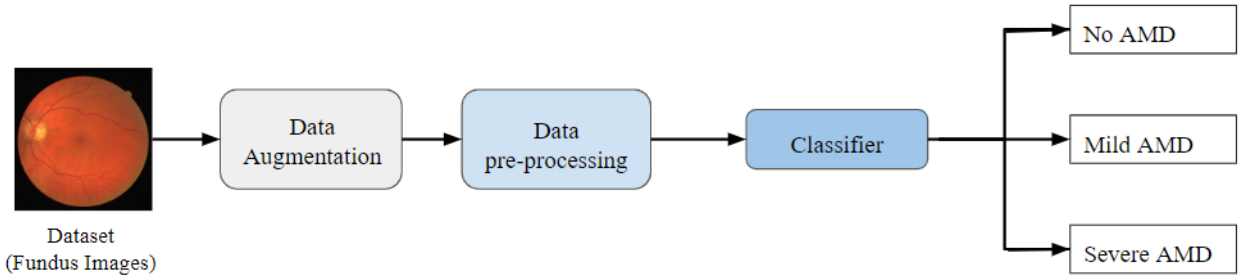

Fig. 4: Proposed Pipeline for Implementation.

They were taken into consideration based on the previous works performed in this field. Augmentation Techniques used include: horizontal and vertical flipping, Cropping of images (10% of the height and width is cropped) and Random rotation (images were rotated at a random angle between 10^0 and 180^0).

The number of images in class 1 were increased from 58 to 290 using these techniques. After augmentation the total number of images was increased to 801. Each of the No AMD, Mild AMD, Severe AMD now had 295, 290 and 274 images in their respective classes.

C. Data Pre-processing

In data pre-processing the images were normalized. Since the images considered were from 3 different data sets they had different resolutions and different formats. All the images were resized to 512x512 pixels. All images were converted into .png format. Random vertical and horizontal flips were used for images belonging to class 0 and 1. This was done to ensure generalization of the model.

D. Classifier

ResNet-101 is a residual network with 101 layers using the core idea of ResNets that is skip connections. In skip connections [14], there are connections between different layers in which the weights of a certain layer are passed on to a different layer by skipping layers in between(as shown in fig 5). These skip connections make sure that the neural network is dynamic and trains optimally [15].

For such deeper residual networks, each residual block has 3 layers. 1x1, 3x3, 1x1 convolutions are the convolution blocks.Finally we have an average pooling layer, which is followed by a fully connected layer. The fully connected layer has 10 neurons (that is the number of classes present in the Cifar-10 dataset). This CNN has over 44 million parameters. A learning rate of 0.0001 along with Adam optimizer, ReLU activation and a batch size of 8 worked best.

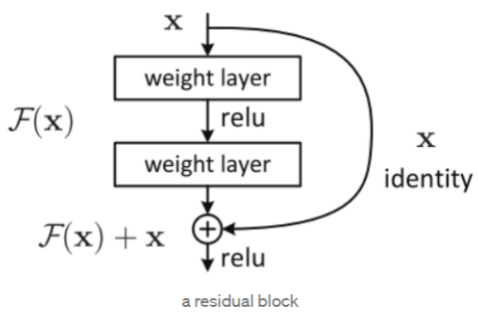

Fig. 5: Residual Block (skip connection)

E. Performance evaluation

The thus obtained weights after training the classifier networks are used to test on the test set of images. The accuraciof these models were compared. Accuracy was the evaluation mteric used as it was the parameter mentioned in already existing works [9]–[11], [16]. Accuracy of the models was calculated using the formula 1.

$$Accuracy = \frac{True_{+ve} + True_{-ve}}{True_{+ve} + True_{-ve} + False_{+ve} + False_{-ve}} \tag{1}$$

Other parameters considered include Specificity Recall and F1 scores of the models. The formulas are as mentioned as below:

$$Specificity = \frac{True_{-ve}}{True_{-ve} + False_{+ve}} \tag{2}$$

$$Sensitivity/Recall = \frac{True_{+ve}}{True_{+ve} + False_{-ve}} \tag{3}$$

$$Precision = \frac{True_{+ve}}{True_{+ve} + False_{+ve}} \tag{4}$$

$$F1_Score = \frac{2 * precision * recall}{precision + recall} \tag{5}$$

+ve=positive
-ve=negative

IV. RESULTS AND DISCUSSION

The results obtained using the ResNet-101 model are reported in table 1. The corresponding confusion matrix can be observed from the Fig 6. The ResNet-101 model gave an accuracy of 95.34%, with a sensitivity of 0.95 and specificity of 0.97. Tabel II compares our results with the other works.

Model	Accuracy	F1-Score	Sensitivity	Specifity
ResNet-101	95.34%	0.95	0.95	0.97

TABLE I: Results obtained.

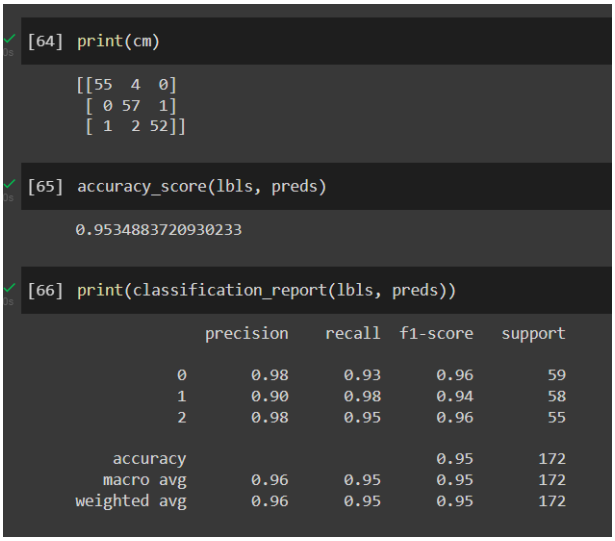

```
[64] print(cm)

[[55  4  0]
 [ 0 57  1]
 [ 1  2 52]]

[65] accuracy_score(lbls, preds)

0.9534883720930233

[66] print(classification_report(lbls, preds))

              precision    recall  f1-score   support

           0       0.98      0.93      0.96        59
           1       0.90      0.98      0.94        58
           2       0.98      0.95      0.96        55

    accuracy                           0.95       172
   macro avg       0.96      0.95      0.95       172
weighted avg       0.96      0.95      0.95       172
```

Fig. 6: Results obtained from the ResNet101 model

-	Method	Accuracy	Datapoints	Classes
1	**Best model of ours**	95.34%	627	3
2	[9]	86.1%	116,875	4
3	[10]	79%	5664	4
4	[17]	91.8%	2772	3
5	[12]	96.1%	116,875	4

TABLE II: Comparison of results.

V. CONCLUSION

Early detection of the severity of macular degeneration can help in preventing or slowing the process of degeneration with the help of required treatments. Artificial intelligence, specifically deep learning based convolutional neural networks can help in automating this process and reducing the burden on ophthalmologists.

In this work deep learning based classifiers have been used to classify and grade the severity of macular degeneration using fundus images as their inputs.

At current, ReNet101 model with a learning rate of 0.0001 is able to classify the fundus images with an accuracy of 95.34%. The dataset used here comprises of three datasets namely: IDRID, Messidor-2 and DRIVE. Images obtained were augmented to balance the dataset and ensure that the neural network once trained is not biased.

In future, better deep learning networks can be considered or come up with to give better results. A dataset of larger size and diversity can help in training the model in a more robust manner.

REFERENCES

[1] P. Mitchell, G. Liew, B. Gopinath, and T. Y. Wong, "Age-related macular degeneration," *The Lancet*, vol. 392, no. 10153, pp. 1147–1159, 2018.

[2] W. L. Wong, X. Su, X. Li, C. M. G. Cheung, R. Klein, C.-Y. Cheng, and T. Y. Wong, "Global prevalence of age-related macular degeneration and disease burden projection for 2020 and 2040: a systematic review and meta-analysis," *The Lancet Global Health*, vol. 2, no. 2, pp. e106–e116, 2014.

[3] P. Porwal, S. Pachade, R. Kamble, M. Kokare, G. Deshmukh, V. Sahasrabuddhe, and F. Meriaudeau, "Indian diabetic retinopathy image dataset (idrid)," 2018. [Online]. Available: https://dx.doi.org/10.21227/H25W98

[4] J. Staal, M. Abramoff, M. Niemeijer, M. Viergever, and B. van Ginneken, "Ridge based vessel segmentation in color images of the retina," *IEEE Transactions on Medical Imaging*, vol. 23, no. 4, pp. 501–509, 2004.

[5] A.-R. E. D. S. R. Group *et al.*, "A randomized, placebo-controlled, clinical trial of high-dose supplementation with vitamins c and e, beta carotene, and zinc for age-related macular degeneration and vision loss: Areds report no. 8," *Archives of ophthalmology*, vol. 119, no. 10, pp. 1417–1436, 2001.

[6] N. M. Bressler, T. S. Chang, I. J. Suñer, J. T. Fine, C. M. Dolan, J. Ward, T. Ianchulev *et al.*, "Vision-related function after ranibizumab treatment by better-or worse-seeing eye: clinical trial results from marina and anchor," *Ophthalmology*, vol. 117, no. 4, pp. 747–756, 2010.

[7] K. J. Blinder, S. Bradley, N. M. Bressler, S. B. Bressler, G. Donati, Y. Hao, C. Ma, U. Menchini, J. Miller, M. J. Potter *et al.*, "Effect of lesion size, visual acuity, and lesion composition on visual acuity change with and without verteporfin therapy for choroidal neovascularization secondary to age-related macular degeneration: Tap and vip report no. 1." *American journal of ophthalmology*, vol. 136, no. 3, pp. 407–418, 2003.

[8] M. P. S. Group *et al.*, "Subfoveal neovascular lesions in age-related macular degeneration. guidelines for evaluation and treatment in the macular photocoagulation study," *Arch Ophthalmol*, vol. 109, pp. 1242–1257, 1991.

[9] A. Govindaiah, R. T. Smith, and A. Bhuiyan, "A new and improved method for automated screening of age-related macular degeneration using ensemble deep neural networks," in *2018 40th Annual International Conference of the IEEE Engineering in Medicine and Biology Society (EMBC)*. IEEE, 2018, pp. 702–705.

[10] P. Burlina, K. D. Pacheco, N. Joshi, D. E. Freund, and N. M. Bressler, "Comparing humans and deep learning performance for grading amd: a study in using universal deep features and transfer learning for automated amd analysis," *Computers in biology and medicine*, vol. 82, pp. 80–86, 2017.

[11] P. M. Burlina, N. Joshi, M. Pekala, K. D. Pacheco, D. E. Freund, and N. M. Bressler, "Automated grading of age-related macular degeneration from color fundus images using deep convolutional neural networks," *JAMA ophthalmology*, vol. 135, no. 11, pp. 1170–1176, 2017.

[12] A. Bhuiyan, T. Y. Wong, D. S. W. Ting, A. Govindaiah, E. H. Souied, and R. T. Smith, "Artificial intelligence to stratify severity of age-related macular degeneration (amd) and predict risk of progression to late amd," *Translational vision science & technology*, vol. 9, no. 2, pp. 25–25, 2020.

[13] F. Grassmann, J. Mengelkamp, C. Brandl, S. Harsch, M. E. Zimmermann, B. Linkohr, A. Peters, I. M. Heid, C. Palm, and B. H. Weber, "A deep learning algorithm for prediction of age-related eye disease study severity scale for age-related macular degeneration from color fundus photography," *Ophthalmology*, vol. 125, no. 9, pp. 1410–1420, 2018.

[14] K. He, X. Zhang, S. Ren, and J. Sun, "Deep residual learning for image recognition," in *Proceedings of the IEEE conference on computer vision and pattern recognition*, 2016, pp. 770–778.

[15] S. Jastrzębski, D. Arpit, N. Ballas, V. Verma, T. Che, and Y. Bengio, "Residual connections encourage iterative inference," *arXiv preprint arXiv:1710.04773*, 2017.

[16] P. Kunumpol, W. Umpaipant, N. Kanchanaranya, T. Charoenpong, S. Vongkittirux, T. Kupakanjana, and C. Tantibundhit, "Automated age-related macular degeneration screening system using fundus images," in *2017 39th Annual International Conference of the IEEE Engineering in Medicine and Biology Society (EMBC)*. IEEE, 2017, pp. 1469–1472.

[17] S. Kankanahalli, P. M. Burlina, Y. Wolfson, D. E. Freund, and N. M. Bressler, "Automated classification of severity of age-related macular degeneration from fundus photographs," *Investigative ophthalmology & visual science*, vol. 54, no. 3, pp. 1789–1796, 2013.