Instructions for Project 1
Biomedical Image Processing

Due: 23:59 Nov.15

TA: Haibin Zhang (张海彬)

Contact: zhanghb2022@shanghaitech.edu.cn

Background

- The carotid artery is one of the main blood vessels supplying blood to the brain and plays a significant role in blood circulation.
- The carotid artery can be divided into the common carotid artery, the internal carotid artery and the external carotid artery.
- The structure of the carotid artery wall is divided into three layers: Tunica Adventitia, the Tunica Media, and the Tunica Intima.

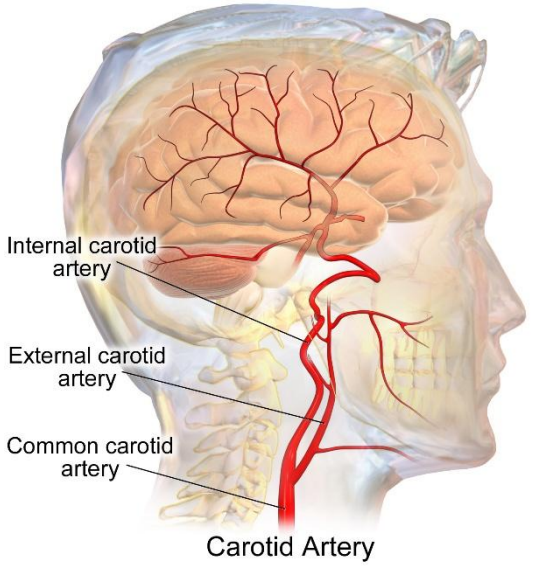

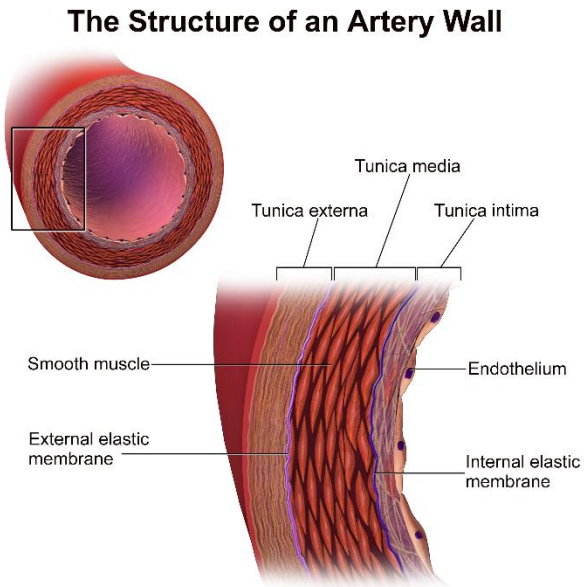

Fig 1. The structure of the carotid artery.

Background

- Carotid Atherosclerosis (CA) is a major cause of stroke, the world's second leading cause of death.
- CA is characterized by thickening of the wall of the carotid artery and plaque formation (**>1.2mm**).
- When the plaque breaks up, it travels through the bloodstream to the brain, blocking capillaries and causing a stroke.

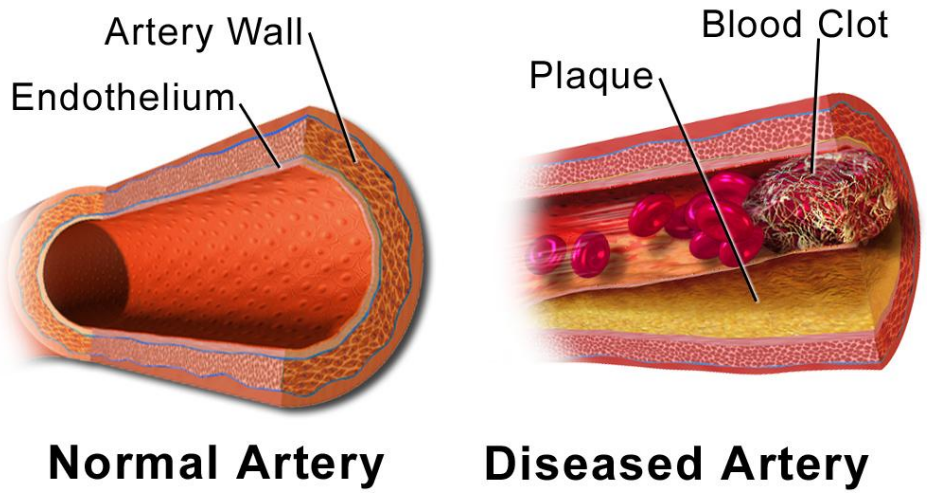

Fig 2. Carotid artery atherosclerosis symptoms. The left is a healthy blood vessel, and the right is a diseased one.

Background

- The mainstream methods for examining carotid atherosclerosis include Digital Subtraction Angiography (DSA), Computed Tomography Angiography (CTA), Magnetic Resonance Imaging (MRI), and Ultrasound Imaging.

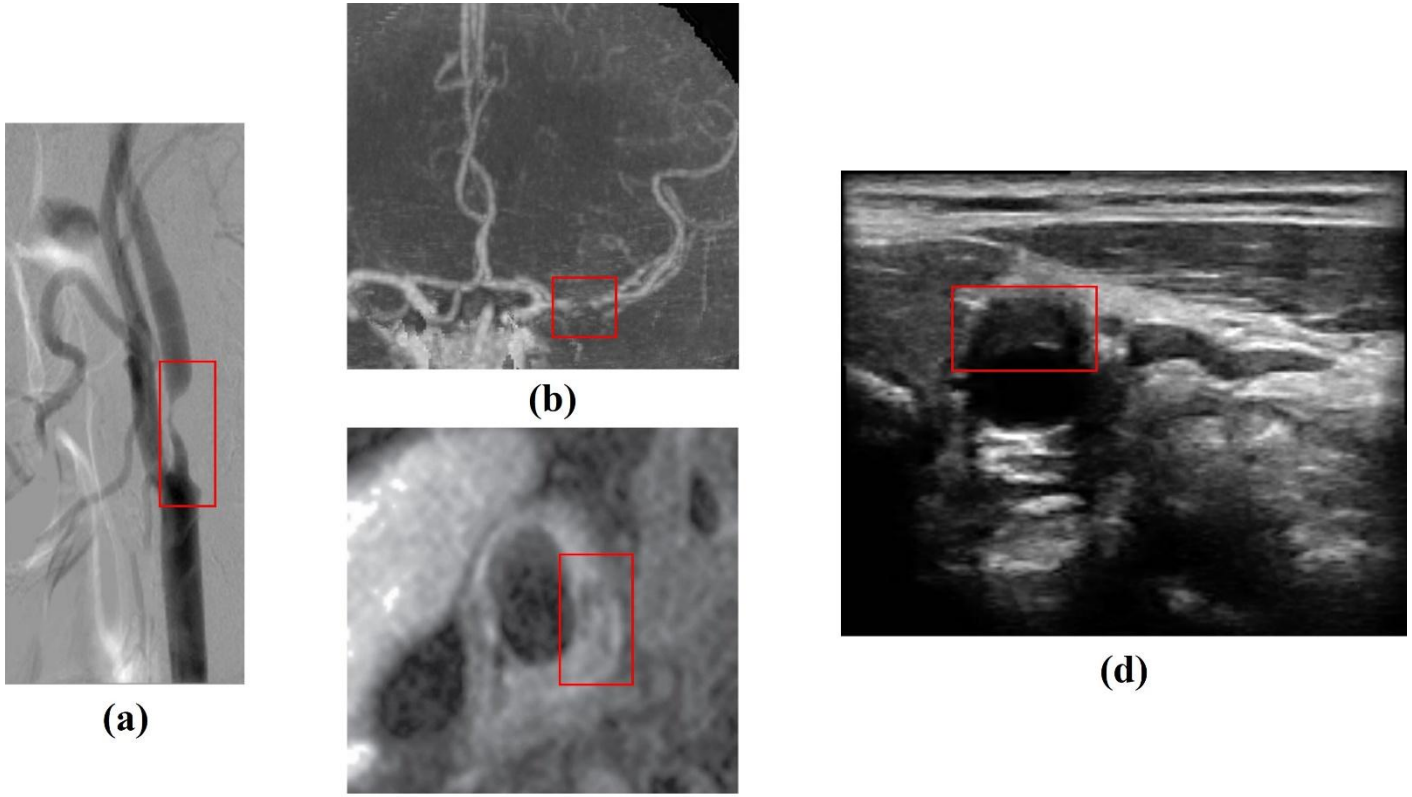

Fig 3. Common imaging examination methods for carotid atherosclerosis and their image presentations. The red box shows the location of carotid plaque. (a) DSA. (b) CTA. (c) MRI. (d) Ultrasound.

Background

- As a **cost-effective**, **rapid**, **safe**, and **non-invasive** imaging method, ultrasound is more widely used in the diagnosis of CA.

- Sonographers measure indicators such as the **stenosis rate of blood vessels** and the **size of plaques** to evaluate the patient's condition.



Fig 4. Clinical examination of the carotid arteries of patients using ultrasound devices.

Background

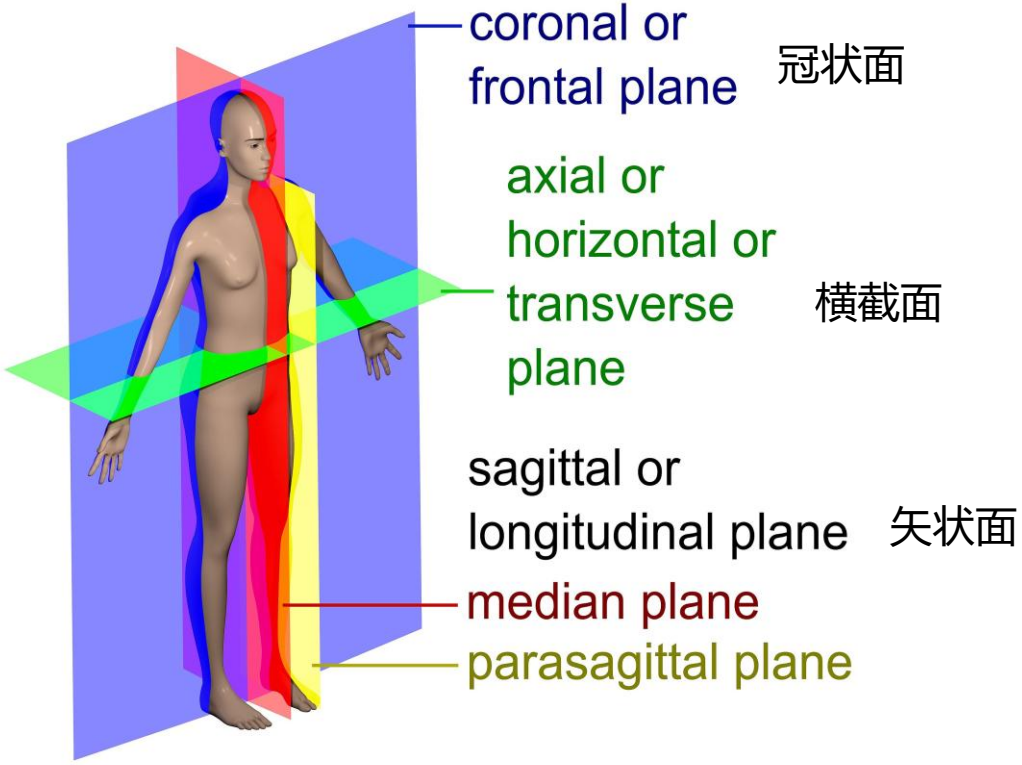
coronal or
frontal plane
冠状面
axial or
horizontal or
transverse
plane
横截面
sagittal or
longitudinal plane
矢状面
median plane
parasagittal plane

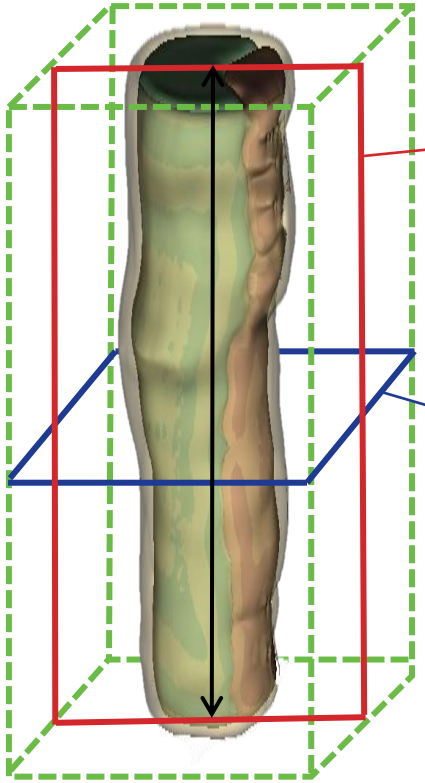

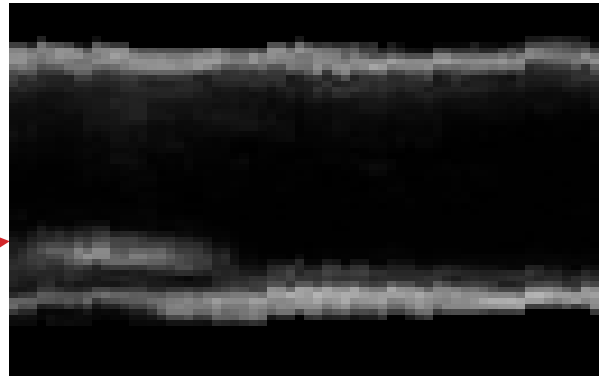

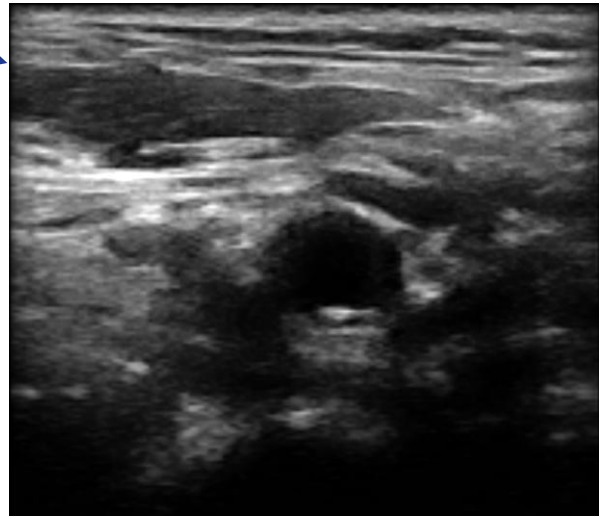

Background

上海科技大学
ShanghaiTech University

- However, Traditional ultrasound Requires experienced sonographers to perform the operation.
- In clinical diagnosis, hypoechoic plaques and artifacts can interfere with the diagnosis.
- Compared with artifacts, the edges of plaques are more complete.

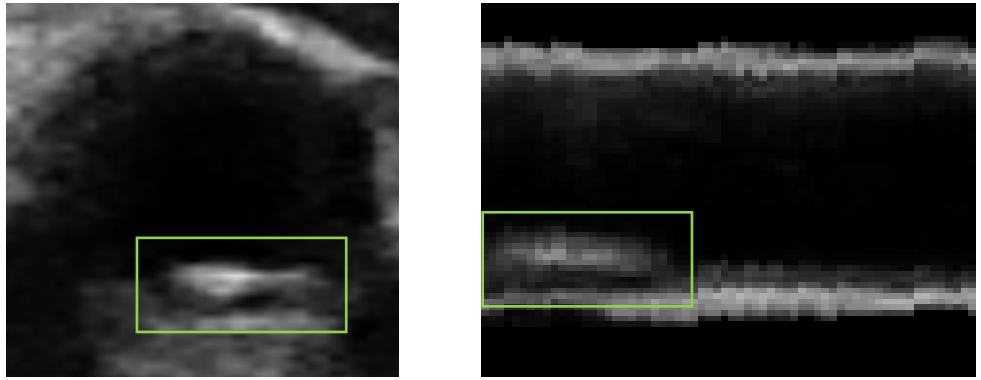

Fig 5. Transverse (left) and longitudinal (right) images of normal plaques.

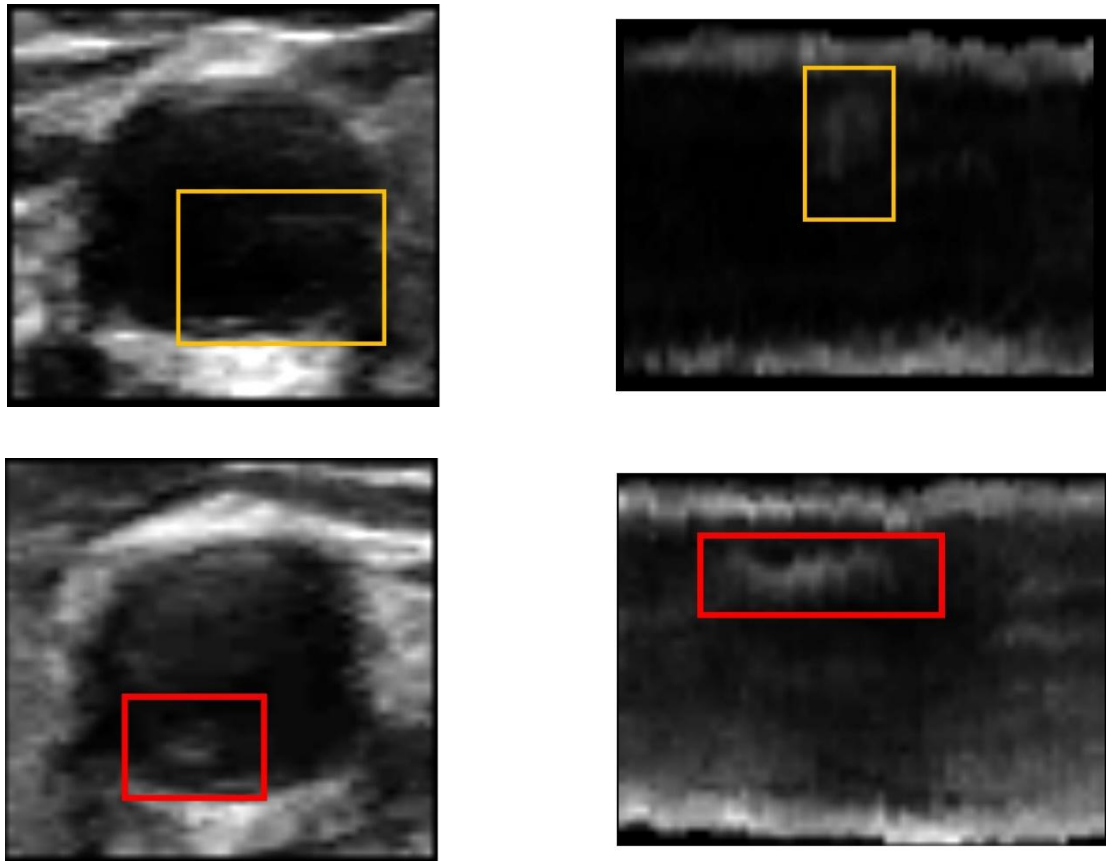

Fig 6. The two images above are low-intensity plaques, and the two images below are ultrasound images with artifacts.

立志成才报国裕民

Task

1. Using traditional methods and deep learning methods to segment the carotid artery regions.

2. Diagnose whether atherosclerosis has occurred in the carotid artery in the two-dimensional ultrasound images provided.

3. Calculate the carotid artery stenosis rate.

Dataset

- We will provide 30 transverse images of carotid arteries and 34 longitudinal images. Among them, not all carotid arteries have developed atherosclerosis. The pixel size was set to 0.2*0.2 mm^2.

- We'll also provide the manual labels of the corresponding data, with the same naming as the corresponding data.

2022-11-17-14-40-19-WDY-L-Y

Time Name Left or Right Diagnosis

Task 1

- For transverse images, you need to segment the carotid artery regions in the images (regions of interest, ROI).
- For longitudinal images, you need to segment the lumen and the vessel wall (include the plaque).

Traditional Method:

- The segmentation method can be chosen based on the course content or by referring to relevant papers by oneself.
- Some relevant papers will be provided for reference.

Deep Learning Method:

- We'll provide the trained network model, and you just need to use it for inference.
- If you are interested in model training, we can also provide additional data for training, but it will **not** be included in the score.

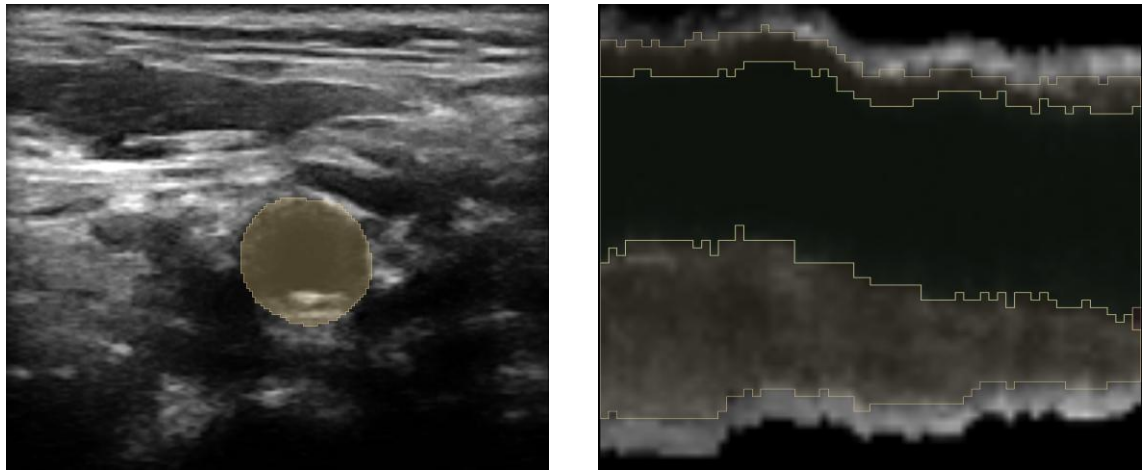

Fig 7. The segmentation result that should be obtained.

Task 2

- Based on the segmentation results, you need to diagnose whether atherosclerosis has occurred in the carotid arteries in each image.

  - For transverse images, you can use the threshold method to diagnosis.
  - For longitudinal images, you can calculate the thickness of the blood vessel wall to diagnosis.
  - If you have other ideas, give them a try as well.

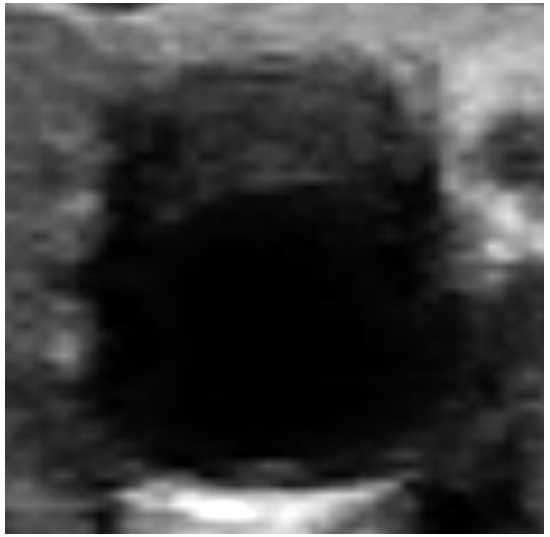

Yes

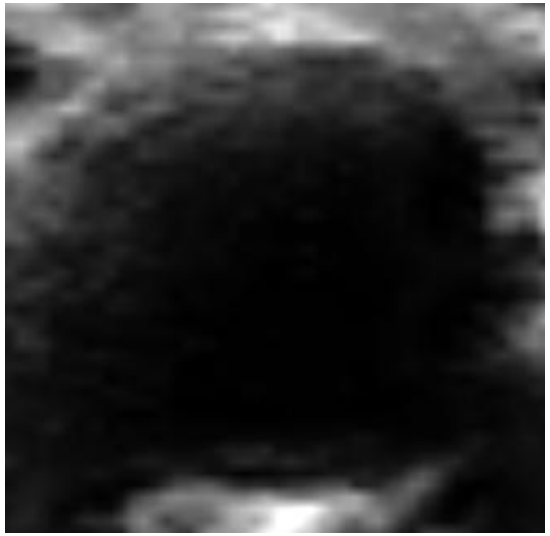

No

Task 3

- There are two methods for calculating the carotid artery stenosis rate (CSR), the calculation formula is as follows.
- For transverse images, you need to calculate the area stenosis rate.
- For longitudinal images, you need to calculate the diameter stenosis rate.

$$CSR_{diameter} = \left(1 - \frac{d_{min}}{d_{norm}}\right) \times 100\%$$

$$CSR_{\text{area}} = \left(1 - \frac{S_{\text{lumen}}}{S_{\text{all}}}\right) \times 100\% = \frac{S_{\text{plaque}}}{S_{\text{all}}} \times 100\%$$

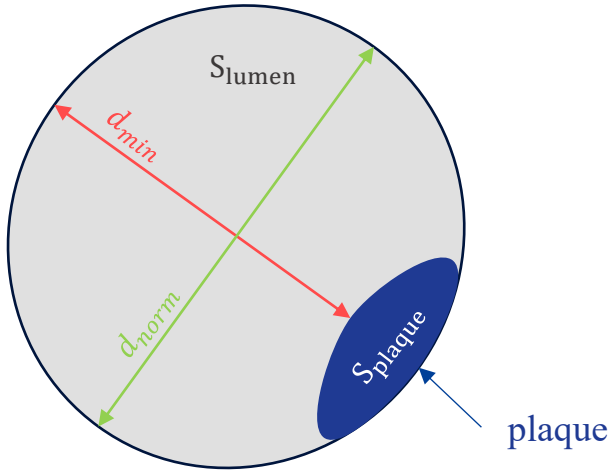

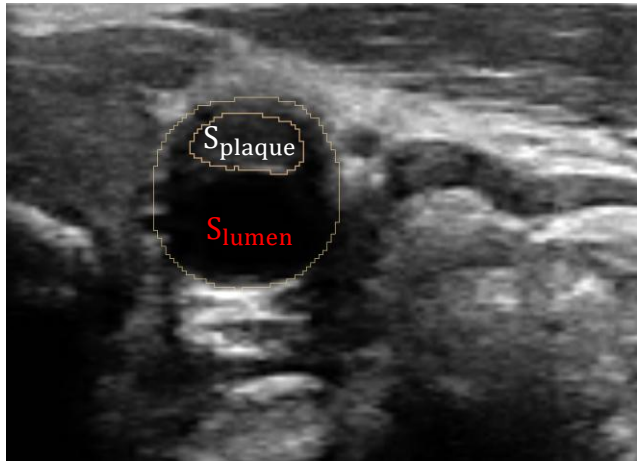



Evaluation Metric: Segmentation

上海科技大学
ShanghaiTech University

- You must use Dice Similarity Coefficient (DSC) and Hausdorff Distance (HD) to evaluate the performance of the segmentation methods.
- DSC is a quantitative indicator for evaluating the area where the predicted results overlap with the manually marked ones.
- HD is a quantitative indicator used to assess the size of the difference between the predicted value contour and the true value contour. To eliminate the influence of extremely small outliers, the HD is usually multiplied by 95% and denoted as HD95. (**Unit: Pixel**)

$$\boldsymbol{DSC} = \frac{\boldsymbol{2|X \cap Y|}}{\boldsymbol{|X| + |Y|}}$$

$$\begin{cases} \mathrm{HD95}(A, B) = 95\% \times max(hd(A, B), hd(B, A)) \\ hd(A, B) = max_{a \in A}(min_{b \in B}||a - b||) \\ hd(B, A) = max_{b \in B}(min_{a \in A}||b - a||) \end{cases}$$

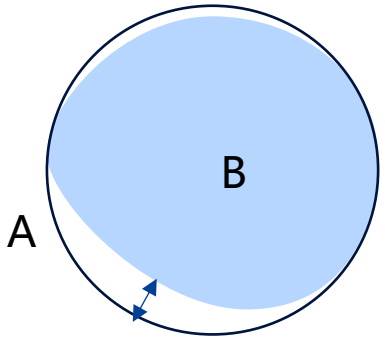

$hd(A, B) = 0$

$hd(B, A) \neq 0$

立志成才报国裕民

Evaluation Metric: Diagnosis

- For classification tasks, you need to statistically analyze the confusion matrix of the diagnostic results and calculate the accuracy, sensitivity and specificity of the diagnostic results.

- There is often a trade-off between sensitivity and specificity. In clinical diagnosis, doctors tend to use models with higher sensitivity.

Table 1. Confusion Matrix

Ground Truth	Prediction	
	positive	negative
Positive	TP	FN
negative	FP	TN

$$Accuarcy = \frac{TP + TN}{TP + TN + FP + FN}$$

$$Sensitivity = \frac{TP}{TP + FN}$$

$$Specificity = \frac{TN}{FP + TN}$$

$$Precision = \frac{TP}{TP + FP}$$

Evaluation Metric: Stenosis Rate

- We will use the Mean Absolute Error (MAE) to evaluate the results of the CSR.
- You do **not** need to calculate it; you just need to provide your results.

$$MAE = \frac{1}{n}\sum_{i=1}^{n}|y_i - \hat{y}_i|$$

Submit

1. A **PDF** paper.
   - Both latex and word template are provided. But submit a pdf. Latex source code or word will **not** be accepted.

2. A folder of Source code with a README.md.

3. Results.
   - We will provide a template to count all the results using excel.
   - Please save the segmentation results obtained by different algorithms to different folders.

Submit a zip file includes all above materials.

Grading

- Code Check (30%)
- The accuracy of the results (20%)
- The paper (50%)

Thanks

Q&A