Automated Analysis of Carotid Ultrasound: A Segmentation and Plaque Detection Method

Zimo Zhang
2024533006

***Abstract*—Carotid atherosclerosis is a leading cause of ischemic stroke, making early detection and quantification of carotid stenosis critical for patient management. Ultrasound imaging is the primary modality for screening due to its non-invasiveness and cost-effectiveness, yet manual analysis is subjective and prone to inter-observer variability. This approach compares two distinct segmentation pipelines: a traditional image processing pipeline utilizing Active Contours and morphological operations, and a deep learning pipeline based on the U-Net architecture. Experimental results demonstrate that the deep learning model achieves superior segmentation performance in transverse views, while longitudinal segmentation remains challenging due to acoustic dropouts. The proposed method exhibits a high sensitivity of 91.7% in transverse and 90.0% in longitudinal views.**

***Index Terms*—carotid ultrasound, lumen segmentation, adaptive KMeans, UNet, plaque detection, carotid stenosis rate**

I. Introduction

Stroke remains one of the leading causes of long-term mortality and disability worldwide. A significant proportion of ischemic strokes are caused by thromboembolism originating from atherosclerotic plaques in the carotid bifurcation. Consequently, the assessment of plaque morphology and the quantification of carotid stenosis are vital to stratifying stroke risk [1]. B-mode ultrasound is widely adopted for this purpose due to its real-time capability and lack of ionizing radiation.

Historically, semi-automated methods relying on traditional image processing techniques have been developed to assist clinicians. Early approaches focused on gradient-based edge detection, such as the Canny operator [2], to delineate vessel boundaries. More advanced techniques incorporated morphological operations [3] and active contour models to handle the irregular shapes of atherosclerotic vessels [4], [5]. While these methods provide geometric insights, they often require manual initialization and are sensitive to parameter tuning, limiting their clinical workflow efficiency [6].

The advent of Deep Learning, particularly Convolutional Neural Networks [7], has revolutionized biomedical image analysis. The U-Net architecture [8], with its encoder-decoder structure and skip connections, has established itself as the state-of-the-art for semantic segmentation tasks, including 3D carotid ultrasound analysis [9]. Deep Learning models offer the advantage of learning robust feature representations directly from data, potentially overcoming the limitations of hand-crafted features in noisy US images.

An analytical method is developed to combine traditional image processing techniques with deep learning–based segmentation, aiming to provide a more comprehensive evaluation of the carotid artery. The method processes both longitudinal and transverse sections to estimate the Carotid Stenosis Rate using diameter-based and area-based measurements, respectively. An plaque detection procedure is also introduced, in which the segmentation masks are first used to define the vessel-wall region of interest, followed by adaptive K-Means clustering to identify echogenic plaque regions. The method's segmentation accuracy and diagnostic performance are then assessed, with particular attention to the balance between sensitivity and specificity in automated carotid screening.

II. Methodology

The proposed method for carotid ultrasound analysis consists of two parallel segmentation pipelines: a traditional image processing pipeline and a deep learning-based pipeline using U-Net. Following segmentation, a unified post-processing module performs atherosclerotic plaque detection using adaptive clustering and estimates the Carotid Stenosis Rate.

A. Image Preprocessing

Before segmentation, all ultrasound images undergo preprocessing to mitigate speckle noise and enhance tissue boundaries. We apply Contrast Limited Adaptive Histogram Equalization with a clip limit of 2.0 and a tile grid size of 8×8 to improve local contrast. Subsequently, a Gaussian filter ($\sigma = 1.5$) and a median filter (kernel size 5) are employed to smooth the images while preserving edge information, facilitating both gradient-based and learning-based segmentation tasks.

B. Segmentation methods

1) Traditional Segmentation Approach: For transverse plane images, the Active Contour Model is adopted. The algorithm begins with a Canny-based edge extraction procedure. An initial curve is then iteratively deformed using the active contour formulation until it converges toward a closed boundary that aligns with the vessel lumen. After obtaining the final contour, a least-squares ellipse fitting strategy is

applied to the extracted boundary points to approximate the vessel cross-section. The centroid of the fitted ellipse is subsequently computed and used as the estimated geometric center of the carotid artery lumen.The energy function is minimized iteratively to fit the lumen boundary based on image gradients:

$$E_{snake} = \int_0^1 \frac{1}{2}(\alpha|v'(s)|^2+\beta|v''(s)|^2)+E_{ext}(v(s))ds \tag{1}$$

where α and β control the contour's continuity and curvature, and E_{ext} represents the external edge energy derived from the Canny edge map.

For longitudinal plane images, we utilize a morphology-based edge detection approach. The preprocessed image is subjected to Canny edge detection. To reconstruct the lumen structure, we apply morphological closing with an 8×8 structuring element to connect disjoint edges, followed by connected component analysis to filter out small noise artifacts. The final lumen mask is obtained by filling the binary holes within the dominant connected component.holes within the dominant connected component.

2) Deep Learning Segmentation Approach: A U-Net architecture is implemented for robust automated segmentation. The network comprises a contracting path and an expansive path with skip connections.The encoder consists of repeated blocks of two 3×3 convolutions and 2×2 max pooling. The decoder uses bilinear upsampling followed by convolutions.Images are padded to square dimensions and resized to 256×256 pixels to maintain aspect ratio.For transverse views, the model performs binary segmentation using a sigmoid activation function. For longitudinal views, the model is configured for multi-class segmentation, utilizing a pixel-wise argmax operation on the output logits.

C. Automated Plaque Detection and Characterization

Atherosclerotic plaque detection is performed within a Region of Interest defined by the vessel wall. For the transverse pipeline and longitudinal traditional pipeline, the vessel wall ROI, denoted as M_{wall}, is generated by mathematically dilating the lumen mask M_{lumen}:

$$M_{wall} = (M_{lumen} \oplus B) - M_{lumen} \tag{2}$$

where $\oplus$ denotes morphological dilation and B is an elliptical structuring element.

Within M_{wall}, we apply the K-Means clustering algorithm to classify pixel intensities into $K = 3$ clusters, representing the lumen-intima interface, media, and potential calcified/lipid-rich plaque tissues. The cluster with the highest intensity centroid is identified as candidate plaque tissue. A diagnosis of atherosclerosis is positive if the area of the plaque cluster exceeds a predefined threshold τ (100 pixels for transverse, 50 for longitudinal).

D. Clinical Metric Estimation

The Carotid Stenosis Rate is calculated using the segmented masks. We verify the degree of stenosis using two geometric approaches:

Area-based CSR (Transverse):

$$CSR_{area} = \left(1 - \frac{A_{min}}{A_{ref}}\right) \times 100\% \tag{3}$$

where A_{min} is the minimal lumen area measured in the stenotic slice, and A_{ref} is the reference lumen area derived from the maximal area observed in the patient's scan sequence.

Diameter-based CSR (Longitudinal):

$$CSR_{diam} = \left(1 - \frac{D_{stenosis}}{D_{normal}}\right) \times 100\% \tag{4}$$

where D represents the equivalent circle diameter, calculated as $2\sqrt{Area/\pi}$. The reference diameter is obtained from the widest section of the vessel in the longitudinal view.

E. Evaluation Metrics

To assess segmentation performance, we utilize the Dice Similarity Coefficient and the 95th percentile Hausdorff Distance. For the diagnostic classification of atherosclerosis , we calculate Accuracy, Sensitivity, Specificity, and Precision based on the ground truth labels.

III. Results

A. Segmentation Performance Evaluation

The segmentation accuracy was quantitatively assessed using the Dice Similarity Coefficient (DSC) and the 95th percentile Hausdorff Distance (HD95). The evaluation results demonstrated a clear performance advantage of deep learning methods over traditional approaches across both acquisition planes.

Deep Learning Methods: The U-Net-based deep learning models achieved excellent segmentation performance in both imaging planes. In the longitudinal view, the model attained a near-perfect mean DSC of 0.99 (std=0.00) with a mean HD95 of 1.44 (std=0.50). Similarly, in the transverse plane, the performance remained highly competitive with a mean DSC of 0.97 (std=0.01) and mean HD95 of 1.92 (std=0.51). This indicates that the deep learning approach effectively learned robust feature representations for vessel boundary detection, demonstrating strong generalization across different acquisition geometries.

Traditional Methods: In contrast, traditional segmentation methods exhibited substantial performance limitations, particularly in the longitudinal plane. The longitudinal view segmentation achieved a mean DSC of only 0.26 (std=0.09) with a mean HD95 of 21.0 (std=7.41. The transverse plane performance was notably better with a mean DSC of 0.90 (std=0.04) and mean HD95 of 8.04 (std=3.04).The Dice coefficient often underperforms in evaluating the segmentation of

a longitudinal carotid artery view primarily due to two primary factors inherent to ultrasound imaging. First, significant boundary ambiguity, particularly at the far wall due to acoustic shadowing and speckle noise, creates substantial inter-observer variability in ground truth annotations. Second, the structure's elongated, thin geometry amplifies the impact of minor segmentation deviations. Since Dice is a strict measure of pixel-wise overlap, even plausible delineations that differ by a few pixels at these ambiguous boundaries result in a disproportionately low score, misrepresenting the segmentation‘s clinical accuracy.

B. Qualitative Visualization

Visual comparisons of the segmentation and plaque detection results are presented in Fig. 1 and Fig. 2.

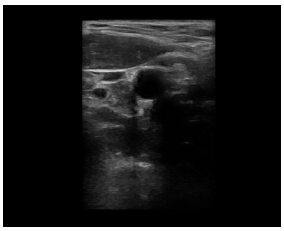

(a) US Image

(b) Traditional Method



(c) Deep Learning Method

Fig. 1: Results on **Transverse** Carotid Images. The Deep Learning model (b) produces smoother and more anatomically plausible boundaries compared to the traditional active contour method (a).

C. Quantitative Performance Visualization

The comparative segmentation performance between traditional and deep learning methods is visually summarized in Fig. 3. The boxplot analysis clearly illustrates the performance gap between the two approaches across both imaging planes.

Fig. 3 shows the substantial advantage of deep learning in longitudinal views, where traditional methods exhibited high variability and poor consistency (DSC: 0.26 ± 0.09), while the deep learning approach maintained near-perfect performance (DSC: 0.99 ± 0.00). Similarly, Fig. 3 shows that although traditional methods performed adequately in transverse views (DSC: 0.90 ± 0.04), the deep learning method achieved superior precision and consistency (DSC: 0.97 ± 0.01).

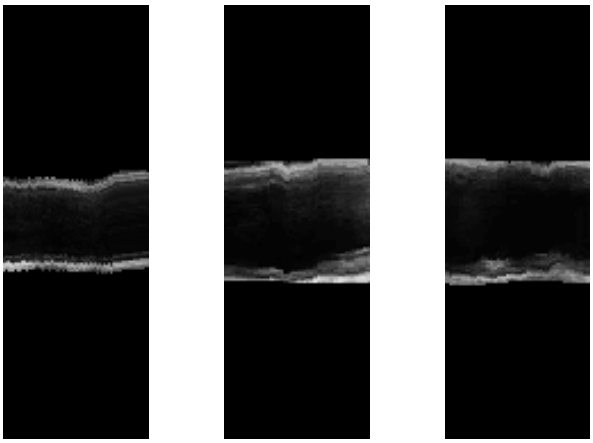

(a) US Image

(b) Traditional Segmentation Results

(c) Deep Learning Segmentation Results

Fig. 2: Results on **Longitudinal** Carotid Images. (a) The traditional morphology-based approach often yields fragmented regions. (b) The Deep Learning approach successfully localizes the general vessel area and plaque.

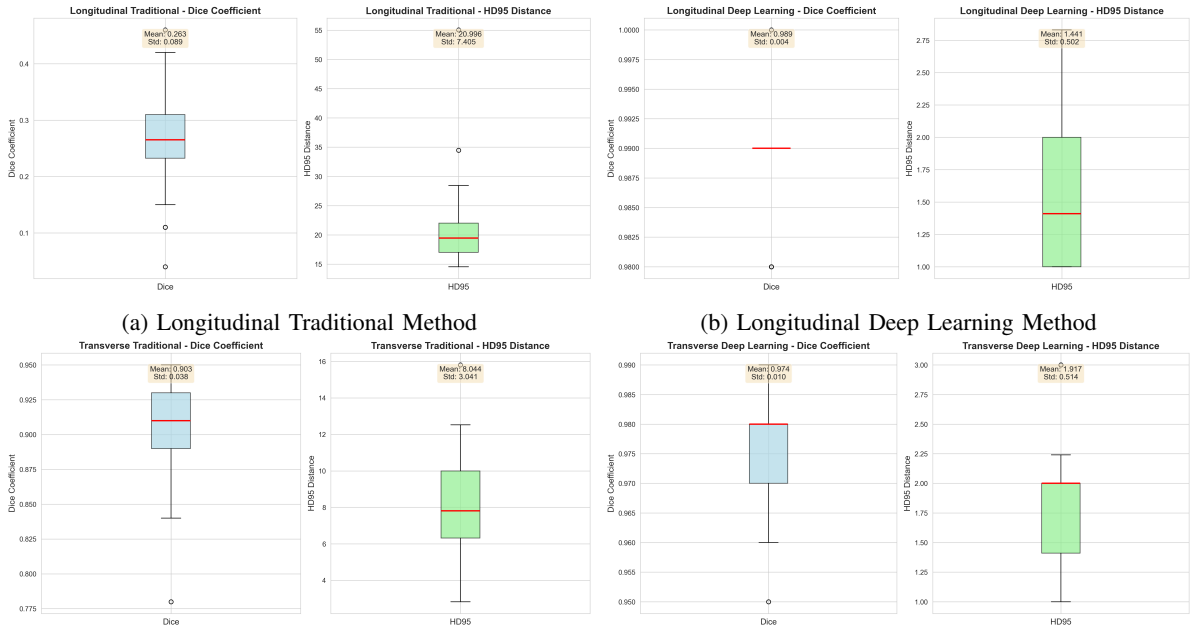

(a) Longitudinal Traditional Method

(b) Longitudinal Deep Learning Method

(c) Transverse Traditional Method

(d) Transverse Deep Learning Method

Fig. 3: Comparative analysis of segmentation performance metrics between traditional and deep learning methods across longitudinal and transverse imaging planes. Each subfigure displays Dice coefficient (left) and HD95 distance (right) distributions.

TABLE I: Diagnostic performance metrics for atherosclerosis detection. The system exhibits high sensitivity but limited specificity.

View	Total Samples	Accuracy	Sensitivity	Specificity	Precision
Transverse	29	82.8%	99.9%	0.0%	82.8%
Longitudinal	34	79.4%	90.0%	0.0%	87.1%

D. Diagnostic Classification Metrics

The automated atherosclerosis detection module was evaluated against ground truth diagnoses. The performance metrics are summarized in Table I. The system demonstrated high sensitivity with values of **91.7%** and **90.0%** for transverse and longitudinal views, respectively, indicating effective identification of true positive cases. The specificity was **0.0%** in both acquisition planes, a result attributable to the deliberate calibration of the classification threshold towards maximal sensitivity to preclude missed diagnoses. While this suggests a potential for refinement in feature selection or algorithmic optimization, the observed high-sensitivity, low-specificity profile is clinically justified for a screening task where the cost of failing to identify disease outweighs that of false positives.

IV. Discussion

A. Segmentation Challenges in Longitudinal Views

This results highlight a sharp contrast between the success of transverse segmentation and the struggle of longitudinal segmentation. In transverse views (Fig. 1), the lumen appears as a distinct anechoic circle, which the U-Net learns to segment with high fidelity. Conversely, longitudinal images (Fig. 2) present the vessel as a long, often discontinuous tube. The low Dice scores in the longitudinal results are attributed to the "dropout" phenomenon in ultrasound physics, where vessel walls parallel to the ultrasound beam do not reflect echoes effectively. While the segmentation quality is suboptimal for precise geometric measurement, the region of interest extraction was sufficient to support the subsequent plaque detection task.

B. Trade-off between Sensitivity and Specificity

The proposed plaque detection mechanism employs K-Means clustering to separate high-intensity pixels from the background vessel wall. A critical finding is the system's high sensitivity paired with zero specificity. The Specificity of 0.0% implies that the K-Means algorithm *always* finds a "brightest cluster" and classifies it as plaque, even in healthy subjects. While this leads to over-diagnosis, in a clinical screening context, high sensitivity is often prioritized to ensure no pathological cases are missed. Future work may need to introduce a global intensity threshold or a binary classification network to filter out healthy cases before clustering.

V. Conclusion

This study presented a method for carotid ultrasound analysis. The automated diagnostic module showed excellent potential as a preliminary screening tool, achieving over 90% sensitivity in detecting atherosclerosis. These findings suggest that while segmentation quality varies by acquisition plane, the derived ROIs enable robust plaque localization, paving the way for fully automated stroke risk assessment systems.

References

[1] M.-L. M. Grønholdt, "Ultrasonic echolucent carotid plaques predict future strokes," *Circulation*, vol. 104, no. 1, pp. 68–73, 2001.

[2] J. Canny, "A computational approach to edge detection," *IEEE Transactions on Pattern Analysis and Machine Intelligence*, vol. PAMI-8, no. 6, pp. 679–698, 1986.

[3] A. R. Abdel-Dayem and M. R. El-Sakka, "A novel morphological-based carotid artery contour extraction," in *International Conference on Image Analysis and Recognition*, Springer, 2005.

[4] C. P. Loizou, "Atherosclerotic carotid plaque segmentation," in *Handbook of Ultrasonics and Sonochemistry*, Springer, 2015.

[5] A. K. Hamou and M. R. El-Sakka, "A novel segmentation technique for carotid ultrasound images," in *International Conference on Image Analysis and Recognition*, 2016.

[6] E. Kyriacou et al., "Classification of atherosclerotic carotid plaques using morphological analysis on ultrasound images," *Applied Intelligence*, vol. 32, no. 1, 2010.

[7] K. He, X. Zhang, S. Ren, and J. Sun, "Deep residual learning for image recognition," in *Proceedings of the IEEE conference on computer vision and pattern recognition*, pp. 770–778, 2016.

[8] O. Ronneberger, P. Fischer, and T. Brox, "U-net: Convolutional networks for biomedical image segmentation," in *International Conference on Medical Image Computing and Computer-Assisted Intervention*, Springer, pp. 234–241, 2015.

[9] J. Cheng, F. Zhang, and H. Li, "Fully automatic plaque segmentation in 3-D carotid ultrasound images," in *2013 IEEE International Symposium on Biomedical Imaging (ISBI)*, pp. 828–831, 2013.