MR ANDREAS SERNER (Orcid ID : 0000-0003-4308-901X)

Accepted Article

Article type : Original Article

Title:
Characteristics of acute groin injuries in the adductor muscles – a detailed MRI study in athletes.

Running head:
Acute adductor injury characteristics

Authors:
Andreas Serner[1,2], Adam Weir[1], Johannes L Tol[1,3,4], Kristian Thorborg[2], Frank Roemer[5,6], Ali Guermazi[5], Eduardo Yamashiro[1], Per Hölmich[1,2]

(1) Aspetar Orthopaedic and Sports Medicine Hospital, Doha, Qatar.
(2) Sports Orthopaedic Research Center (SORC-C), Department of Orthopaedic Surgery, Copenhagen University Hospital, Amager-Hvidovre, Denmark.
(3) The Sports Physician Group, Department of Sports Medicine, OLVG, Amsterdam, the Netherlands
(4) Amsterdam Center of Evidence Based Sports Medicine, Academic Medical Center, Amsterdam, The Netherlands
(5) Quantitative Imaging Center (QIC), Department of Radiology, Boston University School of Medicine, Boston, MA, USA.
(6) Department of Radiology, University of Erlangen-Nuremberg, Erlangen, Germany.

Corresponding author:
Andreas Serner, PT, MSc.
Aspetar Orthopaedic and Sports Medicine Hospital
Sports City Street, P.O. Box 29222
Doha, Qatar
Telephone: +974 55458563
E-mail: andreas.serner@aspetar.com

Key words: Groin pain, muscle injury, thigh, adductor longus, avulsion, imaging, diagnosis.
This article has been accepted for publication and undergone full peer review but has not been through the copyediting, typesetting, pagination and proofreading process, which may lead to differences between this version and the Version of Record. Please cite this article as doi: 10.1111/sms.12936
This article is protected by copyright. All rights reserved.

Accepted Article

ABSTRACT

Acute adductor injuries account for the majority of acute groin injuries; however, little is known about specific injury characteristics, which could be important for the understanding of etiology and management of these injuries. The study aim was to describe acute adductor injuries in athletes using magnetic resonance imaging (MRI). Male athletes with acute groin pain and an MRI confirmed acute adductor muscle injury were prospectively included. MRI was performed within 7 days using a standardized protocol and a reliable assessment approach. 156 athletes presented with acute groin pain of which 71 athletes were included, median age 27 y (range 18-37). There were 46 isolated muscle injuries, and 25 athletes with multiple adductor injuries. In total, 111 acute adductor muscle injuries were recorded; 62 adductor longus, 18 adductor brevis, 17 pectineus, 9 obturator externus, 4 gracilis and 1 adductor magnus injury. Adductor longus injuries occurred at three main injury locations; proximal insertion (26%), intramuscular musculotendinous junction (MTJ) of the proximal tendon (26%) and the MTJ of the distal tendon (37%). Intramuscular tendon injury was seen in 1 case. At the proximal insertion 12 of 16 injuries were complete avulsions. This study shows that acute adductor injuries generally occur in isolation from other muscle groups. Adductor longus is the most frequently injured muscle in isolation and in combination with other adductor muscle injuries. Three characteristic adductor longus injury locations were observed on MRI, with avulsion injuries accounting for three quarters of injuries at the proximal insertion, and intramuscular tendon injury was uncommon.

1. Introduction

Acute adductor muscle injuries are common in multi-directional sports,(Orchard, 2015; Walden, Hagglund, & Ekstrand, 2015) and account for the majority of acute groin injuries in

This article is protected by copyright. All rights reserved.

athletes.(Serner et al., 2015) Several general muscle injury classification systems have been suggested to assist in the management of acute muscle injuries.(Chan et al., 2012; Mueller-Wohlfahrt et al., 2013; Pollock et al., 2014) Most classifications are however based on acute hamstring injuries,(Hamilton et al., 2015) as this is the most frequently injured muscle group in many sports.(Hallén & Ekstrand, 2014). The main purpose of these classification systems is to describe variances between injuries that can define the pathology, and may determine decisions on the type of treatment or prognosis of return to sport. In this regard, several parameters have been suggested to be relevant in different muscle groups. In acute hamstring injuries, variations in injury locations, such as differences in the distance from the injury site to the proximal insertion, and structural involvement, such as intramuscular tendinous injury, have been described as potentially clinically relevant.(Reurink et al., 2015; Brukner & Connell, 2016) Similarly variations in location, as well as larger extent of edema have also been suggested as important elements in rectus femoris injuries.(Balius et al., 2009) Additionally, the location of soleus muscle injuries can be differentiated into central, medial and lateral tendon aponeurosis injuries potentially aiding in prognosis of these injuries.(Pedret et al., 2015)

Acute groin injury classification systems have not yet been developed, and detailed descriptions of acute adductor injuries are lacking. Anatomical studies show that the proximal tendons of both the adductor longus and adductor brevis extend intramuscularly distally,(Strauss, Campbell, & Bosco, 2007; Davis, Stringer, & Woodley, 2012) yet their potential relationship with acute injury has not been described. There are descriptions of imaging of acute adductor injuries available, but these are usually from case studies or examples as part of general descriptions of imaging in groin pain.(Nelson, Kassarjian, & Palmer, 2005; Coker & Zoga, 2015; Pesquer et al., 2015; Greditzer IV et al., 2017) These therefore do not provide a structured overview of the variances within these injuries. The

This article is protected by copyright. All rights reserved.

Accepted Article

purpose of this study is to describe injury characteristics of acute adductor injuries in athletes using magnetic resonance imaging (MRI).

2. Methods

2.1. Participants

Athletes with an acute groin injury were prospectively and consecutively included over 3 sports seasons (August 2012 to May 2015), as part of a larger prospective study at a specialized sports medicine hospital in Qatar.(Serner et al., 2015, 2016a,b) Inclusion criteria were: male athletes, 18-40 years old, participating in competitive sports, and who attended the study center within 7 days of acute onset groin pain sustained during sports. The groin was considered as "the external junctural region between the lower part of the abdomen and the thigh",(National Library of Medicine, National Institutes of Health) with a distal limit corresponding approximately to the upper third of the anterior and medial thigh. Athletes reporting gradual onset or exacerbation of on-going pain, as well as athletes presenting with clinical signs or symptoms of prostatitis, urinary tract infection or other known co-existing chronic diseases, such as significant hip osteoarthritis were excluded. General demographics as well as type of sport and reported injury situation were registered by a sports medicine physician during the initial clinical examination. For the present sub-study focusing on MRI findings, only players with a positive MRI (defined as imaging findings indicating edema with or without structural disruption, as well as complete muscle disruptions or avulsions)(Serner et al., 2016a) in the adductor muscle group (adductor longus, adductor brevis, pectineus, adductor magnus, gracilis, obturator externus) were included. The obturator externus was included based on its secondary function as a hip adductor,(Gudena et al., 2015) as well as being a known, although uncommon cause of acute anterior hip or groin pain in

This article is protected by copyright. All rights reserved.

Accepted Article

sport.(Wong-On et al., 2017) Ethical approval was obtained from the Shafallah Medical Genetics Center Institutional Review Board (IRB#: 2012-013) and the Anti-Doping Lab Qatar Institutional Review Board (IRB#: EXT 2014000004), and written informed consent was acquired from all athletes at inclusion.

2.2. MRI examination

MRI was performed on a 1.5-Tesla system (Magnetom Espree, Siemens, Germany) using a body matrix coil and 8 standardized sequences; two coronal T1-weighted and short tau inversion recovery (STIR), one sagittal fat-suppressed proton density-weighted, three axial T1-, fat-suppressed proton density-, and fat-suppressed T2-weighted, and two axial oblique fat-suppressed proton density- and T2-weighted sequences, for which technical parameters have been described in a previous publication.(Serner et al., 2016a) The MRI assessment was performed by an experienced musculoskeletal radiologist (FWR), and the full standardized multi-dimensional MRI assessment was tested for both intra- and inter-rater reproducibility with specific results published separately.(Serner et al., 2016a) Overall, excellent reproducibility was found for MRI parameters relating to acute lesions, with kappa values generally above 0.8 and ICC values above 0.9.(Serner et al., 2016a) Additionally, after primary assessment all cases were reviewed by the first author, and any discrepancies were discussed with a second experienced musculoskeletal radiologist (EY) and adapted where appropriate. The following muscles in the groin region were evaluated: adductor longus, adductor brevis, pectineus, adductor magnus, gracilis, obturator externus, obturator internus, rectus abdominis, transversus abdominis, internal and external abdominal obliques, iliacus, psoas major, rectus femoris, and sartorius. Based on our previous findings of muscle injuries in athletes with acute groin pain, we also included vastus medialis and tensor fasciae latae.(Serner et al., 2015)

This article is protected by copyright. All rights reserved.

Accepted Article

2.3. MRI assessment parameters

The presence or absence of an acute musculotendinous lesion was scored for each muscle. If multiple injuries were observed, all muscles were scored individually.

2.3.1. Grading

Muscle injury grading was defined by the extent of fluid seen on the MRI. All MRI positive acute lesions were graded on an ordinal scale from 1-3, similar to previously described classifications(Peetrons, 2002; Hancock et al., 2009) with grade 1: diffuse intramuscular hyper-intensity representing edema only; grade 2: architectural disruption defined as fluid equivalent intramuscular collection; and grade 3: avulsions or complete musculotendinous disruptions. Lesions showing a more subtle, diffusely appearing intramuscular hyper-intensity of less contrast in comparison to the acute lesions were defined as non-acute,(Serner et al., 2016a) and not included in our study.

2.3.2. Anatomical location

The anatomical location of the acute injuries was scored as being related to the proximal or distal tendon, and further categorized into insertional or musculotendinous junction (MTJ) injury. The presence or absence of tendon waviness was noted, suggesting a tendinous injury.(Comin et al., 2013) For the adductor longus and brevis we divided the MTJ injuries of the proximal tendon into superficial tendon and intramuscular tendon. The differentiation was made at the point where the proximal tendon first becomes intramuscular. Based on anatomical studies this appears to be approximately 1-2.5 cm from the insertion, with the entire proximal tendon becoming intramuscular at app. 5.5-8.0 cm from the insertion, and a mean total proximal tendon length of 11.6 cm (±5.1).(Tuite et al., 1998; Strauss et al., 2007; Davis et al., 2012). For the adductor brevis this transition less clear, but the proximal tendon

Accepted Article

This article is protected by copyright. All rights reserved.

is described to be apparent superficially until approximately 3-4 cm from the insertion, where it extends intramuscularly to about 4.5-6.5 cm. from the insertion (Davis et al., 2012)

2.3.3. Location and extent of edema and disruption

Edema location was measured using the distance from the proximal border of edema to the pubic insertion. For grade 3 lesions the amount of retraction for avulsion injuries or the substance gap for complete musculotendinous disruption was recorded. As measures of the extent of the injury are often included in muscle injury classification systems,(Hamilton et al., 2015) we also measured the extent of both the edema and muscle disruption in three dimensions in mm: medial-lateral, anterior-posterior, and proximal-distal. We used the following formula for approximation of cross sectional area (CSA): $\frac{\text{medial}-\text{lateral distance}}{2} \times \frac{\text{anterior}-\text{posterior distance}}{2} \times \pi$.

2.4. Statistical methods

Descriptive statistics were used to provide overviews of the scored parameters, and specified for the individual muscle locations. Statistical analysis was performed using SPSS software (v 21; IBM Corp).

3. Results

3.1. Participants

In total 156 male adult athletes presented within 7 days after onset of acute groin pain. Of these, 71 athletes were included in this study (flowchart Figure 1); median age was 27 years (IQR 23-29, range 18-37), height 177 cm (IQR 173-184, range 159-202), and weight 76 kg (IQR 68-86, range 47-131). The athletes participated in football (n=39, 55%), futsal (n=11, 15%), handball (n=8, 11%), basketball (n=4, 6%), volleyball (n=4, 6%) and the remaining

This article is protected by copyright. All rights reserved.

Accepted Article

athletes from other sports (n=5, 7%). Reported injured situations were: kicking (n=17, 24%), change of direction (n=17, 24%), reaching/stretching (n=12, 17%), sprinting (n=8, 11%), jumping (n=7, 10%), tackling (n=7, 10%), sliding (n=2, 3%), and one was pulled by an opponent (n=1, 1%). A specified overview of injury situations compared to specific muscle injuries is provided in Appendix 1.

3.2. Acute adductor injuries

In the 71 athletes with MRI positive acute adductor injuries, a total of 121 acute injuries were identified, with 111 adductor injuries and 10 additional injuries in other muscles (Table 1). Isolated injuries were observed in 46 (65%) athletes, and 25 (35%) athletes had multiple muscle injuries with 18 different combinations of injured muscles (specified in Appendix 2 including grading). The adductor longus was involved in 62 (87%) cases in total, and in 23 (92%) cases with multiple adductor muscle injuries. There were 49 acute injuries in the other adductor muscles, most frequently involving the adductor brevis and pectineus. There were 37 isolated injuries in the adductor longus, 4 in the pectineus (Figure 2), 3 in the obturator externus, and two in the adductor brevis (Appendix 2)

3.3. Anatomical location

The location of injuries in the adductor longus is presented in Table 2. The location of the intramuscular edema and disruption in adductor longus injuries is presented in Table 3. This includes specification for injuries related to the proximal and distal tendon MTJ, which are exemplified in Figure 3. There was one injury with apparent disruption of the intramuscular tendon itself. This was seen in proximal adductor longus and addition to adjacent MTJ injury. In general, we observed that the MTJ injuries of the proximal tendon were primarily located at the anterior side of the intramuscular tendon (Figure 4). Due to the relatively low number

Accepted Article

This article is protected by copyright. All rights reserved.

of injuries in the other adductor muscles, individual specifications of the location and the extent of edema and disruption are not presented for these.

3.4. Injury grading and extent

The majority of injuries were graded as 1 or 2 (n=59, 83%), and there were 12 (17%) athletes with grade 3 injuries (Table 2). These 12 were all proximal adductor longus avulsions, which were combined in all cases with additional injuries in at least two other adductor muscles. Three of the adductor longus avulsions included an additional adductor brevis or pectineus avulsion. The mean retraction of the adductor longus tendon/fibrocartilage was 17 mm (SD 10 mm, range 2-31 mm). The avulsion injuries were all scored as grade 3 injuries, however, it was observed that in two avulsion injuries with only minor retraction, there was a seemingly minimal connection of the most anterior fibers of the adductor longus (Figure 5).

In cases with multiple adductor injuries, the adductor longus was reported to have the same or a higher injury grading than the other muscles in 95% of the cases. In the adductor longus injuries, the mean CSA of disruption (fluid collection) was 99 mm^2 (SD 73, range 20-275), with a mean of 91 mm^2 (SD 66, range 20-224) and 107 mm^2 (SD 81, range 25-275) for the proximal and distal injuries respectively. The mean proximal-distal length of the disruption was 24 mm (SD 11, range 10-51), with 24 mm (SD 12, range 10-51) and 24 mm (SD 10, range (12-39) for the proximal and distal lesions respectively. No avulsion fractures were observed.

3.5. Injury characteristics

The adductor longus injuries can generally be divided into three characteristic injury locations; 1) the proximal insertion, where most injuries were complete avulsions, 2) the MTJ of the proximal tendon, where injury to the tendon structure was rarely identified, and 3) the

This article is protected by copyright. All rights reserved.

MTJ of the distal tendon, which may be located at similar distance from the pubic insertion as MTJ injuries of the proximal tendon (Figure 6).

4. Discussion

In this study we examined acute adductor injury characteristics using MRI. We show that acute adductor injuries usually occur in a single muscle, most often the adductor longus. These adductor longus injuries can generally be divided into three characteristic locations; 1) the proximal insertion, 2) the MTJ of the proximal tendon, and 3) the MTJ of the distal tendon. Multiple adductor muscles injuries were observed in about a third of the athletes, whereas a combination with injuries in other muscles was rare.

4.1. Adductor longus avulsions

There were 12 complete adductor longus avulsions accounting for 75% of the injuries at the proximal insertion and 17% of all cases. Previous reports on complete adductor longus ruptures in athletes are usually presented as case-reports, with the largest studies to date including 6-19 complete adductor longus ruptures with less than two injuries per year,(Schlegel et al., 2009; Ueblacker, English, & Mueller-Wohlfahrt, 2015; Tansey et al., 2015) and with all studies reporting only on avulsion injuries. As such the 12 injuries over a 3-year period in our study appears high, and also accounts for a relatively high proportion of the adductor injuries compared to other muscle injury locations.(Hallén & Ekstrand, 2014) The proportion of injuries might be influenced by a higher likelihood of athletes with more severe injuries attending the hospital. Therefore, a more accurate distribution of injuries should therefore be investigated in sports-specific epidemiological studies. While anecdotally, grade 3 adductor longus injuries can also occur at the intramuscular course of the proximal tendon, as well as at the distal tendon,(Greditzer IV et al., 2017) these were not

This article is protected by copyright. All rights reserved.

Accepted Article

observed in our study. The adductor longus avulsions at the proximal insertion described previously were associated with tendon retraction, which usually varies in the range between 1-3 cm,(Schlegel et al., 2009; Ueblacker et al., 2015) similar to our findings. In our study we also observed two avulsion injuries with only minor retraction due to a seemingly minimal connection of the most anterior fibers of the adductor longus (Figure 5). In these cases, a palpable defect or gap might not be detectable clinically, which suggests that particularly in cases with pain at the proximal insertion, imaging could assist in establishing a definite diagnosis, as avulsion injuries are generally associated with longer recovery duration. Adductor avulsions combined with rectus abdominis avulsions have also been reported,(Tansey et al., 2015) but none were observed in our athletes. In three cases we did however see lower grade injuries in the rectus abdominis in combination with an adductor longus avulsion.

4.2. Intramuscular adductor longus tendon injury

There has been an increasing focus on the potentially higher severity of injuries involving the intramuscular tendons.(Brukner & Connell, 2016; Pollock et al., 2016) There was only one case where the intramuscular proximal tendon itself was actually considered to be disrupted with evident tendon waviness. This suggests that intramuscular tendon injury is less prevalent in the adductor longus compared to the hamstrings muscles, where about a quarter of acute injuries include tendon injury,(Comin et al., 2013; Pollock et al., 2016) and to our findings in the proximal rectus femoris injuries, where more than half included tendon injury *(reference: submitted companion paper on hip flexor injuries).*

4.3. Distal adductor longus injuries

Adductor longus injuries at the MTJ of the distal tendon accounted for about half of the partial adductor longus injuries and have not previously been described. Correspondingly, the

This article is protected by copyright. All rights reserved.

Accepted Article

anatomy of the distal adductor longus tendon and MTJ remains unexplained in the scientific literature. The actual extent of the distal tendon was also difficult to determine on the MRI images in both injured and non-injured sides, however, the injuries in our study all appeared to be at the proximal part of the MTJ of the distal tendon with edema extending proximally. Further research using more specific MRI sequences might be helpful to improve knowledge on exact location and specific tissue involvement in these injuries, as well as comparison with anatomical studies.

The measures of edema extent show that there was an overlap of the potential area of edema of the MTJ injuries of the proximal and distal tendon (Table 3, Figure 3). The edema from an injury at the MTJ of the proximal tendon injury extended up to 16.5 cm distally from the pubic insertion, and the edema from an injury at the MTJ of distal tendon injury was located up to only 5.4 cm from the pubic insertion. Similarly, the location of disruption might be around the middle of the muscle in both proximal and distal MTJ injuries, e.g. 93 mm and 92 mm respectively as reported in Table 3. This could potentially affect the area of palpation pain making a clear diagnostic differentiation challenging in the clinical examination. Future studies should examine if differentiating between these two injuries is of further clinical relevance

4.4. Other adductor muscle injuries

Isolated adductor injury not involving the adductor longus was present in only nine (13%) cases. Most of these isolated adductor injuries were proximal, but three of the four isolated pectineus injuries occurred at the distal MTJ. This distal injury location (Figure 2) adjacent to the distal iliacus and psoas muscles might influence the clinical picture and could possibly also be mistaken for a distal iliacus or psoas major injury, which could explain some of the discrepancies between the clinical and radiological diagnosis previously reported.(Serner et

This article is protected by copyright. All rights reserved.

Accepted Article

al., 2015) The adductor brevis has also been shown to have a proximal intramuscular tendon.(Davis et al., 2012) This intramuscular tendon was however very difficult to identify on the included MRI sequences, which prevented a differentiated overview of specific injury location of the adductor brevis injuries.

Gracilis and adductor magnus injuries were few, and when the gracilis was injured it was in combination with a larger adductor longus injury in all four cases. Although generally also considered rare, isolated injuries to the distal gracilis MTJ have been reported to occur in athletes during hip adduction and hip flexion movements.(Pedret et al., 2011) In that study all 7 gracilis injuries were reported to be located at the most proximal portion of the distal MTJ, which resulted in posterior thigh pain rather than groin pain.(Pedret et al., 2011) It is our clinical experience that athletes with acute adductor magnus injuries also present with posterior medial thigh pain, which can explain the low number of these injuries, since our study only include injuries with pain located in the groin. This is probably a result of the posterior location of the proximal insertion of the adductor magnus, with the ischiocondylar portion of the muscle often being considered part of the hamstring muscle group.(Obey et al., 2016; Broski et al., 2016) Injuries in the gracilis and adductor magnus can therefore be considered rare findings in athletes with acute groin pain, but could be considered if the pain is located more posteriorly in the medial thigh.

4.5. Muscle injury classification

Proposed muscle injury classification systems use different ways of classifying the severity of injuries.(Hamilton et al., 2015) Where some consider specific structural involvement, it is a general approach to attempt to categorize the size of the injury into four general categories on imaging; no injury, edema only, partial disruption, and complete disruption, such as used in our study. Partial disruption is however often further divided, such as in the Munich

This article is protected by copyright. All rights reserved.

Accepted Article

consensus statement on muscle injuries,(Mueller-Wohlfahrt et al., 2013) where a difference between minor and moderate partial tears are defined as lesser or greater than a fascicle/bundle. We chose not to use this differentiation as this can often be difficult to clearly distinguish; instead we measured the extent of the disruption. Measures of the extent of the injury have also been proposed in the British athletics muscle injury classification,(Pollock et al., 2014) where the cut-off between a moderate and an extensive disruption includes architectural fiber disruption of more or less than 5 cm. This classification is however primarily based on injuries in the hamstring muscles, which are considerably more extensive than the adductor muscles. Our measures show that the maximal proximal-distal length of disruption in the adductor longus injuries ranged between 10 - 51 mm. A division as suggested in the muscle injury classification would therefore not be usable for adductor longus injuries. Similarly, it is also suggested to use the CSA of the disruption as a percentage of the muscle CSA with cutoffs at above 10% and 50% .(Pollock et al., 2014) We also calculated CSA of the disruption, and found that the disruption in the proximal and distal adductor longus injuries had very similar CSA in the axial views, while the total muscle cross sectional area is considerably larger in the distal part of the adductor longus than the proximal area of injury. Further research is required to investigate whether injury as percent of muscle CSA influences the treatment duration. The percentage of disruption of the specific total MTJ length could be another way of classifying the extent of the injuries, as small difference in the location of the axial image might result in large differences in muscle CSA depending on which muscle is examined. We therefore recommend future classification systems to consider the individual variance between different muscles to determine potentially prognostic variables.

Accepted Article

This article is protected by copyright. All rights reserved.

Accepted Article

4.6. Limitations

Due to the high proportion of adductor longus injuries and relatively low number of other adductor injuries we did not report specific details on the injury extent within these less common adductor injuries. We have previously reported high intra- and inter-rater reproducibility for the MRI assessment parameters included in this study, however, a few of the parameters showed less than perfect intra- and inter-rater agreement, such as the proximal-distal location of edema.(Serner et al., 2016a) We therefore reviewed the images again and discussed any discrepancies to increase validity. An actual method to validate the MRI scoring is lacking. A surgical comparison would for instance not be feasible in this cohort. As such, there is also a chance of potential over reporting of some injuries. This could be the case in the avulsion injuries, where reported injuries in the adjacent muscles may be a result of spreading of edema rather than separate additional intramuscular injuries. Additionally, validation is required to establish the relevance of these MRI injury details in relation to clinical findings and treatment prognosis.

4.7. Perspectives

Using reliable standardized MRI assessment, we found that acute adductor injuries usually occur in a single muscle, but also often with multiple adductor muscles injured in combination. A combination of an adductor injury and injury in other muscles in the groin region appears very rare. This is contrast to longstanding groin pain, where adductor-related groin pain is often present in combination with pain in other locations. Adductor longus is the most frequently injured muscle, both in isolation and in combination with other acute adductor injuries. When injured with other adductor muscles, the adductor longus generally also had the highest injury grading. This should be considered in the prevention of acute groin injuries, where intervention strategies therefore primarily should focus on elements

This article is protected by copyright. All rights reserved.

related to this muscle. We found three characteristic injury locations of the adductor longus. At the proximal insertion, a high proportion of injuries are grade 3 injuries, i.e. complete avulsions. As avulsion injuries are generally considered to have a longer rehabilitation than lower grade injuries, this is an important consideration for clinicians faced with a player with acute insertional pain. A high proportion of injuries were found at the distal adductor longus tendon MTJ. These injuries might be difficult to clinically differentiate from the injuries at the MTJ of the proximal tendon, as the edema/disruption might be located at similar distance from the pubic insertion. Intramuscular tendon tears were very rare, and does therefore not appear to present as a major concern in acute adductor injuries.

In summary, we have presented new information on variations of acute adductor injuries, which should be considered in the diagnosis of acute groin pain. These findings can be used as a foundation in the investigation of injury mechanisms and prognostic factors related to return to sport.

ACKNOWLEDGEMENTS

5. The authors thank all the Aspetar employees involved in this study, especially the radiologists and radiographers who participated in the numerous examinations, as well as Natalia, Laila and Rachid for always assisting with a smile; the National Sports Medicine Program doctors and physiotherapists for referring the athletes; and the doctors and physical therapists who subsequently managed the treatment of the injured athletes.

Accepted Article

This article is protected by copyright. All rights reserved.

Accepted Article

References

Balius R, Maestro A, Pedret C, Estruch A, Mota J, Rodriguez L, García P, Mauri E. Central aponeurosis tears of the rectus femoris: practical sonographic prognosis. Br J Sports Med 2009: **43**: 818–824.

Broski SM, Murthy NS, Krych AJ, Obey MR, Collins MS. The adductor magnus 'mini-hamstring': MRI appearance and potential pitfalls. Skeletal Radiol 2016: **45**: 213–219.

Brukner P, Connell D. 'Serious thigh muscle strains': beware the intramuscular tendon which plays an important role in difficult hamstring and quadriceps muscle strains. Br J Sports Med 2016: **50**: 205–208.

Chan O, Del Buono A, Best TM, Maffulli N. Acute muscle strain injuries: a proposed new classification system. Knee Surg Sports Traumatol Arthrosc Off J ESSKA 2012: **20**: 2356–2362.

Coker DJ, Zoga AC. The Role of Magnetic Resonance Imaging in Athletic Pubalgia and Core Muscle Injury. Top Magn Reson Imaging TMRI 2015: **24**: 183–191.

Comin J, Malliaras P, Baquie P, Barbour T, Connell D. Return to competitive play after hamstring injuries involving disruption of the central tendon. Am J Sports Med 2013: **41**: 111–115.

Davis JA, Stringer MD, Woodley SJ. New insights into the proximal tendons of adductor longus, adductor brevis and gracilis. Br J Sports Med 2012: **46**: 871–876.

Greditzer IV HG, Nawabi D, Li AE, Jawetz ST. Distal rupture of the adductor longus in a skier. Clin Imaging 2017: **41**: 144–148.

Gudena R, Alzahrani A, Railton P, Powell J, Ganz R. The anatomy and function of the obturator externus. Hip Int 2015: **25**: 424–427.

Hallén A, Ekstrand J. Return to play following muscle injuries in professional footballers. J Sports Sci 2014: **32**: 1229–1236.

Hamilton B, Valle X, Rodas G, Til L, Grive RP, Rincon JAG, Tol JL. Classification and grading of muscle injuries: a narrative review. Br J Sports Med 2015: **49**: 306.

Hancock CR, Sanders TG, Zlatkin MB, Clifford PD, Pevsner D. Flexor femoris muscle complex: grading systems used to describe the complete spectrum of injury. Clin Imaging 2009: **33**: 130–135.

Mueller-Wohlfahrt HW, Haensel L, Mithoefer K, Ekstrand J, English B, McNally S, Orchard J, van Dijk CN, Kerkhoffs GM, Schamasch P, Blottner D, Swaerd L, Goedhart E, Ueblacker P. Terminology and classification of muscle injuries in sport: the Munich consensus statement. Br J Sports Med 2013: **47**: 342–350.

National Library of Medicine, National Institutes of Health P. Groin - - MeSH result.

This article is protected by copyright. All rights reserved.

Accepted Article

Nelson EN, Kassarjian A, Palmer WE. MR Imaging of Sports-Related Groin Pain. Magn Reson Imaging Clin N Am 2005: **13**: 727–742.

Obey MR, Broski SM, Spinner RJ, Collins MS, Krych AJ. Anatomy of the Adductor Magnus Origin: Implications for Proximal Hamstring Injuries. Orthop J Sports Med 2016: **4**: 2325967115625055.

Orchard JW. Men at higher risk of groin injuries in elite team sports: a systematic review. Br J Sports Med 2015: **49**: 798–802.

Pedret C, Balius R, Barceló P, Miguel M, Lluís A, Valle X, Gougoulias N, Malliaropoulos N, Maffulli N. Isolated tears of the gracilis muscle. Am J Sports Med 2011: **39**: 1077–1080.

Pedret C, Rodas G, Balius R, Capdevila L, Bossy M, Vernooij RWM, Alomar X. Return to Play After Soleus Muscle Injuries. Orthop J Sports Med 2015: **3**: 2325967115595802.

Peetrons P. Ultrasound of muscles. Eur Radiol 2002: **12**: 35–43.

Pesquer L, Reboul G, Silvestre A, Poussange N, Meyer P, Dallaudière B. Imaging of adductor-related groin pain. Diagn Interv Imaging 2015: **96**: 861–869.

Pollock N, James SLJ, Lee JC, Chakraverty R. British athletics muscle injury classification: a new grading system. Br J Sports Med 2014: **48**: 1347–1351.

Pollock N, Patel A, Chakraverty J, Suokas A, James SLJ, Chakraverty R. Time to return to full training is delayed and recurrence rate is higher in intratendinous ('c') acute hamstring injury in elite track and field athletes: clinical application of the British Athletics Muscle Injury Classification. Br J Sports Med 2016: **50**: 305–310.

Reurink G, Brilman EG, de Vos RJ, Maas M, Moen MH, Weir A, Goudswaard GJ, Tol JL. Magnetic resonance imaging in acute hamstring injury: can we provide a return to play prognosis? Sports Med Auckl NZ 2015: **45**: 133–146.

Schlegel TF, Bushnell BD, Godfrey J, Boublik M. Success of nonoperative management of adductor longus tendon ruptures in National Football League athletes. Am J Sports Med 2009: **37**: 1394–1399.

Serner A, Roemer FW, Hölmich P, Thorborg K, Niu J, Weir A, Tol JL, Guermazi A. Reliability of MRI assessment of acute musculotendinous groin injuries in athletes. Eur Radiol 2016a: 1–10.

Serner A, Tol JL, Jomaah N, Weir A, Whiteley R, Thorborg K, Robinson M, Hölmich P. Diagnosis of Acute Groin Injuries: A Prospective Study of 110 Athletes. Am J Sports Med 2015: **43**: 1857–1864.

Serner A, Weir A, Tol JL, Thorborg K, Roemer F, Guermazi A, Hölmich P. Can standardised clinical examination of athletes with acute groin injuries predict the presence and location of MRI findings? Br J Sports Med 2016b: bjsports-2016-096290.

Strauss EJ, Campbell K, Bosco JA. Analysis of the Cross-Sectional Area of the Adductor Longus Tendon A Descriptive Anatomic Study. Am J Sports Med 2007: **35**: 996–999.

This article is protected by copyright. All rights reserved.

Tansey RJ, Benjamin-Laing H, Jassim S, Liekens K, Shankar A, Haddad FS. Successful return to high-level sports following early surgical repair of combined adductor complex and rectus abdominis avulsion. Bone Jt J 2015: **97**–**B**: 1488–1492.

Tuite DJ, Finegan PJ, Saliaris AP, Renström PA, Donne B, O'Brien M. Anatomy of the proximal musculotendinous junction of the adductor longus muscle. Knee Surg Sports Traumatol Arthrosc Off J ESSKA 1998: **6**: 134–137.

Ueblacker P, English B, Mueller-Wohlfahrt HW. Nonoperative treatment and return to play after complete proximal adductor avulsion in high-performance athletes. Knee Surg Sports Traumatol Arthrosc 2015: 1–7.

Walden M, Hagglund M, Ekstrand J. The epidemiology of groin injury in senior football: a systematic review of prospective studies. Br J Sports Med 2015: **49**: 792–797.

Wong-On M, Turmo-Garuz A, Arriaza R, Suso JMG de, Til-Perez L, Yanguas-Leite X, Diaz-Cueli D, Gasol-Santa X. Injuries of the obturator muscles in professional soccer players. Knee Surg Sports Traumatol Arthrosc 2017: 1–7.

Tables

TABLE 1:
Muscle injury distribution in the 71 athletes with the total number of injuries and percentage of cases in brackets. Overview of specific combinations of muscle injuries including grading can be found in Appendix 2.

Total muscle injuries (n=71)	
Adductor longus	62 (87%)
Adductor brevis	18 (25%)
Pectineus	17 (24%)
Obturator externus	9 (13%)
Gracilis	4 (6%)
Vastus medialis	4 (6%)
Rectus abdominis	3 (4%)
Sartorius	2 (3%)
Adductor magnus	1 (1%)
Obturator internus	1 (1%)
Total	***121***

Accepted Article

This article is protected by copyright. All rights reserved.

TABLE 2

Proximal-distal injury location in the adductor longus. MTJ = musculotendinous junction

Location	Total	Grade 1	Grade 2	Grade 3
Total number of injuries	62	26	24	12
Proximal tendon insertion	16 (26%)	3 (19%)	1 (6%)	12 (75%)
Proximal tendon MTJ	19 (31%)	8 (42%)	11 (58%)	0
- Superficial MTJ	- 1 (2%)	- 1	- 0	-
- Intramuscular MTJ	- 16 (26%)	- 5	- 11	-
- Non-differentiable	- 2 (3%)	- 2	- 0	-
Distal tendon MTJ	23 (37%)	12 (52%)	11 (48%)	0
Non-differentiable	4 (6%)	3 (75%)	1 (25%)	0

TABLE 3

Adductor longus injuries: Distance from the pubic insertion to the border of edema/disruption (grade 1 & 2 injuries only). Notice the considerable overlap in the range of the location of edema between the proximal and distal injuries, as well as the possibility of similar distance of disruption between these two injury locations. MTJ = musculotendinous junction.

Adductor longus injury location	Edema		Disruption
	Proximal distance from proximal insertion	Distal distance from proximal insertion	Proximal distance from proximal insertion
MTJ of the proximal tendon	34 mm (SD 25, range 0-87)	97 mm (SD 39, range 13-165)	53 mm (SD 27, range 2-93)
MTJ of the distal tendon	95 mm (SD 26, range 54-145)	155 mm (36, range 99-252)	114 mm (SD 14, range 92-132)

Accepted Article

This article is protected by copyright. All rights reserved.

Figures

Figure 1: Flow diagram of patient inclusion and exclusion.

Figure 2: A: Coronal STIR image showing a right distal grade 2 pectineus injury (white arrow) in a 27-year-old football injured during a sprint. **B:** Axial T2-weighted image with fat suppression of the same patient more clearly depicts intramuscular fluid-equivalent signal.

Figure 3. A & B: Coronal STIR image and T2 axial image with fat suppression showing a typical grade 2 injury of the musculotendinous junction (MTJ) of the proximal adductor longus tendon (white arrow) in a 25-year-old futsal player injured during change of direction. **C & D:** Coronal STIR image and T2 axial image with fat suppression showing a typical distal adductor longus MTJ injury (large white arrow) in a 33-year-old football player injured while reaching for the ball. The small arrow in image D shows the proximal intramuscular adductor longus tendon. **E:** Combined image of figure A and C adjusted according to anatomical landmarks illustrating the potential overlap of edema from a proximal and distal adductor longus MTJ injury.

Figure 4: Axial oblique T2-weighted image with fat suppression showing a grade 2 injury (large arrow) at the anterior MTJ of the proximal intramuscular tendon (small arrow) of the right adductor longus in a 32-year-old football player injured during a change of direction.

Figure 5: A & B: Coronal STIR and axial oblique T2-weighted with fat-suppression images showing a complete adductor longus avulsion in a 32-year-old football player injured while reaching for the ball. In addition to the adductor longus avulsion, a grade 2 adductor brevis, grade 1 pectineus, and grade 1 obturator externus injury were also observed. **C & D:** sagittal PD with fat-suppression and axial oblique T2-weighted with fat-suppression images showing an adductor longus avulsion with minimal anterior connection in a 24-year-old football player injured during a change of direction (large white arrows indicate the proximal adductor longus tendon, and small arrows the pubic insertion). In addition to the adductor longus injury, a grade 3 adductor brevis injury, a grade 2 rectus abdominis injury, and a grade 1 pectineus injury were also observed.

Figure 6: Anatomical illustration of the three most common adductor longus injury locations.
MTJ = musculotendinous junction, BTJ = bone-tendon junction.

Accepted Article

This article is protected by copyright. All rights reserved.

Accepted Article

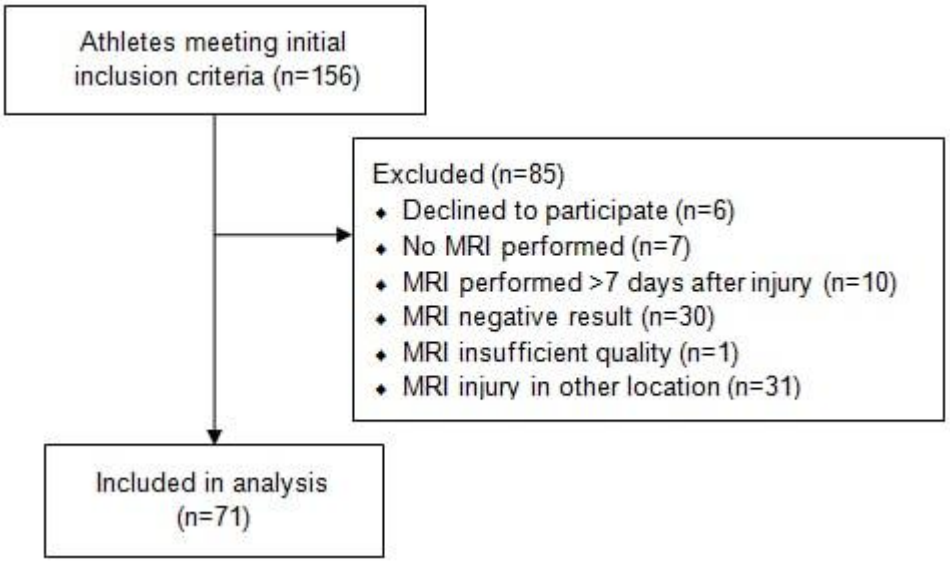

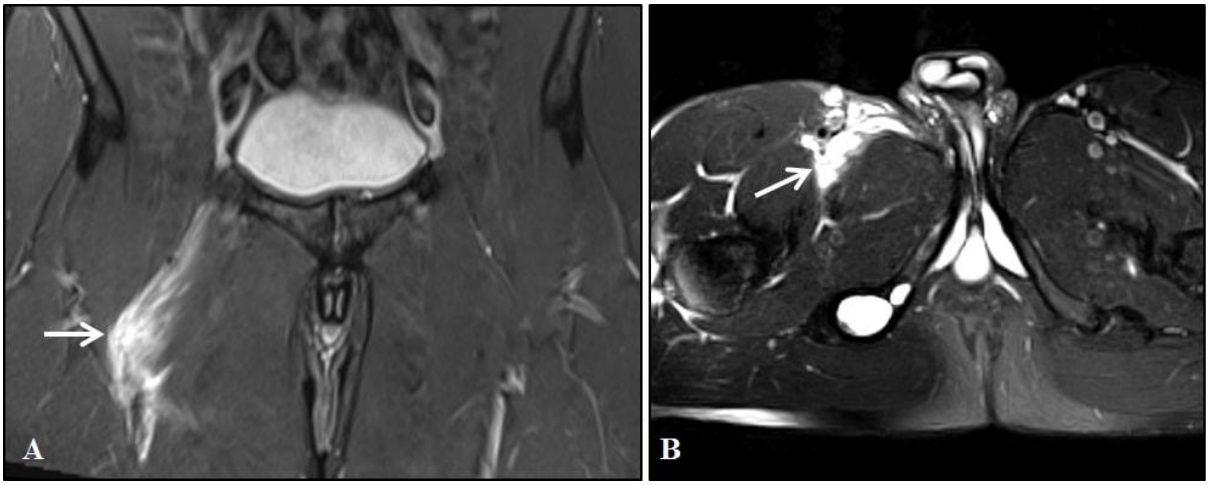

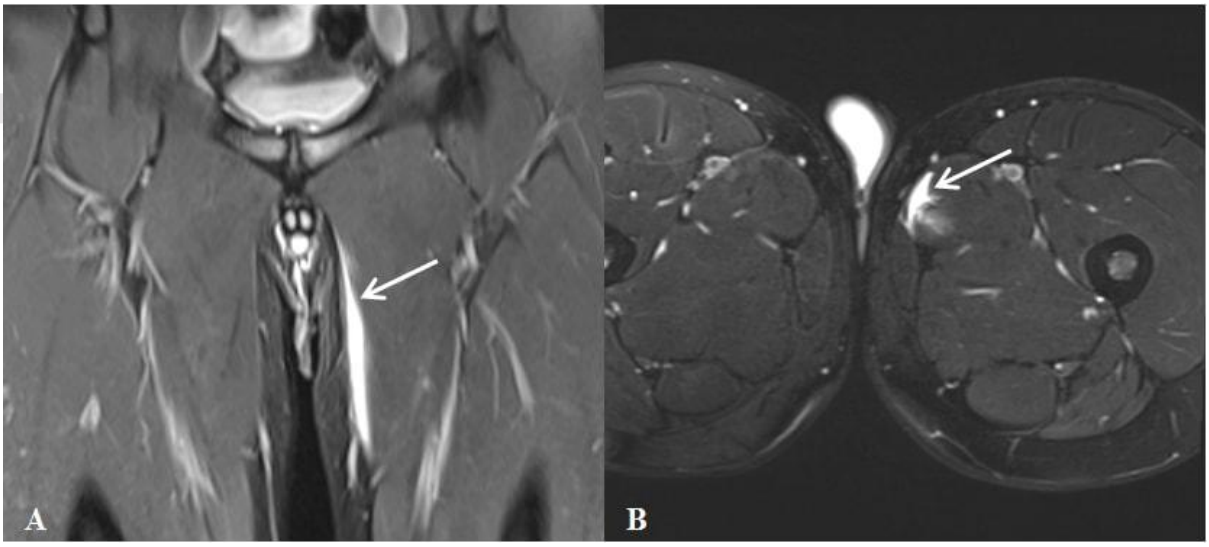

This article is protected by copyright. All rights reserved.

Accepted Article

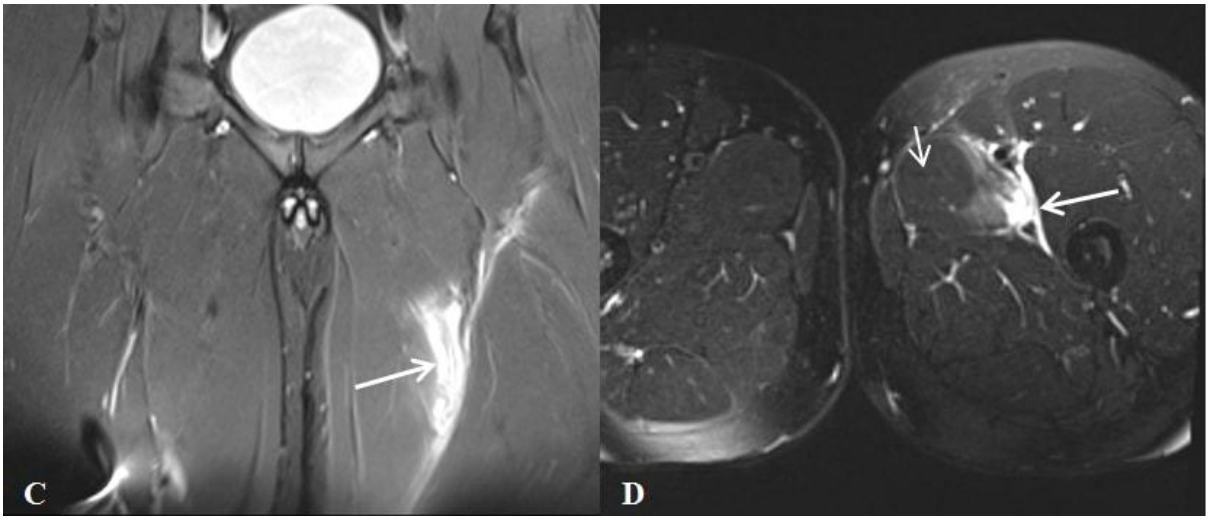

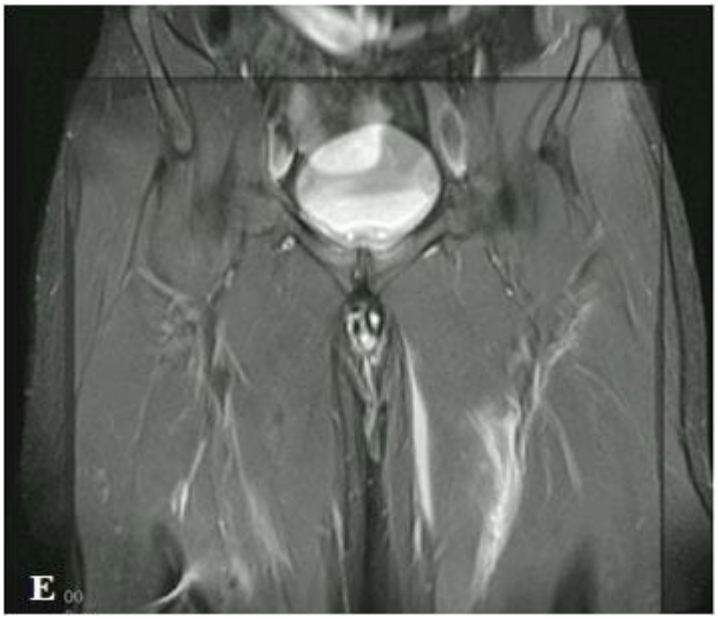

This article is protected by copyright. All rights reserved.

Accepted Article

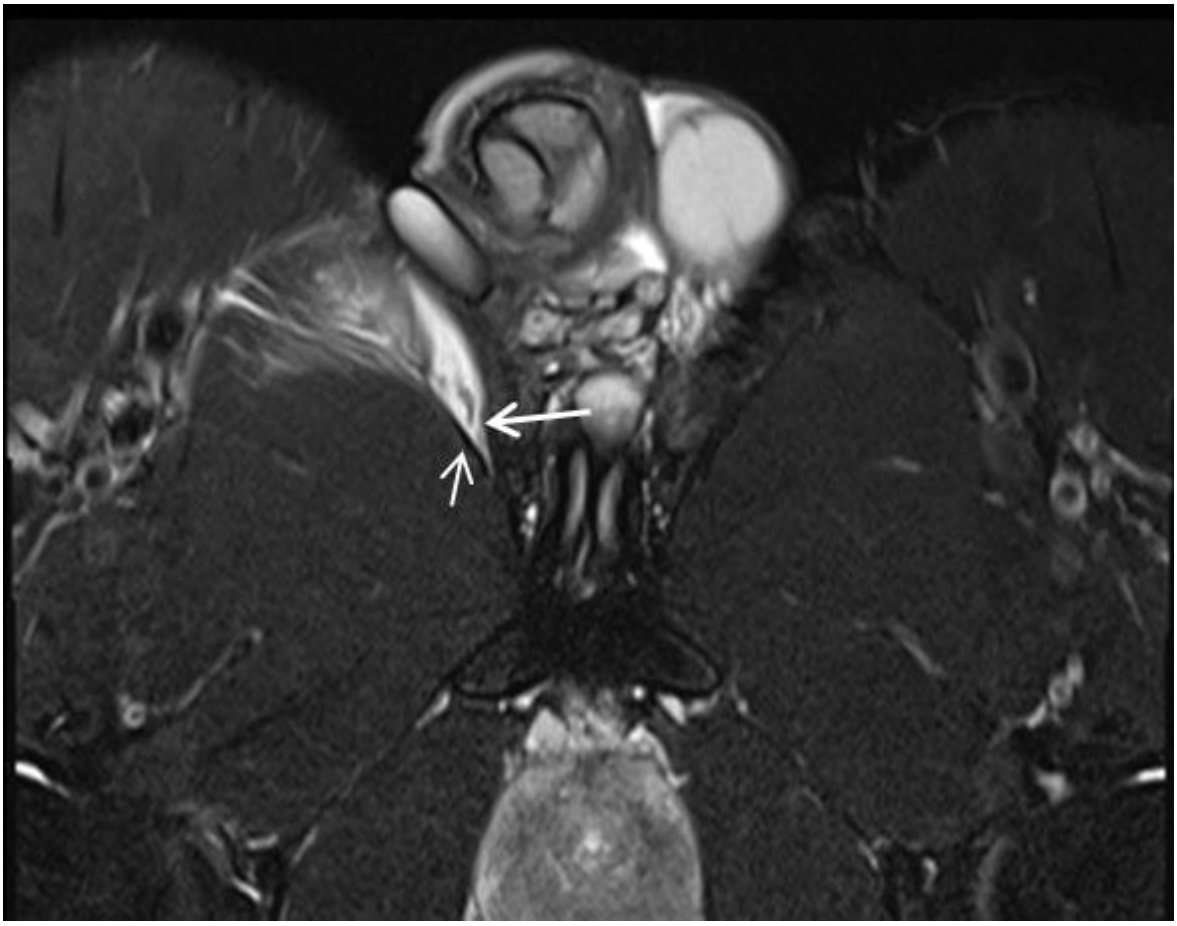

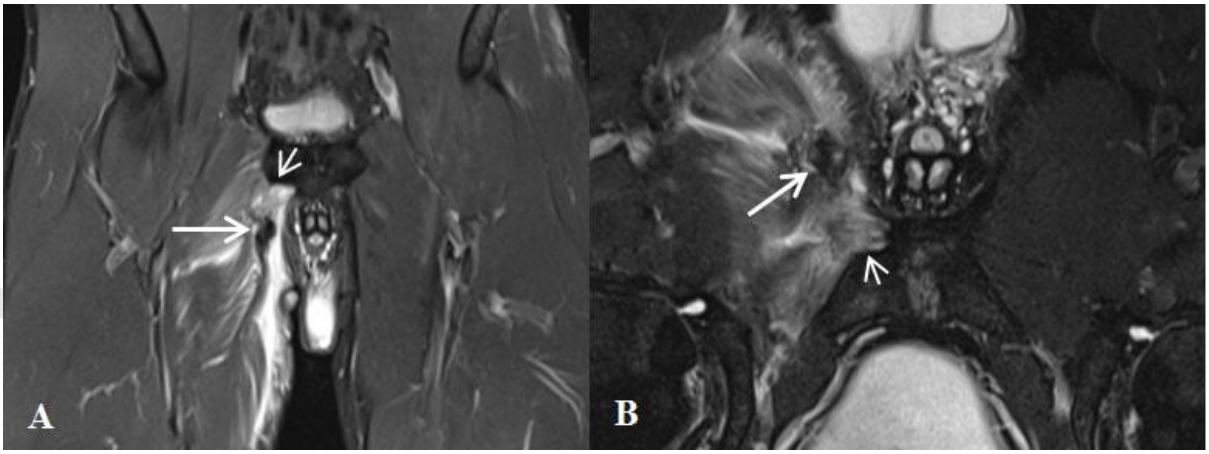

This article is protected by copyright. All rights reserved.

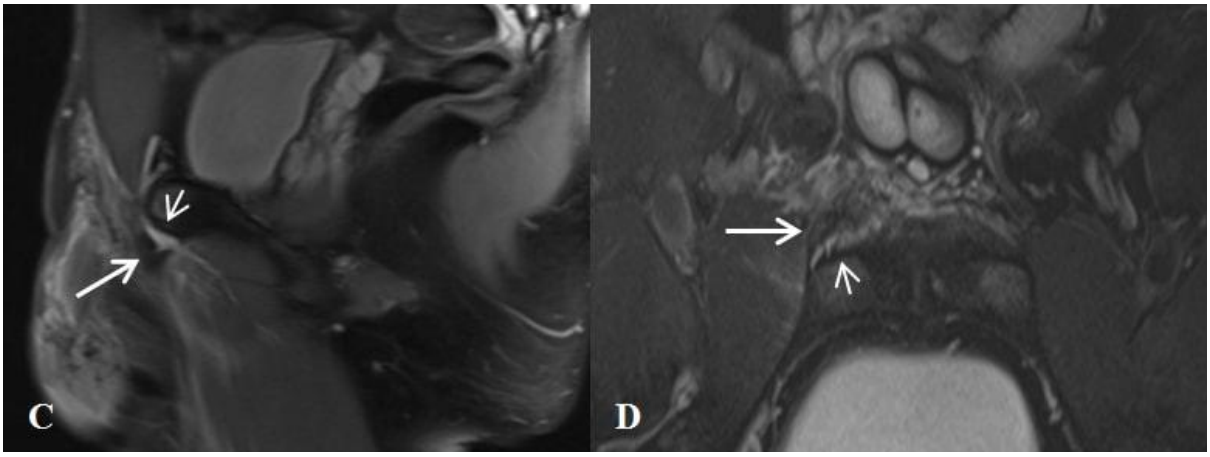

Accepted Article

This article is protected by copyright. All rights reserved.

Accepted Article

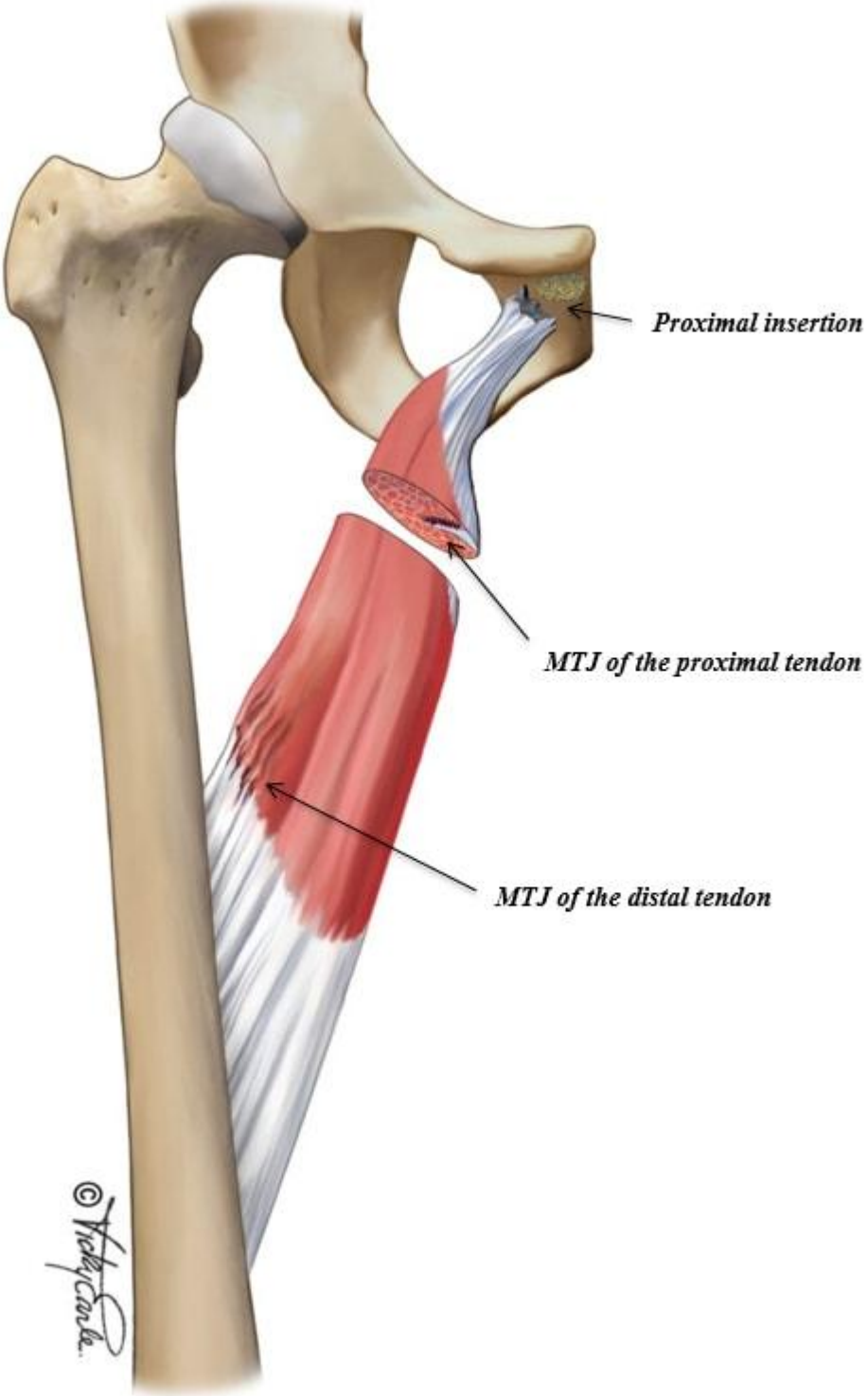

This article is protected by copyright. All rights reserved.