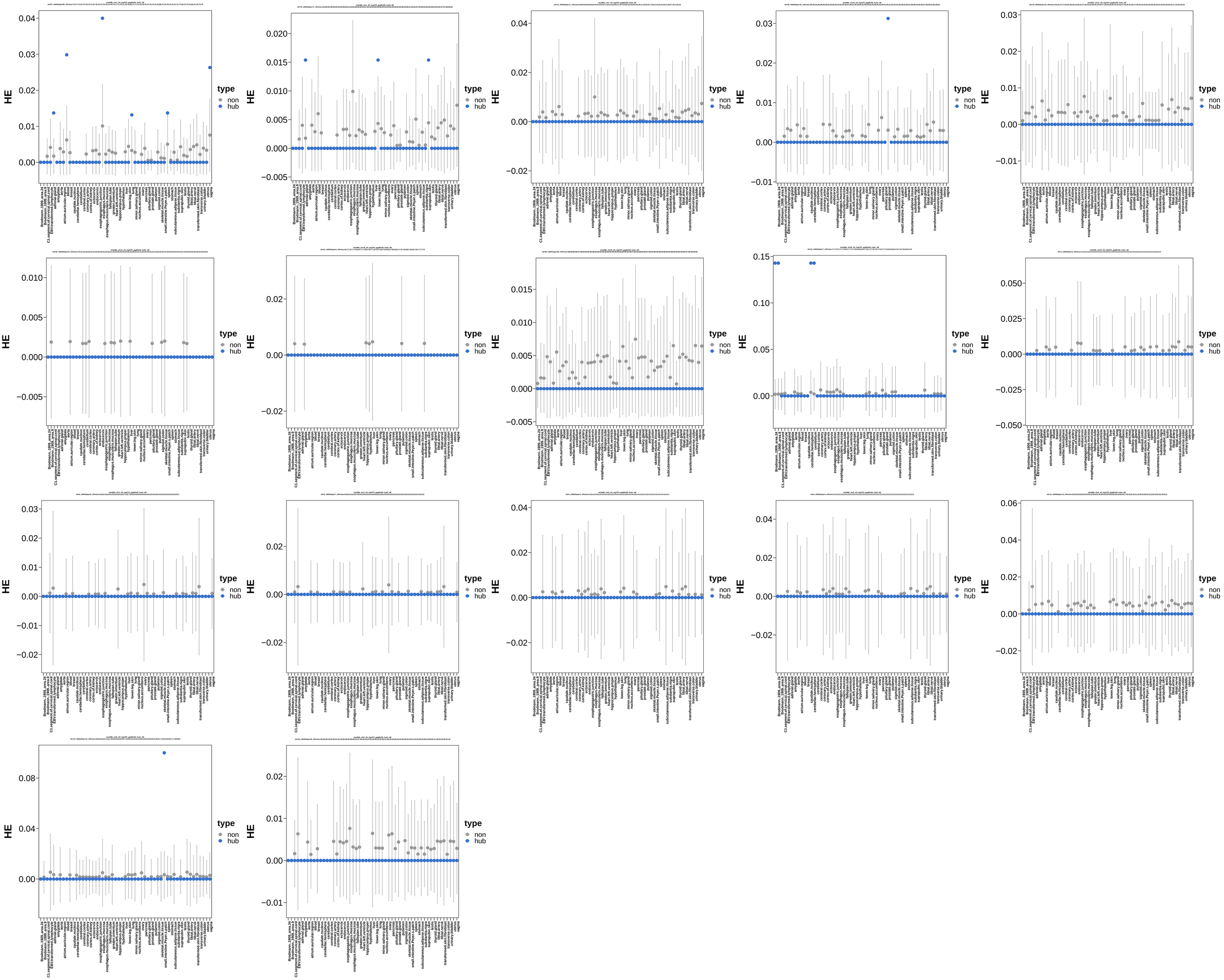
HE
type
non
hub
Brodmann_1909_area.24
Brodmann_1909_area.3
C1.segment.of.cervical.spinal.cord
EBV.transformed.lymphocyte
adrenal.gland
aorta
atrium.auricular.region
blood
caudate.nucleus
cerebellum
cerebellar.hemisphere
coronary.artery
cortex.of.kidney
ectocervix
endocervix
esophagogastric.junction
esophagus.mucosa
esophagus.muscularis.mucosa
fallopian.tube
greater.omentum
heart.left.ventricle
hippocampus.proper
hypothalamus
lower.leg.skin
lung
minor.salivary.gland
nucleus.accumbens
ovary
pancreas
pituitary.gland
prostate.gland
putamen
sigmoid.colon
skeletal.muscle.tissue
small.intestine.Peyer.s.patch
spleen
stomach
subcutaneous.adipose.tissue
substantia.nigra
suprapubic.skin
testis
thyroid.gland
tibial.artery
tibial.nerve
transformed.skin.fibroblast
transverse.colon
urinary.bladder
uterus
vagina