AO TRAUMA

Richard E Buckley | Christopher G Moran | Theerachai Apivatthakakul

AO Principles of Fracture Management

Third Edition

AO TRAUMA

Richard E Buckley | Christopher G Moran | Theerachai Apivatthakakul

AO Principles of Fracture Management

Third Edition

Includes over 200 videos and figure animations as well as over 2,500 images and illustrations

Library of Congress Cataloging-in-Publication Data is available from the publisher.

Hazards

Great care has been taken to maintain the accuracy of the information contained in this publication. However, the publisher, and/or the distributor, and/or the editors, and/or the authors cannot be held responsible for errors or any consequences arising from the use of the information contained in this publication. Contributions published under the name of individual authors are statements and opinions solely of said authors and not of the publisher, and/or the distributor, and/or the AO Group.

The products, procedures, and therapies described in this work are hazardous and are therefore only to be applied by certified and trained medical professionals in environments specially designed for such procedures. No suggested test or procedure should be carried out unless, in the user's professional judgment, its risk is justified. Whoever applies products, procedures, and therapies shown or described in this work will do this at their own risk. Because of rapid advances in the medical sciences, AO recommends that independent verification of diagnosis, therapies, drugs, dosages, and operation methods should be made before any action is taken.

Although all advertising material which may be inserted into the work is expected to conform to ethical (medical) standards, inclusion in this publication does not constitute a guarantee or endorsement by the publisher regarding quality or value of such product or of the claims made of it by its manufacturer.

Legal restrictions

This work was produced by AO Foundation, Switzerland. All rights reserved by AO Foundation. This publication, including all parts thereof, is legally protected by copyright.

Any use, exploitation or commercialization outside the narrow limits set forth by copyright legislation and the restrictions on use laid out below, without the publisher's consent, is illegal and liable to prosecution. This applies in particular to photostat reproduction, copying, scanning or duplication of any kind, translation, preparation of microfilms, electronic data processing, and storage such as making this publication available on Intranet or Internet.

Some of the products, names, instruments, treatments, logos, designs, etc referred to in this publication are also protected by patents and trademarks or by other intellectual property protection laws (eg, "AO", "ASIF", "AO/ASIF", "TRIANGLE/GLOBE Logo" are registered trademarks) even though specific reference to this fact is not always made in the text. Therefore, the appearance of a name, instrument, etc without designation as proprietary is not to be construed as a representation by the publisher that it is in the public domain.

Restrictions on use: The rightful owner of an authorized copy of this work may use it for educational and research purposes only. Single images or illustrations may be copied for research or educational purposes only. The images or illustrations may not be altered in any way and need to carry the following statement of origin "Copyright by AO Foundation, Switzerland".

Check hazards and legal restrictions on www.aofoundation.org/legal

Copyright © 2017 by AO Foundation, Clavadelerstrasse 8, 7270 Davos Platz, Switzerland

Distribution by Georg Thieme Verlag, Rüdigerstrasse 14, 70469 Stuttgart, Germany, and Thieme New York, 333 Seventh Avenue, New York, NY 10001, USA

ISBN: 9783132423091
e-ISBN: 9783132423107

2 3 4 5 6

Foreword

Suthorn Bavonratanavech
AO Foundation Past President 2014–2016
Thailand

When a group of Swiss general and orthopedic surgeons founded the Arbeitsgemeinschaft für Osteosynthesefragen (AO) in 1958, they emphasized that education was of the utmost importance for success in orthopedic trauma care. A new revolution began in 1960 with the initiation of the first hands-on course in Davos, Switzerland, which was a highly successful model for adult education. In 1963, the first AO written report on operative treatment of fractures by Maurice E Müller, Martin Allgöwer, and Hans Willenegger was published in German. Later the technical development of various operative fixation methods for fractures, osteotomies, and arthrodeses was accepted and adopted by the Swiss AO Group. These were demonstrated in detail in 1969 as the first edition of the *Manual of Internal Fixation.* This textbook was translated into English and many other languages and became the preeminent guide for orthopedic trauma surgeons throughout the world. It was a benchmark for precise AO techniques from 1970 through the next two decades with revised editions published in 1977 and 1992. In 1977, as a young inexperienced surgeon, with the help of the book, I learned much about the AO principles and techniques. During those early days, this manual was the main source of orthopedic trauma education offering step-by-step guidance on how to perform operative fracture treatment.

Forty years after AO was founded, with the worldwide acceptance of operative treatment of fractures, the publication of the *AO Principles of Fracture Management* was assigned to an international team of surgeon/authors. The book was designed not to be the manual of osteosynthesis, but primarily to offer comprehensive evidenced-based recommendations to ensure cutting-edge techniques. The *AO Principles of Fracture Management* began with the first edition in 2000, followed by the second edition in 2007, and then with this revised and updated third edition ten years later.

The AO Foundation's mission is “transforming surgery - changing lives” and the team responsible for this text has continued this legacy of excellence with the third edition of the *AO Principles of Fracture Management.* It is unusual in the medical field for any textbook to be as successful and to endure for such an extended period. With the expansion of new knowledge, surgical techniques and technology, the third edition features embedded QR codes that connect readers to a continually evolving store of online AO educational content. This third edition remains a primary source of education, and over the next few years will allow learners to connect to the many forms of electronic media that are rapidly developing on the World Wide Web.

On behalf of the AO Foundation and AO surgeons around the world, I warmly convey our sincere appreciation to the editors, contributors, and publishers. Many thanks to Richard E Buckley, Christopher G Moran, and Theerachai Apivatthakakul, as well as Urs Ruetschi and his AO Education Institute team for their dedication in producing such an excellent book. This book will form the syllabus for AO courses throughout the world and I am convinced that the knowledge provided by this textbook will be as beneficial to a new generation of AO surgeons as the original *Manual of Internal Fixation* was to my generation.

Introduction

This is the third edition of the book on the AO principles of fracture management and it is possible that this will be the last printed version as we move towards the third decade of the 21st century, with most surgeons and students using the World Wide Web as a key source of information. The first and second editions of the book were huge successes, winning prizes with translations into eight languages. These books have formed the syllabus for courses on the surgical management of fractures throughout the world. The third edition builds on this successful format, but rather than being available as just a printed or e-book, it will be developed further to provide a web-based learning platform that integrates multiple learning resources to allow the student immediate access to AO Surgery Reference, teaching videos, webcasts, lectures, demonstrations of surgical technique, and key references.

Since the publication of the second edition in 2007, fracture surgery has continued to evolve. The role and function of locking plates are now better defined, many varieties of anatomically pre-shaped plates are now available, and the number and type of mini-fragment implants has greatly expanded. The widespread use of minimally invasive surgery has continued to emphasize the importance of soft tissues in fracture surgery. Civil and military conflict throughout the world has led to significant advances in resuscitation of polytrauma patients with changes in the timing and approach to fracture surgery. All of these changes are reflected in the text.

All chapters have been profoundly revised and rewritten with new illustrations, animations, and videos. The increasing use of radiology and cross-sectional imaging has been addressed in a new chapter as the surgeon must be aware of these technologies and the risk of radiation exposure to themselves and their patients. There has also been a comprehensive review and update of all references as fracture surgery is now developing a solid evidence base derived from an increasing number of large national randomized controlled trials.

The ageing population is one of the greatest challenges faced by fracture surgeons in many areas of the world. The demographic changes will result in an exponential rise in fragility fractures and so the new edition includes a chapter on fragility fractures and orthogeriatric care. Each year, 2.9 million joint replacements are performed worldwide and this has resulted in a substantial rise in the number of periprosthetic fractures. This increasing clinical problem is covered in another new chapter. The second section of the book on specific fractures has also been expanded to include a new chapter on knee dislocation.

The editors would like to make a special acknowledgement of Thomas Rüedi's contribution not just to this book, but to the teaching of surgery throughout the world. Tom has been an inspiration to us all.

The fundamental principles of fracture surgery have not changed in 60 years, but our increased biological and clinical knowledge, together with advances in technology, have changed how we apply these principles. Successful fracture surgery requires a thorough understanding of these principles with meticulous attention to detail at every single step in the patient's care. We hope that this text will guide you and provide the foundation for a successful career in fracture surgery.

Richard E Buckley, MD, FRCSC
Christopher G Moran, MD, FRCS
Theerachai Apivatthakakul, MD

Acknowledgments

Production and publication of the new third edition of the *AO Principles of Fracture Management* would not have been possible without the dedication and support of an extensive list of contributors. From AO surgeons donating their time and expertise, to colleagues volunteering case notes and images, to our staff within our own medical institutions, and to the teams at AOTrauma and the AO Education Institute, we thank you for assisting us in developing this publication.

While there are many people to thank, we would especially like to mention these individuals:

- Members of the AOTrauma Education Commission for recognizing the importance and significance of this educational opportunity and for approving the development of this publication.
- Thomas Rüedi for his continuing guidance, support, mentorship and friendship. This book represents a legacy within the AO trauma community. It is his guidance and connection to the original philosophy of "AO" which has allowed the spirit of AO to shine through the production of this manual.
- Urs Rüetschi and Robin Greene from the AO Education Institute for their guidance and expertise as well as for enabling extensive resources and staff to prepare this publication and make it into the best publication possible.
- The many colleagues from around the world who provided chapters, cases, and images.
- Suthorn Bavonratanavech for writing the Foreword to this book.
- The entire AO Publishing team led by Carl Lau for their professional support in project management, medical illustration, and graphic design.
- The AO Video team led by Thommy Rüegg for their expertise and assistance in producing video content.
- The AO Surgery Reference medical illustrators led by Lars Veum for their work on the figures.
- And lastly, to our families for their loving support and encouragement throughout this project. Much time was spent away from family for the production of this text and without their kind understanding, this project would not have come to fruition.

Richard E Buckley, MD, FRCSC
Christopher G Moran, MD, FRCS
Theerachai Apivatthakakul, MD

Contributors

Editors

Richard E Buckley, MD, FRCSC
Professor
Foothills Hospital NW
0490 Ground Floor, McCaig Tower
3134 Hospital Drive
Calgary AB T2N 5A1
Canada

Christopher G Moran, MD, FRCS
Professor
Department of Trauma and Orthopaedics
Nottingham University Hospital
Queen's Medical Centre
Derby Road
Nottingham NG7 2UH
UK

Theerachai Apivatthakakul, MD
Professor
Department of Orthopaedics
Faculty of Medicine
Chiang Mai University
Chiang Mai, 50200
Thailand

Illustration and Video Editor

Thomas P Rüedi, MD, FACS
Founding member AO Foundation
Consultant AOTrauma Education
Switzerland

Authors

John Arraf, MD, FRCPC
Department of Anesthesia
Foothills Medical Centre
1403 – 29 St NW
Calgary AB T2N 5A1
Canada

Reto Babst, Dr Med
Professor Vorsteher Department Chirurgie
Leiter Klinik Orthopädie und Unfallchirurgie
Chefartz Unfallchirurgie
Luzerner Kantonsspital
6000 Luzern 16
Switzerland

Zsolt J Balogh, MD
Professor, Director of Trauma
John Hunter Hospital
Locked Bag 1, Hunter Region
Newcastle NSW 2310
Australia

Paulo Barbosa, MD
Hospital Quinta D'or
Rua Almirante Baltazar 435
São Cristovão
Rio de Janeiro CEP 209401 -150
Brazil

Jorge Daniel Barla, MD
Hospital Italiano de Buenos Aires – Orthopedics
Potosí 4247
Buenos Aires C1181ACH
Argentina

Friedrich Baumgaertel, MD, PhD
Associate Professor
Dept. Of Orthopedics and Traumatology
University of Marburg – Private Practice
Neversstr. 7
Koblenz 56068
Germany

Brian Bernstein, MD
P.O. Box 599
Constantia
Cape Town 7848
South Africa

Michael Blauth, MD
Professor Direktor der Univ. –Klinik für Unfallchirurgie
Director Department for Trauma Surgery
Anichstrasse 35
Innsbruck 6020
Austria

Olivier Borens, MD
Professor Service d'Orthopédie et de Traumatologie
Centre hospitalier universitaire vaudois (CHUV)
Rue Bugnon, 46
1011 Lausanne
Switzerland

Douglas A Campbell, ChM, FRCSE, FRCS (Orth)
Spire Leeds Hospital
Jackson Avenue
Leeds LS8 1NT
UK

John T Capo, MD
377 Jersey Ave, Suite 280A
Jersey City, NJ 07302
USA

Keenwai Chong, MD
Bone Joint Institute of Singapore
08-01 Gleneagles Medical Centre
6 Napier road
Singapore 258499
Singapore

Christopher L Colton, MB BS FRCS FRCSEd
Professor Emeritus in Orthopaedic and Accident Surgery
University of Nottingham
England

Piet de Boer, FRCS
Oberdorfstrasse 1
8305 Dietlikon
Switzerland

Mandeep Dhillon, MD, MBBS, MS (Ortho), MNAMS
Professor Department of Orthopaedic Surgery
Post Graduate Institute of Medical Education and Research
92, Sector 24
P.O. Box 1511
Chandigarh 160012
India

Hans Peter Dimai, Prof, Dr Med
Medical University of Graz
Department of Internal Medicine
Division of Endocrinology and Metabolism
Auenbruggerplatz 15
Graz 8036
Austria

Daren Forward, MA, FRCS, DM
The East Midlands Major Trauma Centre
Nottingham University Hospital
Nottingham NG7 2UH
UK

Peter Giannoudis, Dr Med
Professor Academic Department
Trauma & Orthopedic Surgery
Floor D, Clarendon Wing
Great George Street
Leeds General Infirmary
Leeds LS1 3EX
UK

Markus Gosch, Prof, Dr med
Medical Director Department for Geriatrics
Paracelsus Medical University Salzburg, Austria
Nüremberg Hospital North
Prof.-Ernst-Nathan-Str. 1
Nüremberg 90419
Germany

Les Grujic, MD
Orthopaedic & Arthritis Specialist Centre
Level 2, 445 Victoria Ave.
Chatswood, NSW 2067
Australia

Boyko Gueorguiev-Rüegg, PhD
Professor Program Leader Biomedical Development
AO Research Insititute Davos
Clavadelerstrasse 8
7270 Davos
Switzerland

David M Hahn, MD FRCS (Orth)
Consultant Trauma and Orthopaedic Surgeon
Nottingham University Hospital
Queen's Medical Centre
Nottingham NG72UH
UK

Yves Harder, Dr Med
Professor Vice-chief Department of Surgery
Head Plastic, Reconstructive and Aesthetic Surgery
Ente Ospedaliero Cantonale (EOC)
Ospedal Regionale di Lugano;
Sede Ospedale Italiano
Via Capelli
6962 Viganello – Lugano
Switzerland

Martin H Hessmann, Dr med
Professor Academic Teaching Hospital Fulda
Dept. of Orthopaedic and Trauma Surgery
Pacelliallee 4
36043 Fulda
Germany

Dankward Höntzsch, MD
Professor BG Unfallklinik
Schnarrenbergstrasse 95
72076 Tübingen
Germany

James B Hunter, FRCSE (Orth)
Consultant Trauma and Paediatric Orthopaedic Surgeon
Nottingham University Hospital
Queen's Medical Centre
Nottingham NG72UH
UK

Chunyan Jiang, MD
Beijing Jishuitan Hospital
31 Xinjiekoudongjie, Xicheng District
Beijing 100035
China

Matej Kastelec, Dr Med
University Medical Centre Ljubljana
Zaloška cesta 7
1525 Ljubljana
Slovenia

Stephen L Kates, MD
Professor and Chair of Orthopaedic Surgery
Virginia Commonwealth University
Department of Orthopaedic Surgery
1200 E. Broad St
Richmond, VA 23298
USA

James F Kellam, MD, FRCS, FACS
McGovern Medical School
University of Texas
Health Science Center at Houston
6431 Fannin Street, Suite 6.146
Houston, TX 77030
USA

Mauricio Kfuri, MD, PhD
Missouri Orthopedic Institute
1100 Virginia Ave
Columbia, MO 65201
USA

Sherif A Khaled, Dr Med
Professor of Orthopedics
32 Falaky street, Awkaf building
Bab El Louk square
Cairo 11211
Egypt

Hans J Kreder MD, MPH, FRCS(C)
Sunnybrook Health Sciences Centre
2075 Bayview Ave.
Toronto ON M4N 3M5
Canada

Ernest Kwek, MD
Department of Orthopaedic Surgery
Tan Tock Seng Hospital
11 Jalan Tan Tock Seng
Singapore 308433
Singapore

Mark A Lee, MD
Professor Director, Orthopaedic Trauma Fellowship
Vice Chair for Research
UC Davis, Dept. of Orthopaedic Surgery
4860 Y Street, Suite 3800
Sacramento, CA 95817
USA

Fan Liu, MD PhD
Professor Dept. of Orthopaedic Surgery
The Affiliated Hospital to Nantong University
20 Xi Si Road, Nantong
Jiangsu 226001
China

Thomas J Luger, Prof, Dr Med
Department of Anaesthesiology and General Intensive Care Medicine
Anichstrasse 35
Innsbruck 6020
Austria

Cong-Feng Luo, MD
Orthopaedic Trauma Service III
Dept. Orthopaedic Surgery
Shanghai 6th People's Hospital Jiaotong University
600 Yi Shan Road
Shanghai 200233
China

Ching-Hou Ma, MD
1, E-Da Road
Jiau-shu Tsuen, Yan Chau Shiang
Taiwan 824
Taiwan

Michael McKee, MD, FRCSC
Professor and Chair
Department of Orthopaedic Surgery
University of Arizona, College of Medicine
Phoenix, Arizona, USA

Rami Mosheiff, Dr Med
Professor Director of Orthopaedic Trauma Unit
Hadassah University Medical Center
Ein Kerem
P.O.B 12000
Jerusalem 91120
Israel

Stefaan Nijs, MD
Head of the dept. of Traumatology
UZ Leuven
Herestraat 49
Leuven 3000
Belgium

Markku Nousiainen, MD, MSc, FRCSC
Holland Orthopaedic and Arthritic Centre
Sunnybrook Health Sciences Centre
621-43 Wellesley St. East
Toronto ON M4Y 1H1
Canada

Mahmoud M Odat, MD, FACS
Senior Consultant Orthopedic & Trauma Surgeon
Arab Medical Center
P.O. Box 128
Amman 11831
Jordan

Chang-Wug Oh, MD
Professor & Director
Department of Orthopedic Surgery
Kyungpook National University Hospital
130 Dongdeok-ro, Jung-gu
Daegu 700-721
South Korea

Jong-Keon Oh, MD
Department of Orthopaedic Surgery
Guro Hospital
Korea University College of Medicine
80 Guro 2-dong, Guro-gu
Seoul 152-703
South Korea

Rodrigo Pesántez, MD
Professor
Avenida 9# 116-20
Consultorio 820
Bogotá
Colombia

Chanakarn Phornphutkul, MD
Department of Orthopaedics
Faculty of Medicine
Chiang Mai University
Chiang Mai, 50200
Thailand

Matthew Porteous, Dr Med
West Suffolk Hospital
Hardwick Lane
Bury St Edmunds
Suffolk IP33 2QZ
UK

R. Geoff Richards, FBSE, FIOR
Professor Director
AO Research Insititute Davos
Clavadelerstrasse 8
7270 Davos
Switzerland

David Ring, MD PhD
Associate Dean for Comprehensive Care
Professor of Surgery and Psychiatry
University of Texas at Austin
Department of Surgery and Perioperative Care
Dell Medical School
1912 Speedway
Austin, TX 78712
USA

Michael Schütz, Dr Med, FRACS
Professor Geschäftsführender Direktor
Klinik für Unfall- und Wiederherstellungschirurgie
Klinik für Orthopaedie
Universitaetsklinikum Charité (CVK,CCM)
Augustenburger Platz 1
Berlin 13353
Germany

Rogier KJ Simmermacher, MD, Dr med
Dept. of Surgery
University Medical Center Utrecht
PO Box 85500
GA Utrecht 3508
The Netherlands

Michael S Sirkin, MD
140 Bergen St
Suite d1610
Newark NJ 07103
USA

Theddy Slongo, MD
Senior Consultant for Paediatric Trauma and Orthopedics
University Children's Hospital
Freiburgstrasse 7
3010 Bern
Switzerland

R Malcolm Smith, MD FRCS
Chief Orthopaedic Trauma Service
Department of Orthopaedic Surgery
Massachussets General Hospital
55 Fruit Street YAW 3600
Boston MA 02114
USA

Susan Snape
Microbiology department
Nottingham University Hospital
Queen's Medical Centre
Nottingham NG72UH
UK

Christoph Sommer, Dr med
Kantonsspital Graubünden
Department Chirurgie
Loëstrasse 170
7000 Chur
Switzerland

James Stannard, MD
Hansjorg Wyss Distinguished Chair in Orthopedic Surgery
1100 Virginia Ave,
Columbia, MO 65212
USA

Martin Stoddart, PhD, FRSB
Professor
AO Research Institute Davos
Clavadelerstrasse 8
7270 Davos
Switzerland

Wa'el Taha, MD
Department of Surgery
Prince Mohammed bin Abdulaziz National Guard Health Affairs
Madina 41466
Saudi Arabia

John R Williams, DM FRCS (Orth)
Upper Limb Trauma Unit
Royal Victoria Infirmary
Queen Victoria Road
Newcastle upon Tyne NE1 4LP
UK

Abbreviations

ABI	ankle-brachial index
ACL	anterior cruciate ligament
ACT	autogenous chondrocyte transplantation
AFN	antegrade femoral nail
AIS	abbreviated injury score
ALARA	as low as reasonably achievable (ALARA is a principle in radiation protection)
AO	Arbeitsgemeinschaft für Osteosynthesefragen
AP	anteroposterior
APC	anodic plasma-chemical treatment
APC	anterior-posterior compression
APL	abductor pollicis longus
APTT	activated partial thromboplastin time
ARDS	adult respiratory distress syndrome
ARR	absolute risk reduction (or increase)
ASA	acetylsalicylic acid
ASIA	American Spinal Injury Association
ATLS	advanced trauma life support
AVN	avascular necrosis
BCP	biphasic calcium phosphate
BMC	bone mineral content
BMD	bone mineral density
BMP	bone morphogenic protein
CAS	computer-assisted surgery
CAOS	computer-assisted orthopedic surgery
CaP	calcium phosphate
CARS	compensatory antiinflamatory syndrome
C-clamp	compression clamp (for pelvis)
CDMP	cartilage derived morphogenic protein
CE	Conformité Européenne
CFN	cannulated femoral nail
CNS	central nervous system
CPM	continuous passive motion
cpTi	commercially pure titanium
CRE	carbapenem-resistant Enterobacteriacaea
CRP	C-reactive protein
CRPS I	complex regional pain syndrome type I
CRPS II	complex regional pain syndrome type II
CTA	computed tomography angiography
CTN	cannulated tibial nail
CTPA	computed tomography pulmonary angiogram
DAD	distal aiming device (for tibial nail)
dBP	diastolic blood pressure
DCO	damage-control orthopedics
DCS	damage-control surgery
DCS	dynamic condylar screw
DEXA	dual energy x-ray absorptiometry
DFN	distal femoral nail
DHS	dynamic hip screw
DICOM	digital imaging and communications in medicine
DMB	demineralized bone matrix
DRUJ	distal radioulnar joint
DVT	deep vein thrombosis
DXA	dual x-ray absorptiometry
EAC	early appropriate care
EGF	epithelial growth factor
EHN	expert humeral nail
EMG	electromyogram
EPB	extensor pollicis brevis
EPL	extensor pollicis longus
ESIN	elastic stable intramedullary nailing
ESR	erythrocyte sedimentation rate
ETC	early total care
ETNS	expert tibial nail system
FCR	flexor carpi radialis
FCU	flexor carpi ulnaris
FDA	Food and Drug Administration
FES	fat embolism syndrome
FGF	fibroblast growth factor
FPL	flexor pollicis longus
FWB	full weight bearing
GCS	Glasgow Coma Scale
GDF	growth and differentiation factor
GOS	Glasgow Outcome Score
HA	hydroxyapatite
HFS	Hanover fracture scale
hGH	human growth hormone
HMSC	human mesenchymal stem cells
HRT	hormone replacement therapy
HTO	heterotopic (ectopic) ossification
IASP	International Association for the Study of Pain
ICP	intracranial pressure
ICU	intensive care unit
IGF	insulin-like growth factor
IGF-BP	IGF-binding proteins
IGS	image-guided surgery
IMP	intramuscular pressure
INR	international normalized ratio
ISS	injury severity score
IVC	inferior vena cava
K-wire	Kirschner wire
LC-DCP	limited-contact dynamic compression plate
LCL	lateral collateral ligament
LCP	locking compression plate
LDUH	low-dose unfractionated heparin

LHS	locking head screw
LISS	less invasive stabilization system
LMWH	low-molecular-weight heparin
MCL	medial collateral ligament
MEFiSTO	monolateral external fixation system for traumatology and orthopedics
MESS	mangled extremity severity score
MFA	musculoskeletal function assessment
MIO	minimally invasive osteosynthesis
MIPO	minimally invasive plate osteosynthesis
MIS	minimally invasive surgery
MMA	methyl methacrylate
MOdDAD	modular distal aiming device
MODS	multiple organ dysfunction syndrome
MOF	multiple organ failure
MPP	mean muscle perfusion pressure
MRC	medical research council
MRI	magnetic resonance imaging
MRSA	methicillin-resistant *Staphylococcus aureus*
MSC	mesenchymal stem cells
MSSA	methicillin-sensitive *Staphylococus aureus*
MVA	motor vehicle accident
NNT	number needed to treat/number needed to harm
NPWT	negative-pressure wound therapy, also called vacuum-assisted wound closure (VAC)
NSAIDs	nonsteroidal antiinflammatory drugs
OA	osteoarthritis
OC	oral contraceptives
OR	operating room
ORIF	open reduction and internal fixation
ORP	operating room personnel
OTA	Orthopaedic Trauma Association
OTD	Orthopedic Trauma Directions
PACS	picture archiving and communication systems
PCA	patient-controlled analgesia
PCL	posterior cruciate ligament
PDGF	platelet-derived growth factor
PDLLA	poly-D, L-lactide
PDS	polydioxanone
PE	pulmonary embolism
PEEK	polyetheretherketone
PEG	polyethylene glycol
PEKK	polyetherketoneketone
PEP	pulmonary embolism prevention
PET	positron emission tomography
PET-CT	positron emission tomography combined with computerized tomography
PFN	proximal femoral nail
PFNA	proximal femoral nail antirotation
PGA	polyglycolic acid
PHILOS	proximal humerus internal locked system
PHN	proximal humeral nail
PLA	polylactic acid
PLGA	polyglycolides
PLLA	polylactides
PMMA	polymethylmethacrylate
PMN	polymorphonuclear neutrophils
PQ	pronator quadratus
PTH	parathyroid hormone
PTSD	posttraumatic stress disorder
PWB	partial-weight bearing
QCT	quantitative computed tomography
QMRI	quantitative magnetic resonance imaging
QST	quantitative sensory testing
QUS	quantitative ultrasound
R/AFN	expert retrograde/antegrade femoral nail
RCT	randomized control trial
RES	reticuloendothelial system
RIA	reamer irrigator aspirator
ROM	range of motion
RRR	relative risk reduction
RSD	reflex sympathetic dystrophy, also called complex regional pain syndrome (CRPS)
RTW	return to work
SBP	systolic blood pressure
SIGN	Surgical Implant Generation Network
SIRS	systemic inflammatory response syndrome
SMP	sympathetically maintained pain
SPION	superparamagnetic iron oxide nanoparticles
SSSC	superior shoulder suspension complex
SUN	simplified universal nail
SXA	single x-ray absorptiometry
TAN	titanium aluminium niobium
TBI	traumatic brain injury
ß-TCP	ß-tricalcium phosphate
TEN	titanium elastic nail
TGF	transforming growth factor
TFCC	triangular fibrocartilaginous complex
TFN	trochanteric femoral nail
Ti-15Mo	titanium molybdenum
TLSO	thoracolumbosacral orthosis
TNF-α	tumor necrosis factor α
TRAP	triceps-reflecting anconeus pedicle
TTWB	touch toe weight bearing
TXA	tranexamic acid
UHMWPE	ultra-high molecular weight polyethylene
UHN	unreamed (solid) humeral nail
USP	United States Pharmacopocia
USS	universal spine system
UTN	unreamed tibial nail
VAC	vacuum-assisted wound closure, also called negative-pressure wound therapy (NPWT)
VAS	Visual Analog Scale
VEGF	vascular endothelial growth factor
VTE	venous thromboembolism
WBAT	weight bearing as tolerated
WBCT	whole-body computed tomography (for trauma)

Online AO Educational Content

Abundant online educational offerings from across AO are accessible through the QR codes printed on each chapter title page. Using a QR code scanner on a mobile device, readers will be taken to specific chapter microsites that contain not only the Videos and Fig/Animations for each chapter, but also supplemental AO educational content curated by the book editors specifically for that chapter topic.

Links to supplemental AO educational content include:

- AO Surgery Reference
- AO Skills Lab
- AOSTaRT
- Webinars and webcasts
- Lectures
- Teaching videos
- eLearning modules
- Mobile apps
- ICUC cases

As the array of online AO educational resources evolves and develops, the offerings in the chapter microsites will be regularly reviewed and updated by the book editors. This will ensure that readers are linked to the latest in AO education.

Front matter

Foreword	V
Introduction	VI
Acknowledgments	VII
Contributors	VIII
Abbreviations	XII
Online AO Educational Content	XIV

Volume 1–Principles

AO philosophy and basic principles

1.1	AO philosophy and evolution Richard E Buckley, Christopher G Moran, Theerachai Apivatthakakul	3
1.2	Biology and biomechanics in bone healing Boyko Gueorguiev-Rüegg, Martin Stoddart	9
1.3	Implants and biotechnology Geoff Richards	27
1.4	Fracture classification James F Kellam	39
1.5	Soft-tissue injury: pathophysiology, evaluation, and classification Brian Bernstein	51

Decision making and planning

2.1	The patient and the injury: decision making in trauma surgery Christopher G Moran	73
2.2	Diaphyseal fractures: principles Piet de Boer	83
2.3	Articular fractures: principles Chang-Wug Oh	93
2.4	Preoperative planning Matthew Porteous	105

Reduction, approaches, and fixation techniques

Reduction and approaches

3.1.1	Surgical reduction Rodrigo Pesantez	117
3.1.2	Approaches and intraoperative handling of soft tissues Ching-Hou Ma	137
3.1.3	Minimally invasive osteosynthesis Reto Babst	149

Techniques of absolute stability

3.2.1	Screws Wa'el Taha	173
3.2.2	Plates Mark A Lee	185
3.2.3	Tension band principle Markku Nousiainen	209

Techniques of relative stability

3.3.1	Intramedullary nailing Martin H Hessmann	217
3.3.2	Bridge plating Friedrich Baumgaertel	241
3.3.3	External fixator Dankward Höntzsch	253
3.3.4	Locking plates Christoph Sommer	269

General topics

4.1 Polytrauma: pathophysiology, priorities, and management — 311
Peter V Giannoudis

4.2 Open fractures — 331
Rami Mosheiff

4.3 Soft-tissue loss: principles of management — 357
Yves Harder

4.4 Pediatric fractures — 379
Theddy Slongo, James Hunter

4.5 Antibiotic prophylaxis — 421
Susan Snape

4.6 Thromboembolic prophylaxis — 429
Hans J Kreder

4.7 Postoperative management: general considerations — 437
Liu Fan, John Arraf

4.8 Fragility fractures and orthogeriatric care — 451
Michael Blauth, Markus Gosch, Thomas J Luger, Hans Peter Dimai, Stephen L Kates

4.9 Imaging and radiation hazards — 481
Chanakarn Phornphutkul

Complications

5.1 Malunion — 493
Mauricio Kfuri

5.2 Aseptic nonunion — 513
R Malcolm Smith

5.3 Acute infection — 529
Olivier Borens, Michael S Sirkin

5.4 Chronic infection and infected nonunion — 547
Stephen L Kates, Olivier Borens

Volume 2–Specific fractures

Scapula and clavicle

6.1.1 Scapula 565
Michael McKee

6.1.2 Clavicle 573
Ernest Kwek

Humerus

6.2.1 Humerus, proximal 587
Chunyan Jiang

6.2.2 Humerus, shaft 607
John Williams

6.2.3 Humerus, distal 623
David Ring

Forearm and hand

6.3.1 Proximal forearm and complex elbow injuries 637
Stefaan Nijs

6.3.2 Forearm, shaft 657
John T Capo

6.3.3 Distal radius and wrist 673
Matej Kastelec

6.3.4 Hand 699
Douglas A Campbell

Pelvis and acetabelum

6.4 Pelvic ring 717
Daren Forward

6.5 Acetabulum 745
Jorge Barla

Femur and periprosthetic fractures

6.6.1 Femur, proximal 773
Rogier KJ Simmermacher

6.6.2 Femur, shaft (including subtrochanteric fractures) 789
Zsolt J Balogh

6.6.3 Femur, distal 815
Jong-Keon Oh

6.6.4 Periprosthetic fractures 837
Michael Schütz

Knee

6.7.1 Patella 853
Mahmoud M Odat

6.7.2 Knee dislocations 865
James Stannard, Mauricio Kfuri

Tibia

6.8.1 Tibia, proximal 877
Luo Cong-Feng

6.8.2 Tibia, shaft 899
Paulo Roberto Barbosa de Toledo Lourenço

6.8.3 Tibia, distal intraarticular (pilon) 913
Sherif A Khaled

Malleoli and foot

6.9 Malleoli 933
David M Hahn, Keenwai Chong

6.10.1 Hindfoot—calcaneus and talus 961
Richard E Buckley

6.10.2 Midfoot and forefoot 983
Mandeep S Dhillon

Appendix

Glossary A1
Christopher L Colton, Christopher G Moran

Index A15

Section

1

AO philosophy and basic principles

Section 1
AO philosophy and basic principles

1.1	**AO philosophy and evolution** Richard E Buckley, Christopher G Moran, Theerachai Apivatthakakul	**3**
1.2	**Biology and biomechanics in bone healing** Boyko Gueorguiev-Rüegg, Martin Stoddart	**9**
1.3	**Implants and biotechnology** Geoff Richards	**27**
1.4	**Fracture classification** James F Kellam	**39**
1.5	**Soft-tissue injury: pathophysiology, evaluation, and classification** Brian Bernstein	**51**

1.1 AO philosophy and evolution

Richard E Buckley, Christopher G Moran, Theerachai Apivatthakakul

1 AO philosophy

The philosophy of the AO (Arbeitsgemeinschaft für Osteosynthesefragen/Association for the Study of Internal Fixation) has remained consistent and clear, from its inception in 1958 by a visionary group of 13 Swiss colleagues and friends to its status as a worldwide surgical and scientific foundation and community. Advances in basic science and technology, together with growing clinical expertise, have resulted in many changes to the implants, instruments, and techniques used in trauma surgery. However, the basic philosophy of care remains the same today as in 1958 when the AO was founded.

Vision–Excellence in surgical management of trauma and disorders of the musculoskeletal system.

Mission–To foster and to expand a network of healthcare professionals in education, research, development, and clinical investigation to achieve more effective patient care worldwide.

Structure–Medically guided nonprofit organization led by an international group of surgeons specialized in the treatment of trauma.

Fig 1.1-1 Vienna fracture ward from 1913 with patients in traction.

2 Background

In the first half of the 20th century, fracture management mainly focused on achieving bone union and the prevention of infection. The methods used to treat fractures, mostly by immobilization in casts or traction, inhibited rather than promoted function throughout the healing period (**Fig 1.1-1**). The important and key concept of the AO was to provide safe open reduction and stable internal fixation of fractures while protecting the soft tissues and allowing early functional rehabilitation.

Long before the establishment of the AO, the importance of operative fixation of fractures had been recognized. Early advocates included Elie and Albin Lambotte (**Fig 1.1-2**), Robert Danis (**Fig 1.1-3**), Fritz König, William O'Neill Sherman, William Arbuthnot Lane, Gerhard Küntscher (**Fig 1.1-4**), Raoul Hoffmann, and Roger Anderson. However, their ideas and innovations were not widely adopted because significant obstacles needed to be overcome. The list of technical, metallurgical, and biological obstacles was formidable; especially the risk of infection that often resulted in amputation.

Fig 1.1-2 Albin Lambotte's (left) first application of his original model of external fixator (1902).

In addition, peer group skepticism often amounted to real hostility. Innovations, such as stable internal fixation by Albin Lambotte [1], advances in intramedullary nails by Gerhard Küntscher, and the introduction of early motion (albeit in traction) by Lorenz Böhler (**Fig 1.1-5**) [2], Jean Lucas-Championnière [3] and his disciple George Perkins, were restricted by the inability to reconcile two key concepts within one program of care: effective splinting of the fracture and early, controlled mobility of the joints.

3 The role of the AO

What was needed, and what the AO provided, was a coordinated approach to identify these obstacles, to study the difficulties they caused, and to set about overcoming them. The chosen path was to investigate and understand the relevant biology, to develop appropriate technology and techniques, to document the outcomes and react to the findings, and, through teaching and writing, share whatever was discovered.

This enormous challenge was triggered by an apparently small issue. In the 1940s and 1950s questions were being asked, not least by the Swiss workman's compensation board insurance company, why it took some fractures 6–12 weeks to heal but 6–12 months for patients to return to work?

Robert Danis, first through his writings and later by a short personal visit, inspired Maurice E Müller and the early AO group including Martin Allgöwer, Robert Schneider, and Hans Willenegger. The essence of Danis' observation was that healing without callus took place if he used a compression device to impart absolute stability to a perfectly reduced diaphyseal fracture. During healing, the adjacent joints and muscles could be exercised safely and painlessly [4].

Inspired by this concept and driven by a determination to apply it clinically, and establish how and why it worked, Müller and the AO group set in motion a process of surgical innovation, technical development, basic research, and clinical documentation. This progressed as a campaign to improve the functional outcome and minimize the problems and complications of fracture care. The group propagated their message by writing and teaching, and by developing innovative courses to teach their principles and surgical techniques (**Figs 1.1-6–7**). That work continues to this day, involving many specialist groups working for the common goal of improving trauma care worldwide.

Fig 1.1-3 Robert Danis (1880–1962).

Fig 1.1-4 Gerhard Küntscher (1900–1972) instructing Finnish surgeons in 1954.

Fig 1.1-5 Lorenz Böhler receives the first AO Manual as a present from Hans Willenegger in Vienna, Austria, at his 85th birthday celebration.

4 Original AO principles

Today the key concepts, the AO principles, are remarkably similar to the early AO publications from 1962 onward. The essential feature, now as then, is the proper management of the patient, the soft tissues, and the fracture. This requires a complete understanding of patient and fracture factors that influence treatment and outcome.

The original management objectives were:

1 Restoration of anatomy
2 Stable fracture fixation
3 Preservation of blood supply
4 Early mobilization of the limb and patient [5]

These principles were at first presented as the fundamentals of good internal fixation. However, with increased understanding of the importance of soft tissues, the biomechanics of fixation, and how fractures heal, they have undergone certain conceptual changes to become the overall principles of fracture management and not just internal fixation [6].

Central to the AO concept was the understanding that articular fractures and diaphyseal fractures have different biological requirements and the recognition that the type and timing of surgical intervention must be guided by the degree of injury to the soft-tissue envelope as well as the physiological demands of the patient.

5 Progress and development

The AO principles relating to anatomy, stability, biology, and mobilization still stand as fundamentals. However, it is now accepted that the pursuit of absolute stability, originally proposed for almost all fractures, is mandatory only for joint and certain related fractures, provided it can be obtained without damage to the blood supply and soft tissues. Within the diaphysis, length, alignment, and rotation must be restored but anatomical reduction is not necessary (**Fig 1.1-8**). When fixation is required, nails and bridge plates are often used to provide relative stability and this usually leads to union by callus. Even when the clinical situation favors the use of a plate, proper planning and meticulous surgical technique should minimize any insult to the blood supply of bone fragments and soft tissues. Minimal access surgery has taken this a step further.

It is now appreciated that simple diaphyseal fractures react differently to plating and to nailing: if plating is used, absolute stability must be achieved. In contrast, multifragmentary fractures can be treated with relative stability, either with an intramedullary nail, external fixator, or bridge plate. Articular fractures demand anatomical reduction and absolute stability to enhance the healing of articular cartilage and make early motion possible (**Fig 1.1-9**). The principle of the internal fixator, which was introduced by Stephan Perren and Slobodan Tepic with the PC-Fix in 1985, has now evolved to the locking compression plate (LCP). The use of locking head screws, providing angular stability and preventing the plate from being pressed against the bone surface, has changed the concept of plating but must be applied using the same AO principles.

Fig 1.1-6 Early AO course (1960) with Maurice Müller instructing.

Fig 1.1-7 First AO operating room personnel course (1960).

Good soft-tissue care is always essential. This preserves the blood supply to the bone and must be addressed in every phase of fracture management. A thorough assessment of the fracture pattern and related soft-tissue injuries will lead to the formulation of a preoperative plan, including the surgical approach, reduction technique (direct or indirect), the type of fixation, and the choice of implant, compatible with the biological and functional demands of the fracture and the patient.

6 AO philosophy and principles: today and in future

In earlier days, the AO principles appeared in a succinct, even dogmatic format with the goal of improving functional outcome. Fracture care has become a structured process based upon good science, sound technology, and supported by research and clinical studies [7]. With this foundation, the future of trauma care is promising. Locking plates and the internal fixator principle have helped improve fracture

Fig 1.1-8a–d
a–b Complex, high-energy subtrochanteric fracture while skiing.
c–d Fixation at 1 year shows a bridging plate of a subtrochanteric fracture providing relative stability and healing with callus. Length, alignment, and rotation along with normal clinical function were restored.

care. Computer-aided navigation may revolutionize trauma surgery, increase accuracy and safety, and lead to further expansion of minimal access surgery. Biotechnology will allow surgeons to influence fracture healing, perhaps reducing the time to union and preventing nonunion due to "biological failure". However, even with these advances, the AO principles remain as valid today as they were nearly 60 years ago when the AO group was formed. These principles form the basis of this textbook and will remain the key principles of worldwide fracture care for the foreseeable future.

The AO principles:

- Fracture reduction and fixation to restore anatomical relationships
- Fracture fixation providing absolute or relative stability as the personality of the fracture, the patient, and the injury requires
- Preservation of the blood supply to soft tissues and bone by gentle reduction techniques and careful handling
- Early and safe mobilization and rehabilitation of the injured part and the patient as a whole

Fig 1.1-9a–c

a AP view of a displaced intraarticular distal femoral fracture.

b Oblique view of the same fracture.

c At 2 months healing shows no callus, as the lag screws provide absolute stability for the joint and the plate protects the perfect articular reduction.

Classic references **Review references**

7 References

1. **Lambotte A.** *Chirurgie Opératoire des Fractures*. Paris: Masson; 1913. French.
2. **Böhler L.** *Technik der Knochenbruchbehandlung*. Wien: W Maudrich; 1957. German.
3. **Lucas-Championnière J.** Les dangers de l'immobilisation des membres—fragilité des os—altérnation de la nutrition de la membre—conclusions pratiques. *Rev Med Chur Pratique*. 1907;78:81–87. French.
4. **Danis R**. *Théorie et Pratique de L'Ostéosynthèse*. Paris: Masson; 1947. French
5. **Müller ME, Allgöwer M, Willenegger H.** *Technique of Internal Fixation of Fractures*. Berlin Heidelberg New York: Springer-Verlag; 1965.
6. **Müller ME, Allgöwer M, Schneider R, Willenegger H.** *Manual of Internal Fixation, 2nd ed*. Berlin Heidelberg New York: Springer-Verlag; 1979.
7. **Schlich T**. *Surgery, Science and Industry: A Revolution in Fracture Care, 1950s–1990s*. Hampshire New York: Palgrave Macmillan; 2002.

8 Acknowledgments

We thank Joseph Schatzker and Thomas Rüedi for their contributions to this chapter in the first and second editions of the *AO Principles of Fracture Management*.

1.2 Biology and biomechanics in bone healing

Boyko Gueorguiev-Rüegg, Martin Stoddart

1 Introduction

The biological and biomechanical basis of fracture management is covered in this chapter. We review how fractured bone behaves in different biological and mechanical environments, and how this influences the choice and method of treatment by the surgeon. Any surgical procedure may alter the biological environment and every fracture fixation alters the mechanical environment. These changes may have a profound effect on fracture healing and are determined by the surgeon, not the patient. Thus, it is essential that all trauma surgeons have a basic knowledge of the biology and biomechanics of fracture healing so they can make wise decisions in fracture management. This chapter offers a review for the active clinician rather than a pure scientific analysis. It describes the healing process in healthy populations with no discussion of impaired healing in conditions, such as diabetes. Despite worldwide research, much still remains unknown or controversial in this rapidly changing scientific field.

Our understanding of fracture treatment and healing has seen an important change in recent decades with the evolution of the AO principles [1, 2]. During the early phase of the development of these principles, the primary goal of surgical treatment was to provide the fracture with a motionless environment. High priority was given to precise fracture reduction and fixation with absolute stability with over emphasis on mechanical stability at the expense of biology. However, fracture treatment has evolved with recognition that both mechanics and biology are important. Precise reduction and absolute stable fixation is not required in every case and may come at a biological price. Indirect reduction takes advantage of the soft tissues and the blood supply to the bone fragments, which will come into alignment when traction is applied to the main fragments. This reduces surgical trauma and helps to keep the bone alive. Bone has evolved to heal with some movement between fragments and without each fragment being in contact. The concept of relative stability allows the surgeon to control the movement to allow healing while maintaining fracture reduction that will allow early rehabilitation and a good functional outcome for the patient. A more flexible fixation should encourage the formation of callus and indirect reduction will reduce operative trauma.

The main goal of fracture fixation is to achieve prompt and, if possible, full function of the injured limb. Although reliable fracture healing is only one element in functional recovery, it is essential for a good outcome. Fracture fixation is always a compromise that balances biology and biomechanics. It is often necessary to sacrifice some strength and stiffness of fixation, and the optimal implant is not necessarily the strongest or the stiffest available.

> It is not the purpose of osteosynthesis to permanently replace a fractured bone but to provide temporary support, allowing early functional rehabilitation with healing in an appropriate anatomical position.

Under extreme conditions, the mechanical requirements may gain precedence over biological demands and vice versa. Similarly, the choice of implant material is a trade-off, eg, the mechanical strength and ductility of steel versus the electrochemical and biological inertness of titanium. The surgeon decides which combination of technology and procedure best fits his experience, environment, and, in particular, the demands of the patient.

2 Characteristics of the patient

When considering the personality of a fracture, the first critical element is the characteristics of the patient (see chapter 2.1). Clinical decisions must always take into account the patient's age, expectations, comorbidities, and psychosocial factors. Inherent biological deficits may need to be overcome, or expectations must be lowered when a favorable outcome is less likely. No decision can be made solely on the basis of radiological evaluation.

3 Characteristics of bone

Bone is a scaffold that supports and protects soft structures and enables locomotion and mechanical functioning of the limbs.

The most important mechanical characteristics of bone are its stiffness (bone deforms only a little under load) and strength (bone tolerates high load without failure).

In considering a fracture and fracture healing, the brittleness of bone is of special interest. Bone is a strong material. However, it breaks under small deformation. This means that bone behaves more like glass than like rubber. Therefore, at the onset of natural fracture healing, bone cannot bridge a fracture gap that is repeatedly subject to excessive displacement. For an unstable or flexibly fixed fracture (relative stability), a sequence of biological events—mainly the formation of first a soft and then a hard callus—helps to reduce the strain and deformation of the repair tissues and thus increase stability (see section 4.3.3 in this chapter). Resorption at the fracture ends initially increases the fracture gap and this reduces the strain at the fracture site. The lower-strain environment promotes formation of bridging callus, which then increases the mechanical stability of the fracture. Once the fracture is solidly bridged, full bone function is restored. Internal remodeling then restores the original bone structure, a process that can take years (see chapter 5.2).

Video 1.2-1 Implosion of a bone during fracture.

4 Fracture of bone

A fracture is always the result of single or repetitive overload. The fracture occurs within a fraction of a millisecond. It results in predictable damage to soft tissues due to rupture and an implosion-like process. Rapid separation of fracture surfaces creates a void (cavitation) and results in severe soft-tissue damage (**Video 1.2-1**).

4.1 Mechanical and biochemical effects

A fracture produces a loss of bone continuity that results in pathological deformation, loss of the support function of bone, and pain. Surgical stabilization may restore function immediately and alleviate pain. Thus, the patient regains pain-free mobility allowing early rehabilitation and reducing the risk of conditions like complex regional pain syndrome (see chapter 4.7).

Fracture of bone ruptures the blood vessels within bone and periosteum. Spontaneously released biochemical factors help to induce bone healing. In fresh fractures these agents are effective and scarcely need any boost. The role of surgery should be to guide and support this healing process.

4.2 Fracture and blood supply

Although a fracture is a purely mechanical process, it triggers biological reactions, such as bone (callus) formation and bone resorption. These two processes depend on an intact blood supply. The following factors influence blood supply at the fracture site and have an immediate bearing on the surgical procedure:

- **Mechanism of injury:** The amount, direction, and concentration of forces at the fracture site will determine the fracture type and associated soft-tissue injuries. As a result of the displacement of fragments, periosteal and endosteal blood vessels rupture and the periosteum is stripped. Cavitation and implosion of the fracture cause additional soft-tissue damage.
- **Initial patient management:** If rescue and transportation take place without splinting of fractures, motion at the fracture site will add to the initial damage.
- **Patient resuscitation:** Hypovolemia, hypoxia, and coagulopathy will increase damage to injured bone and soft tissues, and must be corrected early in patient management.
- **Comorbidities:** Such as peripheral vascular disease and diabetes.

- **Surgical approach:** Surgical exposure of the fracture will invariably result in additional damage [3]. This can be minimized by a thorough knowledge of anatomy, careful preoperative planning, and meticulous surgical technique.
- **Implant:** Considerable damage to bone circulation may result not only from the surgical trauma but also from the contact between implant and bone [4]. Plates with a flat undersurface (eg, DCP) have a large area of contact; the LC-DCP, which is undercut, was designed to reduce this contact area [5]. However, the extent of the contact also depends upon the relationship of the radii of transverse curvature of the plate and the bone. When the radius of curvature of the undersurface of the plate is larger than that of the bone, bone-plate contact may be in a single longitudinal line, which reduces the advantages of the LC-DCP (and also the locking compression plate [LCP] when used as compression plate) compared with the flat undersurface of the DCP (**Fig 1.2-1a**). If the situation is reversed and the plate has a smaller radius of transverse curvature than the bone, there will be longitudinal contact at both edges (two-line contact), and the lateral undercuts of the LC-DCP and LCP (when used as compression plate) will significantly reduce the area of contact (**Fig 1.2-1b–d**).
- **Consequences of trauma:** Elevated intraarticular pressure reduces the epiphyseal bone circulation, especially in young patients. The increase in hydraulic pressure (produced by an intracapsular hematoma) has been shown to reduce blood supply to the epiphyseal bone when the growth plate is still open.

Dead bone can only be revitalized by removal and replacement (creeping substitution through osteonal or lamellar remodeling), a process that takes a long time to complete. It is generally accepted that necrotic tissue (especially bone) predisposes to infection and sustains it (see chapter 5.3). Another effect of necrosis is the induction of internal (Haversian) remodeling. This allows replacement of dead osteocytes but results in temporary weakening of the bone due to transient porosis, which is an integral part of the remodeling process. This is often seen immediately beneath plates and can be lessened by reducing the contact area of the plate (eg, LC-DCP and LCP), which fosters the periosteal blood supply and reduces the volume of avascular bone.

An immediate reduction of bone blood flow has been observed after fracture or osteotomy, with the cortical circulation in the injured parts of the bone being reduced by nearly 50% [6]. This reduction has been attributed to a physiological vasoconstriction in both the periosteal and the medullary vessels as a response to trauma [7]. During repair of a fracture, however, there is increasing hyperemia in the adjacent intraosseus and extraosseus circulation, reaching a peak after 2 weeks. Thereafter, blood flow in the callus area gradually decreases again. There is also a temporary reversal of the normal centripetal blood flow after disruption of the medullary system.

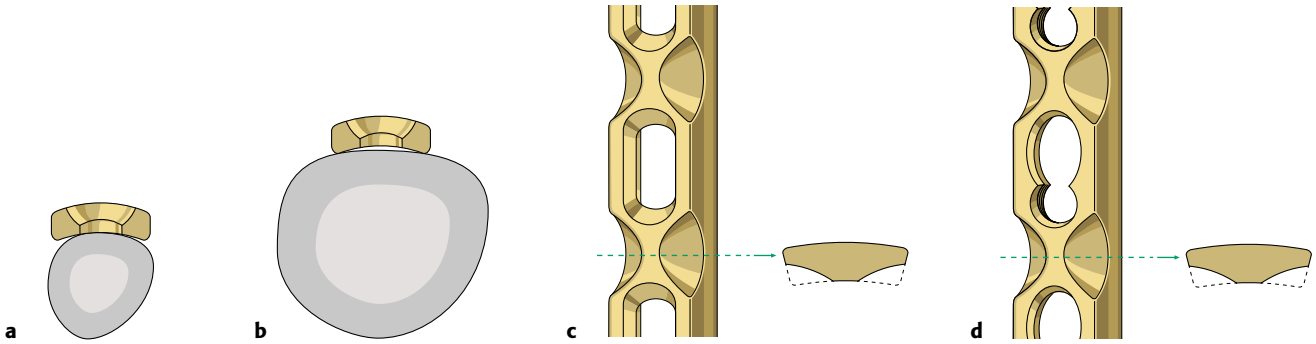

Fig 1.2-1a–d Area of contact under the plate.
a If the radius of transverse curvature of the undersurface of the plate is greater than that of the bone, a single longitudinal line of contact will result. In this situation, the DCP, LC-DCP and LCP (used as compresson plate) will have similar areas of contact.
b If the radius of transverse curvature of the undersurface of the plate is smaller than that of the bone, the plate will have longitudinal contact at both edges, producing a double-line contact.
c–d With contact only at the edge of the plate, the undercut undersurface of the LC-DCP (**c**) and LCP (**d**) reduces the area of contact.

Microangiographic studies [8, 9] have demonstrated that much of the vascular supply to the callus area is derived from the surrounding soft tissues (**Fig 1.2-2**), a good reason not to strip any soft tissues.

Perfusion of callus is of utmost importance and may determine the outcome of healing. Bone can only form when supported by a vascular network and cartilage will not persist in the absence of sufficient perfusion. However, this angiogenic response depends upon both the method of treatment and the induced mechanical conditions:

- The vascular response appears to be greater after more flexible fixation, perhaps due to a larger volume of callus.
- High strain in tissue, caused by excessive instability, reduces the blood supply, especially in the fracture gap.
- The operative procedure during internal fixation of fractures alters the hematoma and soft-tissue blood supply. Following intramedullary reaming, endosteal blood flow is reduced but there is a rapid hyperemic response if reaming has not been excessive.
- Reaming for intramedullary nails results in a delayed return of cortical perfusion, depending on the extent of reaming [10]. Reaming does not affect perfusion within the fracture callus, as blood supply to the callus is mostly from the surrounding soft tissues [11].
- In addition to the wider exposure of the bone, larger bone-implant contact will result in a reduction of bone perfusion, as bone receives its blood supply through the periosteal and endosteal lining.
- Damage to the blood supply is minimized by avoiding direct fragment manipulation, minimally invasive surgery, and the use of external or internal fixators [12, 13].

4.3 Biology of fracture healing

Fracture healing can be divided into two types:

- Primary or direct healing by internal remodeling
- Secondary or indirect healing by callus formation

Direct (primary) bone healing occurs only with absolute stability and is a biological process of osteonal bone remodeling. Note that primary bone healing was not the goal when the technique of absolute stability was developed by Danis: the aim was anatomical reduction and stable fixation to allow early rehabilitation. Primary bone healing was observed as a by-product of this method of fracture fixation. Indirect (secondary) bone healing occurs with relative stability (flexible fixation methods) and is the normal way that broken bones have evolved to heal. It is similar to the process of embryological bone development and includes both intramembranous and endochondral bone formation. In diaphyseal fractures, it is characterized by the formation of callus.

Indirect (secondary) bone healing can be divided into four stages:

- Inflammation
- Soft callus formation
- Hard callus formation
- Remodeling

Although the stages have distinct characteristics, there is a seamless transition from one stage to another; they are determined arbitrarily and have been described with some variation.

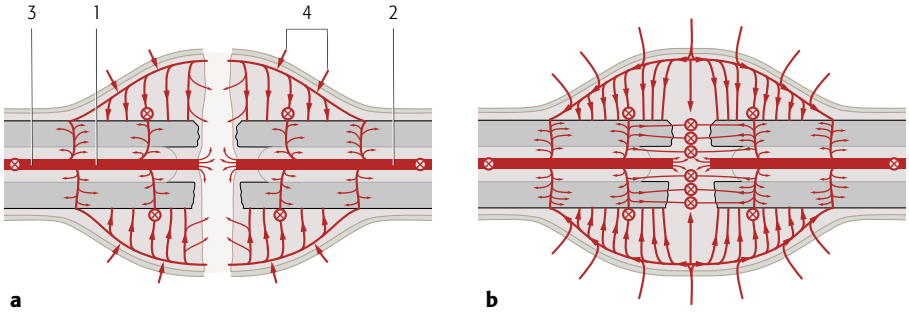

Fig 1.2-2a–b The blood supply of callus.
a Before bony bridging:
1 Nutrient artery ascending.
2 Nutrient artery descending.
3 Metaphyseal arteries.
4 Periosteal arteries.
b After bony bridging.

4.3.1 Inflammation

After fracture, the inflammatory process starts immediately and lasts until fibrosis, cartilage, or bone formation begins (1–7 days after fracture). Initially, there is hematoma formation and inflammatory exudation from ruptured blood vessels (**Fig 1.2-3a**). Bone necrosis is seen at the ends of the fracture fragments. Injury to the soft tissues and degranulation of platelets results in the release of powerful cytokines that produce a typical inflammatory response, ie, vasodilatation and hyperemia, migration and proliferation of polymorphonuclear neutrophils, macrophages, etc. Within the hematoma, there is a network of fibrin and reticulin fibrils; collagen fibrils are also present. The fracture hematoma is gradually replaced by granulation tissue. Osteoclasts in this environment remove necrotic bone at the fragment ends.

4.3.2 Soft callus formation

Eventually, pain and swelling decrease and soft callus is formed (**Fig 1.2-3b**). This corresponds roughly to the time when the fragments are no longer moving freely, approximately 2–3 weeks after fracture.

At the end of soft callus formation, stability is adequate to prevent shortening, although angulation at the fracture site may still occur.

The soft callus stage is characterized by the growth of callus. The progenitor cells in the cambial layer of the periosteum and endosteum are stimulated to become osteoblasts. Intramembranous, appositional bone growth starts on these surfaces away from the fracture gap, forming a cuff of woven bone periosteally, and filling the intramedullary canal. Ingrowth of capillaries into the callus and increased vascularity follows. Closer to the fracture gap, mesenchymal progenitor cells proliferate and migrate through the callus, differentiating into fibroblasts or chondrocytes, each producing their characteristic extracellular matrix and slowly replacing the hematoma [14].

4.3.3 Hard callus formation

When the fracture ends are linked together by soft callus, the hard callus stage starts (**Fig 1.2-3c–e**) and lasts until the fragments are firmly united by new bone (3–4 months). As intramembranous bone formation continues, the soft tissue within the gap undergoes endochondral ossification and the callus is converted into rigid calcified tissue (woven bone). Bone callus growth begins at the periphery of the fracture site, where the strain is lowest. The production of this bone reduces the strain more centrally, which in turn forms bony callus. Thus, hard callus formation starts peripherally and progressively moves toward the center of the fracture and the fracture gap. As the fracture gaps narrows, the strain increases and the final gap is bridged by osteoblasts that line up in a spiral formation, like a spring, to reduce strain and allow bone formation. The initial bony bridge is formed where strain is lowest at the periphery of the callus or within the medullary canal, away from the original cortex. Then, by endochondral ossification, the soft tissue in the gap is replaced by woven bone that eventually joins the original cortex.

4.3.4 Remodeling

The remodeling stage (**Fig 1.2-3f**) begins once the fracture has solidly united with woven bone. The woven bone is slowly replaced by lamellar bone through surface erosion and osteonal remodeling. This process may take anything from a few months to several years. It lasts until the bone has completely returned to its original morphology, including restoration of the medullary canal.

4.3.5 Growth factors

The sequence of events during bone healing is tightly regulated by spacial and temporal expression of a number of growth factors and biochemical agents that are released by the injured tissue. Since their discovery in the 1960s by Marshall Urist, bone morphogenetic proteins (BMPs) have been shown to be potent inducers of bone formation [15]. Bone morphogenetic proteins are members of the transforming growth factor-beta superfamily; there are about 20 mammalian BMPs known to date. These factors offer the potential for the enhancement of fracture repair or reconstruction of bone defects. In clinical practice, BMP-2 is the most frequently used, although it is estimated that up to 85% of use is off-label. Bone morphogenetic protein-2 is indicated for spinal fusion procedures in skeletally mature patients with degenerative disc disease (DDD) at one level from L2-S1, in combination with a spinal fixation device. In 2004, the US Food and Drug Administration (FDA) approved BMP-2 for treating open tibial shaft fractures and in 2007, BMP-2 was approved by the FDA for sinus lift and local ridge augmentation. The recombinant protein is often applied in combination with a collagen scaffold.

While BMPs may lead to robust bone formation, it is crucial to be aware of the numerous potential adverse effects, such as ectopic bone formation, and these factors should be used with caution.

4.3.6 Differences in healing between cortical and cancellous bone

As opposed to indirect healing in cortical bone, healing in cancellous bone occurs without the formation of significant external callus. After the inflammatory stage, bone formation is dominated by intramembranous ossification. This has been attributed to the tremendous angiogenic potential of trabecular bone as well as the fixation used for metaphyseal fractures, which is often more stable. In unusual cases with substantial interfragmentary motion, intermediary soft tissue may form in the gap but this is usually fibrous tissue that is soon replaced by bone.

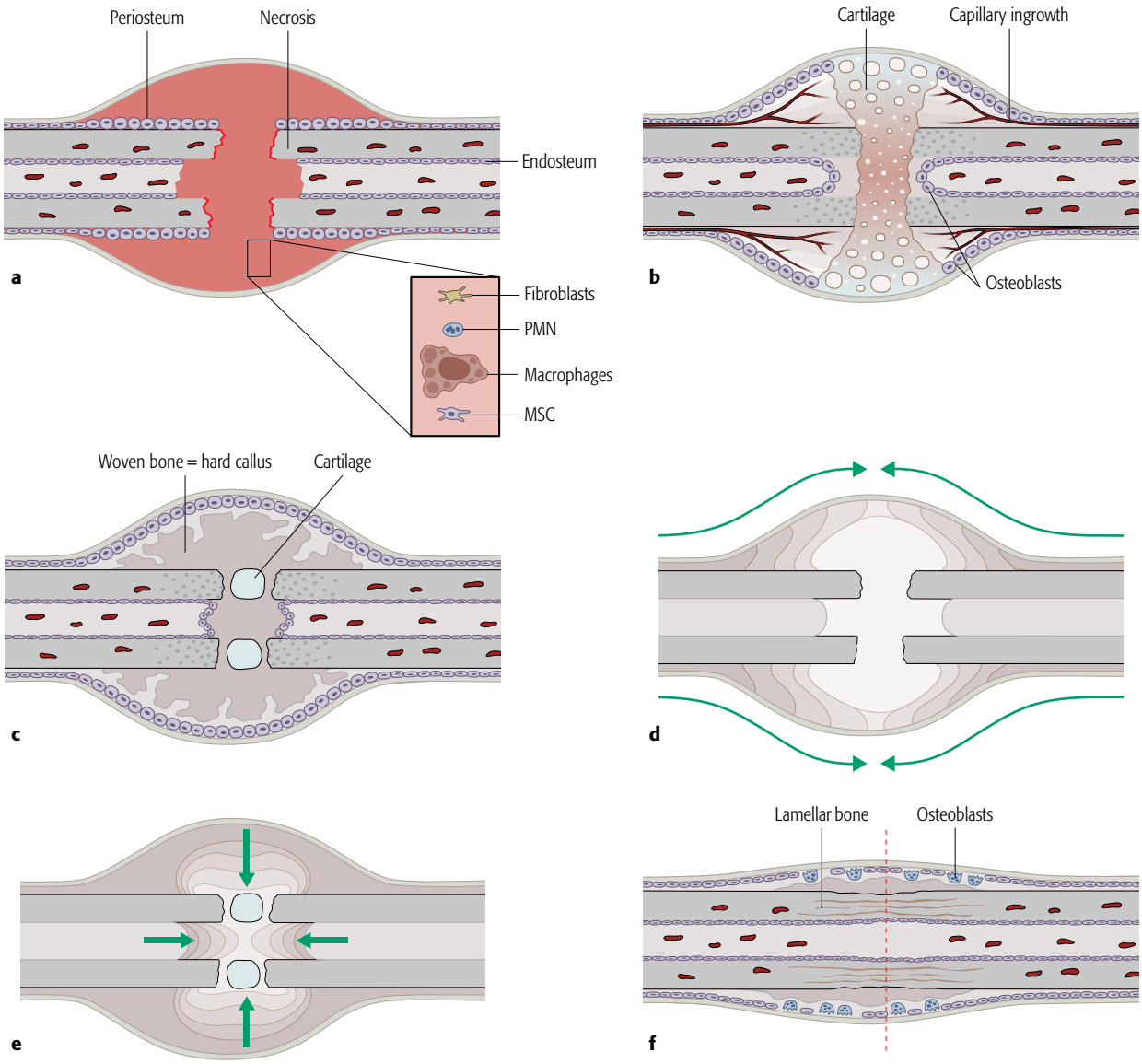

Fig 1.2-3a–f Stages of secondary bone healing.
a The inflammation stage. Formation of hematoma resolving into granulation tissue with the typical inflammatory cascade.
b The soft callus stage. Intramembraneous ossification forming bone cuffs away from the fracture gap. Replacement of the granulation tissue elsewhere in the callus by fibrous tissue and cartilage, and ingrowth of vessels into the calcified callus. This starts at the periphery and moves toward the center.
c–e The hard callus stage. Complete conversion of callus into calcified tissue through intramembranous and endochondral ossification.
f The remodeling stage. Conversion of woven bone into lamellar bone through surface erosion and osteonal remodeling.

5 Biomechanics and bone healing

5.1 Methods of fracture stabilization

The term stability is widely used by surgeons. Its meaning differs from that used in engineering. The surgeon uses the word stability to express the degree of displacement at the fracture site induced by load.

A stable fracture is defined as a fracture that does not visibly displace under physiological load. Fracture fixation with absolute stability means that there is no motion at the fracture site under physiological load. The degree of stability determines the type of fracture healing.

Fracture of a bone often produces an unstable situation. Obvious exceptions are impaction fractures of the metaphysis, undisplaced fractures with intact periosteum, abduction fractures of the proximal end of the femoral neck, and greenstick fractures. These fractures do not require reduction, and stabilization is only required if the fracture will deform under physiological load, ie, the fracture is unstable.

The aim of fracture stabilization is to:

- Maintain the achieved reduction
- Restore stiffness at the fracture site (thus allowing function)
- Minimize pain related to movement at the fracture site

Fig 1.2-4a–b Spontaneous healing of a femoral fracture of a Vietnam war victim.
a AP x-ray.
b Lateral x-ray.

Fixation with absolute stability aims to provide a mechanically neutral environment for fracture healing, ie, no motion at the fracture site. However, this also reduces the mechanical stimulus for repair by callus formation and so healing occurs by remodeling (primary bone healing).

Fixation with relative stability aims to maintain the reduction and still keep the mechanical stimulation for fracture repair by callus formation.

The prerequisite for successful relative stabilization is that the displacement occurring under load is elastic, ie, reversible and not permanent. Fracture healing by callus formation can take place within a wide spectrum of mechanical environments. If titanium elastic nails are compared with bridge plating using a locked plate, there is a large difference in the degree of micromotion at the fracture site. However, both will result in callus formation and fracture healing, if correctly applied.

At either end of the spectrum of relative stability, fracture healing will be delayed. Callus will not form if there is no motion but if there is extensive movement and the fracture fixation is unstable, healing will also be delayed.

5.2 Nonoperative fracture management

5.2.1 Fracture healing without treatment

Without treatment, nature stabilizes mobile fragments by pain-induced contraction of the surrounding muscles, which may lead to shortening and malunion. At the same time, hematoma and swelling temporarily increase the tissue turgor and have a slight stabilizing effect. Observations made on bone healing without any treatment help to understand the positive and negative effects of medical intervention. It is surprising how initial mobility is compatible with solid bone healing (**Fig 1.2-4**). In such cases, the residual problem is lack of alignment and impairment of function.

5.2.2 Nonoperative treatment of fractures

Nonoperative management requires closed reduction to restore alignment and rotation. Subsequent treatment maintains reduction and reduces mobility of the fragments while indirect healing occurs by callus formation. In nonoperative treatment, stabilization is achieved by the following means:

Traction: This can be supplied via the skin or a metal pin inserted into the bone distal to the fracture (skeletal traction). Traction (**Fig 1.2-5**) along the long axis of the bone aligns the bone fragments by ligamentotaxis, and reduces motion, providing some stability.

External splinting: Application of externally applied splints made of wood, plastic, or plaster results in a certain amount of fracture stabilization. The splint dimensions are the most important mechanical aspect. Circular external splints are stiff and strong, based on their curved geometry. However, fixation with external splints is inherently unstable because of poor coupling to bone caused by the interposed soft tissue. Externally applied splints maintain reduction by achieving a three-point contact.

A curved plaster cast produces a straight bone. A straight plaster cast produces a bent bone.

The hydrostatic pressure of the surrounding tissues reduces movement of the fragments. In diaphyseal fractures, correct fragment length, alignment, and rotation are all that is needed for proper function of the limb. For intraarticular fractures, precise anatomical reduction is important to avoid joint incongruity or instability, which may lead to secondary arthrosis (see chapter 2.3).

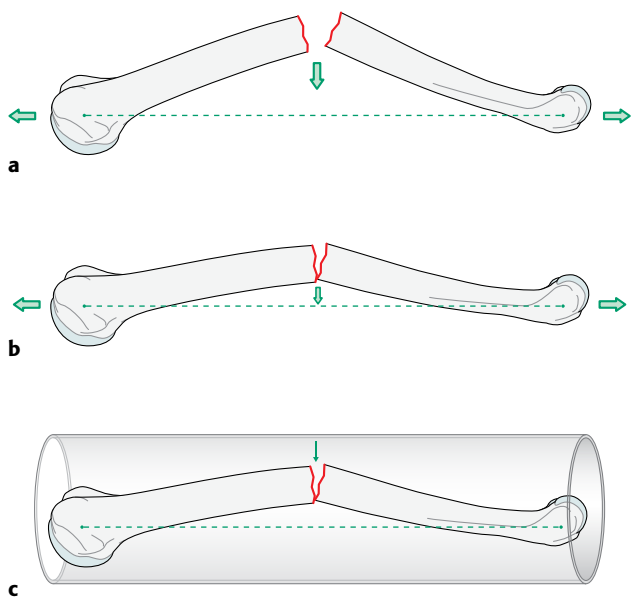

Fig 1.2-5a–c Fracture reduction and stabilization by means of traction.
a–b The force reducing the fracture perpendicularly to the long axis decreases with alignment. Thus, gross mobility is reduced, while micromotion persists.
c Stabilization of a fracture using a plaster cast. The plaster cast acts like a splint and the pressure of the soft tissues maintains alignment. This reduces mobility but does not eliminate it. The cast represents a stiff splint. Mobility occurs because the plaster cast can only be loosely coupled to the bone by soft tissues. If the plaster is too tight, compartment syndrome will occur.

5.3 Surgical fixation with relative stability

5.3.1 Mechanics of techniques of relative stability

With relative stability, the bone fragments displace in relation to each other when physiological load is applied across the fracture. Displacement increases with the applied load and decreases with the rigidity of the fixation device. There is no exact definition of the required or tolerated flexibility. In general, a fixation method is considered flexible if it allows controlled interfragmentary movement under physiological load. Therefore, all fixation methods with the exception of compression techniques may be seen as flexible fixations that provide relative stability.

5.3.2 Implants

Devices such as external fixators, intramedullary nails, or plates provide relative stability. The degree of flexibility can vary and this is determined by how the surgeon applies the device and how it is loaded. All these devices allow interfragmentary movement, which can stimulate callus formation. However, incorrect application of the device can result in excessive movement and inhibit bone union or too little movement, which will also inhibit bone union.

External fixators

External fixators usually provide relative stability, although some ring fixators can be used to apply compression and absolute stability. Unilateral external fixators are eccentrically located and exhibit asymmetrical mechanical behavior. They are stiffer when loaded in the plane of the Schanz screws than in the plane perpendicular to them. Ring fixators display almost uniform behavior in all planes, so that displacement of the bone fragments in relation to each other is mainly axial.

The stiffness of fracture stabilization by external fixation depends on a number of factors:

- Type of implants used, eg, Schanz screws and bars
- Geometrical arrangements of these elements in relation to each other and the bone, ie, uniplanar, biplanar, or circular fixators
- Coupling of the implant to the bone, eg, Schanz screws; tensioned fine wires

The most important factors influencing the stability of fixation are:

- Stiffness of the connecting rods
- Distance between the rods and the bone axis; the stiffer the rod and the closer it is to the bone axis, the more stable the fixation
- Number, spacing, and diameter of the Schanz screws or of the wires and their pretension

The interfragmentary movement of a fracture with a unilateral external fixator under load is a combination of axial, bending, and shearing displacement. A double-tube arrangement under partial loading of 200–400 N results in interfragmentary movement of several millimeters and stimulates callus formation. The external fixator is the only system that allows the surgeon to control flexibility of the fixation by adjusting the implant without additional surgery. This technique, termed dynamization, may be used to modify the loading of the fracture as healing progresses. This can be done by extending the distance between the rods and the bone, or by reducing the number of rods. In addition, some types of external fixators allow axial telescoping to stimulate the healing process.

Intramedullary nails

The classic Küntscher nail achieves good stability against bending moments and shear forces perpendicular to its long axis but is rather unstable when torque is applied and is unable to prevent axial shortening. The torsional stiffness of slotted nails is low and the torsional and axial coupling between the intramedullary nail and the bone is loose. Therefore, in the past, the effective application of this design of intramedullary nail was confined to simple transverse or short oblique fractures, which cannot shorten and will interdigitate to prevent rotation. The advantage of the Küntscher nail is that its flexibility promotes callus formation.

The introduction of locked intramedullary nails and solid or cannulated nails has overcome many of these restrictions. Locked nails withstand torsional moments and axial loading better [16]. The stability under such loads is dependent on the diameter of the nail, its geometry and the number of interlocking screws and their spatial arrangement. The bending flexibility depends on the fit of the nail within the medullary canal, the extent of the fracture and the distance between the proximal and distal locking screws.

The only drawback of locked intramedullary nails is the nonlinear stiffness of the bone-nail construction. The locking holes are larger than the diameter of the interlocking screws to facilitate insertion. This allows some motion at the coupling even at low loads. It may be decreased by insertion of further interlocking screws or by the use of angle-stable locking systems, such as the expert tibial nail.

Bridging fractures with a locking plate—internal fixator

Locking plates with locking head screws placed on both sides of a multifragmentary fracture span the fracture in the manner of an external fixator to provide elastic splinting. The stiffness of such an internal fixation method depends on the dimensions of the implant, the number and position of the screws, the quality of the coupling between the screw and the plate, and the coupling between the screw and the bone. This will be influenced by plate design, the type of bone and the degree of osteoporosis. The mechanics of this type of fixation is discussed in detail in the chapters on bridge plating (see chapter 3.3.2) and locking plates (see chapter 3.3.4).

Plating with relative stability should only be applied in multifragmentary fractures and must not be used for simple fracture patterns, as there is a high incidence of delayed union or nonunion because a high-strain environment is created at the fracture site. If simple fractures are plated, a technique providing absolute stability must be used.

5.3.3 Mechanobiology of indirect or secondary fracture healing

Interfragmentary movement stimulates the formation of callus and is part of the normal healing process [17, 18]. As the callus matures, it becomes stiffer and reduces the interfragmentary movement to a low level that allows bridging by hard bony callus (**Fig 1.2-6**). In the early stage of healing, when mainly soft tissue is present in the fracture gap, the fracture tolerates a greater deformation or higher tissue strain than in a later stage when the callus contains mainly calci-

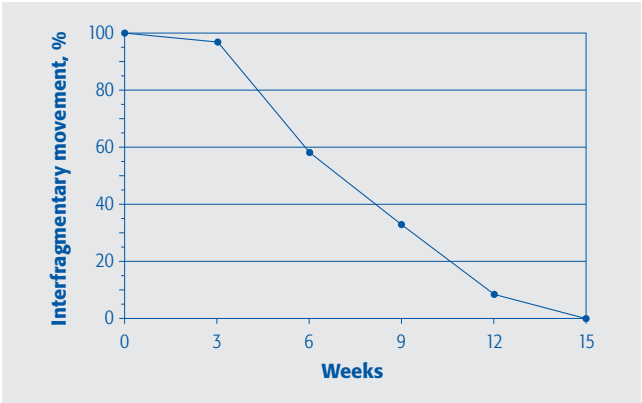

Fig 1.2-6 Typical course of interfragmentary movement monitored for human tibial shaft fractures. The initial postoperative interfragmentary movements under 300 N axial load (normalized to 100% at the outset) decrease with the passage of time. After about 13 weeks, healing by callus has stabilized the fracture.

fied tissue. The manner in which mechanical factors influence fracture healing is explained by Perren's strain theory (**Fig/Animation 1.2-7**). Strain is the relative deformation of a material (eg, granulation tissue within a gap) when a given force is applied. Normal strain is expressed as the ratio of change in length (Δ l) to original length (l) when a given load is applied, ie, Δ l/l. Stain has no dimensions and is often expressed as a percentage. The amount of deformation that a tissue can tolerate and still function is called the strain tolerance and varies greatly. Intact bone has a normal strain tolerance of 2% (before it fractures), whereas granulation tissue has a strain tolerance of 100%. Bony bridging between the distal and proximal callus can only occur when local strain is less than the woven bone forming in the gap can tolerate. As a fracture heals, and the fracture gap narrows, the strain within the fracture gap increases. Hard callus will not bridge a fracture gap when strain between the fracture ends is too great (ie, above the strain tolerance of woven bone) [19] and this will prevent fracture healing and result in nonunion. Nature deals with this problem by expanding the volume of soft callus. This results in a decrease in the local tissue strain at the periphery of the callus to a level that allows bony bridging. Bone then bridges across the fracture gap at the periphery of the callus and fracture healing proceeds from the periphery toward the center as the strain progressively decreases. Nature has a further, elegant way of decreasing the strain in a narrow fracture gap. Rather than lining up directly across the fracture gap, the osteons form in spirals, like a spring, which grow across the fracture gap and produce a lower strain environment to allow bone bridging [18] (**Fig 1.2-8**). A consequence of this type of healing is that overloading of a fracture with a narrow gap (and high strain) later in the healing process is not well tolerated [20, 21].

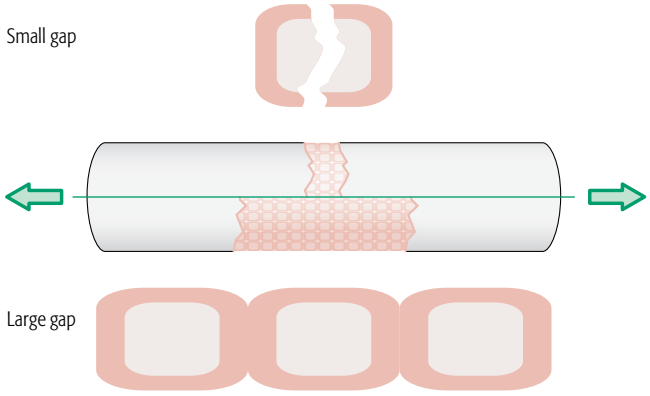

Fig/Animation 1.2-7 Perren`s strain theory.

At the cellular level, where the fundamental process of bone regeneration and tissue differentiation occurs, the situation is more complex. The biomechanical conditions, such as strain and fluid pressure, have an inhomogeneous distribution within the callus. The mechanoregulation of callus cells is a feedback loop in which the signals are created by the applied load and modulated by the callus tissue. Mechanical loading of the callus tissue produces local biophysical stimuli that are sensed by the cells. This may regulate cell phenotype, proliferation, apoptosis, and metabolic activities by induction of growth factor production by the cells receiving the loading signals. With alteration of the extracellular matrix, and the associated changes in tissue properties, the biophysical stimuli caused by mechanical loading are modulated, producing different biophysical signals even under the same loading. In normal fracture healing this feedback

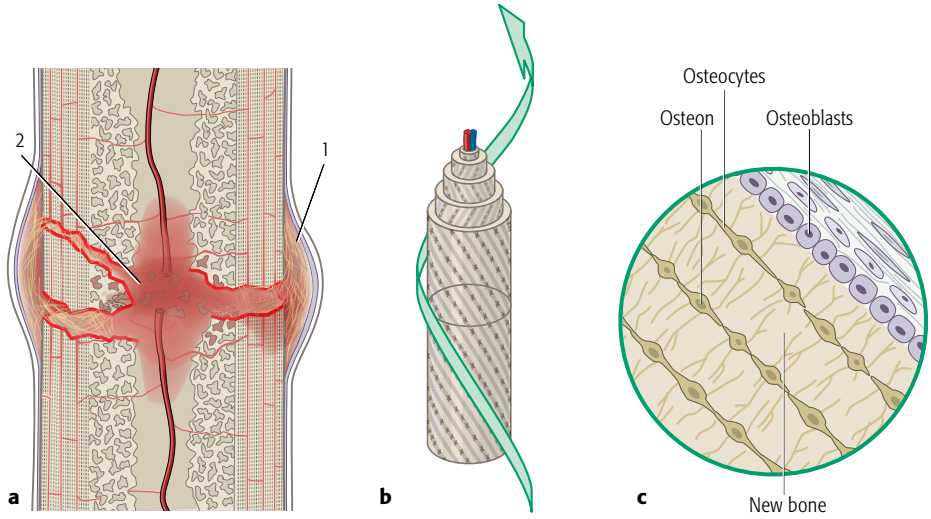

Fig 1.2-8a–c Rather than line up directly across the fracture gap, osteones form a spiral around the periphery of the callus and, like a spring, this reduces strain and allows ossification.
1 Hard callus at the periphery with intramembranous bone formation.
2 Soft callus centrally with endochondral ossification.

process reaches a steady state when the callus has ossified and the original cortex has regenerated, allowing normal autoregulation and bone turnover. The biophysical signals themselves and the way they interact to produce the biological response are still being investigated. Several mechanoregulation algorithms have been postulated and have been shown to be consistent with some aspects of fracture healing, but they require further colloboration. Transduction of these stimuli into intracellular and extracellular messenger systems are being investigated; so both physical and molecular methods of treatment may be developed to treat delayed union and nonunion.

When fractures are splinted, movement of the fragments in relation to each other depends on:

- Amount and direction of external loading
- Stiffness of the splints
- Stiffness of the tissues bridging the fracture

Multifragmentary fractures tolerate more motion between the two main fragments because the overall movement is shared by several fracture planes and this reduces the tissue strain or relative deformation at the fracture gap (**Video 1.2-2**). Today, there is clinical experience and experimental proof that flexible fixation can stimulate callus formation, thereby accelerating fracture healing **[17]**. This can be observed in diaphyseal fractures splinted by intramedullary nails, external fixators, or bridging plates.

Video 1.2-2 The same deforming force produces more strain at the site of a simple fracture than at that of a multifragmentary fracture.

If the interfragmentary strain is excessive (instability), or the fracture gap is too wide, bony bridging by hard callus will not occur despite good callus formation, and a hypertrophic nonunion develops [22].

The capacity to stimulate callus formation seems to be limited and may be insufficient when large fracture gaps are to be bridged. In such cases dynamization (unlocking of the intramedullary nail or external fixator) may permit bony bridging by allowing the fracture gap to decrease and increase its stiffness.

Callus formation requires some mechanical stimulation and will not take place when the strain is too low. A low-strain environment will be produced if the fixation device is too stiff or if the fracture gap is too wide [19]. Delayed healing and nonunion will result.

Again, dynamization may be the solution to the problem. If a patient is too immobile to load the operated leg, an externally applied load might be the way to stimulate callus formation.

5.4 Surgical fixation with absolute stability

If a fracture is bridged by a stiff splint, its mobility is reduced and little displacement occurs under functional load. Although stiffness of the implants contributes to reducing the mobility of the fracture, the only technique which will effectively abolish motion at the fracture site is anatomical reduction and interfragmentary compression.

Absolute stability abolishes deformation (strain) of repair tissue at the fracture site during physiological loading and results in direct bone healing. Reduction of strain to below a critical level will reduce stimulation to form callus, causing the fracture to heal without visible callus.

In a low-strain environment bone heals directly by osteonal remodeling—the same homeostatic mechanism that exists for normal physiological bone turnover.

This process is also called primary bone healing. It is much slower than healing by callus formation and so the implant must not only provide and maintain absolute stability for a prolonged period but it must also be strong enough to resist fatigue failure during the prolonged healing period.

Direct bone healing is not the primary goal of this fracture fixation method but rather an unavoidable consequence of using a technique that obtains and maintains a perfect anatomical reduction. Anatomical reconstruction and early

mobilization is the true goal of surgery in intraarticular fractures and in some simple diaphyseal fractures, such as the forearm.

Disturbance of bone biology or vascularity is far more serious and difficult to treat than delayed union or nonunion resulting from a high-strain environment because the fixation is too flexible.

It takes much more experience and greater skill to treat a complication due to disturbed vitality than to fix a simple hypertrophic nonunion, which just needs enhanced mechanical stability (see chapters 5.2 and 5.3).

5.4.1 Mechanics of techniques of absolute stability

Absolute stability is achieved by using a compressive preload and friction.

Compressive preload

Compression maintains close contact between two fragments, provided compression at the fracture site exceeds the traction forces acting at the fragment ends (**Fig 1.2-9**). Studies in sheep showed that compressive preload (static compression) does not produce pressure necrosis, neither in lag screws nor in plates compressing in an axial direction [23]. Even overloaded bone does not undergo pressure necrosis provided overall stability is maintained.

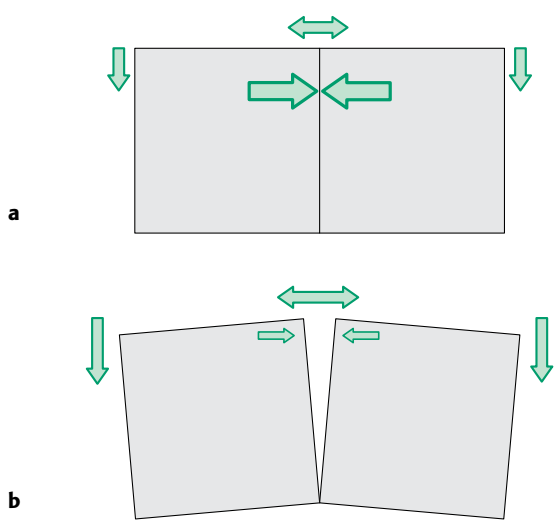

Fig 1.2-9a–b Stabilization by application of interfragmentary compression. The compressive preload prevents displacement of the fracture fragments and results in absolute stability as long as the compression produced is greater than any traction produced by function.

Friction

When fracture surfaces are pressed against each other, friction is produced. Friction counteracts shear forces, so sliding displacements are avoided (**Fig 1.2-10**). Shearing originates, in most cases, from torque applied to the limb, and this is more important than the forces acting perpendicular to the long axis of the bone.

The amount of resistance to shear displacements depends on the compression-induced friction and the geometry of the surfaces in contact (interdigitation). For smooth bone surfaces, the normal forces produce somewhat less than 40% of friction. Rough surfaces allow a firm fixation and interdigitation of the fragments, which additionally counteracts displacement due to shear forces.

5.4.2 Implants

Lag screws

A lag screw is an implant that stabilizes a fracture by compression alone (see chapter 3.2.1). The lag screw is applied to have purchase only in the remote cortex, and approximation between the thread and the head of the screw results in interfragmentary compression between the two cortices. The fracture located between the far and near cortices is thereby compressed and absolute stability is obtained by preload and friction.

In vivo experiments have shown that lag screws can produce high compression forces (> 2,500 N) (**Fig 1.2-11**), which are maintained over a period exceeding the time required for fracture healing. Compression produced by a lag screw acts optimally from within the fracture, in contrast to compression produced by plates (see chapter 3.2.2).

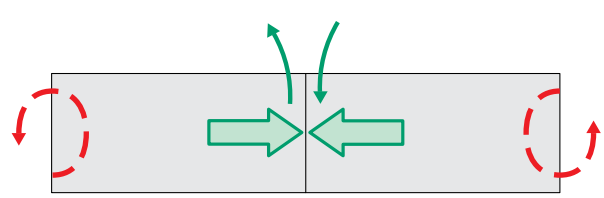

Fig 1.2-10 Stabilization by application of interfragmentary compression (large green arrows) producing friction. As long as the amount of friction is greater than the forces that tend to displace the fracture along the fracture plane, either tangential forces resulting from applied torque (red arrows) or forces acting perpendicular to the long bone axis (small green arrows), absolute stability is maintained. Screw fixation of a plate with dynamic compression relies on the same principle.

There are two disadvantages of compression fixation by lag screws alone. Lag screws provide high compression force, but the lever arm of such compression is, in most instances, too small to resist functional loading. This applies to both bending and shearing because the area of compression is relatively small when viewed from the axis of the screw. Thus, in diaphyseal fractures, lag screws must always be combined with a plate that protects them from these forces (protection plate, previously called neutralization plate). The other disadvantage of lag screw fixation is its lack of tolerance to single overload. When a screw thread strips, it loses its compressive action and is unable to recover its function. This is a contrast to plate fixation when the loss of function of a single screw may be compensated by the rest of the screws.

Lag and plate screws must not be tightened to a level where they start to give way. With this mode of application, the bone threads are partially damaged and/or the screws are plastically deformed and may fail.

The more the screw is tightened, the greater the risk that it will fail. Either the bone thread strips or the metal breaks with complete loss of function. It is especially important to consider this when titanium screws are used, as titanium provides little tactile feedback to the surgeon who may apply too much torque. Titanium screws are only slightly weaker than steel screws (see chapter 1.3) but their ductility (plastic deformation before rupture) is low.

Plates

A fracture fixed with one or more lag screws results in fixation without motion (absolute stability) but in general such fixation tolerates only minimal loading. A splint bridging the fracture site can reduce the load applied to the screws.



Fig 1.2-11 Photoelastic model showing the compression exerted upon an oblique osteotomy. The lag screw produces forces of 2,500–3,000 N.

Therefore, lag screws are usually combined with plates acting as splints to protect the screw by reducing shear or bending forces. The term protection plate (earlier called neutralization plate) refers to a plate functioning in this way.

A plate can be used to function in six different ways (see chapter 3.2.2):

- Protection
- Compression
- Tension band
- Bridging
- Buttress
- Reduction (tool)

A plate may be applied to one side of a fracture and then tensioned (by using eccentric placement of screws in the plate or by using the articulated compression device) to compress the bone (and fracture) along its long axis. This is only effective in simple transverse or short oblique fractures. However, when a straight plate is applied to a straight bone, this will produce compression underneath the plate with slight distraction of the opposite cortex (**Fig 1.2-12**). This is not a stable situation. Overbending of the plate, so that there is a small gap between the plate and the bone at the level of the fracture, will achieve compression of both the near and far cortex and produce absolute stability (**Fig 1.2-13**). A plate may be placed on the tension side of the bone to act as a tension band. When the bone is loaded, the plate converts tension into compression at the far cortex and produces absolute stability. This principle is discussed in detail in chapter 3.2.3.

A buttress plate is used in the metaphyseal areas. A buttress is a construction that resists axial load by applying force at 90° to the axis of potential deformity. Under such conditions, the plate initially carries full functional load. It can be used to provide absolute stability and is often combined with lag screws. Mechanically, a buttress is a strong construct.

A bridging plate is used in multifragmentary fractures. It is used to fix only the two main fragments and restore length, alignment, and rotation. There is minimal disturbance of the fracture site and no fixation of further fragments. This technique always provides relative stability with healing by callus formation. A comprehensive description of the function and application of plates is given in chapter 3.3.2.

The LCP can be used to function in all five different modes described above. Thus, LCPs can be used to provide absolute or relative stability. It resembles the LC-DCP but has combination holes. The smooth part of the dynamic compression

unit allows insertion of conventional screws so the plate can be used in the same way as DCP or LC-DCP. The threaded part of the combination hole allows locking head screws to be inserted to produce a mechanical coupling between the plate and the screw. For multifragmentary fractures, LCP can be used as a standard bridging plate. However, if locking head screws are used for the entire fixation, the plate is not compressed against the cortex and acts like an external fixator. This is the internal fixator principle. It provides relative stability with minimal interference with the blood supply to the fracture.

When using the LCP, it is essential that the surgeon understands the different functions of the plate and knows how to use this device to achieve the goals of surgery. Careful preoperative planning is essential and must include the order of screw insertion, which can fundamentally alter the biomechanical function of this device.

Use of the LCP is explained in detail in chapter 3.3.4.

External fixators

Circular external fixators, as developed by Ilizarov, allow complete control of length, alignment, and rotation of a fracture. These devices can be used to provide absolute stability. The same principle applies when circular frames are used to treat hypertrophic nonunions, where the provision of absolute stability will allow rapid fracture union. Circular frames can also be used to apply compression across oblique fractures but this requires careful planning and a more complex frame design. The frame adjustments that allow compression in different planes are difficult to calculate but computer programs are now available to aid the surgeon in achieving this goal.

5.4.3 Mechanobiology of direct or primary fracture healing

Bone healing is different in cortical and cancellous bone. The basic elements correspond qualitatively but as the vascularity and the volume to surface ratio are different, the speed and reliability of healing is generally better in cancellous bone.

Diaphyseal fractures

In the diaphysis, absolute stability is achieved by means of interfragmentary compression to maintain the fracture fragments in permanent apposition (see chapter 3.2.2). Pain will subside and allow for early recovery of function within a few days after surgery.

Radiologically, only minor changes can be observed: under absolutely stable fixation, there is minimal visible callus formation or none at all [24]. The fact that the fragment ends are closely approximated means that only a fine line can be seen on x-rays. This renders the judgment of fracture healing difficult. A gradual disappearance of the fracture line with trabeculae growing across this line is a good sign, while a widening of the gap is a sign of instability. The surgeon



Fig 1.2-12 Interfragmentary compression with a straight plate. This photoelastic picture shows that by applying tension to the plate, compression of the plated bone segment can be produced. Thus, compression acts within the bone along its long axis. Such compression is effective only in transverse fractures. With a straight plate, there is only compression in the near cortex, underneath the plate.



Fig 1.2-13 Interfragmentary compression with a prebent plate. Symmetrical compression may be achieved by prebending the plate. The slightly curved plate is applied to the bone surface with the middle part elevated. When the screws are tightened, the far cortex opposite to the plate is compressed as well.

judges the progress of healing by the absence of radiological signs of irritation, such as bone resorption or the formation of a cloudy "irritation" callus, as well as by clinical symptoms, such as the presence or absence of pain and swelling. The surgeon should also look carefully at the interface between the screws and the bone. Osteolysis around the screws may be the earliest sign that the fracture is not healing and that excessive load is passing through the plate, resulting in failure of the implant-bone couple.

The histological sequence of healing under conditions of absolute stability:

- In the first few days after surgery there is minimal activity within bone near the fracture site. The hematoma is resorbed and/or transformed into repair tissue. The swelling subsides while the surgical wound heals.
- After a few weeks, the Haversian system starts to remodel the bone internally as visualized by Schenk and Willenegger (**Figs 1.2-14–15**) [25]. At the same time, gaps between imperfectly fitting fragment surfaces—if stable—will start to fill with lamellar bone, the orientation of which is transverse to the long axis of the bone.
- In subsequent weeks, the cutter heads of the osteons reach the fracture and cross it wherever there is contact or only a minute gap [26]. The newly formed osteons crossing the gap provide a type of microbridging or interdigitation.

Fractures in cancellous bone

Fractures around the metaphysis have a comparatively large fracture surface with good vascularity. This offers the opportunity of good fixation in terms of bending and torque, and thus these fractures tend to be more stable, and healing occurs more rapidly. Radiological evaluation is somewhat impeded by the complex 3-D structure of trabecular cancellous bone. The main histological activity seen in fracture healing of cancellous bone occurs at the level of the trabeculae. Healing—due to the larger surface per volume—is likely to occur faster than in cortical bone. Because vascularization of cancellous bone is better than in cortical bone, necrosis is less likely to occur.

The advantage of absolute stability is that it maintains perfect reduction of the articular surface and allows early functional rehabilitation. The disadvantages are that internal Haversian remodeling starts late and takes a long time and that the absence of any movement at the fracture gap does not stimulate callus formation. Therefore, the implant alone must provide stable fixation initially and for a longer period than for fractures under relative stability.

Recovery of blood supply

Absolute stability also has positive effects on the blood supply. Under stable conditions, blood vessels may cross a fracture site more easily. Despite the deleterious effects of surgical procedures used to achieve absolute stability, once obtained, it supports the repair of blood vessels (**Fig 1.2-16**).

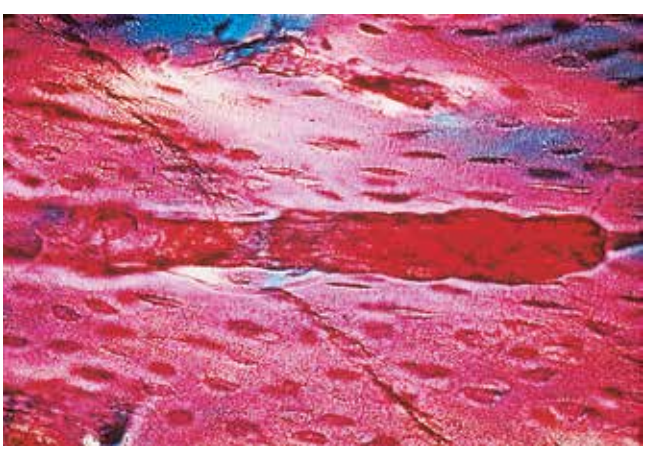

Fig 1.2-14 Histological appearance of direct cortical bone healing. The areas of dead and damaged bone are replaced internally by Haversian remodeling. The fracture line has been graphically enhanced.

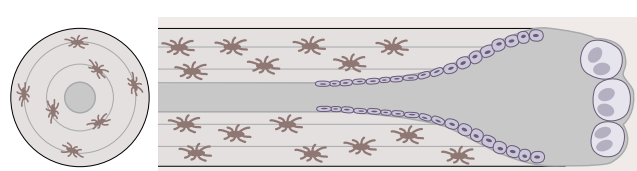

Fig 1.2-15 Haversian remodeling. The osteon carries at its tip a group of osteoclasts that drill a tunnel into the dead bone. Behind the tip, osteoblasts form new bone with living cells and a connection to the capillaries within the canal.

In plate fixation, the comparably large contact area (footprint) of conventional plates is considered a disadvantage. Bone tolerates mechanical loading well and protects its inner blood vessels from being affected by it. The blood vessels entering bone from the periosteal and endosteal sides are, however, sensitive to any external contact. When plates are placed onto the bone surface, they are likely to disturb the periosteal blood supply. In conventional plating, part of the stability is obtained by friction between the plate and bone, which requires a minimum area of contact. Extensive and continuous contact between any implant and bone results in circumscribed areas of bone necrosis in the cortex directly underneath the plate. This may lead to temporary porosis of the bone and, exceptionally, to sequestration. Reduction of the bone-implant interface may improve resistance to local infection and enhance fracture healing (**Fig 1.2-17**).

6 Outlook

Dramatic advances have been made in the understanding of the interplay between biomechanical forces and biological healing of bone. Each has a direct influence on the other and the healing outcome is a result of the combination of signals received (**Fig 1.2-18**). The biomechanical environment can modify the biological response and an understanding of this process could be used to improve clinical decision-making [21]. Increasingly, novel therapies will involve the use of biological components and it is crucial that practicing surgeons inform themselves of the mode of action and potential adverse effects. A willingness to embrace newer therapies will lead to an increased armamentarium to treat bone healing in cases of biological deficits.

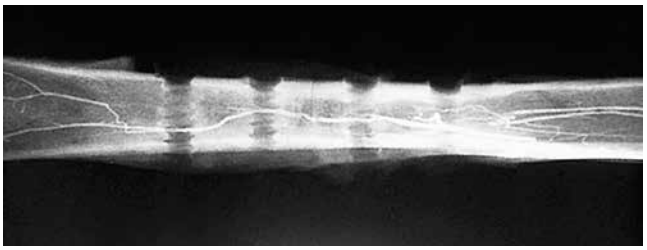

Fig 1.2-16 The effect of stability on revascularization. The osteotomy of a rabbit tibia has been reduced and stably fixed. As early as 2 weeks after complete transection of the bone and medullary cavity the blood vessels have reconstituted and are functioning, as this angiography at 14 days shows.

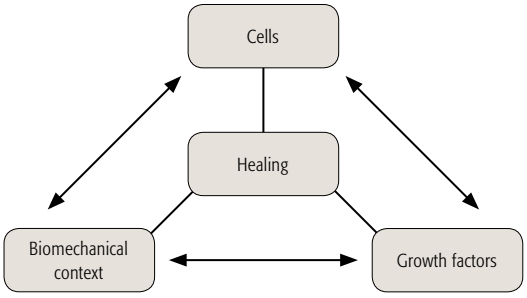

Fig 1.2-18 Interplay between the biomechanical environment, cells and growth factors combines to direct the healing outcome.

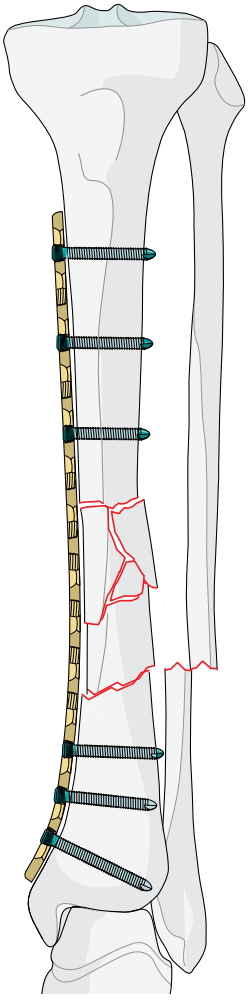

Fig 1.2-17 Bridging plate. The plate spans a critical fracture area and is fixed only near its two ends. Thus, periosteal contact at the fracture site that could impede circulation is avoided and there is the possibility of placing a bone graft under the bridge.

Classic references | Review references

7 References

1. **Perren SM.** Minimally invasive internal fixation: history, essence and potential of a new approach. *Injury.* 2001 May;32:Suppl 1:S-A1–3.
2. **Perren SM.** Evolution of the internal fixation of long bone fractures. The scientific basis of biological internal fixation: choosing a new balance between stability and biology. *J Bone Joint Surg Br.* 2002 Nov;84(8):1093–1110.
3. **Farouk O, Krettek C, Miclau T, et al.** The topography of the perforating vessels of the deep femoral artery. *Clin Orthop Relat Res.* 1999 Nov;(368):255–259.
4. **Gautier E, Cordey J, Mathys R, et al.** *Porosity and Remodeling of Plated Bone After Internal Fixation: Result of Stress Shielding or Vascular Damage?* Amsterdam: Elsevier Science Publishers; 1984:195–200.
5. **Perren SM.** The concept of biological plating using the limited contact-dynamic compression plate (LC-DCP). Scientific background, design and application. *Injury.* 1991;22(Suppl 1):1–41.
6. **Grundnes O, Reikeras O.** Blood flow and mechanical properties of healing bone. Femoral osteotomies studied in rats. *Acta Orthop Scand.* 1992 Oct;63(5):487–491.
7. **Kelly PJ, Montgomery RJ, Bronk JT.** Reaction of the circulatory system to injury and regeneration *Clin Orthop Relat Res.* 1990 May;(254):275–288.
8. **Brookes M, Revell WJ.** *Blood Supply of Bone Scientific Aspects.* London: Springer-Verlag; 1998.
9. **Rhinelander FW.** Tibial blood supply in relation to fracture healing. *Clin Orthop Relat Res.* 1974 Nov-Dec;(105):34–81.
10. **Klein MP, Rahn BA, Frigg R, et al.** Reaming versus non-reaming in medullary nailing: interference with cortical circulation of the canine tibia. *Arch Orthop Trauma Surg.* 1990;109(6):314–316.
11. **Pfister U.** [Biomechanical and histological studies following intramedullary nailing of the tibia]. *Fortschr Med.* 1983 Oct;101(37):1652–1659. German.
12. **Claes L, Heitemeyer U, Krischak G, et al.** Fixation technique influences osteogenesis of comminuted fractures. *Clin Orthop Relat Res.* 1999 Aug;(365):221–229.
13. **Farouk O, Krettek C, Miclau T, et al.** Minimally invasive plate osteosynthesis: does percutaneous plating disrupt femoral blood supply less than the traditional technique? *J Orthop Trauma.* 1999 Aug;13(6):401–406.
14. **Sarmiento A, Latta LL.** *Functional Fracture Bracing.* Berlin Heidelberg New York: Springer-Verlag; 1995.
15. **Urist MR.** Bone: formation by autoinduction. *Science.* 1965 Nov 12;150(3698): 893–899.
16. **Schandelmaier P, Krettek C, Tscherne H.** Biomechanical study of nine different tibia locking nails. *J Orthop Trauma.* 1996;10(1):37–44.
17. **Claes LE, Wilke HJ, Augat P, et al.** Effect of dynamization on gap healing of diaphyseal fractures under external fixation. *Clin Biomech.* 1995 Jul;10(5):227–234.
18. **Claes LE, Heigele CA, Neidlinger-Wilke C, et al.** Effects of mechanical factors on the fracture healing process. *Clin Orthop Relat Res.* 1998 Oct;(355 Suppl):S132–147.
19. **Perren SM, Cordey J.** *The Concept of Interfragmentary Strain.* Berlin Heidelberg New York: Springer-Verlag; 1980.
20. **Claes LE, Heigele CA.** Magnitudes of local stress and strain along bony surfaces predict the course and type of fracture healing. *J Biomech.* 1999 Mar;32(3):255–266.
21. **Elliott DS, Newman KJ, Forward DP, et al.** A unified theory of bone healing and nonunion: BHN theory. *Bone Joint J.* 2016 Jul;98-B(7):884–891
22. **Schenk RK, Müller J, Willenegger H.** [Experimental histological contribution to the development and treatment of pseudarthrosis]. *Hefte Unfallheilkd.* 1968;94:15–24. German.
23. **Perren SM, Huggler A, Russenberger M, et al.** The reaction of cortical bone to compression. *Acta Orthop Scand Suppl.* 1969;125:19–29.
24. **van Frank Haasnoot E, Münch TW, Matter P, et al.** Radiological sequences of healing in internal plates and splints of different contact surface to bone. (DCP, LC-DCP and PC-Fix). *Injury.* 1995;26 (Suppl 2):28–36.
25. **Schenk R, Willenegger H.** [On the histological picture of so-called primary healing of pressure osteosynthesis in experimental osteotomies in the dog.] *Experientia.* 1963 Nov 15;19:593–595. German.
26. **Rahn BA, Gallinaro P, Baltensperger A, et al.** Primary bone healing. An experimental study in the rabbit *J Bone Joint Surg Am.* 1971 Jun;53(4):783–786.

8 Acknowledgments

We thank Stephan Perren and Keita Ito for their contributions to this chapter in the second edition of the *AO Principles of Fracture Management*.

1.3 Implants and biotechnology

Geoff Richards

1 General requirements

The use of metal in fracture fixation has demonstrated unrivaled success for decades owing to the metal's high stiffness, strength, good ductility, biological toleration (biocompatibility), lack of toxic and inflammatory reactions, and reliable function.

An implant material, which corresponds to international standards, generally manifests an adequate level of biocompatibility (the ability of the material to perform with an appropriate host response in a specific application in a specific location). It should be noted that metals that may behave extremely well mechanically and biologically for fracture fixation in one anatomical area may cause biological problems in another.

The metals currently used are electropolished stainless steel (EPSS) (ISO 5832-1) and commercially pure titanium (cpTi) (ISO 5832-2) [1–3], along with titanium alloys such as titanium aluminum niobium (TAN) (ISO 5832-11). Despite the many differences between these metals, they provide a fairly predictable clinical outcome, and offer comparable success for achieving the main biomechanical and biological requirements of fracture fixation despite clear differences in implant properties and biological responses [1]. Ceramics, polymers, carbon composites, and degradable materials are also used for special applications [3] but not in situations where high loads are to be expected, unless metal fixation is also present.

Implant materials used for internal fixation must conform to certain basic requirements; reliable function and minimal adverse effects for the patient are equally important. The selection of material and implant design must respond to several conflicting requirements. This chapter introduces the basic principles used when selecting materials for internal fixation devices.

2 Material mechanical properties

2.1 Stiffness

Stiffness is defined as the ability of a material to resist deformation. It is measured as the association between the load applied to the material and the resulting elastic deformation of the material.

The stiffness of a material is its modulus of elasticity. The stiffness of an implant results from the modulus of elasticity of the material and the shape and dimensions of the implant itself. As an example, the modulus of elasticity of cpTi (titanium) (110 GPa) is much less than that of EPSS (stainless steel) (186 GPa), and so, under similar load conditions, it will deform more. However, the dimension of the actual implant is also important: increasing the thickness of a standard cpTi plate by a few tenths of a millimeter will increase its bending stiffness. EPSS is a much stiffer material than titanium, which may be relevant for problems relating to normal loading of the adjacent bone. The increased flexibility of cpTi and its alloys means that the elastic deformations are closer to bone (20 GPa) compared with EPSS. Due to this, cpTi and its alloys have increased fatigue resistance compared with EPSS and show superiority over steel under cyclic load [3].

Osteosynthesis restores bone stiffness temporarily until fracture healing restores it permanently.

When we consider an implant (screw, nail, plate, or external fixator) spanning a fracture, the stiffness of the implant must prevent deformity at the fracture site. To allow proper healing the device must reduce fracture mobility to below the critical level at which healing tissue will form. During the biological differentiation cascade, the tissue within the fracture site differentiates from hematoma to granulation tissue to cartilage to bone, with a gradual increase in strength associated with a decrease in the tolerance of strain. Granulation tissue tolerates 100% strain, cartilage 15% and forms under conditions of higher dynamic deformation (strain)

than the final mineralized tissue. Cortical bone tolerates 2% strain. Nature gradually increases rigidity and strength and each new tissue forms under the protection of its predecessor (see chapter 1.2).

In the past, attempts have been made to produce implants that have a material stiffness similar to bone, using plastic or carbon reinforced composites [4]. These implants were thought to reduce the stress shielding that was believed to occur with stiff metal implants that take the load away from the bone. Preclinical research combining intravital staining of the vascular system and polychrome fluorescent labeling of bone remodeling demonstrated that early bone porosis in the locality of the implants is the result of internal cortical bone remodeling induced by necrosis rather than by unloading [5]. Perren's necrosis theory is strengthened by (1) bone porosis is temporary in internal bone remodeling; (2) the pattern of the remodeling zone is closely related to that of the disturbed circulation, and not to that of unloading; (3) plastic plates may produce more bone porosis than steel plates; (4) improved blood circulation using modified plates results in reduced porosis. Implants with low material stiffness do not as a rule offer an acceptable balance between biology and mechanical properties

2.2 Strength

Strength is the ability of a material to resist the application of forces without deformation or failure.

Thus, strength determines the amount of load an implant can resist. Before a metal breaks it may irreversibly deform (plastic deformation). The dimensions of the implant are often more important than the strength of the material. The strength of cpTi is about 10% less than that of steel (**Table 1.3-1**), but an increase of the implant cross-section can compensate for the difference in material strength. Strength determines the limit of stress (force per unit area), which results in deformation.

Implant material	International standards	Ultimate tensile strength	Elongation
Stainless steel (cold-worked)	ISO 5832-1	960 MPa	15%
Unalloyed (commercially pure) titanium grade 4B (cold-worked)	ISO 5832-2	860 MPa	18%
Ti-6Al-7Nb	ISO 5832-11	1060 MPa	15%

Table 1.3-1 Typical mechanical properties of implant materials used for bone screws.

For internal fixation, the resistance of an implant to repeated load, which may result in failure by fatigue, is a critical issue.

Compared with steel, cpTi is somewhat less resistant to single loads but greatly superior when high-cycle repeated loads are applied [5].

2.3 Ductility

The ductility of a material is the degree of permanent deformation it tolerates before it breaks (plastic deformation without material fracture).

The ductility of a material determines the degree to which an implant, such as a plate, can be contoured by the surgeon for different anatomical requirements. As a rule, materials of high strength, such as titanium alloys and highly cold-worked cpTi, offer less ductility than steel (though the most common EPSS fracture fixation devices, such as bone screws, plates and nails are cold-worked, which provides an intermediate condition of tensile properties and ductility). Ductility provides some forewarning of impending failure, for instance during insertion of a screw. According to international standards, a 4.5 mm cortex screw (ISO 6475) must tolerate more than 180° of elastic and plastic angular deformation before breakage. However, cpTi, having lower ductility, provides less tactile feedback (pre-warning), which means that the surgeon should first acquire some hands-on experience of the different handling techniques before surgical use.

This limitation of lower ductility of cpTi is now partly overcome by producing anatomically designed implants that do not require contouring (and theoretically should not be contoured) by the surgeon. Contouring can lead to deformation of the thread-bearing part of the combination hole with locking compression plate (LCP) implants, rendering them incapable of retaining locked screws and is therefore not advised.

cpTi and its alloys have two main mechanical conditions, annealed (softer) and cold-worked. The annealed version is used for lower-stress loading applications, such as mini-fragment plates. The cold-worked cpTi (and alloys) has increased strength and is used for plates, screws, and nails.

2.4 Torsional properties

Torsion is the twisting of an object due to an applied torque (the force to rotate an object about an axis, the turning force). One observed clinical benefit of EPSS relates to its torsional properties. When the maximum torque of an EPSS screw insertion is reached, the screw will no longer hold torque properly, bottoms out and no longer advances. Even with continuing screw rotation a constant torque is sustained. The screw head will continue to rotate approximately 1.5 turns until it breaks. For surgeons, this property is an advantage, providing tactile feedback during insertion and limiting the possibility of screw stripping. cpTi (and its alloys) screws do not provide as much of a tactile response. Once the screw bottoms out, it fails to reach maximum torque and continuing rotation of the screw head persists in increasing the torque. Breakage of the screw occurs after approximately an additional three to four turns. Torque-limiting screwdrivers are available to help prevent such problems. A clinically relevant comparison of the torsional performance of EPSS and titanium alloy tibial intramedullary nails was performed using distal locking screw holes and dedicated cross screws to secure each nail distally [6]. From the mechanical testing, the mean torsional rigidity of the titanium alloy nail system was 40.9 N/m2 while that of the EPSS nail system was 34.6 N/m2. Theoretical calculations of the torsional rigidity of the central part of the nail were 83 N/m2 for the EPSS nail and 66 N/m2 for the titanium alloy nail.

This study shows that there are clinically relevant biomechanical properties of the whole implant system. It is not just the material that should be considered.

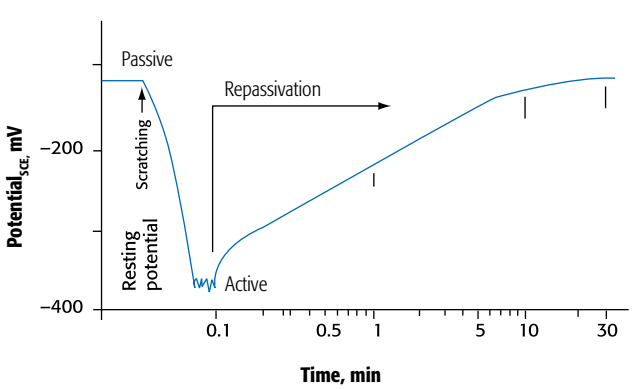

Fig 1.3-1 Repassivation behavior of titanium in 0.9% NaCl solution after scratching the surface with a needle.

3 Material biocompatibilty properties

3.1 Corrosion resistance and toxicity

Corrosion is an electrochemical process that results in the destruction of metal by the liberation of ionic metal.

Corrosion differs in implants made of one single component and implant systems with several metal components. Stainless steel, cpTi, and TAN, if tested as a single element (ie, only as a plate or screw and not as a combination of the two), are highly resistant to corrosion, even in the environment of body fluids. This is due to a protective, passive layer which forms on their surfaces. Titanium and titanium alloys have extreme chemical inertness. An oxide passivation film forms on titanium and its alloys that is much more corrosion resistant and thermodynamically stable than the chromium oxide film that forms on stainless steel. The passive layer on titanium is formed quickly, is electrically isolating, and the implant shows literally no corrosion (**Fig 1.3-1**). Stainless steel is susceptible to crevice corrosion. Cobalt chromium molybdenum (CCM) is more corrosion resistant but can release "toxic" ionic species when depassivated (US Food and Drug Administration [FDA] concern issued February 2012).

Recent in vitro and in vivo research has produced a persuasive case characterizing many constituents of stainless steel implants, such as chromium (Cr), cobalt (Co), iron (Fe), and nickel (Ni), as the main causes of toxicity, the undesirable effects of which extend to a variety of systems such as the vascular, immune, excretory, reproductive, integumentary and nervous systems [1, 7, 8]. The use of titanium and titanium-alloy implants, which have superior function under mechanical/cyclic load compared with EPSS, is an alternative without these concerns. The accelerated regeneration rate of titanium oxide surfaces would afford better resistance to substantial metal ion release compared with EPSS.

Cobalt alloys, which are successfully used in single element endoprosthetic implants, are not currently used in internal fixation implants due to their susceptibility to galvanic corrosion when in contact with steel. Since the polarization plots for cpTi and TAN are similar, the materials could be used for multicomponent device applications; galvanic corrosion would not be expected to occur. On top of the intrinsic corrosion problems, mixing dissimilar materials will likely add the problem of galvanic coupling, though preclinical studies with different metals used for cannulated screws and guide wires could not find adverse in vivo effects [9].

Erosion is a physical process that results in structural degradation of the implant surface, with the release of material debris that ranges in size down to a few nanometers.

In orthopedics, the major form of erosion is fretting corrosion encountered in modular implant systems, such as when a screw head moves in relation to the plate hole. Fretting occurs with micromotion between two adjacent implant surfaces. This results in the release of submicron sized particles into nearby tissue. Fretting particles cause a number of clinical complications. Experimentally produced debris from steel, cpTi, and an alloy Ti-15Mo, when examined in vitro, showed phagocytosis of particles of all three materials by macrophages in a dose-dependent response. Steel particles also inhibited cell proliferation, even when the particles were not in direct contact with the cells and caused cell membrane damage. When two implants made of cpTi are moved against each other under load, metal debris from abrasion may be observed in the local surrounding area (with particle sizes often larger than 10 µm [10]), giving a harmless discoloration in the tissues. Steel wear debris has been observed in organs remote from the site of the implant, showing that it can disseminate around the body [7]. When steel fretting occurs, the particles produced are less than 0.5 µm in size [10] and can be easily transported away from the implant site. If submicron titanium particles are transported away from the implant site, they should not elicit a tissue reaction due to their high biocompatibility. Though cpTi ions have been observed in increased amounts in hair of patients in a study [11] where the patients received spinal implants. To our knowledge, no publications have shown tissue reactions in organs remote from the site of a cpTi implant. For flexible internal fixation where motion and thus fretting is to be expected, titanium or its alloys are the materials of choice.

3.2 Surface properties

EPSS, cpTi, and its alloys differ in their surface oxide composition, which is a major determining factor in protein adsorption, cell attachment, and finally either fibrous-osseous integration or direct osseointegration [1].

When placing an implant into the body, the implant becomes conditioned immediately by water, blood, and protein, minimizing the extent of which the actual implant contacts adjacent tissue. This is followed by either fibrous-osseous integration or direct osseointegration. Without cell adhesion, under the presence of micromotion, fibrous capsule formation occurs [12]. The properties of the implant surface, such as microtopography and chemistry help to define the eventual tissue response via the protein and cell interactions. The influence of surface microtopography continues from the moment of device implantation for several months until a final tissue response has been determined. The reader is referred to a review on this area for further information, including the theory of the "effective roughness spectrum", a hypothesis for control of cell surface integration based upon the notion that for a surface-mediated cell response to occur it is necessary for the individual cells to perceive the micro-roughness [13]. The development of a stable bone-implant interface is considered critical for the success of osteosynthesis implants, such as screws. The surface structure of an implant in contact (direct osseointegration) or near contact (fibrous-osseous integration) with bone is important because force transmission occurs at this interface. An in vivo study in rabbits showed that simple surface roughness modification of steel internal fixation plates within the "effective roughness spectrum" induced more bone formation toward the implant surface without fibrous tissue formation in between (**Fig 1.3-2**).

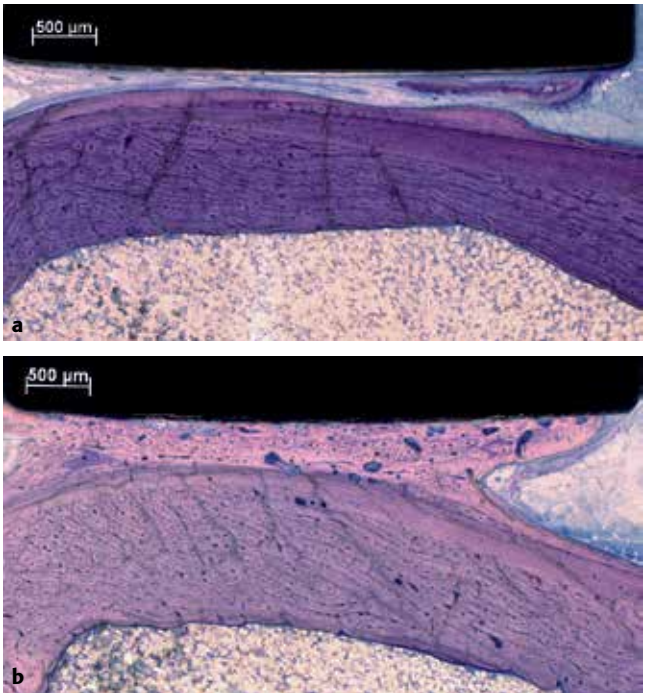

Fig 1.3-2a–b Histological appearance of the undersurface of plates after 12 weeks implantation in rabbits in a nonfractured model.
a A smooth stainless steel plate above the bone with a soft-tissue capsule between plate and bone.
b A rough stainless steel plate above the bone with bone growth toward the plate and bony attachment onto the plate undersurface.

Several studies [14–16] have detected a continuous one- to two-cell thick fibrous cell layer separating EPSS devices from bone (where the EPSS surface topography is outside/below the "effective roughness spectrum"). cpTi (non-polished) and its alloy TAN support direct osseointegration (where the surface topography of cpTi and its alloy TAN are within the "effective roughness spectrum"), without a continuous fibrous interface. A proteoglycan layer has been reported [17], which contains closely packed ordered collagen bundles adjacent to (non-polished) cpTi implants, yet for EPSS this layer does not contain ordered collagen filaments (where surface topography of EPSS is outside/below the "effective roughness spectrum"). This is believed to accelerate osseointegration to cpTi and its alloys due to the enhanced degradation of the hyaluronan network, formed in wound healing [16]. The 3-D surface micro-morphology with microdiscontinuities of (non-polished) cpTi and its alloys (where the surface topography is within the "effective roughness spectrum") compared with the smooth surface of EPSS (outside the "effective roughness spectrum") is thought to offer increased anchorage to the fibrin matrix upon implantation [13]. The distinct fibrous interface formed with EPSS implants does not appear to cause any compromise in implant stability in preclinical studies with bone screws [14], LCPs and locked screws [16], or intramedullary nails [15]. The fibrous interface formed with EPSS implants and polished cpTi and polished titanium alloy implants was observed to generate significantly lower screw removal torque and nail pull-out forces compared with standard microrough cpTi and titanium alloy counterparts [14–16]. Analysis with in vitro research with osteoblasts suggests that the effect of polishing is not only purely mechanical but also has effect at the cellular level [18]. Given the proven success of EPSS in fracture fixation largely without major incident, these numerous research results strongly challenge the unproven myth that direct osseointegration is required for implant stability; fibrous-osseous integration is thought to be sufficient. Modern fracture fixation devices (locking plates and locked nails) attain immediate stability because of the implant design and therefore direct osseointegration is also not essential on such implants for stability. In such cases, surfaces which do not encourage direct osseointegration suffice. Such surfaces will have advantages for implant removal, allowance of free-gliding tissues to glide (eg, tendons, muscles, nerves) and the discouragement of protein, cell and bacteria attachment and reduce implant biofilm formation on osteosynthesis implants.

While (non-polished) cpTi and its alloys would appear to have a clear advantage over EPSS for supporting direct osseointegration, this advantage is compromised in numerous anatomical locations. For instance, the formation of restrictive adhesions between an implant surface and tendons is a large clinical problem in hand surgery [19]. Occurrences of these adhesions appear more common with (non-polished) cpTi implants than with the smooth EPSS implants. The effect of distal radius (non-polished) cpTi implants on the functioning of extensor tendons in a preclinical study [20] demonstrated 100% free gliding of tendons over EPSS implants but only 43% over (non-polished) cpTi. It has been shown that the greater occurrence of liquid-filled capsule formation adjacent to EPSS and polished cpTi implants is due to the smooth surfaces devoid of microdiscontinuities [21]. This effect of surface microtopography has been confirmed in vitro, where increased fibroblast growth and spreading is observed on "smoothened/polished" implants compared with a standard microrough (non-polished) clinical titanium alloy [20]. Clinically, this high attraction of bone for the 3-D microrough surface of cpTi and its alloys can cause an assortment of complications upon removal of the implant, such as screw stripping screw/plate breakage, bone in-growth into the screw-plate interface for locked screws causing great difficulty in removing implants and problems separating the implant from the bone which may result in fracture. Bony integration is minimized by using surfaces with minimal microstructure reducing the forces required to remove screws.

In clinical practice, fibrous capsule formation has been observed to be more prevalent with standard EPSS than with standard (non-polished) cpTi plates (**Fig 1.3-3**). This is the reason why EPSS allows free-gliding tissues, such as tendons to move easily over the implant surface without clinical problems.

3.3 Implant infection susceptibility

It has been demonstrated in preclinical studies [22] with rabbits that for locked implants (eg, LCPs) where minimal periosteal damage occurs upon insertion of the plate, no difference in infection susceptibility was detected between EPSS and titanium. The study indicates that the extent of periosteal damage has a direct role in determining infection susceptibility. The severity of trauma inflicted during an infection model may also influence the overall result, as indicated by the lack of difference when the periosteum is protected. However, for external fixation EPSS appears to support higher pin-track infection rates compared with cpTi and titanium alloy or coated devices [23]. For metal internal fracture fixation implants, preclinical studies [22, 24, 25] currently indicate that clinically used surface microtopography does not seem to influence implant susceptibility to infection. It should be noted that there are major hurdles in relating

current preclinical in vitro and in vivo antimicrobial research strategies with real clinical outcomes [26]. Current in vitro and in vivo preclinical studies are neither as correlative nor predictive of clinical efficacy for device-associated infections [26] and major work is now ongoing to improve this area. Current implant surface approaches to decrease or prevent implant infection incidence broadly fit into two categories: (1) modified surface properties to reduce or prevent bacterial-implant adhesion and (2) implant/antimicrobial agent combinations to actively kill local contaminating bacteria.

Current preclinical studies indicate that clinically used implant surface microtopographies do not influence susceptibility to infection.

3.4 Allergic reactions

Implant quality stainless steels include 13–16 weight percent Ni, even though Ni ions belong to the most common skin contact allergens. Clinically relevant allergic reactions to Ni-containing stainless steel devices after internal fixation occur in 1–2% of cases. Ni, Cr, and Co have been implicated in the inhibition of DNA repair and altered gene expression and to produce reactive oxygen species [27], and are thought to be significant in the development and progression of neurodegenerative disorders [28]. cpTi or titanium alloy implants should be used for internal fixation in patients with known Ni allergies. Low-nickel (approximately 0.03%) stainless steels are not Ni free. They reduce the allergic risk but it is not yet known whether there really is no risk at all.

Clinically relevant allergic reactions to Ni-containing stainless steel implants after internal fixation are estimated to occur in 1–2% of cases. Currently, there have been no proven allergic reactions if cpTi has been used exclusively.

3.5 Induction of tumors

Continuous irritation of tissues may in exceptional cases lead to a neoplastic reaction. This is known for scar tissue as well as a result of heavily corroding metal, such as particles of ammunition. The incidence of carcinogenesis from internal fixation material, ie, primary tumors induced by an implant, seems to be extremely low in humans given the millions of such implants that are not removed after fracture healing. Dogs have been reported to produce sarcomas near stainless steel implants, although infection and physical irritation were contributing factors [29].

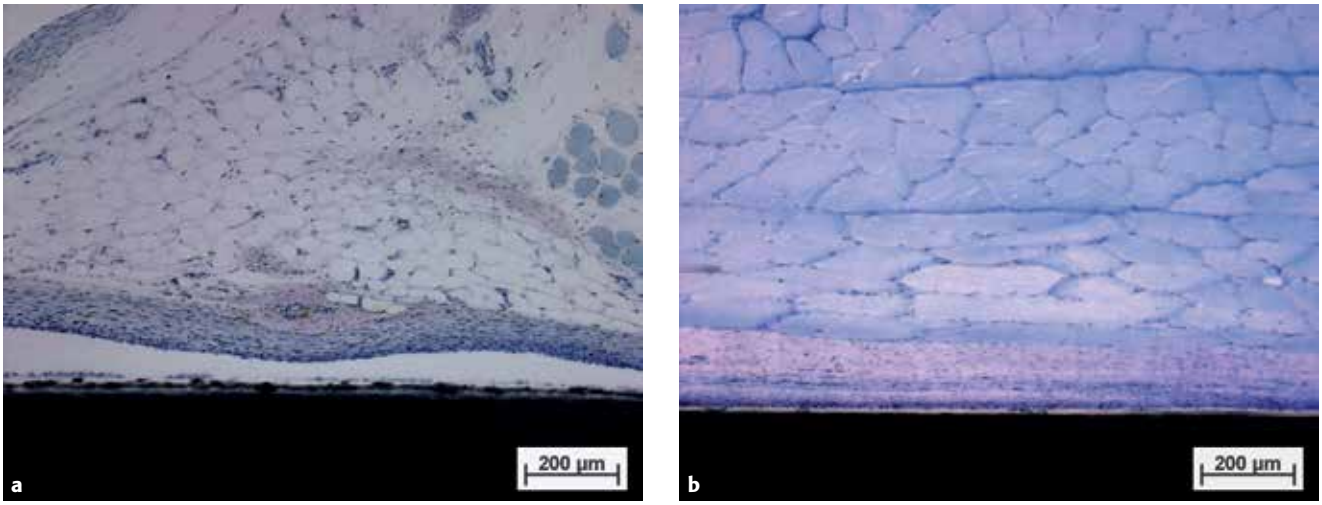

Fig 1.3-3a–b Histological appearance of the upper surface of plates after 12 weeks implantation in rabbits in a nonfractured model.
a A smooth stainless steel plate with fibrous capsule formation and a dead space or void filled with liquid between.
b A cpTi plate with contacting connective tissue and without the presence of a liquid-filled void. After an initial nonspecific reaction, little inflammation and no encapsulation was observed with the cpTi plates tested.

4 Magnetic resonance imaging (MRI) compatibility

AO-approved titanium implants (made either of cpTi or titanium alloys, eg, TAN) are completely nonmagnetic and MRI in patients with these implants does not pose any difficulties. They produce less MRI artifacts, having less magnetic susceptibility compared with EPSS implants, including low-nickel steels. The size of the artifact produced is proportional to the mass of the implant. AO-approved implant quality 316L EPSS is classified as a paramagnetic or nonferromagnetic material. Since cpTi (and its alloys) and EPSS implants do not have high magnetic susceptibility, the risk of implant dislodgment or loosening during MRI is minimal. It is safe to perform MRI on patients who have these implants.

The term MRI safe is used for devices that can be utilized in or around an MR scanner without risk to patients but with possible effects on image quality. The term MR compatible is used for devices that are safe and without influence on the diagnostic information. Some external fixation devices can contain magnetic parts and the surgeon should be aware which ones cannot be placed into an MRI scanner.

5 Coatings

Implant loosening and pin-track infection are unresolved complications associated with external fixation. It is generally accepted that loosening may be overcome by modifying the implant-bone interface for improved osseous integration. It is also thought that pin-track infection may be reduced by the same modifications for improved soft-tissue integration at the implant-soft tissue-air interface. Improved tissue integration may be obtained by the use of hydroxyapatite (HA) or tricalcium phosphate coatings, provided that the initial stability of the interface allows ingrowth. Experimental and clinical studies [30] have shown that HA-coated pins are capable of forming a tight link with living bone tissue and also reduce pin-track infection, possibly by improving the soft-tissue integration at the implant-soft tissue-air interface. This bioceramic material has good biocompatibility for such use, no systemic toxicity, a low degradation rate, and may even become chemically bonded to bone. Unfortunately, the use of HA has been limited by its low adhesive strength to the implant surface, its high stiffness and weak cohesion within its layers (10–60 µm thickness). These factors cause the coating to detach from the implant.

6 Polymeric implants

6.1 Biodegradable polymeric implants

It is recommended that implants are removed after fracture healing in several clinical situations. Implant removal requires another operation with unpredictable clinical results, risk of complications, and associated costs. Biodegradable materials, after a certain period of implantation, are resorbed in vivo in the body in the form of nonharmful by-products, which are then eliminated from the body by normal metabolic processes. In theory this would overcome the question of implant removal once the fracture has healed and the implant has become superfluous.

Polylactides and polyurethanes are synthetic in origin and offer fair tissue tolerance. Due to limited mechanical properties these materials can only be used for implants which must resist only minor loads.

Examples of such implants are pins for the fixation of small chondral or osteochondral defects of articular surfaces, suture anchors, or thin plates and screws used for fracture treatment in the maxillofacial area, including the orbit and skull. Unfortunately, despite a large amount of preclinical research in the field [31], there has been a lack of translation to clinical practice since the mechanical properties, biocompatibility and degradation have not matched the clinical needs.

A strong development in preclinical research, which is likely to translate to clinical practice, is in the field of active molecule delivery locally at the healing site [31]. The combination of biomaterials and biological molecule delivery strategies is a promising avenue for the future in trauma surgery. Active molecule delivery can be used for enhancing the natural bone-healing cascade (with osteogenic substances for osteoprogenitor cell recruitment or improving the angiogenic response), for controlling inflammation (with inflammatory factor molecules), for improving synthetic bone substitutes (with molecules for improved osteoconductivity, osteoinductivity, and osteogenicity) and for treating infections (with locally delivered antibiotics). Local biodegradable polymeric antibiotic carriers offer the possibility of controlled delivery of the active molecule at the actual problem site. Polymeric carriers have been developed to optimize the release and targeting of active molecules, such as antibiotics. Currently, few biomaterials are clinically available for these uses [31].

6.2 Nonbiodegradable polymeric implants

Polyaryletherketone polymers including polyetheretherketone (PEEK) and polyetherketoneketone (PEKK) thermoplastics are considered biocompatible in bone and can be sterilized by most methods including steam, though they have around 5% loss in strength when exposed to gamma radiation. They are x-ray translucent and not magnetic, so are MRI compatible. They do not corrode like metals but there are concerns about possible leakage of their original components (softeners, accelerators, nonpolymerized base components, and solvents). The tensile strength of PEEK is about 90–100 MPa and carbon fiber reinforcement can double this tensile strength. The current high costs of these materials limits applications. As PEEK can be processed into complex shapes, it is used in spine cages for interbody lumbar fusion, patient-specific craniomaxillofacial implants, such as skull plates, and as arthroscopic suture anchors to repair meniscal tears in the knee.

7 Bone regeneration and repair and bone graft substitutes

Adult bone is almost unique in its ability to regenerate to normal bone rather than scar tissue. A number of processes are involved in this mechanism:

- Osteogenesis: the formation of new bone from progenitor tissue
- Osteoconduction: the physical property of a material that provides the microstructure to facilitate the ingrowth of cells that produce bone
- Osteoinduction: the capability of stimulating new bone formation

Materials and factors that influence repair and regeneration of bone are divided into four categories:

- Osteogenic materials include autogenous bone, bone marrow, blood concentrates, and to some extent bone allograft.
- Osteoconductive materials include calcium sulfate, calcium phosphate/hydroxyapatite, calcium phosphate/collagen composites, and demineralized bone matrix.
- Osteoinductive factors include bone morphogenetic proteins.
- Tissue repair factors include fibroblastic growth factors, platelet-derived growth factors, vascular endothelial growth factors, thrombin peptides, prostaglandin agonists, insulin-like growth factor, and growth hormone.

Some materials like autogenous bone have osteogenic, osteoconductive, and osteoinductive properties.

The surgeon is frequently confronted with the need to treat a bone defect that may originate from the initial trauma or is the result of infection and/or avascularity. Bone may be replaced immediately or after an interval during which the host site is prepared. The gold standard remains autogenous bone grafts. Autogenous bone is superior to any current, clinically available substitute. However, the supply for grafting is limited and the donor site is often painful. Synthetic bone graft substitutes approved for clinical use are mostly ceramic materials including calcium sulfates and phosphates. Calcium phosphate-based biomaterials are similar to the mineral part of bone, and often display good biocompatibility, no immunogenicity and high osteoconductivity. The common calcium phosphate-based biomaterials in clinical use for bone regeneration are HA, β-tricalciumphosphate (β-TCP), or their combination, known as biphasic-calcium phosphates. However, they are brittle, which reduces their field of application to low-load or nonload-bearing situations. The resorption rate of HA is counted in decades, so has to be considered as nonresorbable. The solubility of β-TCP is close to that of the mineral part of bone. Therefore, β-TCP granules or blocks are generally resorbed within 1 or 2 years in vivo. β-TCP is degraded by osteoclastic activity in the same way as necrotic bone is degraded. The biological properties of biphasic-calcium phosphates are intermediate between those of β-TCP and HA and degradation rate depends on the ratio of the two: it is faster with a higher ratio of β-TCP.

Solid, bulk materials do not allow cell invasion or vascular ingrowth. Interconnected microporosity (1–10 µm) allows fluid flow, nutrient supply, and waste disposal throughout a porous scaffold. Interconnected macro-porosity (200–300 µm) also allows cell invasion and microvascular ingrowth. The interconnected pores provide for bone conductivity with cell invasion. Increased porosity, though being good for cell, vascular and later bone invasion, decreases the mechanical strength of the scaffolds. Calcium phosphate-based products are now also available as composites (strips or sponges) with a biodegradable polymer counterpart (often collagen) [31]. These substitutes are attractive but ideally they must provide an appropriate combination of reliable mechanical strength and stimulate bone healing with osteoconduction and/or osteoinduction. Resorption should occur without compromising the healing process, including local resistance to infection.

Osteobiologics are also in clinical use. An example is recombinant human-BMP-2 (rhBMP-2). It currently has FDA approval for spinal fusions and tibial fractures, but the safety of this product has been questioned because of adverse effects. This may be from poorly designed delivery systems with poor control of the release of the rhBMP-2 [31]. Naturally occurring materials and scaffolds for bone regeneration approved for human use include allogenic (demineralized bone matrix), xenogenic (often purified bovine bone mineral), and coral-derived materials. Safety is always a concern and therefore the control of the production process with selection of donors, microbiological tests, viral inactivation tests and serological tests is stringent [31].

8 Biological additives, growth factors

Several preclinical studies [31, 32] have attempted to examine the efficacy of growth factors, delivery systems and biomaterials for the repair of bone defects. Improved bone repair has also been demonstrated in the clinical use following European Medicines Agency and FDA approval of BMP-2, BMP-7/OP-1, PDGF, PTH, and PTHrP. For more information on BMPs refer to chapter 1.2. The use of this restricted list of approved growth factors in patients can supplement bone formation. However, our understanding of this highly complex process is limited and temporal, coordinated release of growth factors has to be synchronized with the biological repair process, their duration of activity, their biological activity, and their release kinetics from the carriers.

A simpler method of enhancement of healing may be to induce the cells in the repair environment to produce more of the natural growth factors themselves. The induction of the natural growth factors in biologically correct sequential order and in biologically relevant amounts could be advanced through biomechanical and/or implant surface stimuli [33]. It has been shown over the last two decades through various studies that microtopography of implant surfaces differentially influences osteoblast differentiation in a surface-dependent manner and this influences whether direct osseointegration or fibrous-osseous integration will occur to an implant surface.

9 Future developments

Additive manufacturing (AM) is a process through which 3-D solid objects are created by layers positioned in series until completely built. Additive manufacturing allows the creation of implants that can respond to the specific requirements of patients as changes in shape and structure can be rapidly implemented. It is expected that AM will not substitute normal manufacturing processes, but could find itself in niche sectors where express and personalized implants are necessitated with better fit than other methods. This eliminates the need of time-consuming adjustments and shaping of mass-produced devices during surgery, while the patient is under anesthesia, reducing the risk of medical complications. In the field of bone regeneration, personalized implants can be produced with classic milling approach of preshaped implants but one of the main advantages for AM technologies is the ability to produce clinically relevant printable biomaterials having both biological and physical properties targeted specifically to the patient's conditions (fracture location, segmental bone defect, size, biology, and the patient's comorbidities), which cannot be achieved with other methods. Additive manufacturing also permits high speed production of bespoke implants specifically designed for a patient in line with the surgeon's surgical planning. In addition, manufacturing could occur at the hospital. Bioprinting is a new frontier of 3-D printing technology. Bioprinting involves the incorporation of either living cells or other biological elements within the biomaterial implants for automated implant/tissue manufacturing. Driven by innovations in AM, 3-D printable biomaterials and breakthroughs in 3-D bioprinting technology make the future possibilities of this technology endless.

Classic references | Review references

10 References

1. **Hayes JS, Richards RG.** The use of titanium and stainless steel in fracture fixation. *Expert Rev Med Devices.* 2010 Nov;7(6);843–853.
2. **Perren SM, Pohler O, Schneider E.** Titanium as implant material for osteosynthesis applications. In: Brunette DM, Tengvall P, Textor M, et al, eds. *Titanium in Medicine*. 1st ed. Berlin Heidelberg New York: Springer-Verlag; 2001.
3. **Perren SM, Gasser B.** Materials in bone surgery. *Injury.* 2000 Dec;31(Suppl 4):D1–D80.
4. **Tonino AJ, Davidson CL, Klopper PJ, et al.** Protection from stress in bone and its effects. Experiments with stainless steel and plastic plates in dogs. *J Bone Joint Surg Br.* 1976 Feb;58(1):107–113.
5. **Perren SM, Cordey J, Rahn, et al.** Early temporary porosis of bone induced by internal fixation implants. A reaction to necrosis, not to stress protection? *Clin Orthop Relat Res.* 1988 Jul;(232):139–151.
6. **Aitchison GA, Johnstone AJ, Shepherd DE, et al.** A comparison of the torsional performance of stainless steel and titanium alloy tibial intramedullary nails: a clinically relevant approach. *Biomed Mater Eng.* 2004;14(3);235–240.
7. **Case CP, Langkamer VG, James C, et al.** Widespread dissemination of metal debris from implants. *J Bone Joint Surg Br.* 1994 Sep;76(5):701–712.
8. **Keegan GM, Learmonth ID, Case CP.** Orthopaedic metals and their potential toxicity in the arthroplasty patient. *J Bone Joint Surg Br.* 2007 May;89(5):567–573.
9. **Devine DM, Leitner M, Perren SM, et al.** Tissue reaction to implants of different metals: a study using guide wires in cannulated screws. **Eur Cell Mater.* 2009 Oct;18:40–48.
10. **ap Gwynn I, Wilson C.** Characterizing fretting particles by analysis of SEM images. **Eur Cell Mater.* 2001 Jan;1:1–11.
11. **Kasai Y, Iida R, Uchida A.** Metal concentrations in the serum and hair of patients with titanium alloy spinal implants. *Spine (Phila Pa 1976).* 2003 Jun;15:28(12):1320–1326.
12. **Hayes JS, Welton JL, Wieling R, et al.** In vivo evaluation of defined polished titanium surfaces to prevent soft tissue adhesion. *J Biomed Mater Res B Appl Biomater.* 2012 Apr;100(3):611–617.
13. **Hayes JS, Richards RG.** Surfaces to control tissue adhesion for osteosynthesis with metal implants: in vitro and in vivo studies to bring solutions to the patient. *Expert Rev Med Devices.* 2010 Jan;7(1);131–142.
14. **Pearce AI, Pearce SG, Schwieger K, et al.** Effect of surface topography on removal of cortical bone screws in a novel sheep model. *J Orthop Res.* 2008 Oct;26(10):1377–1383.
15. **Hayes JS, Vos DI, Hahn J, et al.** An in vivo evaluation of surface polishing of TAN intramedullary nails for ease of removal. *Eur Cells Mat.* 2009 Sep 21;18:15–26.
16. **Hayes JS, Seidenglanz U, Pearce AI, et al.** Surface polishing positively influences ease of fracture fixation plate and screw removal. *Eur Cells Mat.* 2010 Feb 26;19:117–126.
17. **Klinger MM, Rahemtulla F, Prince CW, et al.** Proteoglycans at the bone-implant interface. *Crit Rev Oral Biol Med.* 1998;9(4):449–463.
18. **Hayes JS, Khan IM, Archer CW, et al.** The role of surface microtopography in the modulation of osteoblast differentiation. *Eur Cells Mat.* 2010 Jul 21;20:98–108.
19. **Tay SC, Theo LC.** Soft tissue complications in osteosynthesis. In: Herren DB, Nagy L, Campbell D, eds. *Osteosynthesis in the Hand: Current Concepts.* Basel: Karger; 2008;135–141.
20. **Sinicropi SM, Su BW, Raia FJ, et al.** The effects of implant composition on extensor tenosynovitis in a canine distal radius fracture model. *J Hand Surg Am.* 2005 Mar;30(2):300–307.
21. **Meredith DO, Eschbach L, Riehle MO, et al.** Microtopography of metal surfaces influence fibroblast growth by modifying cell shape, cytoskeleton and adhesion. *J Orthop Res.* 2007 Nov;25(11):1523–1533.
22. **Moriarty TF, Debefve L, Boure L, et al.** Influence of material and microtopography on the development of local infection in vivo: experimental investigation in rabbits. *Int J Artif Organs.* 2009 Sep;32(9):663–670.
23. **Neuhoff D, Thompson RE, Frauchiger VM, et al.** Anodic plasma chemical treatment of titanium Schanz screws reduces pin loosening. *J Orthop Trauma.* 2005 Sep;19(8):543–550.
24. **Moriarty TF, Campoccia D, Nees SK, et al.** In vivo evaluation of the effect of intramedullary nail microtopography on the development of local infection in rabbits. *Int J Artif Organs.* 2010 Sep;33(9):667–675.
25. **Moriarty TF, Schlegel U, Perren S, et al.** Infection in fracture fixation: can we influence infection rates through implant design? *J Mater Sci Mater Med.* 2010 Mar;21(3):1031–1035.
26. **Moriarty TF, Grainger D, Richards RG.** Challenges in linking preclinical anti-microbial research strategies with clinical outcomes for device-associated infections. **Eur Cell Mater.* 2014 Sep12;28:112–128.
27. **Valko M, Rhodes CJ, Moncol J, et al.** Free radicals, metals and antioxidants in oxidative stress-induced cancer. *Chem Biol Interact.* 2006 Mar 10;160(1):1–40.
28. **Olivieri G, Novakovic M, Savaskan E, et al.** The effects of beta-estradiol on SHSY5Y neuroblastoma cells during heavy metal induced oxidative stress, neurotoxicity and beta-amyloid secretion. *Neuroscience.* 2002;113(4):849–855.
29. **Stevenson S, Hohn RB, Pohler OE, et al.** Fracture-associated sarcoma in the dog. *J Am Vet Med Assoc.* 1982 May;180(10):1189–1196.
30. **Moroni A, Orienti L, Stea S, et al.** Improvement of the bone-pin interface with hydroxyapatite coating: an in vivo long-term experimental study. *J Orthop Trauma.* 1996;10(4):236–242.
31. **D'Este M, Eglin D, Alini M, et al.** Bone regeneration with biomaterials and active molecules delivery. *Curr Pharm Biotechnol.* 2015;16(7): 582–605.
32. **Gothard D, EL Smith, JM Kanczler, et al.** Tissue engineered bone using select growth factors: a comprehensive review of animal studies and clinical translation studies in man. **Eur Cell Mater.* 2014 Oct 6;28:166–207.
33. **Hayes JS, Kahn IM, Archer CW, et al.** The role of surface microtopography in the modulation of osteoblast differentiation. **Eur Cell Mater.* 2010 Jul 21;20:98–108.

* Note: All articles published in *Eur Cell Mater* (publisher AO Research Institute Davos) are open access and can be freely downloaded (www.ecmjournal.org)

11 Acknowledgments

We thank Stephan M Perren for his contribution to this chapter in the second edition of the *AO Principles of Fracture Management*.

1.4 Fracture classification

James F Kellam

1 Introduction

"A classification is useful only if it considers the severity of the bone lesion and serves as a basis for treatment and for evaluation of the results." Maurice E Müller

Fracture localization and severity are important factors influencing the surgeon's choice of treatment and the patient's functional outcome. These factors are often catalogued into a classification that should facilitate communication among physicians, assist physicians in their treatment, aid documentation and research and have a prognostic value for patients [1–3]. Almost every kind of fracture has at least one classification. However, these groupings were usually free-standing and uncoordinated and were not helpful for comparisons [3–5]. What was needed was a classification system that would be universally applicable and universally acceptable. Maurice E Müller and associates set about this monumental task and developed the Müller AO/OTA Classification of Fractures—Long Bones [6] first published in French as the AO Classification ("classification AO des fractures") [6, 7]. The system for long bones has been expanded by the addition of classifications for fractures of the pelvis [8], spine [9], hand [10], and foot [11]. In 1996, the AO Foundation and the Orthopaedic Trauma Association agreed to develop a Fracture Classification Compendium encompassing all appendicular bones, pelvis, and spine based on the principles and definitions of the Müller system [12, 13]. This compendium was updated in 2018 [14]. Children's fractures have also been incorporated into the compendium following initial scientific validation [15–17].

2 Principles of the AO/OTA Fracture and Dislocation Classification (based on the Müller AO Classification)

2.1 Overall structure and attributes

Diagnosis is an ongoing process of collecting information about the fracture. In many clinical situations, treatment decisions can be made before all information is available.

Classification, however, is completed when all information is collected, including intraoperative observations.

The AO/OTA system is based upon well-defined terminology that allows the surgeon to describe consistently the fracture in as much detail as required for the clinical situation. This description is the key to the classification and aids understanding in biomechanical and biological terms. It forms the basis for an alphanumeric code for documentation and research.

The first aim is to identify what Müller called "the essence of the fracture". This is the attribute that gives the fracture its particular identity and enables it to be assigned to one particular type rather than another. The defined terminology translates the prime characteristics of the fracture into words and subsequently codes, allowing it to be classified.

The classification's terminology provides a complete description of the fracture with regard to location (bone segment) and morphology of the fracture (**Fig 1.4-1**).

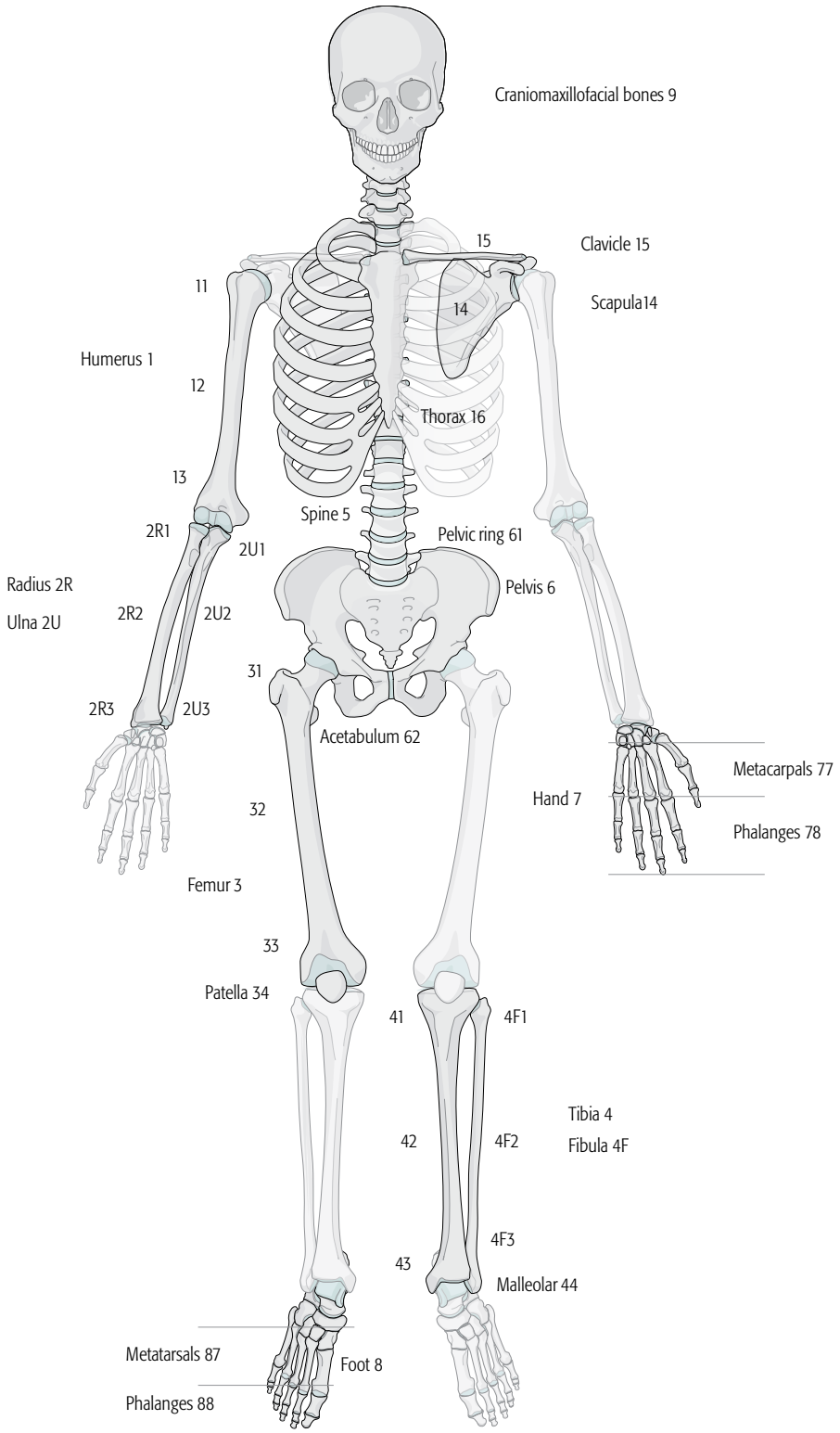

Fig 1.4-1 The AO/OTA coding system for the skeleton. The first number represents the bone and the second number is the anatomical location (proximal end segment = 1; middle or diaphysis = 2; and distal end segment = 3).

2.2 Describing the fracture localization: bones and segments

The bone is described by its anatomical name, followed by the fracture location within the bone. The numbering of the bones has been decided by convention and becomes self-evident from **Fig 1.4-1**. This description is translated into the first number of an alphanumeric code **Fig 1.4-2**.

The identification of the respective segment needs more consideration. Each long bone has three segments: a middle portion or diaphysis and two end segments or metaphyses. The tibia/fibula is an exception due to the malleolar segment (44). Because of the anatomical relationship to the tibia and the universal acceptance of the Weber ankle fracture classification, the malleolar segment is classified as the fourth segment of the tibia/fibula.

In adults, the epiphysis and the metaphysis are fused and are considered one segment—the metaphysis or end segment. The end segment is defined by a square whose sides have the same length as the widest part of the metaphysis (exception: proximal femur). Therefore, each adult long bone has three segments: one shaft (diaphysis) and two end segments (metaphysis). The proximal end segment is labeled 1, the shaft is 2, and the distal end segment is 3 (**Fig 1.4-3**).

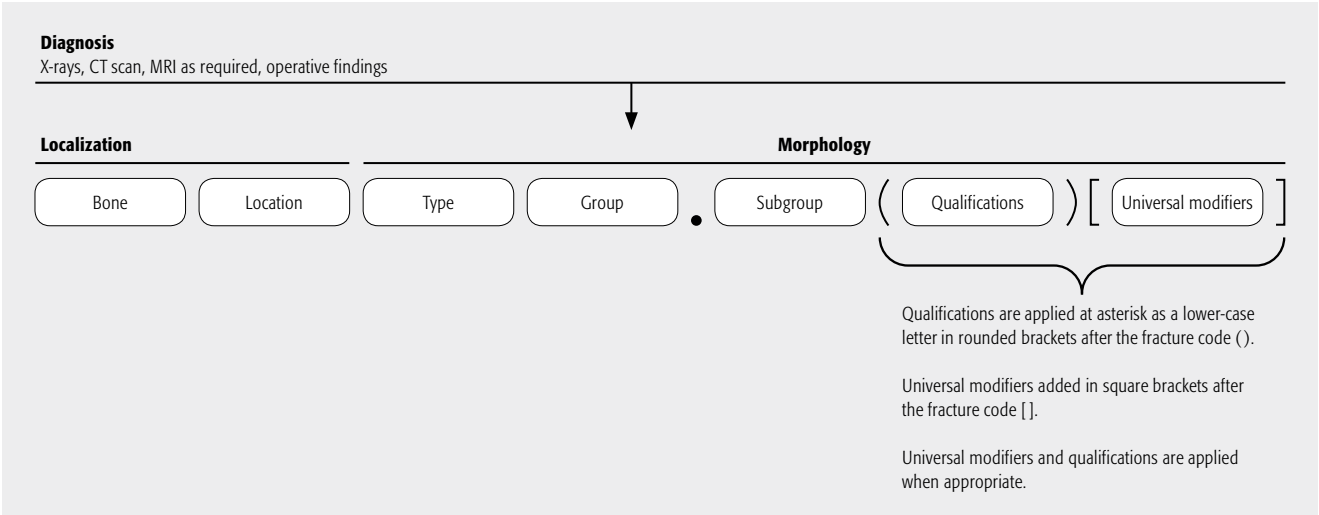

Fig 1.4-2 Alphanumeric structure of the AO/OTA Fracture and Dislocation Classification based on the original Müller classification.

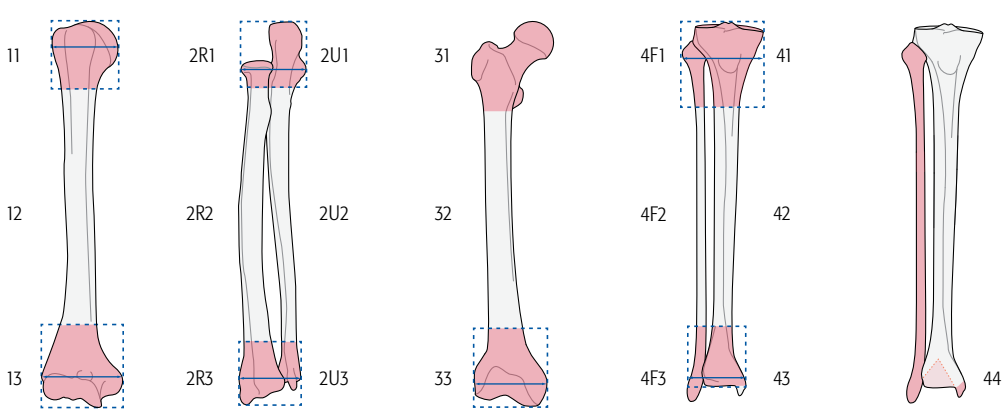

Fig 1.4-3 The anatomical location of the fracture is designated by two numbers: one for the bone and one for its segment. The tibia is an exception with the malleoli representing a fourth segment (44). The proximal and the distal segments of long bones are defined by a square whose sides have the same length as the widest part of the epiphysis (exception: 31).

2.3 Describing the fracture morphology: types, groups, subgroups, qualifiers, and modifiers

The morphology of the fracture is described by precise definitions allowing the surgeon to determine the type, group, and subgroup.

2.3.1 Types

The descriptions of the types differ between diaphyseal and metaphyseal (end-segment) fractures (**Table 1.4-1**). Fractures can be simple, with a single fracture line that produces two fracture fragments or have additional fracture lines to produce multiple fragments (three or more).

The types of diaphyseal fractures are:

- **Simple—type A** with a single circumferential fracture.
- **Wedge—type B** fracture with one or more intermediate fragments. After reduction there is some cortical contact between the main proximal and distal fragments.
- **Multifragmentary—type C** with one or more intermediate fragments. After reduction there is **no contact** between the main proximal and distal fragments.

The types of end-segment fractures are:

- **Extraarticular—type A**, when the fracture does not involve the joint surface.

Segment	Type		
	A	B	C
Proximal 1	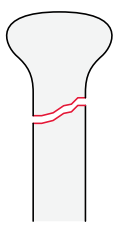	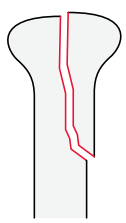	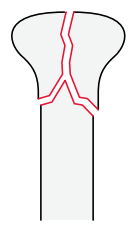
	Extraarticular	Partial articular	Complete articular
Diaphyseal 2			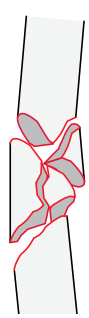
	Simple	Wedge	Multifragmentary
Distal 3		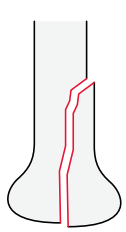	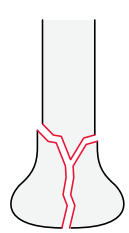
	Extraarticular	Partial articular	Complete articular

Table 1.4-1 Definitions of fracture types for long-bone fractures in adults. For exceptions **see Table 1.4-2**.

- **Partial articular—type B**, when the fracture involves one part of the articular surface while the remainder of the joint remains attached to the metaphysis and diaphysis.
- **Complete articular—type C**, when the fracture has disrupted the joint surface, which is completely separated from the diaphysis.

For the proximal humerus, proximal femur, and malleolar segment, special definitions are applied. The description of proximal humerus uses the term "focal" to describe fracture lines. A unifocal fracture represents one fracture line (type A) and bifocal represents two fractures lines (type B) while type C fractures are articular. The proximal femur is defined as the segment of the proximal femur above a transverse line at the inferior border of the lesser trochanter. These are trochanteric fractures (type A), neck and subcapital fractures (type B), and fractures of the articular surface (type C). The malleolar segment is classified by the level of the lateral malleolar (fibula) fracture with respect to the syndesmosis. The fracture line is infrasyndesmotic (type A), transsyndesmotic (type B), and suprasyndesmotic (type C) (**Table 1.4-2**).

Bone and segment	Type		
	A	B	C
Humerus, proximal 11	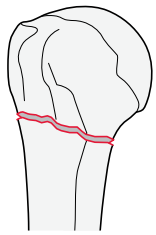 **Extraarticular, unifocal, 2-part** Tuberosity or nonimpacted/impacted metaphyseal	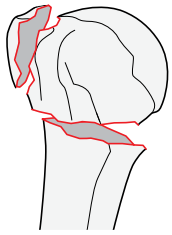 **Extraarticular, bifocal, 3-part** With or without metaphyseal impaction, or with glenohumeral dislocation	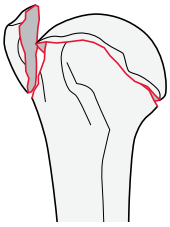 **Articular or 4-part** Displaced, impacted or dislocated
Femur, proximal 31	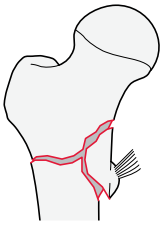 **Trochanteric** Pertrochanteric simple or multifragmentary, or intertrochanteric	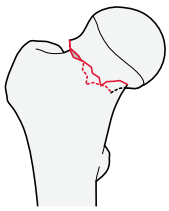 **Neck** Subcapital or transcervical	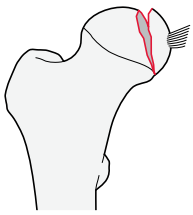 **Head, articular** Split, depression (may involve neck)
Tibia, malleolar segment 44	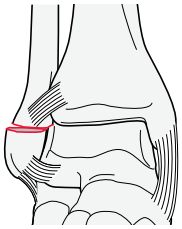 **Infrasyndesmotic** With or without medial lesion	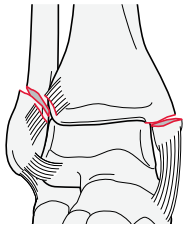 **Transsyndesmotic, fibular** With or without medial or posterior lesion	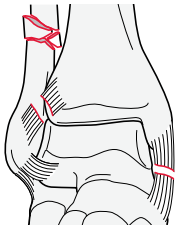 **Suprasyndesmotic, fibular** With or without medial or posterior lesion

Table 1.4-2 Exceptions in the classification of fracture types.

2.3.2 Groups and subgroups

Once a fracture—whichever its bone segment—has been recognized as one of the three fracture types (A, B, or C), it may be described using further fracture groups.

For diaphyseal fractures, the simple fractures are divided into three groups: spiral (A1), oblique (greater than or equal to 30° to a line perpendicular to the long axis of the bone—A2), or transverse (fracture line less than 30° to a line perpendicular to the long axis of the bone—A3). Wedge fractures are divided into two groups: an intact wedge when there is a single wedge fragment (B2) or fragmentary wedge when there is more than one wedge fragment (B3). Multifragmentary (previously termed complex) also has two groups: intact segmental (C2) and fragmentary segmental (C3) (**Table 1.4-3**) (see section 5 in this chapter). For more specialized requirements these groups may be further divided into three subgroups, either based on fracture location or fracture site morphology. In areas of particular complexity, further subgroups known as qualifiers may be applied. These qualifiers may help in the planning of treatment or may be important in predicting the outcome of a particular fracture.

Type	Group 1	Group 2	Group 3
Simple A	Spiral	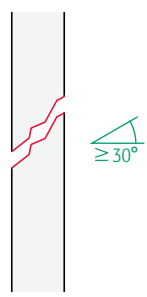 Oblique	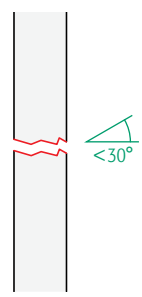 Transverse
Wedge B		Intact	Fragmentary
Multifragmentary C		 Intact segmental	Fragmentary segmental

Table 1.4-3 Classification of fractures of the diaphysis into the three fracture groups.

For end-segment fractures, the metaphyseal extraarticular fracture types are grouped as avulsion (A1), simple (A2), and multifragmentary (A3) while the partial articular fractures are grouped as simple (B1), B2 is variable and based upon the bone involved, and fragmentary (B3). The complete articular fractures are grouped as a simple fracture into the articular surface and simple metaphyseal fracture (C1), simple articular fracture with multifragmentary metaphyseal fractures (C2), and multifragmentary articular with multifragmentary metaphyseal fracture (C3) (**Table 1.4-4**). For more information and further subclassifications (for research purposes), see the 2018 Fracture and Dislocation Classification Compendium in the Journal of Orthopaedic Trauma Supplement [14].

When identifying the information necessary to classify a fracture, the surgeon makes progress in establishing its mechanism, severity, prognosis, and begins to understand the potential problems in treatment. The description may be translated into an alphanumeric code that is useful for computer data acquisition. It may also be used as a method of communication with those who are familiar with the code. However, as the surgeon first has to describe the fracture to make an accurate diagnosis, it is logical to use this description for daily communication among colleagues and for research purposes.

Type	Group		
	1	2	3
Extraarticular A	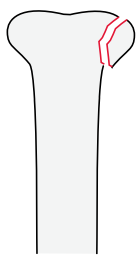	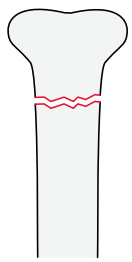	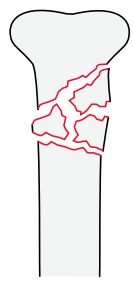
	Avulsion	Simple	Multifragmentary
Partial articular B	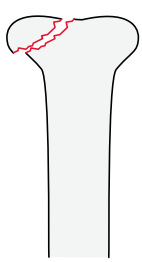	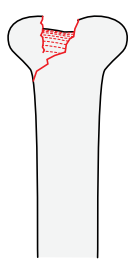	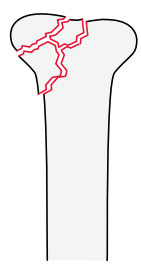
	Simple	Split depression	Fragmentary
Complete articular C	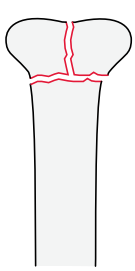	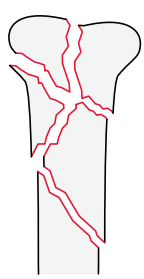	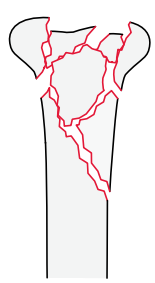
	Simple articular, simple metaphysis	Simple articular, multifragmentary metaphysis	Multifragmentary articular, multifragmentary metaphysis

Table 1.4-4 Classification of fractures of the end segment into the three fracture groups.

3 Defining the classification process

The classification process is straightforward and a fracture cannot be classified fully until all the information is available to the clinician. The following represents the key steps for both diagnosis and classification:

1. History and physical examination determines mechanism, status of the soft tissues, and acuity of the clinical situation.
2. Fracture visualization:
   - Diagnostic imaging: two plain x-rays at right angles are required. This is usually adequate for simple fractures but will miss occult fractures and fail to define fragmentary fractures. Computed tomographic scans enhance understanding of more complex fractures; magnetic resonance imaging is rarely needed. At any time during this process, a diagnosis and treatment decision may need to be made. However, there may be insufficient information to classify definitively the fracture until the treatment is finished.
   - Direct observation of the fractured bones during closed reduction using the image intensifier or open reduction is the final determinant for classification.

3.1 Classifying a fracture step by step

The first obvious question is, "Which bone?" This is followed by, "Which segment?" To assign each fracture to a segment, the center of the fracture must be determined. For a simple fracture it is the midpoint of an oblique or spiral fracture line and for a transverse fracture it is obvious. A wedge fracture has its center at the broadest portion of an intact wedge or the midpoint of a fragmented wedge when reduced. For multifragmentary fractures the center may well have to be determined after reduction when the full extent of the fragmentation is determined. This may force the surgeon to classify after treatment, but the fact that there is a multifragmentary fracture generally guides the treatment decision. A displaced articular fracture will always be classified as an end-segment (metaphyseal) fracture, regardless of its diaphyseal fracture type, since the articular injury is most important for treatment and prognosis. To determine the type, group, and subgroups, the "interrogation" of the fracture usually takes a binary "either/or" approach. For most questions there is only one answer of two or three possibilities.

3.1.1 Diaphyseal fracture

For a diaphyseal fracture of a long bone (**Table 1.4-5**), the first question determines the type of fracture, "Is it simple (A), wedge (B), or multifragmentary (C)?" The second question determines the group, and the third question establishes the subgroup. The 2018 revision of the classification has simplified this process by moving directly to the morphological description of the fractures.

Step	Question	Answer
1	What is the bone?	Specific bone
2	Is the fracture at the end or middle segment?	Middle–diaphyseal segment (2)
3	What is the type?	• Simple (A) • Wedge (B) • Multiframentary (C)
4a	Group: If simple (A), what is the fracture pattern (group)?	• Spiral (1) • Oblique (2) • Transverse (3)
4b	Group: If wedge (B), what is the fracture pattern (group)?	• Intact (2) • Fragmentary (3)
4c	Group: If segmental (C), what is the fracture pattern (group)?	• Intact segmental (2) • Fragmentary segmental (3)
5	Add qualifications and/or universal modifiers	

Table 1.4-5 Steps in identifying diaphyseal fractures.

3.1.2 End-segment (metaphyseal) fracture

In a fracture identified as an end-segment (metaphyseal) fracture (**Table 1.4-6**), the first question asks, "Is the articular surface involved?" and determines if the fracture is extraarticular (type A) or articular. If the fracture is articular, the next question is to determine if the entire articular surface is separated from the diaphysis (complete articular—type C) or not (partial articular—type B). The next question identifies the group. With partial articular fractures the plane of the major fracture line and number of joint fragments determines the group. For complete fractures, the group and subgroup are determined by the amount of articular and metaphyseal fragmentation (single articular fracture line = simple; more than one = multifragmentary). The final question is how the metaphysis is fractured (simple or multifragmentary) (**Fig 1.4-4**, **Video 1.4-1**).

This outline describes the standard method of using the AO/OTA Fracture and Dislocation Classification. However, no classification is all-inclusive and there are some exceptions to this system (**Table 1.4-2**). These are based on anatomical variations—such as the shoulder (11) and hip (31)—or widespread accepted usage, such as for the ankle (44) (**Fig 1.4-2**).

Step	Question	Answer
1	What is the bone?	Specific bone
2	At which end is the fracture located?	• Proximal (1) • Distal (3)
3	Type: Does fracture enter the joint surface (type)?	• No–extraarticluar (A), go to step 5 • Yes–articular (B or C), go to step 4
4a	Type: If articular, is it partial (part of the joint attached to the metaphysis)?	Yes (B type), go to step 6
4b	Type: If articular, is it complete (no part of the joint is attached to the metaphysis)?	Yes (C type), go to step 7
5	Group: If extraarticular (A), what is the fracture pattern?	• Avulsion (1) • Simple (2) • Multifragmentary (3)
6	Group: If partial articular (B), what is the fracture pattern?	• Simple (1) • Split depression (2) • Fragmentary (3)
7	Group: If complete articular (C), what is the articular fracture pattern?	• Simple (1) • Multifragmentary (2)
8	Subgroup: If complete articular (C), this depends on the articular and metaphyseal patterns.	• Simple articular–simple metaphyseal (1) • Simple articular–multifragmentary metaphyseal (2) • Multifragmentary articular with multifragmentary metaphyseal (3)
9	Add qualifications and/or universal modifiers	

Table 1.4-6 Steps in identifying end-segment fractures.

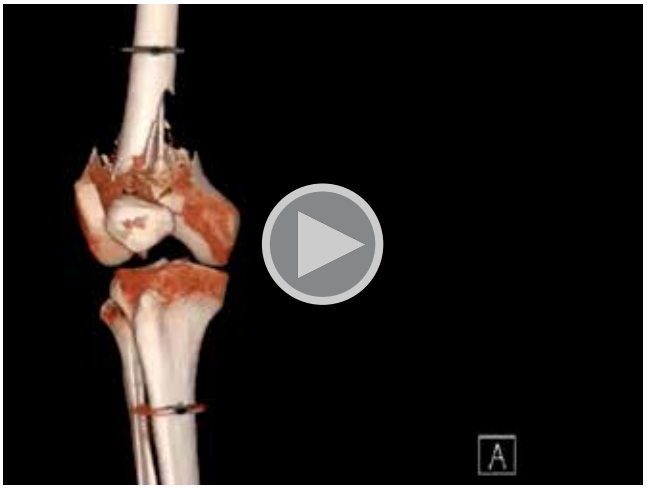

Video 1.4-1 A 3-D computed tomography of distal femoral fracture which demonstrates metaphyseal fracture lines and intraarticular fracture lines, making it a 33C3 fracture.

4 Validation of the classification

A fracture classification must be reliable, accurate and have content validity. Reliability evaluates how well-repeated applications of the classification process on the same fracture agree with each other.

Interobserver reliability is influenced by:
- Timing of classification
- Type and training of the observer(s): expert surgeon, trainee, research assistant, or radiologist
- Use of recording tool(s): a measurement made on the diagnostic images using a ruler, a set of square patterns on a transparency, or the use of specific classification software [16]
- A systematic and standardized approach for coding
- The classification method: a single classification or a consensus classification between two or more observers

Accuracy measures how well classification diagnoses agree with the true fracture status (the gold standard). Content validity means that the classification encompasses all potential observable fractures. The determination of these parameters, before a classification system is applied in clinical practice, is called classification validation [5, 6, 18–20]. Once a classification is validated then it may be reliable to use as the basis for outcome studies. Few classifications have been validated and even fewer have been used to predict outcomes.

Fig 1.4-4a–b AO/OTA Fracture and Dislocation Classification of a fracture. The bone is the femur (3) and fracture is located in the distal end segment (3). The type of fracture is complete articular (C) and the group is multifragmenary articular and multifragmentary metaphyseal (3). The subgroup is metaphyseal diaphyseal multifragmentary (3) further defining the complex nature of the metaphysis. The complete classification is a complete end segment femoral fracture with a multifragmentary articular fracture with multifragmentary metaphyseal diaphyseal extension (33C3.3).

5 Revision process

When the Orthopaedic Trauma Association (OTA) and AO Foundation agreed to publish the compendium in 1996, a 10-year review process was instituted [12]. The first revision was done in 2007 [13]. The second revision began in 2014 for publication in 2018 [14]. The purpose of this latest revision was to:
- Review, update, and simplify codes based on common usage and frequency
- Add new classifications or modify existing definitions based on literature reviews
- Address concerns with existing terminology

A priority for the revision was to maintain the original principles and definitions of the Comprehensive Classification of Fractures (CCF) [6].

The important changes in the 2018 revision are:
- The terms "complex" and "multifragmentary" have created confusion in their application. "Complex" has been replaced with "multifragmentary" to more accurately describe the fracture patterns defined by this term. Multifragmentary will no longer apply to both wedge and complex (diaphyseal types B and C fractures). There will be three types of diaphyseal fractures—simple, wedge and multifragmentary. "Multifragmentary" when used as a subgroup description for types B and C is replaced with "fragmentary".
- The division of the diaphysis into thirds is now optional.
- Many of the qualifications and subqualifications of the first two compendiums were repetitious from bone to bone and fracture to fracture. In a survey of users, they were not routinely used. To simplify the usage, the common modifiers were placed in a list called Universal Modifiers. Certain qualifications were fracture specific and these were left as qualifications with their specific fracture.

- A modification to the proximal tibia classification (as suggested by Mauricio Kfuri and Joseph Schatzker) to define the articular surface in quadrants and better localize significant joint fragmentation or displacement is added as a qualification to types B and C for proximal tibial fractures [21–23].
- To facilitate data entry and lessen the error rate in coding, the hyphen in all codes has been removed.
- The Neer classification of proximal humeral fractures has been introduced into the code description to facilitate the clinician's comprehension of the terms unifocal and bifocal fractures.
- The proximal femoral classification terminology has been defined and codes revised to better represent fracture stability and displacement.
- The addition of a fibular fracture code based on the principles of the CCF provides an opportunity to classify fibular fractures not associated with malleolar fractures.
- It is difficult to code complex injuries, such as the terrible triad of the elbow and the transolecranon fracture dislocation. This is because fractures of both bones of the forearm were placed into one code. This also made the application of the principles difficult for the radius and ulna. The committee decided to separate the bones and classify fractures in each bone. This simplifies the process and when combined with the universal modifiers makes classification of complex injuries about the elbow more consistent and accurate. It also follows the ICD-10 system where each bone is coded separately.

It was recognized by the AO/OTA International Comprehensive Classification of Fractures and Dislocations Committee that this revision must maintain the principles and definitions of the CCF and the prior two compendiums. The committee also realized that this would change some of the coding. The 2018 revision represents a streamlining of the 2007 version, providing a more concise and clinically relevant version. The user will be able to choose the version that best meets their needs for clinical documentation, education, or research. It is hoped that the integration of other standard classifications into the codes will be of value to other orthopedic subspecialties.

6 Conclusion

Fracture classification is extremely important for clinical decision making and research in fracture management. Müller's comprehensive classification gives us the basis for a universal system to do this. The key is a logical structure with clearly defined nomenclature and set of definitions that allow accurate and consistent communication between clinicians and researchers.

7 Classification terminology

This classification is based on the understanding and application of well-defined terms. It has been shown that the accuracy of application of any classification is dependent on the use of defined terminology. As well as the glossary at the end of the book, the following list of terms used in classification may be helpful to understand this chapter and use the classification effectively.

Classification process: The method by which surgeons allocate fractures to respective categories. Such a process can be understood as a diagnostic test.

Fracture classification system: The set of organized fracture categories and its structure based on a defined fracture diagnosis.

Fragmentary fracture: The term is used here to describe a wedge or multifragmentary segmental fracture in the fracture groups.

Impacted fracture: A fracture in which the opposing bone surfaces are driven into each other and behave as a single unit. This is a combined clinical and radiological diagnosis.

Multifragmentary fracture: A fracture with more than one fracture line so that there are three or more pieces. The proximal and distal fragments will not have contact following reduction. The term is used here as a fracture type.

Fragmentary depression fracture: A partial articular fracture in which part of the joint is depressed and there are more than three articular fracture fragments.

Pure depression fracture: An articular fracture in which there is only a depression of the articular surface due to impaction and without a split. The depression may be central or peripheral.

Split fracture: A partial articular fracture in which there is a longitudinal metaphyseal and articular split, without any additional osteochondral lesion or articular impaction.

Classic references | Review references

8 References

1. **Rockwood CA, Green DP, Bucholz RW, et al.** *Rockwood and Green's Fractures in Adults*. 4th ed. Philadelphia New York: Lippincott-Raven; 1996.
2. **Browner BD, Jupiter JB, Levine AM, et al.** *Skeletal Trauma—Fractures, Dislocations, Ligamentous Injuries.* 2nd ed. Philadelphia London Toronto Montreal Sydney Tokyo: WB. Saunders; 1998.
3. **Bernstein J, Monaghan BA, Silber JS, et al.** Taxonomy and treatment—a classification of fracture classifications. *J Bone Joint Surg Br.* 1997 Sep;79(5):706–707.
4. **Colton CL.** Telling the bones. *J Bone Joint Surg Br.* 1991;73(3):362–364.
5. **Colton CL.** Fracture classification—A response to Bernstein et al. *J Bone Joint Surg Br.* 1997 Sep;79 (5):708–709.
6. **Müller ME, Nazarian S, Koch P, et al.** *The Comprehensive Classification of Fractures of Long Bones.* 1st ed. Berlin, Heidelberg, New York: Springer-Verlag; 1990.
7. **Müller ME, Nazarian S, Koch P.** *Classification AO des fractures. Tome I. Les os longs*. 1st ed. Berlin: Springer-Verlag; 1987. French
8. **Tile M.** *Fractures of the Pelvis and Acetabulum.* 3rd ed. Philadelphia: Williams & Wilkins; 2003.
9. **Magerl F, Aebi M, Gertzbein SD, et al.** A comprehensive classification of thoracic and lumbar injuries. *Eur Spine J.* 1994;3(4):184–201.
10. **Petracic B, Siebert H.** AO Classification of fractures of the hand bones. *Handchir Mikrochir Plast Chir.* 1998;30(1):40–44.
11. **Zwipp H, Baumgart F, Cronier P, et al.** Integral classification of injuries (ICI) to the bones, joints, and ligaments—application to injuries of the foot. *Injury.* 2004 Sep;35(Suppl 2):SB3–9.
12. **Orthopaedic Trauma Association Committee for Coding and Classification.** Fracture and dislocation compendium. *J Orthop Trauma.* 1996;10 (Suppl 1):V–IX, 1–154.
13. **Orthopaedic Trauma Association Committee for Coding and Classification.** Fracture and dislocation compendium. *J Orthop Trauma.* 2007;21(Suppl):1–163.
14. **Meinberg E, Agel J, Roberts C, et al.** Fracture and Dislocation Classification Compendium—2018. *J Orthopaed Trauma.* 2018 Jan;32(Suppl 1)
15. **Audigé L, Bhandari M, Kellam J.** How reliable are reliability studies of fracture classifications? A systematic review of their methodologies. *Acta Orthop Scand.* 2004;75(2):184–194.
16. **Slongo T, Audigé L, Schlickewei W, et al.** Development and validation of the AO pediatric comprehensive classification of long-bone fractures by the Pediatric Expert Group of the AO Foundation in collaboration with AO Clinical Investigation and Documentation and the International Association for Pediatric Traumatology. *J Paediatr Orthop.* 2006;26(1):43–49.
17. **Schneidmüller D, Röder C, Kraus R, et al.** Development and validation of a paediatric long-bone fracture classification. A prospective multicentre study in 13 *European paediatric trauma centres. BMC Musculoskelet Disord.* 2011 May 6;12:89.
18. **Garbuz DS, Masri BA, Esdaile J, et al.** Classification systems in orthopaedics. *J Am Acad Orthop Surg.* 2002;10(4):290–297.
19. **Burstein AH.** Fracture classification systems: do they work and are they useful? *J Bone Joint Surg Am.* 1993;75(12):1743–1744.
20. **Meling T, Harboe K, Enoksen C et al.** How reliable and accurate is the AO/OTA comprehensive classification system for adult long bone fractures? *J Trauma Acute Care.* 2012 Jul;73:224–231.
21. **Luo CF, Sun H, Zhang B, et al.** Three-column fixation for complex tibial plateau fractures. *J Orthop Trauma.* 2010 Nov;24(11):683–692.
22. **Parsons BO, Klepps SJ, Miller S, et al.** Reliability and reproducibility of radiographs of greater tuberosity displacement. A cadaveric study. *J Bone Joint Surg Am.* 2005;87:58–65.
23. **Crist BD, Martin SL, Stannard JP.** Tibial plateau fractures. In: Stannard JP, Schmidt AH, eds. *Surgical Treatment of Orthopaedic Trauma 2nd ed.* New York: Thieme; 2016:913–945.

9 Acknowledgments

We thank Laurent Audigé for his contribution to this chapter in the second edition of the *AO Principles of Fracture Management*. It is also important to recognize the AO/OTA International Comprehensive Classification of Fractures and Dislocations Committee (Eric Meinberg, Julie Agel, James Kellam, Craig Roberts, and Matthew Karam) for their work in updating the classification system.

1.5 Soft-tissue injury: pathophysiology, evaluation, and classification

Brian Bernstein

1 Introduction

The biology of bone healing is dependent on a number of factors, the most important of which is the status of the soft-tissue envelope. Girdlestone likened the bone to a plant with its roots in soft tissue, and this comparison is a powerful image for the trauma surgeon to remember.

The effective treatment of fractures depends on good soft-tissue management.

The energy transfer required to fracture bone also results in damage to the neighboring soft tissue, with a "zone of injury" surrounding any fractured bone. This chapter describes the evaluation, classification, and pathophysiological response to soft-tissue injury, and lays the foundation for the management of the trauma patient.

Open fractures and fractures with severe, closed soft-tissue damage are often associated with polytrauma. Life-saving treatment must always take priority and the surgeon must consider both the local injury and the whole patient. Evaluation of the fracture should also determine the extent of the soft-tissue injury, which will be a key factor in management. The surgeon needs to be familiar with the pathophysiology of the soft-tissue injury and the timing, risks, and benefits of the different treatment options.

Knowledge of advanced wound care and an understanding of the biology of wound healing is as important as knowledge of the various fracture treatment options, which will assist the trauma surgeon in making appropriate management decisions.

2 Pathophysiology and biomechanics

The condition of the wound after injury is determined by several factors, including:

- Type of insult and area of contact (blunt, penetrating, crushed, ballistic, etc)
- Magnitude of the force applied
- Direction of force
- Area(s) of body affected
- Wound contamination
- General physical condition of the patient

A combination of these factors will produce different types of wounds (**Table 1.5-1**). Wounds do not only differ in their physical presentation but also in the type of treatment required and the prognosis for healing [1]. All injuries cause bleeding and tissue destruction. This activates humoral and cellular mechanisms to stop bleeding and resist infection. The sequential healing process starts immediately after trauma and can be divided into three phases:

- Exudative or inflammatory phase
- Proliferative phase
- Reparative phase

Type of force	Type of injury
Sharp, pointed	Stab wound, cut
Blunt	Contusion injury, blow
Extension, twist	Laceration
Shear	Degloving, wound defect, avulsions, abrasion
Combination of forces	Wounds from blows, impaling, bites, and gunshot
Crushing	Traumatic amputation, rupture, crush injury
Thermal	Burns

Table 1.5-1 Types of wounds.

3 Pathophysiological responses in healing

Bioactive proteins, such as growth factors, are crucial for tissue healing and are released with platelet activation, eg, platelet-derived growth factor (PDGF), transforming growth factor (TGF), vascular endothelial growth factor (VEGF), insulin-like growth factor (IGF), epidermal growth factor (EGF). The extracellular matrix (ECM) also affects cellular growth and differentiation, activates the repair system and growth factor release, and is in turn regulated by growth factors, such as TGF-β [2]. These bioactive proteins are histopromotive factors, which set the stage for tissue healing including cellular chemotaxis, proliferation, differentiation, removal of debris, angiogenesis, and the development of ECM. Research into the effect of plasma-based biomaterials on soft tissue and bone healing has shown that soft-tissue repair seems to be positively influenced, and infection rates are lower but conclusive evidence of improved bone healing remains elusive [3].

3.1 Inflammatory phase

In the inflammatory phase, there is an increased interaction between leukocytes and the injured microvascular endothelium. Trauma exposes subendothelial collagen structures, leading to the aggregation of platelets. These release serotonin, adrenaline, and thromboxane-A, causing vasoconstriction and producing cytokines, such as PDGF and TGF-β that have a strong chemotactic and mitogenic effect on macrophages, polymorphonuclear neutrophils, lymphocytes, and fibroblasts. Vasoconstriction and thrombocyte aggregation contribute to clotting and are an important part of the coagulation process to stop bleeding. As an adverse effect the damaged tissue is underperfused, leading to hypoxia and acidosis. The first cells to move from the small vessels into the damaged tissue are polymorphonuclear neutrophils (PMN) and macrophages. Polymorphonuclear neutrophils are mobilized rapidly and produce an extremely vigorous initial response. The main function of macrophages is the removal of necrotic tissue and microorganisms (phagocytosis and secretion of proteases) and the production and secretion of cytokines (PDGF: mitogenic and chemotactic; TNF-α: proinflammatory and angiogenic; β-FGF, EGF, PDGF, and TGF-β: mitogenic [4]).

Macrophages are responsible for the cytokine-induced early activation of immunocompetent cells, the inhibition and destruction of bacteria, and the removal of cell debris from the damaged tissue. However, the capacity of the macrophages for phagocytosis is limited. If their capacity is overloaded by an excessive amount of necrotic tissue, this decreases the antimicrobial activities of the mononuclear phagocytes. Since these phagocytic activities are associated with superoxide production and high oxygen consumption, areas of hypoxia and avascular areas are especially threatened by infection and bacterial biofilm formation. Thus, the pathophysiological rationale for performing radical surgical debridement of dead tissue is to support the phagocytic process of the macrophages.

Chemotactic substances, such as kallikrein, improve vascular permeability and exudation by releasing the nanopeptide, bradykinin, which belongs to the α2-globulin fraction. Originating from tissue debris, prostaglandins stimulate the release of histamine from mast cells and cause local hyperemia that is necessary for the metabolic processes of wound healing. In addition, highly reactive oxygen and hydroxyl radicals are released during the peroxidation of membrane lipids, which cause a further destabilization of the cell membranes. These mechanisms result in an impairment of capillary endothelial permeability that again promotes hypoxia and acidosis in the damaged areas. The infiltrating granulocytes and macrophages with their capacity to resist infection and to engulf cell debris and bacteria (physiological wound debridement) play a key role in the inflammatory response of traumatized tissue and therefore have a decisive effect on the subsequent reparative processes.

3.2 Proliferative and reparative phases

The proliferative phase begins when fibroblasts, followed by endothelial cells, migrate into the area of the wound and proliferate. This is stimulated by mitogenic growth factors. These cells have a series of growth factor receptors on their surfaces and, by paracrine and autocrine processes, release several cytokines and synthesize structural proteins of the extracellular matrix, such as collagen. Fibronectins, proteins detached from the surface of the fibroblasts by hydrolases, facilitate the bonding of type I collagen to α1-chains. This is an important prerequisite for progressive, reparative cell proliferation.

There is a smooth transition to the reparative phase and, simultaneously, the proliferating endothelial cells form ingrowing capillaries, which is the typical characteristic of granulation tissue. At the end of the reparative phase, water content is reduced and the collagen initially formed is replaced by cross-linked collagen type III. Fibrosis and scarring follow. The role of the growth factors in scar formation remains unclear but it seems that TGF-β plays a decisive role [5].

4 Diagnosis and treatment of closed soft-tissue injuries

4.1 Problems of diagnosis and assessment

The absence of a visible wound can cause clinicians to underestimate the severity of a closed injury. The degree of injury and ischemic tissue may not be apparent and this can make diagnosis and therapeutic decisions difficult [6]. Many modern imaging techniques permit qualitative assessment of closed soft-tissue injuries but clinically useful quantitative assessment of damage is lacking. There are no diagnostic criteria that allow definitive, preoperative differentiation between reversibly (living) and irreversibly (dead or dying) damaged tissue. Thus, clinical experience and good judgment remain essential when selecting options for treatment and prognosis. Drugs that can reduce posttraumatic microvascular dysfunction and restore the disturbed microcirculation are being investigated [7].

4.2 Secondary damage

The immune response to trauma results in a drastic increase in leukocyte-endothelial interaction and subsequent loss of endothelial integrity with increased microvascular permeability (**Fig 1.5-1**). This leads to transendothelial leakage of plasma and interstitial edema [8]. Edema may reduce the microvascular blood supply in adjacent areas and this can result in progressive necrosis of skeletal muscle or skin in marginal areas that were not directly affected by trauma. Thus, secondary tissue loss may occur.

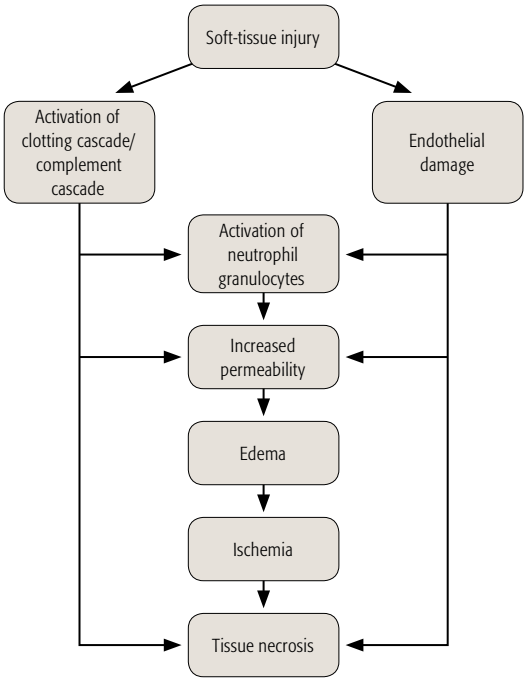

Fig 1.5-1 Pathophysiology of soft-tissue injury.

4.3 Systemic response to soft-tissue injury

Severe soft-tissue injury results in local microvascular and cellular damage and can also lead to a marked systemic inflammatory response due to the release of proinflammatory cytokines (TNF-α, IL-1, IL-6, IL-10). These affect vascular endothelium in various organs, resulting in margination, migration and activation of polymorphonuclear neutrophils, increased capillary permeability, interstitial edema, and an inflammatory response. The systemic inflammatory response syndrome (SIRS) may result in damage to various organs, eg, multiple organ dysfunction syndrome (MODS). The damage is not only to organs such as the lungs (ARDS), liver, gastrointestinal tract, kidneys, myocardium, and central nervous system but also affects the entire immune system: sepsis remains the most common cause of death in these patients. Thus, the pathophysiological changes in damaged tissue after soft-tissue trauma are the product of a vicious cycle.

4.4 Evaluation of soft-tissue injury

4.4.1 Case history

To determine the appropriate choice and timing of treatment, the surgeon needs to know when, where, and how the injury occurred. For instance, prolonged entrapment in a car may indicate the possibility of compartment syndrome, and barnyard injuries have a high risk of infection. Gunshot injuries are influenced by the velocity of the bullet and the associated cavitation, which will result in a significant, occult zone of injury that must not be overlooked.

Most important is the knowledge of the amount and direction of force or energy causing the injury. This determines both the extent of the injury and the necessary steps in treatment. The greater the force, the more serious the damage and sequelae will be.

4.4.2 Systematic examination

Assessment of the skin and muscle

Soft-tissue injuries in closed fractures are less obvious than in an open fracture, but still have enormous importance. Their evaluation can be much more difficult than open injuries and their severity is easily underestimated. Simple abrasions represent an injury of the physiological skin barrier and can allow the development of deep infection.

"Closed skin degloving" occurs when there is shear force, resulting in the skin separating from the underlying fascia without any external break in the skin. The resultant cavity can be filled with serous fluid or hematoma, and the vascularity of the dermis is compromised. The dermis is also denervated and an insensate area of skin, which feels "slippery" to the touch, is pathognomic of a closed degloving injury. Treatment consists of emergent drainage of the collection and pressure dressing. In some instances, an indwelling drain should be left in situ and withdrawn progressively. The aim of this treatment is to allow contact between the separated layers, and acts as an in situ skin graft. The affected skin must be observed diligently to ensure no necrosis occurs. If a degloving injury occurs with concomitant breach in the skin, it is termed an "open degloving injury". The management is much the same, however if there is an associated fracture this injury should be regarded as an open fracture.

Research has shown that the intradermal collection is at risk for contamination and may act as a source of deep infection (The Morel-Lavallée lesion in pelvic and acetabular fractures is an example) [9, 10].

"Fracture blisters" are formed when there is significant acute swelling of a limb, with resultant shearing at the epidermal level. Fracture blisters are sterile and best treated by anti-edema measures alone. However, blood-filled fracture blisters are "more serious" blisters, as they are indicative of significant deeper tissue damage and potential healing delay (**Fig 1.5-2**).

Fig 1.5-2a–b Proximal tibial fracture with severe soft-tissue injury. Evolution of fracture blisters on day 2 (**a**) and day 14 (**b**).

In open fractures (see chapter 4.2), the wound should be covered by a moist sterile dressing after it has been thoroughly irrigated in the emergency department and this should not be removed until the patient is in the operating room. Only there, and under sterile conditions, can the full extent of the soft-tissue damage be assessed. Some authors suggest that a photograph is important to facilitate surgical planning for the team. There is a significant increase in reported infection rate with repeated exposure of the wound. Further evaluation in the operating room under sterile conditions and optimum vision is useful and may affect the final classification and prognosis. The degree of wound contamination is important and influences the course and outcome of the injury. Foreign bodies and dirt particles give useful information about the level of contamination and help the surgeon with grading these injuries. High-velocity gunshot wounds, blasts, and farming injuries are considered as severely contaminated.

Surgical debridement becomes a diagnostic exercise as skin edges, subcutaneous fat, muscles, and fascial elements are checked for viability and bleeding. The definitive assessment of a soft-tissue injury requires an experienced surgeon because it determines the treatment protocol as well as the surgical approach and choice of implant for fracture fixation [11].

Assessment of the vascular status

It is mandatory to determine the vascular status of all injured limbs. The peripheral pulses, temperature, and capillary refill must be checked and compared with the uninjured side. The vascular status must be recorded in the medical history. Although the absence of a palpable pulse is an important pointer to potential vascular damage, the presence of a pulse or good capillary refill does not necessarily guarantee an intact vascular supply. Doppler examination of the injured and unharmed extremity may be helpful for screening and the ankle-brachial index (ABI) is also useful [12]. In all cases of doubt or where the case history, the physical examination, or the radiographic fracture pattern suggests vascular damage, the opinion of a vascular surgeon must be obtained urgently. Management strategies include urgent angiography in the vascular radiology suite, immediate on-table angiography or direct exposure of the injured vessel. The method chosen depends on local facilities, timing, and protocols.

Assessment of the neurological status

Neurological assessment can be difficult in unconscious patients with multiple injuries. However, examination of the reflexes and the response to strong, painful stimuli give some indication of major deficits. These examinations must

be performed repeatedly because the confirmation of a major nerve deficit can be decisive in the choice between salvage versus amputation in severely injured extremities.

Assessment of the fracture

The radiographic fracture pattern provides essential indirect information about the soft-tissue injury and can show foreign bodies, dirt, soft-tissue density and entrapped air around and/or distal to the fracture site. The force absorbed by the bone is indicated by the fracture pattern, and indicates the equivalent force likely to have been applied to the soft tissue.

At the time of debridement, careful inspection of bone fragments, their relationship to the soft-tissue envelope and blood supply, as well as the information obtained from x-rays, help to optimize assessment of the damage.

4.5 Compartment syndrome

Compartment syndrome is due to raised pressure in a closed fascial or osteofascial space that results in local tissue ischemia. This will compromise neuromuscular function and may result in muscle necrosis with loss of function, infection, and possible amputation [13, 14].

Compartment syndrome is seen most frequently in the lower leg, but can also occur in the forearm, buttock, thigh, hand, and foot. It may occur at any time during the first few days after trauma or surgery.

4.5.1 Pathophysiology

In closed fractures with soft-tissue injury, the threat posed by compartment syndrome is not to be underestimated. It is triggered by an increase in intramuscular volume and pressure within a closed osteofascial space, at a level above a critical microvascular perfusion pressure [15]. The cause may be exogenous pressure (eg, restrictive plaster casts) or endogenous pressure due to an increase in volume within the compartment. The latter results from hemorrhage, perivascular infusions, or edema that is caused by abnormal capillary permeability, which in turn is due to prolonged ischemia or reperfusion (**Fig 1.5-3**). If impairment of the microcirculation from increased tissue pressure persists, severe and irreversible neuromuscular dysfunction due to hypoxia will result and lead to muscle necrosis and axonotmesis.

Originally, it was believed that the threshold for compartment syndrome was a constant intramuscular pressure more than 30 mm Hg. However, it is now recognized that the key factor is the difference between the diastolic blood pressure (dBP) and the intramuscular pressure (IMP). This determines the mean muscle perfusion pressure (MPP/DeltaP), for example: 78 (dBP) – 51 (IMP) = 27 (MPP/DeltaP).

$$dBP - IMP = MPP/DeltaP$$

If the muscle perfusion pressure is less than 30 mm Hg, there will be hypoxia and anaerobic cell metabolism. It is important to note that blood pressure has a direct relationship to perfusion pressure. Thus, multiply injured patients with hypotension and hypoxia are predisposed to compartment syndrome. Injuries with a high risk of developing compartment syndrome include vascular injuries with peripheral ischemia and reperfusion, high-energy trauma, severe soft-tissue crush, and complex fractures of the tibia [11]. The aim of any therapeutic procedure must be immediate compartment decompression by dermatofasciotomy to achieve reperfusion of the capillary bed.

Acute compartment syndrome is commonly progressive in nature, and requires urgent attention to avoid irreversible muscle and tissue damage. The law of Laplace relating to membrane permeability and equilibrium applies.

4.5.2 Clinical manifestation of compartment syndrome

A compartment is an anatomical space, bounded on all sides by bone or deep fascia, which contains one or more muscles. In addition, the surrounding epimysium, the skin, or a constricting dressing can create such an envelope with limiting boundaries. The relative inelasticity of the enveloping wall means that if the muscle tissue swells, the pressure in the osteofascial envelope will increase.

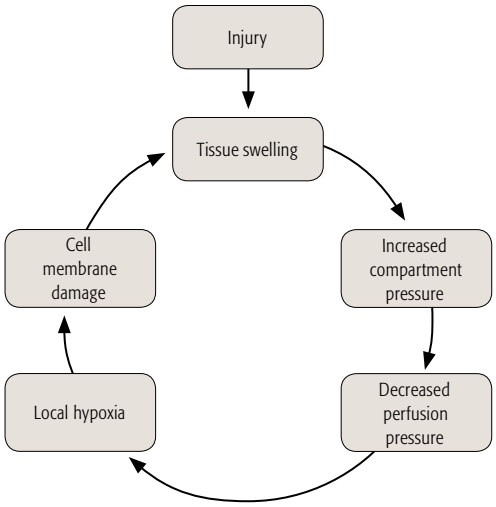

Fig 1.5-3 Compartment syndrome is due to a vicious positive feedback cycle.

The diagnosis of compartment syndrome in a conscious patient is usually made by the clinical manifestation of unrelenting ischemic muscle pain that is unrelieved by the expected amounts of analgesia (pain "out of proportion").

Any nerve traversing the involved compartment will become ischemic, often causing numbness and tingling in the nerve distribution. Reporting of these symptoms requires an alert, conscious, and cooperative patient whose perceptions or response have not been changed by distracting trauma, head injury, alcohol, or drugs.

Clinical examination will show a tense, swollen compartment; palpation of the compartment will reproduce the pain and passive stretching of the digital muscles of the involved compartment will also increase the pain. This sign is helpful, although not specific. A sensory deficit in the nerve traversing the compartment may or may not be present. Motor weakness is a late change. Pulses are always palpable in compartment syndrome because in a normotensive patient the muscle pressure rarely exceeds the systolic level. Persistent, unexplained tachycardia or a high-lactate level should also be regarded as a possible sign of compartment syndrome in the unconscious patient once other causes (eg, hypovolemia) have been excluded.

The balance between intramuscular compartment pressure and the microvascular pressure will determine the adequacy of perfusion, and hence the oxygen supply of the muscle.

Tissue necrosis will result when interstitial pressure is increased beyond an individuals' threshold for some time. Patients who suffer untreated or overlooked compartment syndrome will develop ischemic contracture. This results in a contracted, nonfunctional limb (Volkmann's ischemic contracture). The surgeon must be aware that all limb injuries are at risk of compartment syndrome. It is most common in high-energy fractures and crush injuries but can also be seen after simple injuries and without any associated fracture. Patients receiving anticoagulant therapy are at high risk and young males have a higher risk of compartment syndrome, possibly because they have relatively thick and inelastic fascia. Compartment syndrome can also develop after reperfusion of an ischemic limb. This is seen in patients who have been unconscious for a number of hours (eg, drug addicts) and also after repair of arterial injuries. Therefore, trauma patients who have an arterial repair or reconstruction must have prophylactic distal dermatofasciotomies (**Fig/Animation 1.5-4**).

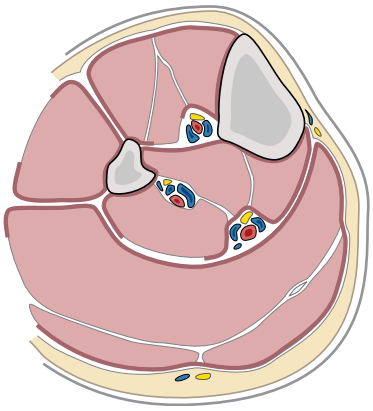

Fig/Animation 1.5-4 Effects of increasing compartment pressure.

4.5.3 Diagnosis of compartment syndrome

The differential diagnosis includes arterial injury and peripheral nerve injury: absent pulses indicate arterial injury; peripheral nerve injury is a diagnosis of exclusion. A high degree of suspicion is essential if cases of compartment syndrome are not to be missed. The surgeon must be vigilant as symptoms and signs may be minimal. Medical and nursing personnel must be aware that analgesics can mask symptoms, which can be a particular problem following surgery when patient-controlled analgesia (PCA) is administered. Excessive use of PCA should alert the team to the possibility of compartment syndrome. Surgeons should also be aware that patients with a peripheral nerve injury may have altered sensation and not experience pain with compartment syndrome.

Compartment syndrome can also be diagnosed by tissue pressure measurements. This is helpful in situations where clinical examination is unreliable, such as in head injury or intoxicated patients. The tissue pressure is usually elevated before signs and symptoms develop and so pressure measurements can be used to diagnose an impending compartment syndrome. They can also be used to monitor patients at high risk of developing this complication following surgery. The criteria of Heppenstall [15] stating that muscle perfusion is compromised when the compartment pressure is within 20 mm Hg of dBP has been used as a guide for many years, but now the calculation of the MPP/DeltaP as described is recommended.

Factors that will affect the accuracy of pressure measurements include:

- Correct calibration and use of equipment
- Correct anatomical placement of the catheter tip
- Depth of needle insertion
- The position and stability of the extremity during testing

As an example, while the measurement of the anterior and lateral compartments of the leg is fairly straightforward, the deep posterior compartment measurement is notoriously unreliable, and the potential "fifth" compartment (the tibialis posterior muscle) is often inadequately assessed.

Ultrasound guidance may be used to assist in catheter placement and various techniques described for catheter placement for the diagnosis of chronic exercise-induced compartment syndrome (CECS) may translate for the acute situation as well. However, in the acute traumatic setting the conditions for accurate diagnosis is less than favorable.

Pressure measurements can be taken by various techniques. The infusion technique is simple and continuous, but may worsen the syndrome and usually has a higher pressure threshold than other methods. The wick technique uses some fine material inside the catheter to maintain the opening to allow continuous monitoring. The stick technique is usually a reliable, simple system to use but the appropriate equipment must be purchased. Over the past few years, fine-wire, intracompartment pressure transducers have become available. These are simple and reliable and allow continuous pressure monitoring in the perioperative period [16]. Advances in diagnostic modalities include magnetic resonance imaging, near-infrared spectroscopy and color Doppler ultrasound; however, these are more appropriate for the diagnosis of CECS [17].

Once the diagnosis is considered, compartment syndrome must be actively excluded. If this is not possible, urgent senior clinical review is essential with a low threshold for surgical decompression. The consequence of delayed management is significant morbidity.

4.5.4 Management of compartment syndrome

The initial treatment should include release of all circumferential dressings and elevation of the limb to the level of the heart (to maximize tissue perfusion pressure).

Compartment syndrome is a surgical emergency and the treatment of choice is immediate dermatofasciotomy.

In trauma, percutaneous fasciotomy is not indicated since the skin, as long as it remains intact, acts as a limiting membrane and may sustain compartment syndrome.

Compartment syndrome is most common in the lower leg (**Fig 1.5-5**). All four compartments must be released using either the Mubarak double-incision technique or the parafibular dermatofasciotomy described by Matsen et al [13]. The fibulectomy-fasciotomy, as popularized in the vascular surgical literature, is contraindicated for trauma patients. Even if pressure is increased in only one or two compartments, it is mandatory to completely release all four. This is also the case for every possible location of compartment syndrome in the upper or lower extremity.

The concept to remember is that of increasing the volume of the compartment to allow for the increased pressure demand. A fasciotomy that increases the diameter of the limb by 2 cm results in a 44% increase in the volume, and thus a significant reduction in pressure. Numerous techniques for delayed closure have been proposed. The recommendation of the British Orthopaedic Association Standards for Trauma (BOAST 10) is a useful guideline for management [18]. The likelihood of requiring a split skin graft for tension-free final closure is high.

Fig 1.5-5a–b Clinical pictures after compartment release.
a Live muscles.
b Death of all muscles in the compartment.

5 Open soft-tissue injuries

Open soft-tissue injuries are often termed "compound" in the literature. This is incorrect and outdated nomenclature. Any fracture associated with an open soft-tissue injury is more susceptible to infection due to the breach in skin integrity, and the likelihood of microorganism impregnation or contamination exists. In addition, the release of the extracellular matrix and potential growth factors and chemokines may lead to a delay in bone and soft-tissue healing and increased incidence of nonunion.

The management of an open fracture is addressed specifically in chapter 4.2 but with respect to the soft-tissue injury, knowledge of advanced wound-dressing techniques, including silver nano crystal dressings and negative-pressure wound dressings is mandatory for adequate trauma patient care.

The findings of the LEAP study have challenged much of the dogma around timing of debridement and primary versus secondary wound closure, but these recommendations should be tempered by local logistics and patient and surgeon profile [19, 20].

6 Classification of soft-tissue injury in fractures

A classification of the soft-tissue injury should consider all essential factors and guide treatment. Accurate classification of the injury effectively decreases complications by preventing avoidable treatment errors and should be of some prognostic value. There is also the possibility to monitor and compare standardized treatment protocols. The most commonly used classifications for soft-tissue injuries were devised by Gustilo and Anderson [21, 22], and another by Tscherne [23].

Many problems in the treatment of complex fractures are due to high-velocity injury patterns causing severe soft-tissue damage. The most frequently used classifications have shown limitations for these types of injuries. Brumback and Jones [24] have shown that there is only a moderate interobserver reliability in classifying open fractures using the Gustilo and Anderson classification.

In practice, all classification systems have problems with validation and user compliance, understanding and application. This has led to the development of the alphanumeric AO/OTA Fracture and Dislocation Classification system. However, many surgeons prefer to use the simpler systems with which they are familiar. In short, the classification system utilized should be easily communicated and understood by all involved in patient care.

6.1 Gustilo classification of open fractures

Gustilo and Anderson developed their classification on the basis of a retrospective and prospective analysis of 1,025 open fractures. They initially described three types, but clinical application led Gustilo, Mendoza, and Williams to extend and subdivide the classification of the severe (type III) injuries into subgroups A, B, and C.

- Type I: These are fractures with a clean wound of less than 1 cm in size with little or no contamination. The wound results from an inside-out perforation by one of the fracture ends. The fracture pattern is simple (eg, spiral or short oblique fractures).
- Type II: Skin laceration is longer than 1 cm but the surrounding tissues have minor or no signs of contusion. There is no dead muscle present and the fracture instability is moderate to severe.
- Type III: There is extensive soft-tissue damage, frequently with compromised vascularity with or without severe wound contamination. The fracture pattern is complex with marked fracture instability.

Because of the many different factors occurring in this group, Gustilo [22] proposed three subtypes.

- Type IIIA: Usually results from a high-energy trauma. There is still adequate soft-tissue coverage of the fractured bone, despite extensive soft-tissue laceration or flaps (similar to AO/OTA Classification IO 2).
- Type IIIB: There is extensive soft-tissue loss with periosteal stripping and bone exposure. These injuries are in need of soft-tissue coverage and may be associated with massive contamination (similar to AO/OTA Classification IO 3).
- Type IIIC: Any open fracture associated with an arterial injury requiring repair. It is independent of the fracture type (similar to AO/OTA Classification IO 4).

The Gustilo classification system should be seen as a progressive indication of the wound size, degree of contamination, soft-tissue damage (including vascular) and bone damage (including the presence of periosteal stripping), reflecting the need for simple or complex reconstructive procedures and techniques (**Table 1.5-2**).

6.2 Tscherne classification of open soft-tissue injuries

In the Tscherne classification [23], soft-tissue injuries are grouped into four categories according to severity. The fracture is labeled as open or closed by an "O" or a "C."

- Open fracture grade I (Fr. O 1): The skin is lacerated by a bone fragment from the inside. There is no or minimal contusion of the skin and these simple fractures are the result of indirect trauma (type A1 and A2 fractures according to the AO/OTA classification).
- Open fracture grade II (Fr. O 2): There is a skin laceration with circumferential skin or soft-tissue contusion and moderate contamination. All open fractures resulting from direct trauma (AO/OTA classification type A3, type B, and type C) are included in this group.
- Open fracture grade III (Fr. O 3): There is extensive soft-tissue damage, often with an additional major vessel and/or nerve injury. Every open fracture that is accompanied by ischemia and severe bone comminution belongs in this group. Farming injuries, high-velocity gunshot wounds, and compartment syndrome are included because of their high risk of infection.
- Open fracture grade IV (Fr. O 4): These are subtotal and total amputations. Subtotal amputations are defined by the Replantation Committee of the International Society for Reconstructive Surgery as a "separation of all important anatomical structures, especially the major vessels, with total ischemia." The remaining soft-tissue bridge may not exceed 1/4 of the circumference of the limb.

Cases requiring revascularization are classified as grade III or IV open.

6.3 Tscherne classification of closed fractures

Tscherne developed a specific soft-tissue classification because he realized that closed injuries were frequently underestimated.

- Closed fracture grade 0 (Fr. C 0): There is no or minor soft-tissue injury with a simple fracture from indirect trauma. A typical example is the spiral fracture of the tibia in a skiing injury.
- Closed fracture grade I (Fr. C 1): There is superficial abrasion or skin contusion, simple or medium fracture types. A typical injury is the pronation-external rotation fracture dislocation of the ankle joint. The soft-tissue damage occurs through fragment pressure at the medial malleolus
- Closed fracture grade II (Fr. C 2): There are deeply contaminated abrasions and localized skin or muscle contusions resulting from direct trauma. Imminent compartment syndrome also belongs to this group. The injury results in transverse or complex fracture patterns. A typical example is the segmental fracture of the tibia from a direct blow by a car fender.
- Closed fracture grade III (Fr. C 3): There is extensive skin contusion, destruction of muscle or subcutaneous tissue avulsion (closed degloving). Manifest compartment syndrome and vascular injuries are included. The fracture types are complex.

It is important to recognize that pigmented skin may cloud the assessment of the closed, soft-tissue injury as the contusion may be less visible.

Type	Wound	Contamination	Soft-tissue damage	Bone injury
I	1 cm and less	Clean	Minimal	Simple with minimal comminution
II	1–10 cm	Moderate	Moderate with some muscle damage	Moderate comminution
IIIa	More than 10 cm	High	Severe with associated crush injury	Moderate–soft-tissue cover possible
IIIb	More than 10 cm	High	Severe loss of cover	Requires reconstructive procedures
IIIc	More than 10 cm	High	Severe with vascular injury requiring repair	Requires reconstructive procedures

Table 1.5-2 Gustilo-Anderson Classification.

6.4 AO soft-tissue grading system

Due to limitations of the existing classification systems, including moderate interobserver reliability and the grading of many different injuries into the same subgroup, AO developed a more detailed and precise grading system for fractures with soft-tissue damage. This grading system identifies injuries to the different anatomical structures and assigns them to different severity groups. The skin or integument (I), muscles (M) and tendons (T), and the neurovascular system (NV) are the targeted anatomical structures; the fracture is classified according to the AO/OTA Classification of fractures. The grading of the skin lesion is done separately for open (O) or closed (C) fractures. Each is divided into five severity groups (**Tables 1.5-3–4** and **Figs 1.5-6–15**). Thus, a closed fracture with no apparent skin lesion would be described as IC 1. The digit "1" indicates the least severe injury. IC5 has the most severe soft-tissue damage.

IC 1	No evident skin lesion (**Fig 1.5-6**)
IC 2	No skin laceration, but contusion (**Fig 1.5-7**)
IC 3	Circumscribed degloving (**Fig 1.5-8**)
IC 4	Extensive, closed degloving (**Fig 1.5-9**)
IC 5	Necrosis from contusion (**Fig 1.5-10**)

Table 1.5-3 AO soft-tissue classification: closed skin lesions (IC).

IO 1	Skin breakage from inside out (**Fig 1.5-11**)
IO 2	Skin breakage from outside in < 5 cm, contused edges (**Fig 1.5-12**)
IO 3	Skin breakage from outside in > 5 cm, increased contusion, devitalized edges (**Fig 1.5-13**)
IO 4	Considerable, full-thickness contusion, abrasion, extensive open degloving, skin loss (**Fig 1.5-14**)
IO 5	Extensive degloving (**Fig 1.5-15**)

Table 1.5-4 AO soft-tissue classification: open skin lesions (IO).

Although there may be considerable damage to a muscle envelope, there is rarely an injury to tendons except in severe injuries (**Table 1.5-5**). The involvement of the neurovascular system (**Table 1.5-6**) always indicates a most severe injury of the kind represented by the Gustilo types IIIB and IIIC and has a high complication rate. Muscle and tendon injuries as well as neurovascular injuries are of high prognostic value for the fate of the extremity.

This system allows a comprehensive description of the entire injury complex. The numbers and letters are useful for computerization, audit, and research. In daily clinical practice it is the use of accurately defined, descriptive terms that aid good decision-making and communication. For example, a simple, closed spiral midshaft fracture of the tibia from skiing with no injury of skin, muscles, tendons, nerves, or vessels is graded: 42-A1.2/IC1-MT1-NV1.

In contrast, **Fig 1.5-16** shows a Monteggia type elbow dislocation fracture with extensive muscle and tendon injury but no neurovascular damage. This is a simple or multiframentary transolecranon anterior fracture dislocation of the elbow, graded as IO5-MT4-NV1. **Fig 1.5-14** illustrates an open, complex, segmental tibial shaft fracture with an open wound greater than 5 cm, muscle defect, and tendon laceration. There is no nerve injury but an injury of the peroneal artery. This injury will be graded as 42C2.3/IO4-MT4-NV3 [25].

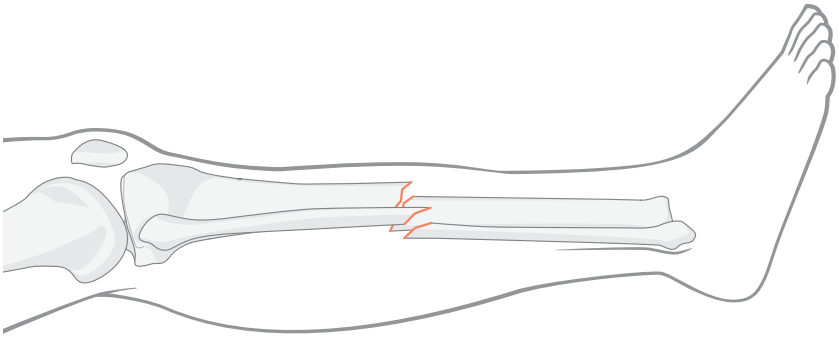

Fig 1.5-6 AO soft-tissue classification: no evident skin lesion (IC 1).

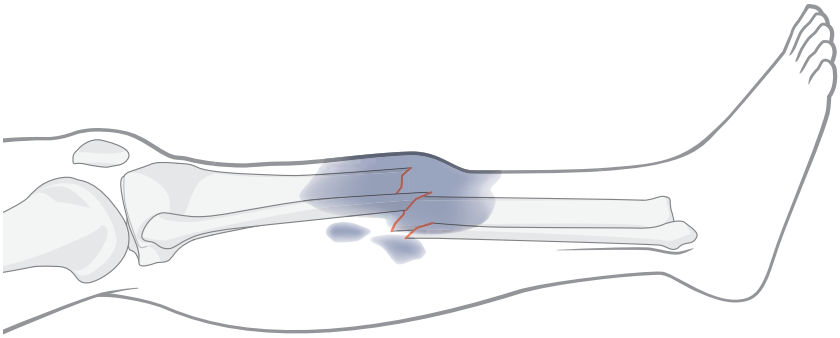

a

b

c

Fig 1.5-7a–c AO soft-tissue classification: no skin laceration but contusion (IC 2).

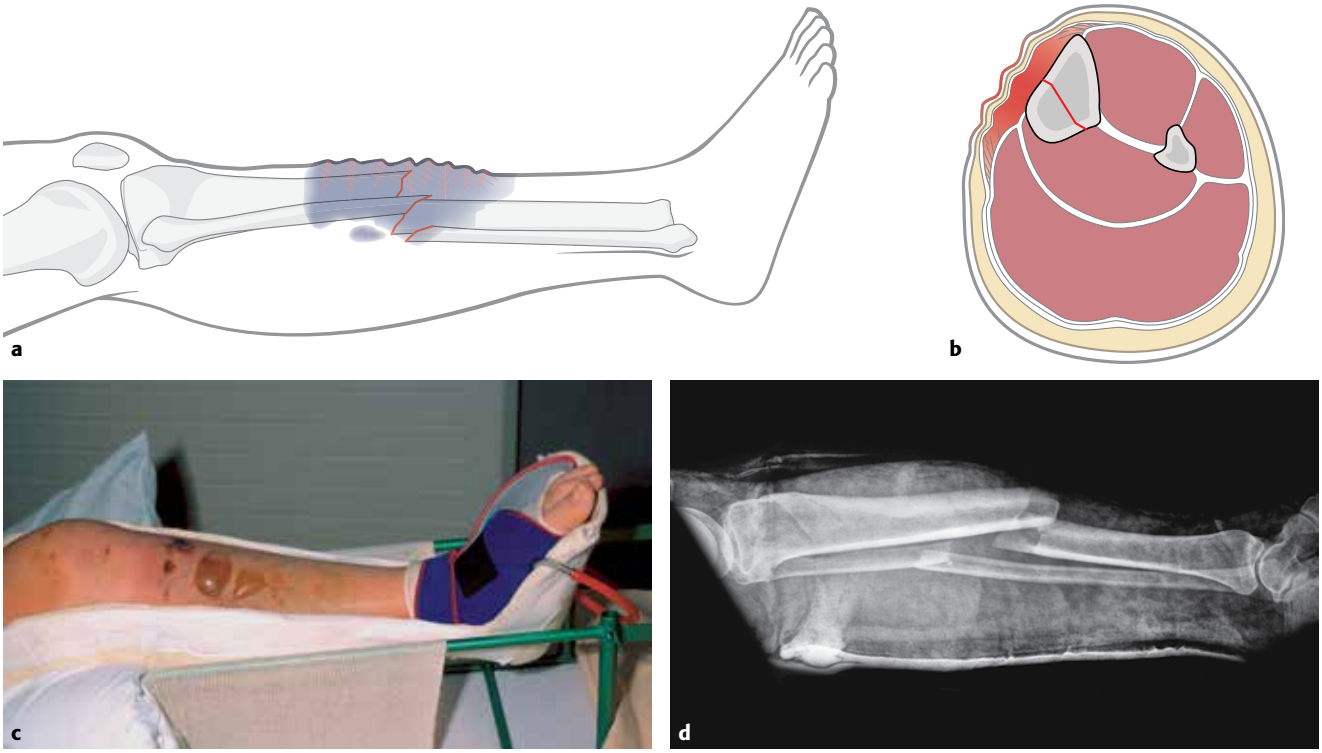

Fig 1.5-8a–d AO soft-tissue classification: circumscribed degloving (IC 3).

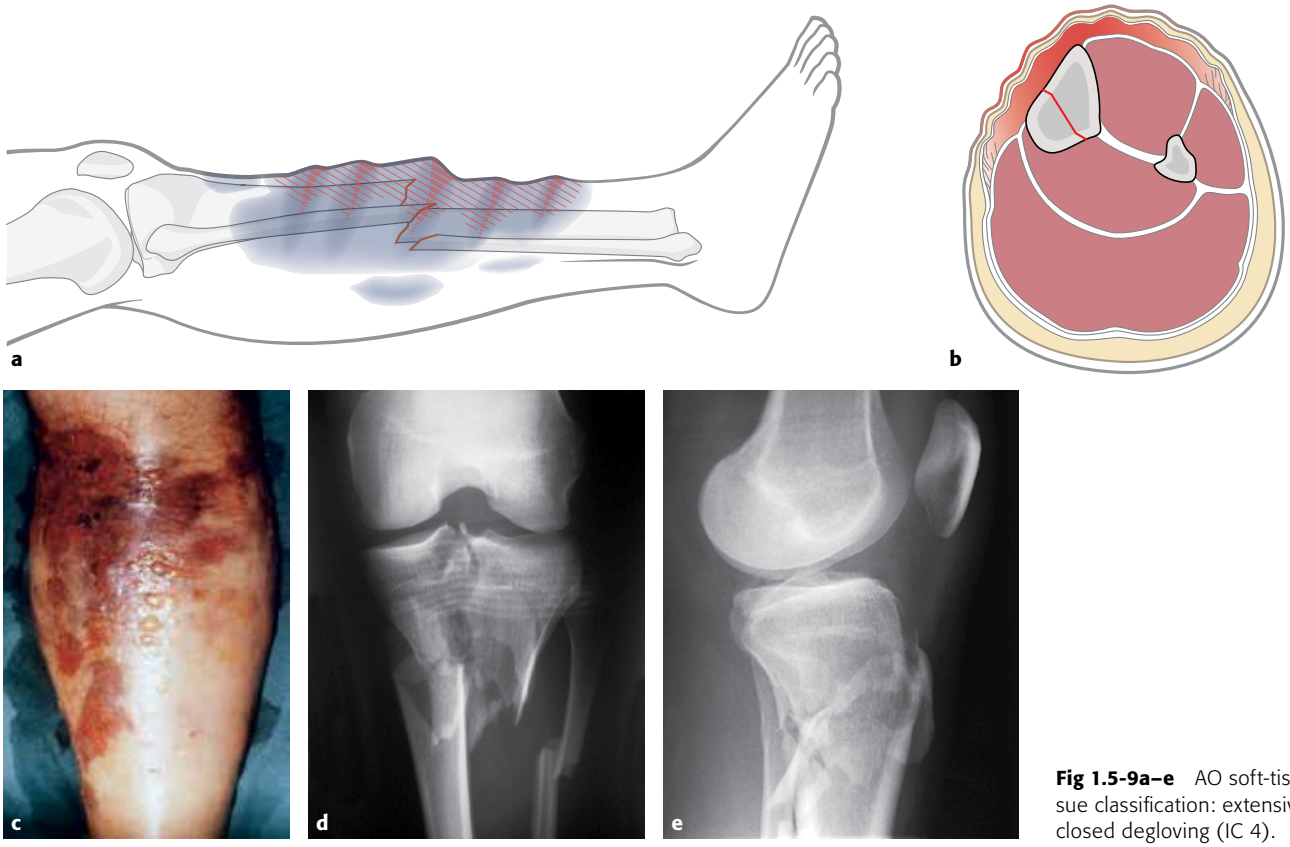

Fig 1.5-9a–e AO soft-tissue classification: extensive, closed degloving (IC 4).

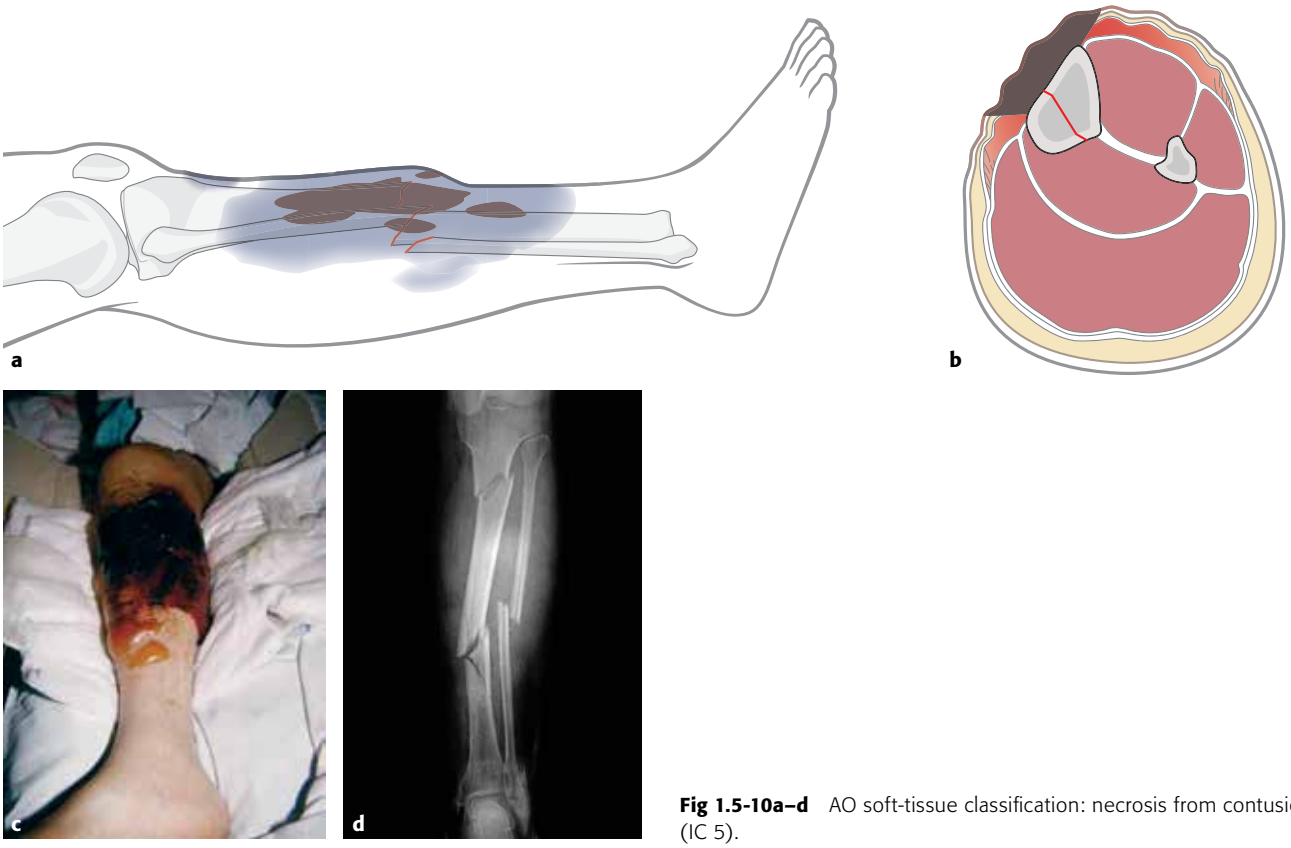

Fig 1.5-10a–d AO soft-tissue classification: necrosis from contusion (IC 5).

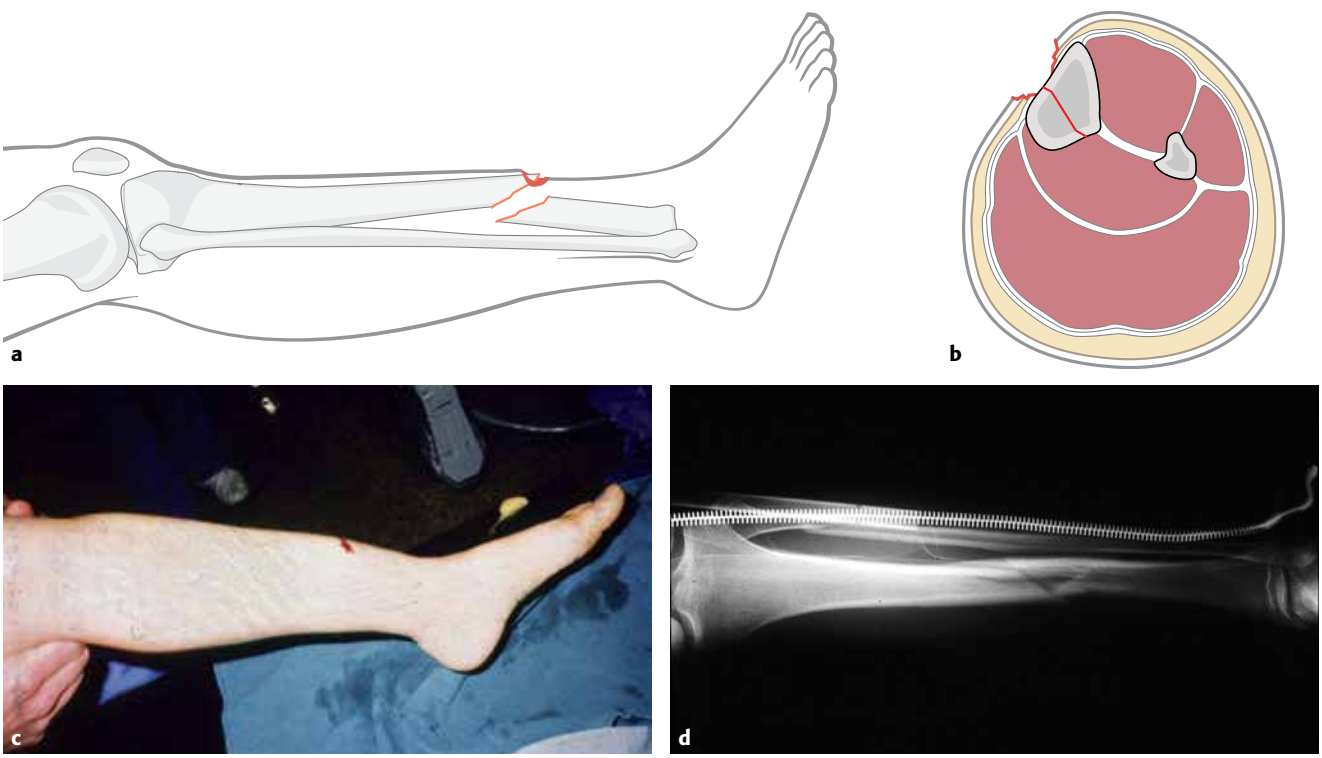

Fig 1.5-11a–d AO soft-tissue classification: skin breakage from inside out (IO 1).

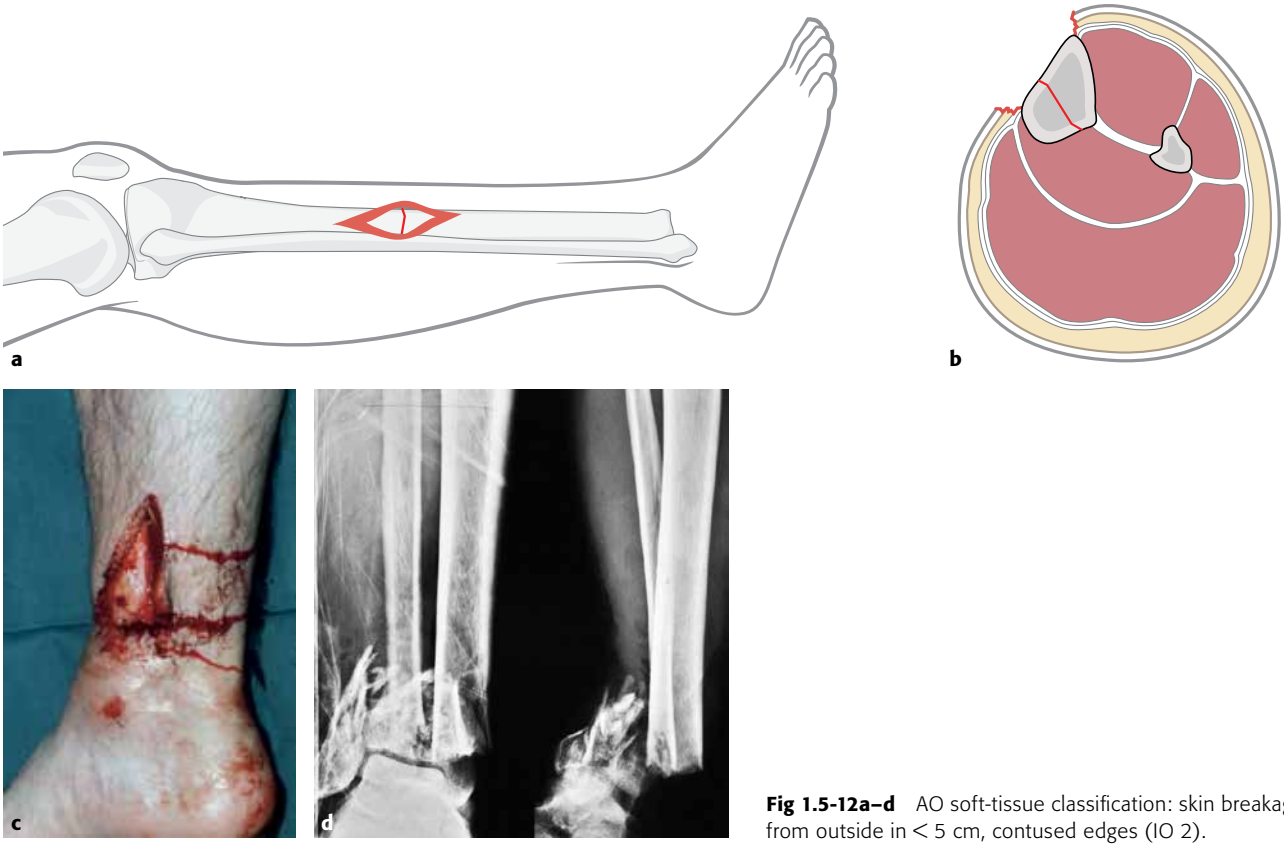

Fig 1.5-12a–d AO soft-tissue classification: skin breakage from outside in < 5 cm, contused edges (IO 2).

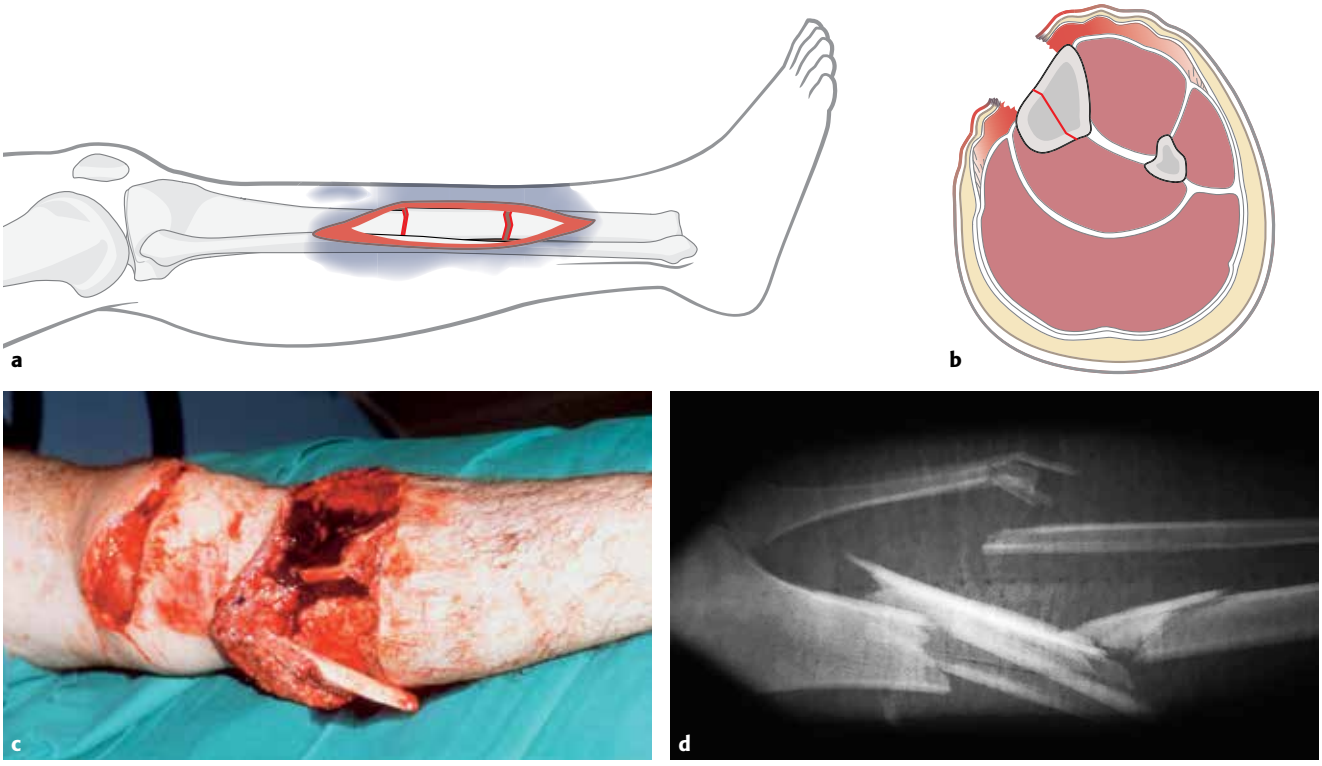

Fig 1.5-13a–d AO soft-tissue classification: skin breakage from outside in > 5 cm, increased contusion, devitalized edges (IO 3).

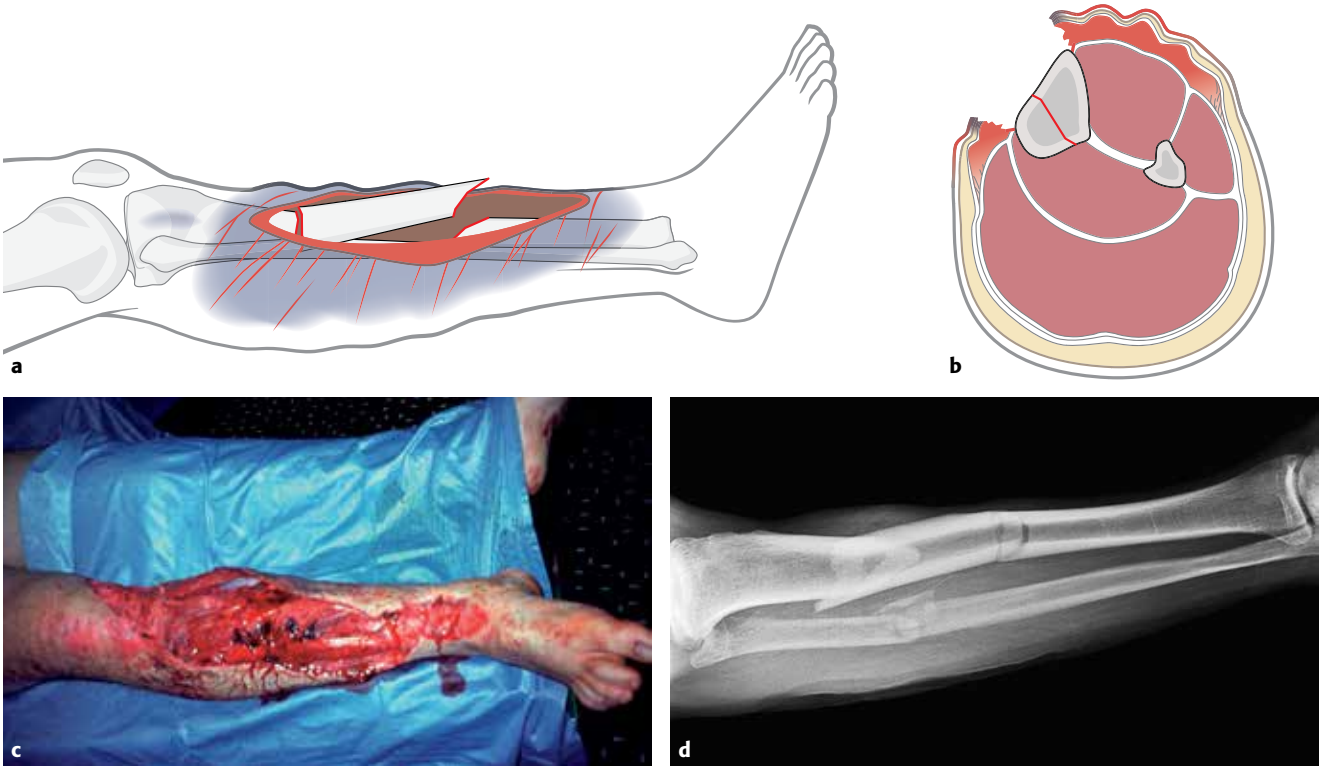

Fig 1.5-14a–d AO soft-tissue classification: considerable, full-thickness contusion, abrasion, extensive open degloving, skin loss (IO 4).

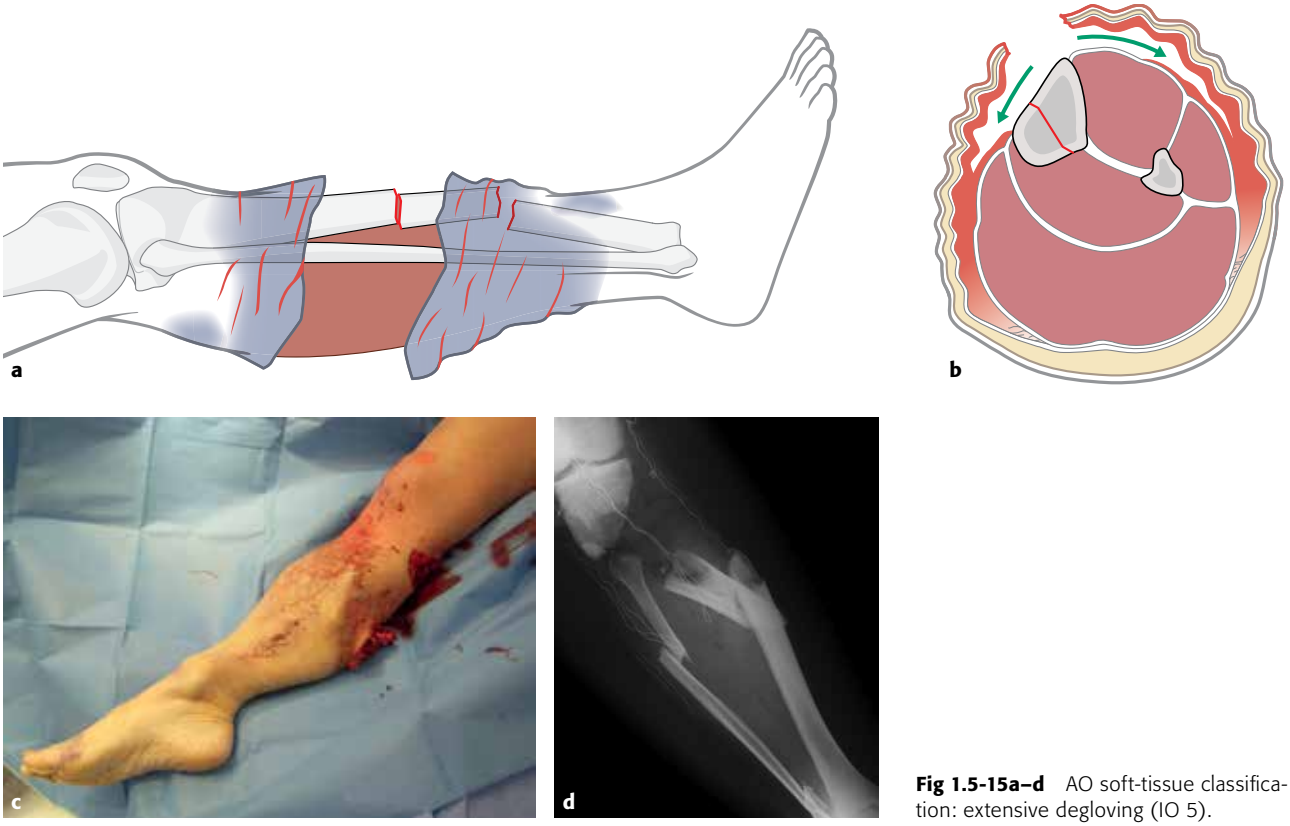

Fig 1.5-15a–d AO soft-tissue classification: extensive degloving (IO 5).

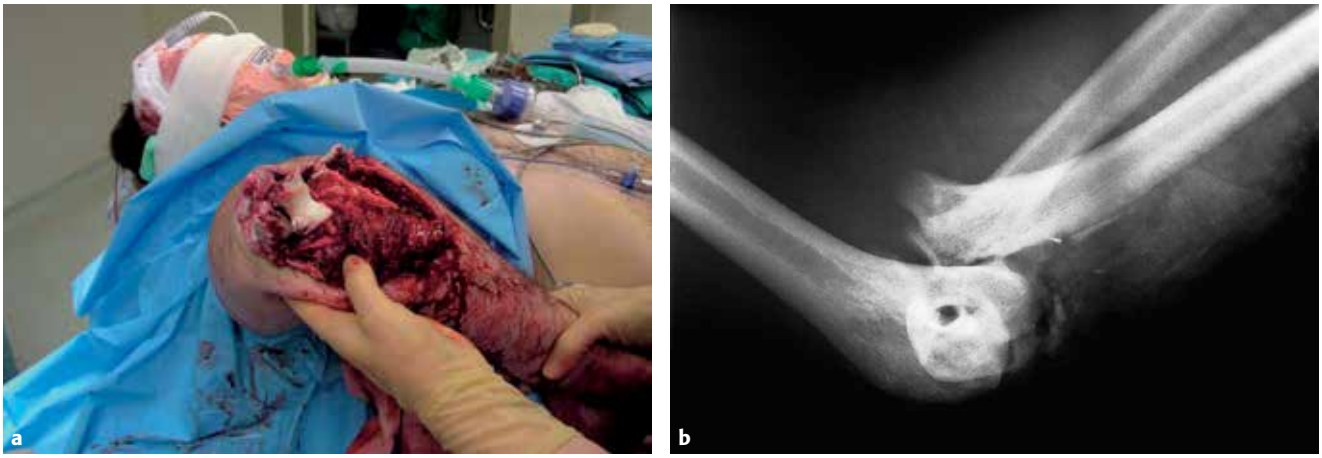

Fig 1.5-16a–b An open, multifragmentary transolecranon anterior fracture-dislocation of the elbow with extensive muscle and tendon injury, but no neurovascular damage.

MT 1	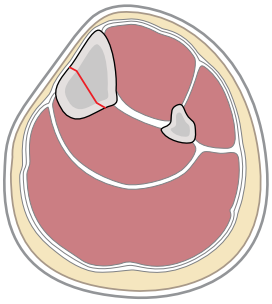	No muscle injury	
MT 2	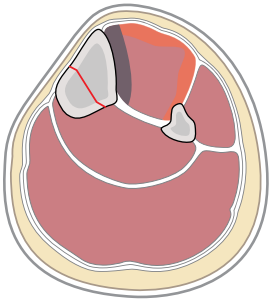	Circumscribed muscle injury, one compartment only	
MT 3	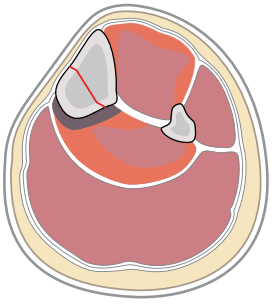	Considerable muscle injury, two compartments	
MT 4	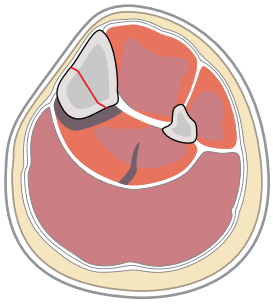	Muscle defect, tendon laceration, extensive muscle contusion	
MT 5	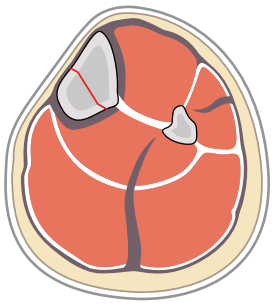	Compartment syndrome/ crush syndrome with wide injury zone	
	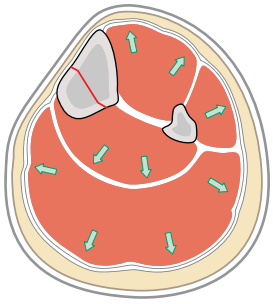	Fulminant compartment syndrome	

Table 1.5-5 AO soft-tissue classification: muscle and tendon lesions (MT).

NV 1	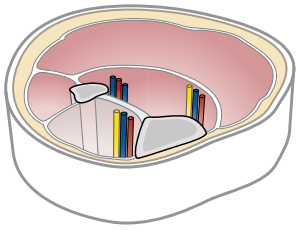	No neurovascular injury
NV 2	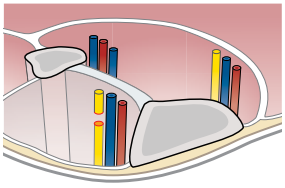	Isolated nerve injury
NV 3	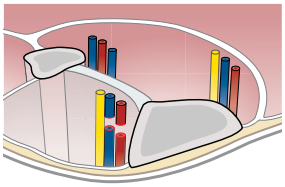	Localized vascular injury
NV 4	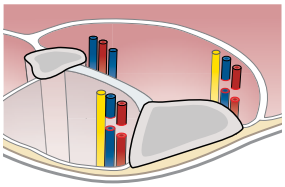	Extensive segmental vascular injury
NV 5	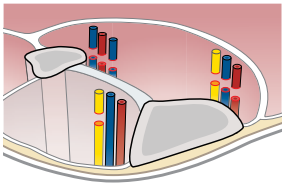	Combined neurovascular injury, including subtotal or even total amputation

Table 1.5-6 AO soft-tissue classification: nerve and vessel lesions (NV).

6.5 Using classification systems

Higher grades of the Gustilo classification of open fractures and of the Tscherne classification of closed fractures are challenging to treat. These injuries have the highest complication rates and can cause severe disability. Classification systems have several objectives, for example:

- Facilitate communication
- Assist decision making
- Identify treatment options
- Anticipate problems
- Suggest treatment method
- Predict the outcome
- Enable comparison with similar cases
- Assist documentation and audit

7 Conclusion

The effective treatment of fractures depends upon good management of the soft tissues. The surgeon must carefully evaluate the injury by systematically examining each structure that could be damaged: the skin, subcutaneous tissue, muscle and tendons, nerves, vessels, and bones. The possibility of compartment syndrome should always be considered and it must be recognized that closed injuries may be associated with severe soft-tissue damage. Careful evaluation will allow the surgeon to classify the fracture using one of the comprehensive grading systems. This will guide decision making, allow clear communication, and give an indication of potential complications and outcome. Up-to-date knowledge of the advances in wound care techniques, the pathophysiology of wound healing, and the appropriate application of this knowledge will benefit trauma patients in their recovery.

Classic references | Review references

8 References

1. **Levin LS.** Personality of soft-tissue injury. *Tech Orthop.* 1995;10:65–72.
2. **Schultz GS, Wysocki A.** Interactions between extracellular matrix and growth factors in wound healing. *Wound Repair Regen.* 2009 Mar-Apr;17(2):153–162.
3. **Bernstein BP, Maqungo S, Nortje M, et al.** First Clinical Use of a Novel Plasma Based Biomaterial to Augment the Healing of Open Tibia Fractures. Scientific poster No. 128 presented at: Annual Meeting of the Orthopaedic Trauma Association; October 15–18, 2014; Tampa, Fla, USA.
4. **Steenfos HH.** Growth factors and wound healing. *Scand J Plast Reconstr Surg Hand Surg.* 1994 Jun;28(2):95–105.
5. **Schmid P, Itin P, Cherry G, et al.** Enhanced expression of transforming growth factor-beta type I and type II receptors in wound granulation tissue and hypertrophic scar. *Am J Pathol.* 1998 Feb;152(2):485–493.
6. **Levin LS, Condit DP.** Combined injuries—soft tissue management. *Clin Orthop Relat Res.* 1996 Jun;(327):172–181.
7. **Gierer P, Mittlmeier T, Bordel R, et al.** Selective cyclooxygenase-2 inhibition reverses microcirculatory and inflammatory sequelae of closed soft-tissue trauma in an animal model. *J Bone Joint Surg Am.* 2005 Jan;87(1):153–160.
8. **Mittlmeier T, Schaser K, Kroppenstedt S, et al.** Microvascular response to closed soft tissue injury. *Trans Orthop Res Soc.* 1997;44:317.
9. **Morel- Lavallée M.** [Decollements traumatiques de la peau et des couches sous-jacentes. *Arch Gen Med.* 1863;1:20–38,172–200,300–332.] French.
10. **Tseng S, Tornetta P 3rd.** Percutaneous management of Morel-Lavallée lesions. *J Bone Joint Surg Am.* 2006 Jan;88(1):92–96.
11. **Mundy R, Chaudhry H, Niroopan G, et al.** Open tibial fractures: updated guidelines for management. *J Bone Joint Surg Rev.* 2015;3(2):e1.
12. **Mills WJ, Barei DP, McNair P.** The value of the ankle-brachial index for diagnosing arterial injury after knee dislocation: a prospective study. *J Trauma.* 2004 Jun;56(6):1261–1265.
13. **Matsen FA 3rd, Winquist RA, Krugmire RB Jr.** Diagnosis and management of compartmental syndromes. *J Bone Joint Surg Am.* 1980 Mar;62(2):286–291.
14. **Shrier I, Magder S.** Pressure-flow relationships in in vitro model of compartment syndrome. *J Appl Physiol (1995).* 1995 Jul;79(1):214–221.
15. **Heppenstall RB.** Compartment syndrome: pathophysiology, diagnosis, and treatment. *Techn Orthop.* 1997;12:92–108.
16. **Willy C, Gerngross H, Sterk J.** Measurement of intracompartmental pressure with use of a new electronic transducer-tipped catheter system. *J Bone Joint Surg Am.* 1999 Feb;81(2):158–168.
17. **Shuler MS, Reisman WM, Whitesides TE Jr, et al.** Near-infrared spectroscopy in lower extremity trauma. *J Bone Joint Surg Am.* 2009 Jun;91(6):1360–1368.
18. British Orthopedic Association Standards for Trauma (BOAST). BOAST 10: Diagnosis and management of compartment syndrome of the limbs. Available at: www.boa.ac.uk. Accessed June 2017.
19. **MacKenzie EJ, Bosse MJ.** Factors influencing outcome following limb-threatening lower limb trauma: lessons learned from the Lower Extremity Assessment Project (LEAP). *J Am Acad Orthop Surg.* 2006;14(10 Spec No.):S205–210.
20. **Higgens TF, Klatt JB, Beals TC.** Lower Extremity Assessment Project (LEAP): the best available evidence on limb-threatening lower extremity trauma. *Orthop Clin North Am.* 2010 Apr;41(2):233–239.
21. **Gustilo RB, Anderson JT.** Prevention of infection in the treatment of one thousand and twenty-five open fractures of long bones: retrospective and prospective analyses. *J Bone Joint Surg Am.* 1976 Jun;58(4):453–458.
22. **Gustilo RB, Mendoza RM, Williams DN.** Problems in the management of type III (severe) open fractures: a new classification of type III open fractures. *J Trauma.* 1984 Aug;24(8):742–746.
23. **Tscherne H, Oestern HJ.** [A new classification of soft-tissue damage in open and closed fractures]. *Unfallheilkunde.* 1982 Mar;85(3):111–115. German.
24. **Brumback RJ, Jones AL.** Interobserver agreement in the classification of open fractures of the tibia. The results of a survey of two hundred and forty-five orthopaedic surgeons. *J Bone Joint Surg Am.* 1994 Aug;76(8):1162–1166.
25. **Volgas DA.** Classification Systems. In Volgas DA, Harder Y, eds. *Manual of Soft-Tissue Management in Orthopaedic Trauma.* Stuttgart New York; Georg Thieme Verlag; 2011:62–70.

9 Acknowledgments

We thank Norbert Sudkamp for his contribution to this chapter in the second edition of the *AO Principles of Fracture Management*.

Section

2

Decision making and planning

Section 2
Decision making and planning

2.1	The patient and the injury: decision making in trauma surgery Christopher G Moran	73
2.2	Diaphyseal fractures: principles Piet de Boer	83
2.3	Articular fractures: principles Chang-Wug Oh	93
2.4	Preoperative planning Matthew Porteous	105

2.1 The patient and the injury: decision making in trauma surgery

Christopher G Moran

1 Introduction

Decision making and communication are vital factors for successful surgery; good surgeons make wise decisions. Before recommending surgical treatment, a thorough assessment of the patient must be undertaken to understand the full extent of the injury, anticipate and prevent postoperative complications, and determine the potential for recovery.

The first priority is to save life and the management of major chest, abdominal, and head injuries will always take precedent. Fractures are rarely life-threatening but pelvic fractures may require splinting, stabilization, packing, or embolization to stop severe hemorrhage. The next priority is to save limb by early treatment of vascular injuries and open fractures. Joint dislocations and severely displaced fractures should be reduced but most fractures can be splinted. This allows time to optimize the patient's condition, perform investigations, and formulate a definitive treatment plan.

The surgeon must evaluate the "personality" of the injury. This is determined by the following:

- Patient factors
- Soft-tissue injury
- Fracture

Decisions must be made in the context of the local healthcare facilities. This chapter presents these key elements in the decision-making process (**Fig 2.1-1**).

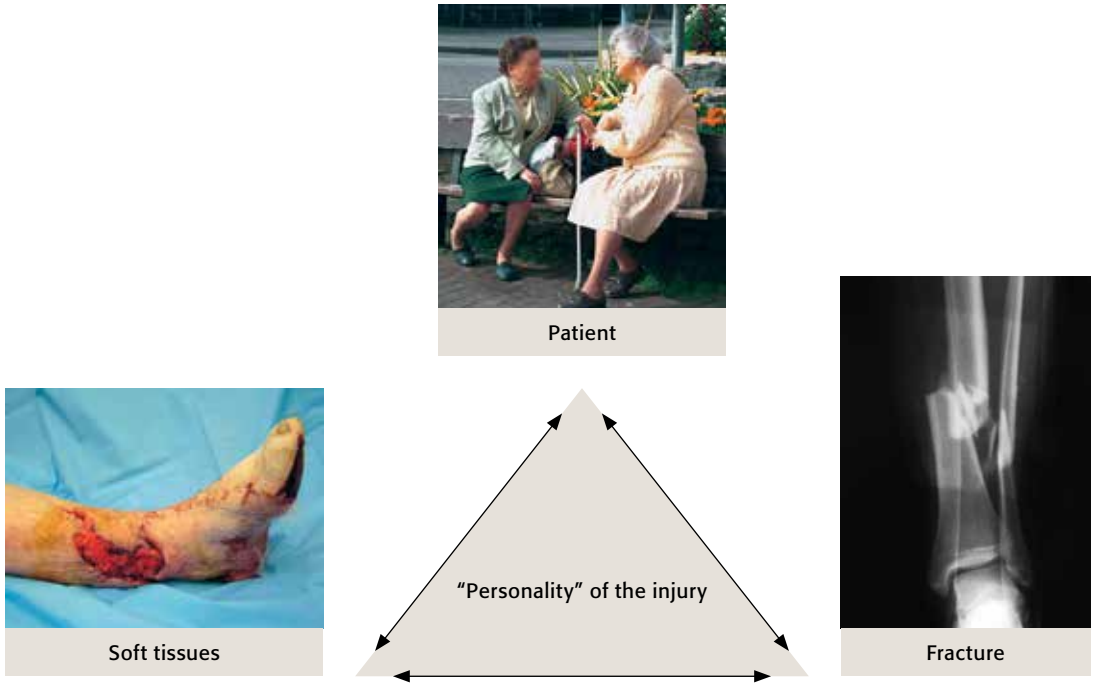

Fig 2.1-1 Factors that determine the "personality" of an injury.

2 Polytrauma

The initial assessment and management of all patients with polytrauma (see chapter 4.1) should follow advanced trauma life support (ATLS) guidelines. This divides treatment into four phases:

- Primary survey
- Resuscitation
- Secondary survey
- Definitive care

2.1 Primary survey and resuscitation

The primary survey and resuscitation are undertaken simultaneously, ideally by a multidisciplinary trauma team. The aim of the primary survey is to identify all immediately life-threatening conditions and commence treatment following cABCDE

c - Control exsanguinating external hemorrhage
A - Airway with cervical spine control
B - Breathing
C - Circulation
D - Disability assessment
E - Exposure and temperature control

If a trauma team is available, these phases can be performed simultaneously by different members of the team (**Fig 2.1-2**). Exsanguinating external hemorrhage is usually due to open injury to a large artery and must be controlled immediately by application of direct pressure. A proximal tourniquet can be applied if the site of injury allows. The neck and spine must be protected until the spine is cleared according to local guidelines. The most common life-threatening injuries occur to the chest, abdomen, and head. They must be dealt with rapidly. Early radiological assessment is essential: ideally this is achieved with an early whole body (trauma) computed tomographic (WBCT) scan with IV contrast from head to pelvis with a scout view that includes the femurs [1]. If immediate access to CT is not available, early chest and pelvic x-rays must be obtained. Excess movement of the pelvis must also be avoided, as this can dislodge blood clots from pelvic fractures and increase bleeding. Pelvic binders are now commonly used to splint the pelvis but a simple belt or tied bed sheet may be effective in the short term.

Fig 2.1-2 Polytrauma is best managed by a well-organized, multidisciplinary trauma team.

Bone injuries are rarely life-threatening unless there is severe hemorrhage from pelvic, open, or multiple long-bone fractures. Hemorrhage from fractures can be reduced by early splinting, which restricts movement and allows clots to form. It is essential that hypothermia is prevented, as this inhibits the coagulation cascade. Victims of blunt or penetrating trauma who have evidence of significant blood loss should receive intravenous tranexamic acid within 3 hours of injury [2, 3]. Early infusion of blood products, such as fresh frozen plasma, platelets, and cryoprecipitate should be considered in all patients with hypovolemic shock using a "Massive Transfusion Protocol" that aims to provide packed red blood cells, plasma, and platelets in a 1:1:1 ratio [4].

2.2 Secondary survey

The secondary survey takes place once the primary survey has been completed. A full history of the accident should be taken from the patient (if possible), paramedics, and relatives. A medical and drug history must be obtained.

A thorough examination from head to toe, front and back, should identify remaining injuries.

In the limbs, each bone and joint should be tested for tenderness and stability and a neurovascular assessment of each limb is mandatory. All wounds should be carefully inspected and any gross contaminants removed. If possible, photographs should be taken before the wounds are covered with saline-soaked, sterile dressings. These must be left undisturbed until definitive wound management in the operating room. Appropriate tetanus coverage and antibiotics should be administered. X-rays of all suspected fractures must be obtained. Computed tomographic scans can be helpful in the evaluation of spine, pelvis, and complex articular fractures.

2.3 Definitive care

Decision making is difficult in polytrauma patients and experienced, senior surgeons should be involved early. A key strategic decision in polytrauma is to undertake damage-control surgery, early total care, or early appropriate care, which is an evolving concept.

2.3.1 Damage-control surgery

Damage-control surgery should be considered in patients who remain hemodynamically unstable or those with hypothermia, abnormal base deficit, increased lactate, or blood-clotting abnormalities.

No single investigation gives a clear guide to decision making and at the present time the overall physiological status of the patient provides the best guide. The immunological response of the patient appears to be an important factor [5] but there is no quick and reliable immunological test that can be used in clinical practice. In patients who remain under-resuscitated with abnormal physiology, only life- and limb-saving surgery should be performed during the early phase. Long-bone fractures can be splinted with casts, splints, or skeletal traction or rapidly stabilized with simple, temporary external fixation. The fixation pins should be outside the zone of injury and, if possible, outside the zone of any future surgery for definitive care (**Fig 2.1-3a–c**). Decision making is difficult in patients who have a vascular injury that needs repair (to save limb) but remain physiologically unstable. In this situation, prolonged vascular reconstruction may put the patient's life at risk and primary amputation should be considered. Damage-limitation surgery must be undertaken as quickly and safely as possible and the patient should be transferred to the intensive care unit as soon as possible. Definitive surgery is delayed until the patient's condition is optimal, often at 5–10 days posttrauma [6].

2.3.2 Early total care

Early total care is beneficial for a significant number of patients with polytrauma. This involves definitive surgical stabilization of all long-bone fractures during the early phase of treatment, usually within the first 24 hours. This may reduce pulmonary complications and allow earlier rehabilitation of the patient [7].

Early total care is suitable for patients with multiple fractures who have been fully resuscitated and are hemodynamically stable with normal blood gases, clotting, and temperature.

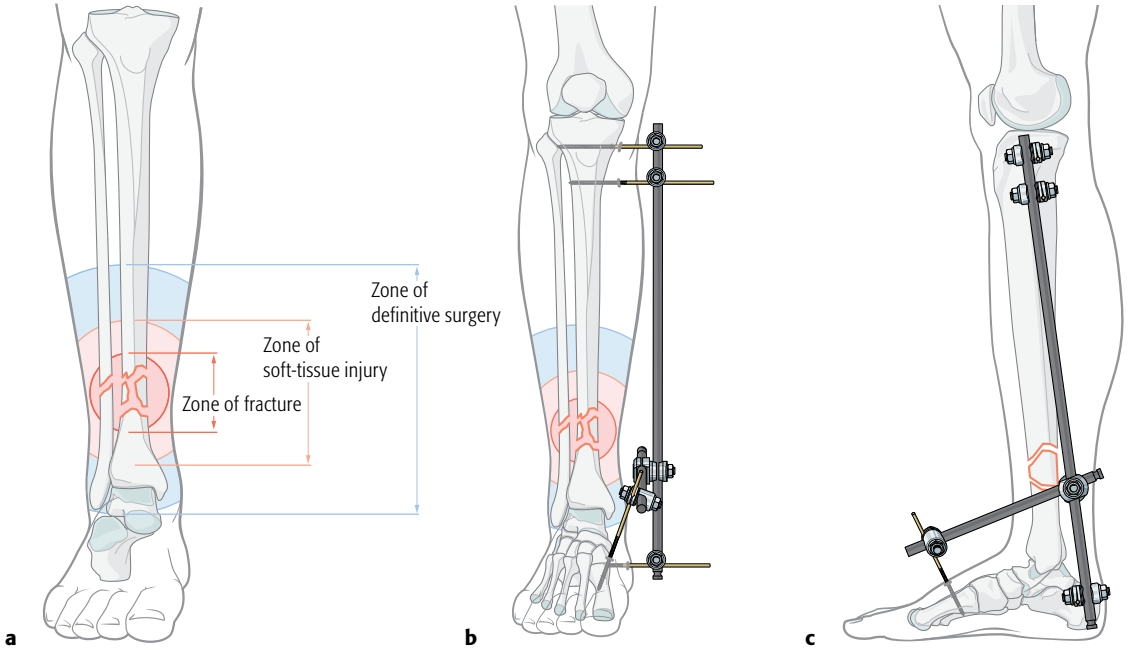

Fig 2.1-3a–c The application of external fixation for damage-control surgery must be outside the zone of injury. The zone of future definitive fracture surgery should also be bridged, if possible.

Definitive fracture fixation should not be performed in patients with persistent hypotension, tachycardia, and oliguria nor those with coagulation defects, a core temperature below 35.5°C or abnormal blood gases. Venous lactate is a good indicator of resuscitation status. Definitive fracture fixation should not take place if the lactate is greater than 3.0 mmol/L. Resuscitation should continue and a damage-control strategy followed if the patient fails to improve. If fracture fixation is performed, careful planning of the sequence and timing of surgery is essential as deterioration in the patient's condition may mandate a change to damage-control surgery. Close liaison with the intensive care and anesthetic teams is essential.

2.3.3 Early appropriate care

Early appropriate care is a more recent concept where fracture surgery is delayed for up to 36 hours while the patient is fully resuscitated so that all of their key physiological parameters return to normal [8]. During this time, long-bone fractures are splinted or put into skeletal traction before definitive skeletal fixation of all unstable pelvic and spinal fractures, together with all long bone fractures. If the soft tissues are suitable and the appropriate surgical team is available, fixation of periarticular fractures may also be considered within this time frame as it allows more rapid mobilization of the patient.

2.4 Isolated injuries

The first questions to ask when presented with an apparently isolated injury are:

- What else is injured?
- Does the mechanism of injury suggest the patient could have polytrauma?
- Is there an injury to the joint above or below?

In polytrauma, each individual injury should have the same thorough evaluation that is undertaken for single injuries. In each case patient factors, such as multiple comorbidities, may have a profound effect on decision making. The local evaluation of each injury has two key facets: the soft tissues and the fracture pattern. These factors, together with patient factors, will determine the personality of the injury and subsequent decision making and treatment.

3 The personality of the injury

3.1 The patient

A holistic approach to the patient is essential. A full case history and examination must be performed together with appropriate investigations.

Important factors that will influence decision making include age, general health status, mental health, occupation, and social factors.

3.2 Age

Age is obviously important, especially in childhood when the growing skeleton has potential to remodel and injuries may result in growth disturbance. The development of osteoporosis in the aging skeleton has a major influence on surgical techniques, but age alone is not sufficient when assessing elderly patients. Pre-injury mobility, residential status, cognitive function, long-term medication, and pre-existing medical conditions are all important and influence decision making [9, 10].

3.3 General health status

Cardiorespiratory problems will influence the anesthetic used and are important factors when determining a patient's fitness for surgery. The increasing use of anticoagulation and antiplatelet therapy for many cardiovascular diseases is also an important factor to consider.

Diabetes alters a patient's metabolic response to trauma and requires careful management during the perioperative period. In patients with diabetes neutrophil granulocytes do not function normally, which predisposes them to infection. They also suffer from small vessel disease, which may cause delayed healing and a further increase in the risk of infection. These patients can develop neuropathic nonunion and joint destruction (Charcot's joint). A careful evaluation of the neurovascular status of the limb is essential and patients must be aware of the increased risks [11].

Peripheral arterial disease will have an important influence on soft-tissue and fracture healing. The ankle-brachial index should be measured in all these cases.

Venous disease in the legs can cause chronic swelling, venous congestion, and ulceration that will affect treatment and prognosis. Surgery must be avoided, if at all possible, in patients with acute vasculitis. The presence of this problem should always be considered in patients with systemic inflammatory diseases, such as rheumatoid arthritis and systemic lupus erythematosus.

Renal disease and chronic renal failure can result in abnormal bone metabolism and it is not unusual to treat fractures in patients receiving dialysis. These patients may have electrolyte and coagulation disorders and are at increased risk of infection and nonunion. It is essential that renal physicians are involved in the perioperative management,

as preexisting renal disease is a key factor in the development of acute kidney injury following surgery.

Liver disease also predisposes to osteoporosis and fracture. Patients with cirrhosis may have coagulation disorders. Liver function and coagulation must always be tested before surgery. Viral hepatitis may put the nursing and surgical team at risk of cross infection.

Neurological conditions, such as stroke and Parkinson disease, may alter a patient's ability to bear weight and comply with rehabilitation. These patients are at risk of further falls and may require additional external splints for protection. Patients with head injury are more prone to heterotopic bone formation and may have muscle spasticity that results in joint contractures. These must be prevented by physical therapy and splints.

Malignant disease should always raise the possibility of pathological fracture and the presence of a primary bone tumor must be considered in young patients presenting with pathological fracture. Decision making in patients with pathological fractures and advanced malignancy is always difficult and should involve the patient, relatives, and the palliative care team.

Joint disease, such as osteoarthritis or rheumatoid arthritis, must be evaluated when assessing any fracture.

Some articular and periarticular fractures may be managed by primary joint replacement if there is advanced arthritis.

The presence of a joint replacement and periprosthetic fracture will require careful assessment to determine preexisting loosening or infection, the etiology of the fracture, and the relationship between the fracture lines and the prosthesis.

Obesity is a major healthcare problem in the Western world and an increasing problem in the developing world. Morbid obesity presents the trauma surgeon and anesthetist with some unique problems. Patients may be too large for a CT or magnetic resonance imaging scanner and standard operating tables and poor respiratory function may preclude the usual supine positioning. Compliance with rehabilitation programs can be a problem and splints or plaster casts may be difficult to apply [12].

Medications, such as corticosteroids, can result in osteoporosis, poor healing, and increased risk of infection. Patients may also be at risk of Addisonian crisis if they have been taking high doses of steroids. Patients given immunosuppressive medications require careful management and have a similar increased risk of infection together with potential coagulation disorders. Patients receiving beta-blockers and other cardiac drugs may be unable to mount a normal response to hypovolemia. Anticoagulants, such as coumadin, are now prescribed commonly and require close hematological monitoring. Nonsteroidal antiinflammatory drugs may be implicated in the pathogenesis of some nonunions and some surgeons limit their use following nonunion surgery [13]. The development of stress fractures in patients given bisphosphonates to treat osteoporosis has recently been recognized with fractures occurring in the subtrochanteric region and shaft of the femur. Healing times are slower and selection of surgical technique and implant must take this into account [14]. Many patients are suffering from hypovitaminosis D and need vitamin D supplementation [15].

3.4 Mental health

Mental health can have a major influence on patient outcome following trauma. Any preexisting psychological disorder must be considered and posttraumatic psychological reactions are common. Depression and anxiety are known to be associated with poor outcome following trauma and patients may benefit from management by the appropriate expert if this condition is diagnosed [16]. Pain management can be complex and difficult and sometimes require specialists in this field. Compliance with treatment, physical therapy, and rehabilitation may be a problem and the involvement of mental health teams is often necessary to optimize treatment of the patient. It is well recognized that worker's claims for compensation can radically alter a patient's response to injury and treatment [17].

3.5 Occupation

Occupation can have an important influence on a patient's functional goals. Following severe hand trauma the functional requirements of a fine-skilled worker, such as a jeweler, will be different from a heavy manual worker. This may warrant a completely different surgical and rehabilitation program. Professional sportsmen and women are another group where functional demands may influence decision making.

3.6 Social factors

Social factors that influence fracture management include cigarette smoking, which may delay soft-tissue and fracture healing, and alcohol abuse, which predisposes to falls and osteoporosis. Patient compliance and rehabilitation can be a major problem in this group. Intravenous drug abusers present similar challenges and are at risk of blood-borne

viral diseases, such as hepatitis B, C, E, and human immunodeficiency virus. Universal precautions must be applied to prevent cross infection of healthcare workers.

4 The soft tissues

Soft tissues are an important factor in determining the timing of surgery, the surgical approach, and the risk of complications.

The major principles of soft-tissue management have been covered in chapter 1.5. Military wounds have their own characteristics and surgical experience with these soft-tissue insults will enhance decision making. Each type of soft tissue must be assessed systematically to determine the full extent of the zone of injury:

- Skin—wounds, grazing, degloving (closed or open)
- Muscle and tendons—function, compartment syndrome
- Nerves—motor and sensory
- Vessels—peripheral pulses, capillary return

Following this examination, the soft-tissue injury can be classified and this part of the personality of the fracture defined (see chapters 1.5).

5 The fracture

Plain x-rays will define the fracture and should be done in two planes at 90° to each other: The joint above and below the injury must be imaged. Most information for fracture care is on the plain x-rays. X-rays taken with traction after the patient is anesthetized can provide valuable information for the planning of fracture fixation. Additional investigations are often required. A CT scan is helpful for the imaging of intraarticular fractures, providing information on the size, location, and displacement of fracture fragments. Computer manipulation of the CT scan in the sagittal and coronal planes and 3-D projections may be helpful. Magnetic resonance imaging provides good detail of bone injuries and may be useful in cases of a combined bone and soft-tissue injury (eg, tibial plateau fracture with meniscal and ligament injury: see chapter 6.7.2).

The concept of "span", "scan" and "plan" creates a solid foundation for decision making. Full evaluation of the fracture will allow classification and surgical planning but the timing of surgery is not determined by the fracture but by the physiological condition of the patient and the soft-tissue injury.

6 Timing of surgery

Choosing the correct time for the performance of fracture surgery is a key decision that will be determined by the personality of the fracture. Surgery at the wrong time can be disastrous for the patient. The hemodynamically unstable polytrauma patient should only have minimal surgery to save life and limb, not complex reconstruction surgery to restore joint function. Surgery through swollen and edematous tissue has a high risk of wound breakdown and secondary infection.

Most patients have an isolated, closed fracture. Surgery is not urgent and should be scheduled after appropriate investigations and planning. The timing of surgery will depend on the patient's health and the state of the soft tissues. Ideally, it should take place within 1–3 days after injury to reduce hospital stay and allow the patient to commence early rehabilitation (**Table 2.1-1**). Isolated, closed femoral shaft fractures should have surgery within 24 hours as this reduces the risk of respiratory complications [18].

Polytrauma patients who are hemodynamically stable and fit for early total care should have urgent fracture fixation. The soft tissues will determine the local treatment and, if these allow, early definitive fracture fixation is ideal. Polytrauma patients who are hemodynamically unstable or otherwise not fit for prolonged surgery (eg, hypothermia) should have damage-control surgery or continued resuscitation to restore normal physiology and allow early appropriate care. The timing of definitive fracture surgery can be difficult in patients who have required temporary splints or external fixation as part of damage-control surgery. Decisions need to be made in consultation with the intensive care team, and current evidence suggests that definitive care is best delayed for 5–10 days (see chapter 4.1). This allows the patient to recover from the systemic inflammatory response to trauma while minimizing the risk of infection secondary to external fixator pin-track sepsis.

Highly contaminated open fractures require urgent wound debridement. However, a longer delay is acceptable in clean wounds and children [19, 20] to avoid surgery in the early hours of the morning and to allow joint orthoplastic care of severe wounds in the right facility. However, type 3 open wounds, especially in the lower extremity, are not forgiving when it comes to risk of late infection and must be debrided expeditiously [19]. Antibiotics should be administered and the patient must be scheduled for surgery as the first case in the morning. The decision to perform local damage-control surgery (ie, wound debridement plus temporary

external fixation) or local definitive care (ie, wound debridement plus definitive fracture fixation) will depend upon many factors, which include the delay between injury and surgery, the state of the soft tissues, the available facilities, and the experience of the surgeon. Most wounds will require delayed primary closure or flap cover. This should be performed within 5 days. If a temporary external fixator has been applied it may be appropriate to perform definitive fixation at this time.

Closed fracture dislocations or complex articular fractures are an important group to consider. These often develop severe soft-tissue swelling with fracture blisters. If the patient is seen early, before the soft tissues have swollen, then early definitive fracture fixation is an option, provided appropriate investigations for planning (eg, CT scan) and an experienced surgical team are available. However, local damage-control surgery should be considered if:

- Soft tissues are compromised
- Patient comorbidities require treatment before surgery
- Specialist surgical or nursing teams are not available
- Specialist surgical implants/instruments are not immediately available

Many fractures can be simply reduced and splinted and elevated (eg, wrist, calcaneous) until the swelling resolves. However, in some cases (eg, pilon, knee) a temporary, joint-spanning external fixator may reduce the fracture and protect the soft tissues from further injury and also prevent shortening, joint subluxation, and additional damage to the articular surface. This treatment appears to facilitate soft-tissue healing and often allows the patient to remain at home while swelling resolves, usually at 7–18 days. Definitive surgery is scheduled at this stage.

Type of injury	Details of injury	Time of primary surgery	Procedure of primary surgery	Time of early reconstruction surgery	Definitive reconstruction surgery
Polytrauma	Hemodynamically unstable	Immediate	Damage-control surgery External fixator	5–10 days "window of opportunity"	After 3 weeks
	Hemodynamically stable	Immediate	Early appropriate care	–	–
Open fracture	Type I–IIIA	< 12–24 hours	Debridement and definitive fracture fixation	24–72 hours Redebridement and soft-tissue coverage	After 6–20 weeks Bone graft and soft-tissue management
	Type IIIB and IIIC	< 6 hours	Debridement, definitive fracture fixation or local damage control	24–72 hours Redebridement and soft-tissue cover by 5 days and definitive fracture fixation when clean	–
Closed fracture	Good soft tissues	1–3 days	Definitive fracture fixation	–	–
	Poor soft tissues	< 24 hours	Local damage control, spanning external fixator	–	After 10–18 days when wrinkle sign presents Definitive fracture fixation
Unstable fracture dislocation	Good soft tissues	< 12 hours	Definitive fracture fixation	–	–
	Poor soft tissues	Immediate	Local damage control, spanning external fixator	–	After 10–18 days when wrinkle sign presents Definitive fracture fixation

Table 2.1-1 Timing of fracture surgery.

7 Communication

The surgeon is the leader of the healthcare team that manages trauma patients.

Clear communication with physicians, nurses, patients, and relatives is an essential skill.

Once the surgeon has evaluated the personality of the injury, he or she must formulate a treatment plan and communicate this effectively. There are three key facets to the treatment plan:

- Surgical strategy
- Surgical tactic
- Surgical plan

Surgical strategy is the overall treatment plan for the patient, including preoperative investigations, surgical and medical treatment, and rehabilitation. In the polytrauma patient, good communication with other specialists is important to set priorities and determine the sequence and timing of multiple procedures. It is essential that one senior surgeon takes overall responsibility for the patient's management; this will usually be the trauma surgeon.

Surgical tactic is the overview and plan for each complete episode in the operating room. This allows the surgeon, anesthetist and operating room personnel to prepare for each operation. Key information that must be communicated includes the planned procedure, patient position, type of operating table, instruments and implants, the need for intraoperative radiology, blood transfusion and antibiotics, splints and special postoperative requirements, such as an intensive care bed.

Surgical planning is the fine-detail drawing that the surgeon should prepare for each fracture fixation. This allows the surgeon to mentally rehearse the operation, decide upon the reduction method and type of fixation (including special instruments and implants) and from this determine the anatomical approach to the fracture (and thus patient position). Potential intraoperative complications and problems can be anticipated and avoided. This is an important discipline for orthopedic trauma surgeons and is described in chapter 2.4.

Good communication with patients and relatives is important. They should have a clear understanding of the nature of the injury, the intended surgical treatment, and the rehabilitation program which should include the time of key rehabilitation goals, such as leaving hospital, return to weight bearing, return to driving, and return to work or education. Realistic expectations of the outcome are essential with patients and good communication will usually prevent a breakdown in trust that may lead to litigation.

8 Healthcare environment

The facilities available to deliver trauma care vary greatly, not just from country to country but also within regions and even cities. The facilities available will be a key determinant of what care can be provided. Before starting treatment, particularly in rare or complex cases, the surgeon must ask two questions:

- Does my hospital have the staff, facilities, and implants to undertake the planned procedure?
- Does the surgeon have sufficient skill, experience, and expertise to treat this condition?

The formulation of the surgical tactic and plan is helpful and will allow the surgeon to anticipate the requirements for instruments and implants, specialist procedures, such as microvascular free-flaps, and special facilities, such as intensive care. This plan can then be matched against the available facilities and expertise within the hospital.

Surgeons must have a realistic appreciation of their own skills and limitations. Without sophisticated facilities and highly trained personnel it may not be safe to carry out complex reconstructive surgery and patients should be transferred (as safely and rapidly as possible) to an institution where these are available.

When the patient's needs exceed the resources available in the treating institution, such a transfer is mandatory.

Good rehabilitation facilities must also be available as the most perfect osteosynthesis will be a waste of time and resources if the patient does not receive the appropriate advice, physical and occupational therapy and nutrition [21] to allow them to regain maximum possible function after injury.

9 Conclusion

In summary, the trauma surgeon must take a holistic approach to fracture management. Fractures are rarely life-threatening and other injuries may take priority. The formulation of a definitive treatment plan will depend upon patient factors, soft-tissue injury, and the fracture itself. These three factors determine the personality of the injury and must be fully evaluated before treatment.

Classic references | Review references

10 References

1. **Huber-Wagner S, Lefering S, Qvick L-M, et al.** Effect of whole-body CT during trauma resuscitation on survival: a retrospective, multicentre study. *Lancet*. 2009 Apr 25;373(9673):1455–1461.
2. **CRASH-2 trial collaborators. Shakur H, Roberts I, et al.** Effects of tranexamic acid on death, vascular occlusive events, and blood transfusion in trauma patients with significant haemorrhage (CRASH-2): a randomised, placebo-controlled trial. *Lancet*. 2010 Jul 3;376(9734):23–32.
3. **CRASH-2 collaborators, Roberts I, Shakur H, et al.** The importance of early treatment with tranexamic acid in bleeding trauma patients: an exploratory analysis of the CRASH-2 randomised controlled trial. *Lancet*. 2011 Mar 26;377(9771):1096–1101.
4. **Holcomb JB, Tilley BC, Baraniuk S, et al.** Transfusion of plasma, platelets, and red blood cells in a 1:1:1 vs a 1:1:2 ratio and mortality in patients with severe trauma: the PROPPR randomized clinical trial. *JAMA*. 2015 Feb 3;313(5):471–482.
5. **Harwood PJ, Giannoudis PV, van Griensven M, et al.** Alterations in the systemic inflammatory response after early total care and damage control procedures for femoral shaft fracture in severely injured patients. *J Trauma*. 2005 Mar;58(3):446–454.
6. **Pape HC, Grimme K, van Griensven M, et al.** Impact of intramedullary instrumentation versus damage control for femoral fractures on immunoinflammatory parameters: prospective randomized analysis by the EPOFF Study Group. *J Trauma*. 2003 Jul;55(1):7–13.
7. **Pape HG.** *Damage-Control Orthopaedic Surgery in Polytrauma: Influence on the Clinical Course and Its Pathogenetic Background*. European Instructional Lectures. Berlin Heidelberg: Springer; 2009:67–74.
8. **Vallier HA, Wang X, Moore TA, et al.** Timing of orthopaedic surgery in multiple trauma patients: development of a protocol for early appropriate care. *J Orthop Trauma*. 2013 Oct;27(10):543–551.
9. **Alegre-Lopez J, Cordero-Guevara J, Alonso-Valdivielso JL, et al.** Factors associated with mortality and functional disability after hip fracture: an inception cohort study. *Osteoporos Int*. 2005 Jul;16(7):729–736.
10. **Todd CJ, Freeman CJ, Camilleri-Ferrante C, et al.** Differences in mortality after fracture of hip: the east Anglian audit. *BMJ*. 1995 Apr 8;310(6984):904–908.
11. **McCormack RG, Leith JM.** Ankle fractures in diabetics. Complications of surgical management. *J Bone Joint Surg Br*. 1998 Jul;80(4):689–692.
12. **McKee MD, Waddell JP.** Intramedullary nailing of femoral fractures in morbidly obese patients. *J Trauma*. 1994 Feb;36(2):208–210.
13. **Giannoudis PV, MacDonald DA, Matthews SJ, et al.** Nonunion of the femoral diaphysis. The influence of reaming and non-steroidal anti-inflammatory drugs. *J Bone Joint Surg Br*. 2000 Jul;82(5):655–658.
14. **Thompson RN, Phillips JR, McCauley SH, et al.** Atypical femoral fractures and bisphosphonate treatment: experience in two large United Kingdom teaching hospitals. *J Bone Joint Surg Br*. 2012 Mar;94(3):385–390.
15. **Sprague S, Petrisor B, Scott T, et al.** What is the role of vitamin D supplementation in acute fracture patients? A systematic review and meta-analysis of the prevalence of hypovitaminosis D and supplementation efficacy. *J Orthop Trauma*. 2016 Feb;30(2):53–63.
16. **Starr AJ.** Fracture repair: successful advances, persistent problems, and the psychological burden of trauma. *J Bone Joint Surg Am*. 2008;90(Suppl 1):132–137.
17. **Harris I, Mulford J, Solomon M, et al.** Association between compensation status and outcome after surgery: a meta-analysis. *JAMA*. 2005 Apr 6;293(13):1644–1652.
18. **Bone LB, Johnson KD, Weigelt J, et al.** Early versus delayed stabilization of femoral fractures. A prospective randomized study. *J Bone Joint Surg Am*. 1989 Mar;71(3):336–340.
19. **Weber D, Dulai SK, Bergman J, et al.** Time to initial operative treatment following open fracture does not impact development of deep infection: a prospective cohort study of 736 subjects. *J Orthop Trauma*. 2014 Nov; 28(11):613–619.
20. **Skaggs DL, Friend L, Alman B, et al.** The effect of surgical delay on acute infection following 554 open fractures in children. *J Bone Joint Surg Am*. 2005 Jan;87(1):8–12.
21. **Deren M, Huleatt J, Winkler M, et al.** Assessment and treatment of malnutrition in orthopedic surgery. *J Bone Joint Surg Rev.* , 2014;2(9) e1.

2.2 Diaphyseal fractures: principles

Piet de Boer

1 Introduction

In the era of minimally invasive surgery, the management of diaphyseal fractures is evolving and progressing. New reduction and fixation concepts are emerging based on better understanding of the biology of fracture repair and the role of soft tissues in the healing process [1].

Restoration of length, axial alignment, and rotation is essential, but anatomical reduction of every fracture fragment is not necessary for normal limb function.

With more options available, decision making has become more complex. The factors relevant to the optimal management of an individual diaphyseal fracture must constantly be reviewed when planning treatment.

2 Functional considerations

The diaphysis of a long bone has many functions. The two most important are to maintain its proximal and distal joints in their correct spatial relationship and to provide attachment for muscles which move them. In the long bones, normal mechanical axis of the limbs should be restored. This requires union without shortening, angulation, or rotational deformity. Good function can be expected, even if individual fracture fragments are not anatomically reduced (**Fig 2.2-1**).

Some residual deformity can be tolerated in the lower limb without causing functional problems for normal daily activity, eg, shortening of up to 1 cm or minimal angular deformities in the plane of adjacent joints. Up to 10° of anterior or posterior bowing of a healed tibia fracture is compatible with good ankle function, despite cosmetic deformity. However, valgus or varus deformity of even 5° may subject the joint to abnormal forces and lead to posttraumatic osteoarthritis [2]. In athletes with higher functional demands anatomical restoration of axial alignment must be obtained.

Fig 2.2-1a–g Indirect reduction to restore length, alignment and rotation.
a–c Fixation using a long bridge plate.
d–g Fixation using an interlocking nail.

Shortening of the humeral shaft produces little functional disability and because the shoulder has the largest range of joint movement in the body, 20° of malrotation or 30° of angular deformity is well tolerated. In contrast, the diaphyses of the radius and ulna, being part of a complex articulation that includes the proximal and distal radioulnar joints, require anatomical reduction for normal limb function.

3 Incidence

In many parts of the world improved car design, drink/drive legislation, road design, and speed restrictions and the use of seat belts have reduced the incidence of diaphyseal fractures. However, in developing countries, the sharp increase of mechanized transport, particularly motorcycles, is producing more diaphyseal injuries. Many of these fractures are open injuries and present late because of delay in transporting victims to hospital. The number of pedestrian trauma injuries is stagnating but the percentage of open fractures is rising. An increasingly aged population [3] has raised the incidence of osteoporotic diaphyseal injuries.

4 Mechanism

4.1 Patterns of injury

Fractures can be caused by direct or indirect forces. Indirect trauma usually involves less energy than a direct blow and causes proportionately less fragment displacement and soft-tissue damage. Open fractures are usually a result of direct rather than indirect forces [4]. The differing injury patterns are recognized in the AO/OTA Fracture and Dislocation Classification [5] (see chapters 1.4, 1.5, and 4.2).

Spiral (A1) fractures result from indirect rotational forces. They have large areas of bone surfaces in contact, and minimal soft-tissue damage. Fracture healing is usually swift and uneventful, although holding the reduction without fixation may be difficult.

Wedge fractures (B2) are produced by bending forces. The force applied to the limb is considerable and the resulting damage to soft tissue and periosteum is significant. Union may take longer and direct surgical approaches to the fracture site will further devitalize the bone.

Transverse fractures (A3), fragmentary wedge fractures (B3) and multifragmentary fractures (type C) are usually caused by direct forces which are often enormous, especially in the femur. If the bone is of normal quality and the fracture is widely displaced, soft-tissue damage will be extensive. Even with intact skin, direct exposure of these fractures results in further injury to the soft tissues. Therefore, fracture type and displacement are good predictors of soft-tissue damage (**Fig 2.2-2**). The greater the anticipated soft-tissue damage, the more important the timing of surgery and the choice of approach, reduction technique, and implant (see chapters 3.1.2 and 3.1.3).

5 Initial evaluation

5.1 Patient status

A clear case history must be obtained when assessing a diaphyseal fracture, particularly to discover the mechanism and forces which caused the fracture. The force generated when a pedestrian is hit by a car bumper at 50 km/h is approximately one hundred times that generated by a simple fall. Although the x-rays may look similar, the associated soft-tissue injury will be different.

Most displaced fractures are identified by observation. Palpation is only used to elicit bone tenderness if there is no obvious fracture. The most important elements of the physical examination concentrate on detecting any arterial or neurological damage. Anatomical areas where major vessels are close to bone, such as the distal femur or proximal tibia, should attract a high level of suspicion for arterial injury.

> An arterial injury will dominate the decision-making process because of the immediate need for arterial repair with appropriate stabilization of the fracture.

> Compartment syndrome also requires urgent treatment. It is seen mostly in the lower leg, but can also occur in the thigh, forearm, buttock, and foot.

Compartment syndrome may occur at any time during the first few days after trauma. It is most common in widely displaced fractures but can occur in simple fractures, open fractures, after intramedullary (IM) nailing and joint dislocation especially the knee. The clinical picture and the management are fully described in chapter 1.5.

5.2 Radiographic evaluation

X-rays are the mainstay of diagnosis. AP and lateral views including the adjacent joints will assist in most cases; oblique projections may be helpful in the metaphysis. X-rays allow accurate classification of diaphyseal fractures. Standard views of the opposite side may be useful for preoperative planning

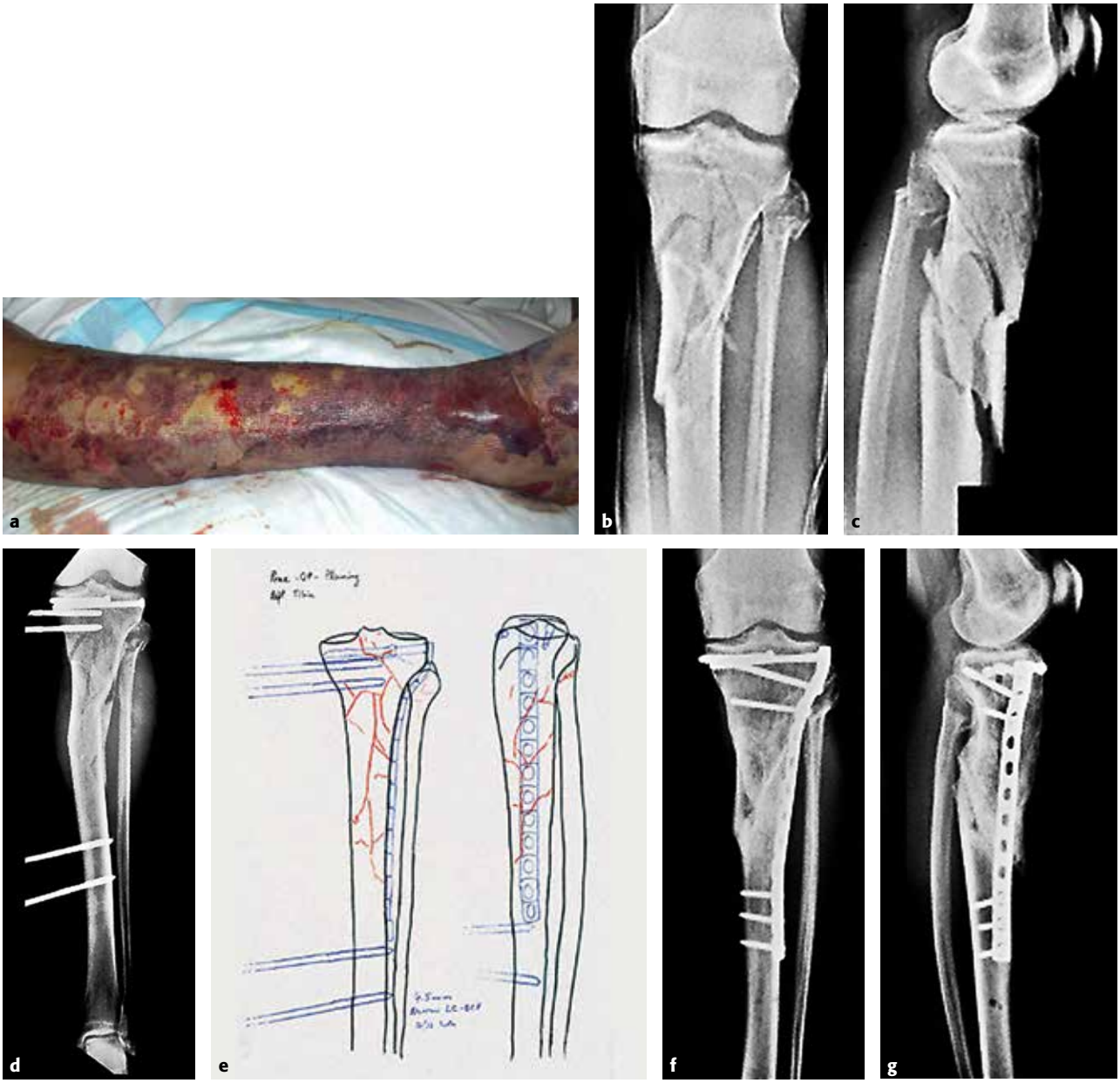

Fig 2.2-2a–g High-velocity injury (motor vehicle crash) to the proximal half of the tibia in a 30-year-old man.

a The closed injury is a multifragmentary fracture of the tibial shaft with proximal metaphyseal and intraarticular extension.

b–c The complex fracture pattern suggests extensive soft-tissue damage despite the fact that the fracture is closed.

d–e 10 days after the injury, when the soft tissues had recovered, a bridge plate was planned and applied to the lateral side of the tibia through stab incisions at the upper and lower ends of the chosen plate. Because the plate alone would not have provided enough stability to prevent varus deformation, the bridging external fixator was kept in situ to allow mobilization of the patient. The external fixator was removed at 8 weeks when callus formation was seen at the fracture site. The intraarticular fracture component was treated by closed reduction and with percutaneous cannulated screws, while the shaft fragments were bridged with a unilateral external fixator. Both procedures avoided any further soft-tissue damage to the zone of injury. The knee was then mobilized on a continuous passive motion (CPM) machine.

f–g The fracture went on to uneventful union at 16 weeks. Note: the correct axis, length, and rotation have been preserved.

(see chapter 2.4). Computed tomographic scan and magnetic resonance imaging have no role in the assessment of acute diaphyseal injuries, although they may be useful when a diaphyseal fracture has an articular extension or in planning reconstructive surgery of complex malunion cases.

5.3 Associated injuries

Soft-tissue injuries always influence and frequently dictate the management options of a diaphyseal fracture. A closed, simple, displaced, transverse fracture of the tibial shaft can be managed by intramedullary nailing, plating, or external fixation. Severe skin contusion excludes the standard open plating option because the surgical approach might further compromise the soft tissues. A badly contaminated wound might be a deterrent to primary nailing because of the risk of sepsis. In this situation, preliminary treatment with an external fixator is the treatment of choice.

Similarly, acute arterial disruption and compartment syndrome both need emergency management. In cases requiring vascular repair or extensive release of the muscle compartments, the associated fracture must be stabilized at the same time. Thus, the associated injury not only dictates the need for stabilization but also determines its timing and the approach. Plating of the fracture through the exposure used for the vascular repair may be the treatment of choice, as there may not be time for anything else.

Management of life-threatening injuries always takes precedence over that of a diaphyseal injury.

The presence of more than one fracture in the same limb is often an indication to fix all the fractures, particularly if the combination has produced a "floating" joint.

Additional fractures in other limbs, eg, bilateral humeral shaft fractures, can render a patient almost helpless. This situation may dictate operative stabilization of a fracture that might well be treated nonoperatively, if isolated.

The increasing number of elderly patients with osteoporosis who have had joint replacement surgery in the past has led to a dramatic increase in the incidence of periprosthetic fractures. This is now the most common reason to plate femurs in the developed world [6].

6 Indications for operative fracture fixation

The indications for internal or external fixation of diaphyseal fractures vary throughout the world depending on the available facilities. There are several absolute indications which can be grouped around two headings—saving life and saving limb.

6.1 Absolute indications

6.1.1 Saving life

Early stabilization of femoral shaft fractures in polytrauma patients who have been fully resuscitated has been shown to decrease morbidity and mortality (see chapter 4.1) [7]. However, there are conflicting reports as to the use of IM nails or plates, while external fixation may be applied to give temporary stabilization [8].

Better understanding of the inflammatory processes associated with trauma and its treatment have led to an increased use of external fixation to stabilize femoral shaft fractures as part of damage limitation in cases of polytrauma. Identifying those patients who would benefit from damage-control orthopedics as opposed to early total care has led to the identification of four patient groups—stable following resuscitation, borderline, unstable following resuscitation, and in extremis. Stable patients benefit from early total care. Unstable patients and those in extremis benefit from damage-control orthopedics. The optimal treatment for borderline patients remains controversial but the concept of early appropriate care involves splinting the fracture, continued resuscitation in the intensive care unit to restore normal physiology and definitive stabilization of long-bone fractures within 36 hours of injury [9, 10] (see chapter 4.1).

Early stabilization of femoral shaft fractures may be life saving but the type and method of stabilization remain controversial.

6.1.2 Saving limb

Stabilization of diaphyseal fractures is part of an emergency operation to save a limb if there is an acute vascular injury, compartment syndrome, or an open fracture. Fracture instability compromises not only the vascular repair but also the healing of any soft-tissue injury.

6.2 Relative indications

Inability to reduce or hold a fracture by means of nonoperative treatment provides an indication for surgery. Fractures of the femoral shaft are difficult to reduce and maintain in traction and nonoperative traction treatment is only indicated if proper operating facilities do not exist.

Fractures of the tibial shaft are often easy to reduce by manipulation but the stability of the reduction depends on the fracture pattern. Well-reduced transverse fractures may be stable to axial loading, but union is often slow. Nonoperative treatment of unstable multifragmented fractures carries a high risk of shortening, malrotation, and malalignment [11].

Humeral shaft fractures are often difficult to reduce and hold by nonoperative means, but significant degrees of malunion are compatible with good limb function and so surgical fixation is not routinely required.

Fractures of the forearm bones are difficult to reduce and hold anatomically by nonoperative means. Even minimal malalignment impedes normal limb function, and so surgery is almost always indicated.

6.3 Early mobilization of patients

Early mobilization of limbs and patients carries enormous benefits, especially for the aged. Stabilization of diaphyseal fractures allows early movement of adjacent joints and avoids stiffness, weakness, and muscle wasting ("fracture disease") which develops with prolonged disuse and immobilization. Early movement also reduces the incidence of type-1 complex regional pain syndrome (CRPS) (see chapter 4.7). Successful fracture fixation is associated with shorter hospital stays, earlier return to work, and reduced social care costs for compensation/invalidity.

There are important socioeconomic aspects; for example, nonoperative treatment of a femoral shaft fracture needs many weeks in hospital compared to a few days after IM nailing. This makes the cost of nonoperative treatment of femoral shaft fractures prohibitive in many developed countries. However, a severe complication following surgery may drastically change the cost/benefit ratio. In most developed countries, patient demand and expectations are also an important factor in decision making. The internet has resulted in a generation of informed patients who are often unwilling to undergo significant periods of cast immobilization. Unfortunately, many websites are commercially biased. Treating physicians need to know that patient choice should not completely dominate their own decision-making processes and all patients should be made aware of the potential hazard of surgery, especially in those cases (eg, humeral shaft) where nonoperative treatment can produce excellent results [12, 13].

7 Nonoperative treatment

Nonoperative treatment, usually by traction and/or cast, may be used for temporary or definitive management. Operative management of displaced diaphyseal fractures usually produces better functional results than nonoperative treatment in all bones apart from the humerus [13].

Advantages:
- Decreased risk of infection
- Minimal surgical equipment and facilities required
- Lower hospital costs for many fractures

Disadvantages:
- Higher risk of malunion, disuse osteoporosis, and stiffness of adjacent joints
- Prolonged hospital stay for femoral fractures

In adults, some fractures are best managed nonoperatively. Nondisplaced or minimally displaced fractures of the tibia and humerus can be effectively treated nonoperatively in a well-molded cast or fracture brace (**Fig 2.2-3**). This requires regular follow-up, since secondary displacements before bony union are frequent.

Femoral shaft fractures should not be managed nonoperatively if adequate facilities and expertise exist for safe surgical care. Nonoperative management is time-consuming and the incidence of shortening and angular deformity is high. If appropriate operating facilities and instrumentation does not exist locally, nonoperative treatment is still indicated even for femoral shaft fractures [14]. It is probably better to end up with a malunion than with chronic osteomyelitis. Nonoperative treatment of femoral and tibial shaft fractures remains the treatment of choice in large areas of the world, even in the 21st century. The correct use of traction and splints remains a critical surgical skill in these parts of the world.

The two main nonoperative methods available are traction and plaster casting. Both require skill, experience, and supervision. Traction is time-consuming and may cause delayed union in the tibia. However, it is an excellent form of provisional fixation while waiting for definitive surgery if external fixators are not available. Casting, if properly applied, is safe, although the need to immobilize adjacent joints may cause stiffness. This can be minimized by the use of hinged braces [13]. Angulation may be controlled by a well-applied cast. However, it may be difficult to control rotation and shortening in some fractures.

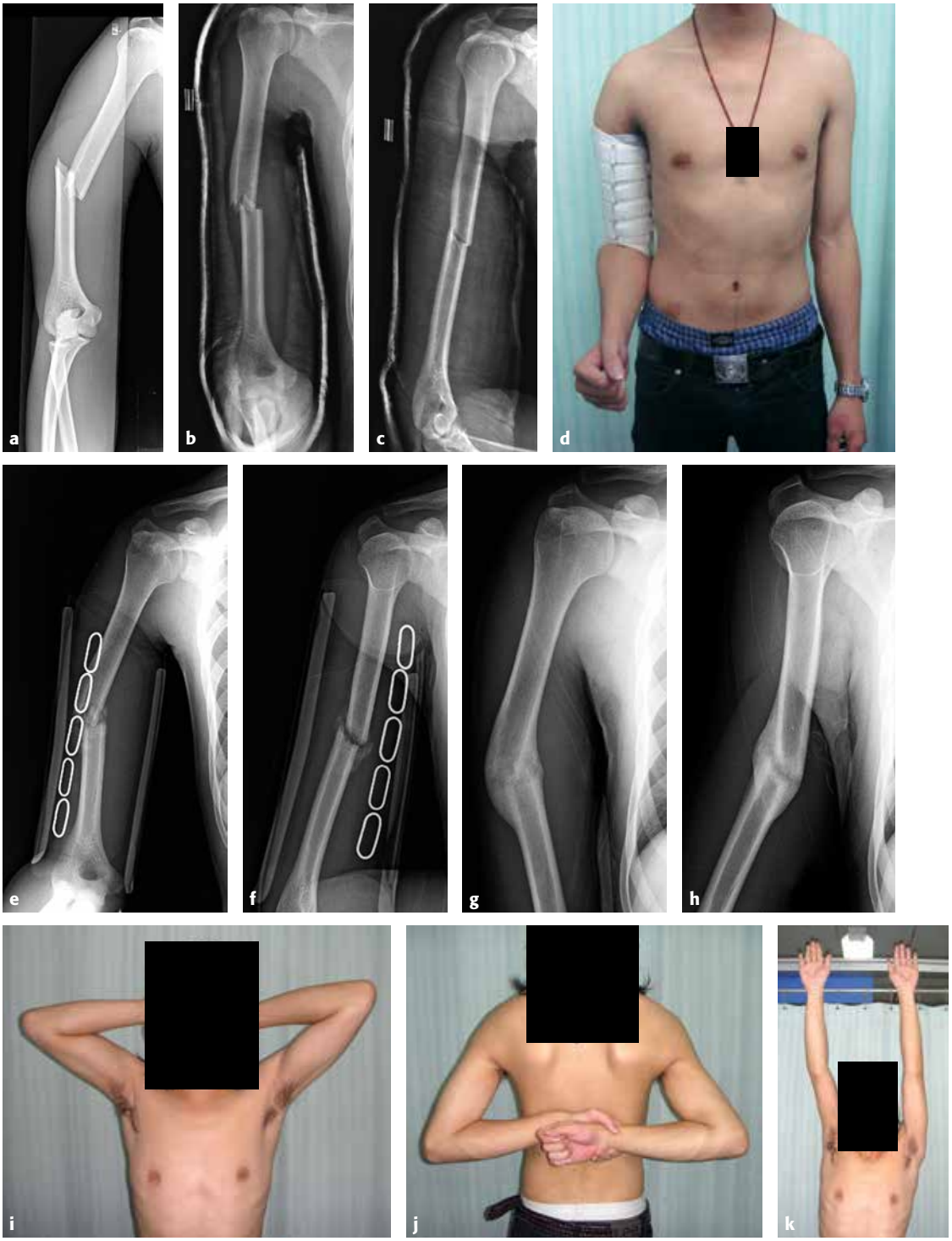

Fig 2.2-3a–k A 23-year-old man sustained a motorcycle injury.
a Fracture of the midshaft of the humerus.
b–c Closed reduction immobilization with U slap.
d After 2 weeks change to functional brace.
e–f At 4 weeks the x-ray show acceptable alignment with callus under functional brace.
g–h At 5 months the x-ray show healing with callus bridging fracture. Acceptable AP and lateral angulation were noted.
i–k Full recovery of function.

Sarmiento and Latta [13] have published excellent results on the nonoperative treatment of tibial shaft fractures and have suggested that a fracture will not displace during treatment to more than its original maximum displacement. It must be recognized that a surgeon is usually unaware of the maximum displacement of a fracture: this occurs a few milliseconds after trauma. X-rays taken at the time of admission do not show the maximum displacement of the fracture that has occurred. Casts in adults are largely confined to those diaphyseal fractures that are minimally displaced and stable.

8 Principles of operative treatment

For more detailed information about specific fracture care see chapter 6.

8.1 Timing

The timing of operative treatment of diaphyseal injuries is critical. Operative treatment should not be contemplated until the patient's general condition has been assessed. Vascular injuries, compartment syndrome, and open fractures are special cases requiring emergency management.

In general, if direct open reduction and internal fixation are indicated the sooner it happens the better. Swelling will develop and operating through swollen tissues leads to difficulty in wound closure and the risk of subsequent wound breakdown. For direct open reduction, surgical intervention within 6–48 hours is recommended for most fractures except in special anatomical locations (eg, proximal tibia, pilon, calcaneus). If significant swelling occurs sooner than this, it is usually safer to establish provisional splintage or stabilization and wait 7–15 days for the swelling to subside.

If there is any doubt as to the viability of the soft tissues, it is much safer to apply a spanning external fixator as a temporary measure and wait for the soft tissues to declare themselves.

Diaphyseal fractures of the tibia and the femur are mostly treated by indirect reduction and closed IM nailing. In this situation, swelling around the fracture site is less of a problem because these soft tissues are not in the surgical field and so timing is less critical. Intramedullary nailing requires significant expertise, thus surgery may need to wait for an experienced surgical and operating room team (**Fig 2.2-4**).

Fig 2.2-4a–f A 25-year-old woman involved in a motorcycle crash.
a–b Fractures of the femoral shaft and tibial shaft (floating knee).
c–d The femur was treated with retrograde femoral nail.
e–f The tibia was treated with antegrade tibial nail.

8.2 Preoperative planning and approaches

All operative fixations of diaphyseal fractures should be planned carefully. Preoperative planning techniques are covered in chapter 2.4. Effective planning should ensure that the surgeon does not embark on a surgical procedure unless the required personnel and equipment are available. In open fractures, it is vital to look beyond the first operation to plan how definitive soft-tissue cover will ultimately be obtained. For example, an external fixator used for provisional stabilization may obstruct the placement of a soft-tissue flap or definitive internal fixation.

The surgical approach to a fracture clearly depends on the site, soft-tissue condition, planned reduction, and choice of fixation device. Knowledge of the anatomy is essential and dissection must be gentle. When the planned approach is unfamiliar, reference to a standard work on surgical approaches is mandatory [15] and dissection of human anatomical specimen is desirable.

Adoption of minimally invasive techniques calls for percutaneous access, usually performed with x-ray control. These techniques may possibly minimize soft-tissue trauma, but are technically demanding and excessive traction on the skin, for the sake of a smaller incision, must be avoided. The need to master the relevant anatomy and reduction techniques is just as important in these instances, as the surgeon cannot see the tissues and structures beneath the soft tissues [15].

8.3 Reduction and fixation techniques

Diaphyseal fractures can be reduced directly or indirectly. The principles are described in chapter 3.1.1.

Independent of the technique, any reduction maneuver should be as gentle as possible to preserve all existing blood supply to the soft tissues and periosteum.

In the treatment of diaphyseal fractures the fixation techniques used most commonly are IM nailing, plating, and external fixation.

Intramedullary nails are internal splints which are load sharing and allow early weight bearing. They allow a small degree of movement at the fracture site (relative stability) and their use is associated with callus formation and early bone union [4]. Locked IM nails control rotation and allow multifragmentary fractures to be held out to length. In the lower extremity, load-sharing implants that allow early weight bearing are usually preferable to implants, such as plates and screws, which are more prone to fatigue failure if healing is prolonged [4]. However, IM nailing is contraindicated in fractures with a small or deformed medullary canal, if the medullary canal is occupied by an implant or prosthesis, and children with open growth plates.

Plates and screws may be a good option for shaft fractures extending to the metaphyseal area or into a joint. They can be inserted using direct or indirect reduction techniques. Simple fractures (that can easily be reduced anatomically, or with interfragmentary lag screws combined with a protection plate) are best treated with this method of fixation or careful nonoperative care (**Fig 2.2-3**).

Bridge plating with relative stability is not a good option for simple diaphyseal fractures. The risk of nonunion is high because of high strain produced at the fracture site [16].

Plating of complex multifragmentary diaphyseal fractures should use minimally invasive techniques with indirect reduction. The plate acts as a bridge, provides relative stability and leaves the fracture site untouched (see chapters 3.1.3 and 3.3.2).

Bone quality is highly important. Severe osteoporosis diminishes the holding power of screws or bolts or external fixation pins. External fixation or plating of fractures using conventional plates and screws may fail in osteoporotic bone.

Locking plates (chapter 3.3.4) have expanded the indications for plate fixation in diaphyseal fractures, especially those fractures extending into the metaphysis. Locking plates provide greater stability than conventional plates with improved fixation in short metaphyseal segments. This advantage may also be seen in osteoporotic bone. Anatomical, precontoured plates are now available for the metaphyses of all bones and may allow diaphyseal injuries associated with metaphyseal or intraarticular fractures to be treated with a single implant.

External fixators are still the gold standard in cases of severe soft-tissue problems and in those parts of the world where nails and plates are more difficult and risky to use. This may be because of infection rates or for logistical and technical reasons, eg, operating room sterility, lack of image intensification. However, pin-track problems (infection, loosening) are common, and fracture healing may be delayed if frames are too stiff and malunion may still occur. Therefore, external fixators are not a popular choice for definitive fixation and a change of method is often considered once the early fracture factors have been mastered (see chapter 3.3.3).

The use of external fixators as a temporary measure to allow the recovery of soft tissues has become increasingly popular, as has the use of temporary external fixation for the immediate stabilization of femoral shaft fractures in polytrauma.

The treatment of pathological fractures demands special consideration. In a patient with a limited life expectancy it may be more sensible to aim for an improved quality of life with mobility and pain relief rather than perfect reduction. The use of an adjuvant technique, eg, the use of bone cement should also be considered, although it may retard bone healing. Joint replacement may also be an option where there is extensive disease of the diaphysis and metaphysis.

9 Postoperative care

Postoperative mobilization is influenced by the presence of other injuries, the patient's general health, and psychosocial issues.

The most important factor in deciding about mobilization and functional loading is the surgeon's assessment of the stability of the fixation.

Fracture anatomy and fixation technique must be considered together. When in doubt, activity may need to be delayed and carefully monitored.

Physiotherapy aimed at muscle rehabilitation should start as soon as possible after surgery and continue until normal function of the limb is obtained.

Early active movement of the muscles and joints is best but can be painful and so must be combined with careful and planned pain management (see chapter 4.7). Continuous passive motion [17], if used, should always be combined with active muscle exercises to reduce the risk of muscle wasting.

Load transmission is an important stimulus for bone growth and prolonged non-weight bearing is associated with disuse osteopenia, atrophy of articular cartilage, and muscle wasting. The aim should be to obtain a fixation construct that allows for early partial or full weight bearing in the compliant patient. Good preoperative planning is the key to avoiding surgical fixation that is not strong enough to allow mobilization with or without weight bearing.

10 Outcome

Patient outcomes vary with the severity of the injury as do complications (see sections 5 and 6). Low-velocity injuries without associated soft-tissue damage should regain full function with appropriate treatment. High-velocity injuries with soft-tissue loss will not regain normal function but careful assessment, preoperative planning, meticulous operative technique, preservation of soft tissues, and diligent postoperative rehabilitation will ensure best possible recovery for any patient.

Classic references | Review references

11 References

1. **Buckwalter J, Einhorn T, Simon S,** eds. *Orthopedic Basic Science.* 2nd ed. Chicago: American Academy of Orthopaedic Society; 2000:371–400.
2. **Pauwels F.** *Biomechanics of the Locomotor Apparatus: Contributions of the Ffunctional Anatomy of the Locomotor Apparatus.* Berlin Heidelberg New York: Springer-Verlag; 1980.
3. **Johnell O, Kanis J.** Epidemiology of osteoporotic fractures. *Osteoporos Int.* 2005 Mar;16(Suppl 2)S3–7.
4. **Perren SM.** The biomechanics and biology of internal fixation using plates and nails. *Orthopedics.* 1989 Jan;12(1):21–34.
5. **Müller ME, Nazarian S, Koch P, et al.** *The Comprehensive Classification of Long Bone Fractures.* Berlin Heidelberg New York: Springer-Verlag; 1990.
6. **Sidler-Maier CC, Waddell JP.** Incidence and predisposing factors of periprosthetic proximal femoral fractures: a literature review. *Int Orthop.* 2015 Sep;39(9):1673–1682.
7. **Pape HC, Hildebrand F, Pertschy S, et al.** Changes in the management of femoral shaft fractures in polytrauma patients: from early total care to damage control orthopedic surgery. *J Trauma.* 2002 Sep;53(3):452–461; discussion 461–462.
8. **Boulanger BR, Stephen D, Brenneman FD.** Thoracic trauma and early intramedullary nailing of femur fractures: are we doing harm? *J Trauma.* 1997 Jul;43(1):24–28.
9. **Vallier HA, Wang X, Moore TA, et al.** Timing of orthopaedic surgery in multiple trauma patients: development of a protocol for early appropriate care. *J Orthop Trauma.* 2013 Oct;27(10):543–551.
10. **Nicholas B, Toth L, van Wessem K, et al.** Borderline femur fracture patients: early total care or damage control orthopaedics? *ANZ Surg.* 2011 Mar;81(3):148–153.
11. **Bone LB, Sucato D, Stegemann PM, et al.** Displaced isolated fractures of the tibial shaft treated with either a cast or intramedullary nailing: an outcome analysis of matched pairs of patients. *J Bone Joint Surg Am.* 1997;79(7):1336–1341.
12. **Wallny T, Sagebiel C, Westerman K, et al.** Comparative results of bracing and interlocking nailing in the treatment of humeral shaft fractures. *Int Orthop.* 1997;21(6):374–379.
13. **Sarmiento A, Latta LL.** *Closed Functional Treatment of Fracture Bracing.* Berlin Heidelberg New York: Springer-Verlag; 1995.
14. **Dresing K, Trafton P, Engelen J.** *Casts, Splints, and Support Bandages—Nonoperative Treatment and Perioperative Protection.* New York Stuttgart: Thieme: 2014.
15. **Hoppenfeld S, de Boer P, Buckley R.** Surgical approaches in orthopaedics. In: *The Anatomy Method.* 6th ed. Philadelphia: Lippincott; 2016.
16. **Paluvadi S, Lal H, Mittal D, et al.** Management of fractures of the distal third tibia by minimally invasive plate osteosynthesis: a prospective series of 50 patients. *J Clin Orthop Trauma.* 2014 Sep;5(3):129–136.
17. **Salter RB.** The physiologic basis of continuous passive motion for articular cartilage healing and regeneration. *Hand Clin.*1994 May;10(2):211–219.

2.3 Articular fractures: principles

Chang-Wug Oh

1 Introduction

Disruption of any component of a joint may result in altered joint function because of the pathological processes of arthrofibrosis or osteoarthrosis. For example, displaced intraarticular fractures are associated with gaps or steps at the joint surface that can immediately affect stability, cause pain, and disrupt effective motion of the joint and joint mechanics. The inflammatory response associated with such an injury can lead to extensive fibrosis both within the joint and in the surrounding soft tissues. This response can be exacerbated by inappropriate immobilization or surgical procedures. For these reasons, closed reduction and external immobilization were commonly unsuccessful in the early treatment of displaced intraarticular fractures. The result was commonly a bone deformity with associated stiffness, pain, and functional disability. The introduction of treatment with traction and joint mobilization improved motion but instability and incongruity of the joint persisted. To avoid these complications of nonoperative treatment, Charnley [1] proposed that perfect anatomical restoration and joint movement could only be obtained by open reduction and internal fixation. However, early implants were unable to achieve sufficient stability to allow immediate motion while preventing displacement. As a result, patients received the worst possible combination of treatments: the risks of open reduction combined with the complications of long-term external immobilization. Outcomes were poor following surgery and most experts advocated nonoperative treatment.

The advent of antibiotics, improved soft-tissue handling, improved metallurgy with new implant designs, and better understanding of the injuries by surgeons dedicated to fracture care, resulted in open reduction and internal fixation of intraarticular fractures becoming safer and more widely accepted. Application of the AO/OTA Fracture and Dislocation Classification principles of operative fracture treatment confirmed that internal fixation with absolute stability and early joint motion improved radiological and clinical results for articular fractures [2].

2 Functional considerations

The surgeon can impact three key factors that influence joint function and the risk of posttraumatic arthritis: joint incongruity, malalignment, and instability.

Incongruity of the articular surface may cause increased contact stresses in the joint [3]. If this incongruity combines with instability, it may cause abnormal movement with disproportionate increases in contact stress rate and magnitude. It can anatomically shift the articular surface-loading pattern, initiating posttraumatic osteoarthritis with secondary inflammation leading to degeneration of the joint. Although, clinical evidence linking incongruity to posttraumatic osteoarthritis is still inconclusive, it is important to attain the suitable congruity of injured joints (**Fig 2.3-1**) [4].

Malalignment may shift the loading pattern of the articular surface in a joint, which may be crucial to subsequent progression of osteoarthritis. The new point of contact may be maladapted for cartilage loading and may be unable to rapidly accommodate the transition to load bearing via remodeling, leading to degeneration of the whole joint. Particularly in the lower extremity, the restoration of the anatomical axis is crucial [5].

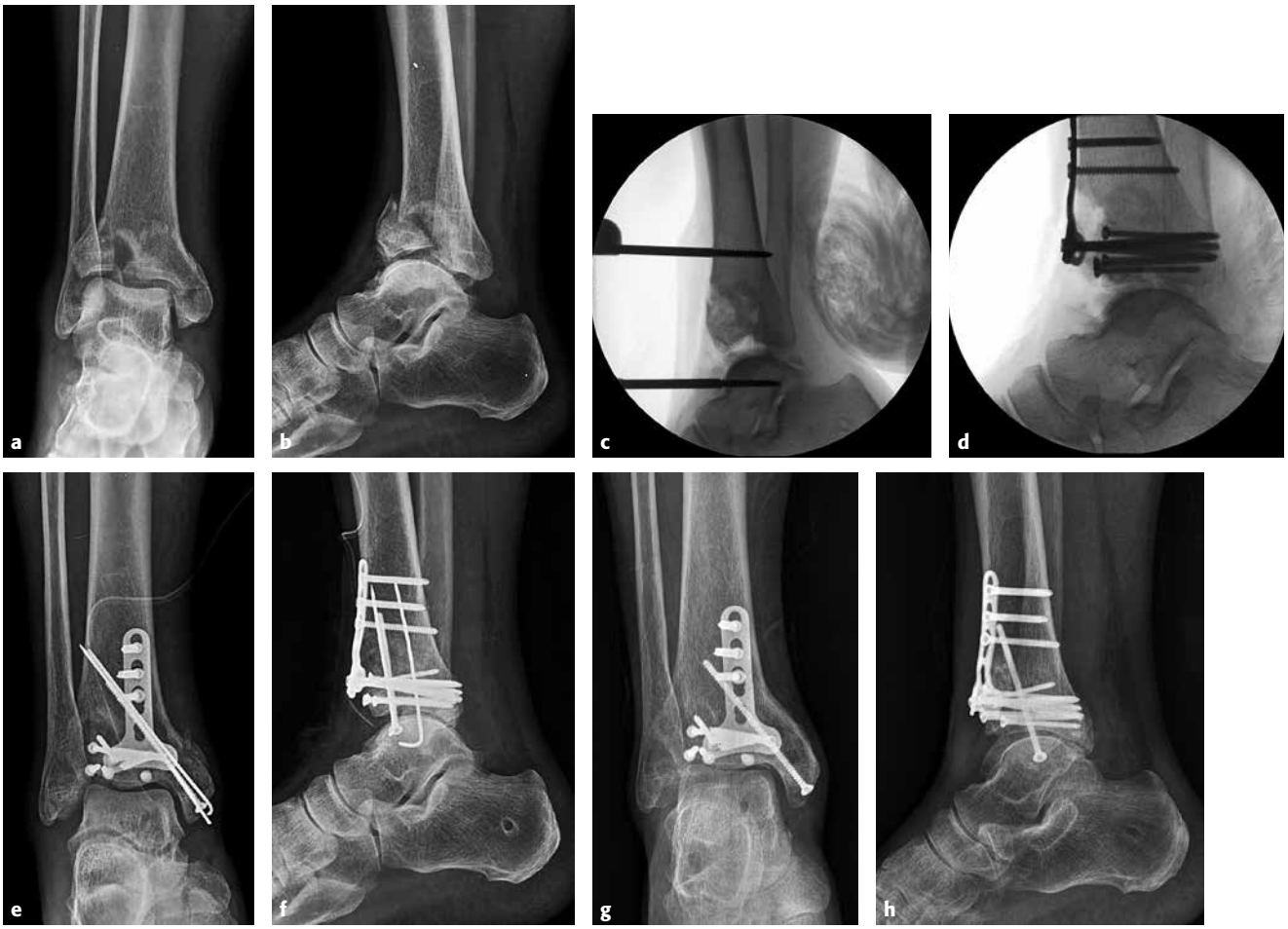

Fig 2.3-1a–h Anatomical reconstruction of the joint surface combined with stable fixation allows early motion and distributes forces evenly across the joint, which is essential for a good long-term result.
a–b Complete articular fracture of the distal tibia.
c–d With the help of distractor, the meticulous reconstruction of joint surface was performed.
e–f Exact reconstruction of the articular surface and stable fixation, followed by early movement of ankle joint.
g–h After 3 years, there are early signs of arthritis but good function persists.

Instability caused by fracture, ligament or meniscal injury can also lead to cartilage degeneration and may be important in determining outcome. An example is the high incidence of posterior subluxation, as the initial mode of failure, after operation on multifragmentary posterior wall fractures of the acetabulum (**Fig 2.3-2**). This may indicate that posterior subluxation or instability of the hip joint is an important factor leading to degeneration after internal fixation of posterior wall fractures. In tibia plateau fractures, excising the meniscus during surgery increases loading strain and may provoke instability of knee joint. The development of osteoarthritis and poor outcomes are common and modern surgical techniques emphasize the importance of preserving the meniscus and restoring knee stability by appropriate ligament repair or reconstruction (see chapter 6.7.2).

Joint malalignment, joint instability, and articular incongruity play a role in the development of posttraumatic osteoarthritis. However, the relative contribution of each factor to the subsequent progression of arthritis has not been well characterized. A combination of these factors is likely to give a worse outcome than a single factor alone. The joint involved is also a factor and symptomatic arthritis is more likely in weight-bearing joints [6, 7].

Fig 2.3-2a–d A poorly reconstructed joint may quickly become osteoarthritic.
a Posterior wall acetabular fracture.
b Reduced with a screw and reconstruction plate.
c Postoperative computed tomographic scan shows an imperfect reduction (arrows) as well as incongruity.
d At 6 months postoperatively, arthritis was noted with narrowing of hip joint.

Thus, most authors agree that it is necessary to secure an anatomical reduction of the articular surface, restore joint stability, and normal axial alignment to provide the patient with the best possible chance of permanent joint preservation.

The current philosophy of operative treatment of these injuries is based on the following observations [8]:

- Plaster cast immobilization of intraarticular fractures results in joint stiffness.
- Plaster cast immobilization of intraarticular fractures after open reduction and internal fixation results in much greater stiffness.
- Depressed central articular fragments are impacted and will not be reduced by closed manipulation and traction.
- Major articular depressions do not fill with fibrocartilage. The resulting instability is permanent.
- Anatomical reduction and stable fixation of articular fragments is necessary to restore and maintain joint congruity.
- Metaphyseal defects beneath reduced articular segments must be filled with structural bone graft or substitute to prevent articular fragment redisplacement.
- Metaphyseal and diaphyseal displacement must be reduced to obtain proper limb alignment and prevent joint overload.
- Early motion is necessary to prevent joint stiffness and to maximize articular healing and recovery. This requires stable internal fixation.

3 Mechanism of injury

There are two common mechanisms of injury for articular fractures:

1. **Indirect application of force**, producing a bending moment through the joint and drives a part of the joint into its opposing articular surface. Usually the ligaments are strong enough to initially resist this eccentric load, converting the bending moment to direct axial overload and fracturing the joint surface. Typically, this results in a partial articular fracture (**Fig 2.3-3a–b**).
2. **Direct application of force**, either to the metaphyseal/diaphyseal component of the joint or through axial transmission of force along the diaphysis (**Fig 2.3-3c–e**). This direct crushing or axial application of force causes an explosion of the bone and a dissipation of force into the soft tissues. Complete multifragmentary articular fractures, often with associated severe soft-tissue injuries, are the result (**Fig 2.3-4**). The bone quality, the position of the limb, and the exact vector of the force determine the fracture pattern.

4 Evaluation of the patient and the injury

4.1 Clinical evaluation

Many joint injuries are caused by high-energy trauma and systematic evaluation of the whole patient is essential because there is a high risk of polytrauma. Once life-threatening injuries have been addressed, the joint injury must be evaluated in a systematic manner.

When assessing any joint injury, pay close attention to the soft-tissue envelope as intraarticular fractures may be open and can cause gross malalignment of the limb, joint subluxation, or dislocation. Associated ligament injuries must be examined initially by palpation along the course of the ligament and examined again after fixation of the fracture. The vascular status distal to the injury must be evaluated in every case and recorded clearly in the medical record. This is best done by palpation of the pulses distal to the injury. If there are no palpable pulses or if a discrepancy exists between the injured and the contralateral side, the use of a Doppler monitor and assessment of capillary refill, color, and skin temperature are necessary. The ankle-brachial index (ABI) provides reliable objective information regarding arterial compromise following blunt or penetrating injury in the lower limb. An ABI of less than 0.9 indicates a probable vascular injury [9]. A careful neurological examination of the limb must also be performed and documented.

Ideally, x-rays should be obtained before any closed reduction maneuver but these must be performed immediately if there is any suggestion of neurovascular compromise. If obtaining radiographs will cause a delay of more than a few minutes, the limb should be realigned. Following realignment and splinting of the limb, neurological and vascular examination must be repeated (and recorded) and a further radiograph obtained.

Extensive open wounds, lacerations, or degloving are identified in the zone of injury. Even a small disruption of the skin near a fracture must be considered an open fracture or an open joint injury until proven otherwise. Leakage of blood-stained synovial fluid, fat globules in the blood or leakage of intraarticularly injected fluid indicate that a fracture or joint injury communicates with the external environment.

Severe injury to the surrounding tissues can occur even in the absence of open wounds. Determining the mechanism of injury can help to predict the evolution of the soft-tissue injury. The presence and location of any abrasions, joint

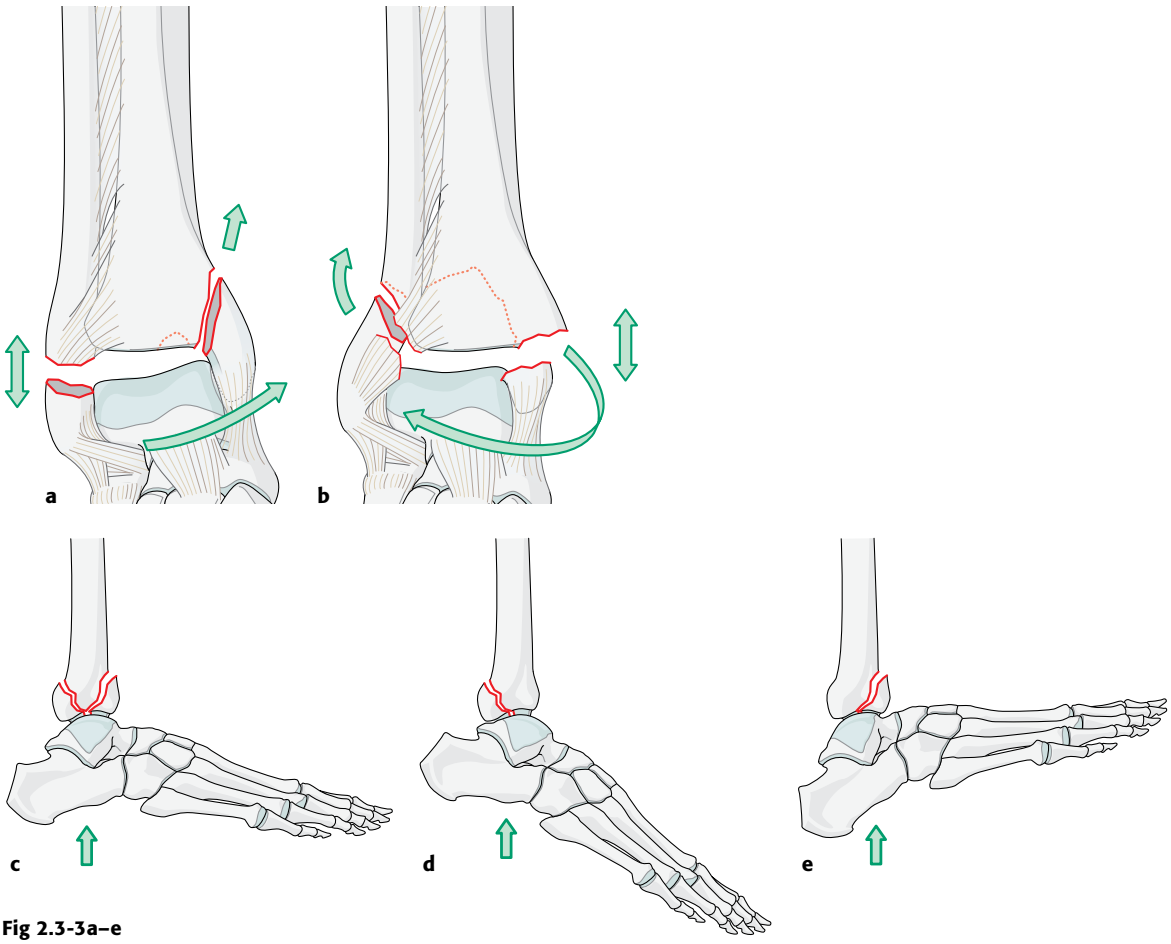

Fig 2.3-3a–e
There are two mechanisms that commonly cause an articular fracture:

a–b An eccentric load or indirect force may cause excess pronation or supination, varus or valgus movement to any joint. Loading one side of the joint usually produces a shearing fracture (**a**), while a pull on the ligamentous insertions on the opposite side results in an avulsion fracture or torn ligament (**b**).

c–e The other mechanism is an axial loading force, which allows one component to act as a hammer on the other, producing impaction of the articular surface or, if more severe, impaction with fracture fragmentation of the metaphysis with or without diaphysis.

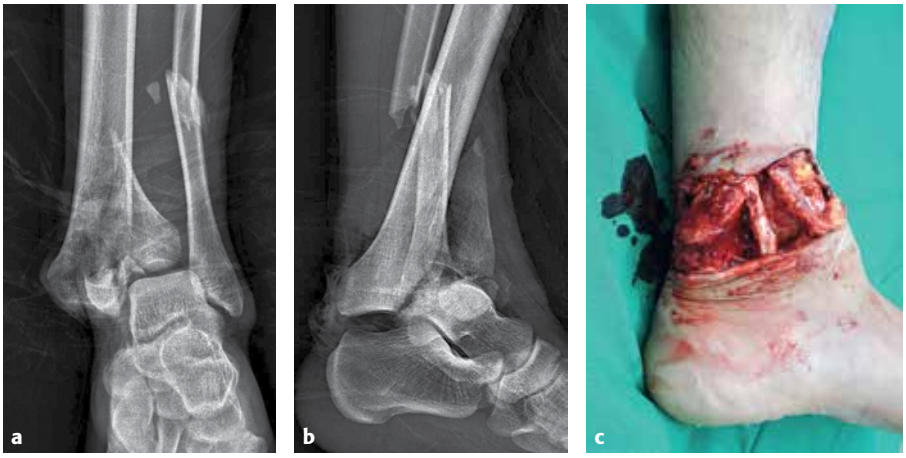

Fig 2.3-4a–c Direct force transmission (fall from a height) results in severe fracture impaction or dislocation (**a–b**) and associated soft-tissue injury (**c**).

effusion, skin blistering, and soft-tissue swelling should be noted. Point tenderness at ligamentous insertions may be the only clue to ligamentous disruption. Muscular compartments should be evaluated for any evidence of compartment syndrome.

4.2 Radiological evaluation

Plain x-rays can provide a wealth of information regarding the injury to bone and offer clues about associated soft-tissue injury. Initial x-ray analysis includes two views obtained in planes 90° to each other and centered over the zone of injury (**Fig 2.3-5a–b**). If clinically indicated, the rest of the limb should be examined by x-rays.

For simple fractures, AP and lateral x-rays suffice. For more complex fractures, oblique x-rays taken at 45° to the coronal plane will help to identify fracture fragments (**Fig 2.3-5c–d**). Displacement and fragmentation of the articular and metaphyseal bone, identified by standard views, can provide information for planning treatment. Free articular fragments impacted into the supporting cancellous bone of the metaphysis can be identified by the density of their subchondral cortical bone (**Fig 2.3-5a–d**). Depressed central fragments, without soft-tissue attachments, cannot be reduced to their original position by closed manipulation. The identification of impacted fragments is important because repositioning requires direct operative reduction.

If there is extensive fragmentation and deformity, traction applied to the extremity during x-ray examination may improve understanding of the injury. If required, traction views are best obtained under anesthesia and are helpful for planning surgical fixation (see chapter 2.4)

Computed tomography with coronal and sagittal reconstructed images provides additional information about the number and position of the articular fragments, the presence of impacted articular segments, the location of metaphyseal fracture lines, and the overall morphology of the injury (**Fig 2.3-5g–i**). This can be invaluable in preoperative planning to determine the surgical approach, screw placement, and implant position. Computed tomography will provide the most information after realignment of a severe deformity and so is best delayed until after a temporary spanning external fixator is applied (**Fig 2.3-5e–f**).

5 Indications for operative fracture fixation

Restoration of limb function after trauma is dependent on free and painless function of the joints. Operative fracture fixation for displaced intraarticular fractures is recommended to achieve anatomical reduction of the articular surface and fixation with absolute stability. However, the decision to operate is not based on the fracture alone but will also depend on the soft tissues and the patient: *the personality of the injury*. In addition, some joints tolerate much greater incongruity than others and so indications for operative reduction will vary by fracture location.

Operative fixation of articular fractures in frail, older patients with osteoporosis is challenging. Outcomes are less good and in some situations primary joint replacement will give more reliable results. This is well established for displaced subcapital fractures of the proximal femur and may also be a good option in some cases of acetabular fracture [10] and supracondylar fractures of the elbow [11].

5.1 Absolute indications

Articular fractures need operative treatment in the following circumstances:

- Open fractures (for soft-tissue management)
- Irreducible fracture dislocations
- Associated neurological injuries when displaced fragments put pressure on nerves
- Associated with vascular injuries
- Associated compartment syndrome

5.2 Relative indications

Surgery for articular fractures should be strongly considered in the following:

- Displaced articular surface > 2 mm
- Loose fragments within joint
- Displaced fractures resulting in instability
- Significant displacement of the mechanical axis of the limb

5.3 Early mobilization of patients

Salter et al [2] demonstrated that articular immobilization after joint injury leads to stiffness and articular cartilage degeneration. It is assumed that this is due to a lack of nutrition and the formation of a destructive pannus. Further experiments revealed that the use of continuous passive motion (CPM) facilitated the repair of full-thickness articular cartilage defects in immature rabbits. In high-energy fractures of the tibia plateau, provisional external fixator used to manage the soft-tissue envelope may be a risk factor for the development of arthrofibrosis. In a recent report [12], CPM following definitive fracture fixation may reduce this complication.

Fig 2.3-5a–i X-ray/computed tomographic scan evaluation of the bone injury.

a–b Standard AP and lateral x-rays usually demonstrate the major fracture pattern. Impaction of the joint surface can be assumed when there are irregularities of the subchondral lines and double densities in the metaphysis.

c–d Oblique views in two planes may give further evidence of the articular involvement and help to determine more precisely the extent and location of the lesion.

e–f Spanning external fixation was performed to care for the soft-tissue injury.

g–i Computed tomographic scan was done after external fixation. 2-D reconstruction images show the depression and impaction of bicondylar fractures. 3-D reconstruction images give the complete picture of a damaged joint and facilitate preoperative planning.

6 Nonoperative treatment

Nondisplaced fractures may be treated nonoperatively. Even with displaced intraarticular fractures, some patients may be better treated without surgery, especially those with significant comorbidities, heavy smokers, and noncompliant patients. The surgeon needs to balance the risks and benefits of surgery and this requires fine judgment.

7 General principles of operative treatment

7.1 Timing

Following full evaluation of the patient and the specific injury, certain factors may influence the timing of surgery. In polytrauma, the timing of surgery will depend on the patient's physiological response to resuscitation. During damage-limitation surgery, the only articular injuries that will be addressed are those with vascular injury, compartment syndrome, or severe wound contamination: surgery is limited to restoring circulation and decontamination. The joints should be splinted or a spanning external fixator applied. Complex fracture reconstruction should not be performed and is often best delayed until the window of opportunity at day 5–10 (see chapter 4.1). Early articular fracture fixation can be considered in patients who respond to resuscitation and are fit for early appropriate care. However, there is no evidence that early stabilization of articular fractures confirms the physiological benefits that are observed with early stabilization of diaphyseal long-bone fractures. Thus, the timing of surgery for complex articular fractures in polytrauma will depend on the soft tissues, preoperative planning, and having the right surgical team.

In a patient with an isolated injury to a joint, the rapid onset of excessive swelling after injury is usually the result of hemorrhage into the joint and the surrounding tissues. Immediate surgery may allow evacuation of such a hematoma, while reduction and fixation will reduce further bleeding and possibly reduce further swelling [13]. Therefore, with experienced surgeons, the best time for early fracture fixation may be immediately after the injury.

If an injury includes open contamination of a joint, very early (< 6 hours) surgery should be performed and exposed articular cartilage must be treated with debridement, irrigation, and early joint closure. Failure to do this will result in drying of the cartilage and very early joint degeneration and destruction.

If the soft-tissue envelope around the joint is swollen or traumatized with abrasions, fracture blisters or degloving, open surgery within the first few days may be contraindicated. Early operative intervention for complex periarticular fractures of the leg is time consuming and has been associated with an increase in wound-healing complications [14]. Delaying definitive surgery for several days may be more appropriate. Temporary stabilization of the fracture by an external fixator spanning the joint may be helpful in preventing further soft-tissue damage and maintaining overall alignment. The external fixator should be placed outside the zone of injury and outside the zone of potential definitive surgery. This not only reduces pain and leads to more rapid resolution of the swelling but also makes the delayed reconstruction much easier. The timing of definitive fixation is determined by the condition of the patient and the soft-tissue envelope. It is safe to operate when the skin in the area of the planned surgery has regained its creases and wrinkles.

Abrasions and blisters need to be epithelialized and dry before performing surgery near them. In case of a closed subcutaneous degloving or crushing of the subcutaneous fat, early operative debridement followed by a delayed articular reconstruction is recommended.

It must be recognized that delayed surgery makes reduction more difficult as hematoma organizes and the soft tissues become stiffer and more difficult to mobilize because of induration. This can pose a serious risk if the approach requires exposure and mobilization of major vessels (large veins are at particular risk of injury). Thus, the surgeon needs to balance the risks of early surgery with the potential for increased wound complication against the risk of poor fracture reduction with delayed surgery. In acetabular fractures, better reduction and outcome may be achieved in patients with surgery within 5 days [15].

7.2 Preoperative planning

Preoperative planning is an important prerequisite in open reduction and internal fixation of intraarticular fractures. Adequate x-ray analysis together with the soft-tissue assessment will allow the surgeon to understand the personality of the injury and what will be needed to achieve the surgical goals. Deciding on the details of the procedure including the operating table, patient position, approach, reduction tactic, specific instruments, implants, need for intraoperative x-ray, before commencing will allow the surgery to proceed more efficiently and without the hazards of unforeseen problems (see chapter 2.4).

A detailed plan of the different steps and surgical tactic is mandatory before starting any surgery on an intraarticular fracture. It also serves as an educational tool and may be used for quality control by the surgeon and their peers.

7.3 Reduction and fixation techniques

Indirect reduction using traction and ligamentotaxis can be effective for articular fractures where the fragments have soft tissue (mainly joint capsule) still attached. Direct reduction is required for central articular fragments that are impacted (depressed) or free within the joint. All fracture surfaces must be thoroughly cleared of hematoma and any early callus. Regardless of their size, all articular fragments should initially be retained as keys to the final reduction. Loose osteochondral fragments can be removed from the wound but impacted fragments should not yet be elevated from their underlying cancellous beds. Once debris has been cleared, traction is reduced to allow the intact portions of the joint to resume their anatomical position. If there is inadequate stability, the large distractor or an external fixator may be used to maintain distraction and axial alignment and to allow some indirect reduction of fracture fragments (**Fig 2.3-6a**). The intact joint surfaces and the opposing articular surfaces are used as templates to judge the reduction of displaced or impacted articular fragments.

Impacted osteochondral fragments should be elevated from the underlying metaphyseal bone together with an adequate block of cancellous bone using an osteotome or elevator. This technique maintains the impacted zone between the subchondral cortical bone and its underlying cancellous bone, facilitating future fixation (**Fig 2.3-6b**).

Free cartilage or small (< 4 mm) osteochondral fragments without any cancellous bone support are helpful in reducing major articular fragments. However, it may be difficult to retain and fix them reliably and their long-term viability is questionable. In general, they are best removed after aiding reduction.

Bone defects remaining within the metaphysis can be filled with autogenous or allogenic bone grafts or bone substitutes to provide early structural support to the articular surface and to stimulate reconstitution of metaphyseal bone stock. This may also provide support for the articular surface once weight bearing has been resumed. Cortex reduction and soft-tissue attachments will aid in reduction of peripheral fracture fragments and their associated articular surfaces. Self-centering, pointed bone-holding forceps or K-wires are temporarily used while the reduction is confirmed radiographically (**Fig 2.3-6c**).

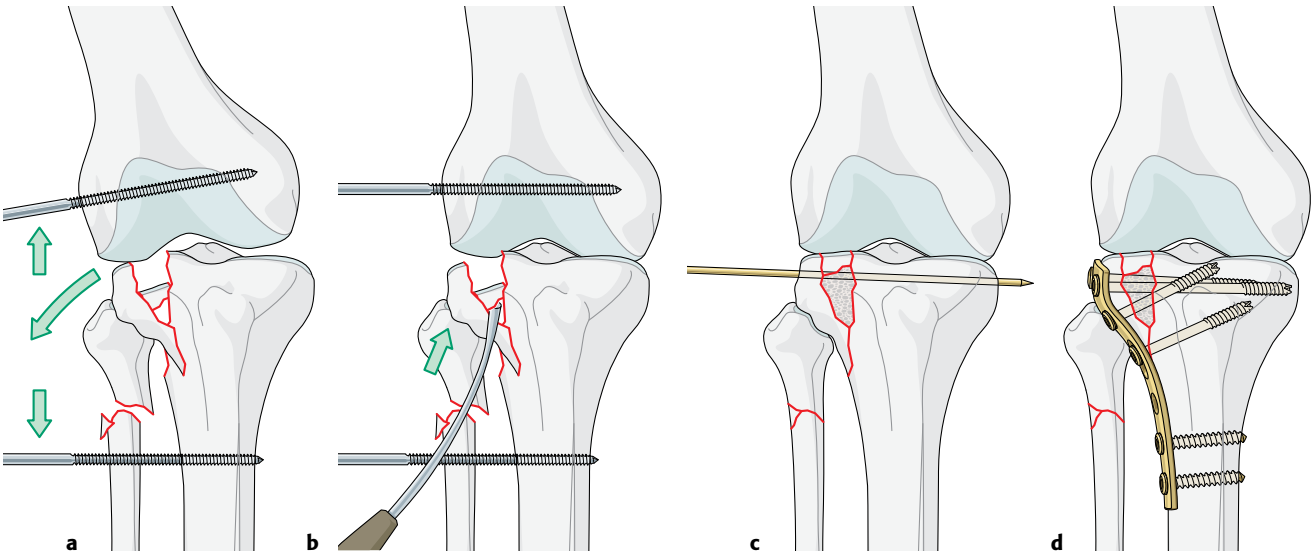

Fig 2.3-6a–d Reconstruction of a tibial plateau fracture through a straight lateral parapatellar approach.

a Indirect reduction and axial alignment is achieved by ligamentotaxis and a joint bridging distractor.

b The large, impacted articular fragment is elevated with a curved impactor introduced through the fracture or through a cortical window in the metaphysis.

c After temporary fixation of the reduced fragment with a K-wire, the metaphyseal bone defect is filled with autogenous cancellous bone or a corticocancellous block acting as a strut.

d The reconstructed lateral plateau is buttressed by a conventional or locked plate. The K-wire has been replaced by a 6.5 mm cancellous lag screw.

In simple partial articular split fractures, closed reduction may be attempted using the image intensifier or arthroscopy to check the reduction, followed by minimally invasive fixation with lag screws. For complete articular fractures with metaphyseal fragmentation (C3 injuries), no portion of the articular surface has any contact to the diaphysis. The surgeon has two strategies for reduction: either they reconstruct the joint surface (converting a C-type fracture to an A-type) and then reattach this to the metaphysis or they reduce the simplest part of the metaphysis and joint to the diaphysis (converting a C-type fracture to a B-type partial articular injury) and then reduce the rest of the joint and metaphysis onto this to produce an anatomical reduction.

Direct inspection of the joint surface, either through arthrotomy or arthroscopy, will help to evaluate the reduction of the joint surfaces. Intraoperative image intensification or x-rays will also provide information on reduction. Once the reduction appears satisfactory, fixation of the intraarticular portion can be completed (**Fig 2.3-7**). Lag screw fixation creates compression between the fracture fragments and results in stable fixation. If multiple small fragments are present care must be taken not to overcompress these fragments. In this situation, reduction and support of the fracture without compression can be maintained with fully threaded position screws as absolute stability cannot be obtained. Multiple 3.5 mm screws can be applied under the subchondral bone to support fracture fragments. This "rafting technique" is best used in combination with locking head screws through a plate, producing a fixed angle device that supports the joint surface. The effect of this stable support on the local biology of the bone and cartilage is not yet clear.

7.4 Articular fractures with metaphyseal/diaphyseal extension

Once the articular block has been reduced anatomically and fixed with absolute stability, the next task is to join it in the correct axial and rotational alignment to the diaphysis. Exact reduction of cortical fragments in the metaphysis is usually not necessary. This fixation must be stable to allow early movement of the joint. This can be achieved using a plate, external fixator, or an intramedullary nail with locking bolts. Larger cancellous bone defects may need some sort of bone graft or bone substitute (**Fig 2.3-6d**).

Hybrid external fixators and ring fixators can be used with limited surgical exposure of the metaphysis/diaphysis [16]. A significant part of the force is transmitted through the fixator, and relative stability of the entire construction will be sufficient to allow controlled early motion.

Fragmentation of the metaphysis or diaphysis may tempt a surgeon to precisely reduce and internally fix all of the nonarticular cortical fragments. Such exact reductions may result in improved stability, but at the cost of biology (eg, devascularization of fragments). This demonstrates poor surgical technique with a high risk of infection and nonunion.

7.5 Soft-tissue repair

Ligament injuries associated with articular fractures are frequent but not always diagnosed. Torn ligaments may impede reduction (eg, deltoid ligament in malleolar fractures) or cause instability (eg, posterolateral corner of the knee). Treatment will depend on the joint involved with primary or secondary repair, or no repair at all. Similarly, the meniscus of a joint may be involved, for example in the knee, where the repair or reattachment of the meniscus is strongly recommended. It will add to the stability of the joint and reduce the risk of posttraumatic arthritis [17].

8 Postoperative treatment

The aim of surgery is to provide stable fixation that allows early postoperative active-assisted exercises under the supervision of a therapist. Isometric muscle exercises are started on the first day following operation.

A removable splint may be used to maintain an optimal position of the joint and limb until muscle control of joint motion is regained. It will help soft-tissue recovery. Although the importance of early motion for cartilage regeneration and ligament healing has been demonstrated, intermittent postoperative immobilization may be needed to ensure healing, especially when the compliance of the patient is doubtful, or when the fixation has not been optimal. Postoperative stiffness then becomes more likely. Limited weight bearing (10–15 kg) is prescribed typically for 6–8 weeks after surgery and can then be increased depending on clinical findings and x-rays.

Regular x-ray surveillance may help to detect a loss of reduction or fixation, will guide rehabilitation and allow timely corrective intervention.

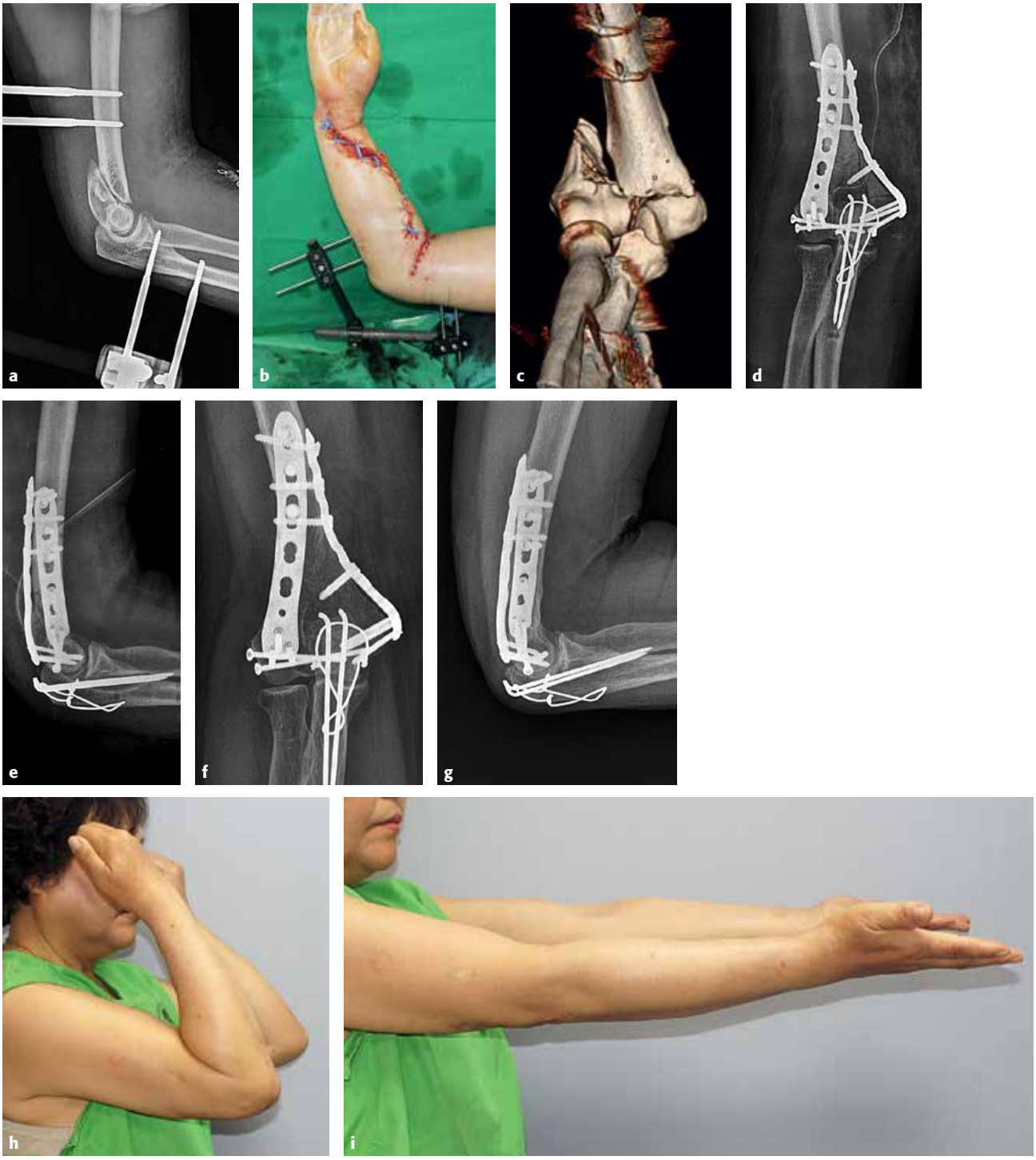

Fig 2.3-7a–i Distal humeral fracture with arterial injury.
a–b Temporary joint-spanning external fixator for damage control was performed after the repair of brachial artery.
c Computed tomographic reconstruction shows the intraarticular fracture.
d–e After the removal of the external fixator at 2 weeks, open reduction and internal fixation was performed. The joint fragments were cleaned, and the articular fracture reduced. Maintaining the reduction, 3.5 mm cortex screws were inserted as lag screws to maintain the reconstruction of the trochlea. The LCP-distal humeral plates 3.5 were used.
f–i At 2 years after operation, the patient had unrestricted elbow flexion with a small extension deficit.

9 Outcome

The main aim of surgical management of articular fractures is to achieve an anatomical reduction, correct axial alignment, and provide stable fixation to allow early active mobilization of the joint. The decision to operate will depend on the condition of the patient and soft tissues. The overall management of an articular fracture requires considerable experience, a well-designed preoperative plan and skillfully executed surgery followed by appropriate postoperative treatment to obtain the best outcome possible. Some joints seem less prone to late arthritis than others possibly based on biomechanics, alignment, or menisci [18]. This review has clarified that reduction of the articular surface is important to prevent late osteoarthritis but the amount of initial step or gap or which exact joints need to be treated is still unclear.

Classic references | Review references

10 References

1. **Charnley J.** *The Closed Treatment of Common Fractures.* Edinburgh: Churchill Livingstone; 1961.
2. **Salter RB, Simmonds DF, Malcolm BW, et al.** The biological effect of continuous passive motion on the healing of full-thickness defects in articular cartilage. An experimental investigation in the rabbit. *J Bone Joint Surg Am.* 1980 Dec;62(8):1232–1251.
3. **Dirschl DR, Marsh JL, Buckwalter JA, et al.** Articular fractures. *J Am Acad Orthop Surg.* 2004 Nov-Dec;12(6):416–423.
4. **Marsh JL, Buckwalter J, Gelberman R, et al.** Articular fractures: does an anatomic reduction really change the result? *J Bone Joint Surg Am.* 2002 Jul;84-A(7):1257–1259.
5. **Giannoudis PV, Tzioupis C, Papathanassopoulos A, et al.** Articular step-off and risk of post-traumatic osteoarthritis. Evidence today. *Injury.* 2010 Oct;41(10):986–995.
6. **Schenker ML, Mauck RL, Ahn J, et al.** Pathogenesis and prevention of posttraumatic osteoarthritis after intra-articular fracture. *J Am Acad Orthop Surg.* 2014 Jan; 22(1):20–28.
7. **Furman BD, Olson SA, Guilak F.** The development of posttraumatic arthritis after articular fracture. *J Orthop Trauma* 2006 Nov-Dec;20(10):719–725.
8. **Schatzker J.** Intrarticular fractures. In: Schatzker J, Tile M, Axelrod T, et al. *The Rationale of Operative Fracture Care.* 3rd ed. Berlin: Springer-Verlag; 2005:33–42.
9. **Mills WJ, Barei DP, McNair P.** The value of the ankle-brachial index for diagnosing arterial injury after knee dislocation: a prospective study. *J Trauma.* 2004 Jun;56(6):1261–1265.
10. **Boraiah S, Ragsdale M, Achor T, et al.** Open reduction internal fixation and primary total hip arthroplasty of selected acetabular fractures. *J Orthop Trauma* 2009 Apr;23(4):243–248.
11. **Popovic D, King GJ.** Fragility fractures of the distal humerus: what is the optimal treatment? *J Bone Joint Surg Br.* 2012 Jan;94(1):16–22.
12. **Haller JM, Holt DC, McFadden ML, et al.** Arthrofibrosis of the knee following a fracture of the tibial plateau. *Bone Joint J.* 2015 Jan;97-B(1):109–114.
13. **White TO, Guy P, Cooke CJ, et al.** The results of early primary open reduction and internal fixation for treatment of OTA 43.C-type tibial pilon fractures: a cohort study. *J Orthop Trauma.* 2010 Dec;24(12):757–763.
14. **Sirkin M, Sanders R, DiPasquale T, et al.** A staged protocol for soft tissue management in the treatment of complex pilon fractures. *J Orthop Trauma.* 1999 Feb;13(2):78–84.
15. **Deo SD, Tavares SP, Pandey RK, et al.** Operative management of acetabular fractures in Oxford. *Injury.* 2001 Sep; 32(7):581–586.
16. **Ahearn N, Oppy A, Halliday R, et al.** The outcome following fixation of bicondylar tibial plateau fractures. *Bone Joint J.* 2014 Jul;96-B (7):956–962.
17. **Weigel DP, Marsh JL.** High-energy fractures of the tibial plateau Knee function after longer follow-up. *J Bone Joint Surg Am.* 2002 Sep;84-A (9):1541–1551.
18. **Peters AC, Lafferty PM, Jacobson AR, et al.** The effect of articular reduction after fractures on posttraumatic degenerative arthritis: a critical analysis review. *JBJS Reviews.* 2013 Dec; 1 (2): e4. http://dx.doi.org/10.2106/JBJS.RVW.M.00041.

11 Acknowledgments

We thank Michael Stover and James Kellam for their contributions to this chapter in the second edition of the *AO Principles of Fracture Management.*

2.4 Preoperative planning

Matthew Porteous

1 Introduction

Planning is the first step in the operative management of any fracture and should not be regarded as an optional extra. This is well understood by many trauma specialists but some wrongly perceive planning as time-consuming and of little benefit. Those who formally plan the management of their fractures can confirm the truth of the maxim that "failing to plan is planning to fail". It is the surgeon's responsibility to ensure that planning is carried out. This chapter discusses the key steps in formulating a successful surgical plan.

2 Why plan?

Planning is an important surgical discipline that encourages the surgeon to focus on the fracture pattern, fixation technique, and surgical approach. The surgeon can mentally rehearse the operation, equipment and instruments can be ordered, operating room personnel (ORP) can be briefed and problems can be anticipated and either avoided or solved by developing an alternative plan to deal with difficulties should they arise during surgery (**Fig 2.4-1**).

Problems that can arise when planning is inadequate include:

- Lack of suitable scrub ORP familiar with equipment to be used
- Inappropriate anesthetic or block given to patient
- Correct operating table in use elsewhere
- Instruments not available (used earlier and not resterilized)
- Implants not available
- Image intensifier booked for another operating room
- Lack of suitable assistant
- Incision in wrong place
- Excessive dissection and soft-tissue stripping to obtain reduction
- Inability to reduce or maintain fracture reduction while the definitive implant applied
- Long wait while unanticipated additional implants or instruments are located
- Position of one screw prevents placement of others from a different direction
- Implant positioned in wrong place
- Unanticipated complications arise
- Surgery takes longer
- Improper wound closure
- Inappropiate postoperative program

Fig 2.4-1 Planning is an important surgical discipline. Failing to plan is planning to fail.

Failure to plan can cause uncertainty about whether a fixation technique is intended to provide absolute or relative stability. This may lead to the failure of the application of the appropriate principles with eventual implant failure and/or fracture nonunion.

3 Assessment

As much information must be obtained about a fracture as is necessary to treat it. Radiology is the mainstay of diagnosis and clear views of the fracture in two planes with correct position showing the joint above and below are mandatory. The use of an image intensifier immediately before surgery, with its inferior image resolution and narrow field of view, is a poor substitute for good quality x-rays. Once the patient is anesthetized, x-rays taken with traction of the limb can be helpful for planning. Good quality x-rays are only useful if they are examined carefully. Fractures tend to follow patterns, which can give a false sense of security. Without a minute inspection of the x-rays, subtle variations that can have significant implications for the operation can easily be missed.

Plain films, even supplemented by oblique views, may be inadequate and when there is uncertainty computed tomography (CT) (supplemented when available by 3-D reconstructions) are required to enable the surgeon to build up the 2-D and 3-D image of the fracture pattern that is required for good planning. This is particularly important in fractures around joints, which generally require accurate anatomical reduction. The 2-D CT is more important than 3-D for evaluating articular fractures as it demonstrates the fracture in the transverse, sagittal, and coronal planes while the 3-D shows only the outer surface and overview of the fracture pattern.

If there is more than one reasonable method for fixing the fracture, all possibilities can be tried out on paper before a decision is made about the method of fixation, the approach, and the equipment required. In some situations the surgeon needs more than one plan; when the first plan is not possible then the second plan is applied. This process allows the surgeon to practice the steps of the operation on paper and rehearse it in their mind. This way mistakes can be left in the wastepaper bin and not in the patient.

With details of the fixation established, the ORP can check the availability of instruments and implants, and other departments, such as radiology, can be notified of the need for their services. During the operation, the ORP and anesthetic teams can follow the steps of surgery from the plan; operations that have been planned tend to have fewer problems and take less time. The type of anesthesia is important in some type of surgery. General anesthesia is required in procedures that need more muscle relaxation such as pelvic and acetabular surgery, while most upper limb operations need only regional or selective nerve block.

Planning allows a detailed analysis of the options and gives a much better evaluation of the risks and benefits of surgery and complications, which can be discussed with the patient to allow informed consent. Inclusion of the preoperative plan and tactics in the medical records clearly reflects the thought and planning put into the operation. It indicates a professional approach and is likely to make any litigation easier to defend.

4 How to plan

For descriptive purposes the planning process is divided into four sequential stages. The first three stages—reconstruction, decision making, and fixation—lead to a detailed drawing and rehearsal of the proposed fixation. The final stage, the surgical tactic, is a sequential list of steps to be taken in the operating room to achieve the planned fixation.

In reality, these stages tend to develop in parallel in the mind of the surgeon. However, the more complex the problem, the more formal the planning process should be.

The steps laid out here form the basis of all surgical planning techniques. Variations and shortcuts are possible and digital radiography is promoting the development of specialized planning software that avoids the need for pens and tracing paper. The principles, however, remain the same.

Material required:

- X-rays of the fracture: It is important to be able to see the joint above and below the fracture. If the fragments appear to be grossly displaced or rotated (which can be a problem in complex elbow fractures), the perspective can be improved by taking traction x-rays once the patient is anesthetized.
- X-ray of the uninjured side: This x-ray is flipped over to produce a mirror image, which is used as the template onto which the fracture is reduced. Both x-rays need to be of the same known magnification.
- Sets of templates of implants: These need to be in a magnification identical to that of the x-rays. Most commercial templates have a magnification of 115%. If necessary, they can be enlarged or reduced on a photocopier.
- Tracing paper.
- Color pens: Making and understanding the drawing is easier if different colors are used for the outline of the bones, fracture lines, and implants, although this is not essential.

4.1 Reconstruction

This involves identifying and reassembling the fracture fragments, much like doing a jigsaw puzzle:

- Step 1—Tracing the intact bone: place a piece of tracing paper over the normal x-ray and trace the outline of the intact bone (this is best done over a light box). If there is significant bone overlap (such as in a lateral view of the forearm), the overlapped bones can be traced separately side by side (**Fig 2.4-2**).
- Step 2—Tracing the fracture: put a separate piece of tracing paper over the fracture x-ray and trace around the fracture fragments. Where fragments overlap they can be drawn separately and slightly apart from each other, as their relative position to each other is not important (**Fig 2.4-3**).
- Step 3—Restoration: place the tracing of the intact bone over the tracing of the fractured bone. By moving the outlines of the intact bone over the fracture pieces it is possible to mark out, on the tracing of the intact bone, where the fracture fragments would fit once the fracture has been fully reduced (**Fig 2.4-4**).

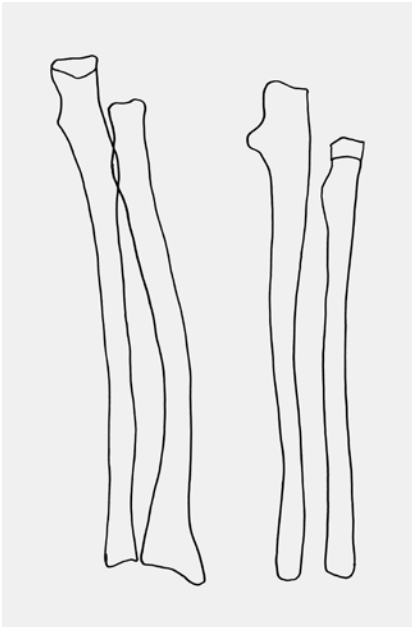

Fig 2.4-2 Tracing of the intact bone. Note that the radius and ulna have been drawn separately on the lateral view.

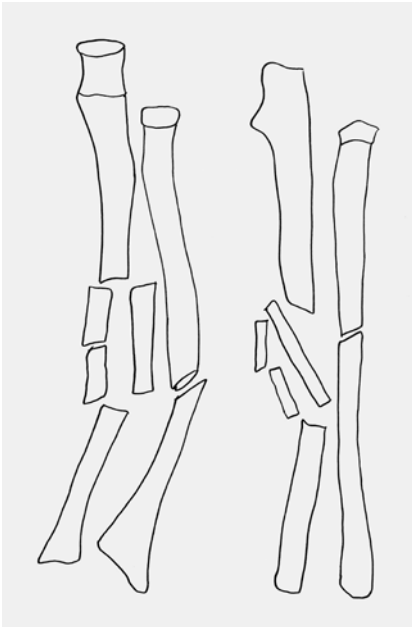

Fig 2.4-3 Tracing of the outline of the fracture fragments. All overlapping fragments have been separated.

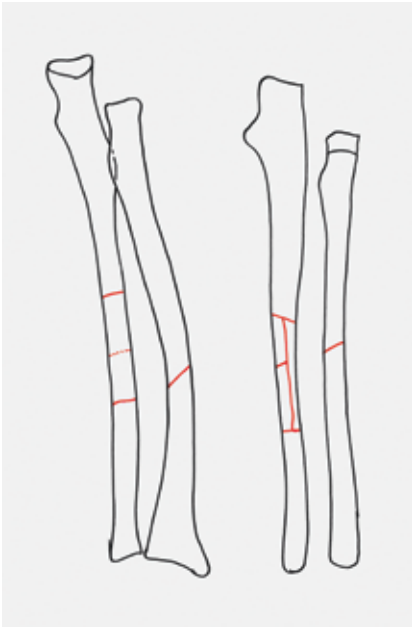

Fig 2.4-4 Restoration: The intact tracing (Fig 2.4-2) is placed over the fracture tracing (Fig 2.4-3) and the fractures drawn onto the intact bone.

The product of the reconstructive phase is a tracing of an intact bone with the reduced fracture fragments marked out on it. In complex fractures it is advisable to copy the reconstruction, as often more than one attempt at fixation planning is required (**Fig/Animation 2.4-5**). In simple fractures it is often possible to reassemble the fragments on tracing paper without requiring a tracing of the intact bone as a guide, like fitting together the bits of a jigsaw without being able to see the original picture before starting.

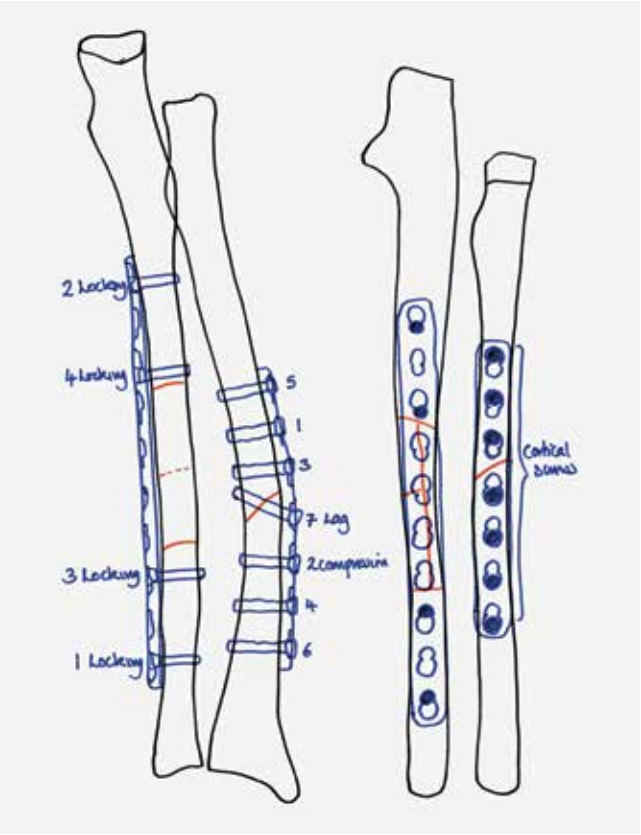

Fig/Animation 2.4-5 Three steps leading to the final preoperative plan: outlines of plates and screws have been drawn onto the reduced fracture using suitable templates. The sequence of screw insertion has been numbered. Further details are developed in the tactic.

4.2 Decision making

Before trying to work out how to fix the reduced fracture, answer the following questions [1]:

- How do I want this fracture to heal (ie, direct or indirect bone healing)?
- Does the fracture need to be held by a method which provides absolute or relative stability?
- What implant provides the desired stability: IM nailing, plate and screw, or external fixator?
- How to position the patient and the C-arm including the type of operating table?
- How is the fracture going to be reduced? Direct or indirect reduction?
- Which surgical approach is required for each technique to reduce the fracture?
- How can I maintain the reduction without obstructing the definitive fixation?
- Which combination of approach and fixation technique will cause least damage to the soft tissues?
- How do I fix the fracture in sequential steps?
- How do I close the wound?
- What is the postoperative program?

Thinking through the operative management of a fracture and how this is to be achieved is by far the most important step of preoperative planning, and must occur before every operation.

The process of writing out a sequence of steps helps clarify the thought process for any surgeon or student.

4.3 Fixation

The appropriate implant template is selected and placed under the tracing of the fracture reconstruction. The best position for the implant is drawn onto the reconstruction, together with any screws (for which there are separate templates). When a plate requires bending, the template and paper are moved in relation to each other to simulate this. Mark on the plan where the bends in the plate will be required, as this will help when contouring the plate during surgery. When there is more than one possible way of achieving fixation, or in complex fractures, several attempts may be required before a satisfactory solution is reached. When screws with different functions are being used (eg, lag screws or locking head screws), the order in which the screws are inserted is vital and the sequence should be clearly numbered on the plan [2]. This also helps in the understanding of the function of each screw (**Fig/Animation 2.4-5**).

4.4 Surgical tactic

Developing a surgical tactic is at least as important as producing the drawings. This lays out the logical sequence of steps needed to achieve fracture reduction, fixation, and rehabilitation of the patient. The tactic can be divided into four sections:

- Equipment required: The instruments and implants required must be discussed with the ORP as far in advance of the surgery as possible [3]. Special implants may require ordering and check that back-up equipment is available in case of predictable intraoperative complications (eg, shoulder hemiarthroplasty when fixing a complex, intraarticular fracture of the proximal humerus). The need for additional equipment, such as an image intensifier or computer guidance, may also require advanced notice (**Fig 2.4-6**). The more detailed the equipment list, the less likely there will be delays during surgery. In complex cases, it is helpful to have a list of equipment that will definitely be required (and prepared at the beginning of the operation for direct use) as well as a list of equipment that should be quickly available but not opened unless requested.
- Preparation: This includes details such as anesthesia, the type of operating table, the need for a tourniquet, the positioning of the patient for surgery, the need for a bone graft donor site, and the surgical approach. The whole layout of the team in the operating room, including the position of the anesthetist, surgeon, and assistant scrub nurse, image intensifier, and the image intensifier screen so that it can be easily seen by the team should be defined and can easily be sketched out to aid in the operating room set-up.
- Reduction and fixation:
  - Reduction method: The surgeon decides whether to use direct or indirect reduction and considers details of the specific technique and instruments.
  - Provisional fixation: This determines how the fracture is to be held without obstructing subsequent definitive fixation with plates or screws (eg, using K-wires or reduction forceps). Particular attention is paid to minimizing soft-tissue damage.
  - Definitive fixation: This is shown on the surgical (fixation) plan, and the exact order of insertion of any screws and plates must be clear. This is particularly important when using combinations of screws with different functions (eg, lag and locking head screws).
- Closure and postoperative regimen: This lays out the method of closure, use of drains and postoperative splints, the rehabilitation regimen, and follow-up details.

Fig 2.4-6 Equipment list for fixation of forearm fracture.

The tactic is written out in a logical sequence from beginning to end to enable the surgical team to follow it easily. However, it is important to recognize that this is not the same order in which the tactic is developed. Planning starts with definitive fixation and works backward through provisional fixation to reduction and surgical approach. It then moves forward through closure and rehabilitation. Only when the method of definitive fixation has been established, can the other details be worked out and an equipment list provided [4] (**Fig 2.4-7**).

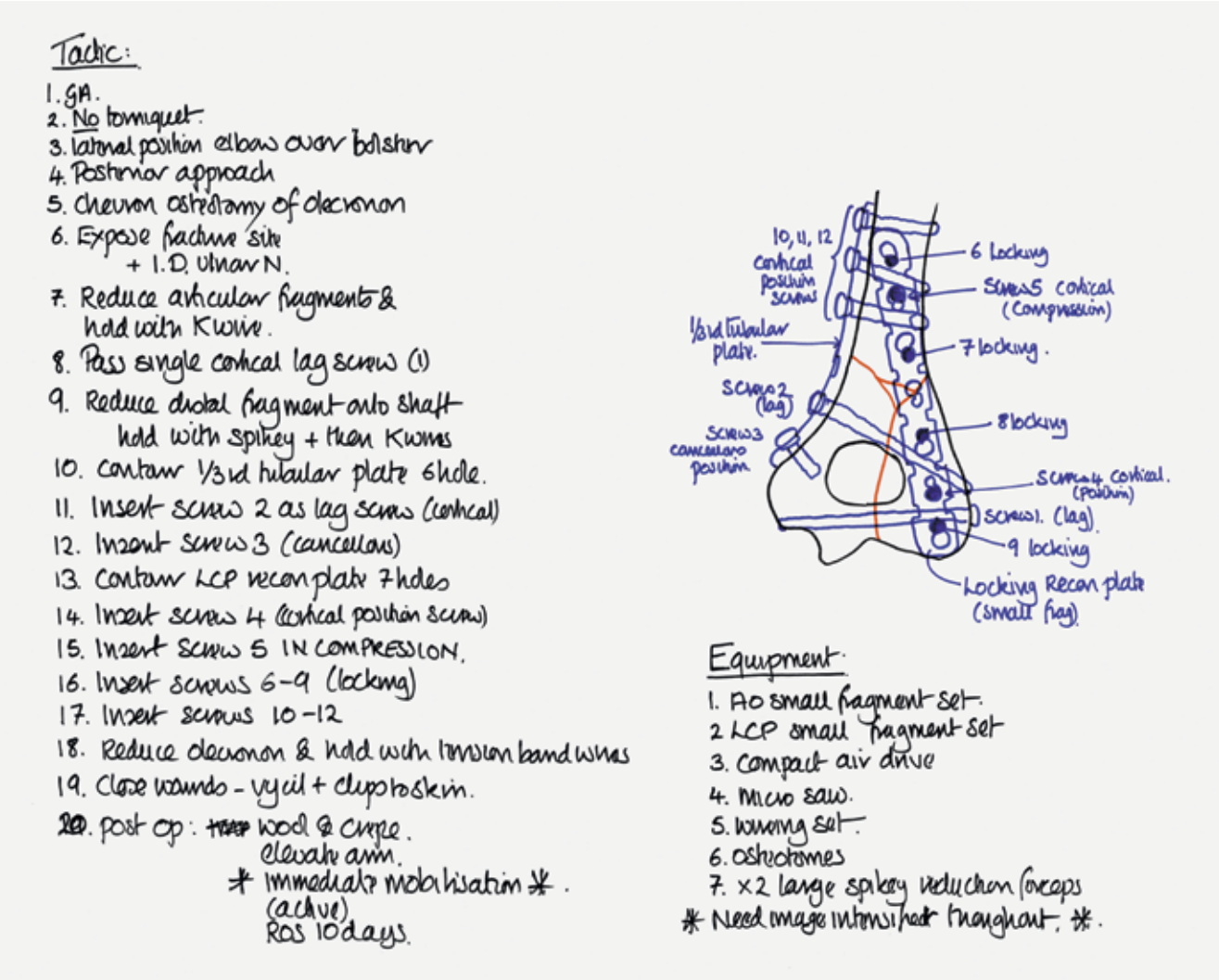

Fig 2.4-7 Completed plan and surgical tactic including equipment list and proposed postoperative treatment.

4.5 Completion of the plan

The final plan consists of three components:

- Surgical tactic
- Annotated drawing
- Equipment list

The application of this plan greatly facilitates surgery and should result in an improved outcome for the patient (**Fig 2.4-8**). The same method can be used for the planning of osteotomies and the treatment of nonunion (**Video 2.4-1**).

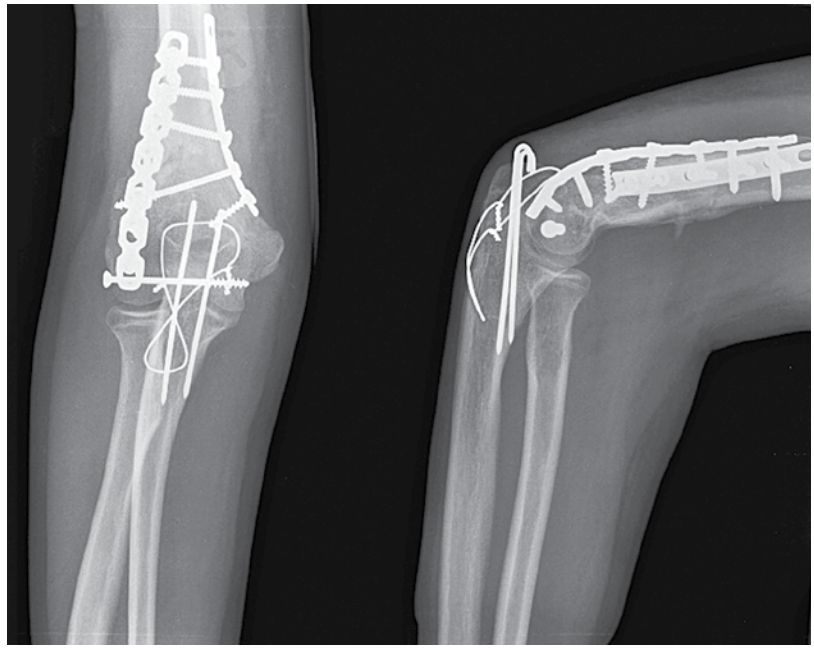

Fig 2.4-8 Postoperative x-ray of fracture fixation planned in Fig 2.4-7. This complex fracture has been perfectly reduced and fixed using a technique of absolute stability. Careful planning has resulted in an excellent fracture fixation, giving the patient the best possible chance of a good outcome.

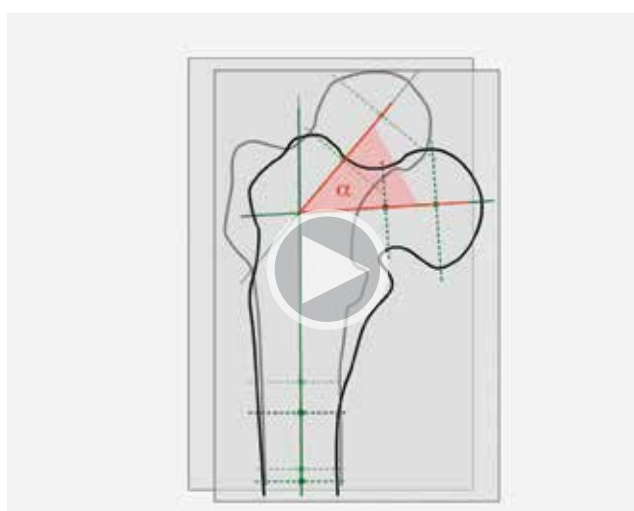

Video 2.4-1 Preoperative planning of valgisation and extension osteotomy of proximal femoral malunion with 120° angled blade plate.

5 Tips and hints

With increasing experience there are shortcuts that can speed up the process without affecting the result. When the use of an intramedullary nail is planned, formal reconstruction may be unnecessary, though nail length and diameter should always be checked. In straightforward fractures with simple patterns, it is often enough to make an adequate plan from the x-ray in one plane only. A quick sketch illustrating the fixation, without the need for formal templates of the implants, may be sufficient (**Fig 2.4-9**). However, a tactic is always required. For more complex fractures, planning in two planes is needed.

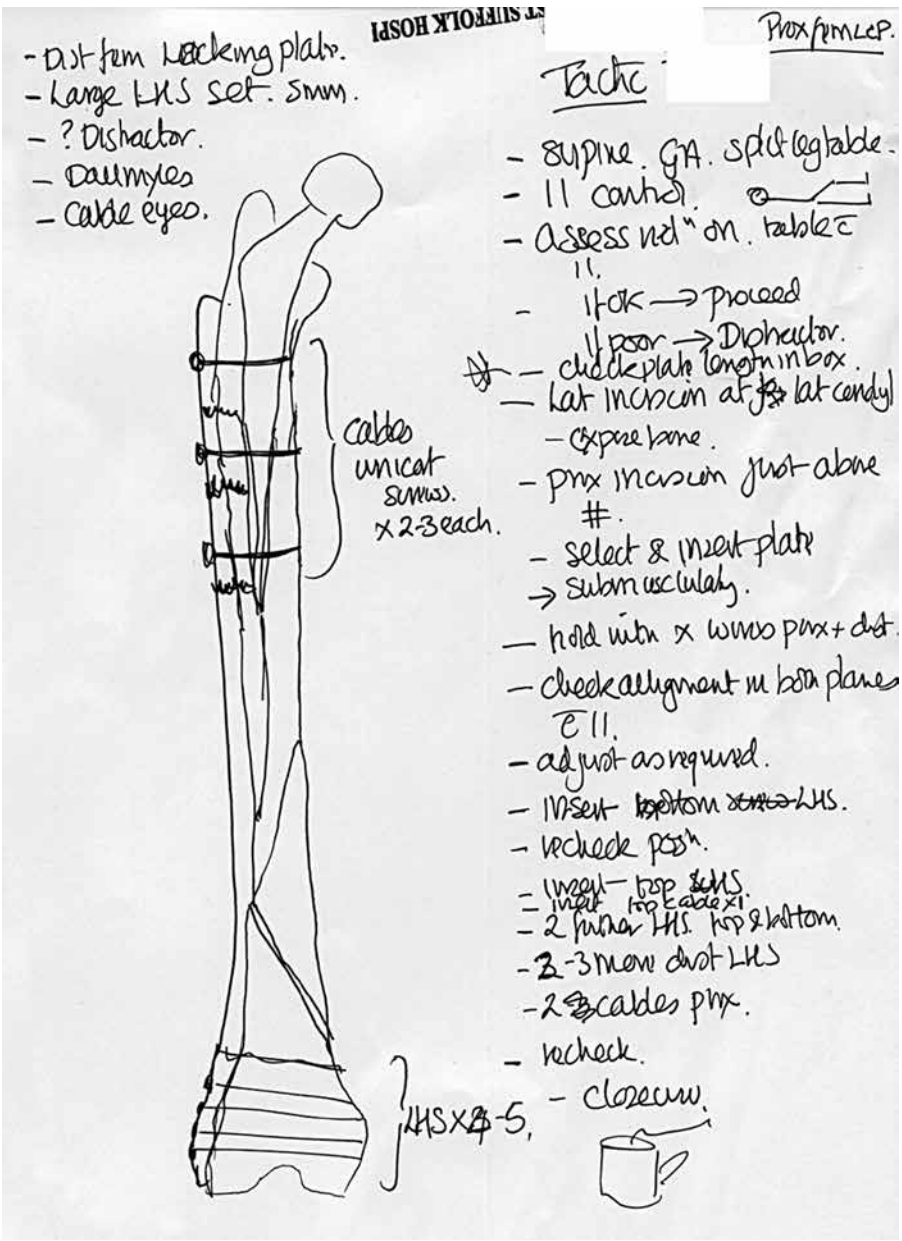

Fig 2.4-9 Surgical tactic for a real case with drawing in a single plane. For simple cases this may be all that is needed but for complex cases, a drawing like Fig 2.4-5 is required.

Articular fractures may require a CT scan to establish the exact position of all fragments, as x-rays alone are often insufficient. These fractures should still be managed using the method of planning outlined above but the main reconstruction may be augmented by tracings of CT sections showing the exact placement of critical screws.

The rapid development of digital radiology has produced some difficulties as films may not be of a uniform scale, which causes problems in providing appropriate templates. The quick way to plan simple fractures is to sketch or even trace them directly off a computer screen directly onto paper and then sketch on the implants (**Fig/Animation 2.4-5**). More complex fractures require the use of a marker of known size placed in the plane of the fractured bone to allow a calculation of the scale. The use of proprietary planning software program will allow the reconstruction of the intact bone and the application of appropriately scaled implants in much the same way as is done using tracing paper above [5]. Software also exists to allow planning in 3-D from CT-generated images and 3-D printers can now be used to produce life-size models. These are particularly helpful in complex osteotomies and can be used to rehearse the operation. The fracture is printed out, and then using the mirror image of the uninjured side as the template, the length and position of the plate, and position of the screws can be determined before surgery.

6 Conclusion

Preoperative planning can seem time-consuming and labor intensive. However, it is an important professional discipline and familiarity with the process makes it quick for simple fractures, though complex fractures take longer. By far the most important step of planning is that of thinking through the surgical management in detail after careful examination of the images. This should be converted into a formal, written tactic and, as the fixation becomes more complex, supplemented by a sketch or a formal scaled plan. The whole process makes it far less likely that x-rays will be misinterpreted, surgical pitfalls overlooked, and the correct size implant found to be unavailable after the operation has started. The benefits to the surgeon and ORP of a planned approach far outweigh the time necessary for the planning itself. A good plan almost always results in a shorter operating time and a better patient outcome.

7 References

1. **Holdsworth BJ.** Planning in fracture surgery. In: Bunker TD, ed. *Frontiers in Fracture Surgery.* London: Martin Dunitz; 1989.
2. **Mast J, Jakob R, Ganz R.** *Planning and Reduction Technique in Fracture Surgery.* Berlin Heidelberg: Springer-Verlag; 1989.
3. **Porteous M, Bauerle S, eds.** *Techniques and Principles for the Operating Room.* Stuttgart: Thieme; 2010.
4. **Hak DJ, Rose J, Stahel PE.** Preoperative planning in orthopedic trauma: benefits and contemporary uses. *Orthopedics.* 2010 Aug;33(8):581–584.
5. **Suero EM, Hüfner T, Stübig T, et al.** Use of a virtual 3-D software for planning tibial plateau fracture reconstruction. *Injury.* 2010 Jun;41(6):589–591.

8 Acknowledgments

We thank Norbert Sudkamp and Joseph Schatzker for their contributions to this chapter in the second edition of the *AO Principles of Fracture Management.*

Section

3

Reduction, approaches, and fixation techniques

Section 3
Reduction, approaches, and fixation techniques

Reduction and approaches

3.1.1 Surgical reduction 117
Rodrigo Pesantez

3.1.2 Approaches and intraoperative handling of soft tissues 137
Ching-Hou Ma

3.1.3 Minimally invasive osteosynthesis 149
Reto Babst

Techniques of absolute stability

3.2.1 Screws 173
Wa'el Taha

3.2.2 Plates 185
Mark A Lee

3.2.3 Tension band principle 209
Markku Nousiainen

Techniques of relative stability

3.3.1 Intramedullary nailing 217
Martin H Hessmann

3.3.2 Bridge plating 241
Friedrich Baumgaertel

3.3.3 External fixator 253
Dankward Höntzsch

3.3.4 Locking plates 269
Christoph Sommer

3.1.1 Surgical reduction

Rodrigo Pesantez

1 Displacement of fragments, deformation, and impaction of bone

A diaphyseal fracture usually separates the bone into two main fragments—proximal and distal—with their adjacent joints. There are six basic ways in which these main fragments can displace in relation to each other: three pairs of translational displacements, and three rotations along and around the x-, y-, and z-axes. Most fractures displace in a combination of ways. The degree and direction of displacement of the fracture fragments reflect the vectors of external forces and the pull of the muscles that remained attached (**Fig 3.1.1-1**). In children, plastic deformation can occur in diaphyseal bone without complete discontinuity of the bone cortex.

Displacement in diaphyseal and metaphyseal bone can readily be detected with conventional x-rays taken in two planes perpendicular to each other. In the metaphysis and epiphysis, 45° oblique views may be helpful but computed tomography with multiplanar reconstruction is often needed to fully assess fragmentation, displacement, deformation, and impaction. Careful analysis of the site and extent of bone deformation as well as the direction and degree of displacement is important to identify the best reduction technique which in turn will help select the most appropriate surgical approach, fixation technique, and choice of implant.

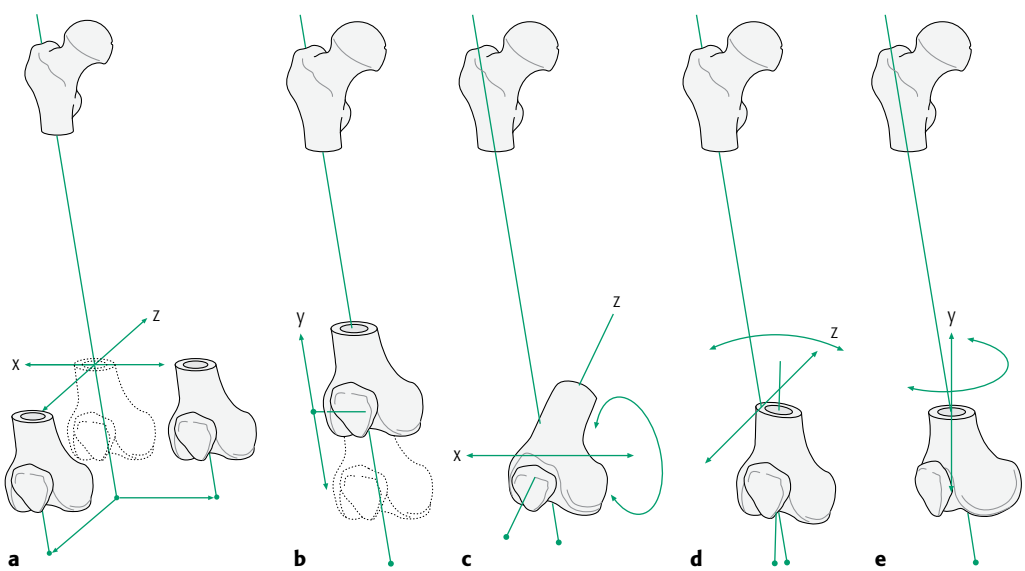

Fig 3.1.1-1a–e Translational and rotational displacement.
a–b Translational or linear displacement can occur along all the three axes in space; the x-, y-, and z-axis. Displacements along the x-axis are medial or lateral and those along the z-axis are anterior or posterior (**a**). Those along the y-axis are shortening or lengthening (**b**).
c–e Rotational displacement is also possible around the three axes in space. Angular displacement in the sagittal plane (around the x-axis) is an axial malalignment in flexion or extension (**c**), in the coronal plane (around the z-axis) an axial malalignment in abduction or adduction (**d**), and in the transverse plane (around the y-axis) a rotational malalignment (**e**).

2 Fracture reduction

Reduction is the act of restoring the correct relation and position of fracture fragments. This includes the process of reconstruction of impacted cancellous bone and articular fragments. In other words, reduction is the recreation of the spacial relationship of one fragment to another (**Video 3.1.1-1**).

Reduction reverses the process which created fracture displacement during the injury and calls for forces in opposite directions to those which produced the fracture (**Fig 3.1.1-2**). Analysis of the displacement and deformation, together with knowledge of the site of muscle insertion and muscle pull, helps to plan the tactical steps needed to achieve reduction, independent of the treatment method (ie, operative or non-operative) [1–3].

Video 3.1.1-1 Direct and indirect reduction.

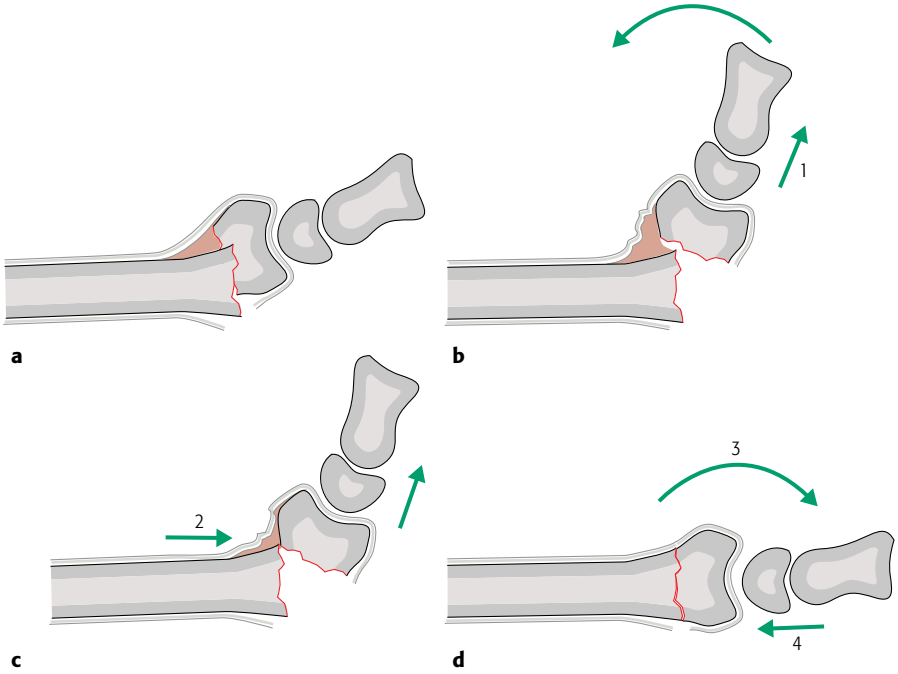

Fig 3.1.1-2a–d Closed reduction with reversing of the forces that have created the fracture displacement.

a Distal radial fracture with shortening, posterior displacement, and dorsal angulation. The intact periosteum on the dorsal side may act as an obstruction to reduction by traction because the fragments are interlocked.

b The first step to reduce this fracture consists in disengaging the bone ends by extension of the wrist and dorsally angulated traction to relax the soft-tissue hinge (arrow 1).

c Under dorsal traction the distal fragment is pushed (arrow 2) into its correct position, with the dorsal fragment ends reduced into contact.

d Adding a flexion force and continuing the push (arrow 3), the distal fragment will realign and the fragments are interlocked (arrow 4).

2.1 Aim of reduction

In the diaphysis and metaphysis, the aim of fracture reduction is to restore length, alignment, and rotation so that the joints above and below the fracture are in the correct position.

This is regardless of whether the fracture is simple or multifragmentary, segmental, or has bone loss. Every fragment does not have to be perfectly reduced but the bone must be restored to its original length, alignment, and rotation (**Fig 3.1.1-3**).

In articular fractures, the aim of reduction is perfect restoration of the joint surface to provide a congruent and stable joint with normal movement. In some cases there may be irreparable damage to the cartilage due to impaction at the time of injury. Anatomical reduction of the joint surface, as well as restoring axial alignment, especially in the lower extremity are factors that the surgeon controls to reduce the risk of posttraumatic osteoarthritis [4]. Ideally, no residual displacement should be accepted. However, different joints with different loading conditions seem to have different tolerance [4]. A concentric joint, such as the hip or ankle, depends much more on perfect articular congruity [5, 6] than a nonconcentric joint, such as the knee joint. In the knee, the restoration of the axial alignment of the whole limb and the restoration of ligament and meniscal stability may be as important as anatomical reconstruction of the articular surface.

To achieve a perfect reduction the surgeon must understand the displacement of the fracture fragments and plan reduction maneuvers in advance. Reduction and maintenance of reduction is often the most difficult part of surgery and master surgeons plan their reductions and anticipate problems.

2.2 Reduction techniques

Reduction techniques must be gentle and create as little additional damage as possible.

Reduction techniques must preserve the vascularity of the soft-tissue envelope and any remaining tissue attachments to bone fragments. Bone healing will be delayed or come to a stop if the biological environment is critically disturbed. The risk of infection is also increased [7–9].

The degree of stability achieved by fixation (absolute or relative stability) is the mechanical input for the biological response and determines the healing pattern (primary bone healing or callus formation).

The healing process is modulated by any additional damage to the bone and the surrounding soft-tissue envelope caused by the surgical exposure, reduction maneuvers, and the application of fixation devices.

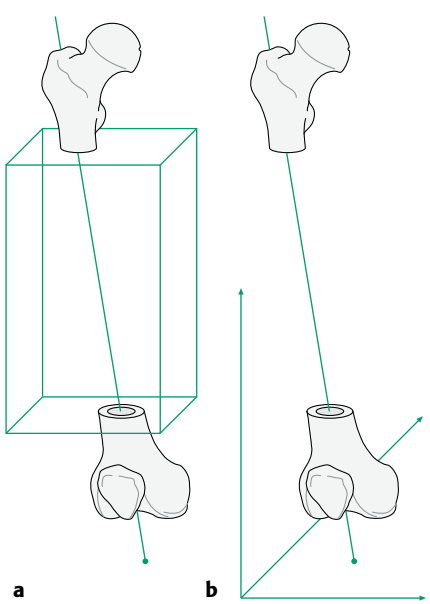

Fig 3.1.1-3a–b Fracture reduction in the diaphysis.
The fracture zone is like a black box, whose content is of no or only minor importance with regard to the primary aim of reduction. After reduction, the proximal and the distal main fragments should be relocated into their correct positions in space.

There are two fundamental techniques for fracture reduction: direct and indirect reduction (**Table 3.1.1-1**).

Direct reduction means that hands or instruments are in contact with fracture fragments for manipulation under vision.

In simple diaphyseal fractures (eg, simple forearm shaft fractures), direct reduction is technically straightforward and the results are reproducible. Exact coaptation of the two main fragments restores anatomical length, alignment, and rotation. A careful surgical exposure should not add vascular damage to the bone or soft tissues and should maintain biology. However, this is only true if surgery is done gently, with meticulous soft-tissue handling, and limited periosteal exposure of the bone [10].

In more complex diaphyseal fractures, direct reduction techniques may result in attempts to expose, reduce, and stabilize every single fragment. In doing so, the surgeon may devascularize these fragments by stripping the periosteum and soft tissues.

The repeated use of bone forceps and other reduction tools may completely devitalize the fragments. X-rays do not show how much manipulation occurs during surgery. This can have disastrous consequences for the healing process, including delayed union, nonunion, infection, and implant failure. Only by understanding and respecting the biology of bone, periosteum, and soft tissues can the surgeon avoid failure after open reduction and internal fixation [1, 9].

	Direct reduction	Indirect reduction
Main field of application	Articular fractures and simple diaphyseal fractures	Specific articular fractures (ligamentotaxis), multifragmentary diaphyseal fractures (soft-tissue taxis)
Difficulty to achieve reduction	Relatively easy	Demanding
Control of reduction	Direct exposure, x-rays, image intensifier	Technical: clinical, radiological, or image intensification, arthroscopy, computer assisted
Soft-tissue dissection	Relatively extensive	Limited
Bone devascularization	Relatively extensive	Minimal
Usually employed fixation principle	Absolute stability	Relative stability

Table 3.1.1-1 Comparison of two reduction methods: direct and indirect.

Indirect reduction means that fragments are not exposed and are manipulated by applying corrective force at a distance from the fracture. Radiological imaging is required to ensure appropriate positioning of the fracture.

Correct reduction by indirect techniques may be difficult to achieve. It requires understanding of the fracture pattern, anatomy (muscle pull), and meticulous preoperative planning. The actual process of reduction is often more demanding and necessitates the use of an image intensifier. In biological terms, indirect reduction techniques offer significant advantages. If correctly applied, they add minimal surgical damage to tissues. All reduction tools are applied away from the fracture focus so that any local damage from the instruments themselves will not affect fracture healing.

Most instruments and implants available today can be used as tools for either direct or indirect reduction. The success in preserving the biology of the tissues is not dependent on any specific instrument or implant but rather on the skill of the surgeon. It cannot be emphasized enough how important planning is to this process:

Converting an intended indirect reduction to an unplanned open, direct reduction may result in significant soft-tissue damage. This may not be visible on x-rays or recorded in the operation record but puts the patient at additional risk of serious complications.

2.2.1 Traction or distraction

The most important mechanism to reduce a fracture is traction. This is normally applied in the long axis of the limb.

In comminuted articular fractures, traction across a joint may reduce fragments by ligamentotaxis. Traction may be applied manually, by means of a fracture table, or by applying a distractor (**Video 3.1.1-2**). The fracture table requires that traction is applied across at least one joint. The disadvantage is that the limb cannot be moved by the surgeon and the surgical approach or limb alignment may be compromised. The distractor, applied directly to the main fragments, permits maneuvering of the limb during surgery. However, its application is demanding and requires tension; angular or rotational corrections are difficult and the construction may be cumbersome. There is also an inherent

tendency for curved bones to straighten during distraction and so the eccentric force produced by the unilateral distractor may produce additional deformity (**Fig 3.1.1-4**).

The distractor can also be applied across joints to aid with the reduction of articular injuries through ligamentotaxis. This also helps direct visualization of the joint surface by distracting the joint (**Fig 3.1.1-5**).

The external fixator can be used for indirect reduction but gentle lengthening is more difficult than with the distractor. By applying traction across a joint, ligaments, and soft tissues around the fracture area can help to achieve reduction, either by ligamentotaxis or soft-tissue reduction. The main fields of application are comminuted metaphyseal/articular segments when the soft-tissue condition or fracture fragmentation does not permit open reduction and stabilization techniques [10].

The use of traction and distraction to reduce fractures is also used in pelvic and acetabular surgery with specially designed frames and percutaneous clamps.

2.2.2 Instruments for reduction

Various reduction forceps are shown in **Table 3.1.1-2**.

Video 3.1.1-2 The large distractor can be used for indirect reduction of a femoral fracture.

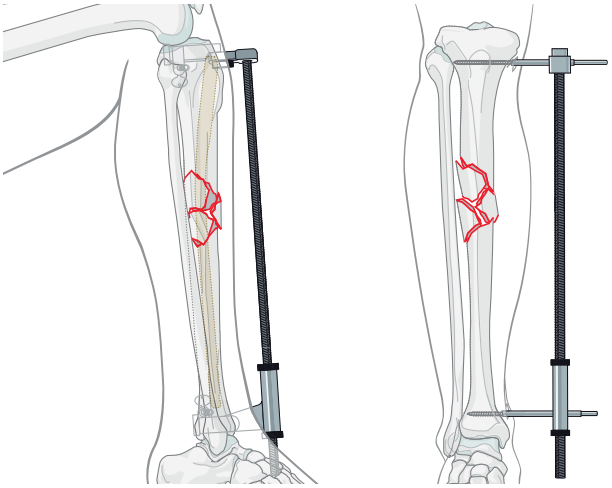

Fig 3.1.1-4 Unilateral distractor used for indirect reduction of multifragmentary tibial shaft fractures. Note the posterior position of the Schanz pins to allow introduction of an intramedullary nail.

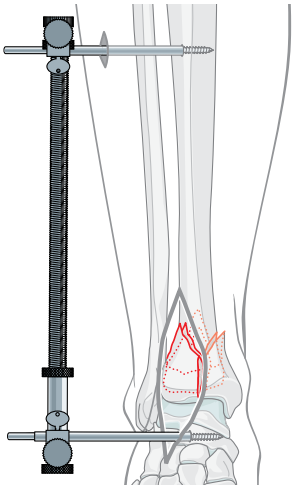

Fig 3.1.1-5 Distractor applied across the ankle joint to allow treatment of a pilon fracture. The distractor provides indirect reduction or alignment and rotation plus access to the joint to allow direct reduction of articular fragments.

Instrument	Image of instrument	Description	Application technique
Reduction forceps with points (Weber forceps)	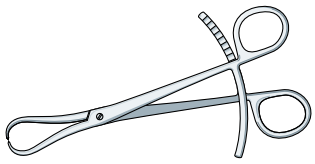	This instrument has points on each prong so they can hold into the bone and help to manipulate and reduce fragments. Very helpful in most type A and some type B1 and B2 fractures.	Put each tine of the forceps on the bone (directly or through a small drill hole) and manipulate the fracture fragments until reduction is achieved (**Videos 3.1.1-3–4**).
Reduction forceps, toothed	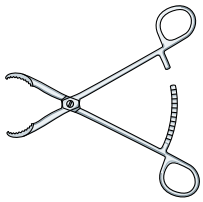	This instrument is similar to the pointed reduction clamps but its tine ends are more aggressive on the bone, it can help in plate application (holding plate) on small bones (forearm and fibula).	Apply one tine end to the bone and the other tine to the plate so it can hold the plate while fixing it with screws (**Fig 3.1.1-8**). It can also be used to manipulate bone fragments in simple fracture patterns using the one or two forceps technique.
Bone holding forceps, self-centering (Verbrugge forceps)	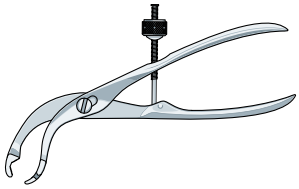	One end is similar to a Hohmann retractor and the other one is designed to hold the plate to the bone. It goes around the bone and is less soft-tissue friendly.	The Hohmann retractor end goes round the bone and the plate holding end will hold and center the plate to the bone (**Fig 3.1.1-9**). It can also provide compression if used in the pull technique (**Fig 3.1.1-8b**).
Bone spreader	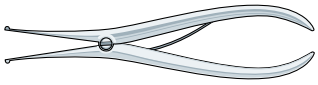	It helps to achieve distraction of fragments and gain length using the push-pull technique.	Its ends are supported by an independent screw in the bone and the plate end on the other side to achieve distraction (**Fig 3.1.1-8a**, **Video 3.1.1-12**).

Table 3.1.1-2 Design and function of reduction forceps.

Instrument	Image of instrument	Description	Application technique
Collinear reduction forceps	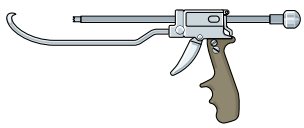	It is designed to provide linear force and reduce/compress fracture fragments or to hold the plate to the bone. It has different arms that can be attached to it according to the desired fusion and bone size.	It can be applied percutaneously to compress (distal femoral fractures, syndesmosis) or open reduction (posterior column acetabular fractures through anterior approach). It also helps to hold plate position in MIPO techniques.
Pelvic reduction forceps with ball points (Queen tong)	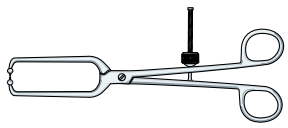	This forceps is similar to a Weber forceps but it is bigger and provides higher force. The balls prevent overpenetration of the cortex.	In articular injuries, distal femur and proximal tibia it can help to reduce simple fracture patterns and compress them through the stab incisions (**Fig 3.1.1-11**).
Angled pelvic reduction forceps (Matta forceps)	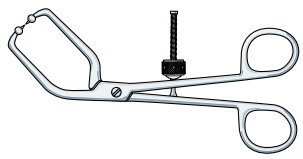	The angulation of this forceps allows them to reach difficult areas in pelvic and acetabular surgery.	It can help to compress and reduce transverse fracture patterns in acetabular fracture surgery through the posterior approach (sliding it through the greater sciatic notch).
Pelvic reduction forceps (Farabeuf forceps)		This forceps has two arms with ends designed to grasp screw heads (3.5 and 4.5 mm).	Once independent screws are attached to each fracture end the forceps can grasp each screw head and manipulate the fragments in different planes (**Video 3.1.1-6**). It can also be used to grasp anterior column fracture fragments in the anterior approach.
Pelvic reduction forceps (Jungbluth forceps)	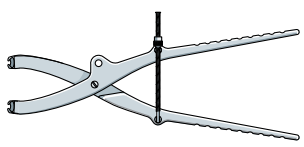	This forceps has two arms with ends designed to be fixed to bone through screws (3.5 and 4.5 mm).	Each arm of the forceps is fixed to the bone with a screw and then each arm is attached to the other to provide manipulation of fracture in different planes (**Fig 3.1.1-13**, **Video 3.1.1-6**).

Table 3.1.1-2 (**cont**) Design and function of reduction forceps.
Abbreviation: MIPO, minimally invasive plate osteosynthesis.

Reduction forceps with points (Weber forceps)

The pointed reduction forceps is the primary choice of reduction tool because it is gentle to the periosteal sleeve and can be used for direct and indirect reduction.

The two-forceps technique consists of seizing each of the two main fragments of a transverse fracture with a reduction forceps (**Video 3.1.1-3**). Reduction can be achieved by manual traction, and in a transverse fracture intrinsic stability then allows removal of the forceps without loss of reduction (**Fig 3.1.1-6**).

For an oblique fracture plane that needs some lengthening, the pointed reduction forceps engages on the main fragments on each side of the fracture with a slight tilt of the forceps (one-forceps technique). By combining compression with a rotational movement of the forceps, correction of length can be obtained (**Video 3.1.1-4**). To keep the fragments reduced, the first forceps often has to be replaced by a second one perpendicular to the fracture plane (**Fig 3.1.1-7**).



Video 3.1.1-3 The two-forceps technique of fracture reduction.

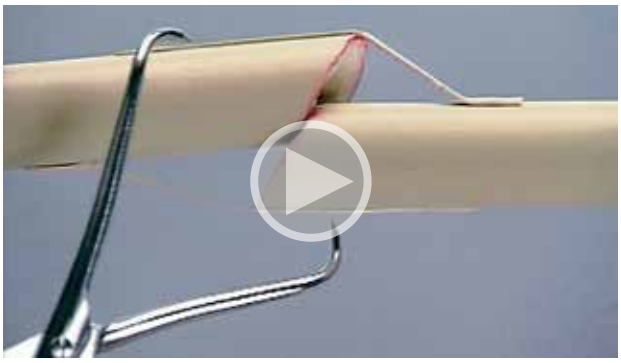

Video 3.1.1-4 The single-forceps technique for reduction of oblique fractures.

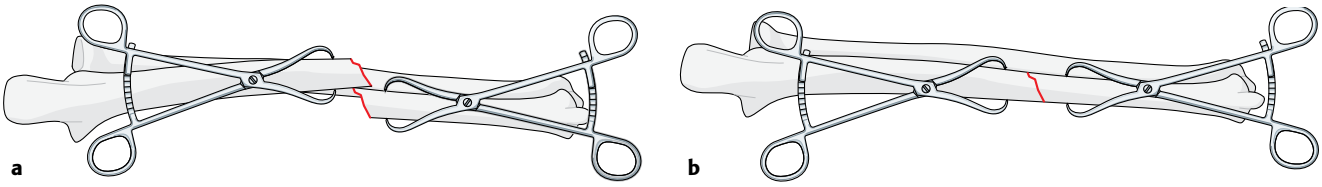

Fig 3.1.1-6a–b Direct manual reduction using two pointed reduction forceps.
a Each main fragment is held with a pointed reduction forceps.
b Lengthening is achieved by manual traction while correct rotation and axial alignment can be controlled with the forceps.

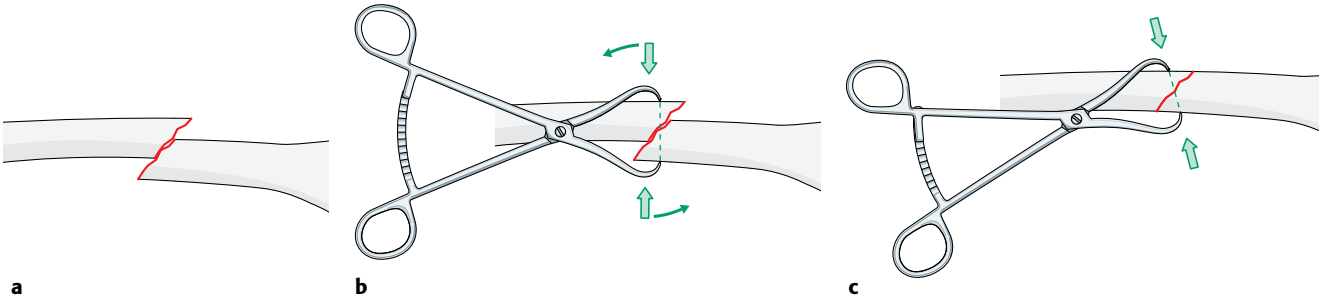

Fig 3.1.1-7a–c Direct reduction of an oblique diaphyseal fracture.
a Both fragments are held with the slightly tilted, pointed reduction forceps.
b By gently rotating and compressing the forceps the bone is lengthened and the fracture reduced.
c To secure reduction, a second forceps perpendicular to the fracture plane is applied.

Reduction forceps, toothed

This reduction forceps is a typical instrument used for direct fracture reduction.

Due to its dimension and the design of the jaws, the toothed reduction forceps has a tendency to slip on the bone surface, further damaging the periosteal envelope.

It is used to adjust and fine-tune fracture reduction and plate position.

Bone spreader

This device can be used for distraction if placed between two fragments or between the end of a plate and an independent screw 1 cm from the plate end (push technique) (**Fig 3.1.1-8a**).

Bone holding forceps, self-centering (Verbrugge forceps)

The main function of this forceps is to hold a plate to diaphyseal bone. Due to its design, it produces considerable circumferential exposure of the bone because its pointed end has to reach completely around the bone (**Fig 3.1.1-9**). A second function of this forceps is compression: the pointed end of the forceps may be hooked into an end hole of the plate while the broad end reaches around an independent screw head to pull the plate, thereby compressing the fragments (pull technique) (**Fig 3.1.1-8b**).

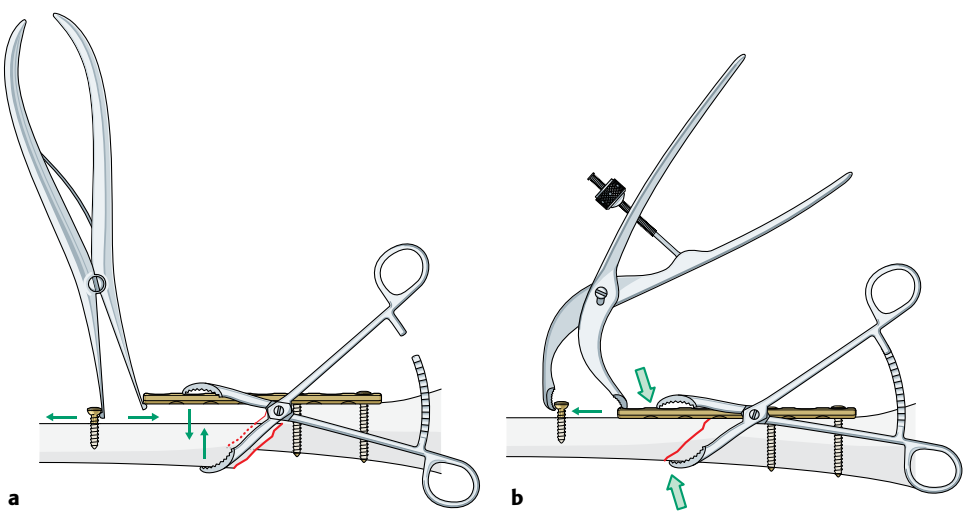

Fig 3.1.1-8a–b Push-pull technique.
a The bone spreader, placed between the end of a plate and an independent screw, can be used to distract or push apart the fracture for reduction.
b Using the same independent screw, interfragmentary compression can then be obtained by pulling the plate end toward the screw with a small Verbrugge forceps.

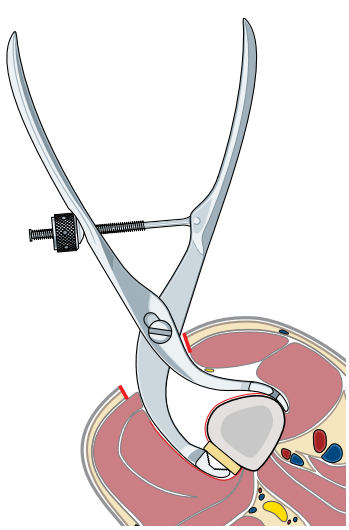

Fig 3.1.1-9 Verbrugge forceps are self-centering bone forceps that may be used to hold a plate. It should be used outside the fracture zone to minimize damage to the blood supply.

Colinear reduction forceps

This forceps has a sliding mechanism that allows linear movement. The hook is designed to pass around the bone without stripping of soft tissues (**Fig 3.1.1-10**) [11].

Pelvic reduction forceps with ballpoints ("King tong clamp", "Queen tong clamp")

These reduction forceps are mainly used for reduction of pelvic, acetabular, and tibial plateau fractures. To avoid deep penetration of the points into bone, a mobile washer can be fixed to the ballpoints. The king tong forceps can also be used for indirect reduction of other articular fractures, such as the tibial plateau. One or both points of this forceps can be inserted percutaneously through stab incisions (**Fig 3.1.1-11**), while the wide arms of the forceps avoid crushing of soft tissues as the forceps are closed.

Angled pelvic reduction forceps (Matta forceps)

These reduction forceps are also used for pelvic and acetabular fractures. The angulation allows access to anatomical areas that are difficult to reach (eg, through the sciatic notch). The ballpoints and mountable washers reduce point forces on weak bone.

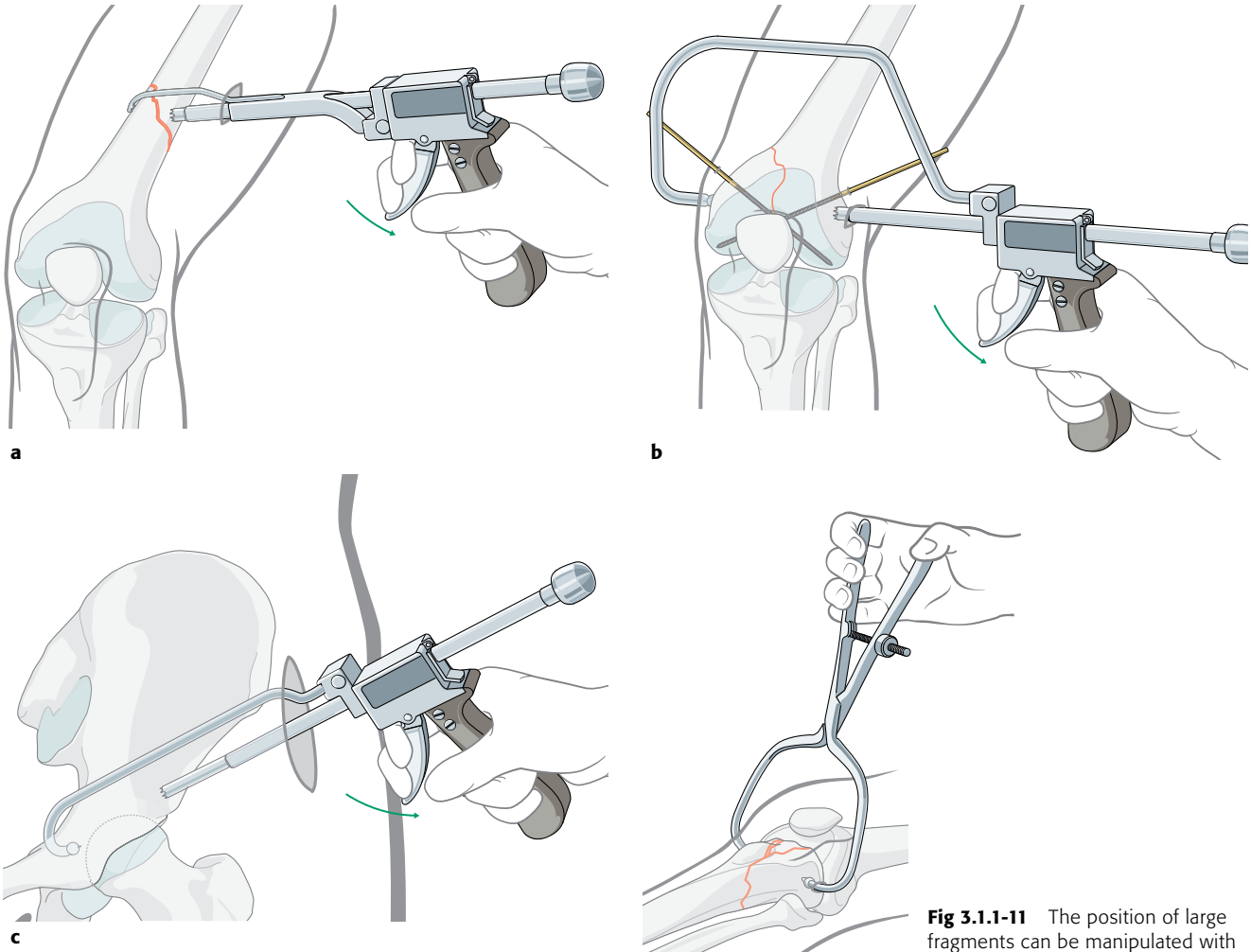

Fig 3.1.1-10 Colinear reduction forceps.
a Reduction of the femoral shaft using the Hohmann-style arm.
b Reduction of the femoral condyle using the periarticular arm.
c Reduction of the pelvis using the pelvic extension arm.

Fig 3.1.1-11 The position of large fragments can be manipulated with a large ballpoint reduction forceps (King tong) grasping the medial and lateral fragments through small stab incision.

Pelvic reduction forceps (Farabeuf forceps)

The Farabeuf forceps is designed to grasp screw heads inserted on either side of a fracture line (3.5 or 4.5 mm screws) (**Fig 3.1.1-12**). Manipulation of the forceps allows compression and also permits limited manipulations in two different planes (**Video 3.1.1-5**). However, distraction of the fracture gap is not possible.

Pelvic reduction forceps (Jungbluth forceps)

The Jungbluth forceps is fixed on both fragments with a 3.5 or 4.5 mm cortex screw. This allows the fragments to be moved and reduced in three planes (distraction and compression, as well as lateral displacement in two planes) (**Fig 3.1.1-13**, **Video 3.1.1-6**).

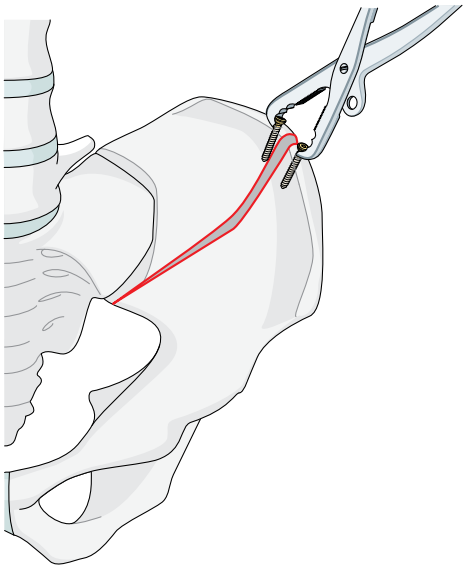

Fig 3.1.1-12 The Farabeuf forceps is mainly used for fracture reduction of the pelvic ring/iliac crest. It is anchored on both sides of the fracture with either 3.5 or 4.5 mm cortex screws. The forceps is helpful only to reduce a side-to-side displacement or to close a fracture gap. Distraction is not possible.

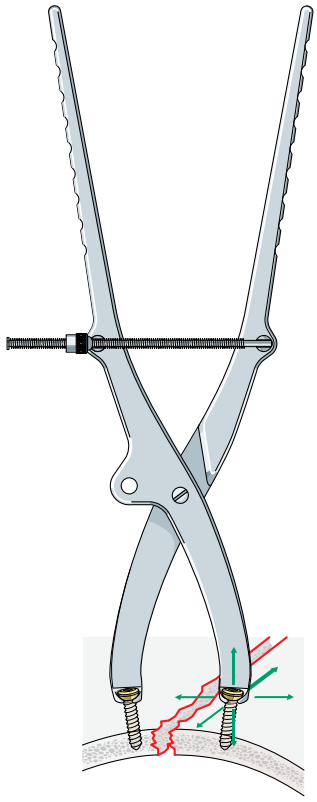

Fig 3.1.1-13 The Jungbluth forceps is fixed to fragments with 4.5 mm cortex screws. This firm connection allows translational reduction maneuvers in all three planes.

Video 3.1.1-5 Application of Farabeuf forceps using screw heads.

Video 3.1.1-6 Jungbluth forceps allow reduction in three planes.

Hohmann retractor

In cortical bone, the small tip of the Hohmann retractor can be used as a lever or pusher to achieve reduction. The tip of the Hohmann retractor is inserted between the cortices of two diaphyseal fragments. It is then turned around 180° to engage the cortex of the opposite fragment. With a bending force applied to the Hohmann retractor, the two cortices can be realigned, allowing gentle reduction of the fracture. Another turn of the retractor is usually needed to remove it (**Fig 3.1.1-14**) [1]. Because the tip of the retractor is entirely within the fracture, no additional soft-tissue stripping is created during this maneuver (**Video 3.1.1-7**). However, it may displace the fracture if there is an unrecognized crack or if the bone is osteoporotic.

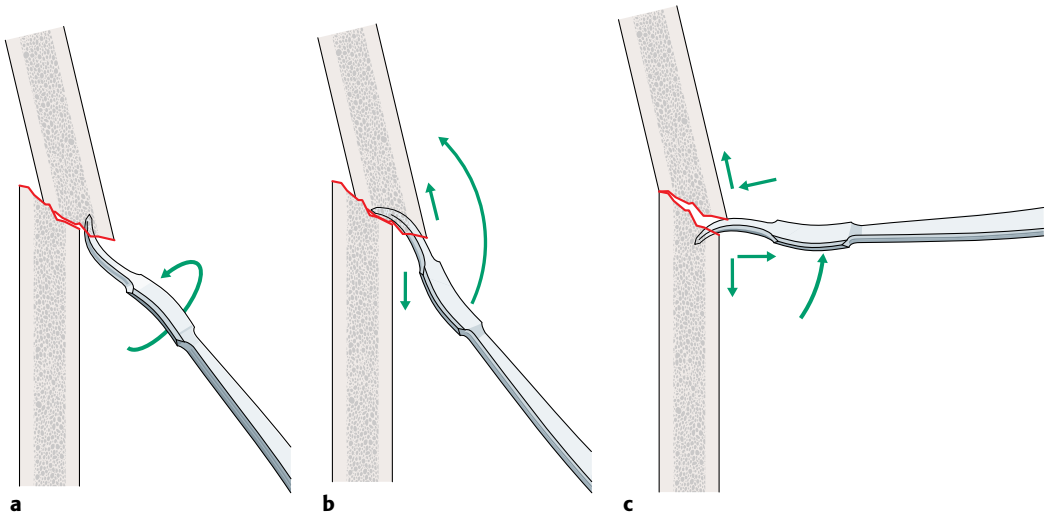

Fig 3.1.1-14a–c Diaphyseal reduction with the small Hohmann retractor.
In cortical bone, the tip of the Hohmann retractor is placed between the two fragments. By turning and bending the retractor handle the fragments can be disengaged and reduced. Another turn is usually required to remove the Hohmann retractor.



Video 3.1.1-7 Fracture reduction with a small Hohmann retractor.

A further application of the Hohmann retractor is to reduce a translational displacement in the cancellous bone of an iliac wing fracture. First the tip of the Hohmann retractor is lightly hammered into the bone. Then it is turned and reduction can be achieved with a bending force (**Fig 3.1.1-15**, **Video 3.1.1-8**). This maneuver usually produces a small zone of impaction on the thin cortex of the fragment pushed down.

Ball spike, bone impactor, bone hook

Fracture reduction in one direction can be carried out by instruments designed to push or pull. Using the ball spike, fragments can be pushed firmly into the right position. The bone impactor, used from within, serves to disengage (elevate) impacted fragments from an articular surface. The hook (dental pick) or the regular bone hook can be most useful for fine tuning the reduction of a fragment.

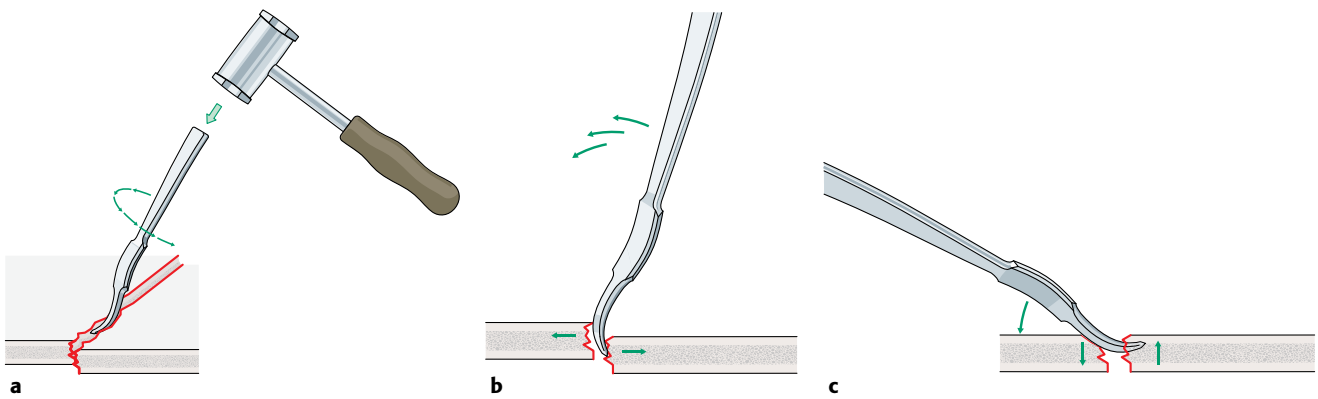

Fig 3.1.1-15a–c Hohmann retractor for reduction in cancellous bone. By placing the slightly curved tip of a Hohmann retractor between two overlapping fragments and then turning and tilting the retractor the fracture may be reduced and brought to interdigitate. A precondition is a solid layer of bone.

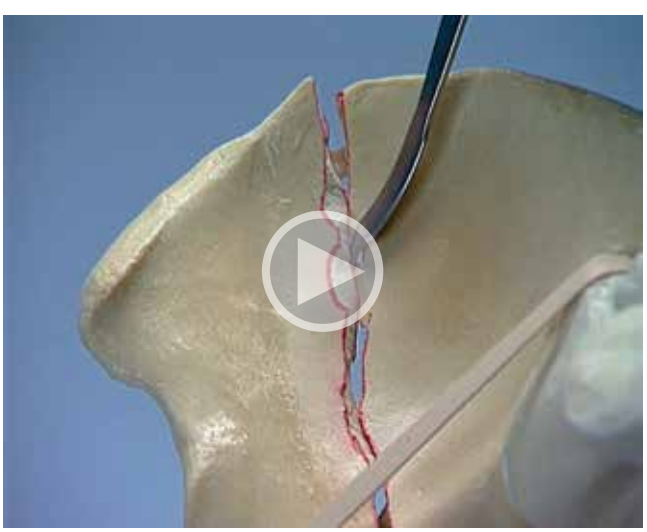

Video 3.1.1-8 Reduction of iliac wing fracture with small Hohmann retractor.

Joystick reduction

This technique can be used with Schanz screws or K-wires to manipulate fracture fragments in different planes; it can be used alone or associated to other reduction techniques (distractors, reduction forceps). The insertion of a Schanz screw into the ischium is a common technique to manipulate the posterior column of the acetabulum (in case of a posterior column, transverse, or T-shaped fracture). The same technique may be used to control rotation of the femoral diaphysis or femoral condyle when reducing a supracondylar-intercondylar fracture. The open or percutaneous insertion of threaded or unthreaded K-wires allows manipulation of bone fragments with or without a direct view (**Fig 3.1.1-16**, **Video 3.1.1-9**) [3, 12].

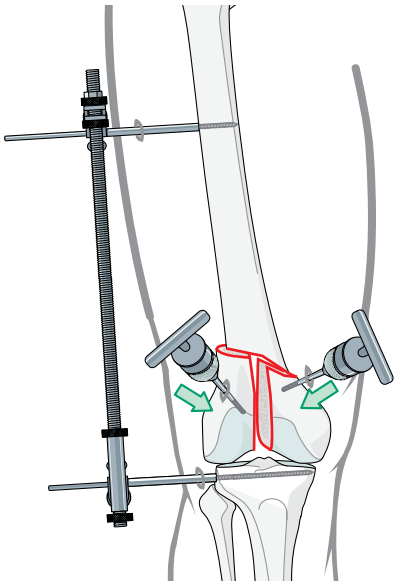

Fig 3.1.1-16 Joystick technique combined with femoral distractor.

Kapandji reduction

With a K-wire inserted through the fracture gap, the radiostyloid fragment of a distal radial fracture can be manipulated and rotated similarly to the technique with the Hohmann retractor. Definitive stabilization is achieved by completing the insertion of the K-wire into the opposite cortex of the bone (see chapter 6.3.3).

Cerclage wires

Cerclage is defined as circumferential, periosteal wire loops placed perpendicularly to the long axis of the bone. It exerts a centripetal force reducing and keeping radially displaced fragments together [13-16]. It can be used as a reduction tool and as fixation device. Nowadays the use of percutaneous application of cerclage wires using the minimally invasive technique and wire passer has been proved to do minimal harm to soft tissues and bone (**Fig 3.1.1-17**) [16]. Wähnert et al [15] have demonstrated that the stability provided by the cerclage wire is determined by the plastic deformation of the knurled twist, and the key is the innermost turn. This is achieved by applying at the same time torque and traction trying to pull the twist away from the bone (**Video 3.1.1-10**).

When applying cerclage as a reduction tool it should be applied at least 1 cm from the tip of the fracture, especially in oblique, spiral, and butterfly fragments. In large oblique or butterfly fragments several cerclage wires can be used.

Cerclage use has increased in recent years especially in periprosthetic fractures and spiral proximal or distal femoral fractures [13].

Video 3.1.1-9 Joystick reduction using K-wires in a distal radial fracture.



Video 3.1.1-10 Reduction with a cerclage wire. Soft-tissue stripping must be minimal.

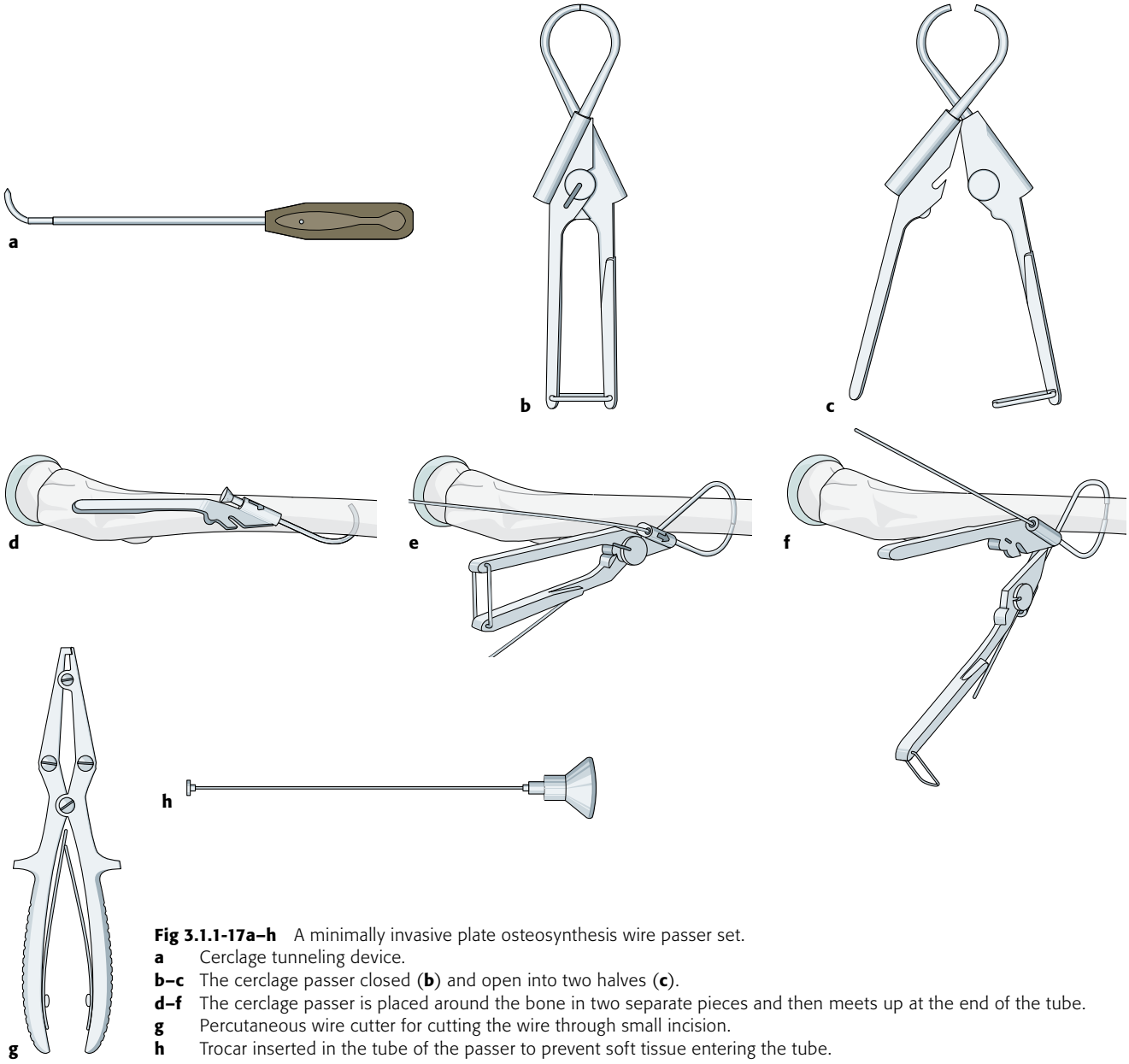

Fig 3.1.1-17a–h A minimally invasive plate osteosynthesis wire passer set.
a Cerclage tunneling device.
b–c The cerclage passer closed (**b**) and open into two halves (**c**).
d–f The cerclage passer is placed around the bone in two separate pieces and then meets up at the end of the tube.
g Percutaneous wire cutter for cutting the wire through small incision.
h Trocar inserted in the tube of the passer to prevent soft tissue entering the tube.

2.2.3 Reduction with the aid of implants

An implant can be used as a reduction tool as well as providing fracture fixation.

A simple example of this is the reduction achieved by an anatomically shaped intramedullary nail. As the nail crosses the fracture from one fragment with the same diameter to the other, reduction in the coronal and sagittal planes must occur. In multifragment shaft fractures some lengthening can be obtained after distal interlocking by hammering the nail further distally. However, precise planning is needed with the measurement of the correct nail length on an x-ray of the entire opposite bone [17].

Reduction onto a plate

Fractures within a straight segment of the diaphysis may be reduced with a plate to restore alignment before definitive fixation (Video 3.1.1-11).

By distracting the fracture the tension in the soft tissues is increased, which tends to realign the fragments to their original position. The push-pull technique with a bone spreader and the Verbrugge forceps is an elegant way of distracting and reducing a fracture of, for example, forearm bones or in delayed surgery of a malleolar type B or type C fracture (**Fig 3.1.1-18**, **Video 3.1.1-12**).

Video 3.1.1-11 Reduction of an oblique fracture using the plate as a reduction tool.

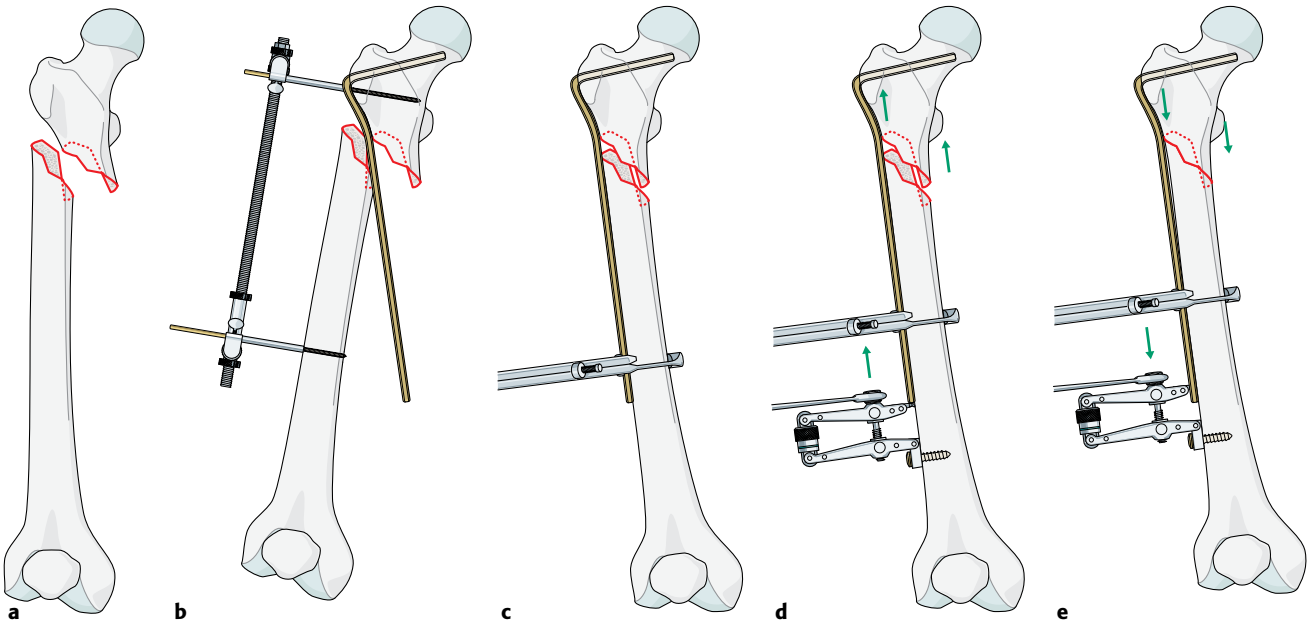

Fig 3.1.1-18a–e Reduction with the help of the condylar blade plate.
a Displaced proximal femoral fracture with the proximal fragment in adduction and flexion.
b Introduction of the 95° angled blade plate (condylar blade plate) and distraction of the fracture with the large distractor.
c Provisional fixation with a reduction forceps distally.
d Use of the articulated tension device to distract the fracture and to allow complete reduction proximally.
e By reversal of the small hook, the tension device is used for interfragmentary compression.

Buttress/antiglide plate

Another simple and powerful reduction mechanism uses the plate in buttress function. Applying a properly contoured plate to the diaphyseal fragment of an oblique metaphyseal fracture automatically reduces the fracture. This technique corrects small displacements and angulation while maintaining stability as the reduction occurs (**Fig 3.1.1-19**, **Video 3.1.1-13**).

Angled blade plate

An angled blade plate, when correctly inserted in the proximal or distal metaphyseal segment of the femur, will, by its shape, bring the diaphyseal segment into anatomical alignment. This technique is mainly used for deformity correction for malunions or nonunions (**Fig 3.1.1-18**).

Video 3.1.1-12 A bone spreader can be used to distract a fracture and allow reduction.

Video 3.1.1-13 Reduction of type B lateral malleolus fracture with a posterior buttress plate.

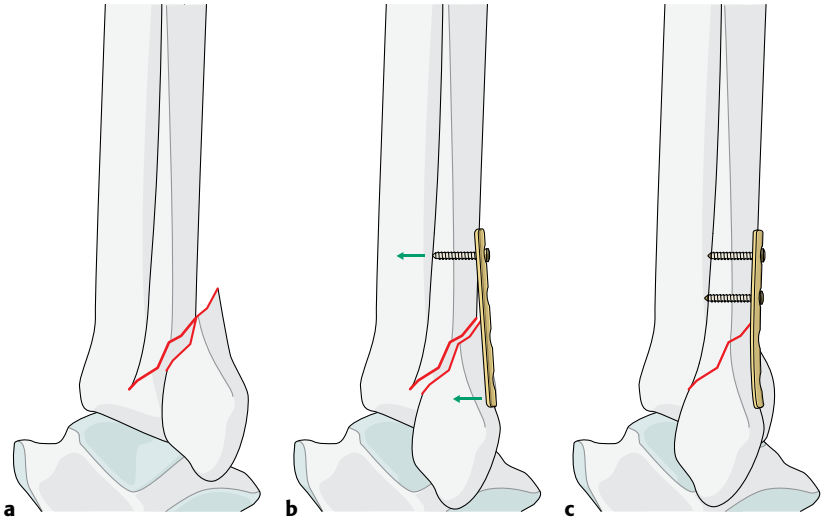

Fig 3.1.1-19a–c Indirect reduction with a plate functioning in buttress (or antiglide) mode.
a Posteriorly displaced fracture (type B) of the lateral malleolus.
b Fixation of a 4-hole or 5-hole one-third tubular plate posteriorly onto the proximal fragment.
c Tightening of the screw forces the distal fragment to glide distally and anteriorly along the oblique fracture plane into the correct position, where it is firmly locked by the plate. A lag screw may now be placed through the plate across the oblique fracture.

Anatomical contoured plates

The goals of reduction with this new generation of implants remain the same as with conventional plates. However, the application of these implants may be more demanding if they are used with submuscular or subcutaneous insertion in combination with indirect reduction techniques. Preoperative planning of the reduction, implant insertion, and order of screw placement is essential (**Figs 3.1.1-20–21**).

If conventional screws and locking head screws are to be used in the same bone segment, the order of screw insertion is important.

Miniplates and unicortical screws

The use of mini-fragment plates (2.7, 2.4, and 2.0) and screws to assist in reduction of long bone injuries in upper extremity fractures is increasing [18, 19], especially in complex periarticular injuries (see chapter 3.2.2).

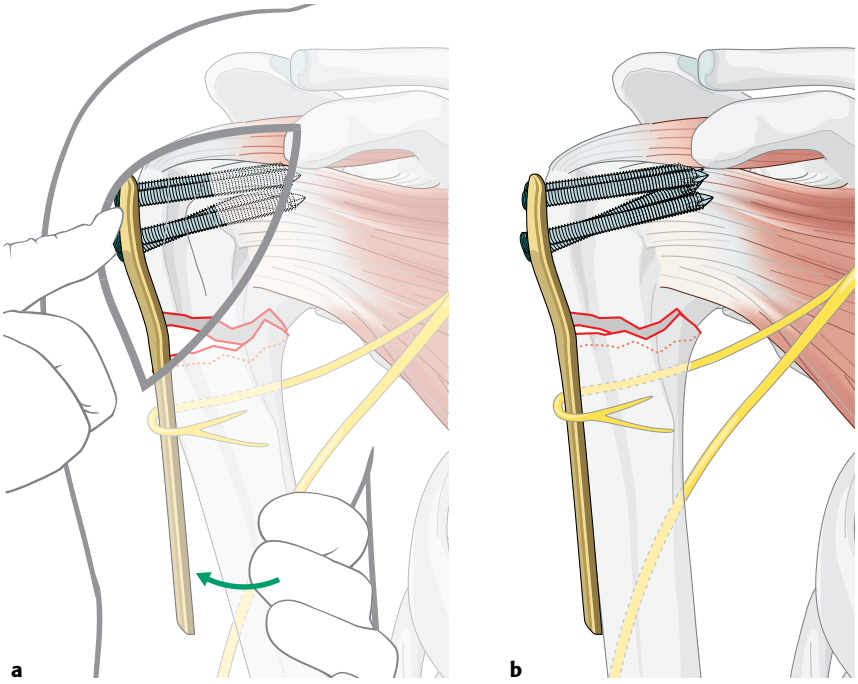

Fig 3.1.1-20a–b The anatomical plate is used as a reduction aid in the proximal humerus. Note that the plate is passed deep to the axillary nerve.

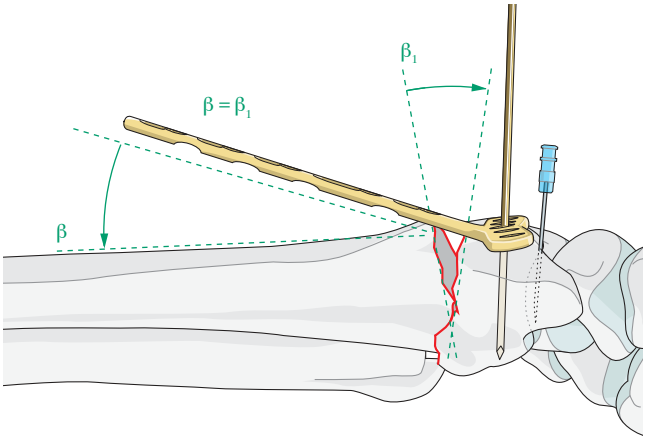

Fig 3.1.1-21 The anatomical distal radial plate is used as a reduction aid during an anterior (palmar) approach to the wrist. Careful planning of the reduction and plate placement is required. It must be noted that fixation must first be obtained distally before the reduction takes place and is followed by proximal fixation.

3 Assessment of reduction

Once the reduction of a fracture has been performed by either direct or indirect techniques, correct alignment and rotation must be checked.

There are various ways to do so (**Table 3.1.1-3**), including direct vision, palpation (digital or instrumental), intraoperative x-rays or image intensification, arthroscopy, as well as computer-assisted systems.

The small indentations or landmarks that are present in every fracture line must be aligned if the fracture is visible (jigsaw puzzle technique). When a fracture surface cannot be viewed directly, gentle palpation with a fingertip may be helpful, eg, on the quadrilateral surface in the pelvis to control reduction of an acetabular fracture. Similarly, an appropriate instrument, such as an elevator, may be used blindly to check the accuracy of reduction of an articular surface, eg, of the tibia plateau. Clinical assessment of axial and rotational alignment may be difficult and unreliable. It is, however, frequently needed, especially in closed intramedullary nailing.

Intraoperative control of fracture reduction and fixation should be done by image intensification or x-rays in two planes, even if direct reduction is performed. Angulation of the fracture may be difficult to appreciate within the limited operative field.

In articular fractures the use of arthroscopy has been described to assist or check reduction (eg, tibial plateau).

The latest developments include the use of computer-guided systems for the placement of instruments and implants or for localizing of bone fragments in space. Anatomical landmarks proximal and distal to a fracture site can serve as a reference for the calculation of residual (translational or rotational) displacement using mathematical algorithms. Navigated long-bone fracture reduction is becoming available with the use of dedicated software and trackers. This will allow rapid and accurate reduction with much less radiation exposure [20, 21].

Method of control	Field of application	Advantages	Disadvantages
Visual control of anatomy/ reconstruction	Articular/simple diaphyseal fractures (humerus/forearm)	Direct visualization, accurate	Exposure of fracture fragments, soft-tissue damage in exposure
Palpation	Acetabulum and pelvic fractures	Can be done in any fracture	Needs experience, less accurate than direct visualization
Visual control of limb	Alignment of extremity (lower)	Easy to do, can be assisted by image intensifier	Inaccurate, needs normal contralateral extremity
	Rotation of the extremity (clinical)	Compare to normal side, easy to do	Inaccurate, needs normal contralateral extremity
Intraoperative x-rays	Any fracture	Better imaging than C-arm; accurate in assessing alignment in shaft fractures	Time consuming
Image intensification	Any fracture, MIO techniques	Available, immediate evaluation	Limited field of view, increase radiation exposure
Iso C 3-D image intensifier (3-D)	Articular fractures	Accurate	Cost, time consuming, radiation exposure
CT scan	Assess articular fractures, rotation in shaft fractures	Accurate	Unavailable in most operating rooms
Arthroscopic control	Articular fractures	Accurate for articular surface	Experience, saline pumped into joint and soft tissues
Computer-assisted navigation	Articular fractures, pelvis, acetabulum, spine	Accurate, no radiation	Cost, time to learn technique

Table 3.1.1-3 Control of reduction.
Abbreviations: CT, computed tomography; MIO, minimally invasive osteosynthesis.

Classic references | Review references

4 References

1. **Mast J, Jakob R, Ganz R.** *Planning and Reduction Technique in Fracture Surgery.* 1st ed. Berlin Heidelberg New York: Springer-Verlag; 1989.
2. **Müller ME, Allgöwer M, Schneider R, et al.** *Manual of Internal Fixation.* 3rd ed. Berlin Heidelberg New York: Springer-Verlag; 1990.
3. **Schatzker J, Tile M.** *The Rationale of Operative Fracture Care.* 3rd ed. Berlin Heidelberg New York: Springer-Verlag; 1987.
4. **Marsh JL, Buckwalter J, Gelberman R, et al.** Articular fractures: does anatomical reduction really change the result? *J Bone Joint Surg Am.* 2002 Jul;84(7):1259–1271.
5. **Matta JM.** Fractures of the acetabulum: accuracy of reduction and clinical results in patients managed operatively within three weeks after the injury. *J Bone Joint Surg Am.* 1996 Nov;78(11):1632–1645.
6. **Olson SA, Matta JM.** The computerized tomography subchondral arc: a new method of assessing acetabular articular continuity after fracture (a preliminary report). *J Orthop Trauma.* 1993;7(5):402–413.
7. **Rhinelander FW.** Tibial blood supply in relation to fracture healing. *Clin Orthop Relat Res.* 1974 Nov-Dec;(105):34–81.
8. **Trueta J.** Blood supply and the rate of healing of tibial fractures. *Clin Orthop Relat Res.* 1974 Nov-Dec;(105):11–26.
9. **Wilson JW.** Blood supply to developing, mature, and healing bone. In: Sumner-Smith G,ed. *Bone in Clinical Orthopedics,* 2nd ed. Stuttgart New York: Georg Thieme Verlag; 2002:23–116.
10. **Volgas D, Harder Y.** *Manual of Soft-Tissue Management in Orthopedic Trauma.* New York: Thieme; 2011.
11. **Link BC, Rosenkranz J, Winkler J, et al.** Minimally invasive plate osteosynthesis of the distal femur. *Oper Orthop Traumatol.* 2012 Sep;24(4-5):324–334.
12. **Siegall E, Ziran B.** En bloc joystick reduction of a comminuted intra-articular distal radius fracture: technical trick. *Am J Orthop (Belle Mead NJ).* 2014 Aug;43 (8):351–353.
13. **Mouhsine E, Garofalo R, Borens O, et al.** Cable fixation and early total hip arthroplasty in the treatment of acetabular fractures in elderly patients. *J Arthroplasty.* 2004 Apr;19(3):344–348.
14. **Perren SM, Fernandez Dell'Oca A, Lenz M, et al.** Cerclage, evolution and potential of a Cinderella technology. An overview with reference to periprosthetic fractures. *Acta Chir Orthop Traumatol Cech.* 2011;78(3):190–199.
15. **Wähnert D, Lenz M, Schlegel U, et al.** Cerclage handling for improved fracture treatment. A biomechanics study on the twisting procedure. *Acta Chir Orthop Traumatol Cech.* 2011;78(3):208–214.
16. **Apivatthakakul T, Phaliphot J, Leuvitoonvechkit S.** Percutaneous cerclage wiring, does it disrupt femoral blood supply? A cadaveric injection study. *Injury.* 2013 Feb;44(2):168–174.
17. **Krettek C, Miclau T, Grün O, et al.** Intraoperative control of axes, rotation and length in femoral and tibial fractures. Technical note. *Injury.* 1998;29(Suppl 3):C29–39.
18. **Archdeacon MT, Wyrick JD.** Reduction plating for provisional fracture fixation. *J Orthop Trauma.* 2006 Mar;20(3):206–211.
19. **Oh JK, Sahu D, Park JW, et al.** Use of 2.0 Miniplate system as reduction plate. *Arch Orthop Trauma Surg.* 2010 Oct;130 (10):1239–1242.
20. **Khaler D.** Navigated long-bone fracture reduction. *J Bone Joint Surg Am.* 2009 Feb;91 Suppl 1:102–107.
21. **Khoury A, Beyth S, Mosheiff R, et al.** Computer-assisted orthopaedic fracture reduction: clinical evaluation of a second generation prototype. *Curr Orthop Pract.* 2011;22(1):109–115.

5 Acknowledgment

We thank Emmanuel Gautier for his contribution to this chapter in the second edition of the *AO Principles of Fracture Management*.

3.1.2 Approaches and intraoperative handling of soft tissues

Ching-Hou Ma

1 Introduction

"Exposure is the key to surgery"—this age-old adage has been revised in modern surgery. No longer are large skin incisions and wide subcutaneous exposures considered acceptable practice in trauma surgery. The health of the soft tissues, which surround a fracture, is now recognized as a key to successful fracture healing. The extent and the degree of soft-tissue injury at the time of fracture play an important role in healing and are one of the important factors that determine the personality of the injury. Patient factors, including advanced age, smoking, and systemic diseases, such as diabetes mellitus and vasculitis, may also affect soft-tissue healing and careful identification of comorbidities is essential when dealing with fractures. Correct interpretation of the soft-tissue damage, profound knowledge of the anatomy and the blood supply to the soft tissues, careful planning of incisions as well as accurate handling of the soft tissues can help avoid further damage and reduce complications.

2 Anatomy and blood supply of soft-tissue layers

Bone, endosteum, periosteum, muscles with their surrounding fascial layer, subcutaneous tissue, including its superficial fascial layer (tela subcutanea) [1], and finally skin can be regarded as an anatomical unit.

The blood supply to all these structures is closely related and interdependent, so it is important to understand the complex network of blood vessels and the flow of blood to successfully plan a safe and correct exposure of a fracture.

The blood supply to the skin is provided by two main sources: a fasciocutaneous vascular system and a musculocutaneous vascular network [2]. The fasciocutaneous vascular system runs through structures, such as fascia or septa of muscles. The musculocutaneous vascular system consists of three kinds of vessels:

- Segmental arteries, which are in continuity with the aorta with regard to perfusion pressure, generally course underneath the muscles and are accompanied by a single large vein, and often by a peripheral nerve [3]. The radial artery is a good example.
- Perforating vessels, also known as true muscle perforators, pass through the muscle or septa and serve as connections from segmental vessels to the cutaneous circulation. These conduits or perforators have connections to supply the muscles with blood.
- Cutaneous vessels, which consist of:
  - Musculocutaneous arteries coursing perpendicular to the skin surface
  - Direct cutaneous vessels coursing parallel to the skin

The latter can be divided into fascial, subcutaneous, and cutaneous plexuses (**Fig 3.1.2-1**) [4].

The fascia of the muscle, which consists of a dominant prefascial and a subfascial plexus, is well vascularized. In contrast, subcutaneous tissue is a poorly vascularized adipose tissue, which is separated by a well vascularized and mechanically resistant superficial fascial layer [1] that includes the subcutaneous plexus. This fascia is well developed in the trunk and in the thigh. The skin is vascularized by a complex system of various horizontal plexuses on different levels, including the subepidermal, the dermal, and the subdermal levels (**Fig 3.1.2-1**).

The different horizontal vascular plexuses are interconnected by vertically oriented vessels that perforate the muscle, septa, and subcutaneous tissues. These vertically oriented vessels originate from the cutaneous and musculocutaneous vascular system.

In a horizontal extension, these plexuses form vascular territories, also known as angiosomes, which are composite units of skin and the underlying deep tissue supplied by their source arteries [5]. They are defined by the extent of connections of the source vessel before they anastomose with branches of adjacent source vessels.

To guarantee perfusion to the adjacent soft tissue, the surgeon has to be aware of two major facts before exposing a fracture site:

- Mechanism of injury and the energy involved
- Local angiosomes including anatomical relations of the perforator vessels

If these facts are not taken into account, there is a risk of underestimating the extent of the injury to the soft tissue. Direct injury and edema may reduce or completely interrupt collateral blood supply to the skin and so further surgical injury to perforating vessels may result in skin necrosis that would not occur during elective surgery on uninjured skin. Degloving injuries are a particular risk.

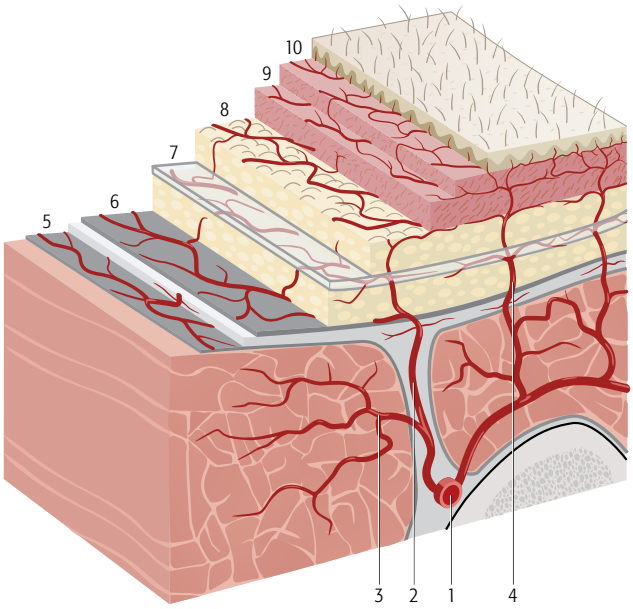

Fig 3.1.2-1 Cutaneous circulation.
The segmental artery (**1**) gives septocutaneous (**2**), muscular (**3**), and musculocutaneous (**4**) branches. The septocutaneous and musculocutaneous vessels perforate the deep fascia (the "perforators"). The cutaneous vessels consist of the perforators (**2**, **4**), which continue to run perpendicular to the skin. These give rise to three horizontal arterial plexuses: the fascial, which can be prefascial (**5**) and subfascial (**6**), the subcutaneous (**7**), and the cutaneous, which has three elements: subdermal (**8**), dermal (**9**), and subepidermal (**10**).

The surgeon must take care to avoid undermining the skin and to protect (vertical) perforating vessels during fracture surgery.

A wound must never be closed under tension, as this will reduce cutaneous blood flow and put the surrounding soft tissue at jeopardy.

3 Planning the surgical approach

The surgical approach will vary depending on the anatomical location of the injury, the type of reduction required, and the planned fracture fixation. In areas, such as the subcutaneous border of the ulna, where the skin is loosely attached to the underlying tissue and easily mobilized to cover a plate, a direct subcutaneous approach may be used. In other areas, such as the medial border of the distal tibia, the skin adheres tightly to the underlying structures and cannot be mobilized easily. Therefore, a subcutaneous approach may be much riskier. If the skin breaks down, the implant will be exposed and attempts to cover it by mobilizing local tissue will not be successful. Where possible, skin incisions should be sited over muscle. If there is skin break down with underlying muscle exposed, this can be covered by a skin graft.

Consideration should also be given to the following:

- Langer's lines (The result of elastic fibers within the dermis that serve to maintain the skin in a state of constant tension. They are a useful guide for the planning and designing of skin incisions.)
- Prevention of soft-tissue contracture (Curved or broken incisions should be used over skin creases overlying joints.)
- Anticipation of further surgery

For example, in periarticular knee fractures, delayed ligament repair or arthroplasty may be required, suggesting that straight incisions be used rather than curved ones. Likewise, an incision for plating of the fibula should be made more posteriorly to create a wide skin bridge if a second anterior approach is used to repair the distal tibial fracture at a later stage (**Fig 3.1.2-2**).

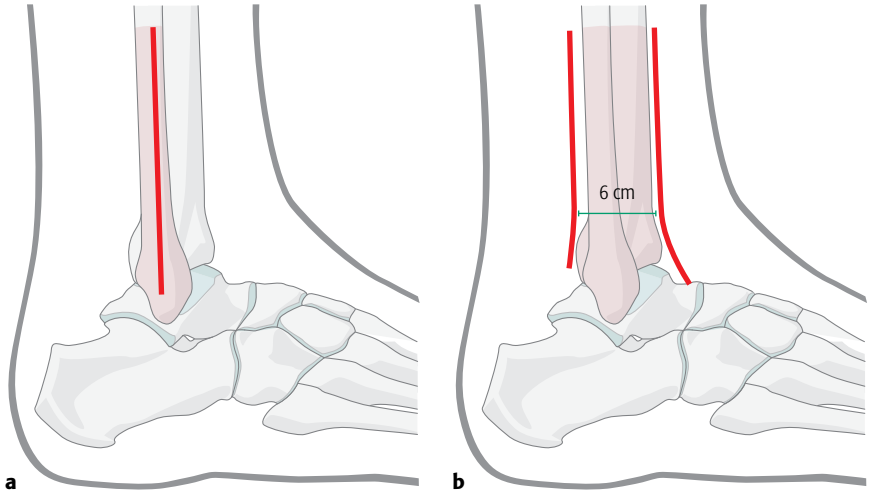

Fig 3.1.2-2a–b The standard incision for the lateral malleolus (**a**) must be moved more posterior if a second anterior approach to the distal tibia (**b**) is planned to allow a minimum skin bridge of 5–6 cm. The incisions must not undermine the skin margins.

4 Timing of surgery

There are several factors affecting the optimal timing of fracture fixation, the most important are:

- General condition of the patient, eg, polytrauma, acute comorbidities
- Soft-tissue injury
- Fracture reduction
- Planned rehabilitation

For each of these factors there may be a different optimal time for surgery and sometimes they are in conflict. Early fracture fixation allows earlier mobility of the limb and the patient, and reduces complications that are associated with prolonged immobilization, such as deep vein thrombosis and joint stiffness. Early surgery facilitates fracture reduction before the fracture becomes "sticky" due to callus formation and soft-tissue fibrosis. On the other hand, early fracture fixation may lead to increased wound complications if performed while the soft tissues are still traumatized and swollen. The amount of energy imparted on the tissues determines the zone of injury. This zone is characterized by disturbed microcirculation, which potentially endangers the viability of the soft tissues [6]. At the time of injury, it is often not possible to predict the extent of damage. Accordingly, the real area of traumatized soft tissue might be more extensive than initially appreciated, especially after high-energy trauma in the lower extremities.

The return of skin wrinkles shows that dermal edema has settled and is a favorable sign that soft-tissue swelling has decreased to the point where surgery can be undertaken safely. Gently pinching the skin or moving a neighboring joint (if possible) will demonstrate the presence or absence of skin wrinkles.

Fracture blisters are a problem for surgeons because they represent an injury to the dermis. There is little histological difference between blood-filled and clear blisters. Both are characterized by necrosis of the epidermis, although most surgeons are more concerned about blood-filled blisters [7]. There are many ways of treating fracture blisters while waiting for surgery. Removing the roof of the blister, followed by the application of various antibiotic ointments or Benzoin-tincture is advocated by some. Others leave the blister intact until surgery. No method is proven to be more beneficial than the other [7]. There is a consensus to delay surgery for 7–10 days for these types of injuries. If possible, incisions should avoid running through a blister and excessive retraction must be avoided.

As a rule, open reduction and internal fixation of the calcaneus, proximal and distal tibia can safely be postponed until 10–14 days after injury. In the upper limb, distal humeral fractures should ideally be repaired within 10 days. Elderly patients often benefit from early surgery and this has been established for hip fractures and may also be true for fractures in other sites, such as the proximal humerus [8]. The timing of fixation for fractures with associated compartment syndrome is difficult but early internal fixation in the upper limb is probably safe [9]. Most other fractures can be treated within 3 weeks from injury, if the soft tissues do not improve earlier. The patient should be counseled about smoking [10] and nutrition during this period when soft tissues are setting.

While waiting for surgery the fracture must be immobilized by a splint, by traction, or a temporary external fixator. This reduces not only pain but also significantly contributes to the recovery of the soft tissues. Moderate elevation of the extremity as well as foot compression devices—if applicable—help to resolve the swelling. Special attention must be given to the development of compartment syndrome (see chapter 1.5), especially if a circular splint or plaster cast has been applied.

A special and severe soft-tissue injury is the Morel-Lavallée lesion. It was originally described as an injury pattern associated with pelvic fractures where there is detachment of the skin and subcutaneous layers from deeper fascia. This type of lesion is caused by compression and shear stress at the transition zones of subcutaneous tissue and muscle fascia or the periosteum of bone as seen in run-over injuries. It leads to shearing of skin and subcutaneous tissue from the underlying muscle and/or bone, followed by the development of a blood-filled hollow space and fat liquefac-

tion (**Fig 3.1.2-3**). If the skin remains intact, this closed degloving injury can persist for weeks or even months, and carries a risk of infection generally thought to be caused by hematogenous seeding. Up to 46% of closed degloving lesions may have culture positive aspirates before incision and debridement. The usual clinical appearance is a fluctuant mass with mobile skin and bruising but it may also present as a solid tumor that could be confused with neoplasm. Once opened, these cases carry a similar prognosis as full-thickness burns with risk of severe infection and skin necrosis.

Occasionally, the soft-tissue envelope does not return to a state that permits surgery. For example, some open fractures need flap reconstructions and the interval between first debridement and definitive fixation is lengthy. This will result in delayed rehabilitation and poor functional outcomes. Recently, a two-stage protocol has been designed for open tibial injury consisting of a first stage that used low-profile, locking plates for temporary fixation after debridement and reduction, followed by soft-tissue reconstruction [12–14]. The second stage then consisted of locking plates for definitive internal fixation, using minimally invasive percutaneous osteosynthesis. This protocol allows patients to start rehabilitation before definitive internal fixation. Decision making is key in these complex situations and the surgeon must weigh the risks of surgery against the complications of nonoperative treatment. There are times when nonoperative treatment is the best option because the patient's physiology, comorbidities, or soft tissues may never allow safe surgery. This course of treatment may be appropriate in older patients with poor nutrition or peripheral vascular disease or patients with severe multiple injuries who remain critically ill for a number of weeks.

Fig 3.1.2-3
a Soft-tissue injury to right thigh of patient with closed degloving (Morel-Lavallée).
b After surgical debridement.
c Negative-pressure wound therapy.

5 The incision and soft-tissue handling

Surgical dissection is a skill that is best learned by observing the techniques of experienced surgeons and by repeated practice. Careful attention to detail and observation of the following basic principles can help avoid many complications:

- **Time surgery carefully.** The risk of wound-healing complications is increased if extensive dissection is done in traumatized soft-tissue areas.
- **Remember that the blood supply to the skin comes from the underlying soft tissues.** Any dissection between the different planes endangers the blood supply. Dissection in high-risk areas should occur in a vertical direction and dissecting instruments must be oriented accordingly (**Fig 3.1.2-4**). Horizontal undermining will disrupt the vertical perforating vessels that supply the overlying skin.
- **Retractors must be used gently and sparingly.** Too much force applied to retractors may impede the capillary blood flow in the skin and disrupt perforating vessels. The assistant must be instructed to retract with gentle force and just to a point where the surgeon can see the area of interest. If excessive force is needed for the surgeon to visualize the fracture, it is often better to extend the incision and reduce the tension.
- **Retractors should be placed over, not beneath, the periosteum, especially Hohmann retractor on the opposite side of the incision.** Placing a retractor beneath the periosteum will result in considerable periosteal stripping, which must be avoided.
- **The use of forceps to hold the skin should be avoided.** If required the teeth of the forceps may be used to lift up the edge of the skin rather than to grasp it. This prevents undue squeezing of the delicate skin.
- **Sharp dissection leads to less tissue damage** than that caused by dull scalpels or blunt scissors. The creation of multiple planes of dissection by repeated attempts at exposing the fracture must be avoided.
- **Use meticulous hemostasis.** Poor hemostasis will result in hematoma or seroma and increases the risk of wound breakdown and infection. Finger pressure on the skin edges close to a bleeder will control bleeding and allow precise hemostasis focused on the actual vessel.
- **High-electrocautery settings that burn the skin edges must be avoided.** The indiscriminant use of electrocautery causes tissue necrosis and increases the risk of wound breakdown and infection.
- **Look for signs of soft-tissue damage during the approach.** Contusion of the subcutaneous fat or dermis indicates significant trauma to the soft-tissue envelope. Dead or questionably viable tissue must be excised.

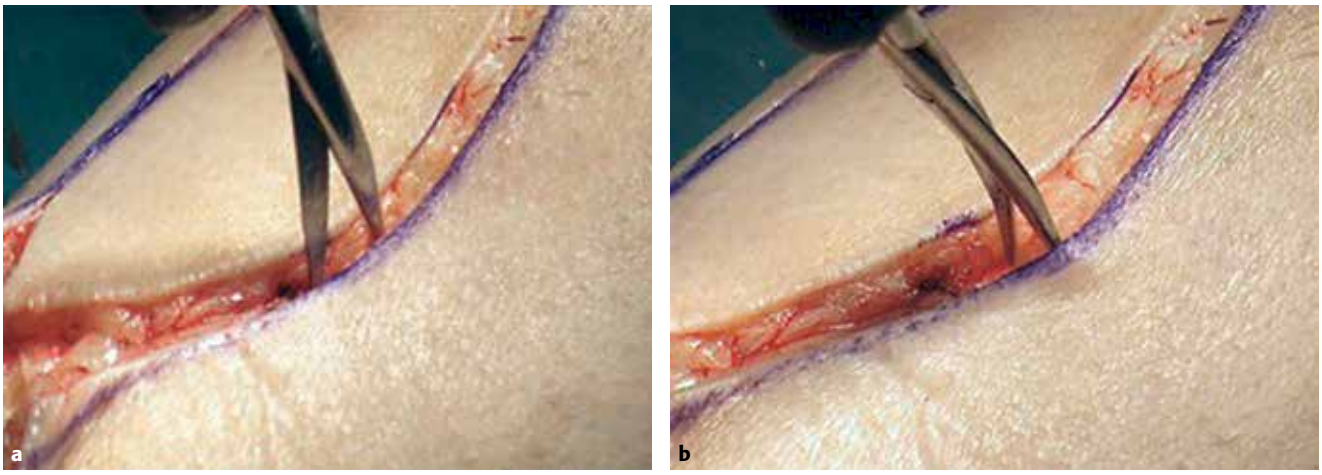

Fig 3.1.2-4a–b Dissection of subcutaneous tissue. This should always be in a vertical direction (**a**). Horizontal dissection that undermines the skin must always be avoided (**b**).

6 Incision and reduction technique

The type of reduction—direct or indirect (see chapter 3.1.1)—are important in determining the site and extent of the incision. There is a trend toward minimally invasive surgery in both acute and elective cases. Care must be taken that the planned incision allows satisfactory exposure, while minimizing any additional surgical insult (**Fig 3.1.2-5**).

The goal must be safe surgery, not the smallest possible incision.

It is better to use a larger incision than to use excessive traction that results in soft-tissue damage and necrosis. Repeated closed reductions or manipulation causes more tissue damage. Minimally invasive surgery is not indicated if the fracture cannot be reduced indirectly or in cases where there is a significant delay before surgery.

Diaphyseal fractures can often be approached through the muscle envelope, which may be significantly traumatized by the fracture from within. The approach must be gentle and respect the vascular supply to that area. In the humerus, the diaphyseal fracture often involves significant parts of the muscle envelope, which may facilitate the approach. Sometimes the surgeon must be prepared to modify the approach during surgery depending upon the "dissection" that has been produced by the fracture. Most muscles receive their blood supply and innervation from a proximal pedicle and care must be taken not to injure these structures.

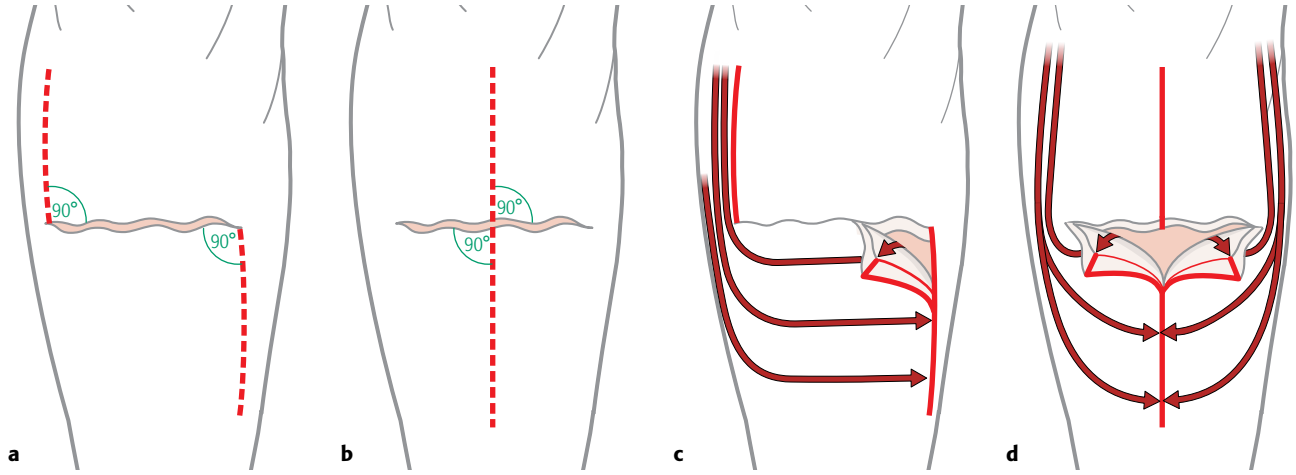

Fig 3.1.2-5a–d Management of a transverse wound.
a Transverse wound extended in a Z-fashion (red dotted line = planned incision).
b Transverse wound extended in a double opposing T-fashion (red dotted line = planned incision).
c Perfusion of a skin flap using a Z-like extension technique. Note that blood flow must traverse the entire zone of elevated skin flap (arrows).
d Perfusion of a skin flap using a double-opposing T-like extension technique. Note that the distance, which must be perfused (arrows) to reach the incision, is halved in comparison to that in **Fig 3.1.2-5c**.

The approach to metaphyseal and articular fractures should be carefully planned (**Fig 3.1.2-6**). Reconstruction of an articular fracture requires an open approach to allow a direct reduction. Associated metaphyseal comminution may be reduced indirectly and bridged by a plate that is inserted subcutaneously. Thus, an injury may be best treated by a combination of direct and indirect reduction to allow optimal soft-tissue handling.

7 Wound closure

The importance of wound closure must not be underestimated. This important part of fracture surgery should not be left to junior members of the team. Poor suture technique and misjudging the wound tension contribute to wound dehiscence. Poor placement of a splint or cast may also compromise the wound and so meticulous attention to detail is essential from the moment the patient enters the operating room to the moment he/she leaves.

Wound closure involves several basic principles:

- Wound healing depends on maintaining microcirculation and viable tissue at the wound edges.
- Excessive use of electrocautery may lead to poor vascularity at the skin edges.
- It is vitally important to keep the use of forceps to a minimum during suturing because crushing the skin edge will compromise the delicate vascular branches.

Fascial closure in the lower leg and forearm is not recommended for fear of compartment syndrome. If the subcutaneous tissue is badly contused, or if it is thin, a one-layer closure is preferable. In general, increasing the number of sutures will decrease the tension on a single suture. However, as the number of sutures increases, the local damage to subcutaneous tissue increases as there are more ischemic areas. The surgeon must rely on experience to determine the optimal tension for wound closure. A whitish area of skin between sutures is a sign of too much tension. Most surgeons do not advocate the use of a relaxation incision to

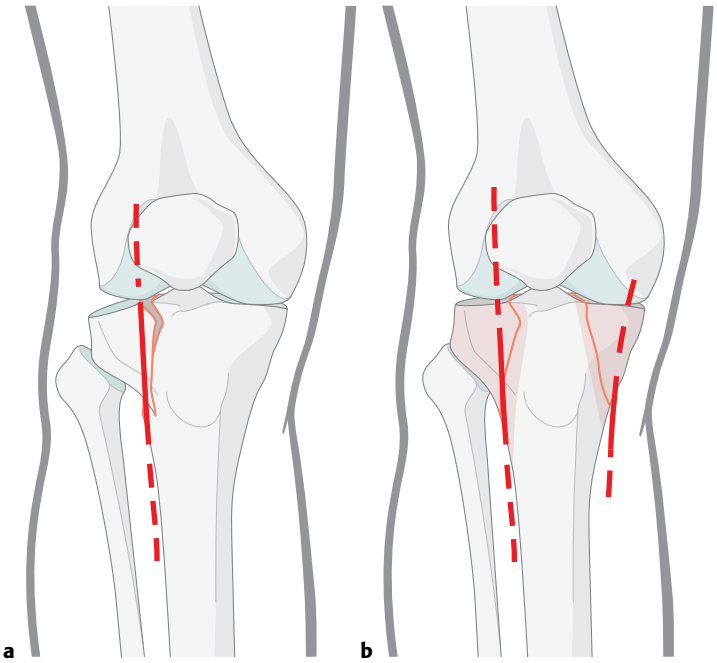

Fig 3.1.2-6a–b Approaches to proximal tibial fractures.
a The straight parapatellar approach is appropriate for proximal tibial fractures. It is extensile and does not compromise eventual secondary surgery.
b In more complex type C fractures, the medial condyle is best reduced and fixed via a separate posteromedial incision, while the lateral fracture is approached through an anterolateral approach. These two approaches are on opposite sides of the leg. The most delicate skin over the anterior and medial proximal tibia should not be touched.

allow wound closure with less tension. If the skin cannot be closed without tension then some form of primary reconstructive procedure will be needed (eg, skin graft or fasciocutaneous flap). Alternatively, the wound may be left open for delayed primary closure after swelling has resolved or a delayed reconstructive procedure [11] (**Fig 3.1.2-7**). These important decisions require experience.

The Allgöwer-Donati suture (**Fig 3.1.2-8**) is similar to a corner suture in that it enters the skin on one side of the wound, depicts a horizontal mattress on the far side of the incision, and then advances from deep to superficial at the end. It offers the advantage of grasping a relatively broad amount of tissue (thus spreading the tension force over a large area) while not disrupting as much of the vertical blood flow as a truly horizontal mattress. It is useful wherever there are flaps or parts of an incision that appear less vascularized than others. Furthermore, the Allgöwer-Donati suture technique—if properly applied—results in cosmetically acceptable scars [11] (**Video 3.1-1**).

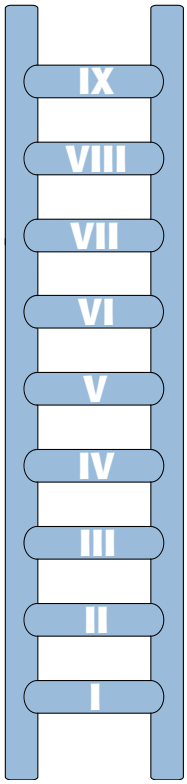

Fig 3.1.2-7 Classic reconstructive ladder. The simplest method that is likely to achieve stable closure or coverage should always be aimed at to avoid complications. The next rung is only climbed, if a simpler method fails. Primary, delayed primary, and secondary closure are not considered in this ladder. (Modified according to Ashton SJ, Beasley RW, Thorne CHM [1997] *Grabb and Smith's Plastic Surgery.* 5th ed. Philadelphia: Lippincott-Raven, 14.)

I Healing by secondary intention.
II Primary closure.
III Delayed primary closure.
IV Split-thickness skin graft.
V Full-thickness skin graft.
VI Tissue expansion.
VII Random pattern flap.
VIII Pedicled flap.
IX Free flap.

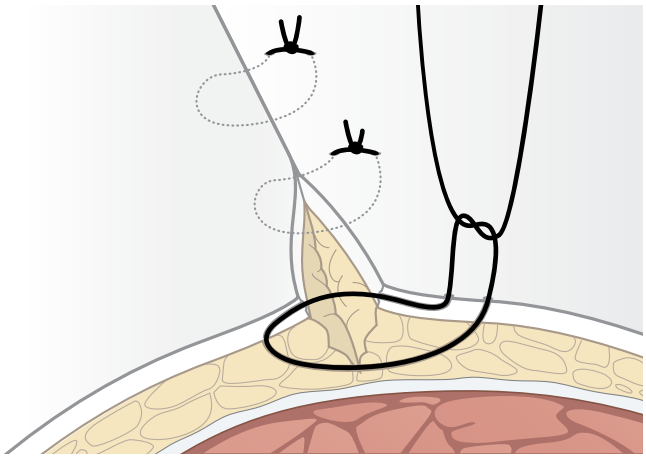

Fig 3.1.2-8 Allgöwer-Donati suture.

Another technique that may be useful in wounds that cannot be closed primarily is the use of silastic vessel loops to approximate the wound edges in stages (**Fig 3.1.2-9**) [15]. These prevent retraction of the skin edge and, as swelling decreases, the vessel loops pull the skin edges closer together. Antibiotic bead-pouch techniques can be used to enhance local antibiotic levels [11]. This can be done with wounds closed or left open (**Fig 3.1.2-10a–d**). Negative-pressure wound therapy [16] is useful in areas of skin loss and open fractures and promotes the rapid formation of granulation tissue. It may be combined with the silastic loop technique but is not advised when local antibiotic beads are used, as the vacuum effect removes the local eluted antibiotic.

Drains are a matter of personal preference with little evidence base for use. If they are used, active suction drains (vacuum) must be applied to aspirate any fluid accumulation in the wound, reduce any subcutaneous or submuscular dead space, and reduce bacterial contamination via the drain site. Because of the risk of infection, these drains should be removed within 24–48 hours. Drains are not a replacement for adequate hemostasis.

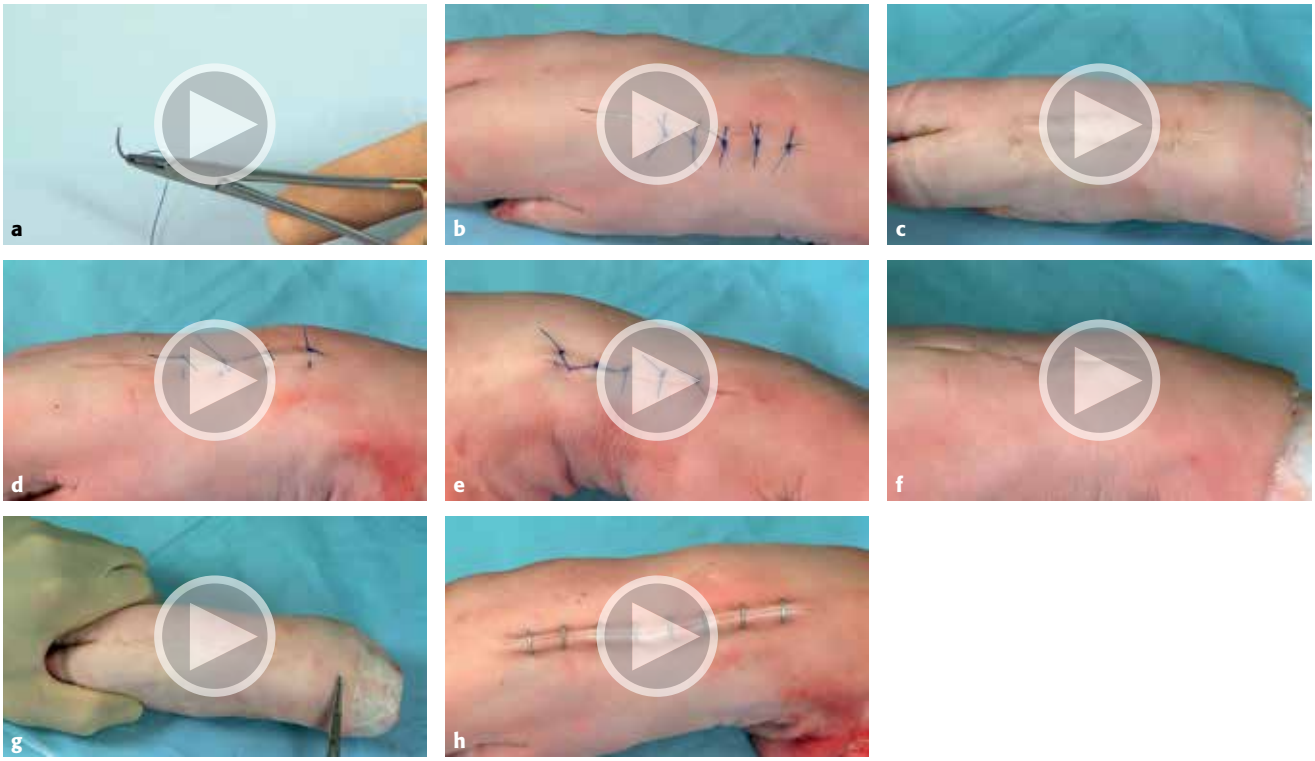

Video 3.1.1 Suture techniques shown on a porcine foot.
a General handling of instruments.
b Simple, interrupted suture technique.
c Simple, running suture technique.
d Vertical mattress (Donati) suture technique, interrupted and running.
e Allgöwer-Donati suture technique, interrupted and running.
f Simple, buried, interrupted suture technique.
g Intradermal, running suture technique.
h Skin closure with staples. There is level-1 evidence that skin staples should not be used to close wounds after hip fracture surgery in older patients.

Fig 3.1.2-9 Silastic vessel loops can be used to prevent skin retraction and facilitate delayed primary wound closure.

Fig 3.1.2-10a–d Antibiotic bead-pouch technique consisting of bone cement with 2.0 g vancomycin and 2.4 g tobramycin.

a Clinical photograph of a Gustilo type IIIB fracture after debridement.

b The edge of the wound is protected by first applying collodion or benzoin, and a thin rim of occlusive dressing in order to prevent maceration of the wound edges.

c Small 5–8 mm beads strung on a suture are placed over the wound.

d Coverage by an occlusive dressing.

Classic references | Review references

8 References

1. **Nakajima H, Minabe T, Imanishi N.** Three-dimensional analysis and classification of arteries in the skin and subcutaneous adipofascial tissue by computer graphics imaging. *Plast Reconstr Surg.* 1998 Sep;102(3):748–760.
2. **Daniel RK, Williams HB.** The free transfer of skin flaps by microvascular anastomoses: an experimental study and a reappraisal. *Plast Reconstr Surg.* 1973 Jul;52(1):16–31.
3. **Daniel RK.** The anatomy and hemodynamics of the cutaneous circulation and their influence on skin flap design. In Grabb WC, Myers MB, eds. *Skin Flaps.* Boston: Little Brown; 1975.
4. **Daniel RK, Kerrigan CL.** Principles and physiology of skin flap surgery. In: McCarthy JG, ed. *Plastic Surgery.* Philadelphia: Saunders; 1990.
5. **Taylor GI, Palmer JH.** The vascular territories (angiosomes) of the body: experimental study and clinical applications. *Br J Plast Surg.* 1987 Mar;40(2):113–141.
6. **Yaremchuk MJ, Brumback RJ, Manson PN, et al.** Acute and definitive management of traumatic osteocutaneous defects of the lower extremity. *Plast Reconstr Surg.* 1987 Jul;80(1):1–14.
7. **Giordano CP, Koval KF.** Treatment of fracture blisters: a prospective study of 53 cases. *J Orthop Trauma.* 1995 Apr;9(2):171–176.
8. **Menendez ME, Ring D.** Does the timing of surgery for proximal humeral fracture affect inpatient outcomes? *J Shoulder Elbow Surg.* 2014 Sep;23(9):1257–1262.
9. **Blum J, Gercek E, Hansen M, et al.** [Operative strategies in the treatment of upper limb fractures in polytraumatized patients.] *Unfallchirug.* 2005 Oct;108(10):843–844. German.
10. **Sorensen LT, Karlsmark T, Gottrup F.** Abstinence from smoking reduces incisional wound infection: a randomized controlled trial. *Ann Surg.* 2003 Jul;238(1):1–5.
11. **Volgas D, Harder Y.** *Manual of Soft tissue Management in Orthopedic Trauma.* Stuttgart: Thieme; 2011.
12. **Ma CH, Tu YK, Yeh JH, et al.** Using external and internal locking plates in a two-stage protocol for treatment of segmental tibial fractures. *J Trauma.* 2011 Sep;71(3):614–619.
13. **Ma CH, Wu CH, Yu SW, et al.** Staged external and internal less-invasive stabilisation system plating for open proximal tibial fractures. *Injury.* 2010 Feb;41(2):190–196.
14. **Ma CH, Yu SW, Tu YK, et al.** Staged external and internal locked plating for open distal tibial fractures. *Acta Orthop.* 2010 Jun;81(3):382–386.
15. **Asgari MM, Spinelli HM.** The vessel loop shoelace technique for closure of fasciotomy wounds. *Ann Plast Surg.* 2000 Feb;44(2):225–229.
16. **Harvin WH, Stannard JP.** Negative-pressure wound therapy in acute traumatic and surgical wounds in orthopedics. *J Bone Joint Surg Am.* 2014 Aug 6;96(15):1273–1279.

9 Acknowledgments

We thank David Volgas and Yves Harder for their contributions to the second edition of the *AO Principles of Fracture Management.*

3.1.3 Minimally invasive osteosynthesis

Reto Babst

1 Introduction

Minimally invasive fracture treatment is not a new concept in operative fracture care. Percutaneous fracture fixation using external fixators and intramedullary nails were used at the beginning of the last century by the French surgeon Alain Lambotte and during World War II by the German surgeon Gerhard Küntscher. Common to both techniques was minimal access to the bone through small skin incisions and an indirect reduction technique that did not involve direct manipulation and visualization of the fracture site. The relative stability achieved by both stabilization concepts resulted in indirect bone healing by callus formation. The appeal of this minimally invasive approach to fracture fixation was not the small incisions leaving small scars but the biological advantage with minimal soft-tissue compromise at the fracture site, allowing for undisturbed fracture healing and less infection. Open reduction and internal fixation (ORIF) aiming for absolute stability may result in devascularization of individual bone fragments.

In the late 1980s the concept of not touching the fracture site, when applying a plate as an extramedullary splint, was introduced by Mast et al [1] using an open approach but indirect reduction techniques in multifragmentary metaphyseal fractures. They used the term "biological osteosynthesis", since this technique aimed not for rigid anatomical fixation but for restoration of length, axis, and rotation without compromising the vascularity of the fracture fragments. This resulted in secondary bone healing with ample callus formation allowing earlier weight bearing, and fewer secondary bone grafts and deep infections. The first attempts at percutaneous submuscular fixation with the introduction of a plate through a small skin incision was described by Krettek et al [2], applying a fixed angle plate to the distal femur. The last two decades has seen the introduction of new adaptations to plate technology with locking head screws (LHS). This has facilitated the surgical technique and the world wide spread of the minimally invasive plate osteosynthesis (MIPO) technique [3]. The application of these locking plates has also been helped by special reduction and introduction tools and by the development of anatomically preshaped plates [4].

2 Definition of minimally invasive osteosynthesis

Minimally invasive osteosynthesis (MIO) is the internal fixation of fractures using indirect reduction techniques through small incisions to reduce a fracture and to insert an implant remote from the fracture zone. Minimally invasive osteosynthesis therefore includes all types of percutaneous fracture fixation, such as external fixation, intramedullary nailing, percutaneous K-wire and screw fixation, as well as MIPO.

This chapter focuses on MIPO, while other MIO procedures like external fixation (see chapter 3.3.3), intramedullary nailing (see chapter 3.3.1), and percutaneous K-wire and screw fixation (see chapter 3.2.1) can be found elsewhere.

In general, the biomechanical concept used with MIO is relative stability. However, under special conditions, absolute stability with MIPO can also be achieved using percutaneous lag screws in combination with a protection plate.

3 Indications for MIPO

The option of minimally invasive plate application must always be balanced against other possibilities, especially intramedullary nailing. Both have similar biological advantages over conventional ORIF and require careful preoperative planning.

MIPO is used in the following cases:
- In metaphyseal fractures
- When soft-tissue conditions preclude an open procedure
- When the fracture pattern is not suitable for intramedullary nailing (intraarticular extension, narrow or deformed medullary canal)
- When other implants obstruct the medullary canal (arthroplasties, femoral nails)
- When a fracture involves open growth plates
- When a patient's general condition (eg, polytrauma, lung contusion) precludes additional systemic insults, such as intramedullary reaming

Plate osteosynthesis must also provide the correct biomechanical environment for the specific fracture pattern. For example, when plating a simple metaphyseal fracture, absolute stability is best using interfragmentary compression with lag screw fixation. This goal can be achieved in a percutaneous fashion using minimally invasive techniques but requires meticulous surgical planning and technique.

The balance between MIPO and open surgery must always be tempered by the principles of osteosynthesis and the skills and experience of the treating surgeon.

4 Preoperative planning for MIPO

Preoperative planning is of paramount importance with MIPO techniques because imaging of the fracture zone is only possible with the C-arm. Therefore, adequate positioning of the patient to provide good access for AP and lateral C-arm views is imperative. The surgeon should consider draping both legs free to provide the healthy leg as a template for intraoperative control of length, alignment, and rotation.

4.1 What does planning include?

The surgeon should consider:
- Position of the patient, surgeon, surgical assistant, and operating room personnel
- Specific instruments and implants
- C-arm location and draping, type of operating table (eg, radiolucent)
- Draping of patient
- Biomechanical fixation concept
- Surgical approach
- Surgical sequence
- Tactic(s) for reduction
- Fixation steps
- Closure and aftercare

Several questions should be answered before starting a MIPO procedure:
- Where are the danger zones or safe corridors in respect to the planned implant access?
- Should the fixation provide relative stability by using a bridge plate or is the fracture best treated with absolute stability with interfragmentary compression?
- How can reduction be achieved and maintained?
- How best to check for length, alignment, and rotation with the C-arm before fixation?
- Are the surgical assistants and instruments for direct and indirect reduction available?
- Is the C-arm available with a competent technician?
- Is there need for additional instruments to facilitate percutaneous reduction?
- Is there need to precontour the plate?
- How and when does the surgeon proceed when the original goal of MIPO cannot be achieved (back-up plan)?

4.2 Danger zones

A thorough knowledge of surgical anatomy is necessary to avoid damaging vital structures, such as nerves and blood vessels. Several danger zones must be considered when inserting and manipulating instruments and implants through small incisions without visual control of the endangered structures.
- Proximal humerus:
  - Axillary nerve passes 5–7 cm below the acromion tip, around the proximal humerus, coming from posterior to anterior.

- Humeral shaft:
  - Radial nerve passes from proximal posterior to distal anterolateral and then between the brachialis and brachioradialis muscle.
  - Musculocutaneous nerve passes beneath the biceps muscle along the anterior and medial brachialis muscle.
- Femoral shaft:
  - Superficial femoral artery runs from proximal anterior to distal posterior through the adductor canal at the junction of the middle and distal third of the femur and comes close to the medial and posterior femur shaft before emerging in the popliteal fossa.
- Distal tibial shaft:
  - Neurovascular bundle of the anterior tibial artery and the deep peroneal nerve are closely adjacent to the distal third of the tibia running from posterior to the anterior surface of the tibia.
- Medial malleolus:
  - Saphenous nerve and vein are at the level of the medial malleolus.

4.3 Reduction

Closed reduction

Closed reduction using indirect reduction is a main tenet in MIPO. This technique can be demanding when the fracture has to be reduced without touching the fracture site. The soft-tissue envelope together with traction forces alongside the limb axes are needed to counteract the deforming forces and to create a stable operative field for MIPO. Complete muscle relaxation by an anesthetist may also be needed. This should result in restoration of length, alignment, and rotation. Several instruments, like the traction table, one or two large femoral distractors [5] or an external fixator can create a stable operative field. The insertion of the plate, which is temporarily or definitively fixed to the distal or the proximal fragment, can also be used to align the fracture. Additional tools like bumps or radiolucent triangles can also help reduce the fracture. Schanz screws, percutaneous ball spike pushers, manipulators, collinear forceps (**Fig 3.1.3-1**) or intramedullary rods help to fine tune the reduction of the fracture and to maintain it for x-ray control before MIPO fixation.

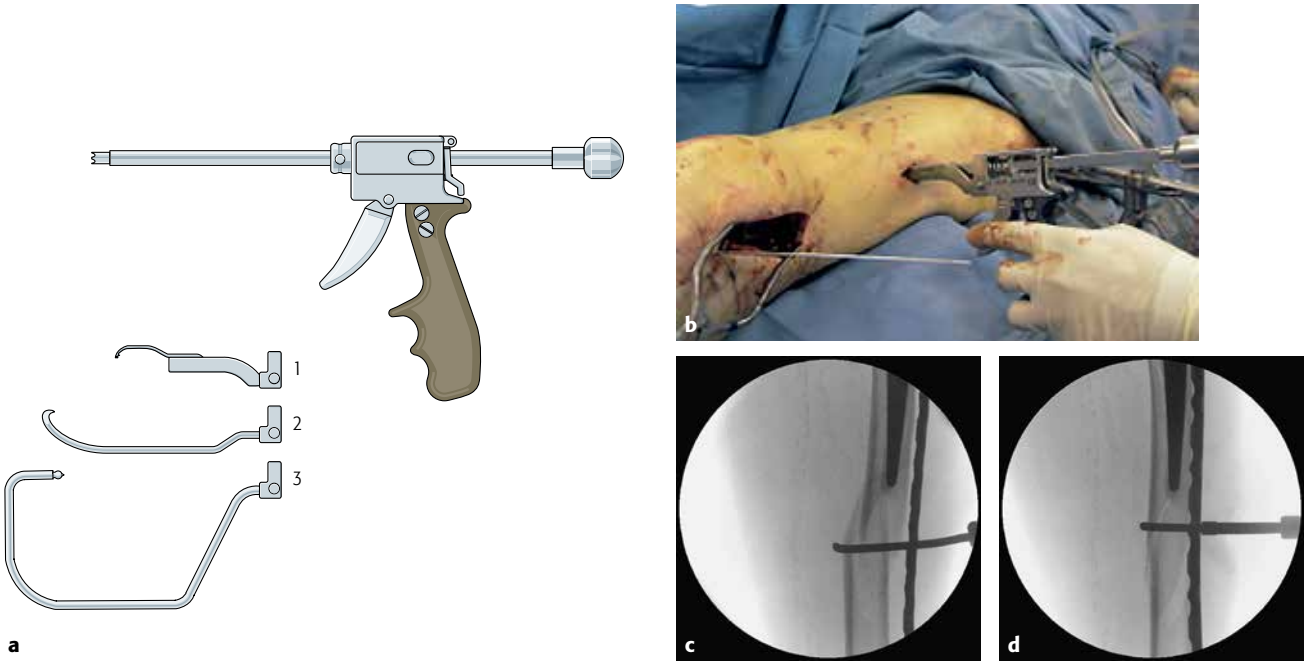

Fig 3.1.3-1a–d Collinear reduction forceps for minimally invasive percutaneous reduction of a periprosthetic fracture of the femoral shaft.
a Reduction forceps with different tips for minimally invasive plate osteosynthesis of shaft fractures (1). Pelvic and proximal femoral fractures (2) and articular fractures (3).
b Reduction forceps inserted through a short skin incision.
c Fracture reduction with collinear forceps in a periprosthetic fracture.
d Reduction of the distal fragment against the plate and holding the reduction with the collinear forceps.

Soft-tissue handling

The aim of MIPO is not to produce the smallest possible incision(s). Careful soft-tissue handling remains essential and excessive traction on the wounds must be avoided—it is better to extend the wound a few millimeters to facilitate insertion of the implant. Stretched and contused skin is prone to poor healing and wound infection. Subcutaneous plates must be carefully contoured and placed so they do not cause pressure necrosis of the wound. This can be a problem with tibial plates inserted at the medial malleolus.

Limited open reduction

Displaced intraarticular fractures and simple metaphyseal or diaphyseal fractures require anatomical reduction with lag screw fixation. This can be achieved by percutaneous manipulation using pushers, tamps and balloons for articular fractures under arthroscopic and C-arm control. For simple metaphyseal fractures, percutaneous applied clamps may provide anatomical reduction followed by insertion of a lag screw. A protection plate is then inserted through small incisions. In these situations, a limited open approach to achieve an anatomical reduction and stable fixation is recommended (**Fig 3.1.3-2**).

Role of cerclage in reduction

A cerclage is a simple and efficient centripetal reduction tool especially for simple spiral or oblique fractures and for the reduction of fragments around an implant (periprosthetic fractures). Historically, this technique developed a bad reputation but recent evidence has shown that when properly used with minimal soft-tissue stripping, it may be one of the best reduction techniques [6]. The method of application of the cerclage is vital. The periosteal blood supply must not be disturbed at the fracture site. A special forceps for minimally invasive application of cerclage wires allows for safe application of cerclage wires or cables for reduction of simple spiral fractures or additional fixation in periprosthetic fractures. The MIO wire passer is a special forceps with two connectable cannulated semicircles which can be inserted atraumatically around the bone. A wire or a cable can then be inserted with minimal soft-tissue damage (**Fig 3.1.1-17**).

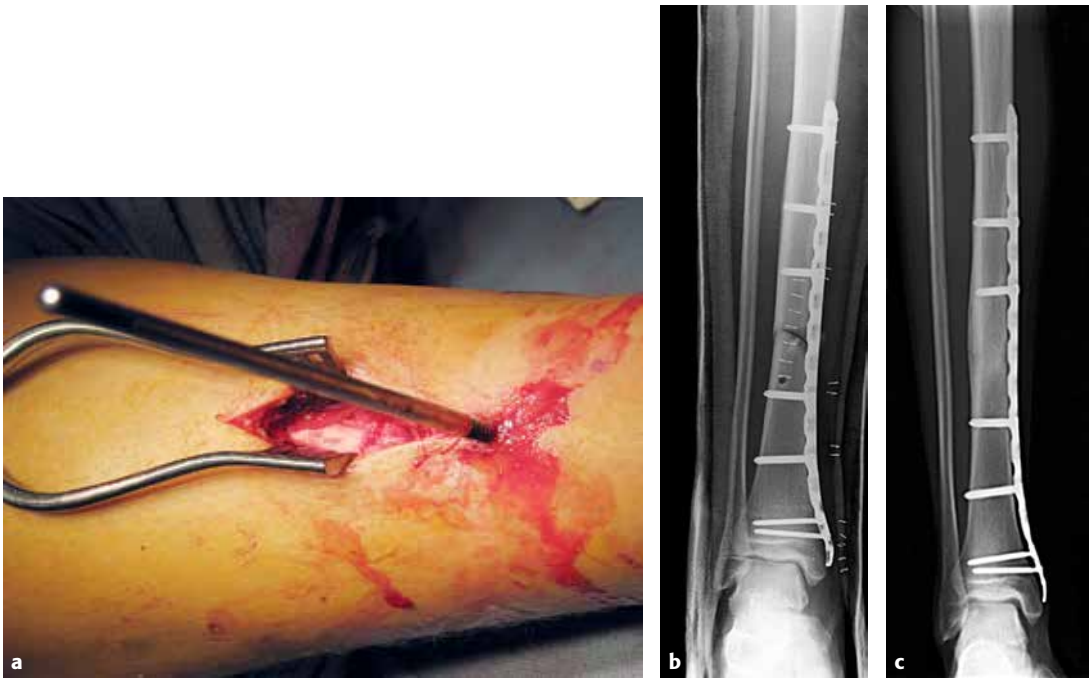

Fig 3.1.3-2a–c A 16-year-old patient with a simple fracture of the tibia.
a Closed percutaneous reduction with joystick (still in situ) did not give anatomical reduction, therefore a limited open approach to achieve anatomical reduction was performed before plate insertion.
b Postoperative x-ray: bridging plate concept. Note skin staples at the level of the incisions.
c X-ray 1 year postoperatively: bone healing with minimal callus formation.

4.4 Absolute or relative stability?

For most MIPO techniques, relative stability is the recommended biomechanical principle. The indirect reduction technique using long plates to bridge a multifragmentary metaphyseal or diaphyseal fracture is a classic example. This corrects length and alignment and allows undisturbed indirect fracture healing by callus formation.

However, the surgeon must be aware of rotational malalignment, as the literature shows a surprisingly high rate of this specific deformity (as high as 25% of cases) [7].

In contrast, simple metaphyseal or diaphyseal fractures (AO/OTA Classification type A fractures) require anatomical reduction and absolute stability obtained by interfragmentary compression using a lag screw and protection plate. This is the recommended principle to prevent high strain at the fracture gap and results in direct bone healing.

4.5 Implants

Minimally invasive plate osteosynthesis can be performed using many types of plates. Long straight plates are usually adequate for midshaft fractures. In recent years, anatomically preshaped locking compression plates (LCP) have become available.

Conventional plates (LC-DCP)

Conventional plates should be long (10–14 holes in the tibia and the humerus; 16–24 holes in the femur).

As a rule, the plate length should be three times longer than the fracture length.

The plate should reach from one metaphysis to the other [8]. Exact contouring of the plate is necessary to fit metaphyseal flares: conventional screws will bring the bone to the plate and if contouring is not precise, there will be a loss of reduction when the first screw is tightened (**Fig/Animation 3.1.3-3**). Precontouring the plate with a plastic bone model is helpful. This plate is sent for sterilization before the operation.

Locking compression plates

The LCP, if used as a locking plate, does not require a precise contouring. However, minimal contouring of straight LCPs (when not using anatomical plates) is advisable to prevent prominence of the plate under the skin.

Contouring of the LCP should not occur within the threaded holes as deformation may prevent purchase of the locking head screws.

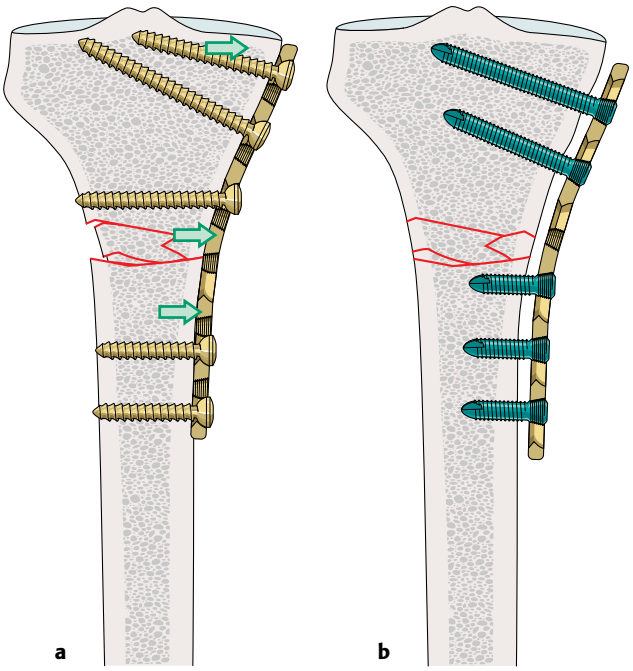

Fig/Animation 3.1.3-3a–b

a With conventional screws the bone is reduced (pulled) toward the plate producing primary reduction loss when not precisely contoured.

b Angular stability of the locking head screws ensures maintenance of the initial reduction even if the plate is not contoured exactly. This allows the locking compression plate to be inserted by MIPO technique.

4.6 Intraoperative imaging

Without intraoperative imaging, MIO and MIPO are not feasible. An approach through soft-tissue windows remote from the fracture site with no direct visualization of the fractured fragments needs repetitive imaging to check the reduction. It is important to create a stable operative field, which allows maintenance of the reduction achieved. Fracture reduction can be maintained by indirect reduction tools like the traction table, the large femoral distractor, or the external fixator. Additional tools like bumps, towels, percutaneous clamps and K-wires are also helpful. This provides an environment where C-arm pictures in AP and lateral projection can be taken without radiation exposure of the surgeon's hands (see chapter 4.9).

4.7 Alternative plan

There should always be an alternative plan in case MIO/MIPO cannot be carried out as desired. This should include:

- Limited opening at the fracture site to apply an instrument for direct reduction
- Exposing the fracture as in conventional plating (ORIF)
- Asking for help from a more experienced surgeon

A thorough knowledge of the pros and cons of MIPO will help to reduce pitfalls associated with this demanding technique including malunion, delayed union, and nonunion.

4.8 Postoperative management

Postoperative management after MIPO surgery is not different from other MIO or ORIF cases. Pain medication may be required for a shorter time due to limited skin incisions. Antibiotic and thromboembolic prophylaxis is also mandatory like in other implant surgery. The affected limb should be well positioned and elevated and wrapped to reduce swelling. Splints will help to prevent contractures, eg, application of a U-slab to the ankle and the foot to prevent equinus. Physical therapy should be started as soon as possible after MIPO procedures. Joints should be mobilized by active or active-assisted movements or by passive continuous motion, especially after articular fractures. Weight bearing should be limited according to the fitness of the patient, the bone quality, and the fixation stability.

Implant removal may be considered after 1–2 years depending on the bone segment if:

- The patient is young
- When the implant is in the lower extremity
- When the implant limits limb function during work or sport or causes irritation

The patient should be informed about the possibility that broken screws may be left in situ because removal may cause soft-tissue and bone damage and increase the risk of refracture. When removing LHSs, special removal instruments should be available to remove jammed screw heads with conical extraction screws or special drill bits. To reduce the risk of refracture, patients should be advised to avoid contact sports or heavy labor for 2–4 months after implant removal [9].

5 MIPO in specific bone segments

Minimally invasive plate osteosynthesis has been shown to have some biological advantages in long bones when nailing is not an option, especially in periarticular fractures extending into the shaft. Recent literature [10–12] has shown the feasibility, safety, and efficacy of this technique. However, there remain some anatomical regions where MIPO is too dangerous for general application, such as the distal humerus or the forearm, due to the close proximity of the neurovascular structures [13]. In addition, MIPO may be used with scapula fractures [14], in the pelvis [15], in the calcaneus [16], and for corrective osteotomies [17] and bone transport [18].

5.1 Clavicle

Principle: Plate contouring and plate position is an important issue when deciding to perform MIPO of the clavicle. Superior plate position is easier to apply. The plate has to be bent in a horizontal S-shape fashion using a reconstruction plate 3.5 or an anatomical plate. Fixation of the plate is possible with conventional screws due to the flat surface of the clavicle. If anterior plate position is preferred, a vertical S-shape must be contoured or an anatomical plate is used. For anterior plate position, LCPs are preferred because they tolerate malcontour without compromising the achieved reduction. The fracture has to be reduced and stabilized either by a temporary plate or by a mini external fixator placed 90° to the definitive plate (**Fig 3.1.3-4**). The patient can be positioned in a supine or beach chair position. C-arm views in AP [10–12] are taken during the operation. Superior plate position causes more skin irritation than anterior position and is cosmetically less appealing in slim patients.

Patient selection: Simple clavicular shaft fractures are a good indication for MIO surgery with titanium elastic nails (ESIN, see chapter 6.1.2), whereas the indication for MIPO in clavicle fractures is multifragmentary clavicle fractures. Compared with ORIF, MIPO of midshaft clavicle fractures seems to be an effective fixation method (**Fig 3.1.3-4**) [19], but there may be a slightly increased risk of nonunion.

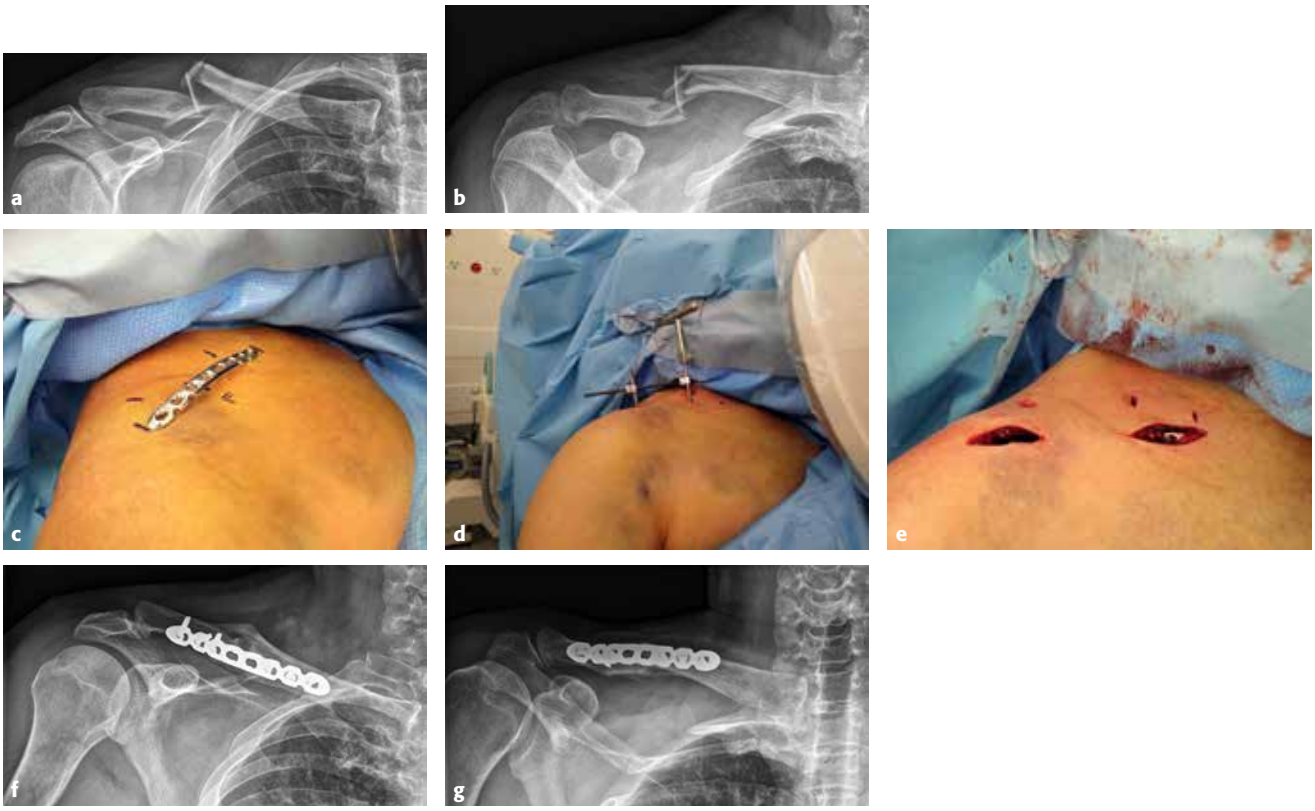

Fig 3.1.3-4a–g
a–b A 25-year-old patient with multifragmentary midshaft clavicular fracture.
c Due to fragmentation, a minimally invasive plate osteosynthesis anterior plating was chosen. Planning of incisions using the anterior plate.
d Reduction of the fracture with a superior small fragment external fixator.
e Soft-tissue windows after plate fixation.
f–g X-ray 1 year after operation.

5.2 Humerus

5.2.1 Humerus proximal

Principle: There are a multitude of anatomical plates for proximal humeral fractures available and these can be inserted using two MIPO approaches: either a short version of the conventional deltopectoral approach or a lateral deltoid-split where the plate is slid beneath the axillary nerve at the neck of the humerus. There is some recent evidence in favor of the MIPO approach [20]. Ligamentotaxis is of great help for reduction when using a beach chair position. Traction by an assistant or a pneumatic traction device (**Fig 3.1.3-5e**) reduces the fracture, which is then additionally stabilized by the inserted plate, temporarily fixed at the humeral head level, and then fixed at the shaft level (**Fig 3.1.3-5f–h**). The shaft is then reduced to the plate using a conventional screw before definitive fixation takes place. Intraarticular fractures that are not reduced by ligamentotaxis have to be reduced first by direct reduction through the fracture using an elevator before temporary fixation with K-wires. To neutralize the traction forces of the rotator cuff, stay sutures add stability when tied to the plate at the end of the fixation.

Patient selection: Displaced surgical neck fractures (11A2, 11B), including those with metaphyseal extensions, 3-part fractures (11B1 and 11B2), especially those with a large posterior major tuberosity fragment, and 4-part valgus impacted fractures (11C1) where soft-tissue attachments to the tuberosities remain intact (**Fig 3.1.3-5**). Fracture dislocations and grossly displaced fractures are difficult to reduce, so a formal deltopectoral or an extended lateral approach might then be chosen.

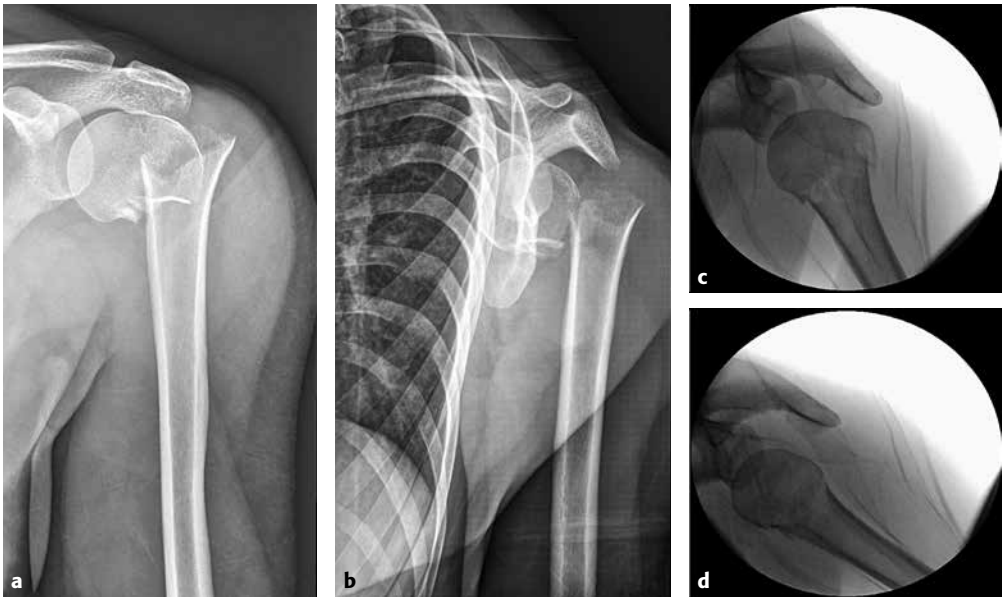

Fig 3.1.3-5a–l
a–b A 36-year-old patient with a displaced 2-part proximal humeral fracture.
c–d Intraoperative view after traction.

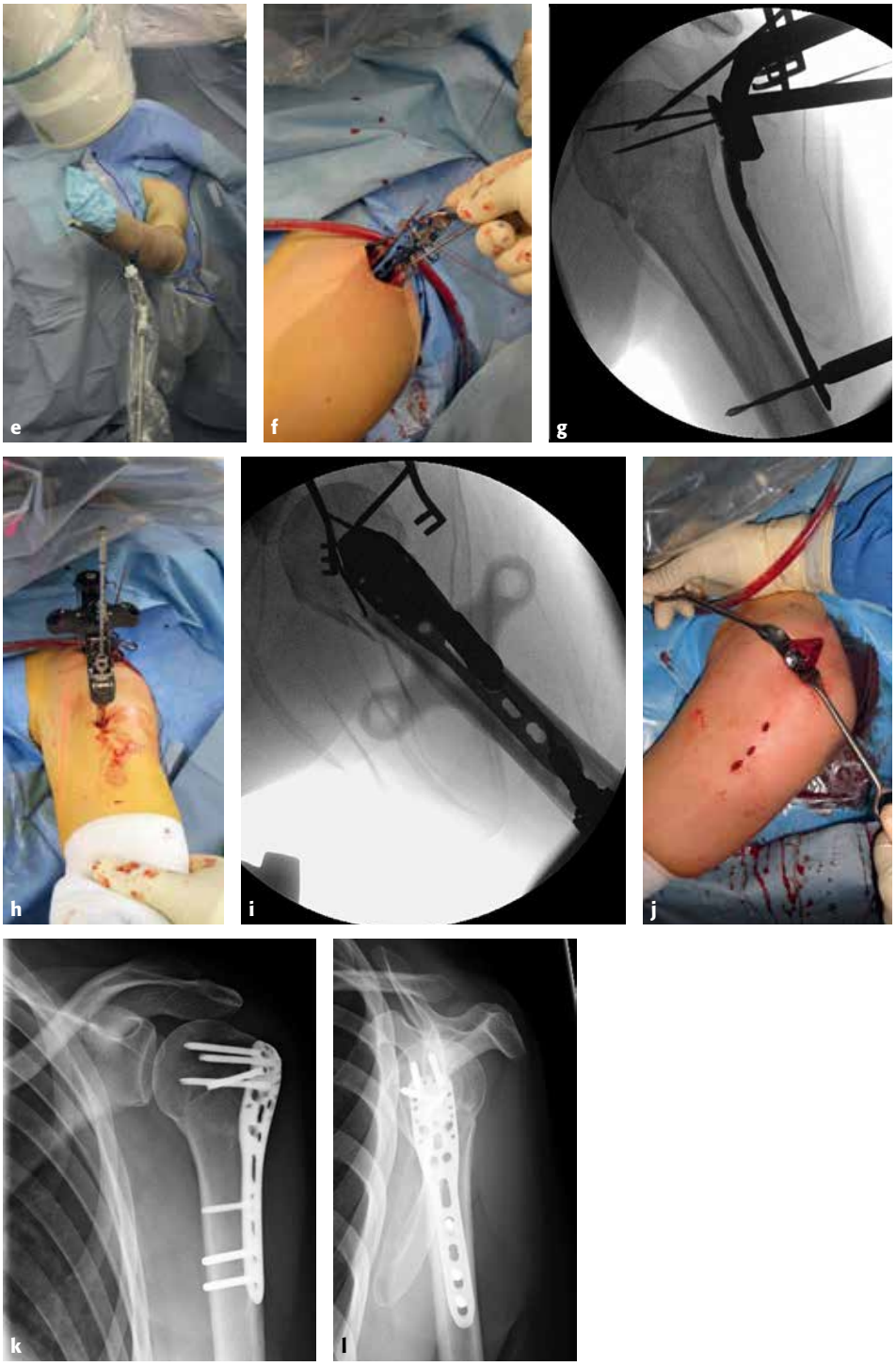

Fig 3.1.3-5a–l (**cont**)
e Pneumatic traction device to maintain reduction.
f Insertion of PHILOS plate.
g–h Temporary fixation of plate to the shaft using K-wires and a drill bit distal in AP view.
i X-ray control in axial view.
j–l Percutaneous definitive fixation of plate.

5.2.2 Humeral shaft

Principle: Fractures of the proximal and middle humerus need two different approaches when MIPO is used. Proximal humeral shaft fractures with fracture extension close to or into the humeral head are approached proximally by the same deltoid-split lateral approach as proximal humeral fractures. Depending on the fracture extension at the shaft level, the plate length determines the distal approach (**Fig 3.1.3-6**). This is determined by the course of the radial nerve and the decision of the surgeon to twist the MIPO plate or not. If the plate is not twisted, the incision is lateral and the radial nerve has to be explored, as it passes through the intermuscular septum between the lateral head of the triceps muscle and the brachioradialis muscle. The nerve will be in close relationship to the plate. If the plate is twisted then it will be positioned more anterolateral (twist ≤ 45°) or anterior (twist 70–90°) on the distal humeral shaft. For the anterolateral approach, the biceps muscle is retracted to the medial side and the brachialis muscle is split in the middle section, leaving a part of the brachialis muscle as protection for the radial nerve (**Fig 3.1.3-7**). A lateral straight plate helps fracture alignment and is technically easier to apply than a twisted plate. Patient position can be either supine using an arm table or in beach chair position using traction to stabilize the operative field. The inserted plate is temporarily fixed proximally to allow enough stability to check reduction with the image intensifier. An external fixator may be used to add stability to the operative field (**Fig 3.1.3-8c–d**).

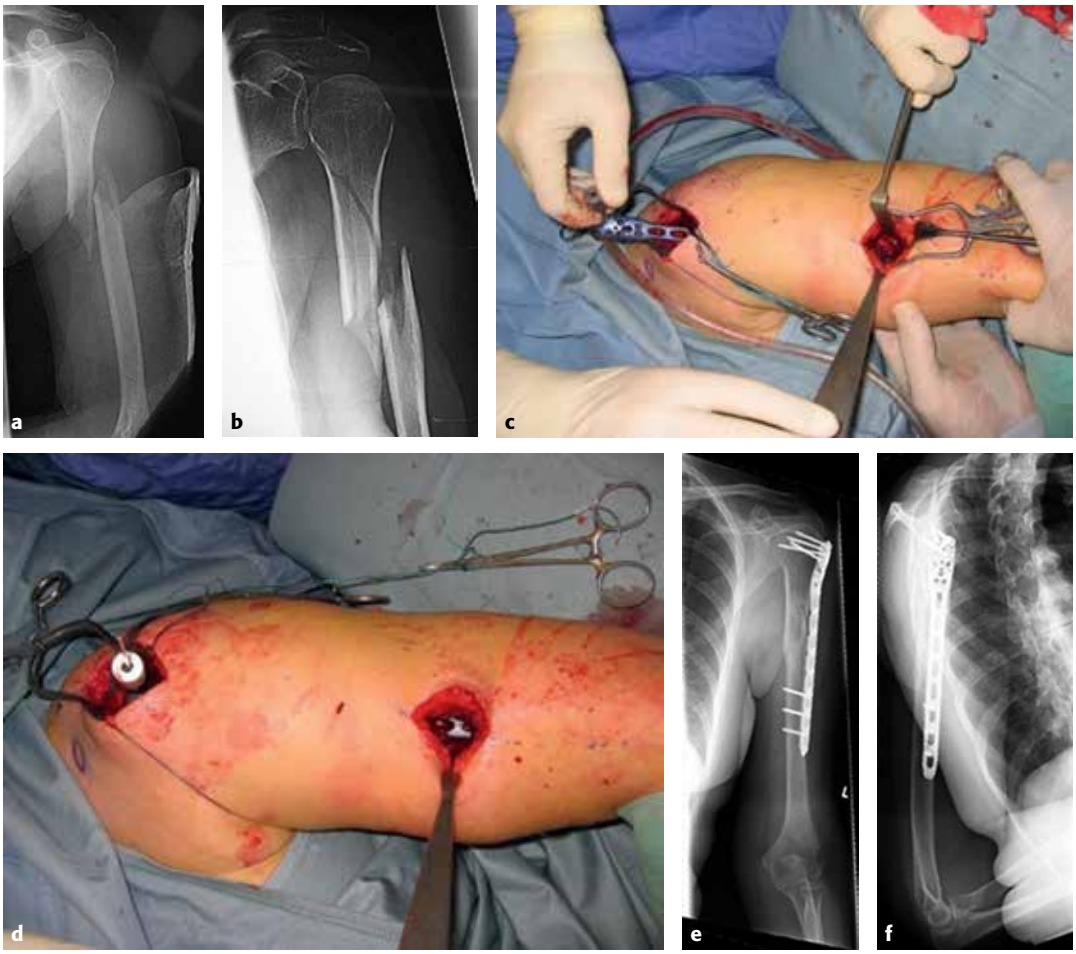

Fig 3.1.3-6a–f
a–b A 66-year-old patient with a displaced proximal spiral humeral shaft fracture. Insertion of a straight PHILOS plate.
c The distal incision was proximal to the anterior course of the radial nerve. Note stabilization of the operative field by traction.
d Temporary fixation of the plate for C-arm control.
e–f X-ray control 1 year postoperative.

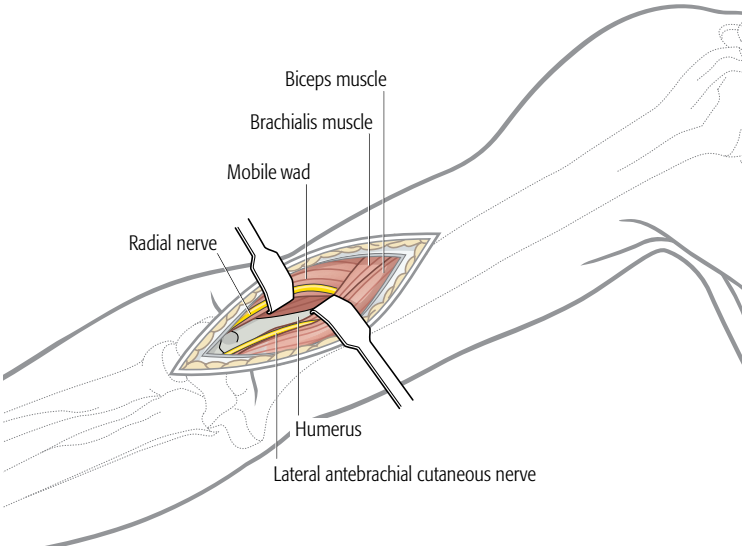

Fig 3.1.3-7 Anterolateral distal incision for distal plate fixation for a humeral midshaft fracture. The biceps muscle including the lateral antebrachial cutaneous nerve is pulled to the medial side. The brachialis muscle is split in the middle. The lateral part then serves to protect the radial nerve.

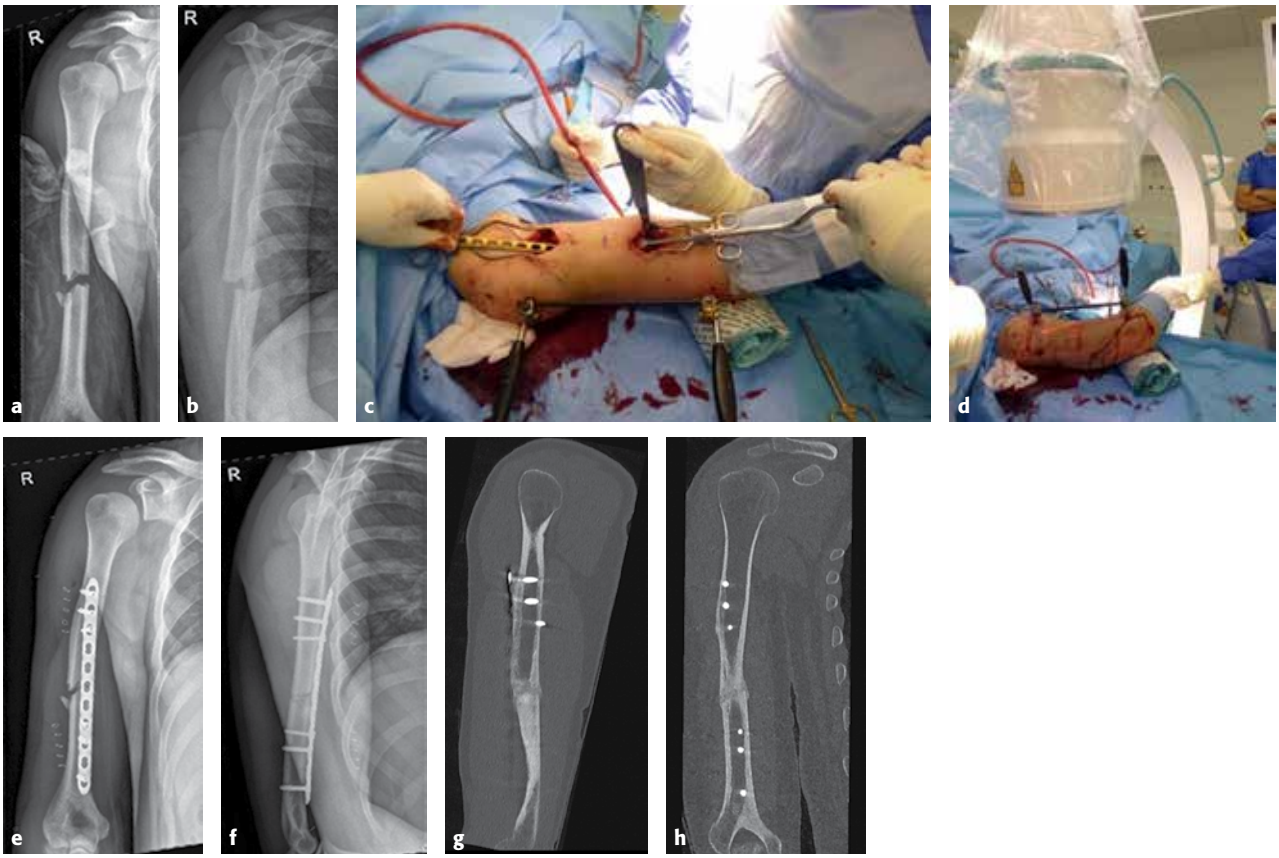

Fig 3.1.3-8a–h

a–b A 33-year-old patient with a distracted humeral midshaft fracture (12A3)

c The fracture was reduced and stabilized using the minimally invasive plate osteosynthesis manipulators combined with an external fixator rod. Insertion of the plate from proximal to distal using the epiperiostal surfer to pull the plate from proximal to distal.

d Lateral x-ray control of the reduction.

e–f Postoperative AP and lateral x-ray. Note the conventional screws close to the fracture as reduction screws and locking head screws at both plate ends. The fracture was fixed in slight distraction on the lateral side.

g–h The fracture was bridged by callus at the posteromedial cortex and the patient was fully weight bearing as a heavy manual worker 6 months after the operation.

Humeral midshaft fractures can be stabilized through an anterior approach using long, conventional narrow plates 3.5 or 4.5 according to the bone diameter. Because of the wide rotational excursion of the upper extremity, a long plate provides much more stable fixation than a short plate. Plate contouring is minimal in the distal part when using conventional screws and it is not necessary when using locking screws alone. The patient is preferably positioned in a supine position with an arm table in slight abduction to obtain a stable operative field. In the distal soft-tissue window, Hohmann retractors should not be used to avoid traction on the radial nerve. The long plate, spanning most of the length of the humerus, is then fixed with three screws in each fragment (**Fig 3.1.3-8**). Minimally invasive plate osteosynthesis of humeral shaft fracture has been shown to be a safe and reliable technique with similar results as conventional ORIF [21].

Patient selection: MIPO is a good indication for:
- Multifragmentary humeral shaft fractures extending proximally and distally
- Segmental fractures
- Small medullary canal, which does not allow nailing
- Shaft deformation due to earlier fracture
- Patients with open growth plates

Minimally invasive plate osteosynthesis is not recommended in delayed cases with significant shortening or in nonunions. Simple fractures are much more challenging to reduce and suboptimal reduction may lead to delayed healing or nonunion with implant failure and are better treated with anatomical reduction and compression plating to provide absolute stability.

5.3 Femur

5.3.1 Femur proximal

Principle: Many fixation devices are available for the treatment of proximal femoral fractures, eg, intramedullary and extramedullary implants. Extramedullary implants include the dynamic hip screw (DHS), the dynamic condylar screw (DCS), the 95° blade plate, the proximal femur locking compression plate (LCP-PF), and the reversed distal femur LCP (LCP-DF). According to the fracture pattern an intramedullary or an extramedullary implant may be preferred. Reduction is performed using a traction table in a supine position, or with the large femoral distractor or external fixator (**Fig 3.1.3-9**) when using a MIPO approach.

Patient selection: The role for MIPO in proximal femoral fractures is limited to:
- Trochanteric fractures with proximal extension involving the nail entry point
- Ipsilateral neck and complex shaft fractures not suitable for an intramedullary device
- Open subtrochanteric fractures

Open reduction and internal fixation in this region has been associated with a significant risk of nonunion and implant failure. Minimally invasive plate osteosynthesis has been shown to reduce the incidence of nonunion and the need for primary and secondary bone grafting [22].

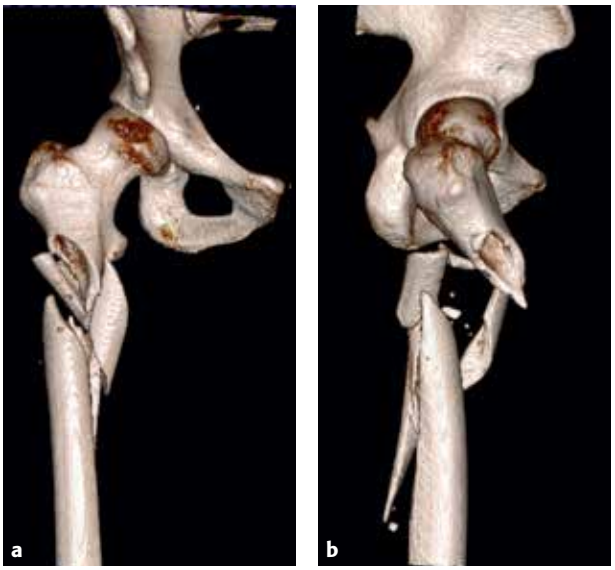

Fig 3.1.3-9a–h
a–b A 22-year-old polytrauma patient with a multifragmentary subtrochanteric fracture.

Fig 3.1.3-9a–h (**cont**)

c Damage-control surgery with external fixator.

d Through a proximal soft-tissue window the proximal fragment is reduced using a Schanz screw with a T-handle to neutralize the flexion forces of the iliopsoas muscle, an proximal femur locking compression plate was inserted and the proximal fragment was reduced using the collinear forceps against the LCP-PF.

e Intraoperative C-arm image with the proximal fragment reduced against the plate and temporary fixation with a K-wire and the collinear reduction clamp.

f Intraoperative clinical control for rotation. Length was controlled using the contralateral leg and the alignment is controlled by C-arm with the help of the cable method.

g–h X-ray control 1 year after trauma.

5.3.2 Femoral shaft

Principle: For MIPO of the femoral shaft, the broad dynamic compression plate (DCP), the low-contact dynamic compression plate (LC-DCP), or the LCP is available. The contoured LCP with antecurvature is helpful for MIPO fracture fixation due its sagittal bend. The patient is positioned on a radiolucent table with both legs draped free and a bump underneath the knee joint. There are two methods to achieve a stable operative field when performing MIPO of the femoral shaft.

- The plate is used as a reduction tool by proximal and distal temporary fixation in the center of the lateral cortex (**Fig 3.1.3-10**).
- The femoral shaft is reduced first using an external fixator or the large distractor before inserting and fixing the plate to the bone.

It is recommended to use at least three percutaneously inserted screws in the proximal and distal fragments. The plate length in multifragmentary fractures is usually 16–18 holes, whereas plates in simple fractures (which require anatomical reduction and absolute stability) have a length of 8–10 holes with a plate/screw density of 0.5.

Patient selection: Femoral shaft fractures (32B and 32C) are good indications for MIPO if:

- The femoral shaft is narrow or deformed.
- The pediatric patient has open physes.
- The medullary canal is occupied by an implant.
- General condition or associated fractures do not allow intramedullary nailing.

5.3.3 Femur distal

Principle: Several implants are specially designed for distal femoral fractures like the 95° blade plate, the distal femoral locking plate (LCP-DF), and the distal femoral nail. Intraarticular distal femoral fractures need absolute stability and are addressed first using a parapatellar approach to perform anatomical reduction of the joint surface. In extraarticular fractures, a soft-tissue window centred on the lateral femoral condyle is sufficient for plate insertion. However, the approach should be big enough to allow proper positioning of the implant. The patient is placed on a radiolucent table, with the contralateral leg draped free to compare length, alignment, and rotation after reduction of the joint block to the shaft. The reduction can be obtained by temporary fixation of the plate distally by using the plate as a reduction

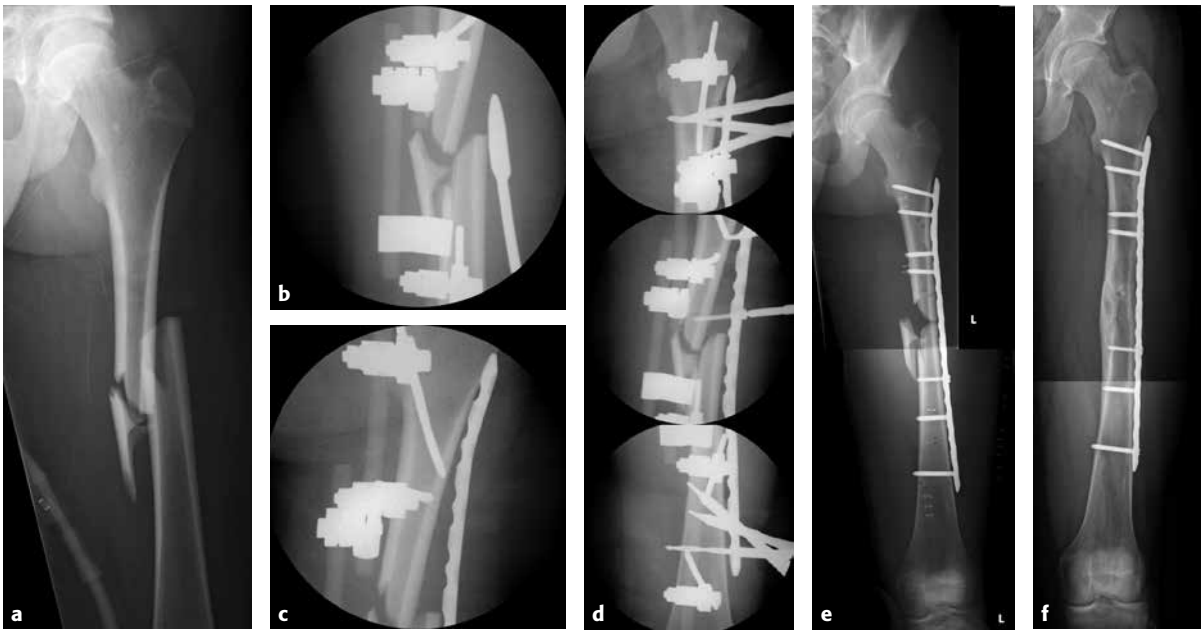

Fig. 3.1.3-10a–f

a A 17-year-old polytrauma patient with narrow femoral canal, damage-control surgery with external fixator.
b Remote from the fracture focus, a submuscular epiperisotal surfer was inserted and a submuscular tunnel was prepared.
c The plate was inserted and aligned with the fracture.
d The fracture was temporary fixed with drill bits through drill sleeves inserted in the threaded holes of the locking compression plate positioned in the center of the shaft. The intermediate fragment was reduced with a reduction screw.
e AP x-ray postoperative. Apart from the reduction screw, all other screws are locking head screws to maintain the reduction.
f AP x-ray after uneventful healing 1 year after the operation.

tool. Or the reduction can be maintained by reducing the joint block against the shaft with the help of the large femoral distractor, the external fixator, or by percutaneous clamping using a collinear clamp or a cerclage wire (**Fig 3.1.3-11**) before insertion and fixation of the plate.

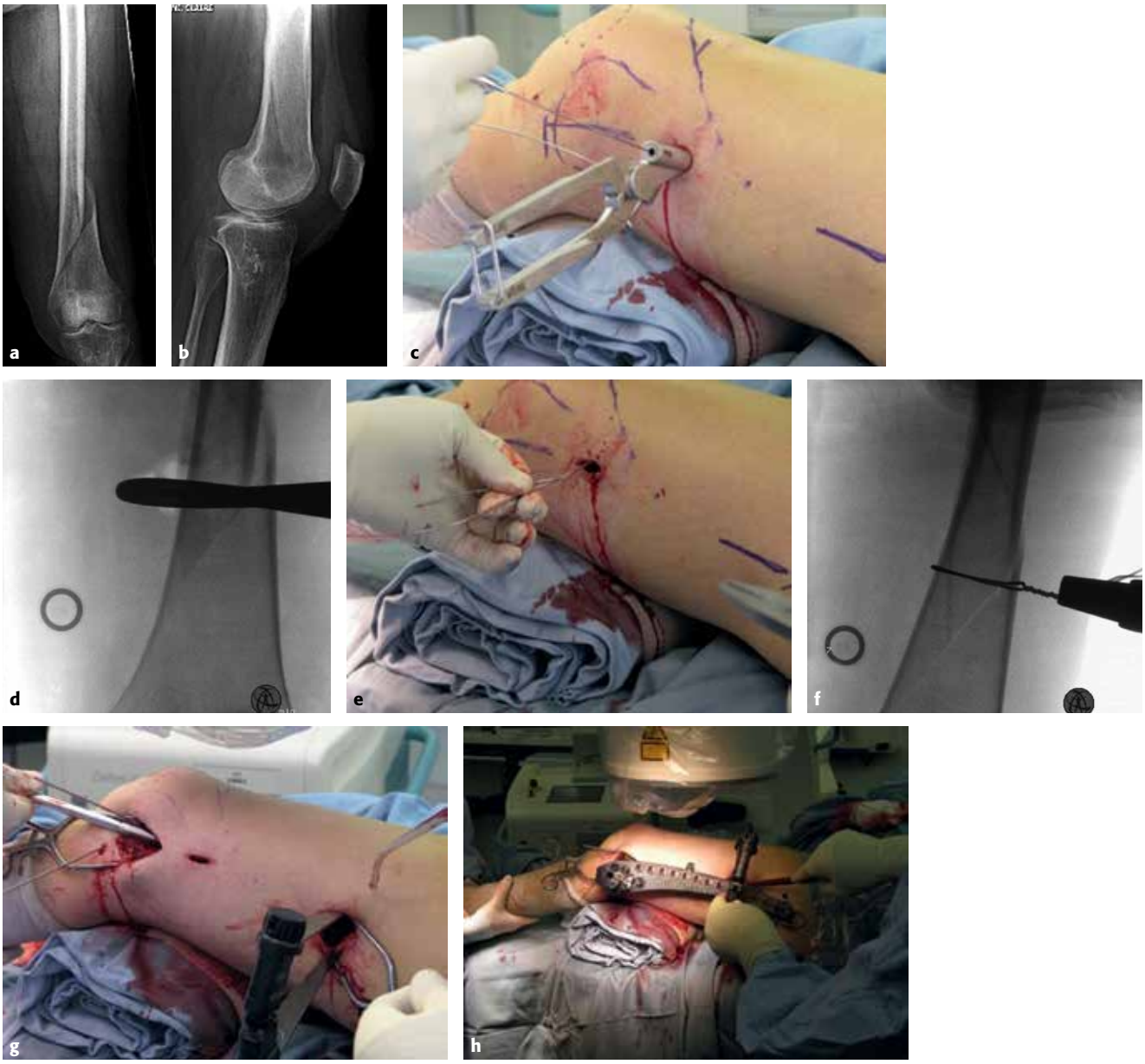

Fig. 3.1.3-11a–l
a–b A 56-year-old woman with an extraarticular spiral distal femoral fracture.
c Direct reduction of the spiral fracture with minimally invasive plate osteosynthesis (MIPO) wire passer (**Fig 3.1.1-17**).
d Intraoperative C-arm picture with wire passer in situ.
e After extraction of the wire passer instrument, the cerclage wires were ready to be tightened.
f Maintaining reduction of the shaft facture with the cerclage.
g Submuscular insertion of the MIPO epiperiosteal surfer tunneling instrument.
h Insertion and fixation of the less invasive stabilization system distal femur using the aiming arm.

Patient selection: All distal femoral fractures (33A and 33C) are suitable for MIO with distal femoral nails or MIPO. Complex 33C fractures are more reliably treated with LCP-DF after the articular surface is addressed.

5.4 Tibia

5.4.1 Tibia proximal

Principle: Proximal tibial fractures caused by high-energy trauma, with or without dislocation are challenging fractures to treat because the soft-tissue envelope around the knee joint is often severely injured. After the first assessment, the treatment in most of these fractures is the application of a spanning external fixator followed by computed tomographic (CT) (span and scan). The pins of the external fixator should be outside the zone of injury and potential implant position. According to the fracture pattern, two different fixation strategies are applied. In extraarticular (41A) and partial articular (41B) fractures, single column plating is sufficient. In bicondylar intraarticular fractures (41C), the application of single or double column plates depends upon the fracture pattern. In bicondylar fractures, a posteromedial approach buttressing the medial column is performed as a first step. The second step addresses the intraarticular fracture, before definitive fixation between the joint and the shaft takes place on the lateral side (to combine the articular block with the shaft). If there is a simple cortical fracture in the medial column, which can be reduced anatomically to a stable position, then lateral column fixation alone, using an LCP, may be sufficient. Different medial and posteromedial anatomical plates are available but conventional tubular plates 3.5 or LCPs 3.5 may be sufficient if buttress fixation alone provides stability. Depending upon the extension of the fracture into the proximal shaft, anatomical plates 3.5 or 4.5/5.0 (proximal tibial LCP) allow for safe stabilization (**Fig 3.1.3-12**).

Patient selection: High-energy proximal tibia fractures or low-energy fractures with soft tissue compromise profit from a soft tissue friendly MIPO approach (41A, 41B, 41C). In open fractures, the soft-tissue envelope should be reestablished after thorough debridement together with the MIPO technique or the osteosynthesis should be performed in a staged procedure after definitive soft-tissue cover [23].

Fig. 3.1.3-11a–l (**cont**)
i–j AP and lateral view of postoperative x-ray.
k–l X-ray control after 2 years.

Fig. 3.1.3-12a–h

a–c A 49-year-old patient with a closed bicondylar 41C3 tibial plateau fracture.

d After initial joint spanning external fixator and compartment release. The compartment release was closed before minimally invasive plate osteosynthesis fixation took place.

e Before a locking compression plate proximal tibia (LCP-PT) was inserted, the lateral plateau was reduced and additionally buttressed with rafting screws through a tubular plate 2.7.

f–g Postoperative AP and lateral x-rays with reduction plate on the medial side and AP reduction screws. Lateral buttressing of the lateral column with an LCP-PT and tubular raft plate 2.7 proximally.

h One year after surgery, fracture healing with good alignment.

5.4.2 Tibia shaft

Principle: MIPO for tibia midshaft fractures is the exception. Intramedullary nailing is the gold standard for the treatment of this bone segment. Straight DCP, LC-DCP, or LCP plates 5.0/4.5 are used for MIPO. Long plates with 12–16 holes are needed in multifragmentary fractures, extending proximal or distal. In this situation, additional bending to fit the proximal or distal flare is needed. Correct bending and twisting are of importance to keep correct alignment and rotation of the tibia to avoid reduction loss when using conventional screws. Plate position is chosen according to the fracture pattern, the soft-tissue condition, and at the discretion of the surgeon. Medial plating is easier but may cause hardware prominence leading to wound breakdown. This is more common in slim patients (with little subcutaneous fat) and in elderly patients with frail skin and impaired circulation. Plate insertion starts either proximal or distal through a soft-tissue window of 3–4 cm, close to the posteromedial border of the tibia. At the proximal metaphysis a transverse incision is often easier to use. Distally, the greater saphenous vein and the nerve have to be avoided. Reduction with the help of the plate (**Fig 3.1.3-13**) or preliminary reduction in simple fractures using percutaneous clamps or an external fixator before inserting the plate are the two strategies used. The contralateral leg, if draped free may serve as a template for length, alignment, and rotation. If a lateral plate position is chosen, soft-tissue cover is much better but plate application is more difficult and contouring the plate is more difficult as a twist is required. In the distal tibia, the soft-tissue window has to be large enough to avoid harm to the anterior tibia vessels and the deep peroneal nerve.

Patient selection: MIPO is only indicated for closed and first and second degree open tibial midshaft fractures if nailing is not possible due to:

- Fracture extension into the articular surface of the tibia
- Proximal and distal shaft fractures
- Some segmental fractures
- A small medullary canal
- A medullary canal blocked by an implant
- A periprosthetic fracture
- A deformed medullary canal
- Open growth plates

Fig. 3.1.3-13a–k
a–b A 51-year-old patient with a spiral fracture of the distal diaphysis (42A1). With fracture line extending into the tibial plafond.
c Medial percutaneous plate insertion.

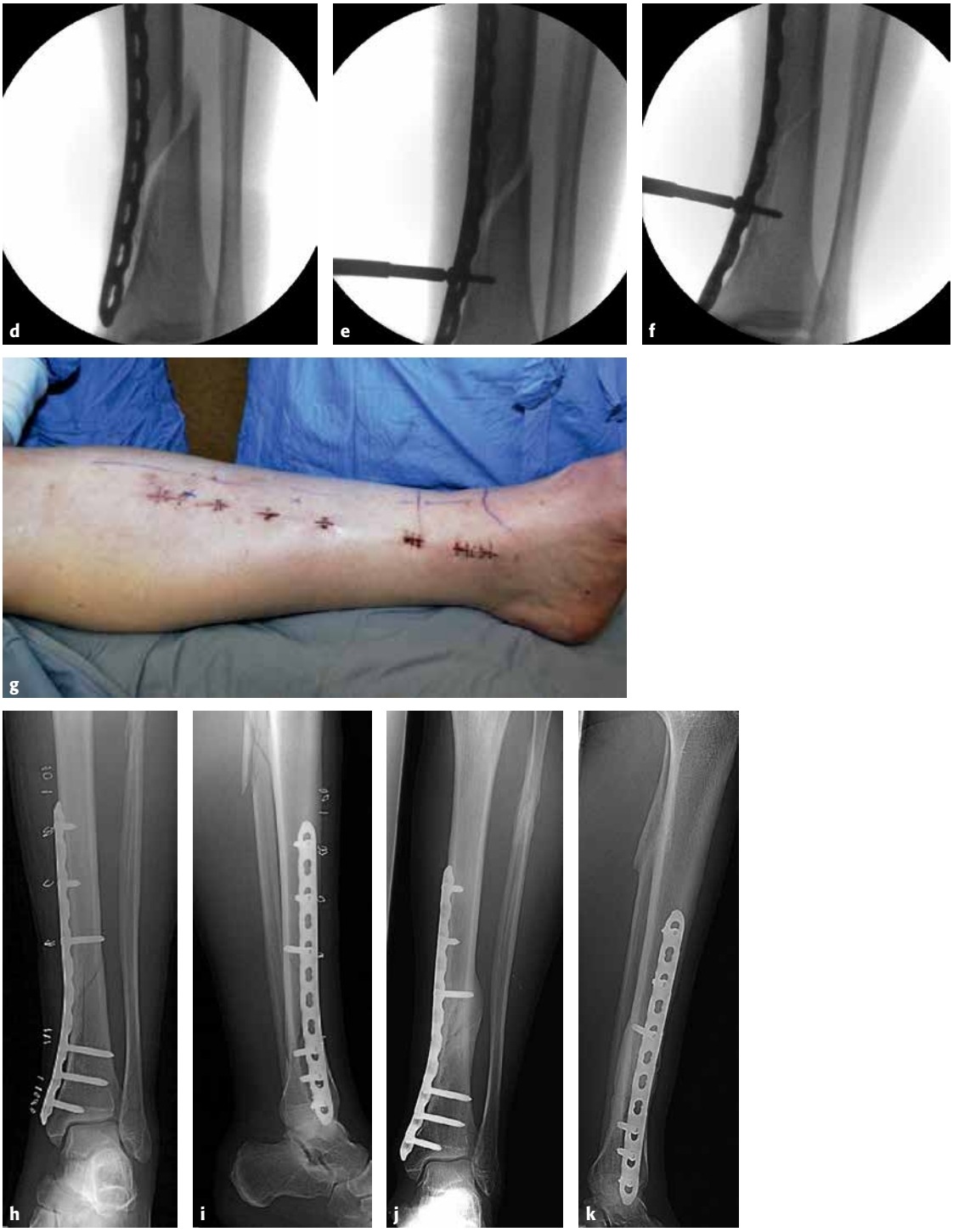

Fig. 3.1.3-13a–k (**cont**)

d Under traction, the displaced distal fragment was not aligned with the precontoured plate.
e Percutaneous insertion of a cortical screw as a reduction screw.
f After tightening the screw, the distal fragment was reduced against the plate.
g Closed skin incisions of the distal tibia.
h–i Postoperative AP and lateral x-ray. Note after proximal and distal fixation with locking head screw, the reduction screw was replaced by a LHS.
j–k AP and lateral view 1 year after fixation. Note the callus after applying bridge plate fixation.

5.4.3 Tibia distal intraarticular

Principle: In distal tibial fractures involving the joint and/or the metaphysis, the condition of the soft tissue plays a key role when considering MIPO procedures. Displaced fracture fragments should be reduced and the tibia aligned by immobilization in a well-padded splint or in an external fixator before CT scans (span and scan). In low-velocity injuries with extraarticular fractures that are not amenable to nailing, MIPO is a reliable and safe approach for all fracture patterns, especially C-type fractures [24]. Depending on the fracture pattern and the soft-tissue condition, a staged procedure is recommended, especially in high-velocity injuries. After swelling has subsided, the articular fracture is addressed from anteromedial (**Fig 3.1.3-14**), anterior, anterolateral, posterolateral or posteromedial or combinations of these approaches depending upon the fracture pattern. Incisions must be large enough to achieve an anatomical reduction of the joint and bone graft or substitute should be used to support the articular surface. Visualization and reduction of the joint is facilitated by using the large femoral distractor. According to the fracture pattern, plates are inserted from distal to proximal without stripping the periosteum and plate fixation on the shaft is achieved by percutaneous screw fixation.

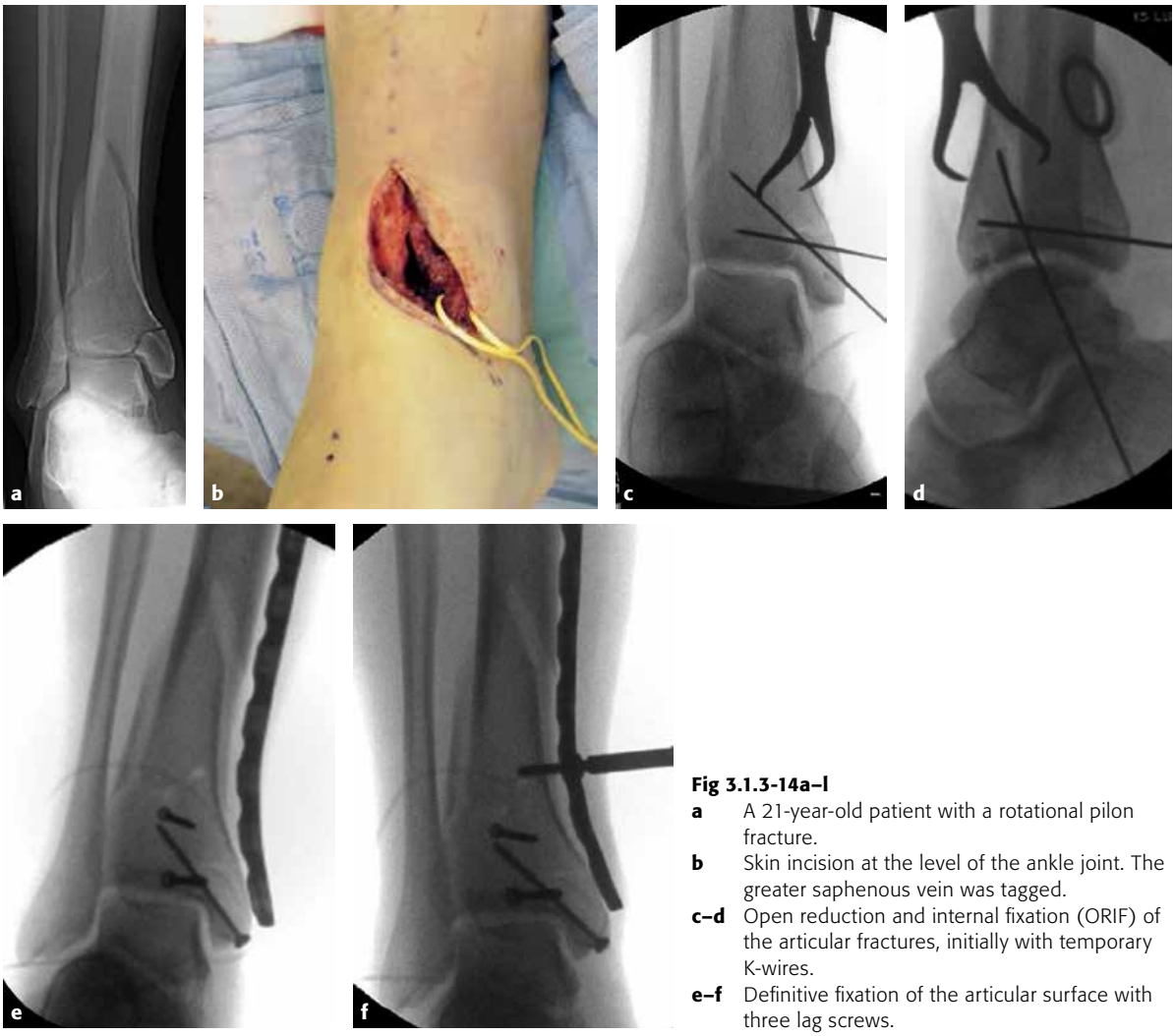

Fig 3.1.3-14a–l
a A 21-year-old patient with a rotational pilon fracture.
b Skin incision at the level of the ankle joint. The greater saphenous vein was tagged.
c–d Open reduction and internal fixation (ORIF) of the articular fractures, initially with temporary K-wires.
e–f Definitive fixation of the articular surface with three lag screws.

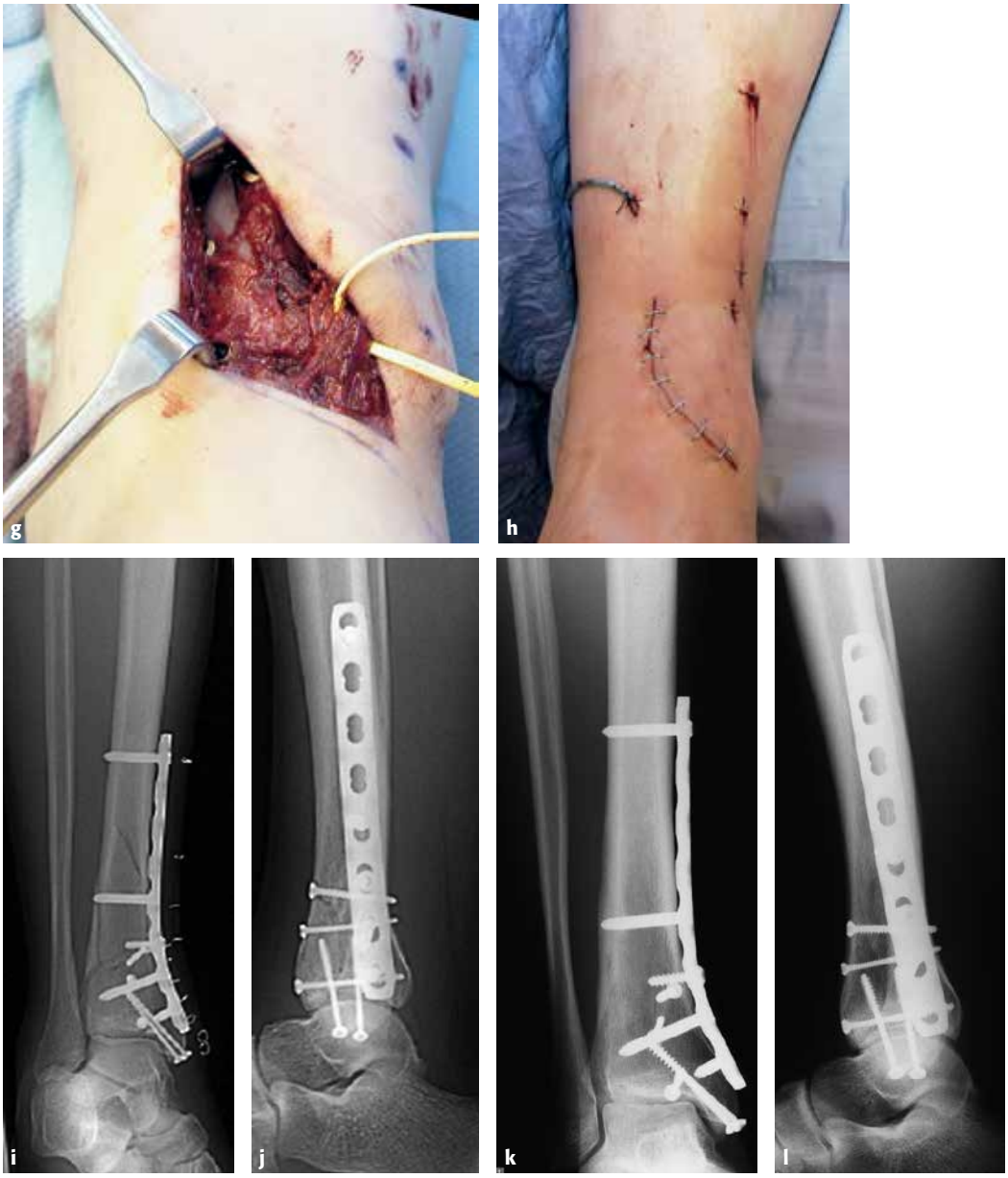

Fig 3.1.3-14a–l (**cont**)
g Distal tibia after open reduction internal fixation of the articular block and plate insertion.
h Stapled skin incision.
i–j Postoperative x-rays.
k–l AP and lateral view 1 year after the operation. The fracture healed with no signs of ankle arthrosis.

Patient selection: Extraarticular fractures (43A) which are not amenable to new antegrade nail designs are good indications for MIPO, as well as tibia plafond fractures with fracture extensions into the shaft. Simple fracture patterns (43A1, 43A2, and 43A3) require anatomical reduction and fixation with absolute stability while bridge-plate fixation and relative stability is used for multifragmentary fractures (43B and 43C). Several anatomical low profile plates are available (anterolateral tibial plate 3.5, LCP 3.5, metaphyseal plate 3.5/2.7, distal tibial T-plate 3.5/4.5/5.0, 3.5) to treat these fractures by buttressing the joint block from the anterolateral, posterior, or anteromedial sides. The requirement and sequence of fibular fixation depends on its fracture pattern and the fracture pattern of the distal tibia. Anatomical reduction of the fibula helps in most situations to achieve correct length and position of the attached posterolateral tibia plafond and adds to the stability. The mortise must always be checked for stability once alignment is assured.

6 Complications

The principle of minimally invasive surgery is to reduce operative trauma from surgical approaches and at the fracture site.

Short skin incisions are not the goal of MIO surgery, as they may result in significant traction to the underlying soft tissue and the skin.

This may provoke soft-tissue necrosis and secondary infection. Apart from gentle soft-tissue handling, MIO/MIPO surgery requires meticulous preoperative planning and correct positioning of the patient and image intensifier to allow for indirect reduction techniques.

Skin break down

Skin breakdown, with or without infection, may occur when too much tension has been applied to the soft tissue with retractors or with sutures. It may also be caused by prominent plates causing pressure necrosis. This can be a particular problem in some sites, such as the medial border of the tibia, if locking screws alone are used as these allow the plate to stand proud of the bone.

Deep infection

Compared with conventional open procedures, infection rates after MIO have been reported to be lower, even in cases of open fractures [4]. But disproportionate traction on skin and soft tissue as well as repetitive insertion and removal of the plate may cause a deep infection. Minimally invasive surgery is not necessarily minimal infection surgery.

Malunion

Indirect reductions of the fracture site and the reduced diameter of the C-arm image are inherent risks for creating a malunion. Intraoperative assessment of length, alignment, and rotation under stable conditions is important. Maintenance of the achieved reduction with adjuncts like the inserted and temporarily fixed plate, an external fixator, a large femoral distractor or a traction table are as important as using the contralateral uninjured leg as a template in the lower extremity.

The learning curve for MIPO procedures is steep and elevated rates of malunion are reported for MIPO surgery [7, 12]. Locking plates and anatomically preshaped plates have decreased the learning curve. However, the surgeon cannot solely rely upon precontoured plates for reduction because there is variation in normal anatomy.

Delayed union/nonunion

Nonunion is uncommon following MIPO, provided the principles of internal fixation are followed. In high-velocity fractures, the necessity for secondary bone graft is between 2.5% and 7% [12, 22, 23]. Secondary bone grafting is advised when no callus formation is visible after 6–8 weeks. Simple fractures, when treated with a bridge plate, are at risk of delayed healing because gap-healing is required and fatigue failure of the plate may occur before the fracture heals. Anatomical reduction and fracture fixation with absolute stability using compression is recommended for simple (type A) fracture patterns.

Implant failure

Plate breakage after MIPO has been observed in cases of delayed union. This may be due to distraction with a fracture gap > 2 mm, high-energy impact with soft-tissue injury and devascularization of the bone fragments or failure to achieve absolute stability in a simple fracture pattern. Screw placement too close to a fracture gap when providing a bridge plate concept will also lead to implant failure, as lack of relative stability will prevent callus formation: gap healing is slow in this situation of "too much stability" with subsequent fatigue failure of the implant (**Fig/Animation 3.1.3-15**). When using locking screws the plate has to be placed on the center of the shaft to obtain enough screw purchase to achieve the planned stability of the implant (**Fig 3.1.3-16**).

7 Implant removal

Implant removal after MIO may be more difficult than implant insertion. As swelling subsides, incisions are often not in their original position relative to a screw. Patients should be warned that a larger incision may be needed to remove the implants. Special instruments and drill bits should be available when performing implant removal. This may facilitate hardware removal, especially when LHS are jammed in the plate because of poor insertion technique or bone ingrowth onto titanium implants [9].

8 Education in MIO and how to start

Minimally invasive plate osteosynthesis surgery is a form of minimal access osteosynthesis. Minimal invasiveness is not defined by the lengths of the incision but more by the reduction technique under the conditions of limited visual control. This technique is more demanding. The principles of internal fixation using plates and the application of other MIO procedures, such as external fixators and intramedullary nailing, should be well known to the surgeon. Minimally invasive plate osteosynthesis should not be performed by inexperienced trauma surgeons. Open procedures should be the first step for the learning surgeon who then can proceed to more difficult MIPO cases as they arise.

9 Conclusion

Technology for fracture fixation has rapidly evolved in recent years. Specific instruments for percutaneous fracture reduction and numerous plates for many anatomical regions with locking head screws have facilitated MIPO surgery. The soft-tissue preserving goal of this surgery is appealing and has helped spread this novel technique. However, this technique is demanding and needs a step-by-step approach with critical case analysis, proper preoperative planning, creation of a stable operative field, and C-arm visualization of the achieved reduction before definitive fixation. The biomechanical principles of plate osteosynthesis are identical and should not be compromised using this technique. The goals of surgery remain the same.

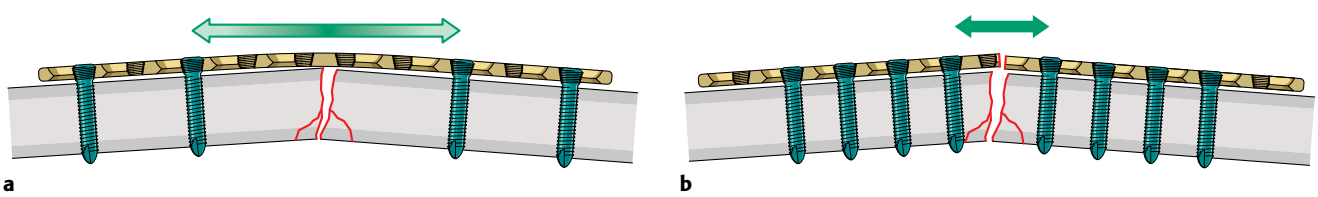

Fig/Animation 3.1.3-15a–b Stress distribution. Influence of screw fixation on forces within the plate.

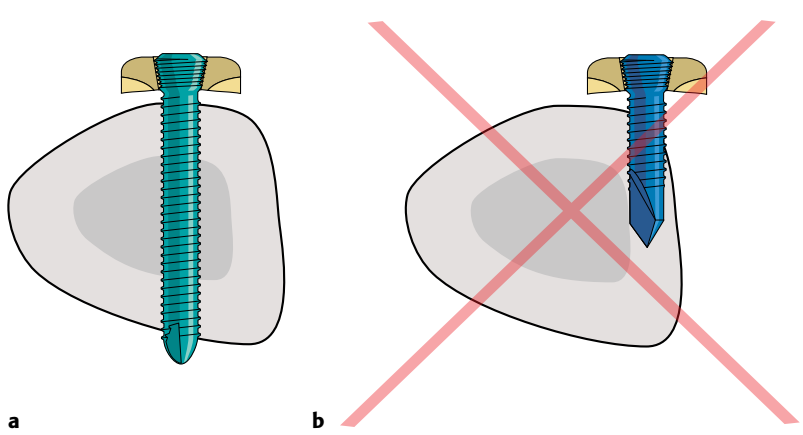

Fig 3.1.3-16a–b Plate position has to be centered on the shaft to avoid tangential screw placement, which is associated with loss of fixation.

Classic references | Review references

10 References

1. **Mast J, Jakob R, Ganz R.** *Planning and Reduction Technique in Fracture Surgery.* 1st ed. Berlin Heidelberg: Springer Verlag; 1989.
2. **Krettek C, Schandelmaier P, Tscherne H.** [Distal femoral fractures. Transarticular reconstruction, percutaneous plate osteosynthesis and retrograde nailing.] *Unfallchirurg.* 1996 Jan;99(1):2–10. German.
3. **Frigg R.** Development of the locking compression plate. *Injury.* 2003 Nov;34 Suppl 2:B6–10.
4. **Babst R, Bavonratanavech S, Pesantez R.** *Minimally Invasive Plate Osteosynthesis (MIPO). 2nd ed.* Stuttgart: Thieme Verlag; 2012.
5. **Babst R, Hehli M, Regazzoni P.** [LISS tractor. Combination of the "less invasive stabilization system" (LISS) with the AO distractor for distal femur and proximal tibial fractures.] *Unfallchirurg.* 2001 Jun;104(6):530–535. German.
6. **Perren SM, Fernandez dell'Orca F, Regazzoni P et al.** New aspects of cerclage: improved technology applicable to MIO with special reference to periprosthetic fractures. In: *Minimally Invasive Plate Osteosynthesis.* 2nd ed. Stuttgart: Thieme Verlag; 2012.
7. **Buckley R, Mohanty K, Malish D et al.** Lower limb malrotation following MIPO technique of distal femoral and proximal tibial fractures. *Injury.* 2011 Feb;42(2):194–199.
8. **Gautier E, Sommer C.** Guidelines for the clinical application of the LCP. *Injury.* 2003;34 Suppl 2:63–76.
9. **Georgiadis GM, Gove NK, Smith AD, et al.** Removal of the less invasive stabilization system. *J Orthop Trauma.* 2004 Sep;18(8):562–564.
10. **Hasenboeler E, Rikli D, Babst R.** Locking compression plate with minimally invasive plate osteosynthesis in diaphyseal and distal tibial fractures: a retrospective study of 32 patients. *Injury.* 2007 Mar;38(3):365–370.
11. **Livani B, Belangero WD.** Bridging plate osteosynthesis of humeral shaft fractures. *Injury.* 2004 Jun;35(6):587–595.
12. **Zlowodzki M, Bhandari M, Marek DJ, et al.** Operative treatment of acute distal femur fractures: systematic review of 2 comparative techniques and 45 case series (1989 to 2005). *J Orthop Trauma.* 2006 May;20(5):366–371.
13. **Livani B, Belangero WD, Castro De Medeiros R.** Fractures of the distal third of the humerus with palsy of the radial nerve: management using minimally invasive percutaneous plate osteosynthesis. *J Bone Joint Surg Br.* 2006 Dec;88(12):1625–1628.
14. **Gauger EM, Cole PA.** Surgical technique: a minimally invasive approach to scapula neck and body fractures. *Clin Orthop Relat Res.* 2011;469(12):3390–3399.
15. **Routt ML Jr, Nork SE, Mills WJ.** Percutaneous fixation of pelvic ring disruptions. *Clin Orthop Relat Res.* 2000 Jun;(375):15–29.
16. **Rammelt S, Amlang M, Barthel A, et al.** Percutaneous treatment of less severe intraarticular calcaneal fractures. *Clin Orthop Relat Res.* 2010 Apr;468(4):983–990.
17. **Oh CW, Song HR, Kim JW, et al.** Deformity correction with submuscular plating technique in children. *J Pediatric Orthop B.* 2010 Jan;19(1): 47–54.
18. **Oh CW, Song HR, Kim JW.** Limb lengthening with a submuscular locking plate. *J Bone Joint Surg Br.* 2009 Oct;91(10):1394–1399.
19. **Sohn HS, Kim WJ, Shon MS.** Comparison between open plating versus minimally invasive plate osteosynthesis for acute displaced clavicular shaft fractures. *Injury.* 2015 Aug;46(8):1577–1584.
20. **Lin T, Xiao B, Ma X, et al.** Minimally invasive plate osteosynthesis with a locking compression plate is superior to open reduction and internal fixation in the management of the proximal humerus fractures. *BMC Musculoskelet Disord.* 2014;15:206:1–7.
21. **Kim JW, Oh CW, Byun YS, et al.** A prospective randomized study of operative treatment for noncomminuted humeral shaft fractures: conventional open plating versus minimal invasive plate osteosynthesis. *J Orthop Trauma;* 2015 Apr;29(4):189–194.
22. **Oh CW, Kim JJ, Byun YS, et al.** Minimally invasive plate osteosynthesis of subtrochanteric femur fractures with a locking plate: a prospective series of 20 fractures. *Arch Orthop Trauma Surg.* 2009 Dec;129(12):1659–1665.
23. **Kim JW, Oh CW, Jung WJ, et al.** Minimally invasive plate osteosynthesis for open fractures of the proximal tibia. *Clin Orthop Surg.* 2012 Dec;4(4):313–320.
24. **Zou J, Zhang W, Zhang CQ.** Comparison of minimally invasive percutaneous plate osteosynthesis with open reduction and internal fixation for treatment of extra-articular distal tibia fractures. *Injury.* 2013 Aug;44(8):1102–1106.

11 Acknowledgments

We thank Kok-Sun Khong for his contributions to the second edition of the *AO Principles of Fracture Management*.

3.2.1 Screws

Wa'el Taha

1 Design and function

1.1 What is a screw?

A screw is a powerful mechanical device that converts rotation into linear motion.

Most screws used for fracture fixation share several design features (**Fig 3.2.1-1**):

- Central core that provides strength
- Thread that engages the bone and converts rotation into linear motion
- Tip that may be blunt or sharp
- Head that engages either the bone or the plate
- Recess to attach a screwdriver

Screws come in different shapes and sizes and their names are based upon a number of factors (**Fig 3.2.1-2**):

- Design (eg, cannulated, locking head)
- Dimension (eg, 4.5 mm)
- Characteristics (eg, self-tapping, self-drilling)
- Area of application (cortex, cancellous, monocortical, or bicortical)
- Function or mechanism

Since the introduction of locking head screws (LHS), all other types of screws are referred to as "conventional" screws. A screw can be applied to compress a fracture surface (lag screw), fix a plate to the bone by producing compression between the plate and the bone (plate screw), or it may be used to fix an external fixator (Schanz screw) or internal fixator (locking head screw) to the bone. A position screw holds two fragments together without compression. Lag screws can be inserted through a plate or independently. The term lag screw does not describe screw design but refers to the function of compressing two fragments together.

Rotation of a screw is converted in to linear motion by screw threads. As the screw advances, the head is pressed against the bone cortex and further advancement of the screw compresses the head against the cortex, creating a preload. This preload compresses the fracture and prevents separation, while friction between the fracture surfaces and between the screw and the bone opposes displacement by shear. Lag screws are used to achieve absolute stability. In contrast, LHS have a head with a thread that matches a reciprocal thread in the hole of the plate (**Fig/Animation 3.2.1-3**). As it advances, it forms a mechanical couple with the plate that does not rely on compression between the two elements. This produces angular stability and the plate is not pressed against the bone. The load transfer of this construction occurs via the plate, not by preload and friction. This is the same principle as that of an external fixator and the stabilizing effect of LHS and Schanz screws is based on their bending stiffness plus the mechanical couple to the plate or the external fixator frame.

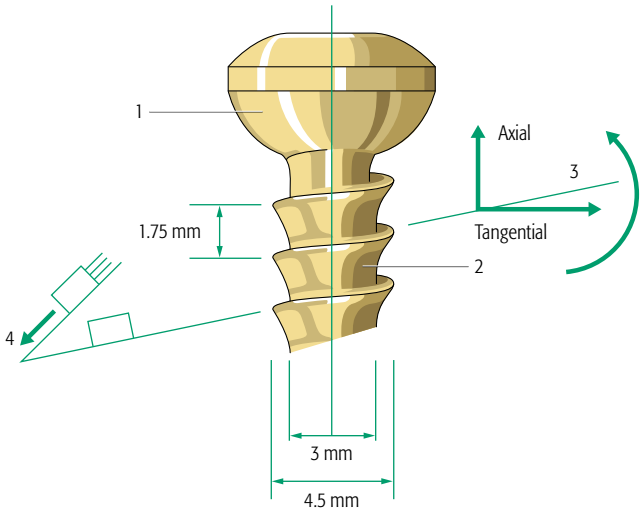

Fig 3.2.1-1 A conventional cortex screw, as used in diaphyseal bone. The underside (1) of the screw head is spherical, allowing a congruous fit to be maintained while tilting the screw, eg, within a plate hole. The thread (2) is asymmetrical with the pitch of 1.75 mm. The dimensions shown are designed to offer a good relation between axial forces and torque applied (3), and these dimensions result in an inclination of the thread which is self-locking (4). The screw corresponds to the ISO standard 5835. In this example of a screw, 3 mm demonstrates the "core" diameter of the screw and 4.5 mm demonstrates the "thread" diameter of the screw.

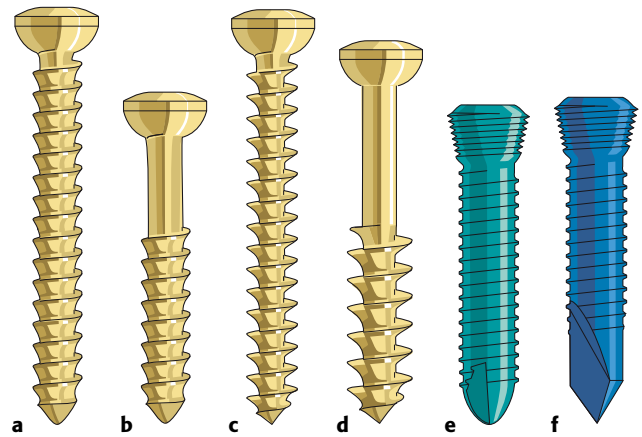

Fig 3.2.1-2a–f The types and functions of screws differ, however all screws have a head that has a recess for the screwdriver attachments. The core diameter of the screw corresponds to the size of the drill bit used to create a tract for the screw. The thread diameter of the screw corresponds to the screw size, ie, 3.5 mm or 4.5 mm. The tip of the screw can be rounded or pointed depending upon whether it is self-tapping or non self-tapping in function. The pitch (distance between the thread) of the screw differs according to the screw being cortical or cancellous or locking in nature.

a Cortex screw.
b Partially threaded cortex screw.
c Cancellous bone screw.
d Partially threaded cancellous bone screw.
e Locking head screw.
f Self-tapping/self-drilling locking head screw.

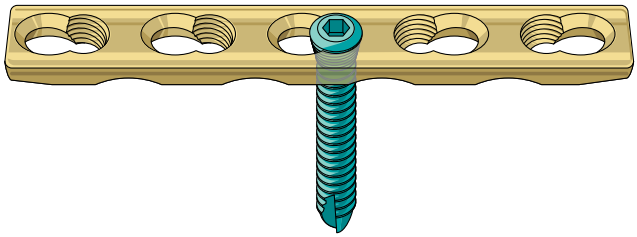

Fig/Animation 3.2.1-3 The threaded screw head locks within the reciprocal threads of the locking compression plate (LCP). The combination hole allows for insertion of a conventional screw as an alternative.

A screw is an efficient tool for the fixation of a fracture by interfragmentary compression or for fixing a splint, such as a plate, intramedullary nail or fixator, to the bone.

1.2 Biomechanics

The axial force produced by a screw (**Fig 3.2.1-4a**) results from rotating it clockwise, whereby the inclined surface of its thread glides along a corresponding surface of the bone. The inclination of the thread—the pitch—must be small enough to provide purchase of the screw in bone, ie, to prevent the screw from unwinding and becoming loose (**Fig 3.2.1-1**) and the pitch must be large enough to allow full insertion with an acceptably low number of revolutions [1].

Turning the screw within bone creates friction, which in turn generates heat. Screw design and the method of insertion will have a major influence on the amount of heat generated. This heat has the potential to cause thermal necrosis of bone with subsequent loosening of the screw and must be avoided. Thermal necrosis can also be caused by blunt drill bits or by inserting large diameter (> 2 mm) wires and pins into cortical bone without appropriate predrilling. It is the surgeon's responsibility to avoid this.

Two forces are active, one along the circumference of the screw thread (tangential), the other along the axis of the screw (axial). The first results from the torque of insertion. The second results from the displacement along the inclined surface between screw thread and bone thread, which produces axial tension. At the same time, the axial force acting upon the inclined surface produces torque, which tries to unwind the screw. This force increases with the inclination. As the friction remains constant, the range of angle of inclination that can be used is limited.

The torque applied to a conventional 4.5 mm cortex screw during tightening is divided into three components:

- 50% is used to overcome friction at the screw head interface
- 40% is transformed into axial force
- 10% overcomes the friction of the thread

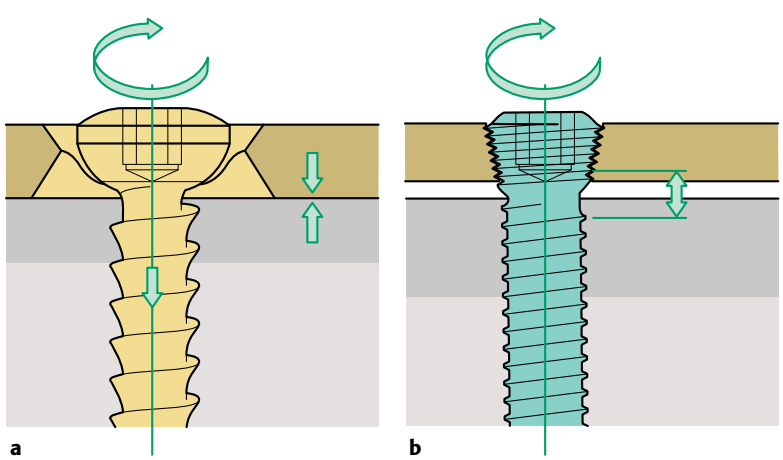

Fig 3.2.1-4a–b Conventional and locking head screws.

a This shows the design and force components of a conventional screw as used for the dynamic compression plate (DCP) and limited-contact DCP (LC-DCP). The screw acts by producing friction between the underside of the plate and the bone surface due to compression of the interface.

b Locking head screws as used in the less invasive stabilization system (LISS) and locking compression plate (LCP). They work more like bolts than screws; the axial force produced by the screw is minimal. The screw provides fixation based on the fact that the screw head is locked in a position perpendicular to the body of the plate that is not pressed against the bone. Such systems act like fixators rather than as plates.

Thus, during bench testing, a screw inserted through a plate hole can be tightened to nearly twice the torque that an isolated screw can. The reason for this is that the cortex under the head of an isolated screw is more likely to fail because of concentrating the force from the screw head to a small contact area on the bone. In cortical bone, the countersink can be used to increase the area of contact between the head of the screw and the cortex. This reduces contact stress and the risk of local microfracture beneath the screw head, especially if the screw is inclined (**Fig 3.2.1-5**). The relation between torque applied and axial force induced is about 670 N/Nm for a conventional 4.5 mm cortex screw. In LHS, once the screw head engages within the plate hole, practically all torque is used for locking, and the torque applied to the screw thread is minimal. The screw thread is, therefore, protected, as it will only withstand functional forces without preload. This explains the observation that in a closely monitored clinical series of more than 2,000 inserted titanium LHS not one failure occurred [1]. However, if a surgeon applies uncontrolled torque during tightening, something will have to give way. This could be the connection to the drive where, at higher torque, the hexagonal recess may strip, especially if a worn-out screwdriver is used.

It is important that the surgeon checks the quality of the screwdriver tip regularly before use.

The compression applied by a screw affects a comparatively small area of the surrounding bone. Therefore, a single screw compressing an oblique fracture does not effectively counteract rotation of the bone fragments around the axis of that screw. The area of the compression induced around the screw is small. This is of importance with respect to torque acting upon smooth osteotomy surfaces: a single screw applied to a surface does not provide much resistance against torque between the two fragments. Such situations require a second screw placed well apart from the first one and, if possible, in a different direction. The leverage then corresponds to the distance between the screws plus twice the leverage of the single screw (**Fig 3.2.1-6**).

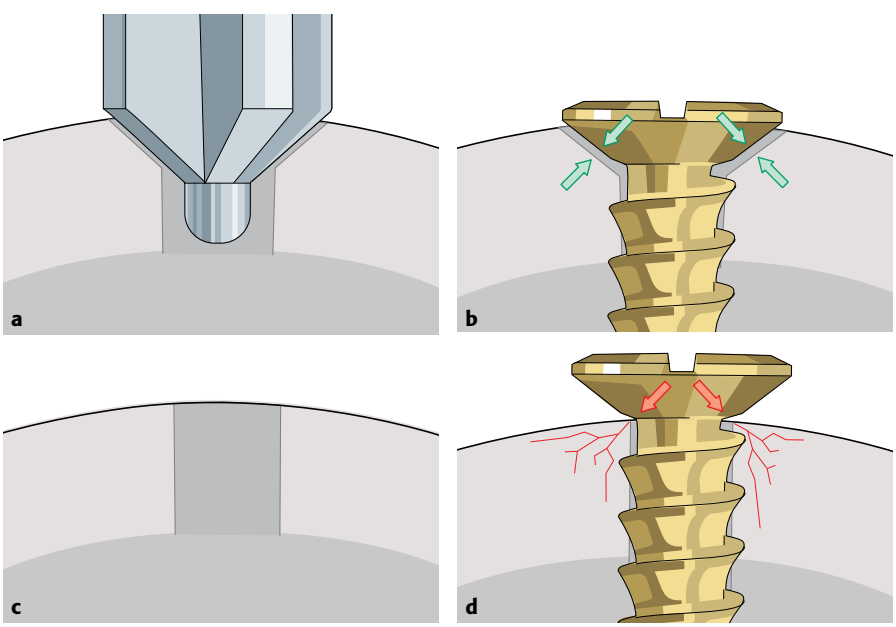

Fig 3.2.1-5a–d The countersink device is used to prepare the bone to receive the head of the screw so that the contact area between the screw head and the bone is increased (**a–b**). Without countersinking, forces would concentrate at a small area (**c–d**).

1.3 Screw thread

There are three types of screw threads used for the AO technique:

- The cortex screw thread is designed for application in diaphyseal bone and is available in different sizes.
- The cancellous bone screws have a deeper thread, a larger pitch, and a larger outer diameter than the cortex screws. Their applications are in metaphyseal or epiphyseal cancellous bone.
- The LHS used with the locking compression plate (LCP) (**Fig 3.2.1-4b**) are characterized by a larger core diameter and a comparatively shallow thread with blunt edges. These result in increased strength and a larger interface between screw and bone compared with conventional screws [2]. The head of the screw is also threaded. The shallow profile of the thread demands precise insertion technique with the power drive to prevent toggling that will result in a reduction of purchase at the screw thread – bone interface [3]. The advantages and hazards of the LHS are described in detail in chapters 3.3.2 and 3.3.4.

When inserting LHS, the last revolutions must always be done by hand using a torque-limiting screwdriver.

1.4 Screw tip

Different designs are available for the tip of the screw, and these include:

- Smooth, conical tips for insertion into a tapped drill hole
- Self-tapping, which will cut a channel for the thread
- Self-tapping/self-drilling, which will cut a drill hole and channel for the thread

A tap is an instrument that cuts a channel for the thread of a screw. The original, smooth, conical-tipped screws were designed for insertion after the drill hole had been tapped. Tapping may reduce the pull-out strength of screws because inadvertent toggling of the tap causes the hole to be enlarged to a size greater than actually needed. In osteoporotic and cancellous bone it is often better to avoid using a tap or to use a tap for just the near cortex to allow engagement of the screw. Tapping using the power drive reduces toggle but deep penetration can be more difficult to control and is dangerous.

In dense cortical bone the flutes of the screw may clog and a tap must be used. In this situation, it is important that the tap is reversed one half turn for every three or four complete

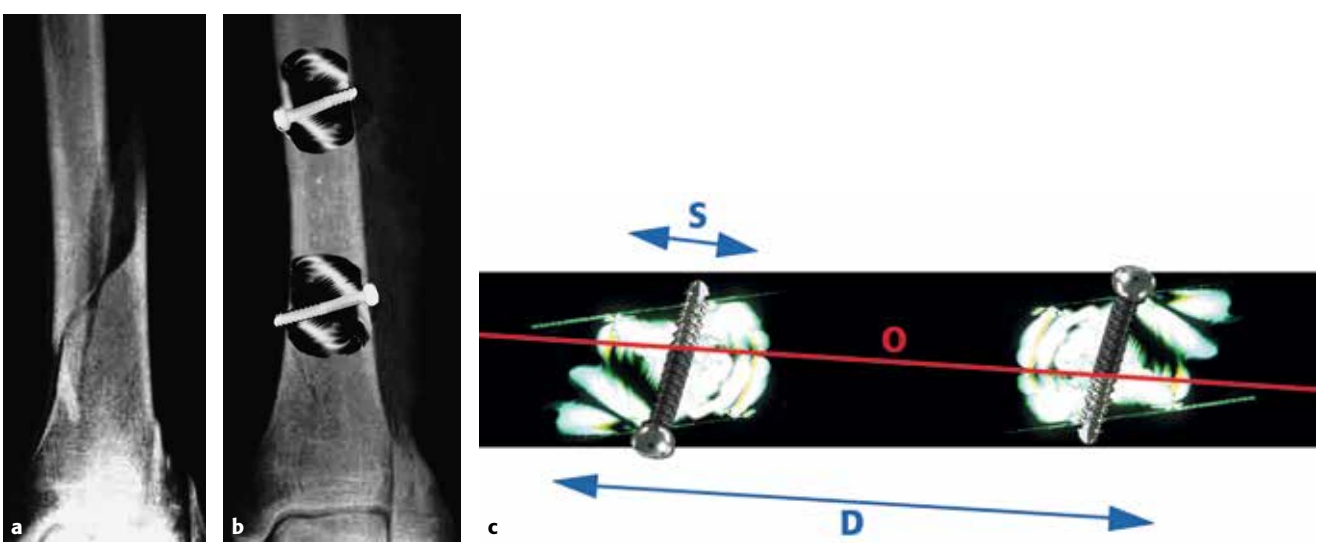

Fig 3.2.1-6a–c The different effects of using one or two lag screws for stabilization against torque in pure lag screw fixation.

a Model of a spiral fracture in a diaphysis.

b Fixation of the fracture using two lag screws. The extent of interfragmentary compression around a lag screw is demonstrated by a photoelastic experiment. The photoelastic pictures are superimposed on the x-ray to give a rough idea of the distribution of compression.

c In this figure the area of compression around a lag screw, as obtained from a photoelastic experiment, has been inserted into a schematic drawing of a long oblique osteotomy to explain the different effect of one lag screw alone (S) compared with the effect of two well-spaced lag screws (D).

S Lever arm of a single lag screw.
D Lever arm of double lag screws.
O Osteotomy.

This schematic diagram shows that whenever lag screws are used alone, there should be at least two well-spaced screws.

turns forward. This clears bone debris into the channel in the tap to reduce friction and prevent jamming that may result in the tap breaking.

Self-tapping screws have several advantages, including ease and speed of application [4]. However, it is still necessary to use a tap in hard cortical bone in young adults. This is particularly important for the smaller screw sizes (3.5 and 2.7 mm) as the screw heads may break if high torque is used to insert the screw without tapping.

Self-tapping screws must be accurately inserted without toggling and may be difficult to use during minimally invasive plate osteosynthesis techniques as soft-tissue tension may cause misdirection of the screw. The cutting flutes reduce the amount of contact between screw and the bony cortex. This may reduce the pull-out strength of the screw. This is more pronounced in small diameter bones like the forearm. Therefore, when inserting self-tapping screws it is recommended that the screw chosen should be 2 mm longer than the actual measured length to maximize the pull-out strength (**Fig 3.2.1-7**) [5].

Removal of self-tapping screws may be difficult when the cutting flutes are filled by bony ingrowth, or if the friction between screw and bone surfaces is high.

To avoid problems with screw removal the surgeon should try to disengage bone in the flutes by first slightly tightening the screw, thereby shearing off the ingrown bone from the cutting flutes. Thus, the first turn should be clockwise followed by anticlockwise removal of the screw.

The obvious advantage of using self-drilling screws is their ease of application. However, this is offset by the fact that advancement of the drill bit and of the thread must be compatible and synchronous. Many self-drilling screws fail to offer good purchase because the pitch of their thread requires rapid progression of the drill-bit tip of the screw, which often cannot be achieved. A further disadvantage of self-drilling screws is that measurement of the proper screw length is not possible.

Therefore, most self-drilling screws are also cannulated screws. A guide wire is used first to predetermine the direction of the screw and to help with measurement. The self-drilling screw is then introduced and inserted over the guide wire, which is subsequently removed once the screw is in the desired place.

The use of bicortical, self-drilling screws with a long, sharp protruding tip that may damage nerves, vessels, or tendons is not recommended.

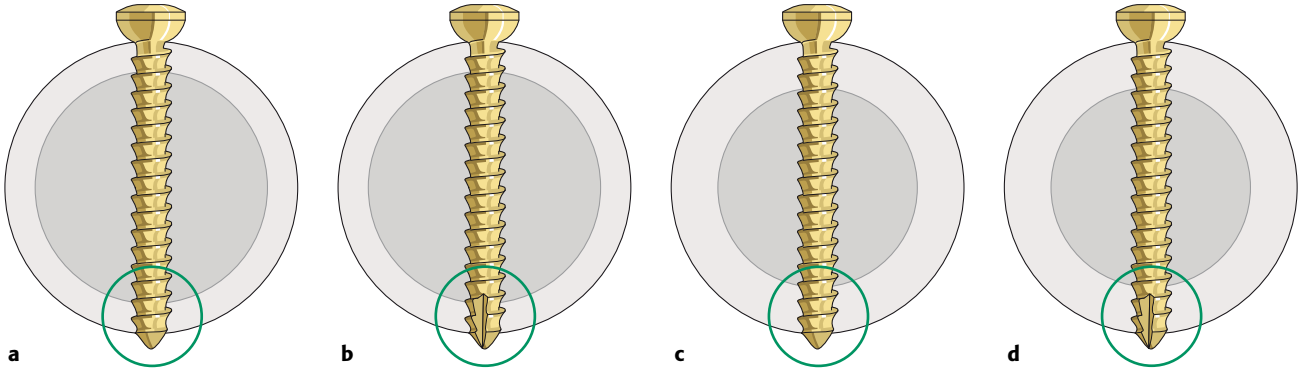

Fig 3.2.1-7a–d Self-tapping screws.
a–b When using self-tapping screws in bones with a thin cortex, it is essential to make sure that the tapping flutes pass the cortex to increase the pullout strength of the screw.
c–d In thick cortical bone, the pullout strength may not be affected significantly when a proper size self-tapping screw is used in comparison to a nonself-tapping screw.

The use of self-drilling/self-tapping monocortical LHS has been associated with failure of the screw. Therefore, the screw should be advanced until it engages on the far cortex without protruding out (**Fig 3.2.1-8**).

1.5 Screw function

A screw can be used to perform different functions depending upon the surgical plan **Table 3.2.1-1**

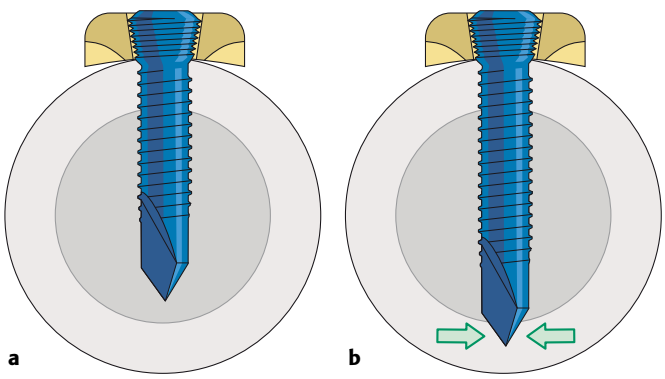

Fig 3.2.1-8a–b Self-drilling screws.
If the screw is introduced only a short distance inside the bone, there is risk of loosening of the screw with increased loads (**a**). When using these screws, it is noted that the tip is sharp and it can injure soft tissue beyond the cortex if it protrudes through the far cortex. This screw type should only be introduced deep enough to engage into the far cortex (**b**).

2 The lag screw

2.1 Interfragmentary compression

2.1.1 Application of a fully threaded screw as a lag screw

A fully threaded screw can be used as a lag screw, provided that the thread does not engage the cortex close to the screw head (near cortex).

Function		Clinical example
Name	**Mechanism**	
Plate screw	Preload and friction is applied to create force between the plate and the bone	Forearm LC-DCP
Lag screw	The glide hole allows compression between bone fragments	Fixation of a butterfly or wedge fragment or medial malleolus fracture
Position screw	Holds anatomical parts in correct relation to each other without compression, ie, thread hole only, no glide hole	Type C malleolar fracture (diastasis screw) or type C articular fracture with defect of distal humerus
Locking head screw	Used exclusively with LCP/LISS; threads in the screw head allow mechanical coupling to a reciprocal thread in the plate and provide angular stability	LCP/LISS in osteoporotic bone
Interlocking screw	Couples an intramedullary nail to the bone to maintain length, alignment, and rotation	Locked femoral/tibial intramedullary nail
Anchor screw	A point of fixation used to anchor a wire loop or strong suture	Tension band anchor in a proximal humerus fracture
Push-pull screw	A temporary point of fixation used to reduce a fracture by distraction and/or compression	Use of an articulated compression device
Reduction screw	Conventional screw used through a plate to pull fracture fragments towards the plate; the screw may be removed or exchanged once alignment is obtained	MIPO technique to reduce multifragmentary fracture onto a LCP
Poller screw	Screw used as a fulcrum to redirect an intramedullary nail (chapter 3.3.1)	Proximal tibial fracture during intramedullary nailing

Table 3.2.1-1 Functions of screws.
Abbreviations: LCP, locking compression plate; LC-DCP, limited-contact dynamic compression plate; LISS, less invasive stabilization system; MIPO, minimally invasive plate osteosynthesis.

This principle technique is achieved by drilling a glide hole into the near cortex with a diameter slightly larger than the outer diameter of the screw thread. In the opposite or far cortex, a smaller hole is drilled using a drill guide that inserts into the glide hole. This is called the pilot hole. It is the same diameter as the core of the screw to be inserted. A self-tapping screw may be introduced to the pilot hole or a tap can be used to cut a channel for the threads of a screw. It is then called a threaded hole. When a fully threaded cortex lag screw is applied, it only has purchase in the thread hole and does not engage in the glide hole. As the head of the screw is pressed against the cortex, preload is created. The bone fragments are compressed as the screw is tightened, producing interfragmentary compression (**Fig 3.2.1-9**, **Video 3.2.1-1**).

2.1.2 Application of a partially threaded screw as a lag screw

This principle technique is indicated in cancellous bone. It is achieved by drilling a pilot hole into the near cortex, across the fracture and into the far cortex. The smooth shaft of the partially threaded cancellous screw serves as the gliding hole, the threaded part engages the far cancellous and cortical bone and, as the head is compressed against the near cortex; preload is created which results in interfragmentary compression (**Fig 3.2.1-10**).

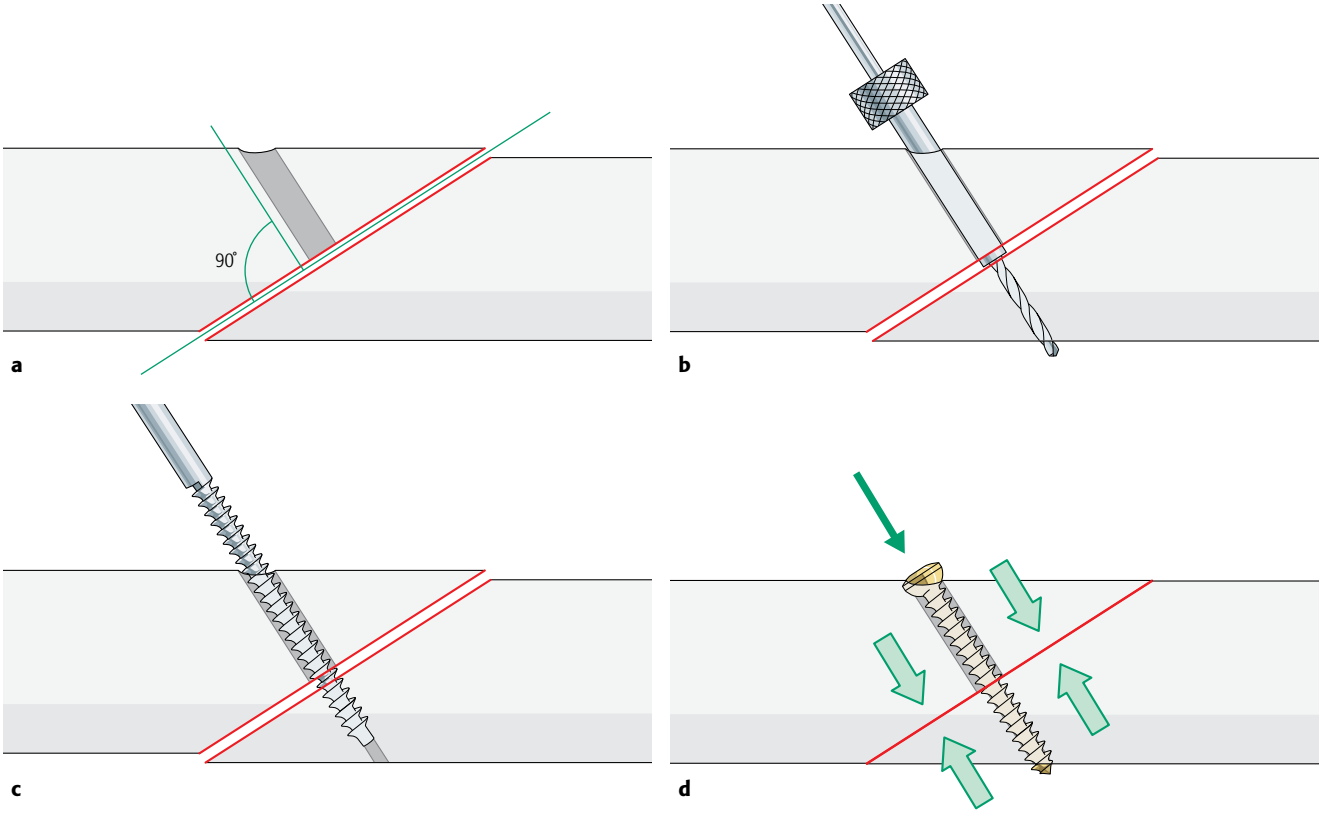

Fig 3.2.1-9a–d A fully threaded 4.5 mm cortex screw used to lag a fracture (function = interfragmentary compression).
a Anatomical fracture reduction. The glide hole is slightly wider than the thread diameter of the screw. It is drilled at 90° to the fracture line.
b The appropriate drill guide is placed within the glide hole. The pilot hole is drilled to the diameter of the core of the screw. The hole will be countersunk with the countersinking tool.
c A tap is used to cut a channel for the threads in the pilot hole. This creates a thread hole. This step is omitted if self-tapping screws are used.
d As the screw advances, the head engages the near cortex and creates preload. Further advancement of the screw creates compression at the fracture site (interfragmentary compression).

2.2 Screw-tightening and torque-limiting screwdrivers

When an experienced surgeon tightens a screw to the degree which he considers optimal, the surgeon achieves torque that is close to the thread-stripping torque. Because screws produce high amounts of axial force, it does not make sense to tighten screws to this utmost limit. When the holding force of a screw is fully achieved by preload, there is little holding force left to sustain additional functional load. Historically, surgeons tried to achieve the utmost axial force, including repeated retightening. Today, the surgeon is advised to apply lag screws (and plate screws) at about 2/3 of the possible torque. It is also important that the surgeon appreciates that titanium gives less tactile feedback to the surgeon that stainless steel and extra care must be taken when inserting titanium screws (see chapter 1.3).

The LHS, LCP, and variable angle LCP (VA-LCP) lock upon tightening within the threaded plate hole and thus protect the screw thread and the bone. With these screws, a torque-limiting screwdriver must be used to prevent the screw heads from jamming. However, torque-limiting screwdrivers are of no practical use when applied to conventional screws because the quality and thickness of the bone exhibits large individual and topographic variations.

A variant of the LHS is the variable angle LHS which provides four options for threaded locking between the plate (VA-LCP) and the screw, forming a fixed angle construct at the desired angle. The head of the variable angle locking screw is rounded to facilitate various angles within the locking hole (see chapter 3.3.4).

2.3 Compression

Tests with expert surgeons have shown that 4.5 mm screws were routinely tightened to a torque that produced between 2,000–3,000 N of axial compression. In vivo measurements of compression applied to living bone demonstrated that the compression that was initially applied slowly decreases over months [6] but the compression outlasts the time required for the osteons to bridge the fracture gap and result in primary bone healing.



Video 3.2.1-1 Lag screw technique. The glide hole in the near cortex is wider than the diameter of the thread. The thread hole in the far cortex is the same as the core diameter of the screw and has been tapped.

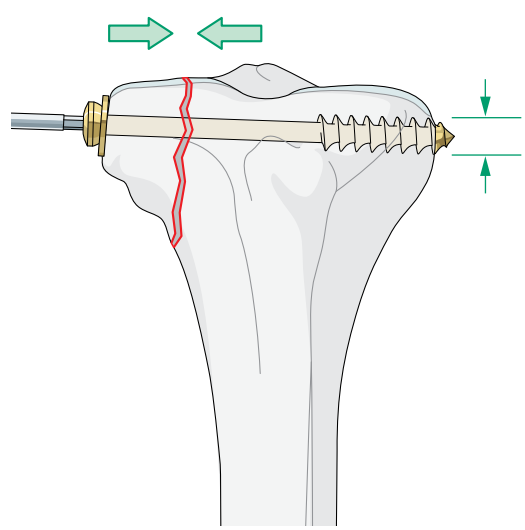

Fig 3.2.1-10 Compression of a partial articular fracture using a partially threaded 6.5 mm cancellous bone screw. The thread pulls the opposite bone fragment toward the head of the screw. The shaft of the screw does not transmit any great axial force between the shaft and the surrounding bone. The length of the screw shaft must be chosen so that the threaded part of the screw lies fully within the opposite bone fragment. To prevent the screw head from sinking into the thin cortex, a washer is used.

In vivo loosening of well-placed screws is induced by micromotion at the interface between thread and bone, and not by pressure (**Fig 3.2.1-11**) [7].

If the strain produced by micromotion is greater than the strain tolerance of bone, the screw will become loose and then place additional strain on the adjacent screw. There will be progressive loosening of the implant. This is a particular problem in osteoporotic bone that has low strain tolerance.

In most cases loosening is due to poor technique and common pitfalls include:

- Failure to plan
- Inappropriate implant positioning
- Failure to achieve anatomical reduction for absolute stability techniques
- Excessive force causing destruction of the screw-bone interface

In many cases, the overall stability will be irreversibly lost and the fracture may not heal.

2.4 Screw insertion

In conventional plating, the inclination of screws in relation to the long axis of the plate can be selected to provide an optimal lag screw position (**Video 3.2.1-2**), or to bypass either an area of comminution or a fracture line in the far cortex. The purchase of the screw in the far cortex then locks the inclination of the screw.

When monocortical screws are used, angular stability must be provided by the design of the screw head-to-plate locking process. A conical spiral thread provides this locking process. We use the general term of LHS for this type of construction. There are only a few indications for monocortical screws as their hold is inferior to bicortical screws; they are used most commonly for periprosthetic fractures where an intramedullary implant prevents the insertion of bicortical screws.

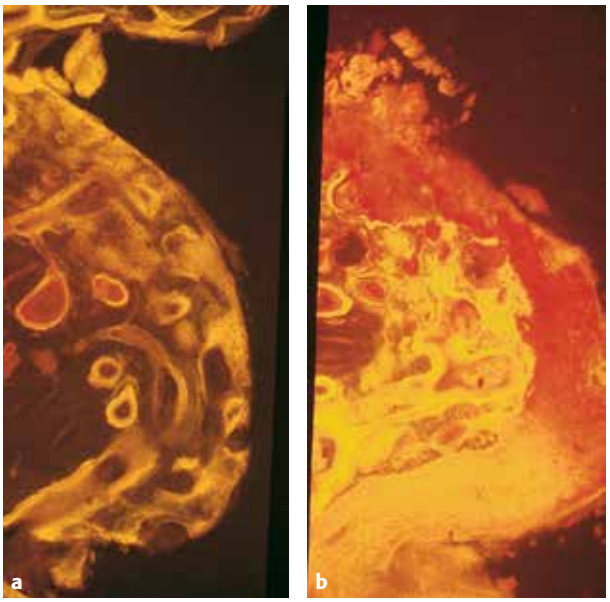

Fig 3.2.1-11a–b Mechanical loosening of a screw—biological reaction.

a Histological section of a well-fixed screw. There is close contact between bone and adjacent screw with bone remodeling.

b The appearance of the "thread" where the screw had been undergoing movement within a range of micrometers. Bone has been resorbed and replaced by fibrous tissue that no longer has holding power.

Video 3.2.1-2 The screw hole in the limited-contact dynamic compression plate (LC-DCP) allows inclination of screws and optimal lag screw placement.

Locking head screws cannot be used as lag screws.

An LHS can be inserted using minimally invasive techniques, but require careful planning and a thorough understanding of both the mechanics and biology of fracture fixation. Their use is described in detail in the chapter on locking plates (see chapter 3.3.4).

2.5 Modes of failure

Screws can fail because of axial pull out, bending forces, torque, or a combination of all these factors. Screws can fail during insertion when the surgeon attempts to apply maximum torque. While screws usually resist axial pullout well, most conventional screws poorly resist bending and torque due to their small core diameter. Based on the knowledge that the core diameter of a screw may be increased without unduly forfeiting the pull out force, the resistance to bending may be increased threefold by only a 30% increase of the core of a standard size screw.

The best implants tolerate intermittent peak (over-)load without irreversible loss of the bone-implant interface. While today's plates, intramedullary nails, and external fixators give way and spring back into their former shape, screws are less tolerant of peak load. With overload, the bony thread may strip and the screw will lose its holding power forever. This behavior must be considered when using lag screw fixation in isolation and in combinations of screws and flexible devices, such as intramedullary nails and external fixators.

3 Clinical applications of lag screws

3.1 Positioning of lag screw

Lag screws are most efficient when placed either perpendicular to the fracture plane or in an inclination halfway between the perpendiculars to the fracture plane and to the long axis of the bone (**Fig 3.2.1-12**). Whether the first or the second option is to be favored depends on the absence or presence of forces along the bone axis. The perpendicular position in relation to the fracture plane is, in most cases, simple to achieve and provides nearly optimal function of the lag screw. To improve stability in a long spiral fracture, several lag screws may be used. Their direction must follow the spiral plane of the fracture. This may cause considerable stripping of soft tissues and periosteum, and the preservation of the periosteal blood supply and biology must be considered when applying lag screws. Before inserting an inclined lag screw in diaphyseal bone, a countersink for the screw head should be prepared.

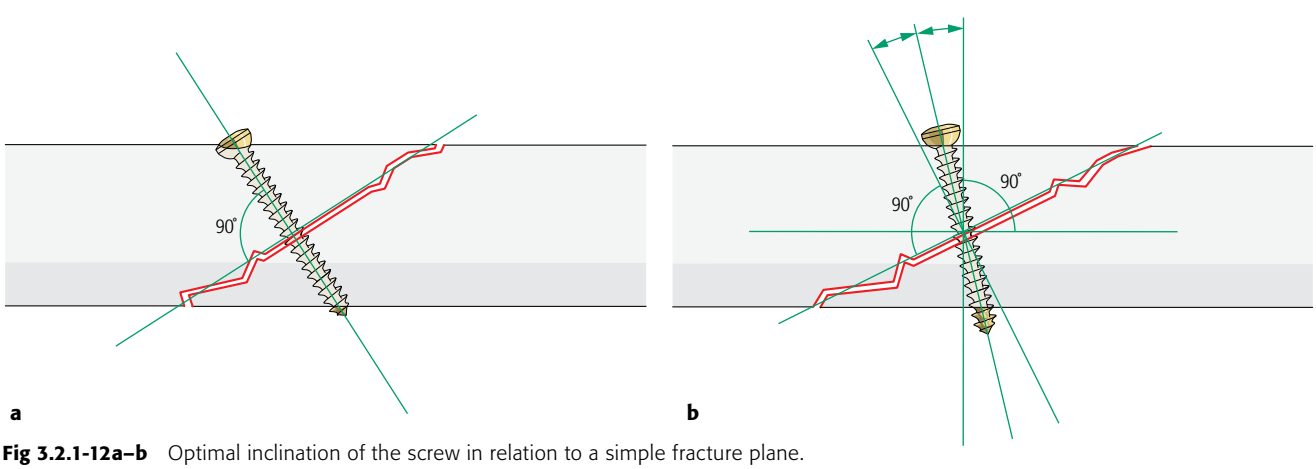

Fig 3.2.1-12a–b Optimal inclination of the screw in relation to a simple fracture plane.
a The lag screw is oriented perpendicular to the fracture plane. This is an ideal inclination in the absence of forces along the bone axis.
b An inclination halfway between the perpendiculars to the fracture plane and to the long axis of the bone is better suited to resist compressive functional load along the bone's long axis.

Single lag screws require protection by a plate—except close to a joint.

3.2 Lag screws in metaphyseal and epiphyseal regions

Articular and periarticular fractures need anatomical reduction and absolute stability to obtain and maintain perfect congruity of the joint. In this region, lag screw fixation is the predominant procedure. To prevent the screw head from sinking into the bone, a washer is often needed (**Fig 3.2.1-10**, **Video 3.2.1-3**). For postoperative functional treatment, most of these screw fixations will be supplemented by a protection or buttress plate. Locking head screws in combination with locking plates may provide angular stability when there are multiple fragments in the metaphysis. These screws cannot act as lag screws.

Video 3.2.1-3 Partially threaded cancellous bone screw used to lag a tibial plateau fracture.

4 References

1. **Haas N, Hauke C, Schütz M, et al.** Treatment of diaphyseal fractures of the forearm using the Point Contact Fixator (PC-Fix): results of 387 fractures of a prospective multicentric study (PC-Fix II). *Injury.* 2001 Sep;32(Suppl 2):B51–62.
2. **Tepic S, Perren SM.** The biomechanics of the PC-Fix internal fixator. *Injury.* 1995;26(Suppl 2):5–10.
3. **Krettek C, Krettek G.** Minimally invasive plate osteosynthesis . *Injury.* 1998;29(Suppl 3):C3–6.
4. **Baumgart FW, Cordey J, Morikawa K, et al.** AO/ASIF self-tapping screws (STS). *Injury.* 1993;24(Suppl 1):1–17.
5. **Taha W, Blachut P.** Pullout testing for self-tapping screws. Presented at: 50th Annual Orthopedic Research Day at University of British Colombia; May 2000; Vancouver, BC; 2000.
6. **Blümlein H, Cordey J, Schneider U, et al.** [Langzeitmessung der Axialkraft von Knochenschrauben in vivo.] *Med Orthop Tech.* 1977;97(1):17–19. German
7. **Ganz R, Perren S, Rueter A.** [Mechanical induction of bone resorption.] *Fortschr Kiefer Gesichtschir.* 1975;19:45–48. German.

5 Acknowledgments

We thank Peter Messmer, Stephan Perren, and Norbert Suhm for their contribution to this chapter in the second edition of the *AO Principles of Fracture Management*.

3.2.2 Plates

Mark A Lee

1 Introduction

While plating technology continues to evolve, the basic functions and applications of plates have remained essentially unchanged. With improvements and advances in the screw to plate interface options, plates are being used in an ever-widening array of applications. Conventional compression plate fixation, using techniques of absolute stability leading to direct bone healing, has generally been recommended for operative fracture treatment since Danis' and the AO group's pioneering work in the mid-20th century [1] and continues to have an important place in fracture treatment. Our improved understanding of the spectrum of stability and its influence on the mode of fracture healing, in concert with new screw interface technology and mixed screw type applications, has allowed us the opportunity to use plates in different ways than ever considered before [2–4].

Intraarticular fractures require anatomical reduction and absolute stability and plates are often used for fixation of the metaphysis. In these fractures, anatomical reduction is essential to minimize arthrosis, and callus formation is not desired. Diaphyseal fractures of long bones are often treated with intramedullary nailing but good indications for plating include the need for anatomical reduction (eg, forearm and fibular shaft) and the presence of a short distal or proximal fragment, which makes nailing technically difficult. Plate osteosynthesis may be preferred to external fixation in some polytrauma patients and in some cases of nonunion, especially in the presence of deformity.

Fixation with relative stability results in fracture healing via endochondral ossification with callus. Callus formation after attempts at fixation with absolute stability indicates a degree of instability that ultimately may lead to implant fatigue and failure (see chapter 1.3). Absolute stability results in direct fracture healing via remodeling and generally takes longer than healing by callus. A plate, in direct contact and pressed down onto the bone surface, can disturb blood flow to the underlying cortex. This may lead to local cortical necrosis [5], yet the clinical relevance of this necrosis is unclear. The process of bony remodeling and revascularization is slow and local osteoporosis is observed in cortical bone at the points of contact (footprints) with the plate.

> The disturbance of the cortical blood supply can be decreased by minimizing stripping of the periosteum. The plate should be placed on top of it.

Due to its reduced area of contact with bone, the limited-contact dynamic compression plate (LC-DCP) appears to preserve the blood supply better than the original dynamic compression plate (DCP), an effect which is even more evident with locking plates, which do not rely on compression and friction between the plate and bone for stability [6]. It was previously theorized that plates weakened the local bone due to stress protection, a theory that is no longer widely accepted. It is more likely that disturbed vascularity results in slower remodeling of the cortex underneath a plate.

> The classic plating technique, providing absolute stability, requires strict adherence to the principles of anatomical reduction and interfragmentary compression.

Errors of technique and misapplied principles may lead to complications, such as delayed healing, implant failure, and nonunion. These errors in technique are frequently related to failed or incomplete attempts at reduction during interfragmentary compression of simple fracture patterns (type A) or misguided attempts to stabilize multifragmentary fractures (type C) with lag screws. Locking plate designs can create secure and stiffer neutralization in a wide range of bone qualities and these technical errors may occur more commonly [7] with these implants if the surgeon fails to understand the principles and fails to plan.

2 Plate designs

Many different plates have been developed, most of which may be used to perform different biomechanical functions, depending upon how the surgeon applies the plate.

The surgeon, not the designer of the plate, determines how a plate will function and how it will be applied.

This is a key element of preoperative planning. Any nonlocking plate can be used to provide any of the six key functions of a plate (**Table 3.2.2-1**). However, the design and application of the plate must take into account the biomechanical environment. Thus, a thin, one-third tubular plate is an excellent choice to protect a lag screw fixation of the lateral malleolus but is not strong enough to act as a bridge plate for a multifragmentary fracture at the same site.

This section discusses the design and application of the various plates available and helps guide the surgeon in selecting the correct plate during preoperative planning.

2.1 Limited-contact dynamic compression plate

The LC-DCP was introduced by Perren in 1990 [6] and has become the gold standard for plate fixation (**Fig 3.2.2-1**). The plate is available in two sizes, 3.5 and 4.5, which is determined by the thread diameter of the cortex screws used with the plate. The screw hole design allows for axial compression by eccentric screw insertion.

The LC-DCP can be used to provide six different biomechanical functions:

- Compression
- Protection
- Buttress
- Tension band
- Bridging
- Reduction

2.1.1 Design

Several changes in design have improved the LC-DCP compared with earlier designs (eg, DCP).

The area of plate-bone contact (the plate footprint) is greatly reduced in the LC-DCP. There is less impairment of the capillary network of the periosteum, resulting in a relative improvement of cortical perfusion.

This reduces bone resorption underneath the plate. Moreover, the structured geometry of the undersurface of the plate results in an even distribution of stiffness, making contouring easier, and minimizing the likelihood of bends in the plate being concentrated (**Fig 3.2.2-2**). When using the

Plate function	Biomechanics	Example of application
Compression	The plate produces compression at the fracture site to provide absolute stability.	Simple transverse humeral fracture
Protection	The plate neutralizes bending and rotational forces to protect a lag screw fixation.	Simple oblique radial fracture
Buttress	The plate resists axial load by applying force at 90° to the axis of potential deformity.	Lateral tibial plateau fracture
Tension band	The plate is attached to the tension side of a fracture and converts the tensile force into a compressive force at the cortex opposite the implant.	Olecranon fracture
Bridging	The plate provides relative stability by fixation to the two main fragments, achieving correct length, alignment, and rotation. The fracture site is left undisturbed.	Multifragmentary ulnar fracture
Reduction	The plate assists in the direct reduction and overall position of fracture fragments that is either temporary or definitive. The plates do not harm fracture biology but are needed to provide accurate positioning of fracture fragments as definitive fixation can be achieved.	Multifragmentary proximal tibial fracture

Table 3.2.2-1 The six functions of a nonlocking plate.

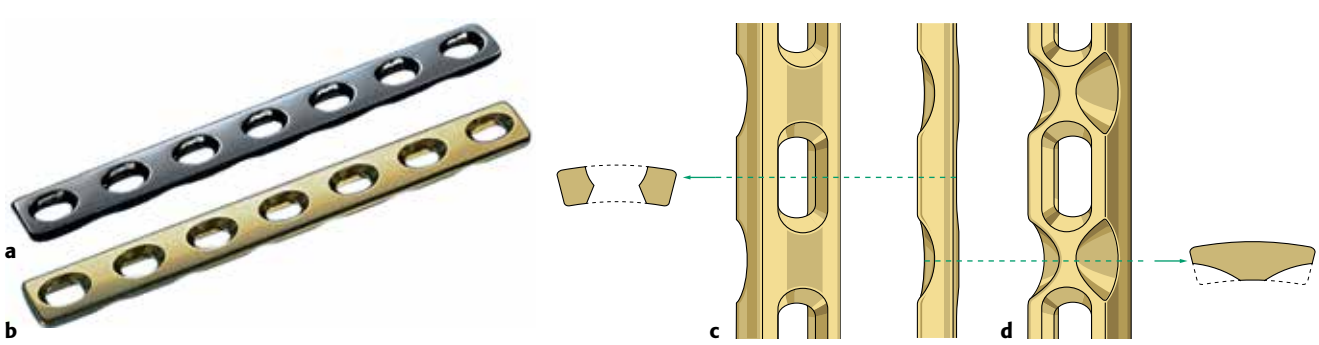

Fig 3.2.2-1a–d The LC-DCP is available in either stainless steel (**a**) or titanium (**b**). Its structured undersurface (**c–d**) allows limited contact between plate and bone, and there is an even distribution of holes along the plate.

bridging method, this distribution of stiffness results in a gentle elastic deformation of the entire plate without stress concentration at one screw hole. The cross-section of the plate is of a trapezoidal shape; hence, the bony ridges that form along the edges of the plate tends to be thicker and flatter, rendering them less prone to damage during plate removal.

The LC-DCP design is available in many sizes for different large and small bones with the broad 4.5 design used for the femur and the narrow 4.5 design used for the humerus and the tibia. The small 3.5 design is used for the forearm and the fibula.

The screw holes in the LC-DCP are best described as a portion of an inclined and angled cylinder. Like a ball, the screw head slides down the inclined shoulder of the cylinder (**Fig 3.2.2-3**). In practice, when the screw is inserted in such a hole and tightened, this results in movement of the bone fragment relative to the plate and consequently, compression

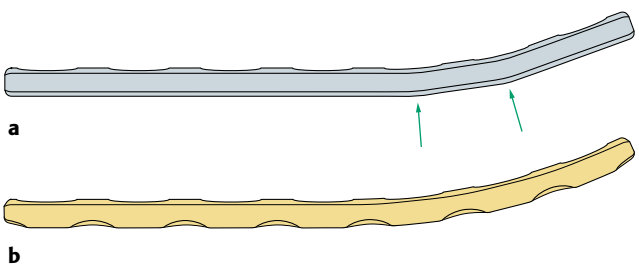

Fig 3.2.2-2a–b
a In DCP, the area at the plate holes is less stiff than the area between them. During bending the plate tends to bend only in the areas of the hole.
b The LC-DCP has an even stiffness without the risk of buckling at the screw holes.

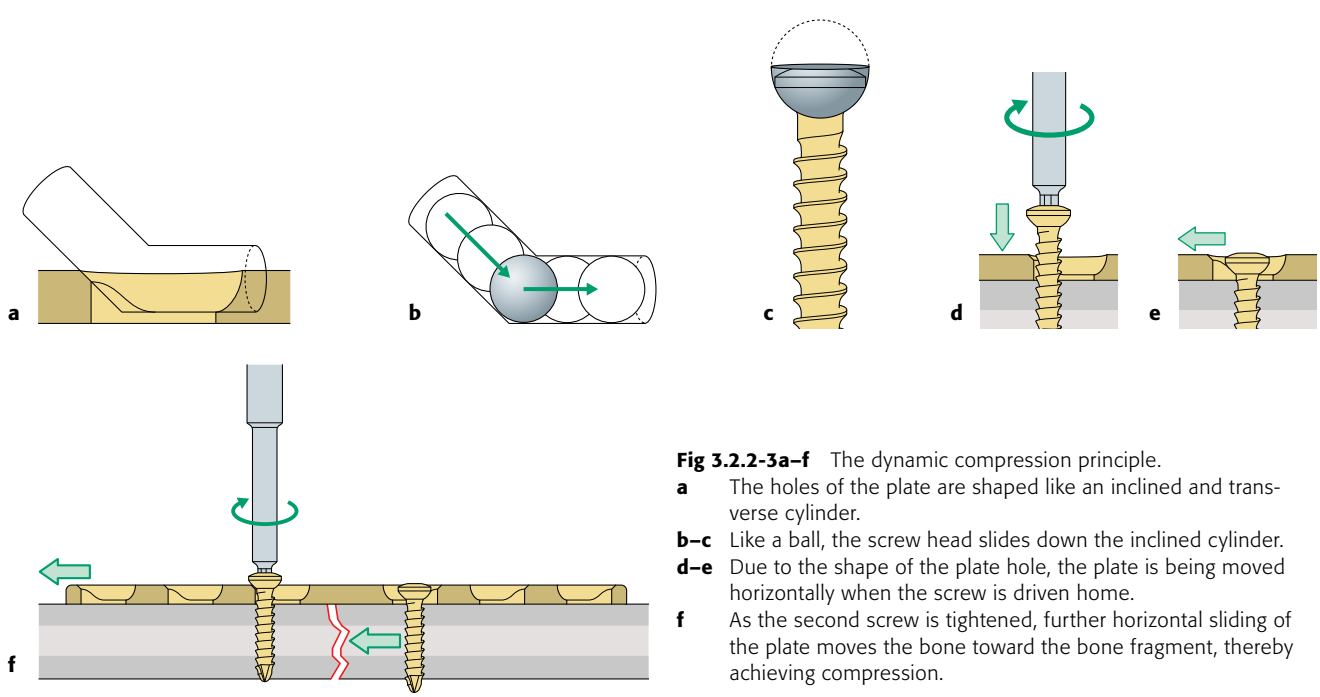

Fig 3.2.2-3a–f The dynamic compression principle.
a The holes of the plate are shaped like an inclined and transverse cylinder.
b–c Like a ball, the screw head slides down the inclined cylinder.
d–e Due to the shape of the plate hole, the plate is being moved horizontally when the screw is driven home.
f As the second screw is tightened, further horizontal sliding of the plate moves the bone toward the bone fragment, thereby achieving compression.

across the fracture site. The design of the screw holes allow for a displacement of up to 1.0 mm (**Video 3.2.2-1**). After the insertion of one compression screw, additional compression using one more eccentric screw is possible before the first screw is completely tightened (**Fig 3.2.2-4**). For axial compression over a distance more than 2.0 mm, the use of the articulated tension device is recommended (see section 3.2 in chapter). The oval shape of the holes allows 25° inclination of the screws in the longitudinal plane and up to 7° inclination in the transverse plane (**Fig 3.2.2-5**).

2.1.2 Technique of application

The LC-DCP 4.5 is used with 4.5 mm cortex screws and 6.5 mm cancellous bone screws. The LC-DCP 3.5 is used with 3.5 mm cortex and cancellous screws.



Video 3.2.2-1 Eccentric positioning of a conventional screw in the combination hole of the LCP allows this plate to be used as a compression plate.

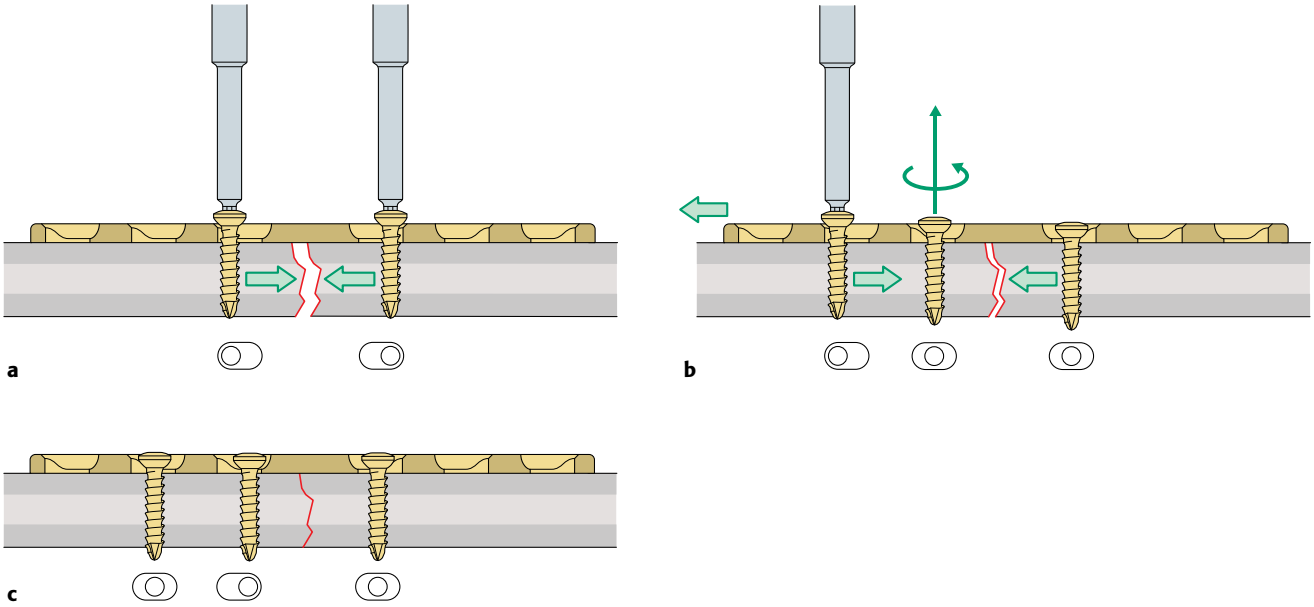

Fig 3.2.2-4a–c
a Inserting one compression screw on either side of the fracture.
b If after insertion of the two compression screws there remains a fracture gap, a third eccentrically placed screw may be inserted. Before this screw is tightened, the first screw has to be loosened to allow the plate to slide.
c After that, the first screw is tightened again.

There are two DCP drill guides, one with an eccentric (load) hole and a gold collar, the other with a concentric (neutral) hole and a green collar, for each size of plate/screws (**Fig 3.2.2-6a–b**). Depending upon the intended function of the plate, the eccentric or neutral drill guide is chosen. If the screw is inserted in a neutral (green) position, the hole is 0.1 mm off-center and still adds a small amount of compression. The load (gold) drill guide contains a hole 1.0 mm off-center and should be positioned away from the fracture, so that when the screw is tightened the bone is displaced relative to the plate, applying compression to the fracture site (**Video 3.2.2-2**).

If the plate is intended to function as a buttress (see section 4.2 in this chapter), the universal drill guide (or sleeve) may be used, placing the screw at the opposite end of the hole. This prevents any gliding of the plate relative to the bone (**Fig 3.2.2-6c**).

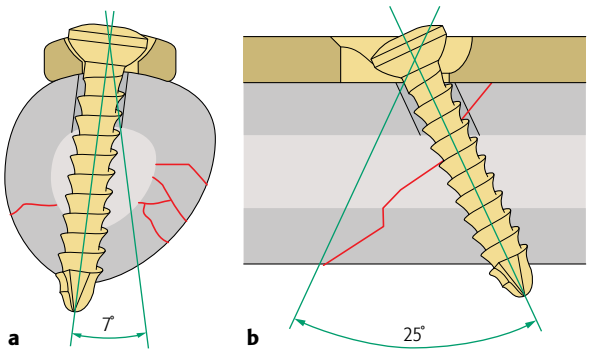

Fig 3.2.2-5a–b The shape of the holes of the DCP allows inclination of the screws of up to 7° in transverse direction (**a**) and of 25° in longitudinal direction (**b**).

Video 3.2.2-2 To drill an eccentric (load) hole and apply compression, the arrow on the drill guide must point toward the fracture.

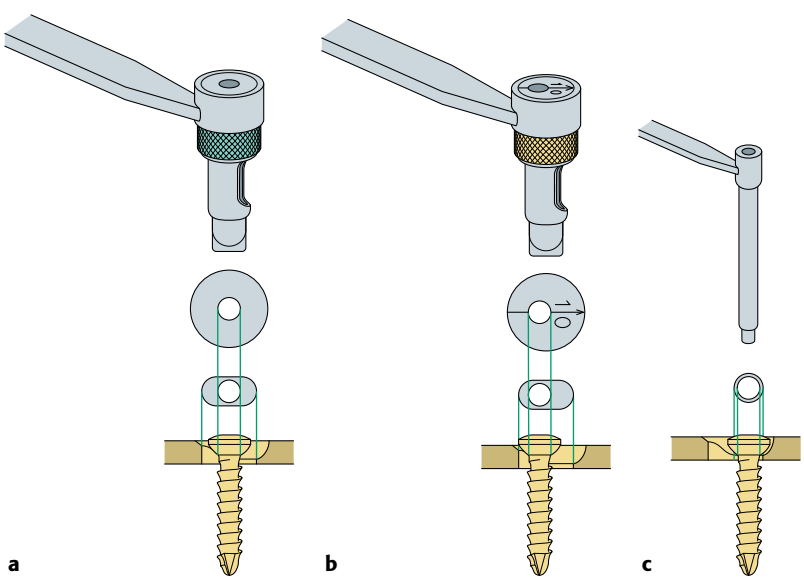

Fig 3.2.2-6a–c The application of the drill guides depends on the function the screw will have:
a Neutral position (green end of the guide).
b Compression (golden end of the guide).
c Buttressing (universal drill guide).

The LC-DCP universal spring-loaded drill guide permits placement of the drill into the plate hole in a neutral or eccentric position. If the inner drill sleeve tube is extended (normal status of the drill guide) and placed against the end of the plate hole, an eccentric drill hole will result (**Fig 3.2.2-7a**). However, if the spring-loaded guide is pressed against the bone, the inner drill sleeve tube retracts and the rounded end of the outer tube glides down the slope of the hole into the neutral position (**Fig 3.2.2-7b**, **Video 3.2.2-3**).

2.2 Tubular plates

The one-third tubular plate exists only in the 3.5 version. Its counterpart in the 4.5 system is the semitubular plate. The one-third tubular plate is available in either titanium or stainless steel (**Fig 3.2.2-8a**). As it only has a thickness of 1.0 mm, its ability to confer stability is somewhat limited. However, it may be useful in areas with minimal soft-tissue covering, such as the lateral malleolus and the distal end of the ulna. Each hole is surrounded by a small collar (**Fig 3.2.2-8b**)

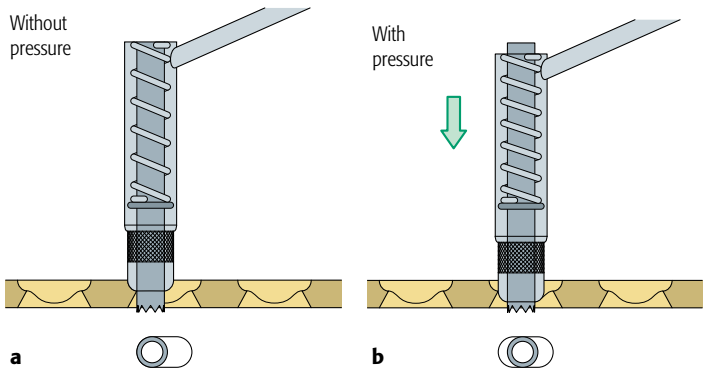

Fig 3.2.2-7a–b Application of the spring-loaded LC-DCP universal drill guide.
a Eccentric position.
b Neutral position.



Video 3.2.2-3 The LC-DCP universal drill guide, used without downward pressure, produces an eccentric hole.

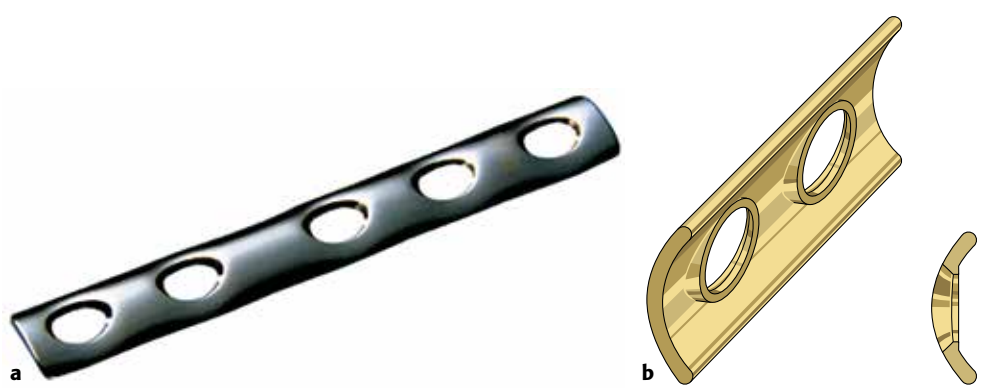

Fig 3.2.2-8a–e One-third tubular plates.
a Stainless steel one-third tubular plate.
b The collar around the hole of the one-third tubular plate prevents the screw head from protruding and secures plate-bone contact.

to prevent the spherical screw heads from penetrating the plate and producing cracks in the near cortex (**Fig 3.2.2-8c–d**). The oval shape of each hole allows a certain degree of eccentric screw placement to produce fracture compression (**Fig 3.2.2-8e**). This plate can also be stacked one upon another to improve stiffness yet maintain accurate bone contour and contact without the need for additional plate bending. The flexibility of the one-third tubular plate optimizes its function as a buttress (anti-glide) plate (**Fig 3.2.2-9**). This plate works well when applied at the apex of an oblique fracture since precise contouring is not necessary but critical, intimate plate-bone contact can still be achieved to produce an efficient buttress.

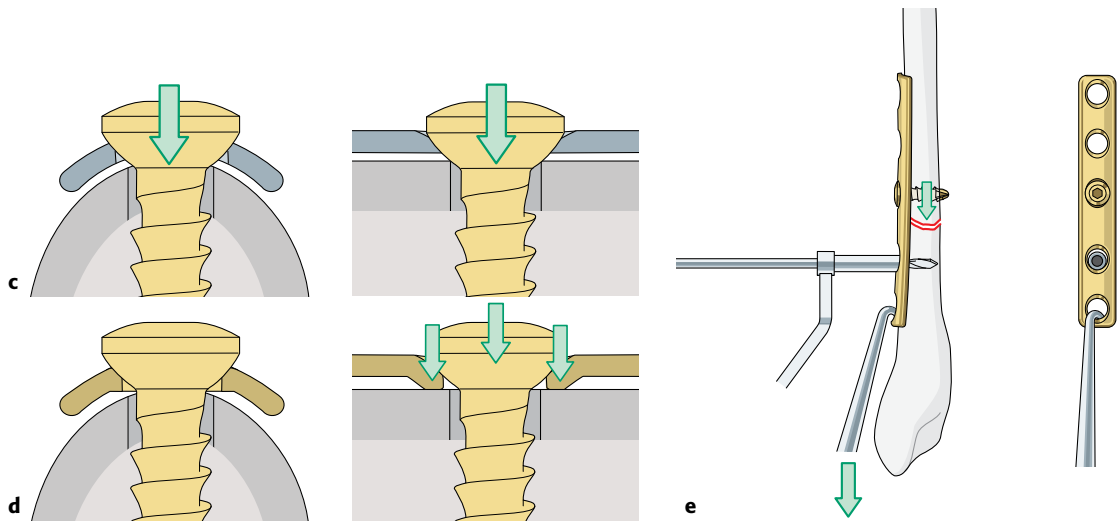

Fig 3.2.2-8a–e (**cont**) One-third tubular plates.
c Without a collar, the screw head would protrude through the plate, preventing good fixation.
d Due to the collar the plate-screw-bone coupling is improved.
e The oval shape of each hole allows a certain degree of eccentric screw placement to produce fracture compression, which can be augmented by pulling at one end of the plate.

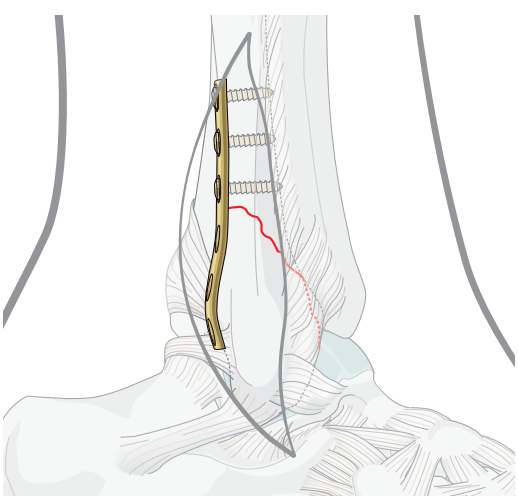

Fig 3.2.2-9 Buttress (antiglide) function demonstrated by a minimally contoured one-third tubular plate placed upon the posterior surface of the distal fibula with screws placed to reduce the oblique fracture.

2.3 Reconstruction plates

Reconstruction plates have deep notches on the edge of the plate. These notches are situated between the holes and allow accurate contouring of the plate in all planes (**Fig 3.2.2-10a**). Two plate sizes are available for use with 3.5 and 4.5 cortex screws. The plate is not as strong as the LC-DCP and may be further weakened by heavy contouring, so sharp bends in any direction should be avoided. The holes are oval to allow dynamic compression. These plates are especially useful in fractures of bone with complex 3-D geometry, such as the pelvis, acetabulum, distal humerus, distal tibia, and clavicle. Special instruments are available for the contouring of these plates (**Fig 3.2.2-10b**).

2.4 Locking plates

2.4.1 Design and biomechanics

Locking plate technology demonstrates some of the most recent advances in screw and plate interfaces. The locking compression plate (LCP) can be applied to function like any other plate, ie, it can provide compression, protection, bridging, and so on. Other locking plates, such as the less invasive stabilization system (LISS), act as internal fixators and can only provide a bridging function.

Conically threaded undersurfaces of the screw heads fit matching, reciprocal threads in the different locking plate designs, allowing screws to effectively bolt into the plate and bone (**Fig 3.2.2-11**). This has significant biomechanical implications. Because of angular-stable screws, the fixation does not require the plate to be compressed to the bone for stability. The combi-hole design also allows standard screws to be inserted into neutral or load holes and this allows the LCP to be used to perform any of the six biomechanical functions of a standard plate.

Locking plates can be used as internal fixators, especially the more rigid plate varieties, eg, LCP 4.5. Ideally, there is no contact with the periosteum. This provides relative stability and maximizes the possible blood supply to allow rapid, indirect healing through callus formation [2].

Angular-stable screws also allow load to be more evenly distributed along the entire fixation rather than being concentrated at a single bone-screw interface (**Fig 3.2.2-12**) [8]. Failure of fixation with standard plates often starts at one screw, which may then propagate to other screws. Because a similar phenomenon does not occur with locking plates, they may be particularly useful in osteoporotic bone.

The LCP is versatile—it can be used to provide any of the six biomechanical functions of a nonlocking plate and can also be used as an internal fixator or a fixed-angle device.



Fig 3.2.2-10a–b
a Reconstruction plate.
b The special bending pliers for the reconstruction plates: bending irons are available to twist the plate.

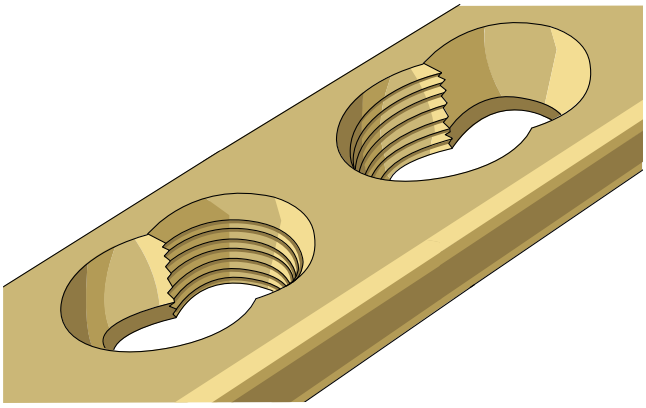

Fig 3.2.2-11 The LCP combination hole (combi-hole) allows conventional and locking head screws to be placed into the same implant but not into the same hole at once.

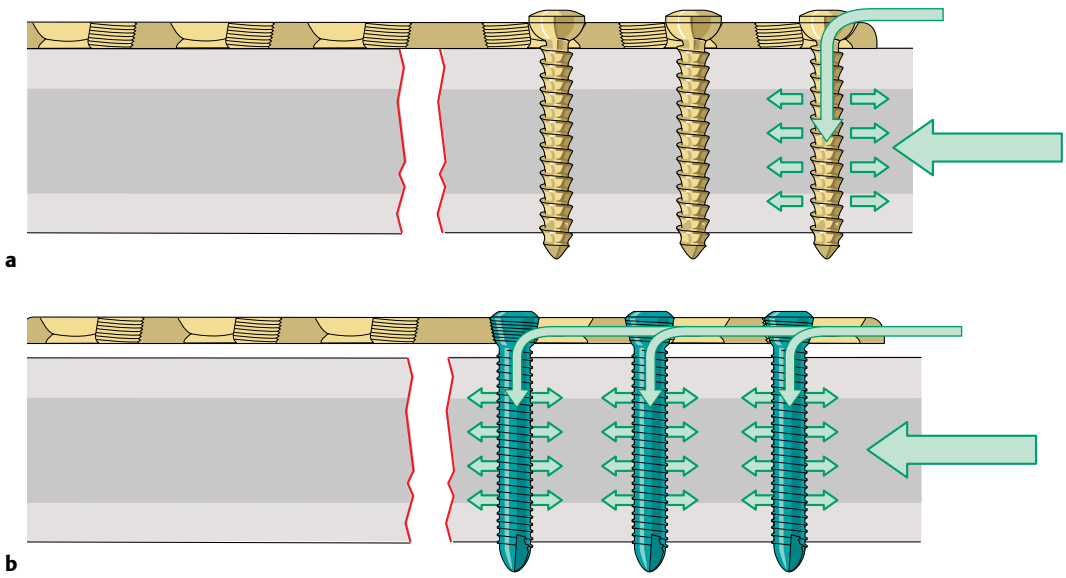

Fig 3.2.2-12a–b

a Because a conventional screw head is allowed to toggle during loading, energy is dissipated at the bone-screw interface farthest from the fracture. Energy is concentrated at this level, shielding additional screws from load initially.

b In locking plates, the angular-stable screws (LHS) prevent load concentration at a single bone-screw interface by distributing load more evenly **[8]**.

The most recent development in locking plates is polyaxial screw technology. This plate-hole design allows for limited angulation of the screws within a defined radius (15° off the central/nominal axis) and still provides angular stability by a special threaded screw head and plate interface. It is best suited for periarticular fixation to maximize the purchase of screws close to the subchondral plate in a periarticular fracture while allowing the surgeon to position the screws so that the joint itself is not penetrated (**Fig 3.2.2-13**).

2.4.2 Technique of application

It is essential to understand that a locking head screw cannot be used as a reduction tool. Inserting a locking head screw will not realign a fracture fragment and it will not move the plate to improve reduction. Once a single locking head screw is applied through the plate on one side of a fracture, the position of the plate and that fracture fragment is fixed and cannot be adjusted.

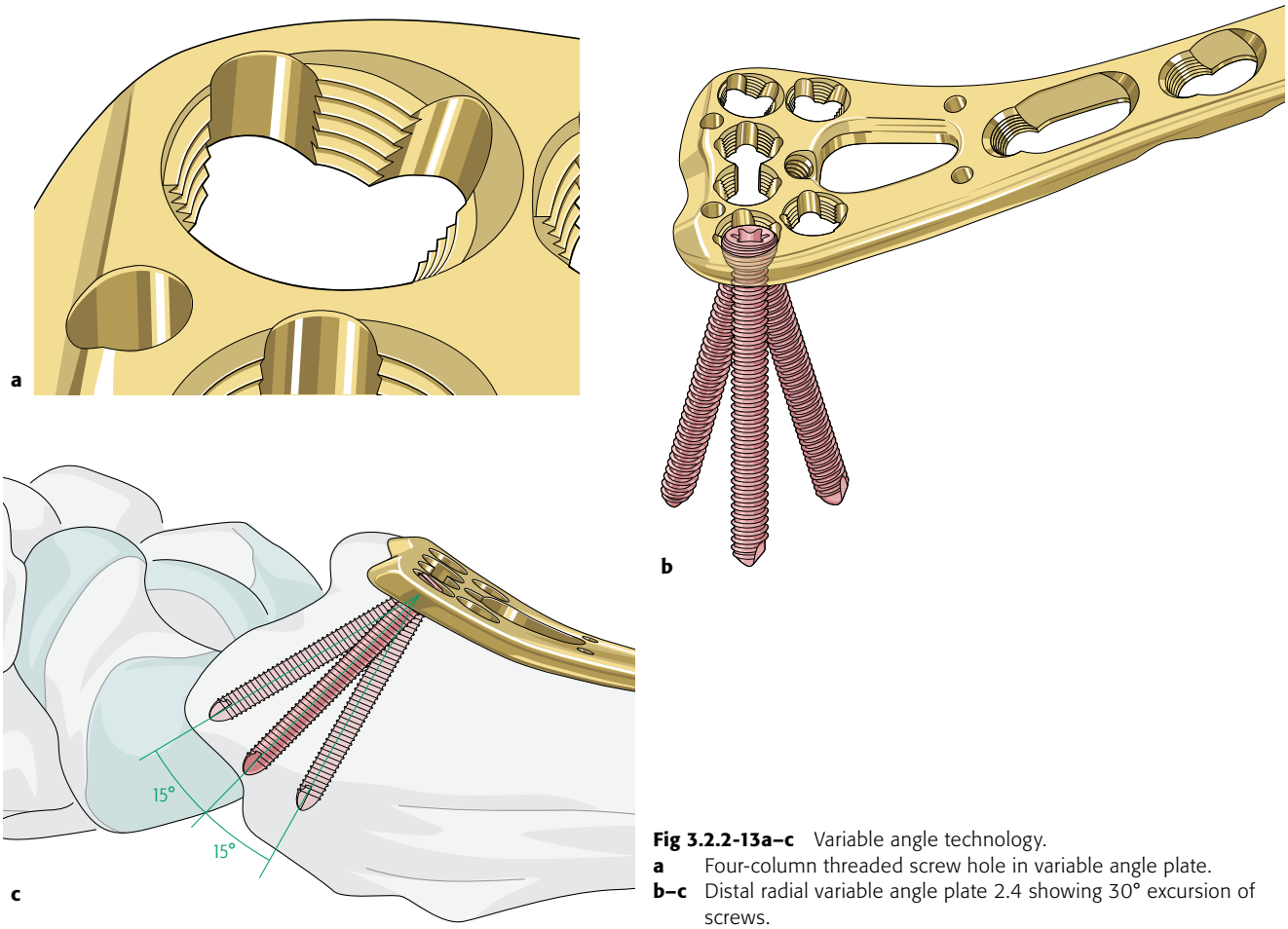

Fig 3.2.2-13a–c Variable angle technology.
a Four-column threaded screw hole in variable angle plate.
b–c Distal radial variable angle plate 2.4 showing 30° excursion of screws.

Careful preoperative planning is essential when using the LCP and this must include the order in which screws are applied. Before using a locking head screw, it is crucial that the final reduction is obtained.

Correct engagement of the locking mechanism requires a precise and predefined angle of insertion. Therefore, drilling is only performed after a threaded drill guide has been screwed onto the desired plate hole. Full seating of the threaded drill guide prevents later cross-threading of the locking head screw threads. Three methods of measuring screw length are possible:

- Removing the drill guide and using the standard, indirect measuring device
- Using a specific, indirect measuring device through the guide
- Measuring directly from the drill shaft

Variable angle locking screws must also be placed with precision. Most implant systems contain an angled guide to limit drill angulation. For any of the current designs, aiming of the screw path near the maximal suggested angulation may severely limit the amount of angular stability achieved. For most applications with these plates, the nominal screw axis (central or 0° off-axis) should be selected to optimize stability; however, angulation to the smallest acceptable deviation from the nominal axis may enhance fixation in osteoporotic bone.

The surgeon must be aware that fixation achieved is due to the screw-plate contact rather than screw-bone contact.

It is essential that the correct torque screwdriver is used to prevent overtightening of the screw.

Conventional and locking head screws can be used in the same fracture fragment but this requires careful planning.

Once a locking head screw has been inserted into a fracture fragment, no (additional) conventional screws should be inserted into this side of the fixation—only additional locking head screws may be used. "Reduce and lag first, lock second."

Poor bone quality is a clinical situation in which combination fixation may prove useful [9]. Initially, lag screws are placed in each segment to compress the fragments. Subsequently, the rest of the plate fixation is performed with locking head screws rather than conventional screws. These locking head screws support the friction fit established by the compression screws, without adding additional compression and risking implant cut-out by overtightening. Additionally, the angular stability may improve the overall strength of the construction by minimizing forces at the screw-bone interface. The biomechanics of this construction are untested and combining different principles in the same fracture fragment may not take full advantage of either principle [10, 11].

2.5 Special plates

Several special periarticular plates for specific locations have been developed (**Fig 3.2.2-14**). They are shaped anatomically, corresponding to the site where they are to be applied and many have combi-holes, making the plates versatile. These plates approximate average bone morphology and so there can still be a mismatch with individual bones. Depending upon the technique of application (use of locking versus nonlocking screws) manual contouring of these plates may be necessary. Bending near a locking screw hole must be done with caution; there may be deformation of the threads in the locking hole, which might change the screw head locking interface quality [12].

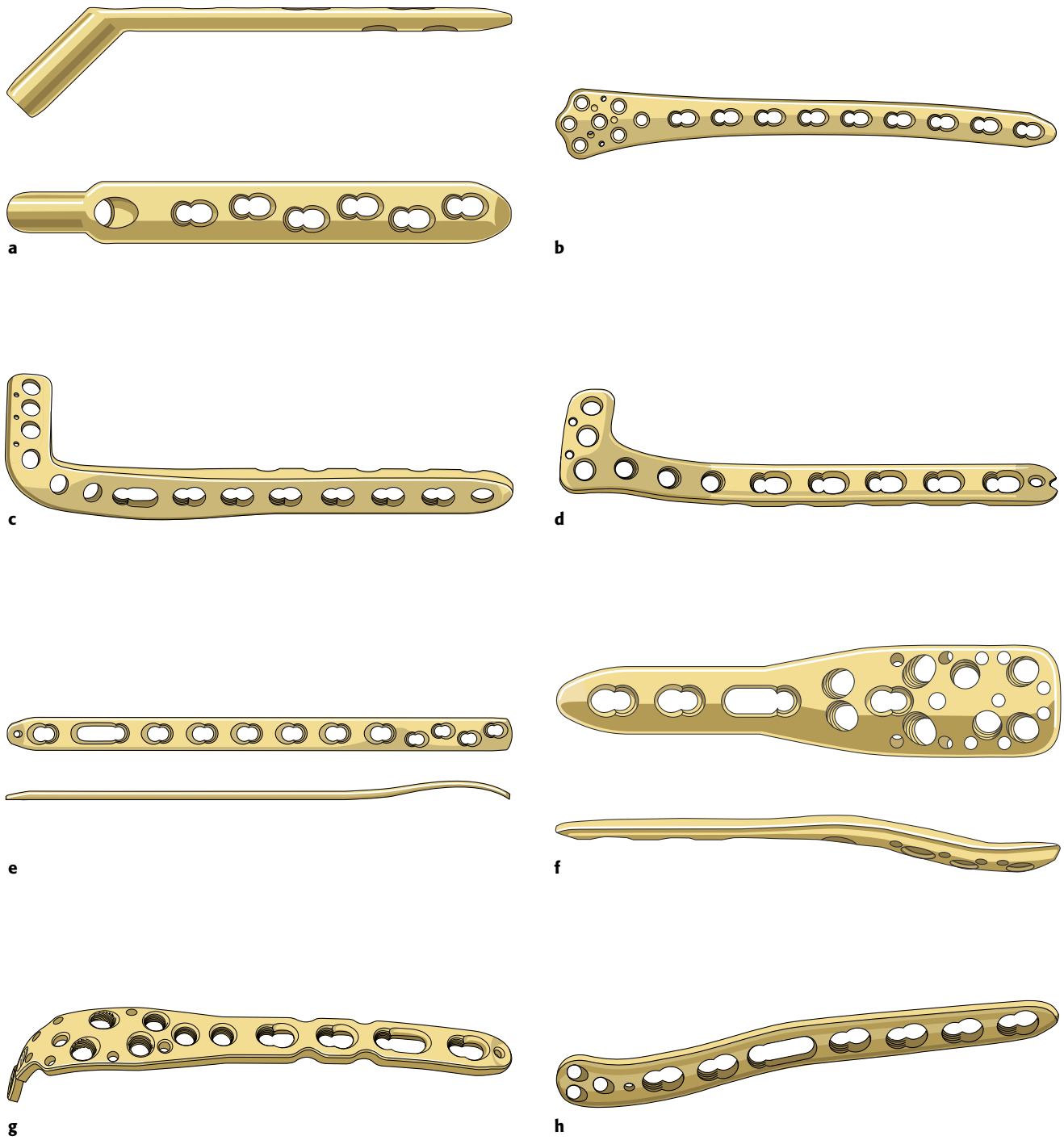

Fig 3.2.2-14a–m Selection of anatomically shaped plates.
a Side plate for DHS
b LCP-DF (distal femur)
c LCP anterolateral distal tibia
d LCP proximal tibia
e LCP metaphyseal plate
f PHILOS (proximal humerus)
g LCP olecranon plate
h LCP distal humerus

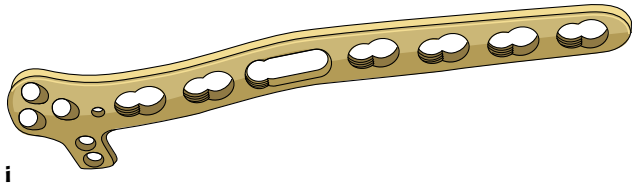

i

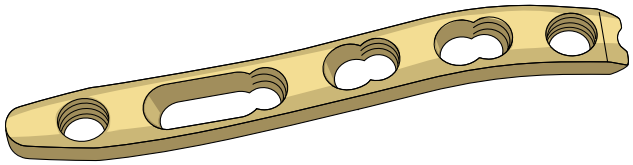

j

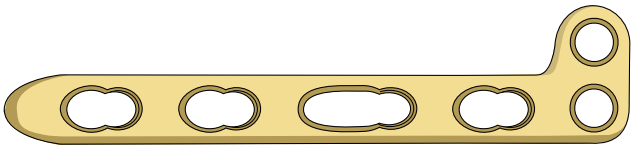

k

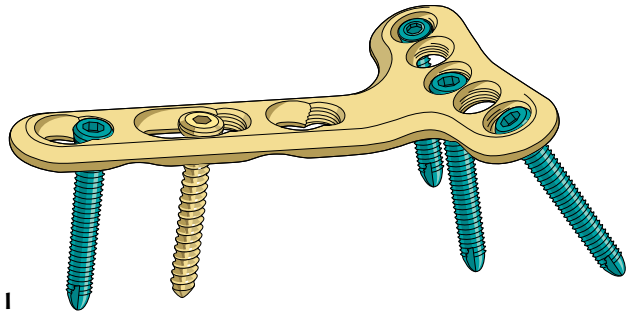

l

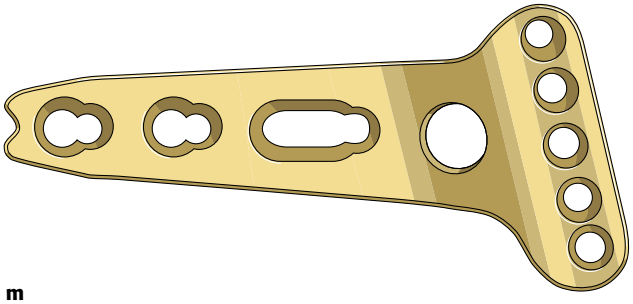

m

Fig 3.2.2-14a–m (**cont**) Selection of anatomically shaped plates.
i LCP lateral distal humerus
j–m LCP distal radius

3 Classic principle of absolute stability using plates

Absolute stability of plated fractures requires anatomical reduction and interfragmentary compression. This can be established by lag screws, axial compression by plate, or both. Static compression between two fragments is maintained over several weeks [13] and does not enhance bone resorption or necrosis (**Fig 3.2.2-15**). Fracture fragment interdigitation and compression reduces interfragmentary motion to nearly zero and allows for direct bony remodeling of the fracture (primary bone healing without callus).

To achieve absolute stability, compression must sufficiently neutralize all forces (bending, tension, shear, and rotation) along the whole cross-section of a fracture.

There are four ways of obtaining interfragmentary compression with a plate:

- Compression with the dynamic compression unit in a plate (LC-DCP)
- Compression by contouring (overbending) the plate
- Compression by lag screws through plate holes
- Compression with the articulated tension device

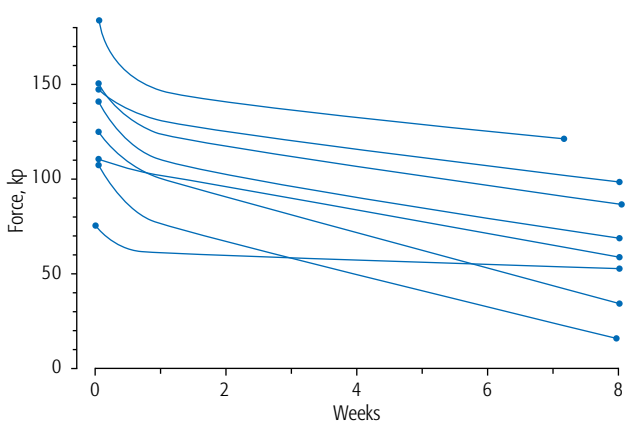

Fig 3.2.2-15 Compression applied to cortical bone in vivo. The compression force decreases slowly. This pattern of change in compression indicates that pressure necrosis with surface resorption in the compressed area does not occur.

3.1 Absolute stability by lag screw and protection plate

Simple fracture patterns treated with plate fixation are best reduced anatomically and fixed with a technique of absolute stability using a combination of lag screws and protection plate (**Fig 3.2.2-16**). A protection plate reduces the load placed upon an interfragmentary screw fixation, protecting it from failure. In metaphyseal split fractures, lag screw fixation often needs to be combined with a buttress plate to protect these screws from shearing forces. Plate contour should be accurate when using an LC-DCP for screw protection function, as a poorly contoured plate applied with nonlocking screws will cause translation of the bone toward the plate and create fracture displacement or loss of lag screw purchase. An LCP with all locking screws can also provide protection and may be a better choice when accurate plate contour cannot be achieved. A lag screw correctly inserted in good bone generates forces up to 3,000 N. Since the same effect cannot be brought about by any of the methods listed below, lag screws should be used whenever the fracture pattern permits.

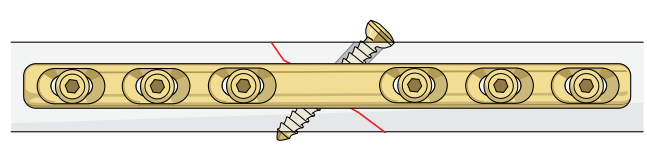

Fig 3.2.2-16 Lag screw osteosynthesis with a protection plate is shown. Interfragmentary compression is achieved by a lag screw. The function of the plate is to prevent the lag screw from bending, shear, and rotational forces. Lag screws may be placed independently or inserted through a plate.

A lag screw can be placed either by itself or through a plate. To avoid any additional soft-tissue stripping, placement through the plate is preferred.

In the case of a wedge fragment opposite to the plate, the fragment should be reduced with the aid of pointed hooks or a pointed reduction forceps (**Fig 3.2.2-17**). This has to be done carefully to avoid soft-tissue stripping.

3.2 Compression using the tension device

In transverse or short oblique fractures of the diaphysis, placement of a lag screw is not always possible. The articulated tension device (**Fig 3.2.2-18**) was developed to achieve adequate compression (more than 100 kp) in these instances. Furthermore, it is recommended for fractures of the femoral or humeral shaft, when the gap to be closed exceeds 1–2 mm, as well as for the compression of osteotomies and nonunions. Most plates have a notch at either end, which fits the hook of the tension device. Before use, the two branches of the tension device should be opened completely. After fixation of the plate to one main fragment, the fracture is reduced and held in position with a reduction forceps. The tension device is now connected to the plate and fixed to the bone by a short cortex screw. For the application of forces of 100–120 kp, or in osteoporotic bone, bicortical fixation is always recommended. In oblique fractures, to prevent displacement, the tension must be applied in such a way that the spike of the mobile fragment is pressed into the axilla that is formed by the plate and the other main fragment to

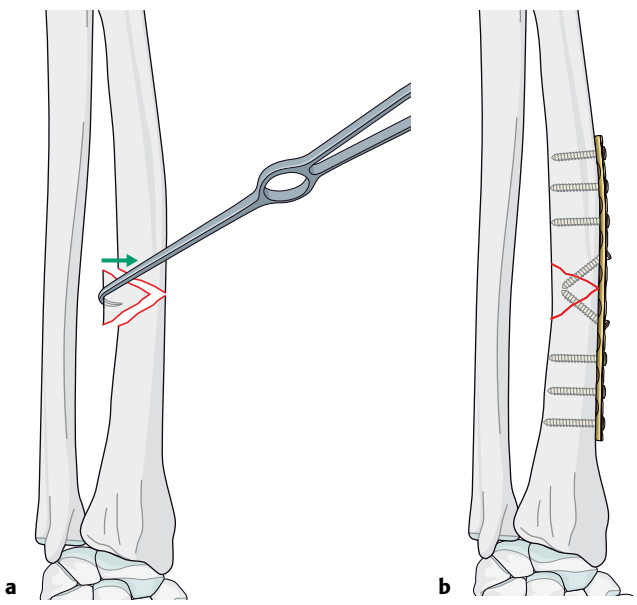

Fig 3.2.2-17a–b
a Bending wedge fracture reduced using dental pick to avoid soft-tissue stripping.
b Fixation with 2.7 mm lag screws through the 3.5 plate.

Fig 3.2.2-18 Articulated tension device. Depending on the position of the hook, the device can be used for distraction or compression.

which it has been fixed (**Fig 3.2.2-19**). Biomechanical studies have shown that the bending and rotational stability of such fractures is greatly increased if a lag screw is added through the plate once axial compression has been established (**Video 3.2.2-4**). For transverse fractures, it is essential that the plate is prebent at the fracture site to prevent eccentric tensioning and a gap at the opposite cortex (**Figs 3.2.2-20–21**).

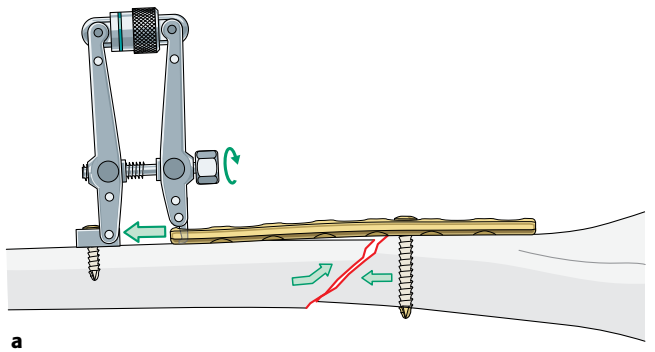

a

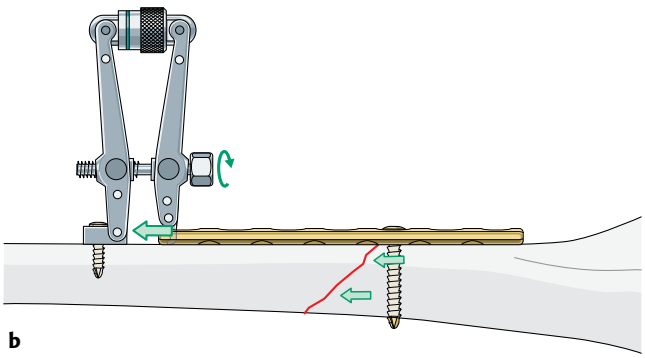

b

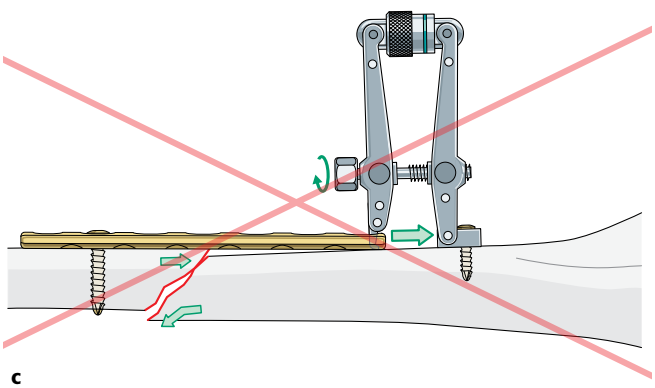

c

Fig 3.2.2-19a–c Application of the articulated tension device.
a–b In oblique fractures the tension device must be applied in such a way that the loose fragment locks in the axilla if compression is produced.
c This figure demonstrates the tension device applied in the wrong position.



Video 3.2.2-4 LCP applied to a simple radial fracture in conventional technique with a lag screw placed through the plate.

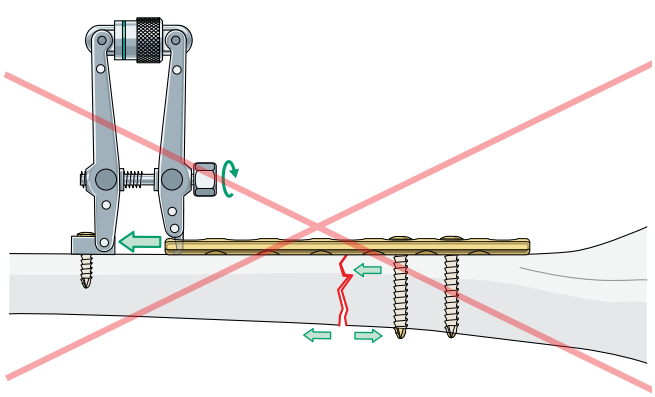

Fig 3.2.2-20 If a straight plate is tensioned on a straight bone, a fracture gap opens up due to the eccentric forces acting on the opposite side.

3.3 Compression by overbending

If a straight plate is applied to a straight bone, compressive forces are highest directly underneath the plate. At the far cortex a small gap results due to tension (**Fig 3.2.2-20**). This may prevent adequate concentric compression across the entire fracture surface. If the placement of an additional lag screw is not possible, prebending of the plate is essential (**Fig 3.2.2-21**). By applying tension, the overbent plate is straightened, which leads to compression of the opposite cortex, thereby adding to stability. There are special instruments available for prebending or contouring plates (**Fig 3.2.2-22**).

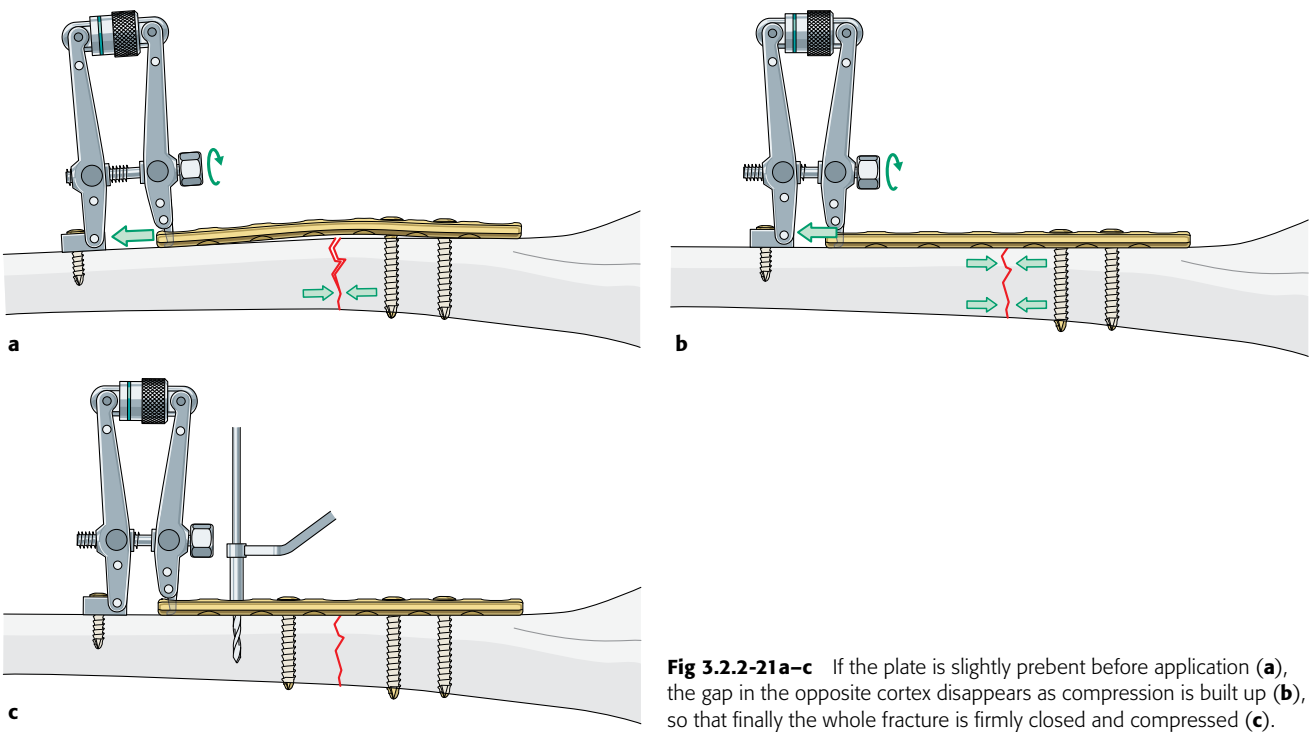

Fig 3.2.2-21a–c If the plate is slightly prebent before application (**a**), the gap in the opposite cortex disappears as compression is built up (**b**), so that finally the whole fracture is firmly closed and compressed (**c**).

Fig 3.2.2-22 The handheld bending pliers are useful and its correct use is shown in **Video 3.2.2-5**.

3.4 Compression using the LC-DCP (dynamic compression principle)

Axial compression can also be generated with the LC-DCP. However, the compression force achievable is lower than with the tension device. Prebending of the plate is necessary to obtain even distribution of the compressive forces.

3.5 Contouring of plates

Straight plates often need to be contoured before application to fit the anatomy of the bone. If this is not done, the reduction may be lost; especially if no lag screws are placed across the fracture. Anatomically shaped plates (see section 2.5 in this chapter) may also require fine contouring before application. This is best done with handheld bending pliers (**Fig 3.2.2-22**), the bending press, or bending irons (**Video 3.2.2-5**). If complex 3-D contouring is required, special flexible templates are available that can be modeled to the bone surface (**Fig 3.2.2-23**). Repeated bending back and forth should be avoided, as this weakens the plate. The LCP should be contoured by bending at an area away from the thread hole.

4 Different functions of plates

It is important to emphasize that each time a plate is used, the surgeon determines how a plate will function. Plates can be used in at least six different ways:

- Compression
- Protection
- Buttress
- Tension band
- Bridging
- Reduction

While the LCP also can be used as an internal fixator to bridge a fracture.

4.1 Compression and protection plates

The use of compression and protection plates has been described in detail (see section 3.1 in this chapter).

Video 3.2.2-5 Accurate contouring of plates requires correct use of tools, such as the bending press.

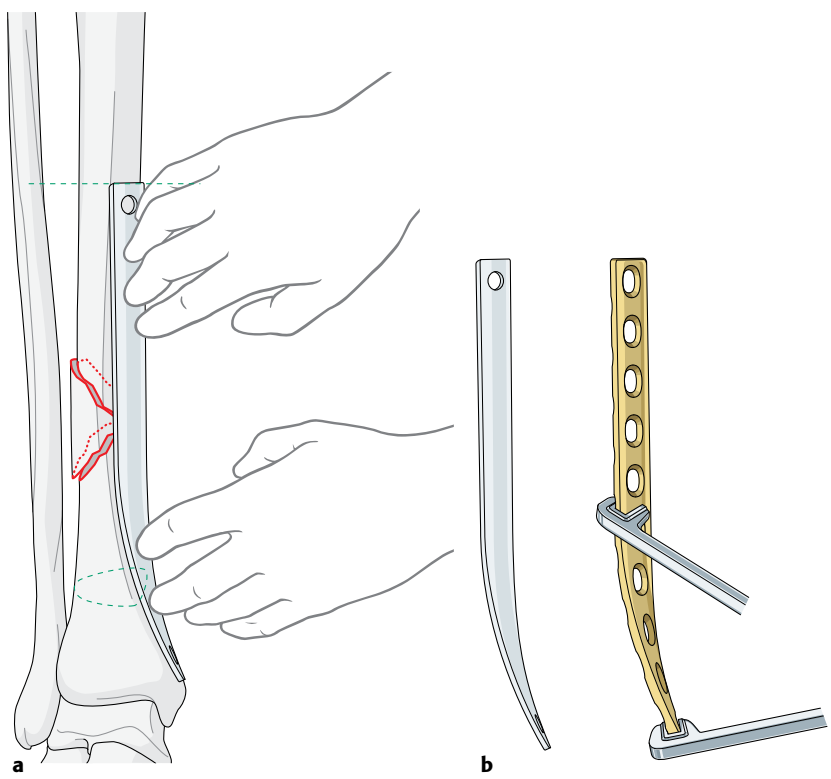

Fig 3.2.2-23a–b Flexible templates are used to facilitate plate contouring.

4.2 Buttress/antiglide plate

A buttress plate resists axial load by applying force at 90° to the axis of potential deformity.

In a metaphyseal shear or split fracture, fixation with lag screws alone is often insufficient. A lag screw should therefore be combined with a plate with buttress function (**Video 3.2.2-6**). This will protect the screw from shear forces across the fracture. Plates can be used without lag screws to provide a buttress and, in plates with DC holes the screws should be inserted in the buttress position (**Fig 3.2.2-24**). A buttress is a powerful mechanical construct, as a visit to any medieval cathedral in Europe will demonstrate. If the surgeon has the option of using a buttress, it will usually provide the best fixation.

4.3 Tension band plate

The following four criteria must be fulfilled for a plate to act as a tension band:

- The fractured bone must be eccentrically loaded, eg, femur
- The plate must be placed on the tension (convex) surface
- The plate must be able to withstand the tensile forces
- The opposite cortex must be able to withstand compressive force

The last point is of paramount importance: anatomical reduction of the far cortex is essential and a tension band plate cannot function if the far cortex is in multiple fragments.

Video 3.2.2-6 For application of a buttress plate, the first screw must be eccentric to prevent sliding of the plate.

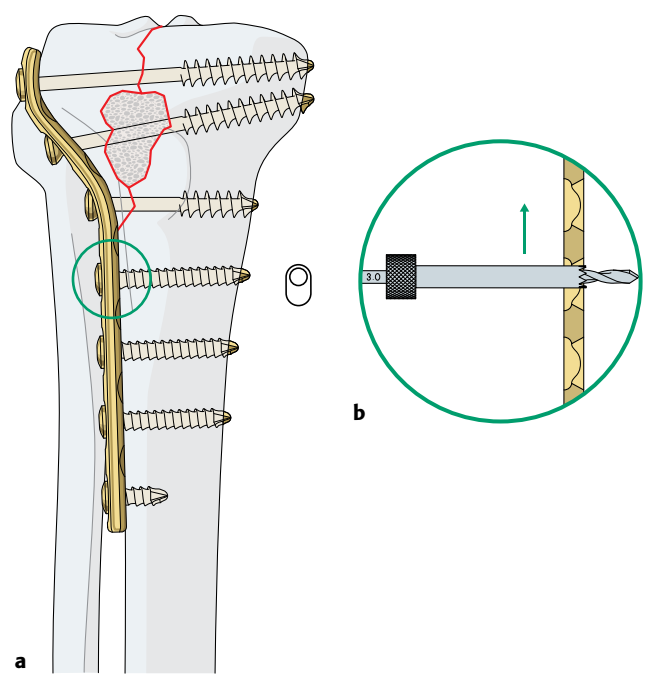

Fig 3.2.2-24a–b
a Application of the DCP in buttress function.
b To prevent any sliding of the plate, the screw is placed as proximal as possible in the hole.

The function of a tension band is to convert tensile force into compressive force. After fracture reduction, the opposite cortex must provide a bony buttress to prevent cyclic bending and failure of fixation.

A good example of an eccentrically loaded bone is the femur (**Fig 3.2.2-25**). If a plate is placed on the lateral (tension) side of a transverse fracture, the distraction forces are converted to compressive forces across the whole fracture interface provided the medial cortex is intact. If the same plate is placed medially, it cannot counteract the tensile force and the fixation will fail under load (see chapter 3.2.3).

4.4 Bridging plate

To respect the biology of a complex multifragmentary fracture and to minimize any additional soft-tissue injury, the bridge plating principle may be applied. Bridging plates provide relative stability and fracture healing occurs by callus formation.

The key concept of bridge plating is that the plate is fixed only to the two main fragments leaving the fracture zone untouched to maximize the blood supply.

If feasible, the fracture should be reduced indirectly and bridge plates should be applied through minimal exposure to restore length, axial alignment, and rotation [14]. Bridging plates are discussed in detail in chapter 3.3.2.

There are some important biomechanical principles to consider when using this technique. To maximize implant stability in this flexible fixation, long plates with few screws should be used to increase the lever arm and distribute the bending forces [15, 16]. A plate length of more than three times the fracture length in multifragmentary fractures, and more than eight to ten times the fracture length in simple fractures has been taught [9]. Screw to plate hole ratios of less than 0.5 create a long lever arm and decrease the bending loads on the distal screws [9]. In addition, a span of at least

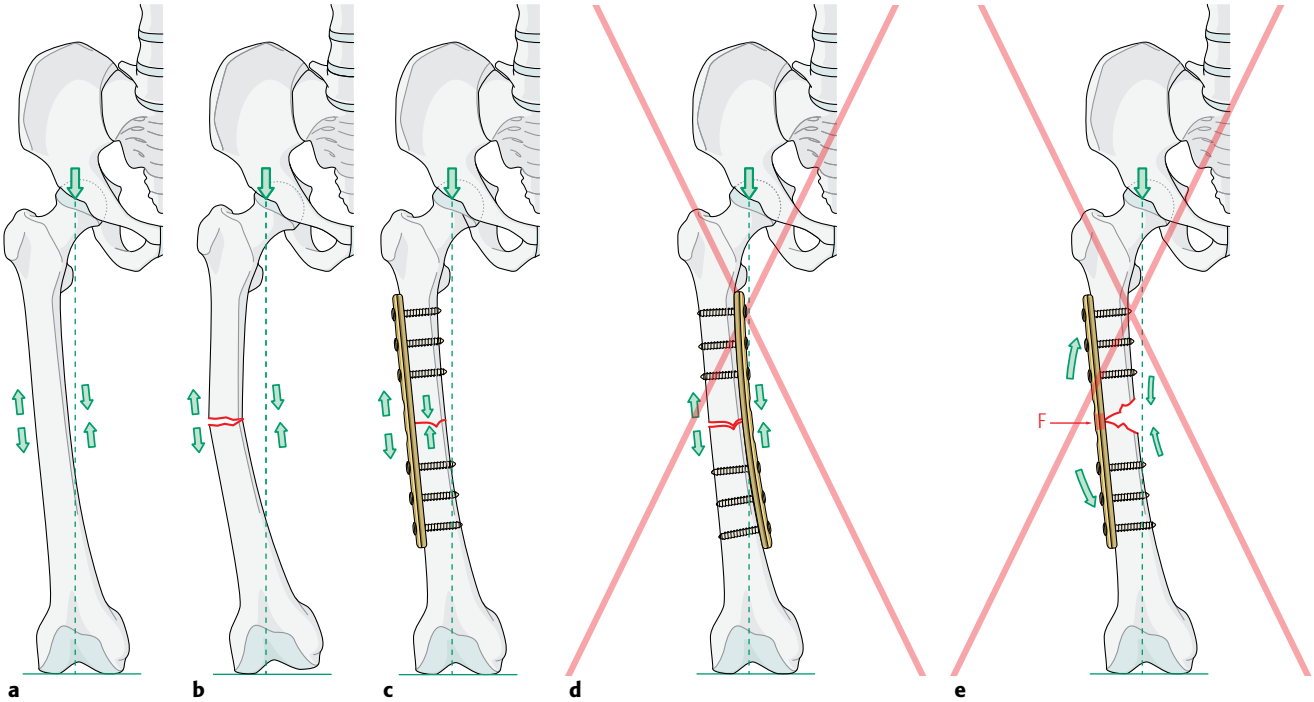

Fig 3.2.2-25a–e Tension band principle at the femur.
a The intact femur is an eccentrically loaded bone with distraction or tensile forces laterally and compression on the medial side.
b In case of a fracture, the lateral fracture gap opens, whereas the medial is compressed.
c A lateral plate is under tension when loaded, thereby compressing the fracture gap, provided there is bone contact medially.
d If the plate is placed onto the compression side, it is not able to prevent opening of the lateral gap (instability).
e If the medial cortex is not intact, the tension band principle cannot work because of lack of a buttress (see chapter 3.2.3). Both these situations (**d–e**) must be avoided.

two or three screw holes should be left open over the fracture to decrease stress concentration (**Fig 3.2.2-26**, **Video 3.2.2-7**) [9, 15]. If the vascularity of the bone and surrounding soft tissue has not been overly disturbed, the physiological response to this relatively flexible construction is callus formation that bridges the fragments, as occurs in nonoperative treatment or after intramedullary nailing.

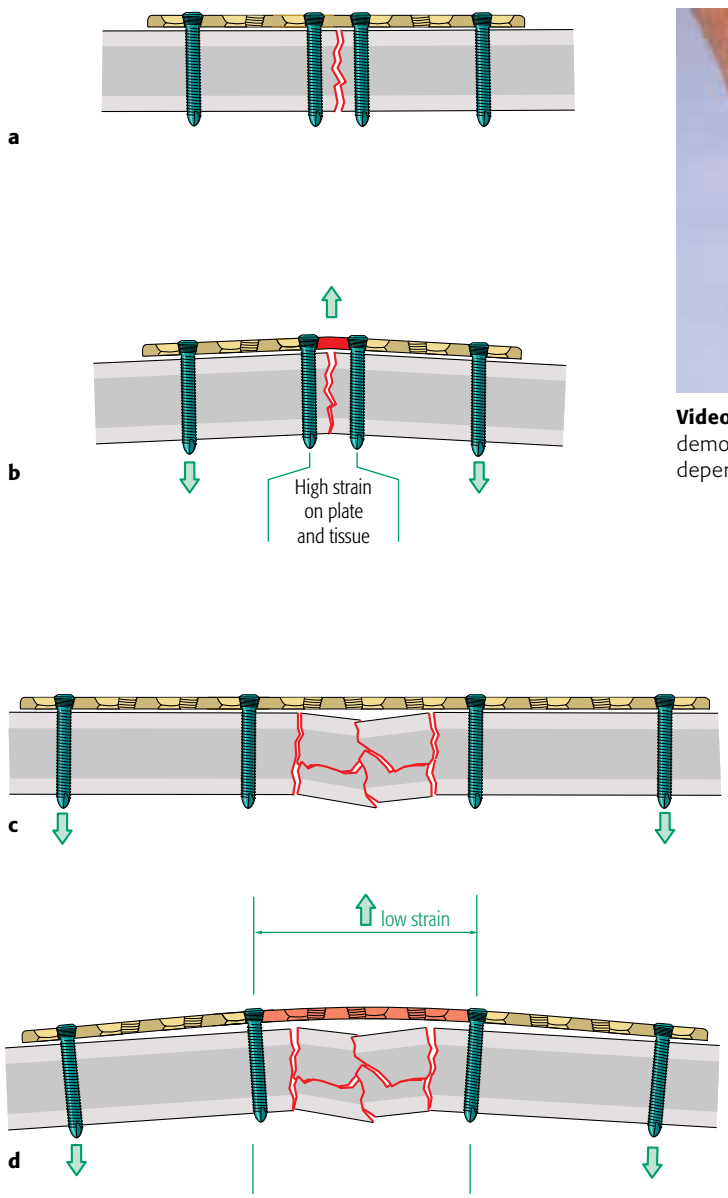

Fig 3.2.2-26a–d
a–b In a simple transverse fracture a short segment of the plate undergoes deformation (shown in red) due to high strain on the plate and tissue.
c–d In multifragmentary fractures, bridging is best done with long plates. In such a case the spanned segment is longer and a force such as shown in **a–b** is distributed over a longer distance. The strain on the plate is lower and its resistance to fatigue is higher [15].

Video 3.2.2-7 Credit card being stressed by two different methods demonstrates low strain and high strain in a dynamic system depending upon where the fixation is placed.

4.5 Reduction plate

The classic example of a reduction plate is the 95° angled blade plate applied with a plate first technique (**Fig/Animation 3.2.2-27**). With planning and accurate insertion, a fixed angle plate can correct multiple planes of displacement as it is transfixed above and below a fractured zone or deformity. Smaller caliber reduction plates (small fragment and mini-fragment size) are also used for reduction of transverse diaphyseal fractures, such as mid-shaft humeral fractures or clavicle fractures (**Fig 3.2.2-28**). Extreme care must be taken when using plates for reduction that significant additional dissection is not performed just to apply the reduction plates, as the least invasive reduction technique should always be selected. Small or mini-fragment plates are also frequently used to achieve and hold reductions of short metaphyseal segments or open diaphyseal fractures during intramedullary nailing procedures, especially in the tibia [17]. These plates should also be applied with caution as principles of preservation of local biology and soft-tissue management should be maintained. The decision to use locking or nonlocking plates should be based on bone quality for these applications; unicortical (intracortical) nonlocking screws can be placed to stay clear of the path an intramedullary nail then later converted to bicortical screws around the nail. The decision to leave the reduction plate should also be tailored to the application. Frequently plates used for metaphyseal reduction are left in place since they do not change the selected mode of stability (relative stability with intramedullary device). However, diaphyseal reduction plates are almost always removed since there is a risk that these plates might either fix a small gap between the bone segments or might limit the dynamic bone compression that is achieved with intramedullary load sharing of simple fracture patterns [17].

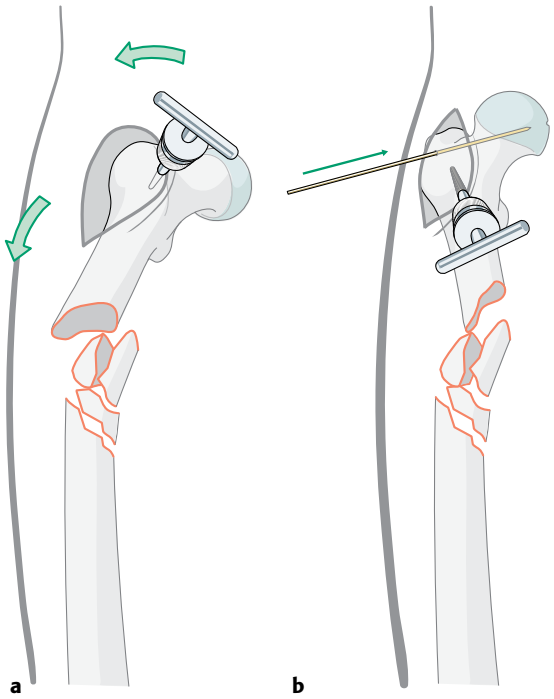

Fig/Animation 3.2.2-27a–e MIPO of proximal femoral fractures using the 95° condylar blade plate.

a The Schanz screw is inserted to counteract the muscle pull and to keep the proximal femur in AP position. Care must be taken that the Schanz screw does not interfere with the preparation of the chiseled canal.

b A guide wire is inserted at a 95° angle in the AP view with correct anteversion in the lateral view. The position of the guide pin is checked using image intensifier.

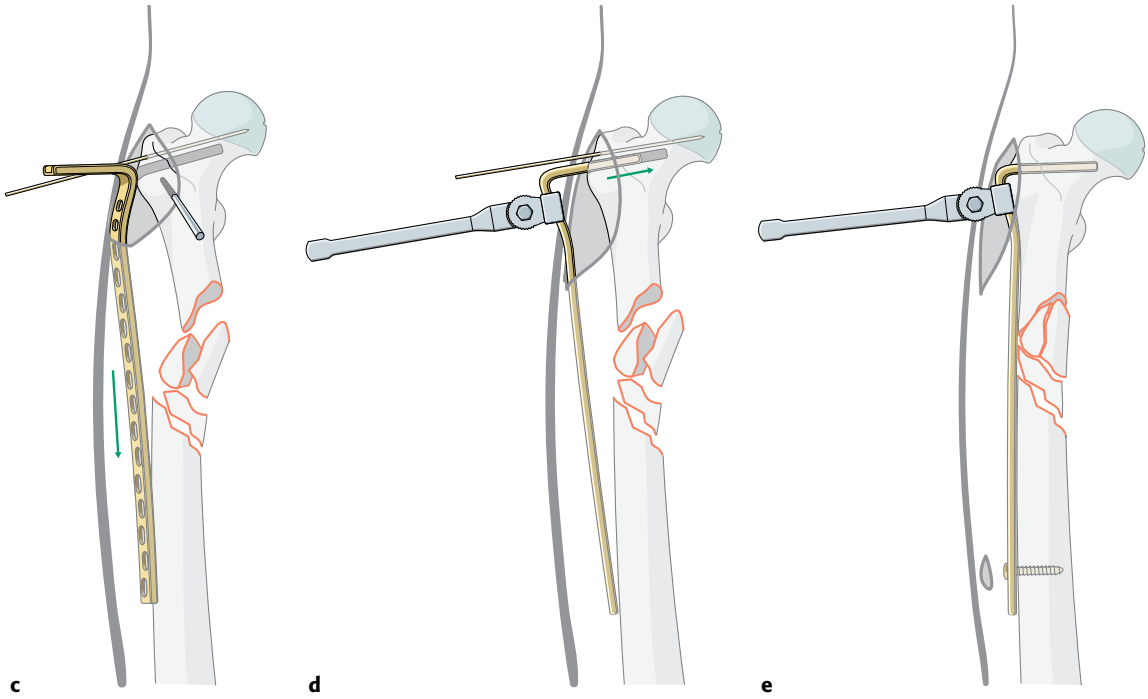

Fig/Animation 3.2.2-27a–e (cont) MIPO of proximal femoral fractures using the 95° condylar blade plate.

c After the canal has been prepared, the condylar plate is slipped under the vastus lateralis muscle with the blade facing laterally. The guide wire is kept as a reference for the direction of canal.

d–e The blade is turned 180° and inserted into the prepared canal using a plate holder. In some cases, the Schanz screw can be used to manipulate the proximal femur during blade insertion. Application of the distal screw will reduce the bone to the plate.

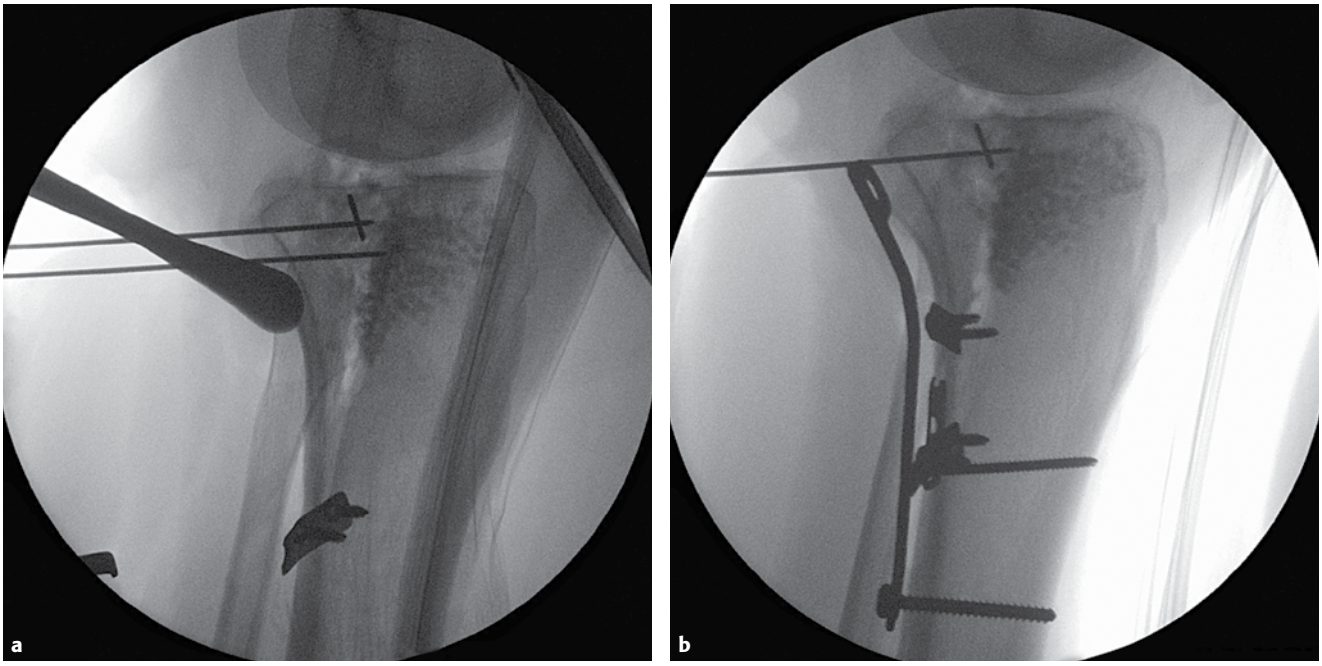

Fig 3.2.2-28a–b Lateral intraoperative images of posterior approach to a proximal tibial plateau fracture. Short, 3-hole one-third tubular plates have been applied with unicortical screws to help with reduction.

Classic references | Review references

5 References

1. **Miclau T, Martin RE.** The evolution of modern plate osteosynthesis. *Injury.* 1997;28(Suppl 1):A3–6.
2. **Perren SM.** Evolution of the internal fixation of long bone fractures. The scientific basis of biological internal fixation: choosing a new balance between stability and biology. *J Bone Joint Surg Br.* 2002 Nov;84(8):1093–1110.
3. **Schmal H, Strohm PC, Jaeger M, et al.** Flexible fixation and fracture healing: do locked plating "internal fixators" resemble external fixators? *J Orthop Trauma.* 2011 Feb;25(Suppl 1):S15–20.
4. **Bottlang M, Feist F.** Biomechanics of far cortical locking. *J Orthop Trauma.* 2011 Feb;25 Suppl 1:S21–28.
5. **Perren SM, Cordey J, Rahn BA, et al.** Early temporary porosis of bone induced by internal fixation implants. A reaction to necrosis, not to stress protection? *Clin Orthop Relat Res.* 1988 Jul;(232):139–151.
6. **Perren SM, Klaue K, Pohler O, et al.** The limited contact dynamic compression plate (LC-DCP). *Arch Orthop Trauma Surg.* 1990;109(6):304–310.
7. **Davis C, Stall A, Knutsen E, et al.** Locking plates in osteoporosis: a biomechanical cadaveric study of diaphyseal humerus fractures. *J Orthop Trauma.* 2012 Apr;26(4):216–221.
8. **Gardner MJ, Brophy RH, Campbell D, et al.** The mechanical behavior of locking compression plates compared with dynamic compression plates in a cadaver radius model. *J Orthop Trauma.* 2005 Oct;19(9):597–603.
9. **Wagner M, Frigg R.** *Internal Fixators—Concepts and Cases Using LCP and LISS.* New York: Thieme; 2006.
10. **Haidukewych GJ, Ricci W.** Locked plating in orthopedic trauma: a clinical update. *J Am Acad Orthop Surg.* 2008 Jun;16(6):347–355.
11. **Anglen J, Kyle RF, Marsh JL, et al.** Locking plates for extremity fractures. *J Am Acad Orthop Surg.* 2009 Jul;17(7):465–472.
12. **Gallagher B, Silva MJ, Ricci WM.** Effect of off-axis screw insertion, insertion torque and plate contouring on locked screw strength. *J Orthop Trauma.* 2014 Jul;28(7):427–432.
13. **Perren SM, Huggler A, Russenberger M, et al.** The reaction of cortical bone to compression. *Acta Orthop Scand Suppl.* 1969;125:19–29.
14. **Mast JW, Jakob R, Ganz R.** *Planning and Reduction Technique in Fracture Surgery.* 1st ed. Springer-Verlag: Berlin; 1989.
15. **Gautier E, Sommer C.** Guidelines for the clinical application of the LCP. *Injury.* 2003 Nov;34 Suppl 2:B63–76.
16. **Acharya AV, Evans SL.** Does placing screws off-centre in tubular bone alter their pullout strength? *Injury.* 2009 Nov;40(11):1161–1166.
17. **Dunbar RP, Nork SE, Barei DP, et al.** Provisional plating of type III open tibia fractures prior to intramedullary nailing. *J Orthop Trauma.* 2005 Jul;19(6):412–414.

6 Acknowledgments

We thank Dean Lorich and Michael Gardner for their contribution to this chapter in the second edition of the *AO Principles of Fracture Management.*

3.2.3 Tension band principle

Markku Nousiainen

1 Biomechanical principles

Early concepts of load transfer within bone were developed and described by Frederic Pauwels [1]. He observed that a curved, tubular structure under axial load always has a compression side as well as a tension side (**Fig/Animation 3.2.3-1**). From these observations, the principle of tension band fixation evolved.

A tension band converts tensile force into compression force at the opposite cortex. This is achieved by applying a device eccentrically, on the convex side of a curved bone.

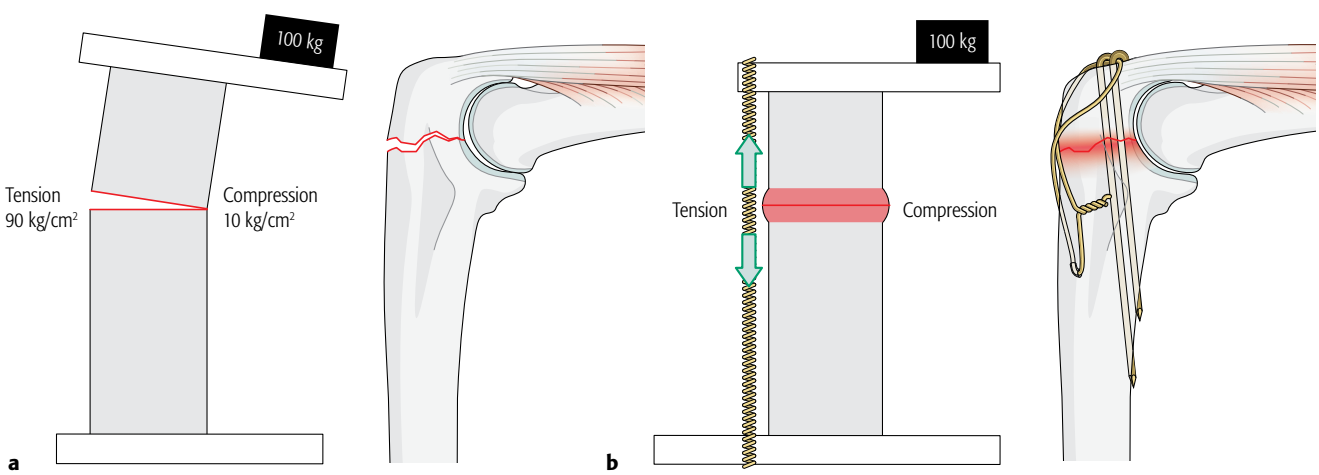

Fig/Animation 3.2.3-1a–b The tension band principle.
a An eccentrically loaded bone has a tension and a compression side.
b A tension band converts tension into compression at the opposite cortex.

The concept can most easily be understood by examining the femur under mechanical load (**Fig 3.2.3-2**). If a fracture is to unite, it requires mechanical stability, which is obtained by compression of the fracture fragments. Conversely, distraction or tension interferes with fracture healing. Therefore, tension force on a bone must be neutralized or, ideally, converted into compression force to promote fracture healing. This is especially important in articular fractures, where stability is essential for early motion and good functional outcome. In fractures where muscle pull tends to distract the fragments, such as fractures of the patella or olecranon, the application of a tension band will neutralize

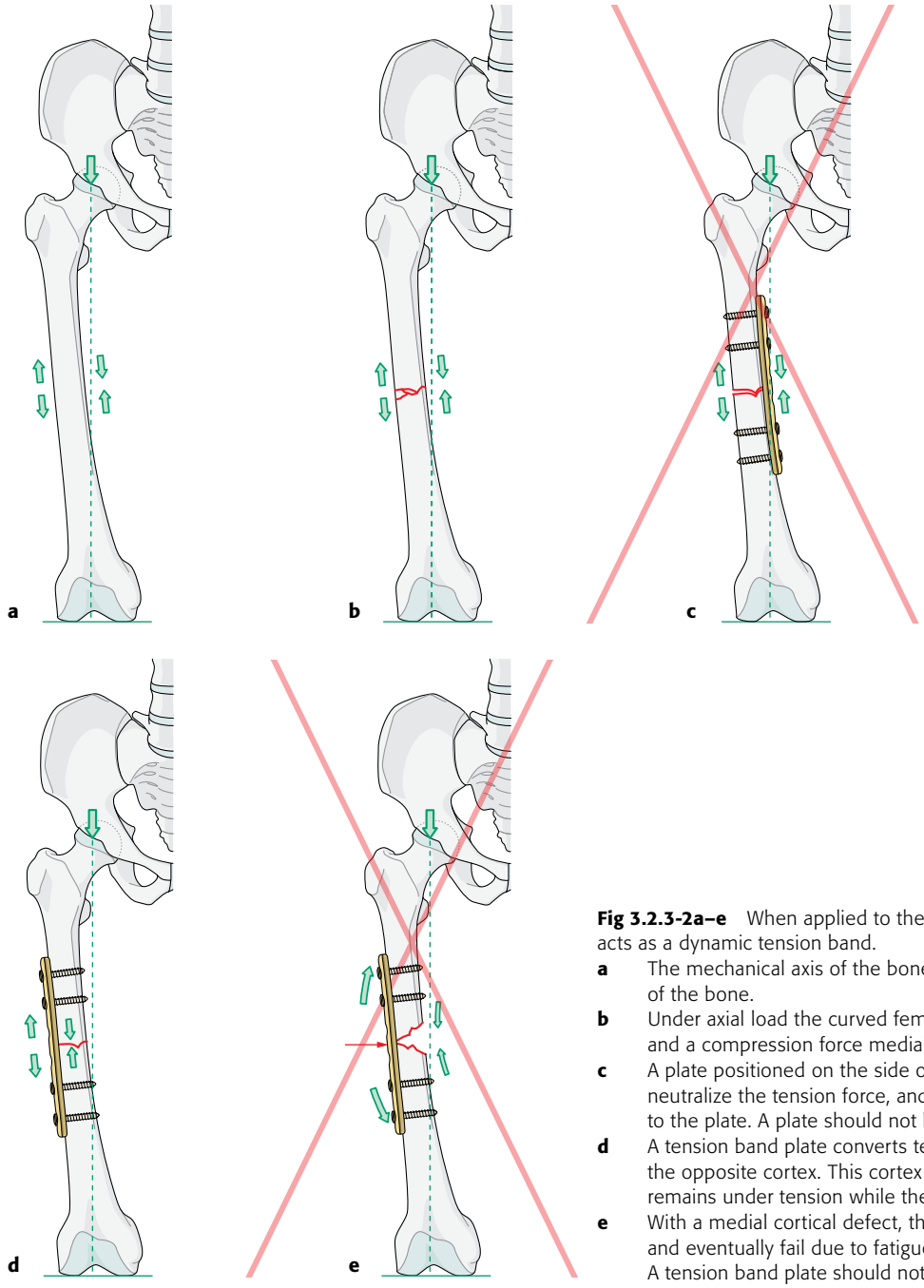

Fig 3.2.3-2a–e When applied to the tension side of the bone, a plate acts as a dynamic tension band.

a The mechanical axis of the bone is not necessarily within the center of the bone.

b Under axial load the curved femur creates a tension force laterally and a compression force medially.

c A plate positioned on the side of compressive forces cannot neutralize the tension force, and gapping will be observed opposite to the plate. A plate should not be applied in this position.

d A tension band plate converts tensile force into compression on the opposite cortex. This cortex must provide a buttress. The plate remains under tension while the bone is compressed.

e With a medial cortical defect, the plate will undergo bending stresses and eventually fail due to fatigue at a specific point (arrow). A tension band plate should not be used in this situation.

these forces and even convert them into compression when the joint is flexed (**Fig 3.2.3-3a–b**). This is accomplished through the creation of a "hinge" at the side of the fracture occupied by the tension band construct. The subsequent application of distraction forces rotates the fracture around this hinge, producing a compression force opposite to it. Similarly, a bone fragment can be avulsed at the insertion of a tendon or ligament, as in the greater tuberosity of the humerus (**Fig 3.2.3-3c**), the greater trochanter of the femur, or the medial malleolus (**Fig 3.2.3-3d**). Here, too, a tension band can reattach the avulsed fragment, converting tensile forces generated by ligamentous pull into compression forces at the fracture surface.

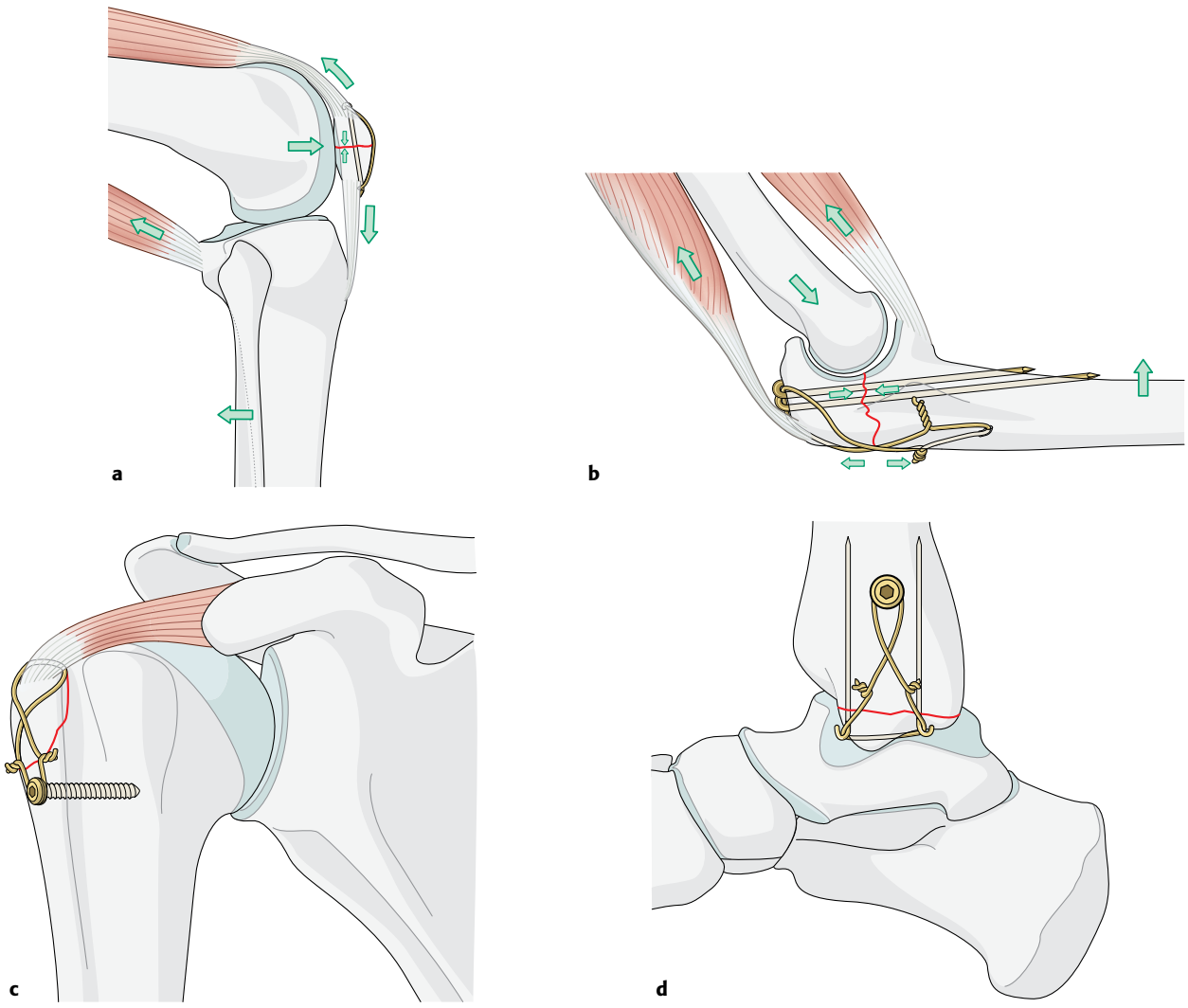

Fig 3.2.3-3a–d

a Tension band principle applied to a fracture of the patella. The figure-of-eight wire loop lies anterior to the patella and fracture. Upon knee flexion, the tensile force (between the quadriceps muscle and the tibial tuberosity) is converted into compression at the articular surface.

b In the olecranon fracture, the figure-of-eight wire loop acts as a tension band during flexion of the elbow. This is an example of a dynamic tension band.

c Application of the tension band principle at the proximal humerus for an avulsion of the greater tubercle. The wire loop is anchored to the humerus by a 3.5 mm cortex screw.

d Application of the tension band principle to the medial malleolus. The wire loop may be anchored to the tibia by a 3.5 mm cortex screw. This is an example of a static tension band.

2 Concepts of application

The tension band principle with wire loops is often applied to articular fractures of the patella and olecranon, converting tension from muscle pull into a compression force on the articular side of the fracture. In addition, small avulsion fractures may benefit from the principles of tension band fixation (**Fig 3.2.3-3c–d**).

The principle of tension band fixation with a plate can also be applied in diaphyseal fractures of curved bones, such as the femoral shaft. Application of a tension band construct to the tension side of the bone neutralizes distraction at this site, while promoting compression on the opposite side of the bone.

In curved long bones, the convex side of the diaphysis indicates the tension side.

Similarly, in delayed union or in nonunion, where the presence of angular deformity creates a tension side in the bone, adherence to the tension band mechanical principles is extremely important.

Whenever feasible, any internal or external fixation device should be applied to the tension side [2].

Bony union will then consistently occur. Loops of wire, cables, as well as absorbable or nonabsorbable suture material can function as a tension band. When appropriately placed, intramedullary nails, plates, and external fixators can also fulfill the function of a tension band (**Fig 3.2.3-4**).

Fig 3.2.3-4a–d Clinical example of a plate acting as a tension band in a nonunion after intramedullary nailing of a femoral nonunion.
a–b Symptomatic nonunion with broken nail—note the hypertrophic area around the fracture site.
c–d After removal of the intramedullary nail, a tension band plate was applied on the lateral or convex side of the femur without bone grafting, and weight bearing was encouraged. The nonunion consolidated.

A tension band that produces compression at the time of application is called a static tension band, as the forces at the fracture site remain fairly constant during movement.

Tension band application to the medial malleolus is an example of a static tension band (**Fig 3.2.3-3d**).

If the compression force increases with motion, the tension band is a dynamic one.

A good example is the application of the tension band principle to a fracture of the patella. Upon knee flexion, the increased tensile force is converted to compression force (**Fig 3.2.3-3a**, **Fig 3.2.3-5**).

Fig 3.2.3-5a–f A transverse patellar fracture treated successfully with open reduction and internal fixation using a modified tension band technique.

a–b Preoperative AP and lateral views of a transverse patellar fracture amenable to tension band fixation.

c–d Early postoperative views of the tension band construct. Note the placement of K-wires parallel and close to the articular surface. The tension band has been tightened with a double twist to ensure even tension across both sides of the construct.

e–f Late postoperative x-rays demonstrating fracture union. Patient achieved a full return of knee strength and range of motion.

3 Operative technique

Fractures that are subject to distraction forces are at risk of displacement if movement occurs, eg, the patella upon knee flexion or the greater tuberosity of the humerus during contraction of the supraspinatus muscle. By applying a figure-of-eight or a simple loop to the anterior aspect of the patella, and by obtaining good purchase within the insertions of the tendons at either end of the patella, an excellent tension band mechanism is created, which compresses the fracture under dynamic load (**Fig/Animation 3.2.3-6**). The 1.0 or 1.2 mm wire must be anchored as close to the bone as possible. It should be directed through the insertion of the tendons with a large gauge needle (**Fig 3.2.3-3a**). Cannulated screws may also be used in the application of a patellar tension band wire. In this case, two cannulated screws provide interfragmentary compression and a transosseous pathway for the tension band's vertical limbs (**Fig 3.2.3-7**).

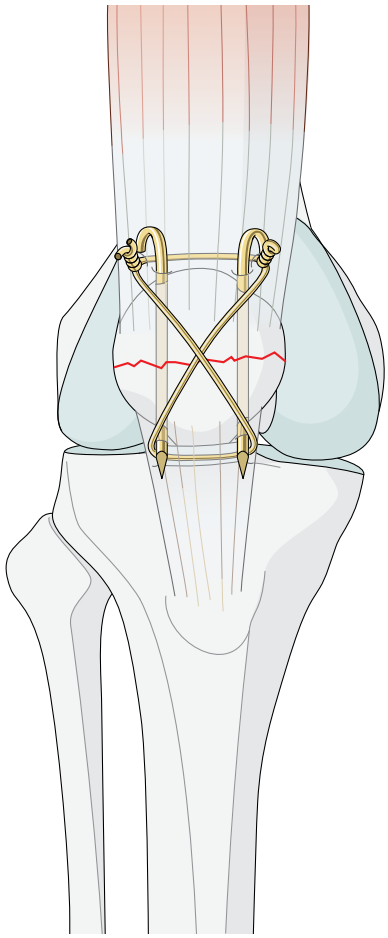

Fig/Animation 3.2.3-6 Technique for tension band wiring of the patella. A wire is placed beneath the quadriceps tendon as close to the patella as possible. The wire is crossed in a figure-of-eight fashion across the patella and placed beneath the patellar tendon to complete the tension band. The construct is tightened via simultaneous wire twists on both sides of the patella.

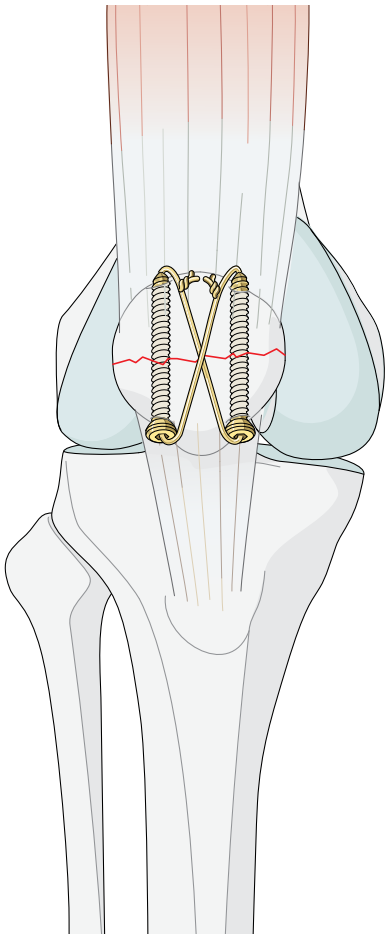

Fig 3.2.3-7 Cannulated screws used in the application of a patellar tension band wire.

In olecranon fractures, the tension band loop is placed through a 2 mm drill hole in the proximal ulna (**Fig 3.2.3-3b**), while in the proximal humerus or medial tibia, a screw head may serve as an anchor (**Fig 3.2.3-3c–d**). A plate or external fixator that functions according to the tension band principle must be applied to the tension side of the bone or the convex side of a deformity or nonunion (**Fig 3.2.3-4**).

The following prerequisites are essential for a tension band fixation:

- Fracture pattern or bone that is able to withstand compression
- Intact cortical buttress opposite to the tension band construct
- Fixation construct that withstands tensile forces

Traditionally, stainless steel wire has been used for tension band fixation; braided metal cables have become popular because of their strength and ease of tightening. The use of nonabsorbable braided polyester suture has been studied and is the mechanical equivalent of 1.25 mm diameter stainless steel wire, with similar healing rates and fewer hardware complications [3, 4]. Biodegradable implants have been applied with success and potentially minimize the complication of painful hardware and decrease the need for implant removal [5]. Nevertheless, biodegradable materials may produce an acute inflammatory soft-tissue reaction that can resemble an infection.

4 Pitfalls and complications

The most common complications are K-wire loosening, prominent hardware, implant failure, and early fracture displacement [6–8].

A wire under tension is strong; however, if bending forces are added, it will break due to fatigue. This principle of fatigue failure also holds true for plates.

In patellar fractures treated with tension band wiring techniques, early fracture displacement has been attributed to nonparallel K-wire placement, poor wire tensioning techniques, and cerclage wires placed too far from the bone to attain solid fixation [9, 10]. These factors allow for fracture displacement with early knee motion. K-wire “back-out” in patellar fixation can be prevented by bending the proximal end posteriorly and impacting it into the proximal cortex of the patella. Tension band wiring through cannulated screws has demonstrated numerous advantages over the modified tension band, including reduced fracture gapping, greater load to failure, and lower hardware removal rates [9, 11].

In simple diaphyseal fractures undergoing plate fixation, the plate should be placed on the tension side of the bone, assuming that the opposite cortex is able to withstand compression forces (**Fig 3.2.3-2c–d**). When the cortex opposite the plate is comminuted, the plate is exposed to repeated bending stress, which invariably will lead to plate breakage if the fracture does not unite rapidly. Early bone grafting may be required to create enough strength to withstand compression forces along the cortex opposite to the plate.

Classic references | Review references

5 References

1. **Pauwels F.** *Biomechanics of the Locomotor Apparatus.* 1st ed. Berlin Heidelberg New York: Springer-Verlag; 1980.
2. **Stoffel K, Klaue K, Perren SM.** Functional load of plates in fracture fixation in vivo and its correlate in bone healing. *Injury.* 2000 May;31 Suppl 2:S-37–50.
3. **Patel VR, Parks BG, Wang Y, et al.** Fixation of patella fractures with braided polyester suture: a biomechanical study. *Injury.* 2000 Jan;31(1):1–6.
4. **Chen C, Huang H, Wu T, et al.** Transosseous suturing of patellar fractures with braided polyester: a prospective cohort with a matched historical control study. *Injury.* 2013 Oct;44(10):1309–1313.
5. **Chen A, Hou C, Bao J, et al.** Comparison of biodegradable and metallic tension-band fixation for patella fractures: 38 patients followed for 2 years. *Acta Orthop Scand.* 1998 Feb;69(1):39–42.
6. **Hung L, Chan K, Chow Y, et al.** Fractured patella: operative treatment using the tension band principle. *Injury.* 1985 Mar; 16(5):343–347.
7. **Kumar G, Mereddy PK, Hakkalamani S, et al.** Implant removal following surgical stabilization of patella fracture. *Orthopedics.* 2010 May;33(5).
8. **Smith S, Cramer K, Karges D, et al.** Early complications in the operative treatment of patella fractures. *J Orthop Trauma.* 1997 Apr;11(3):183–187.
9. **Carpenter J, Kasman R, Patel N, et al.** Biomechanical evaluation of current patella fracture fixation techniques. *J. Orthop Trauma*. 1997 Jul; 11(5): 351–356.
10. **Schneider M, Nowak T, Bastian L, et al.** Tension band wiring in olecranon fractures: the myth of technical simplicity and osteosynthetical perfection. *Int Orthop.* 2014 Apr; 38(4):847–855.
11. **Hoshino C, Tran W, Tiberi III J, et al.** Complications following tension-band fixation of patellar fractures with cannulated screws compared with Kirschner wires. *J Bone Joint Surg.* 2013 Apr 3;95(7):653–659.

6 Acknowledgment

We thank David Hak, Steven Sylvester, and Rena Stewart for their contribution to this chapter in the second edition of the *AO Principles of Fracture Management*.

3.3.1 Intramedullary nailing

Martin H Hessmann

1 Types of intramedullary nails

Intramedullary nailing of shaft fractures of the femur, tibia, and humerus is generally accepted as a standard treatment. Indirect reduction and fixation without opening of the fracture site, implant insertion along the mechanical loading axis of the bone, good bone-implant interface and early load sharing to allow weight bearing are clear advantages of intramedullary nailing. The design and application of intramedullary nails have rapidly evolved since the pioneering work of Küntscher in World War II.

1.1 Classic Küntscher nail (tight fitting, reamed, no locking)

The Küntscher nail was a straight, open section nail with a longitudinal slot and no locking holes. Its use was restricted to relatively simple midshaft fractures because stabilization was dependent upon tight contact between the elastic implant and the stiff bone (intramedullary nailing principle) (**Videos 3.3.1-1–2**). Reaming the medullary cavity increases the area of contact between the intramedullary nail and bone and allows insertion of a larger diameter nail. This extends the indication to fractures that are more complex or more proximal or distal to the isthmus in the shaft. However, the reaming process itself has some inherent biological disadvantages, especially when performed excessively. These include a considerable rise in intramedullary pressure and temperature, increasing the risk of bone necrosis and infection. In the past, these disadvantages limited the use of reamed nailing to fractures with only minor soft-tissue injuries.

1.2 Universal nail (tight fitting, reamed, locked)

The addition of interlocking screws to the intramedullary nail, introduced by Grosse and Kempf, enhanced the mechanical properties of the intramedullary implant. It widened the range of indications to include more proximal or distal fractures, as well as more complex and unstable fracture patterns. However, if the fracture is more distal, more proximal, or more complex, its fixation will mainly depend on the interlocking screws and much less on the principle of circular press fit. The length of the bone-implant construction is still effectively maintained because the interlocking screws prevent shortening and rotation. However, the longitudinal slot in the tubular universal nail results in decreased rotational stiffness and can lead to rotational instability, especially with small diameter intramedullary nails.

Video 3.3.1-1 Küntscher nailing as performed in the middle 20th century.

Video 3.3.1-2 Nail types and mechanics of intramedullary fracture fixation.

1.3 Intramedullary nailing with neither reaming nor locking

Several groups in Europe and North America have treated shaft fractures with significant soft-tissue injuries using solid, small diameter, intramedullary nails, which were inserted without reaming, and therefore, loose fitting. Since these implants (Ender nail, Lottes nail, and Rush pins) were thin and could not be locked proximally or distally, longitudinal and rotational instability resulted, especially in complex fractures. Thus, a major disadvantage was the frequent need for additional external stabilizers, such as plaster casts.

1.4 Intramedullary nailing without reaming but with mandatory locking (unreamed solid or cannulated nails)

There was an obvious need for a small diameter intramedullary nail that could be locked. The absence of a longitudinal slot considerably increases the torsional stiffness of the tubular implant, and also reduces capacity to adapt to the shape of the bone. If the insertion site is not optimal, or the shape and radius of the intramedullary canal diverge from those of the intramedullary nail's geometry, a proper fit may be a problem. With a smaller diameter (ie, 9 mm) in the femur, the material strength of the intramedullary nail must be reinforced to keep the risk of implant failure as low as possible. These two demands (low stiffness and high-fatigue strength) were met by a change of material, from stainless steel to a titanium alloy. Titanium nails seem to have a beneficial effect on strength, mineralization, and fracture healing at 12 weeks [1]. The higher strength of the material allows the use of larger, 4.2/4.9 mm diameter interlocking screws. The solid cross-section of the intramedullary nail does not add much to its mechanical bending properties, but it has biological advantages. Results of animal experiments indicate that the susceptibility to infection is lower with the solid intramedullary nail compared with the tubular intramedullary nail with its inner dead space [2]. However, a cannulated system allows for the use of a guide wire, which makes intramedullary nail insertion easier.

1.5 Angular stable locking system (ASLS)

Intramedullary nails with standard locking options provide adequate stability in long-bone shaft fractures. In metaphyseal and segmental fractures, however, the wide diameter of the medullary canal and fracture morphology may cause problems with reduction and stable fixation of the short proximal or short distal fragment because circular press fit of the implant in the wide medullary cavity cannot be obtained. Malunion and/or nonunion are common. The improved 3-D design of proximal and distal locking has expanded the spectrum of indications of intramedullary nailing to metaphyseal and even simple articular fractures of the femur, tibia, and humerus [3]. These implants are cannulated and the instrumentation is modular. Relative movement of the main fragments is effectively reduced by angular stable locking screws. Angular stability is produced by a mechanical couple between the locking screws and the nail. This can be achieved by jamming locking screws or by the use of resorbable sleeves inserted into the locking holes of the nail (ASLS) [4].

2 Pathophysiology of intramedullary nailing

2.1 Intramedullary nailing with reaming

2.1.1 Local response

Reaming the medullary cavity causes damage to the internal cortical arterial and venous blood supply, which, in animal experiments, was shown to be reversible within 8–12 weeks [5]. There is a direct correlation between the extent of reaming and the degree of the reduction in cortical blood flow. Reaming also generates heat and may cause thermal bone necrosis. Large reamers and blunt reaming heads should not be used in clinical practice. The reduced blood supply and thermal bone damage during the early weeks after trauma and reaming might contribute to an increased risk of infection, especially in open tibial fractures. Since the femur has a good soft-tissue envelope, femoral shaft fractures are more often closed than open and treatment by intramedullary nailing is more straightforward and less risky than for the tibia. The infection rates for Gustilo type I and type II open fractures of the femur following intramedullary nailing with reaming are 1–2%, whereas for open fractures with extensive soft-tissue injury (Gustilo type III) the infection rates are 4–5%.

There are some biological advantages of intramedullary reaming, as it enhances the bone healing process by:

- Increased perfusion and oxygenation in the adjacent soft tissues
- Reaming debris has osteogenic and osteoinductive properties
- Local "autografting" of bone debris into the fracture site stimulates osteogenesis
- Systemic liberation of growth factors
- Allowing the insertion of larger (mechanically more stable) diameter nail

Clinical studies [7] demonstrate a possible benefit for reamed intramedullary nailing in patients with closed fractures, whereas the optimal nailing technique for open fractures remains uncertain.

2.1.2 Systemic response

Systemic effects of intramedullary reaming are pulmonary embolization, humoral, neural, immunological, and inflammatory reactions plus temperature-related changes of the coagulation system. Intramedullary pressures exceeding the diastolic blood pressure result in extravasation of bone marrow content into the venous vascular system (fat embolism). Transesophageal echocardiography (TEE) shows the passage of thrombi into the pulmonary circulation. Pulmonary embolization may cause mechanical vascular obstruction. Systemic liberated fatty acids and bone debris additionally induce vasculitis of vessels within the lung [8]. Liberation of inflammatory mediators, such as thromboxane, serotonin and prostaglandins, cause bronchial spasms and vasoconstriction. Due to shunt systems within the lung, fat embolism may also get access to the systemic circulation, evoking cerebral embolization.

Any device introduced into the medullary canal (awl, guide wire, reamer, intramedullary nail) acts as a piston and forces the contents of the medullary cavity both through the fracture gap into the adjacent tissue and into the venous system. Polytrauma patients with chest injury are especially at risk, since the lungs are sensitive to any additional stress in the period immediately after trauma.

Distal venting of the femur has been shown to reduce the intramedullary pressure during reaming by 50–90%. The clinical efficacy of this technique, however, has not been documented in prospective randomized trials.

There is ongoing controversy between those who recommend reamed intramedullary nailing for all patients with severe trauma, and those with concerns about its role in pulmonary impairment in multiple-injured patients [9]. Recent clinical studies [10] found similar rates of pulmonary embolism and no significant difference in the rate of pulmonary response between reamed and unreamed femoral nailing, provided surgery was delayed until the patient was fully resuscitated (early appropriate care). Comparing reamed femoral nailing with plate fixation in multiple-injured patients with head injury showed that nailing did not increase the risk of neurological complications [11].

2.1.3 Reaming, irrigation, and aspiration

The reaming, irrigation, and aspiration (RIA) system was developed to reduce the amount of systemic fat liberation during the procedure of reaming [12]. Irrigation during the reaming procedure reduces the viscosity of the bone marrow and allows suction of the intramedullary content. Reaming using the RIA technique lowers the maximum reaming temperature and causes less sustained increases in intramedullary pressures in comparison to conventional reaming [8]. A significant reduction of fat embolization compared to conventional reaming could be demonstrated in pig femora [12]. However, values were still higher than with external fixation. Whether RIA reduces systemic complications during nailing of femoral fractures in multiple-injured patients still needs further investigation.

Reaming, irrigation, and aspiration are also used for nailing of pathological fractures and for debridement in patients with acute and chronic osteomyelitis. An additional application of RIA is bone harvesting by sucking the reaming eluate through a filter for surgical procedures, such as treatment of bone defects and nonunions. Similar union rates with significant less donor-site pain in comparison to iliac crest harvesting have been reported [13]. However, extensive thinning of the inner cortex of more than 2 mm may be a risk factor for postoperative fracture of the donor site and the surgical and anesthetic teams must be aware that this procedure can result in considerable blood loss.

2.2 Intramedullary nailing without reaming

Small diameter implants are used for intramedullary nail insertion without reaming. The benefits are less heat production, and, although the insertion of thinner implants certainly disturbs the endosteal blood supply, this occurs to a lesser extent. There is also less bone necrosis, which is one of the risk factors for the development of postoperative infection. However, an explicit clinical benefit of unreamed intramedullary nailing in comparison to reamed nailing has not be demonstrated.

A metaanalysis comparing reamed versus unreamed nailing in closed fractures of the tibia showed a significantly lower risk of nonunion, screw breakage, and implant exchange in the reamed nailing group [14]. Reamed nailing of closed fractures seems to be associated with a higher fracture healing [7, 8].

2.3 Current aspects of femoral intramedullary nailing

2.3.1 Isolated femoral shaft fractures

Both methods of intramedullary nailing (reaming and not reaming) are associated with similar generation of emboli. A prospective, randomized, clinical study [15] found no significant differences in pulmonary physiological response or clinical outcome between patients treated with unreamed or reamed femoral nailing.

Other clinical studies have demonstrated significant benefits of reaming compared to unreamed femoral nailing. In a multicenter, prospective, randomized trial [16], intramedullary nailing of femoral shaft fractures without reaming resulted in a significantly higher rate of nonunion compared to intramedullary nailing with reaming. In addition, reaming led to faster healing and a reduced rate of delayed union.

Femoral nailing with reaming remains the gold standard for the treatment of isolated femoral fractures.

2.3.2. Femoral shaft fractures in polytrauma patients

In multiple-injured patients, especially in the presence of chest trauma, the reamed femoral nail has been implicated as a cause of significant disturbance of pulmonary function. Using an unreamed nail reduces but does not abolish pulmonary sequelae. In addition to the pulmonary consequences of intramedullary nailing, systemic effects on the coagulation system and on the inflammatory response with increased levels of interleukin-6 and C-reactive protein have been reported in clinical and experimental studies for both the reamed and the unreamed femoral nail [17]. No significant differences in the incidence of acute respiratory distress syndrome (ARDS) were observed following reamed and unreamed nailing in a series of 315 multiple-injured patients with femoral fractures, treated with a nail within 24 hours after injury [18].

To limit the physiological insult resulting from operative treatment after trauma, a move from early total care (ETC) to damage-control orthopedics (DCO) in patients with multiple injuries has occurred. Damage-control orthopedics starts with initial external fixation of femoral shaft fractures with a later conversion to an intramedullary nail [19]. This concept has been judged as a viable alternative to obtain temporary fracture stabilization in polytrauma patients, especially those with concomitant injuries to the head, chest, or an exceptionally high injury severity score (ISS) [17, 20].

Definitive primary femoral stabilization by intramedullary nailing imposes considerable stress on a multiple-injured patient with blunt trauma. Principles of management include adequate resuscitation with appropriate timing of reconstruction depending on the patient's physiological response.

Vallier et al [10] defined clinical conditions that warranted delay for definitive fracture fixation in a retrospective study on 1442 patients with pelvic, spinal, and/or femoral shaft fractures. Chest injury was identified as the greatest predictor of pulmonary complications. The authors emphasized the importance of adequate resuscitation and correction of acidosis before nailing. They recommended early definitive fixation of unstable fractures of the axial skeleton and long bones within 36 hours in patients who demonstrated response to resuscitation. Lactate < 4.0 mmol/L, pH > 7.25, and BE > 5.5 mmol/L were indicators to proceed with definitive fracture fixation.

Pape et al [21] described four pathophysiological cascades, associated with the development of posttraumatic immune dysfunction and endothelial damage. They recommended assessing for hemorrhagic shock, hypothermia, coagulopathy, and soft-tissue injury in all patients with multiple blunt trauma and long-bone fractures. Clinical parameters that characterize an unstable patient (as opposed to a stable or a borderline patient) include blood pressure < 90 mm Hg, body temperature < 33° C, platelets < 90,000, and significant soft-tissue trauma (major extremity injuries, crush trauma, severe pelvic fracture, thoracic and abdominal trauma with AIS > 2).

Even when the initial insult of trauma (the "first hit") is moderate, a "second hit" resulting from surgical procedures with inappropriate timing can aggravate the overall amount of damage and may lead to an increased morbidity and mortality [9]. Pape et al [21] suggested categorizing patients into one of four categories (stable, borderline, unstable, in extremis) and adapting the treatment approach accordingly. In patients who are unstable or in extremis, damage-control surgery, including rapid external fixation of long-bone fractures, followed by early secondary definitive fracture stabilization, typically within 5–7 days, is recommended.

In patients with delayed definitive fracture fixation (> 2 weeks), or if there is pin-site infection, converting

provisional external fixation to intramedullary nailing should include a short fixator-free interval (pin holiday) [19] of 2–3 days, during which patients are placed in skeletal traction to reduce the risk of infection.

2.4 Current aspects of tibial intramedullary nailing

Intramedullary nails are the treatment of choice for most unstable tibial diaphyseal fractures. The incidence of intravasation of intramedullary content and pulmonary embolization after tibial fractures is significantly lower than after femoral shaft fractures (tibia 19% versus femur 78%) as the venous drainage system of the tibia is less extensive than that of the femur.

The use of intramedullary nails with reaming for the treatment of closed tibial fractures results in shorter time to union without an increase of postoperative complications [22]. A higher rate of malunions after unreamed intramedullary nailing has been reported than after reamed intramedullary nailing [22]. A reamed procedure for stabilization of the tibia did not increase the risk of complications in open tibial fractures of the Gustilo type I–IIIA [22].

The SPRINT blinded randomized trial [7] compared healing rates and complications after reamed and unreamed intramedullary nailing of open and closed tibial fractures in a large series of 1,319 adults. The study demonstrated a possible benefit for reamed nailing in closed fractures with fewer screw breakages, whereas there were no significant differences between both procedures in patients with open fractures. The reoperation rate in response to infection was not significantly different between both groups [7].

2.5 Conclusion

The systemic impact of intramedullary nailing of femoral shaft fractures seems to be significantly higher compared to tibial fractures. There is good evidence that reamed femoral intramedullary nailing is the method of choice for isolated femoral shaft fractures. In polytrauma patients, adequate resuscitation before nailing is essential. Early definitive intramedullary stabilization of the femur should not be performed in patients in extremis or who do not respond to resuscitation and continue to have uncorrected acidosis, coagulopathy, or severe hypothermia. The preferred approach is damage-control surgery with temporizing external fixation.

Stabilization of tibial fractures is mostly influenced by local soft-tissue factors. For closed tibial fractures, reamed intramedullary nailing is the method of choice. In open fractures the method of choice remains controversial.

3 Implants

3.1 Femur

The universal femoral nail is a curved, slotted intramedullary nail made of stainless steel and is still widely used in many parts of the world. It has a static and dynamic locking option proximally, and two static locking options distally. The femoral version of the simplified universal nail (SUN) is an unslotted, tubular version of the universal femoral nail. Both the SUN and the SIGN nail have been designed for hospitals without an image intensifier, with a simple mechanical aiming device to allow for interlocking without image guidance.

The unreamed femoral nail is a solid titanium nail with a variety of proximal locking options (static, dynamic, spiral blade, and miss-a-nail). It is curved and requires an entry point in line with the medullary cavity. The cannulated femoral nail allows the insertion along a guide wire. The entry point in the piriformis fossa has been criticized for being technically demanding, with a possible risk of compromising the blood supply to the femoral head. This led to the development of the antegrade femoral nail, which has a bend in the proximal part that allows for insertion at the tip of the greater trochanter. The lateral femoral nail has a starting point even more lateral to the tip of the greater trochanter. The very lateral starting point facilitates nail insertion. The nail has a helical design and rotates by approximately 90° during insertion. Standard and reconstruction locking options provide stability in diaphyseal as well as in subtrochanteric and segmental fractures. The adolescent femoral nail is used in small stature (adolescent) patients with small diameters of the medullary cavity.

The distal femoral nail is specifically designed for retrograde insertion. The proximal locking is performed anteriorly in long nails and lateral to medial in short nails. As part of the expert nail system the retrograde/antegrade femoral nail can be introduced through an antegrade as well as a retrograde entry point. It is cannulated and allows for optional spiral blade locking at the level of insertion with retrograde insertion.

For fractures in the proximal femur (subtrochanteric or intertrochanteric), intramedullary nail-screw combinations are available in different dimensions for different indications. The original proximal femoral nail with two parallel femoral head screws of different sizes has mainly been used outside the US, while in the US the trochanteric femoral nail is popular. The trochanteric femoral nail has a double spiral blade configuration for improved rotational stability in the

femoral head/neck area. This design has now been integrated into the proximal femoral nail, resulting in the proximal femoral nail antirotation. Both the proximal femoral nail antirotation and the proximally smaller sized trochanteric femoral nail-advanced can be used with either a blade or a head-neck screw. Perforations at the tip of the blade or screw allow for cement augmentation that aims to reduce failure rates in osteoporotic bone by increasing the implant to bone surface contact area.

Every specific nail has its own specific entry point. Each specific entry point has advantages and potential complications. The piriformis starting point, which is collinear with the axis of the femoral medullary canal, is appropriate for nails that are straight in the AP plane (eg, unreamed femoral nail). Piriformis start nails are better for preventing varus deformity and offer excellent stability specifically in subtrochanteric fractures. Occasional femoral neck fractures have been described after nailing through the piriformis fossa. Concern exists in young patients with an open proximal femoral growth plate about the potential risk of avascular necrosis, resulting from intraoperative damage to the medial circumflex femoral artery [23].

Nails with a lateral bend have a more lateral starting point, usually at or just lateral to the tip of the greater trochanter. Inserting a nail through a lateral entry point is mechanically stable, technically easier to perform and causes less damage to the muscles and vascular structures [24].

Reamers for nails inserted into the tip of trochanter tend to lateralize the center of the entry point as the lateral bone is softer. This can result in varus malalignment when the nail is inserted and these nails must be used with caution for subtrochanteric fractures.

In a prospective randomized trial, Stannard et al [25] compared functional outcome with the piriformis fossa and the greater trochanter entry point in the treatment of femoral shaft fractures. The tip of the trochanter starting point resulted in a better outcome at 6 months but function was equal at 1 year. Pain scale values were equal in both groups [25]. From the technical perspective, operative time and image intensifier time were significantly shorter and incision length was smaller with the trochanter starting point, indicating that nailing through the tip of trochanter entry is a simpler procedure.

3.2 Tibia

The universal tibial nail is a slotted tubular intramedullary nail made of stainless steel, which is still widely used in many parts of the world. It has a static and dynamic locking option proximally, and two static locking options distally. There is a SUN for the tibia which is an unslotted, hollow version of the universal tibial nail. The SUN nail as well as the SIGN nail is designed for hospitals where an image intensifier is not available, with a simple mechanical target device to allow for interlocking without radiation. The unreamed tibial nail is a solid titanium nail with a variety of proximal locking options (oblique, dynamic, static). The cannulated tibial nail allows for insertion along a guide wire. The expert tibial nail system offers additional and improved proximal and distal locking options with a 3-D configuration, which makes this nail suitable for the fixation of proximal and distal metaphyseal fractures as well as for segmental fractures.

3.3 Humerus

The unreamed humeral nail is a locking intramedullary nail, which provides the smallest diameter (6.9 mm) and the use of a spiral blade into the humeral head. The proximal bend allows for antegrade and retrograde insertion. The proximal humeral nail is a short unreamed humeral nail, specifically designed for proximal humeral fractures. The expert humeral nail is cannulated and has the option for either antegrade or retrograde insertion. Newer humeral nails with multi-locking options are available in a short and a long version with 3-D angle-stable locking possibilities and the option of inserting secondary screws (screw-in-screw technique) to enhance the stability of proximal fixation. The nail is appropriate for both simple type A as well as complex types B and C fractures [26]. As the implant is straight, it is inserted in the axis of the humerus and the proximal end of the nail acts as a fifth anchor point in addition to the four locking screws. In its long version, the nail allows optional compression; it is appropriate for the fixation of both diaphyseal and segmental fractures.

3.4 Forearm

Intramedullary fixation of forearm shaft fractures is limited to the titanium elastic nail. It has only exceptional indications in adults because rotation around the nail cannot be prevented. Locked nailing systems for the forearm are in development. The short olecranon nail is mainly used for surgical fixation of osteotomies of the olecranon as well as for simple articular fractures of the proximal ulna.

3.5 Clavicle

Simple midshaft fractures of the clavicle are—as an alternative to plate fixation—successfully addressed by elastic stable intramedullary nailing. Elastic titanium nails with a diameter of 2.0–3.0 mm are inserted from medial to lateral. Fracture reduction is achieved either in a closed or minimally open manner. The use of elastic stable intramedullary nailing in comminuted fractures is still being debated, since the technique may be associated with complications like shortening, telescoping, and skin perforation [27].

3.6 Lateral malleolus

Locking nails have been developed for fixation of lateral malleolar fractures in patients with osteoporosis or multifragmentary fractures with the option of placing a diastasis screw (see chapter 6.9).

4 General techniques

4.1 Preoperative planning and management

4.1.1 Patient positioning

The traction table or a standard radiolucent operating table, with or without the use of the femoral distractor, are alternatives for patient positioning for femoral nailing. Nailing can be done either in the lateral or in the supine position. The use of a traction table will maintain defined reduction throughout the procedure, which may be helpful in the placement of reamed intramedullary nails. Much depends on personal experience and preference as well as on the operating room environment. With the unreamed intramedullary nail, maintenance of accurate reduction is only necessary for the short period required to pass the intramedullary nail from the proximal fragment into the distal main fragment. In reamed intramedullary nailing, however, preservation of fracture reduction is a requirement for every passage of the reamer and, finally, for the insertion of the nail as well. Polytrauma patients with ipsilateral and/or bilateral tibial and/or femoral fractures can be treated on a regular operating room table without the need to change either the position of the patient or the drapes. This appears to be safer and quicker. Intraoperative control of rotational alignment is easier when both legs are draped.

4.1.2 Sequence of stabilization in multiple extremity fractures

The recommended order for the treatment of closed fractures is:

1. Femur
2. Tibia
3. Pelvis or spine
4. Upper limb

To follow this sequence, alternative methods were developed for the treatment of concomitant ipsilateral and/or bilateral fractures of the lower limb. In multiple fractures of the lower limb, standardized stabilization protocols have been helpful for the sequence and method of stabilization according to the patient's condition (stable, borderline, unstable, in extremis). More recent techniques for intramedullary stabilization are no longer based on a fracture table but show a preference for the temporary use of a distractor or manual traction. This allows a single positioning and draping procedure for stabilization of multiple fractures.

4.1.3 Correct implant selection

Preoperative selection of intramedullary nail length

Templates are commonly recommended for the preoperative planning of intramedullary nailing. The accuracy of templates, however, is dependent upon the x-ray magnification. Unfortunately, there is currently no accepted standard for long bones, and magnification ranges from 10–20%. As a consequence, templates are highly unreliable for selecting the correct nail length. Implant selection should be based on an x-ray of the intact contralateral bone, intraoperative clinical measurements, or image intensifier-based measurements with the use of opaque rulers. Clinical comparison with the uninjured limb is another reliable option but requires separate draping of the uninjured leg.

Measuring intramedullary nail length intraoperatively with a special ruler under C-arm control is an accurate method for implant selection. If the proximal and distal ends of the bone are centered in the x-ray beam, and the ruler is placed parallel to the diaphysis, projection-induced misjudgment of implant length is minimized (**Fig 3.3.1-1**).

An alternative manner of selecting intramedullary nail length is to draw the landmarks onto the skin using a sterile pen and measure with a ruler. The proximal landmark in the femur is the tip of the greater trochanter, which is identified by palpation. The distal landmarks are the lateral knee joint space and/or the superior edge of the patella. In simple fracture patterns, one picture of the reduced fracture site taken with the image intensifier allows correct measurement and choice of an intramedullary nail of appropriate length.

Proximal landmarks for the tibia are both the medial and lateral knee joint spaces; the distal point is the anterior part of the ankle joint with a dorsally flexed foot.

Selecting the intramedullary nail diameter

A special ruler permits measurement of the implant diameter (**Video 3.3.1-3**). A technical trick for the selection of the cavity diameter during intramedullary nailing is the use of the reamer head as a probe.



Video 3.3.1-3 Preoperative planning of nail length and diameter in the femur with a special ruler.

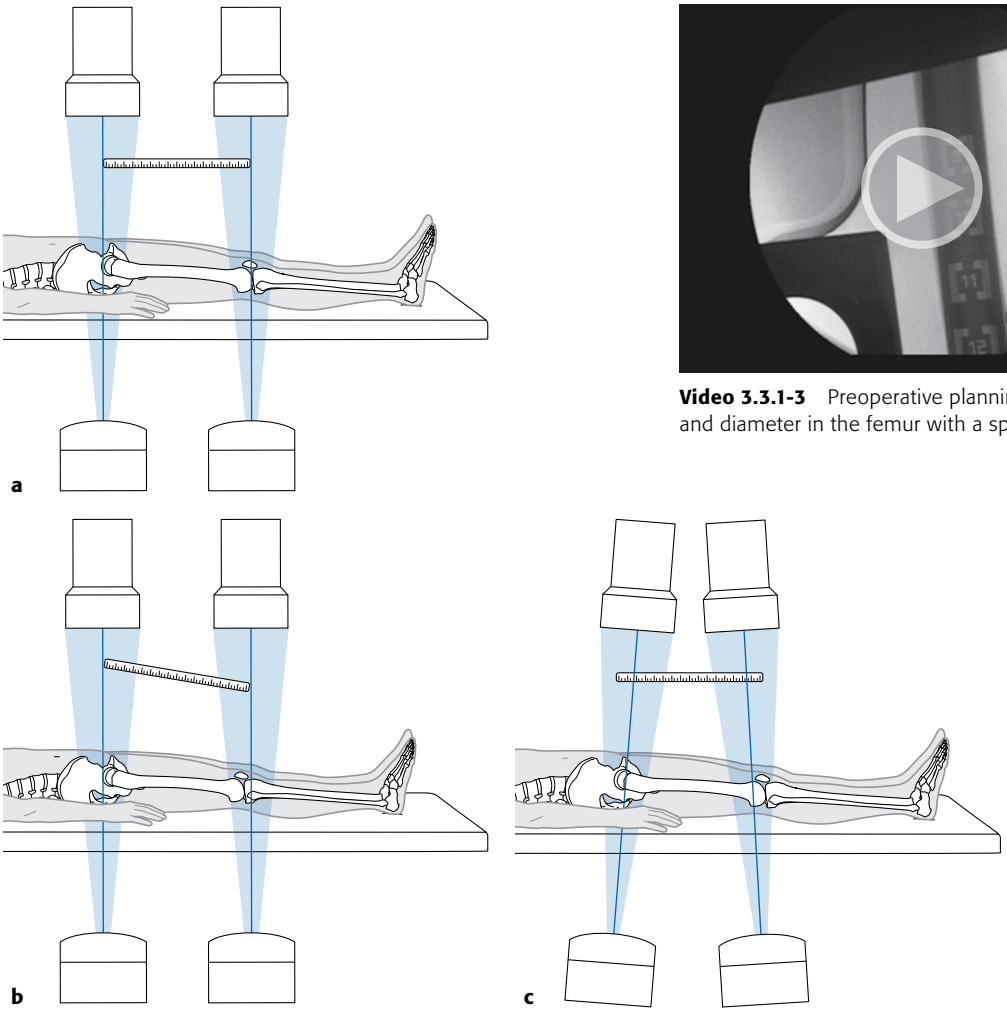

Fig 3.3.1-1a–c Intraoperative determination of nail length with the use of an image intensifier. Note that errors can occur in various combinations to produce different patterns of error.
a Correct position of patient, C-arm, and ruler parallel to the femur.
b Error: Nonparallel ruler position results in too long a measurement.
c Error: Eccentric position of the C-arm results in too short a measurement.

4.2 Insertion techniques

4.2.1 Surgical approach and preparation of the entry point

Stab incision techniques have been developed for the femur and the tibia. In both bones, care must be taken to place the incisions in line with the axis of the medullary cavity and not too close to the chosen entry point on the bone (**Figs 3.3.1-2–3**). Smaller approaches reduce blood loss as well as the risk of heterotopic ossification at the tip of the greater trochanter of the femur.

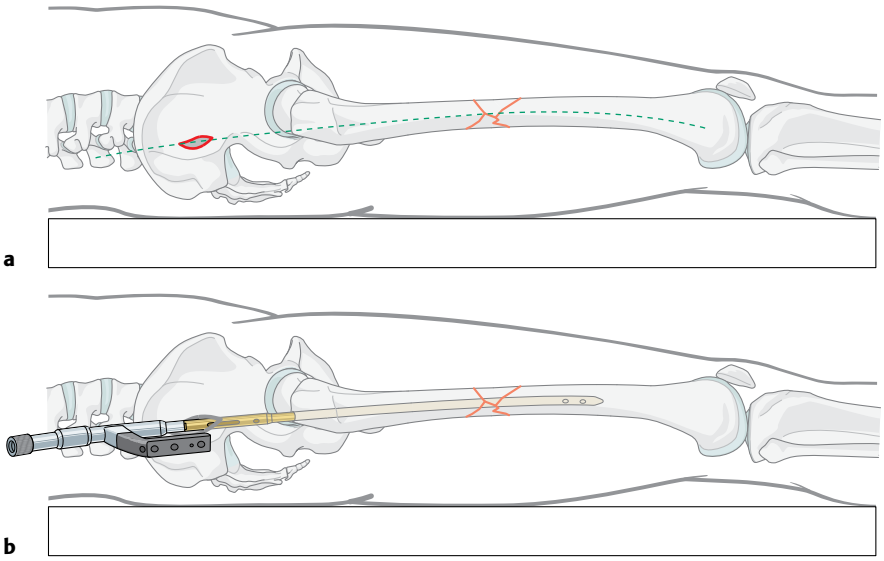

Fig 3.3.1-2a–b Surgical approach for antegrade femoral nailing. When planning the stab incision, which lies approximately 10 cm proximal to the tip of the greater trochanter, the natural antecurvation of the femur has to be considered. Before making the incision it is useful to identify it using the image intensifier and a metal ruler and mark the position of key anatomical landmarks with a skin marker pen.

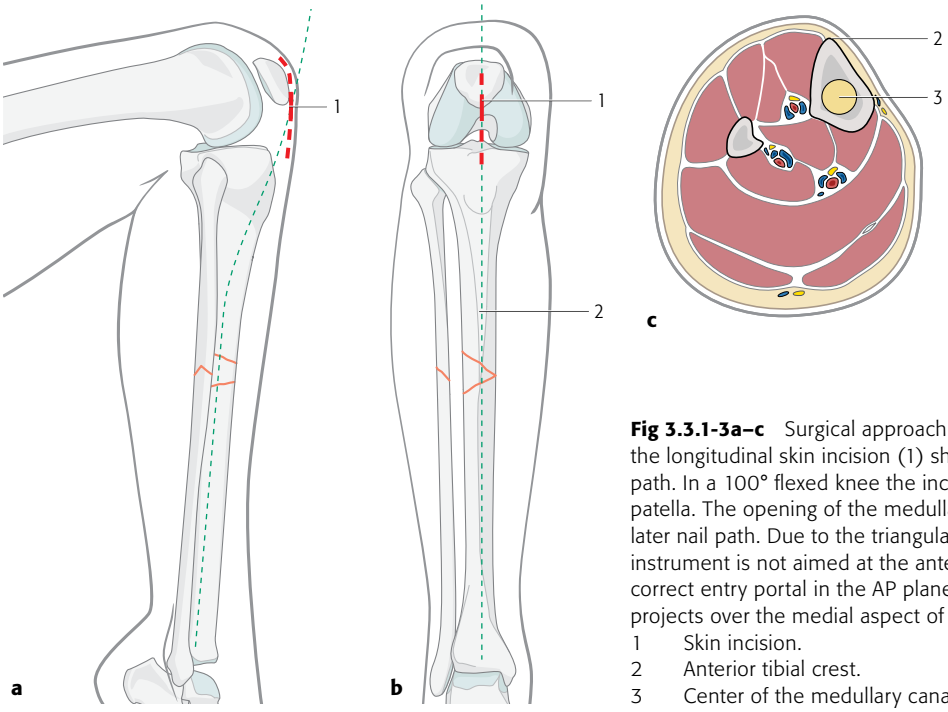

Fig 3.3.1-3a–c Surgical approach for intramedullary nailing of the tibia: the longitudinal skin incision (1) should be in line with the chosen nail path. In a 100° flexed knee the incision lies over the lower end of the patella. The opening of the medullary cavity should also be in line with the later nail path. Due to the triangular cross-section of the tibia, the opening instrument is not aimed at the anterior tibial crest (2) but medial to it. The correct entry portal in the AP plane is slightly lateral from the midline and projects over the medial aspect of the lateral eminentia.

1 Skin incision.
2 Anterior tibial crest.
3 Center of the medullary canal.

4.2.2 Preparation of the entry point in antegrade femoral nailing

The correct entry point is crucial in all intramedullary nailing. A suboptimal entry point leads to malalignment and may create iatrogenic fractures during implant insertion.

The surgeon should always view the entry point on the AP and lateral image before opening the bone.

In the femur, flexion and adduction of the hip joint facilitates the approach to the trochanter for antegrade femoral nailing. This decreases the length of the incision, especially in obese patients. The greater trochanter, lateral femoral condyle, and, if possible, the femoral shaft are palpated and, if necessary, identified with a marker. A line is drawn in a proximal direction corresponding to the curvature of the femur. A stab incision of about 3–5 cm is made approximately 10 cm proximal to the tip and directed toward the greater trochanter (**Fig 3.3.1-2**). This allows insertion of a palpating finger alongside the implant (**Video 3.3.1-4**). Incisions should not be placed too posteriorly since abductor muscle weakness has been recorded after intramedullary nailing. The choice of the correct entry point is crucial and the surgeon must be aware that there is considerable variation in normal anatomy [28]. Too posterior with the starting point may lead to loss of reduction; too anterior with the entry point generates huge forces and may lead to bursting of the proximal femur. Depending on the intramedullary nail design, different entry points are recommended (piriformis fossa, tip of the greater trochanter, etc). This must be considered in every case (**Fig 3.3.1-4**).

Video 3.3.1-4 Clinical video of the surgical approach for antegrade femoral nailing.

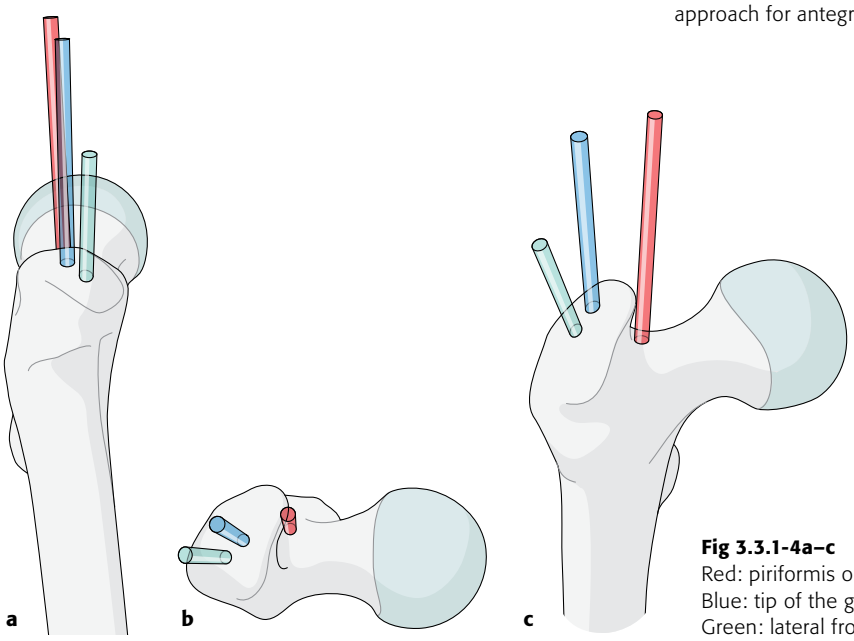

Fig 3.3.1-4a–c Correct entry points for various nails.
Red: piriformis or trochanteric fossa.
Blue: tip of the greater trochanter.
Green: lateral from the greater trochanter.

The perfect position of the guide wire in both planes is rarely achieved on the first attempt, especially in the femur. In these cases, a correct second pin is inserted using the initial wire as a reference. A multi-hole wire guide is a useful instrument that allows insertion of a second guide wire in corrected position. A sleeve protects the hip abductors from the 3.0 mm cannulated drill bit used to open the entry point.

4.2.3 Preparation of the entry point in retrograde femoral nailing

For retrograde nailing of the femur, the knee is flexed approximately 30°. A guide wire is lined up with the midline of the medullary cavity of the distal femoral shaft, using an image intensifier. The stab incision is placed on this line and a K-wire with a protection sleeve is pushed through or just medial to the ligamentum patellae into the distal femur. The position of the K-wire is also checked in a lateral view. Care must be taken that the origin of the posterior cruciate ligament is not injured. The important landmark in the lateral view is the Blumensaat line, a radiodense line representing the cortical bone of the roof of the intercondylar notch of the femur.

4.2.4 Antegrade tibial nailing

In the tibia, with the knee completely flexed, a 15–20 mm stab incision is made in line with the medullary cavity. The incision starts at the inferior pole of the patella and passes through the patellar tendon (or just medial to it) and all layers down to the bone (**Fig 3.3.1-3**). The proximal anterior edge of the tibia can be easily identified with the sharp tip of the guide wire.

The 4.0 mm guide wire, mounted on a universal chuck with T-handle, is pushed through the thin cortex in the direction of the center of the medullary canal. The position is checked with an image intensifier with both AP and lateral views. Accurate position is important (see chapter 6.8.2). The protection sleeve for the cannulated cutter is placed through the stab incision and through the patellar ligament directly onto the bone. The cannulated cutter ("cheese cutter") for the medullary canal cuts out a cylinder of corticocancellous bone. This may be used as bone graft. To prevent malalignment it is essential to place the entry point exactly in line with the center of the medullary cavity.

Alternatives to the transtendinous patellar approach are the medial parapatellar approach and the suprapatellar approach. The suprapatellar approach has the great advantage that nailing can be done in a semiextended position, which is especially beneficial in fractures of the proximal tibia and in segmental fractures (**Video 3.3.1-5**). The stable position of the lower leg and less deforming force from the patellar tendon facilitates fracture reduction and instrumentation. To avoid damage to the cartilage of the knee, it is mandatory to use a soft protection sleeve while passing instruments and implants through the joint [29].

4.2.5 Floating knee injury

In cases where retrograde femoral and antegrade tibial nailing is planned, intramedullary nail insertion can be performed through the same skin incision. In this situation the surgeon must ensure that the incision is proximal enough to allow insertion of the retrograde nail (close to the patella).

4.2.6 Reaming technique

For fresh fractures, power reamers are more convenient and faster than hand reamers. However, for more difficult situations (eg, nonunions with sclerosis of the medullary cavity), specially designed hand reamers are safer and more effective. Reamer design and condition (cutting flutes, geometry and diameter of the reamer shaft, sharpness, etc) are important.

Blunt reamers, small flutes, high axial forces, and large diameters of the reamer shaft cause an increase in pressure and temperature.

Cases of thermal necrosis of the femur and tibial isthmus after reaming have been observed. The temperature rise is mainly related to the amount of reaming performed on hard cortical bone. Some surgeons recommend that a tourniquet is not used when reaming the tibia but a randomized trial suggests that this may be an acceptable technique [30].

Video 3.3.1-5 Suprapatellar approach for antegrade tibial nailing.

The use of a distal venting hole to reduce intramedullary pressure during reaming is dependent on the diameter of the hole. This method is not generally used for fractures but a distal venting hole is essential if an intact bone is reamed for prophylactic nailing of an impending pathological fracture.

4.3 Reduction techniques

4.3.1 Reduction of femoral fractures

For several reasons femoral fractures are more difficult to reduce than tibial fractures:

- Thicker soft-tissue envelope and less direct access to bone.
- More deforming muscle force.
- Entry point at the proximal end is partly hidden.
- Iliotibial tract tends to shorten the fracture if the leg is adducted.

4.3.2 Reduction of tibial fractures

The most effective and gentle instruments for reducing fresh tibial fractures are our hands. In contrast to the femur, large parts of the tibia are easily palpated. Since most fractures are type A or B fractures of the midshaft or distal diaphysis, they are suitable for simple manual reduction during implant insertion. Temporary overcorrection of the fracture zone during intramedullary nail passage is sometimes advantageous and helpful in oblique fractures.

4.3.3 Reduction aids

Reduction of fresh fractures for closed intramedullary nailing is rarely a problem but delayed intramedullary nailing often requires additional tools to overcome shortening and to control axial alignment. The traction table is safe and reproducible for some surgeons but some prefer the limb free on a radiolucent table.

The towel-sling and beanbag techniques are easy, noninvasive, and inexpensive ways of manipulating the main fragments. However, they are rather imprecise and not suitable for adjusting the length. In the tibia, pointed reduction forceps are best used, since they can be applied percutaneously or through an open wound, without additional soft-tissue trauma.

The use of temporary Schanz screws is an effective way to get direct contact with the bone. This is especially helpful in femoral or delayed tibial fractures. Three principles have to be respected:

- Screw placement must be as close to the fracture as possible.
- Monocortical insertion is used in the proximal fragment in order not to interfere with implant insertion.
- A universal chuck with T-handle is used for easier manipulation.

There are two planes in which reduction has to be controlled:

- Coronal (AP) plane
- Sagittal (lateral) plane

Use of the image intensifier can be reduced by fixing universal chucks with T-handle to the Schanz screws and analyzing their position in relation to each other. Furthermore, tactile control of the main fragments may also decrease the need for radiation exposure (**Fig 3.3.1-5**).

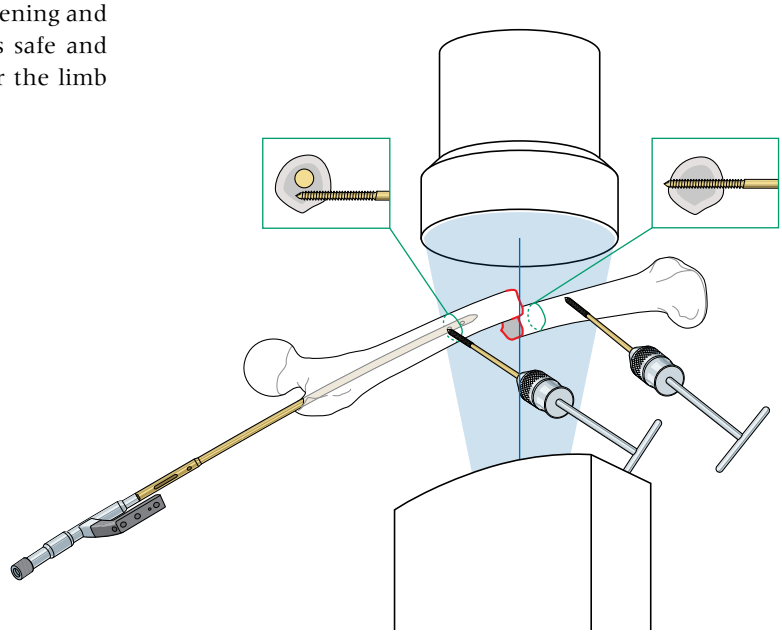

Fig 3.3.1-5 The use of Schanz screws for reduction. The Schanz screws are placed monocortically in the proximal fragment and bicortically in the distal fragment. With two universal chucks with T-handle, the fragments may be manipulated under C-arm control (AP view). The orientation in the sagittal plane is obtained by feeling the fragments touching each other.

In cases of delayed intramedullary nailing with shortening of the limb, the use of a large distractor may be essential for restitution of length and axis. Care must be taken since the single Schanz screw tends to bend and rotate under strain. If a distractor is not available, a tube-to-tube external fixator and a distraction tool can be used for the same purpose (**Fig 3.3.1-6**). Specific modular fracture reduction frames, including circular frames, are in use as well.

Intramedullary nailing of fractures in the metaphysis is associated with a higher rate of malalignment. Strong muscle pull and a wide medullary canal can lead to malposition, even with locking. Screws placed adjacent to the intramedullary nail can prevent lateral or medial translation in both the tibia and the femur. These blocking screws, also called Poller screws, decrease the width of the metaphyseal medullary canal, forcing the intramedullary nail to the center

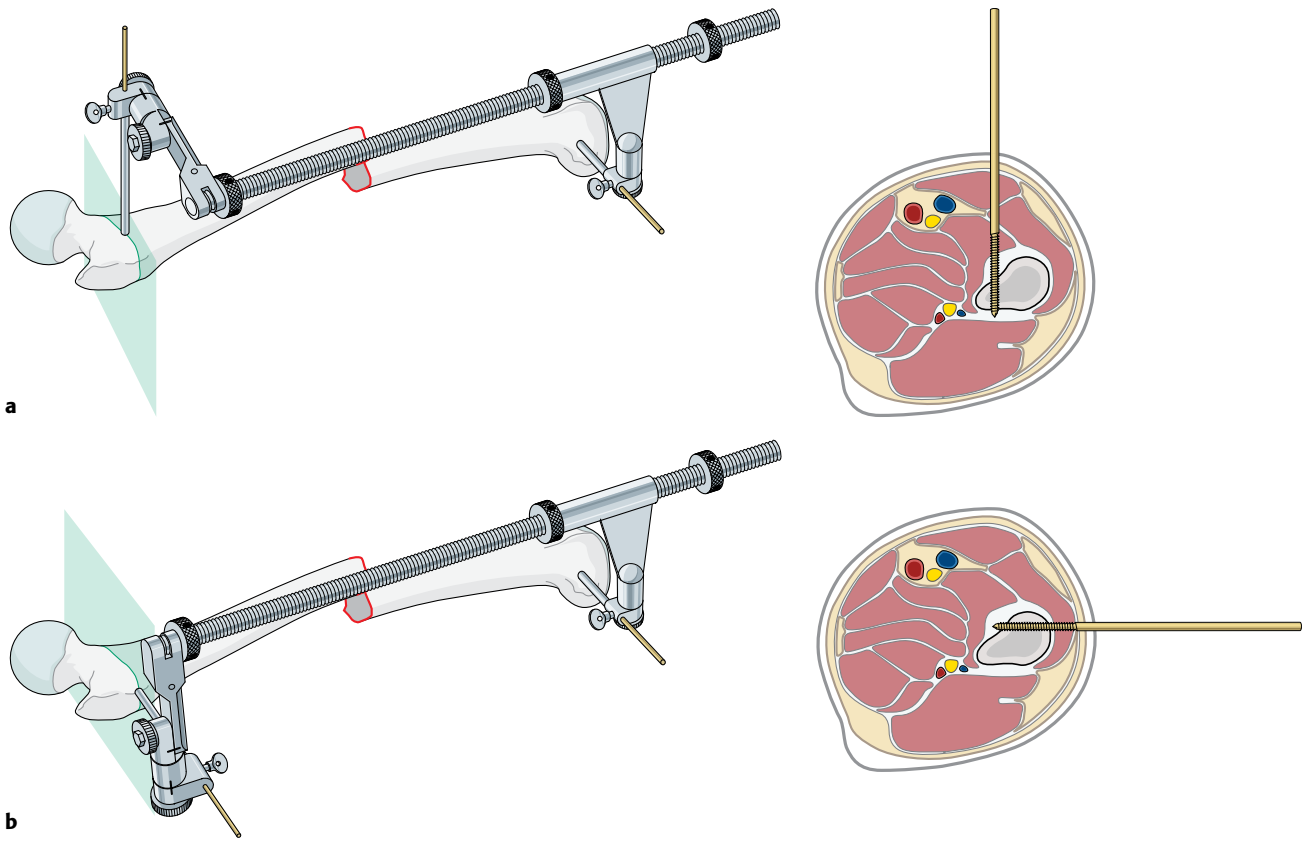

Fig 3.3.1-6a–b The use of a distractor for reduction.

a Standard application of the large distractor. The AP Schanz screw is inserted just proximal to the lesser trochanter, medial to the medullary canal, and lateral to the medial cortex. In the cross-section the safe distance of this Schanz screw to the neurovascular structures in the femoral triangle can be appreciated.

b Alternate application, with both Schanz screws applied laterally. The proximal Schanz screw usually interferes with the insertion handle of the intramedullary nail, so the distractor has to be removed before the nail is fully introduced.

of the medullary cavity and also increasing the mechanical stiffness of the bone-implant construct. They can also be applied to narrow the AP diameter of the medullary canal to prevent deformity in the coronal plane. Poller screws can be used for alignment, stabilization, and manipulation. The screw is placed perpendicular to the direction in which the implant might displace (**Fig 3.3.1-7**, **Video 3.3.1-6**)

In oblique metaphyseal fractures of the distal tibia or femur, the Poller screw may be helpful for stabilization, as shear forces are transformed into compression forces (**Video 3.3.1-7**).

The Poller screw may help to prevent displacement in revision surgery where there is deformity from a previously misplaced intramedullary nail. The new nail tends to slip into the old nail path but this can be prevented by a carefully placed Poller screw (**Fig 3.3.1-8**). The same technique can be used in situations where the entry point for the nail was originally poorly chosen, forcing the proximal bone fragment into malalignment: the intramedullary nail must be removed temporarily and the Poller screw placed to block the incorrect path while the intramedullary nail is reinserted.

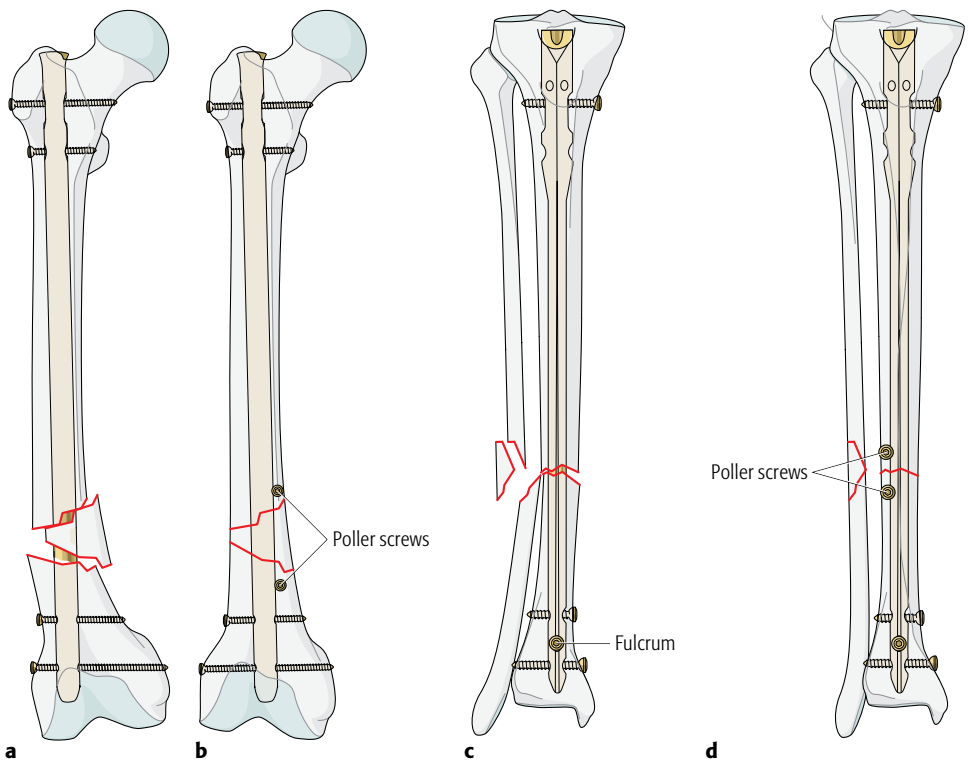

Fig 3.3.1-7a–d With the aid of Poller screws, malalignments can be prevented or corrected, while stability is simultaneously increased.

a Example of a distal femoral fracture: due to the large discrepancy between medullary canal and nail diameter, the intramedullary nail may move a few millimeters sideways along the interlocking screws, which results in varus or valgus deformity.

b Placement of one (distal) or two (distal and proximal) Poller screws before nail insertion prevents malalignment and increases stability (**Video 3.3.1-6**).

c Example of a distal tibial fracture: despite the presence of an AP screw, displacement in the coronal plane can occur in cases of short distal fragments or poor bone stock. The AP screw acts as a fulcrum in these cases.

d Closed reduction and either unilateral or bilateral support with Poller screws placed bicortically in the sagittal plane before nail insertion prevents angulation in the coronal plane.

Exact closure of the fracture gap may be challenging in long oblique and spiral fractures, especially in subtrochanteric femoral fractures. Inserting the nail does not necessarily lead to an appropriate fracture reduction. In such a situation, mini open reduction or percutaneously applied cerclage wires or cables may facilitate fracture reduction. It has been shown that one or two circumferential wires are safe as long as the bone is not devitalized. Wires should be retained to prevent redisplacement after intramedullary nail fixation.

4.3.4 Sequence of locking

In simple diaphyseal fractures with good fracture apposition and no gap, the sequence of locking is not critical. However, intramedullary nails can produce fracture distraction that may cause a significant rise in compartment pressure and/or delay fracture healing. If the intramedullary nail is statically locked, the weight-bearing load is directly transmitted to the interlocking screws, which will eventually fail. Axial deformities are also more likely to develop, especially in

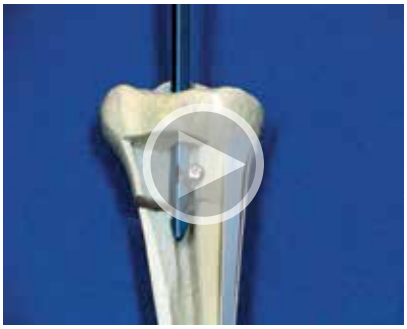

Video 3.3.1-6 Poller screws inserted in the correct way act as fulcrum to redirect the intramedullary nail.



Video 3.3.1-7 Poller screws can be used for alignment, stabilization, and manipulation.

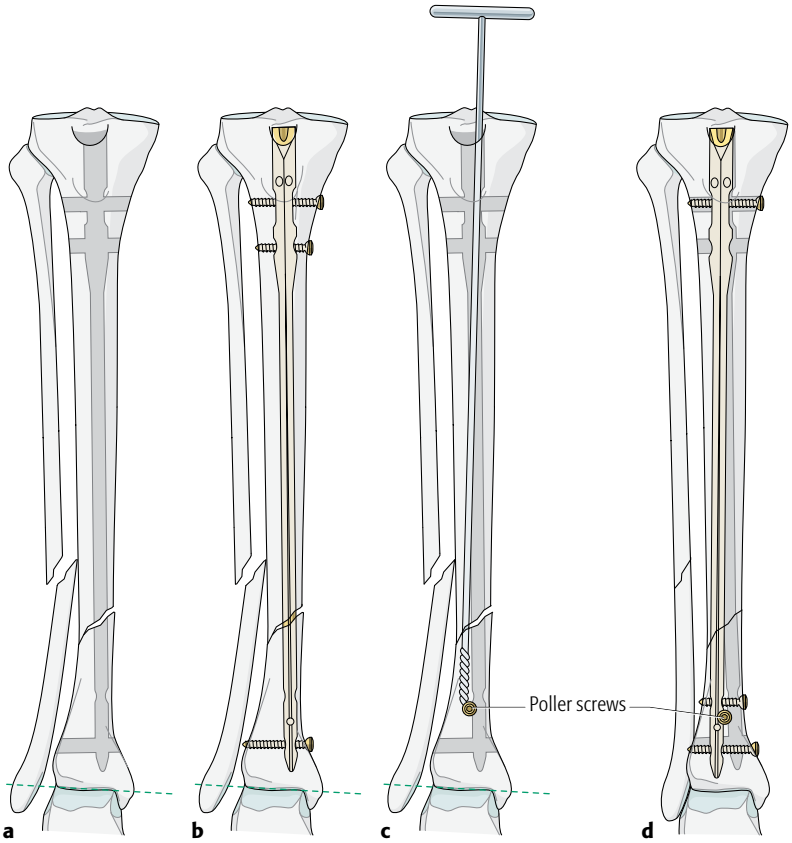

Fig 3.3.1-8a–d Poller screw as a reduction tool in a malunited fracture.

a The fracture healed with valgus malalignment. After nail removal, a refracture occurred.

b Since the original nail path is sclerotic, the new intramedullary nail follows the preexisting path with the same malalignment.

c This problem can be solved by using a Poller screw as a reduction tool: The Poller screw is placed in the old intramedullary nail path to block it, while a new path is prepared with a hand reamer.

d Once the new nail path has been prepared, the new intramedullary nail is inserted and locked, while the Poller screw remains in place.

distal metaphyseal fractures. Locking of the distal end is now recommended as a first step. This gives the opportunity to apply the backstroke technique to adapt and compress the fracture (**Fig 3.3.1-9**). If the intramedullary nail length has been correctly chosen, there should be no problem; otherwise the intramedullary nail may protrude proximally by a few millimeters.

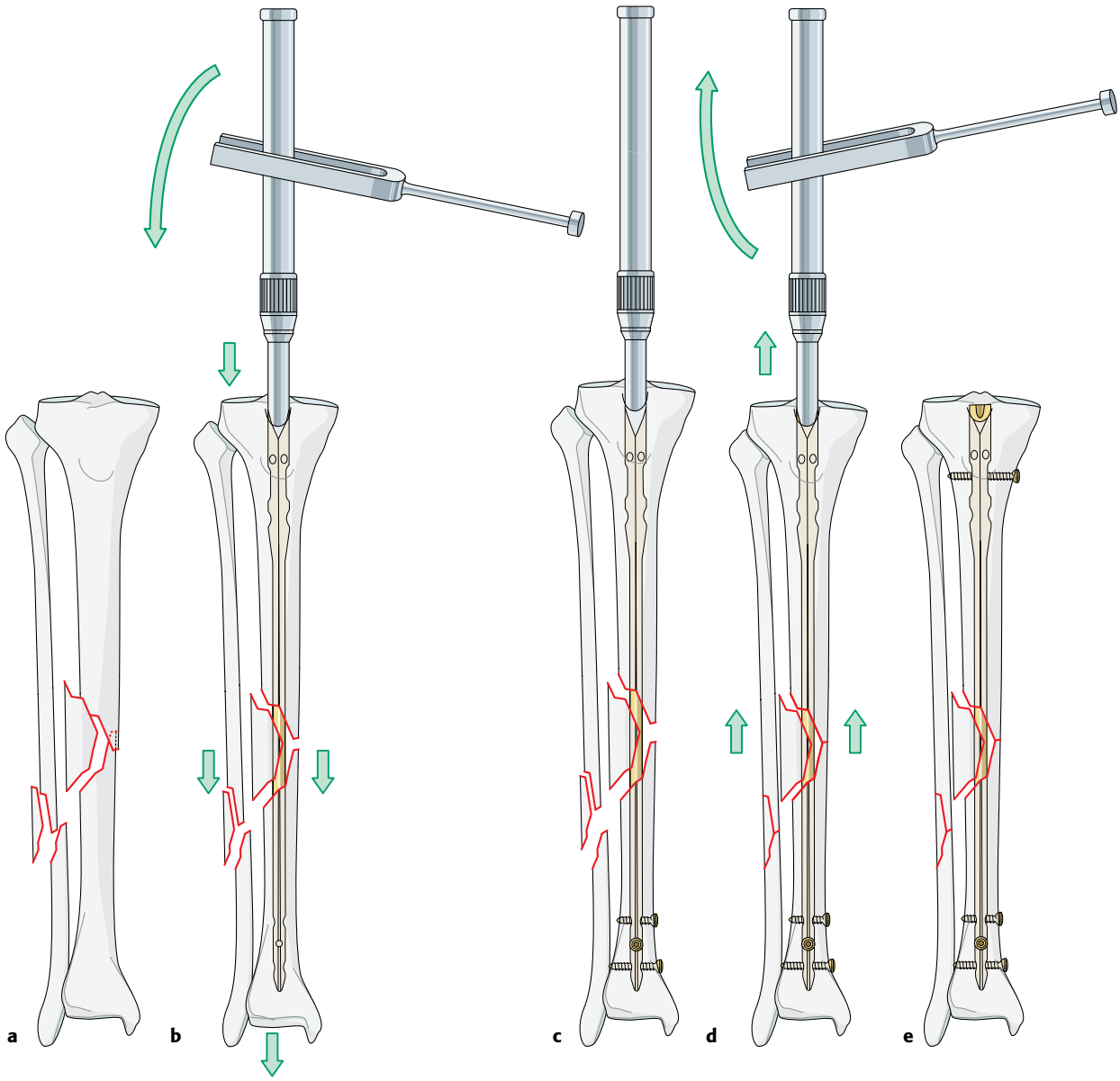

Fig 3.3.1-9a–e Backstroke technique for correction of fracture distraction.
a–b Insertion of an unreamed intramedullary nail frequently results in fracture distraction, which may worsen a compartment syndrome and delay healing.
c Distal locking first with three interlocking screws (increasing strength).
d Careful backstrokes under image intensifier control, until main fragments are reduced or the planned length is achieved.
e Proximal locking, dynamic or static, according to the fracture pattern and fracture location. If the intramedullary nail protrudes proximally, a shorter one should be chosen.

4.3.5 Intraoperative techniques for the control of alignment

Length

Inserting the distal interlocking screws first has the advantage that the distal fragment is fixed to the intramedullary nail. Any further reduction maneuvers can be performed with the insertion handle. In all type C fractures and spiral fractures (A1), reduction and especially length, should be radiologically assessed after distal locking.

To assess length in femoral fractures, the upper margin of the femoral head is brought into line with the measuring device under image intensification (**Fig 3.3.1-1**). This has the length of the contralateral femur marked on it with a clip (femoral head—lateral femoral condyle). Subsequently, the knee joint is viewed and any length discrepancy can be measured between the lateral femoral condyle and the position of the clip. By using a ram with a handle, limb length can be continuously adjusted in both directions (**Fig 3.3.1-10**). It is much easier to evaluate the length of the tibia than that of the femur, although clinical measurement usually suffices for both.

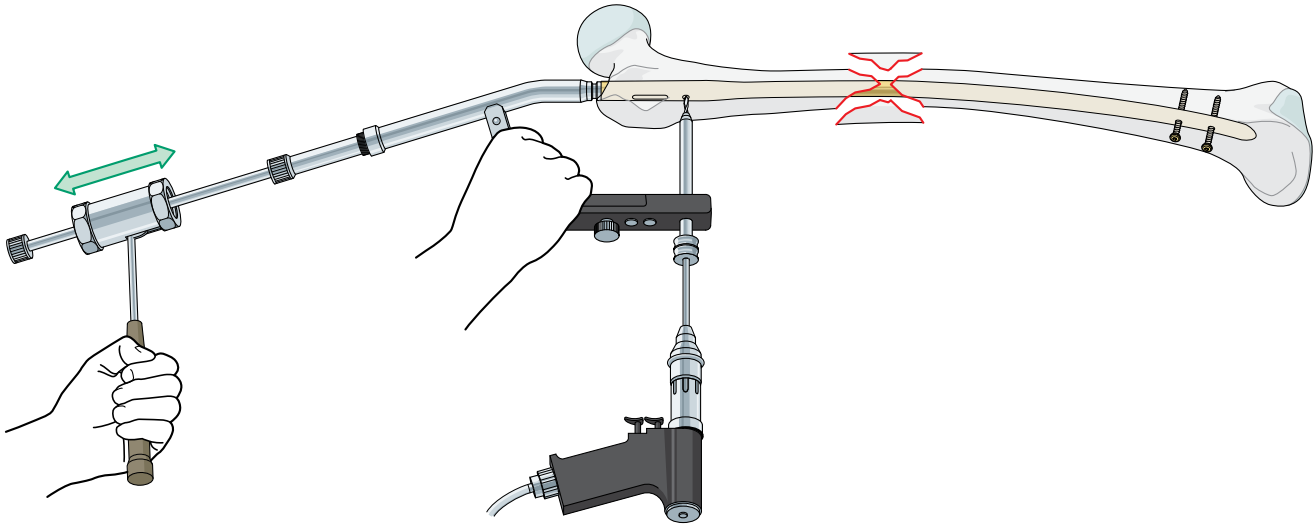

Fig 3.3.1-10 Control of length after distal locking with the sliding hammer and the insertion instruments in place.

Axial alignment

In simple tibial and femoral midshaft fractures, coronal and sagittal plane alignment is usually not a problem. Once the nail passes the fracture, the fracture will remain reduced. The femoral neck angle can be measured and checked by image intensifier. However, the evaluation of the correct weight-bearing axis is more difficult, especially in complex or metaphyseal fractures. The cable technique greatly facilitates intraoperative assessment of axis in the coronal plane with the image intensifier centered on the knee joint. Varus/valgus alignment can now be determined using the projection of the cable (**Fig 3.3.1-11**). The sagittal alignment is determined by lateral x-ray.

Rotation

There are several methods for intraoperative assessment of the rotation of femoral and tibial fractures. Clinical judgment is not precise and depends on the position of the patient and the leg during surgery. Preoperatively, the rotation of the intact limb is established with the knee and the hip flexed at 90°. Intraoperatively, after intramedullary nailing and temporary locking of the fractured bone, rotation is checked again. To do this correctly the insertion handle has to be removed. Draping both limbs facilitates intraoperative assessment of the rotation.

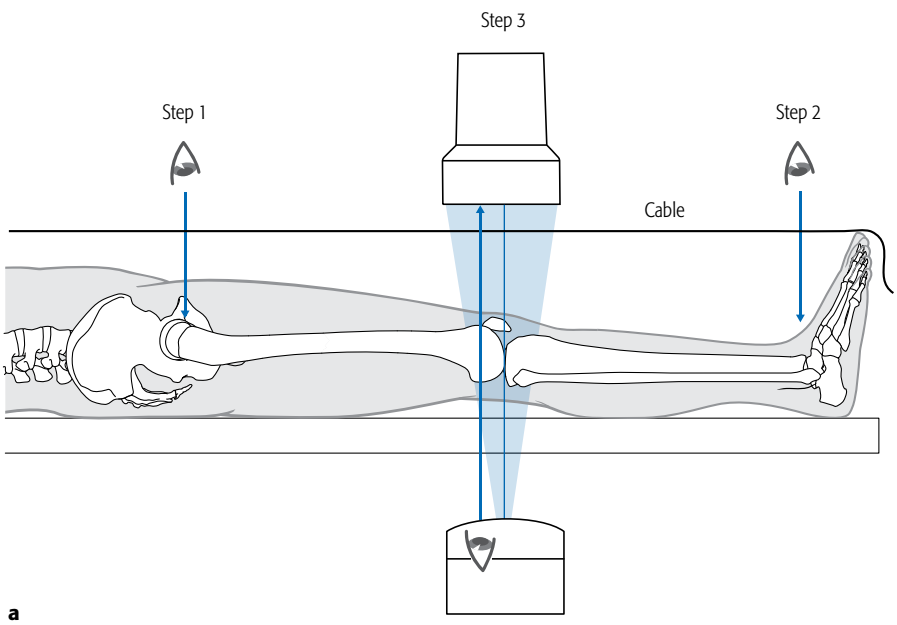

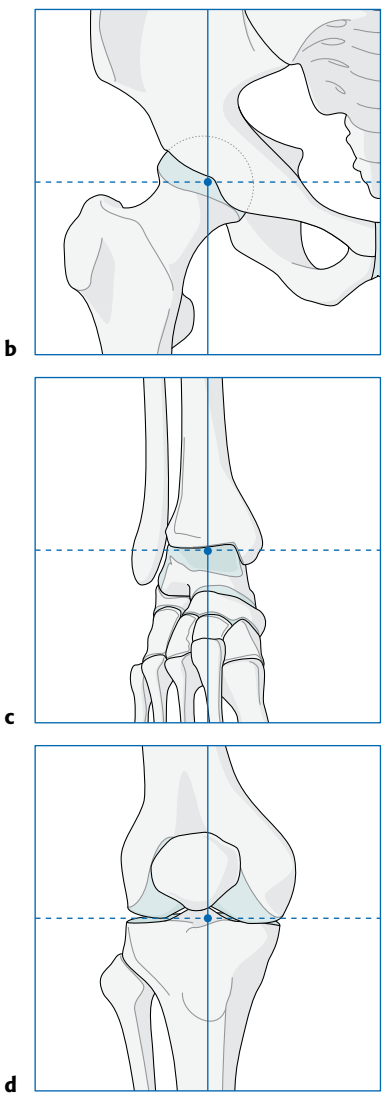

Fig 3.3.1-11 Cable technique for checking alignment in the coronal plane.
a The knee is fully extended and the patella must face anterior.
b Step 1: With the image intensifier beam vertical, the center of the femoral head is centered on the screen. A marker pen is then used to mark the center of the femoral head on the patient's skin.
c Step 2: In a similar way the center of the ankle joint is marked. An assistant then spans the cautery cable between these two surface markings.
d Step 3: When the knee joint is viewed with image intensifier, the cable should run slightly medial to the center of the knee. Any deviation of the projected cautery cable from the center of the joint indicates the axial deviation in the frontal plane.

In the tibia, rotation should be checked with the knee in flexion and the foot dorsally flexed. However, as well as comparing the position of the feet, the range and symmetry of foot rotation also has to be taken into account.

Several radiographic signs can be helpful in assessing femoral rotation. These include:

- Shape of the lesser trochanter (**Fig 3.3.1-12**)
- Thickness of the cortices of the proximal and distal main fragments (cortical step sign)
- Difference in bone diameters

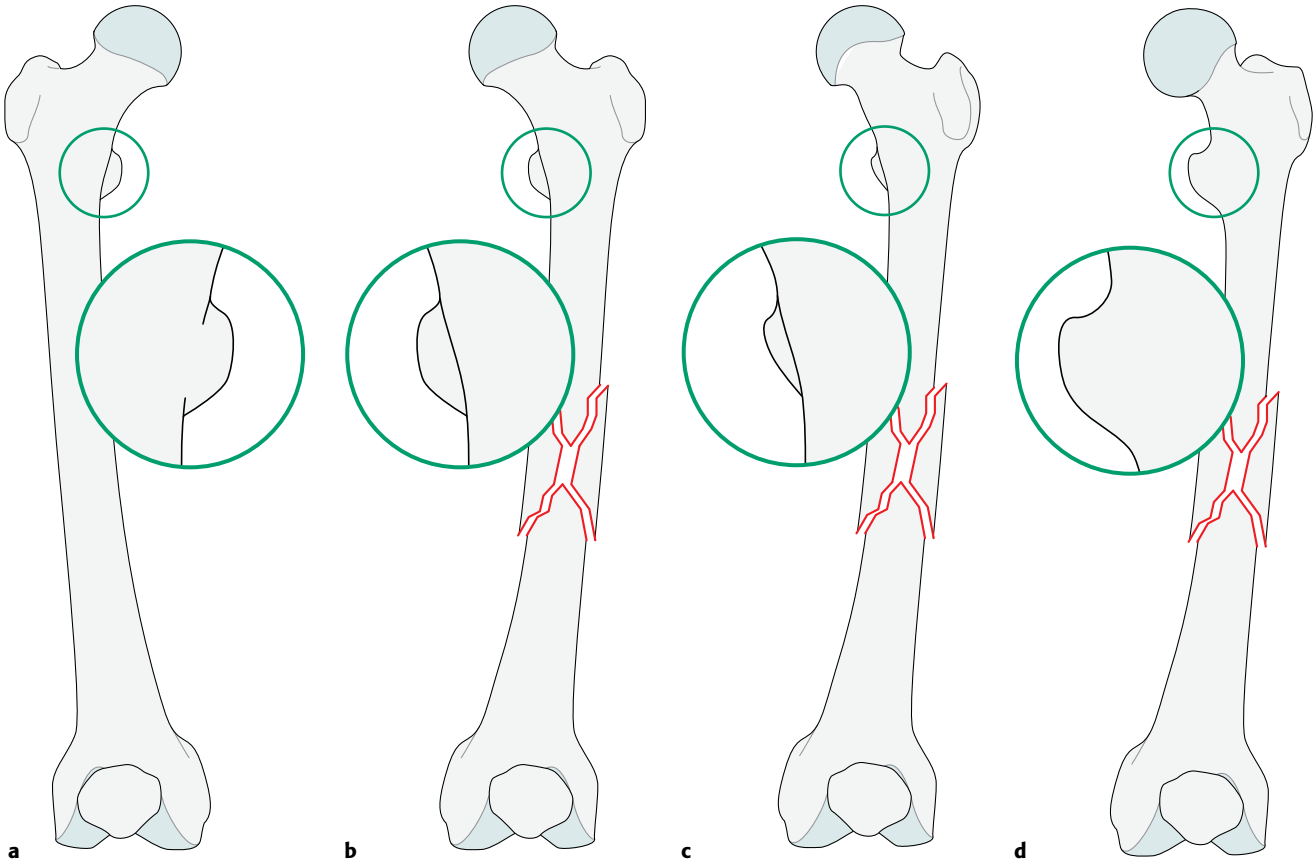

Fig 3.3.1-12a–d Intraoperative radiological assessment of rotation. The shape of the lesser trochanter is compared with the contralateral side (lesser trochanter shape sign).

a Before positioning the patient, the shape of the lesser trochanter of the intact opposite side (patella facing anterior) is stored in the image intensifier.

b After distal locking with the patella facing anterior, the proximal fragment is rotated until the shape of the lesser trochanter matches the stored view of the intact side.

c With external malrotation, the lesser trochanter is smaller and partially hidden behind the proximal femoral shaft.

d With internal malrotation, the lesser trochanter appears enlarged.

The x-ray contour of the lesser trochanter in relation to the proximal femoral shaft depends on the rotation of the bone. Preoperatively, the shape of the lesser trochanter of the uninjured limb (with the patella facing anterior) is analyzed and stored in the image intensifier.

Before proximal locking is performed, the proximal fragment can be rotated around the intramedullary nail using a Schanz screw (while the patella faces anterior), until the outline of the lesser trochanter matches the stored image of the uninjured side. With external malrotation, the lesser trochanter is smaller because it is partially hidden by the femoral shaft. With internal malrotation, the lesser trochanter appears bigger (**Fig 3.3.1-12**, **Video 3.3.1-8**).

In transverse or short oblique fractures, the correct rotation may be judged by the thickness of the cortices of the proximal and distal main fragments (cortical step sign). This is less reliable, however, than the lesser trochanter shape sign (**Fig 3.3.1-13**). In simple diaphyseal fractures, the fracture interdigitation can be used as a clue for correct rotation. If a fracture gap is present it is usually caused by distraction or malrotation.

Finally, the sign of bone diameter may be applied at levels where the bone diameter is rather oval than round. With malrotation, the transverse diameter of the proximal and distal fragment is projected differently. This sign is not that reliable (**Fig 3.3.1-13**).

Video 3.3.1-8 Anatomical landmarks and their use in judging rotational alignment (lesser trochanter shape sign).

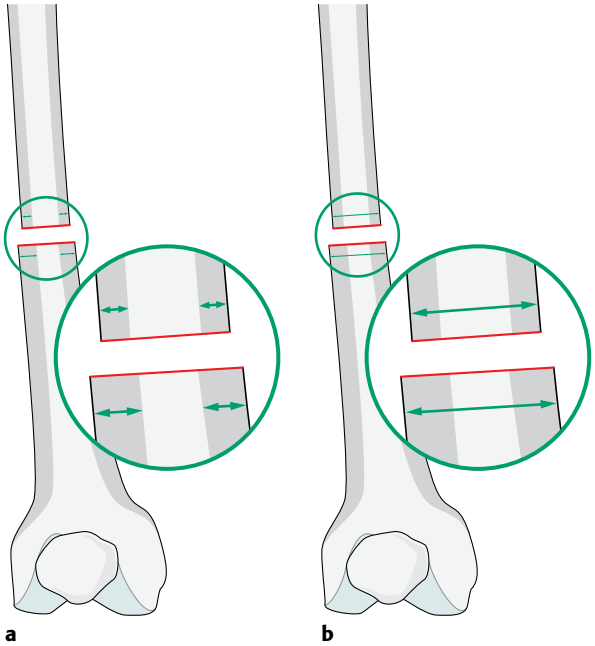

Fig 3.3.1-13a–b Radiological signs of malrotation depending on the cortical thickness and bone diameter.

a Cortical step sign: in the presence of considerable rotational deformity, this can be diagnosed by the different thickness of the cortices.

b Diameter difference sign: this sign is positive at levels where the bone cross-section is oval rather than round. With malrotation, the diameters of proximal and distal main fragments appear to be of different sizes.

4.3.6 Reduction techniques for delayed cases and management of nonunion

In delayed cases, and depending on the time interval, the surgeon faces the following problems:

- Axial deformation (shortening, angulation, and/or translation)
- Rotational deformity
- Tissue ingrowth and early callus formation that make reduction difficult
- Sclerosis at the fracture site with a sealed medullary canal
- Osteoporosis of the main fragments

These conditions make intramedullary nailing difficult because guide wires, reamers, and intramedullary nails are easily deflected and may penetrate the cortex in the wrong direction. Angular deformities can be corrected with the use of a distractor but an offset due to fragment translation is much more difficult to overcome.

In these situations, the use of Poller screws, as described earlier in this chapter, helps to guide instruments and implants in the desired direction. A temporary reduction plate may also be a useful option.

Hypertrophic nonunion after intramedullary nailing of femoral shaft fractures requires exchange nailing with the insertion of a reamed nail with a larger diameter. The increased stability this produces is usually sufficient to achieve union. Exchange nailing requires static locking to obtain maximum stability. Intraoperative compression can provide additional stability. As an alternative, the nail can be left in situ and augmentation plate fixation with or without bone grafting may be used [31]. Applying an additional plate on the lateral aspect of the femur increases rotational stability while alignment is maintained by the nail.

4.3.7 Prevention of malalignment

Selection of the correct entry point in the proximal fragment and a central position of the intramedullary nail in the distal fragment are the most important ways to avoid coronal and sagittal deformities. In proximal or distal metaphyseal fractures, the relatively loose contact between interlocking screws and the nail is a common source of malalignment. New implants with improved 3-D locking options (expert nails) are much better able to maintain stable fracture reduction [3]. Increased stability of the bone-implant construction can be obtained by temporarily adding external fixation devices, Poller screws, or plates (**Fig 3.3.1-8**).

4.4 Fixation techniques/locking

4.4.1 Interlocking screws

Locking is strongly advised in reamed intramedullary nailing and is mandatory in unreamed nailing procedures since the nails are thinner. Stable fracture patterns are treated with a dynamically locked intramedullary nail, which allows axial compression but prevents rotational instability. Distal locking may be done with the freehand technique using an image intensifier (**Fig/Animation 3.3.1-14**). Proximal locking is performed through a guide attached to the insertion handle.

Distally, at least two interlocking screws are recommended because toggling may occur as there is no tight fit between the screws and the nail. This can lead to instability and malalignment, especially in the coronal plane. The insertion of two or more reduces the toggling.

Breakage of an interlocking screw is related to the implant material, design, diameter, and surface finish, the amount of load applied, and the number of cycles.

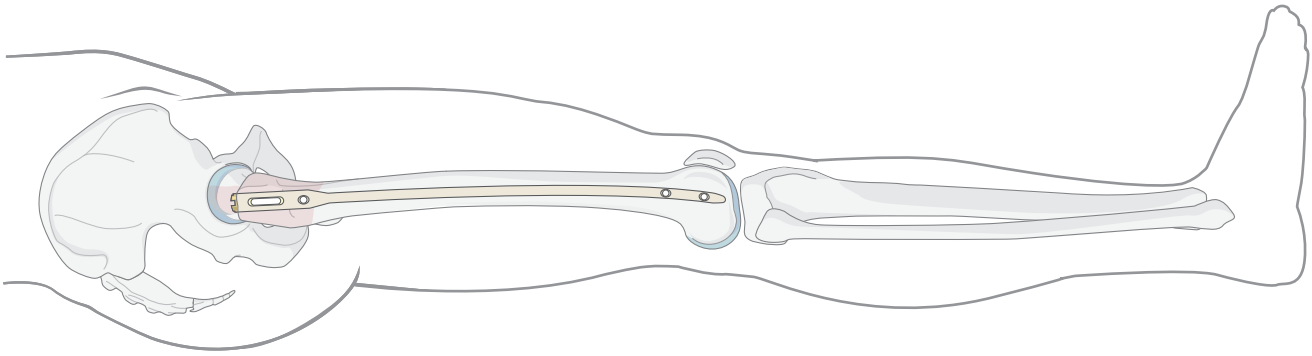

Fig/Animation 3.3.1-14 Freehand technique of distal locking with a radiolucent drive.

Since the distal interlocking screws are usually the weakest part of the intramedullary nail construct, we recommend using the full range of locking options, especially in the distal tibia. Biomechanical data demonstrates that the fatigue strength of an intramedullary nail construct is proportional to the diameter of the interlocking screws. Increasing the number of interlocking screws as well as the interlocking screw diameter will reduce the risk of hardware failure [4].

4.4.2 Dynamization

Dynamization of an intramedullary nail allows controlled axial shortening (impaction) of a fracture with weight bearing to speed up the fracture healing rate. It is achieved by removing static locking screws (from a round hole) while a screw within an oval hole controls alignment and rotation but allows some impaction of the fracture. In the femur, dynamization of statically locked intramedullary nails is rarely advised except in transverse fracture patterns. In the tibia, it may be used in combination with a bone graft for certain fracture patterns with a high risk of delayed fracture healing. The best time seems to be 2–3 months after initial surgery.

Autodynamization results from broken locking screws and is a due to instability. Small diameter locking screws are much more prone to fail than larger diameter screws, especially when not all available locking options were used. Autodynamization may lead to compression at the fracture site and healing but in some cases screw failure increases instability and may impair solid fracture healing. If screw breakage is observed, the patient should be kept under regular review as this may be a sign of a developing non-union.

5 Contraindications

The development of new intramedullary nails designed for different indications has greatly expanded the spectrum of intramedullary nailing in terms of fracture location, fracture pattern, soft-tissue damage, and concomitant injuries.

There are, however, still several biological and mechanical concerns about intramedullary nailing, including:

- Infection at the entry site, within the medullary canal, or at pin sites (after external fixation for damage control)
- Femoral fracture(s) in polytrauma patients with lung injury, where temporary stabilization by external fixation or plating is advocated by some
- Metaphyseal fractures where fixation with interlocking screws may be insufficient to prevent malalignment
- Extremely narrow or deformed medullary canal

Classic references | Review references

6 References

1. **Utvag SE, Reikeras O.** Effects of nail rigidity on fracture healing. Strength and mineralisation in rat femoral bone. *Arch Orthop Trauma Surg*. 1998;118(1-2):7–13.
2. **Melcher GA, Claudi B, Schlegel U, et al.** Influence of type of medullary nail on the development of local infection. An experimental study of solid and slotted nails in rabbits. *J Bone Joint Surg Br*. 1994 Nov;76(6):955–959.
3. **Hansen M, Mehler D, Hessmann MH, et al.** Intramedullary stabilization of extraarticular proximal tibial fractures: a biomechanical comparison of intramedullary and extramedullary implants including a new proximal tibia nail (PTN). *J Orthop Trauma*. 2007 Nov-Dec;21(10):701–709.
4. **Kaspar K, Schell H, Seebeck P, et al.** Angle stable locking reduces interfragmentary movements and promotes healing after unreamed nailing. Study of a displaced osteotomy model in sheep tibiae. *J Bone Joint Surg Am*. 2005 Sep;87(9):2028–2037.
5. **Schemitsch EH, Kowalski MJ, Swiontkowski MF, et al.** Cortical bone blood flow in reamed and unreamed locked intramedullary nailing: a fractured tibia model in sheep. *J Orthop Trauma*. 1994 Oct;8(5):373–382.
6. **Giannoudis PV, Pountos I, Morley J, et al.** Growth factor release following femoral nailing. *Bone*. 2008 Apr;42(4):751–757.
7. **Bhandari M, Guyatt G, Tornetta P 3rd, et al.** SPRINT Trial Randomized trial of reamed and unreamed intramedullary nailing of tibial shaft fractures. *J Bone Joint Surg Am*. 2008 Dec;90(12):2567–2578.
8. **Pfeifer R, Barkatali B, Giannoudis P, et al.** *Physiological Effects Associated With Intramedullary Reaming*. Rommens PM, Hessmann MH, eds. London Heidelberg New York: Springer; 2015.
9. **White T, Petrisor BA, Bhandari M.** Prevention of fat embolism syndrome. *Injury*. 2006 Oct;37 Suppl 4:S59–67.
10. **Vallier HA, Wang X, Moore TA, et al.** Timing of orthopaedic surgery in multiple trauma patients: development of a protocol for early appropriate care. *J Orthop Trauma*. 2013 Oct;27(10):543–551.
11. **Bhandari M, Guyatt GH, Khera V, et al.** Operative management of lower extremity fractures in patients with head injuries. *Clin Orthop Relat Res*. 2003 Feb(407):187–198.
12. **Schult M, Kuchle R, Hofmann A, et al.** Pathophysiological advantages of rinsing-suction-reaming (RSR) in a pig model for intramedullary nailing. *J Orthop Res*. 2006 Jun;24(6):1186–1192.
13. **Dawson J, Kiner D, Gardner W, et al.** The reamer-irrigator-aspirator as a device for harvesting bone graft compared with iliac crest bone graft: union rates and complications. *J Orthop Trauma*. 2014 Oct;28(10):584–590.
14. **Xia L, Zhou J, Zhang Y, et al.** A meta-analysis of reamed versus unreamed intramedullary nailing for the treatment of closed tibial fractures. *Orthopedics*. 2014 Apr;37(4):e332–338.
15. **Anwar IA, Battistella FD, Neiman R, et al.** Femur fractures and lung complications: a prospective randomized study of reaming. *Clin Orthop Relat Res*. 2004 May(422):71–6.
16. **Canadian Orthopedic Trauma Society.** Nonunion following intramedullary nailing of the femur with and without reaming. Results of a multicenter randomized clinical trial. *J Bone Joint Surg Am*. 2003 Nov;85-A(11):2093–2096.
17. **Pape HC, Hildebrand F, Pertschy S, et al.** Changes in the management of femoral shaft fractures in polytrauma patients: from early total care to damage control orthopedic surgery. *J Trauma*. 2002 Sep;53(3):452-61; discussion 61–62.
18. **Canadian Orthopedic Trauma Society.** Reamed versus unreamed intramedullary nailing of the femur: comparison of the rate of ARDS in multiple injured patients. *J Orthop Trauma*. 2006 Jul;20(6):384–387.
19. **Nowotarski PJ, Turen CH, Brumback RJ, et al.** Conversion of external fixation to intramedullary nailing for fractures of the shaft of the femur in multiply injured patients. *J Bone Joint Surg Am*. 2000 Jun;82(6):781–788.
20. **Scalea TM, Boswell SA, Scott JD, et al.** External fixation as a bridge to intramedullary nailing for patients with multiple injuries and with femur fractures: damage control orthopedics. *J Trauma*. 2000 Apr;48(4):613–21; discussion 21–23.
21. **Pape HC, Giannoudis PV, Krettek C, et al.** Timing of fixation of major fractures in blunt polytrauma: role of conventional indicators in clinical decision making. *J Orthop Trauma*. 2005 Sep;19(8):551–62.
22. **Larsen LB, Madsen JE, Hoiness PR, et al.** Should insertion of intramedullary nails for tibial fractures be with or without reaming? A prospective, randomized study with 3.8 years' follow-up. *J Orthop Trauma*. 2004 Mar;18(3):144–149.
23. **Dora C, Leunig M, Beck M, et al.** Entry point soft tissue damage in antegrade femoral nailing: a cadaver study. *J Orthop Trauma*. 2001 Sep-Oct;15(7):488–493.
24. **Linke B, Ansari Moein C, Bosl O, et al.** Lateral insertion points in antegrade femoral nailing and their influence on femoral bone strains. *J Orthop Trauma*. 2008 Nov-Dec;22(10):716–22.
25. **Stannard JP, Bankston L, Futch LA,et al.** Functional outcome following intramedullary nailing of the femur: a prospective randomized comparison of piriformis fossa and greater trochanteric entry portals. *J Bone Joint Surg Am*. 2011 Aug 3;93(15):1385–91.
26. **Hessmann MH, Nijs S, Mittlmeier T, et al.** Internal fixation of fractures of the proximal humerus with the Multiloc nail. *Oper Orthop Traumatol*. 2012 Sep;24(4-5):418–431.
27. **Smekal V, Irenberger A, Struve P, et al.** Elastic stable intramedullary nailing versus nonoperative treatment of displaced midshaft clavicular fractures-a randomized, controlled, clinical trial. *J Orthop Trauma*. 2009 Feb;23(2):106–12.
28. **Farhang K, Desai R, Wilber JH, et al.** An anatomical study of the entry point in the greater trochanter for intramedullary nailing. *Bone Joint J*. 2014 Sep;96-B(9):1274–1281.
29. **Sanders RW, DiPasquale TG, Jordan CJ, et al.** Semiextended intramedullary nailing of the tibia using a suprapatellar approach: radiographic results and clinical outcomes at a minimum of 12 months follow-up. *J Orthop Trauma*. 2014 Aug;28 Suppl 8:S29–39.
30. **Giannoudis PV, Snowden S, Matthews SJ, et al.** Friction burns within the tibia during reaming. Are they affected by the use of a tourniquet? *J Bone Joint Surg Br*. 2002 May;84(4):492–496.
31. **Hakeos WM, Richards JE, Obremskey WT.** Plate fixation of femoral nonunions over an intramedullary nail with autogenous bone grafting. *J Orthop Trauma*. 2011 Feb;25(2):84–89.

7 Acknowledgments

We thank Christian Krettek for his contribution to this chapter in the second edition of the *AO Principles of Fracture Management*.

3.3.2 Bridge plating

Friedrich Baumgaertel

1 Introduction

Plate fixation of fractures is a form of stabilization with the potential for both load-bearing and load-sharing properties. Functional treatment of the limb to preserve muscle strength, coordination, and joint mobility depends on the stability provided by the plate-bone construction. Fracture consolidation is to be expected if the mechanics of fixation and the biology of the fracture are compatible and mutually beneficial.

Biological bridge plating uses the plate as an extramedullary splint fixed to the two main fragments and spanning the fracture zone that is left virtually untouched. Length, alignment, and rotation are restored but anatomical reduction of each fragment is not attempted.

This concept produces relative stability and preserves the natural fracture biology to achieve rapid callus formation and fracture consolidation.

Bridge plating techniques are applicable to all multifragmentary long-bone fractures and where intramedullary nailing or conventional plate fixation is not suitable (**Fig 3.3.2-1**).

With direct fracture reduction and plate fixation with absolute stability, the viability of soft tissues and bone fragments may be jeopardized. This risk exists to a lesser degree in simple fractures (with less soft-tissue injury and less dissection) and thus has less consequence on fracture healing. Fracture surgery must maintain vascularity at the fracture site. This calls for the use of bridging techniques in fracture patterns with significant fragmentation.

Simple type A diaphyseal fractures can be successfully treated with intramedullary nailing, a technique of relative stability, or by anatomical reduction and compression plate fixation, providing absolute stability.

Recent developments in plate design, including angular stability of the plate-screw construct with locking screws, have extended the indication for bridge plating to fractures with less fragmentation. Submuscular plates inserted using minimally invasive approaches and using locking head screws placed well away from simple fractures, can provide relative stability and subsequent bone healing with callus formation similar to intramedullary fixation.

Bridging simple type A diaphyseal fractures to produce relative stability can lead to delayed or nonunion and plate failure. If the soft tissues allow the surgeon to safely achieve absolute stability, this remains the method of choice for plating simple fracture patterns.

Fig 3.3.2-1 Multifragmentary fractures of femur and tibia (33C3 and 41C2). There is also severe soft-tissue injury.

Bridge plating of simple fracture patterns should be avoided because the strain at the fracture site will be above the strain-tolerance of the tissue within the fracture site and so fracture healing will not take place (**Fig/Animations 3.3.2-2–5**). In multifragmentary type C diaphyseal fractures with multiple fragments, a bridging plate allows micromovement between the different fragments but strain is within the strain tolerance of healing tissue, allowing normal callus formation (**Fig/Animation 3.3.2-5**) [1]. If a complex, multifragmentary fracture is splinted in a cast or with a bridge plate, there will be some movement between fragments. However, the system as a whole will tolerate a significant amount of deformation, since it is distributed along the whole distance of the fracture zone. Thus, strain is low and this allows tissue differentiation to progress. Callus formation between intermediate fragments can occur rapidly, even in the presence of (controlled) movement. This is the basis of the Perren strain theory (**Fig/Animations 3.3.2-2–5**). The prerequisites for successful bone healing in this situation are optimal preservation of fragment vascularity and a favorable mechanical and cellular environment for the production of callus (**Fig 3.3.2-6**, **Video 3.2.2-7**).

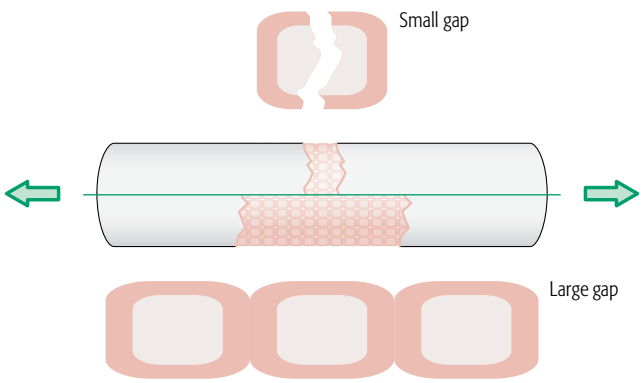

Fig/Animation 3.3.2-2 Perren's strain theory. Motion at the fracture results in deformation producing strain in the granulation tissue at the fracture site.

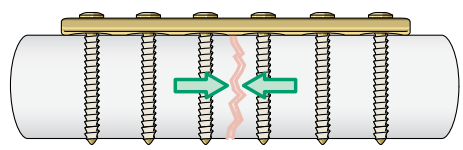

Fig/Animation 3.3.2-3 Perren's strain theory. A perfectly reduced simple fracture (small gap) stabilized under compression (absolute stability and low strain) heals without external callus (direct healing).

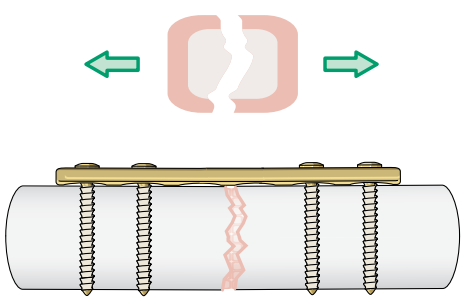

Fig/Animation 3.3.2-4 Perren's strain theory. A simple fracture (small gap) fixed with a bridging plate (relative stability) is exposed to movement (high strain). Fracture healing is delayed or will not occur at all. The plate will eventually fail.

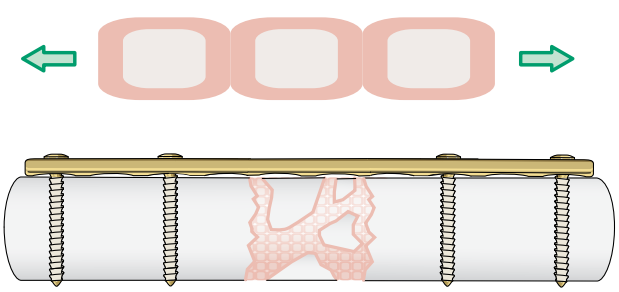

Fig/Animation 3.3.2-5 Perren's strain theory. In a complex fracture (large gap) fixed with a bridging plate (relative stability) the strain will be low despite movement, and fracture healing will occur with callus formation (indirect bone healing).

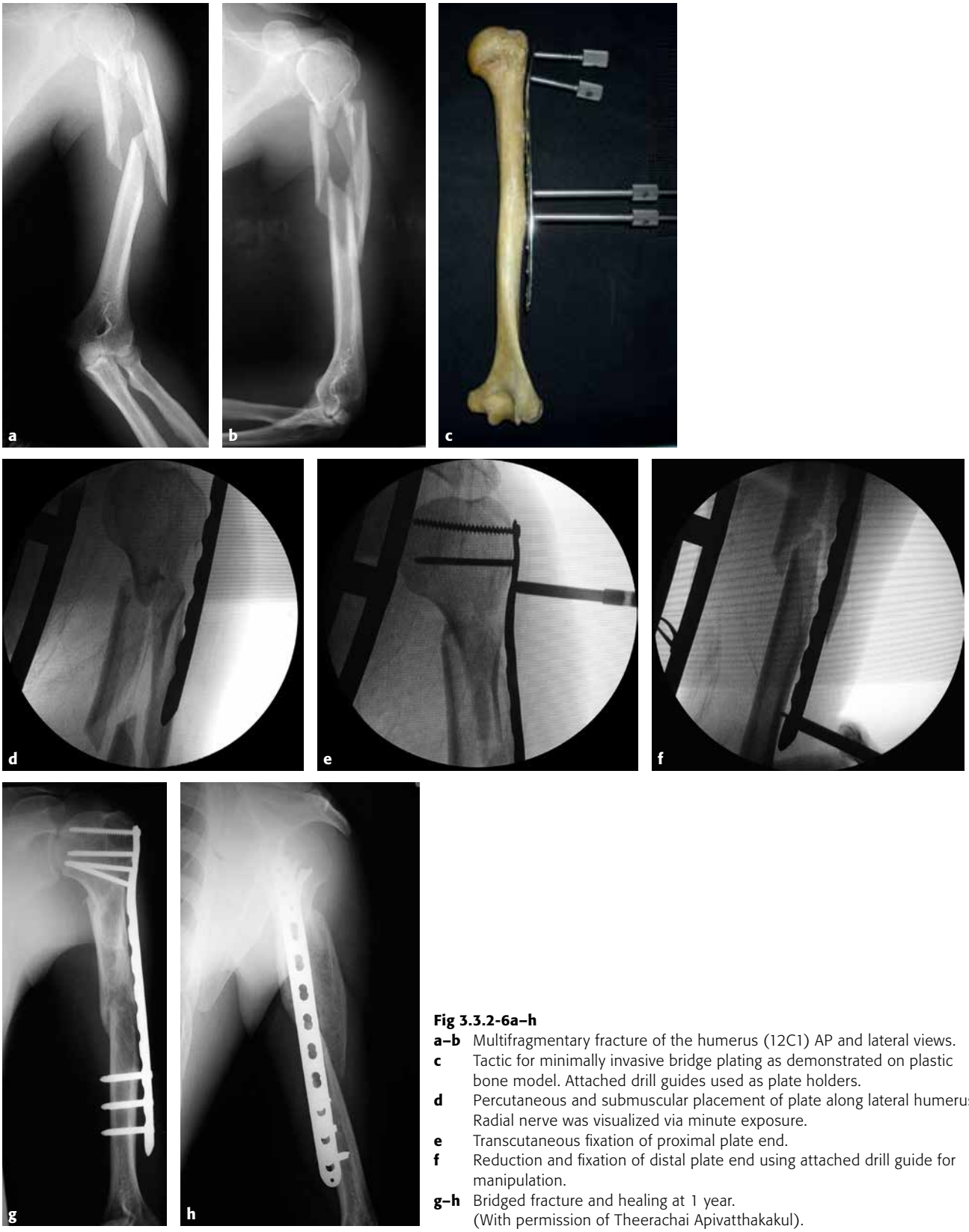

Fig 3.3.2-6a–h

a–b Multifragmentary fracture of the humerus (12C1) AP and lateral views.

c Tactic for minimally invasive bridge plating as demonstrated on plastic bone model. Attached drill guides used as plate holders.

d Percutaneous and submuscular placement of plate along lateral humerus. Radial nerve was visualized via minute exposure.

e Transcutaneous fixation of proximal plate end.

f Reduction and fixation of distal plate end using attached drill guide for manipulation.

g–h Bridged fracture and healing at 1 year.
(With permission of Theerachai Apivatthakakul).

Bone fragments, once they have been stripped of their soft-tissue attachments (periosteum, muscles, etc) will not be incorporated into the early callus because they first need to be revascularized.

In diaphyseal type C fractures, the endosteal blood supply of fragments is, as a rule, interrupted. Preservation of bone vitality relies on periosteal vascularity, which also contributes to fracture healing. In the absence of mechanical continuity between the two main fragments, maintenance of stability entirely lies with the bridging plate. The technique of wide exposure with periosteal stripping to allow precise fragment reduction and fixation by interfragmentary compression and plating should be considered obsolete and must be avoided, as it increases the risk of bone-healing complications in type C fractures [2–3]. Misapplication and misunderstanding of the principles of internal fixation are responsible for most failures and complications in this situation.

Simple metaphyseal fractures (type A) that require plate fixation are best treated with techniques of absolute stability with anatomical reduction and interfragmentary compression. In general, the same principle should be applied to simple metaphyseal fractures with simple articular fractures (C1). However, this technique is not suitable for complex metaphyseal fractures (A3) or those associated with articular fractures (C2 and C3). Anatomical reduction and absolute stability of the joint surface is paramount. The metaphyseal bone, given its better blood supply and good healing qualities, will withstand a higher degree of iatrogenic damage from surgical dissection than will the diaphysis. The critical area is not the metaphysis but its junction with the more compact bone of the diaphysis. These regions of transition remain under significant bending loads and show a tendency to delayed or failed fracture healing. In the past, liberal use of bone grafting was advocated in attempts to restore the biological activity that was compromised by the injury and the subsequent treatment.

Current plating concepts embrace the principle of achieving the correct biomechanical environment while maintaining biology. Plates incorporating angular stability have greatly facilitated bridging multifragmentary metaphyseal segments of bone.

This development allows a more flexible and individualistic approach to internal fixation, based on the personality of the injury. Operative stabilization of a complex multifragmentary fracture requires fracture reduction without interfering with the blood supply and a fixation device that maintains length, alignment and rotation to produce a biological and mechanical environment that stimulates rapid healing by callus (see chapter 3.1.3).

2 Indirect reduction techniques

Biological or bridge plating is usually applied following some form of indirect reduction (see chapter 3.1.3).

The goal of indirect reduction is to manipulate fragments into the correct position without opening the fracture site, thus minimizing further damage to the bone blood supply [4–6]. The mechanical principle underlying indirect reduction is distraction. This principle applies to diaphyseal as well as to metaphyseal bone. The muscular envelope surrounding the diaphysis of long bones provides the mechanical environment for indirect reduction, since a controlled pull on the muscle and periosteal attachments of any single fragment often produces correct alignment. A muscle envelope under distraction exerts concentric (hydraulic) pressure on the shaft, easing fragments into place. This also holds true for metaphyseal and periarticular bone, although the distraction required to align fragments is transferred through capsular tissues, ligaments, tendons, and muscular attachments. This phenomenon, regularly used as part of nonoperative fracture management, is described by the term "ligamentotaxis", coined by Vidal [7]. Traction applied by a traction table to an entire limb produces indirect reduction of a fracture. However, the use of an implant or large distractor attached to a single bone controls reduction more effectively and permits subtle adjustments as well (**Video 3.3.2-1**). Indirect reduction techniques can use a distractor, external fixator, or plate as reduction tools, sometimes in combination. Other tools for indirect reduction include plates

Video 3.3.2-1 The femoral distractor is an excellent tool for indirect fracture reduction.

in conjunction with the articulated tension device, bone spreaders, or screws (**Fig/Animation 3.3.2-7**).

3 Implant considerations

In biological or bridge plating, the surgeon must study the fracture morphology, carefully plan the reduction, and finally choose a plate appropriate to the anatomical location and the configuration of the fracture.

New plates designed for different anatomical locations have different thicknesses, shapes, and widths within the implant itself. Combination holes receiving either locking screw heads or conventional screw heads and/or individual holes that take only locking head screws provide plate functions as required by the fracture pattern. Angular stability at the metaphyseal end of a locking plate allow it to function as a fixed angle device while locking head screws at both ends of the plate allow it to function as an internal fixator. Both techniques allow the implant to act as a bridge plate

Most plates can function as a bridging plate, whether they are conventional (LC-DCP) or locking (LCP).

The common denominator in all bridge plating is the use of a long plate as a splint on the outside of a bone, in the same way a nail splints the bone from within or an external fixator spans the fracture and holds the bone from the outside. Splinting of complex fractures has been a principle applied by surgeons for many years, but it has only recently been accepted as a principle of plate fixation (**Fig 3.3.2-8**).

The original bridge plate was a dynamic compression plate (DCP) used as a "wave" plate, with a central curved segment leaving room for a bone graft. The wave plate reduces interference with the vascular supply of the fracture site by avoiding bone contact but bending forces to the plate, which functions as weight-bearing implant, are considerable. Bridging fractures with a conventional DCP used in minimally invasive plate osteosythesis (MIPO) lacks the mechanical advantage of angular stability achieved by a plate using locked screws (LCP).

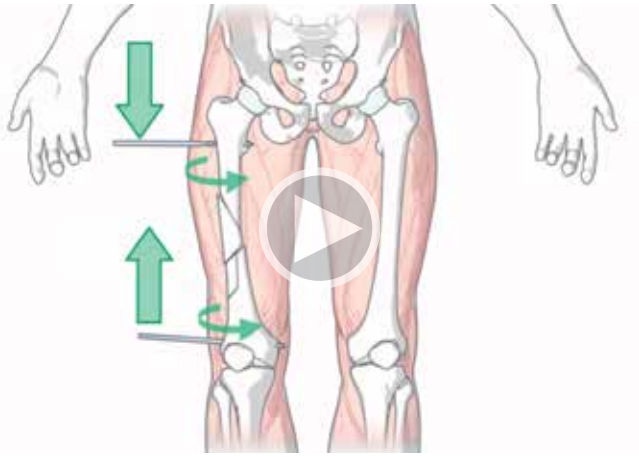

Fig/Animation 3.3.2-7 Shortening and angulation of femoral fracture and indirect reduction by distraction between Schanz screws.

Fig 3.3.2-8a–k A 54-year-old woman was hit by a motor vehicle while walking.
a–b Distal femoral multifragmentary fracture involving the medial and lateral femoral condyles in coronal plane (bilateral Hoffa fractures).

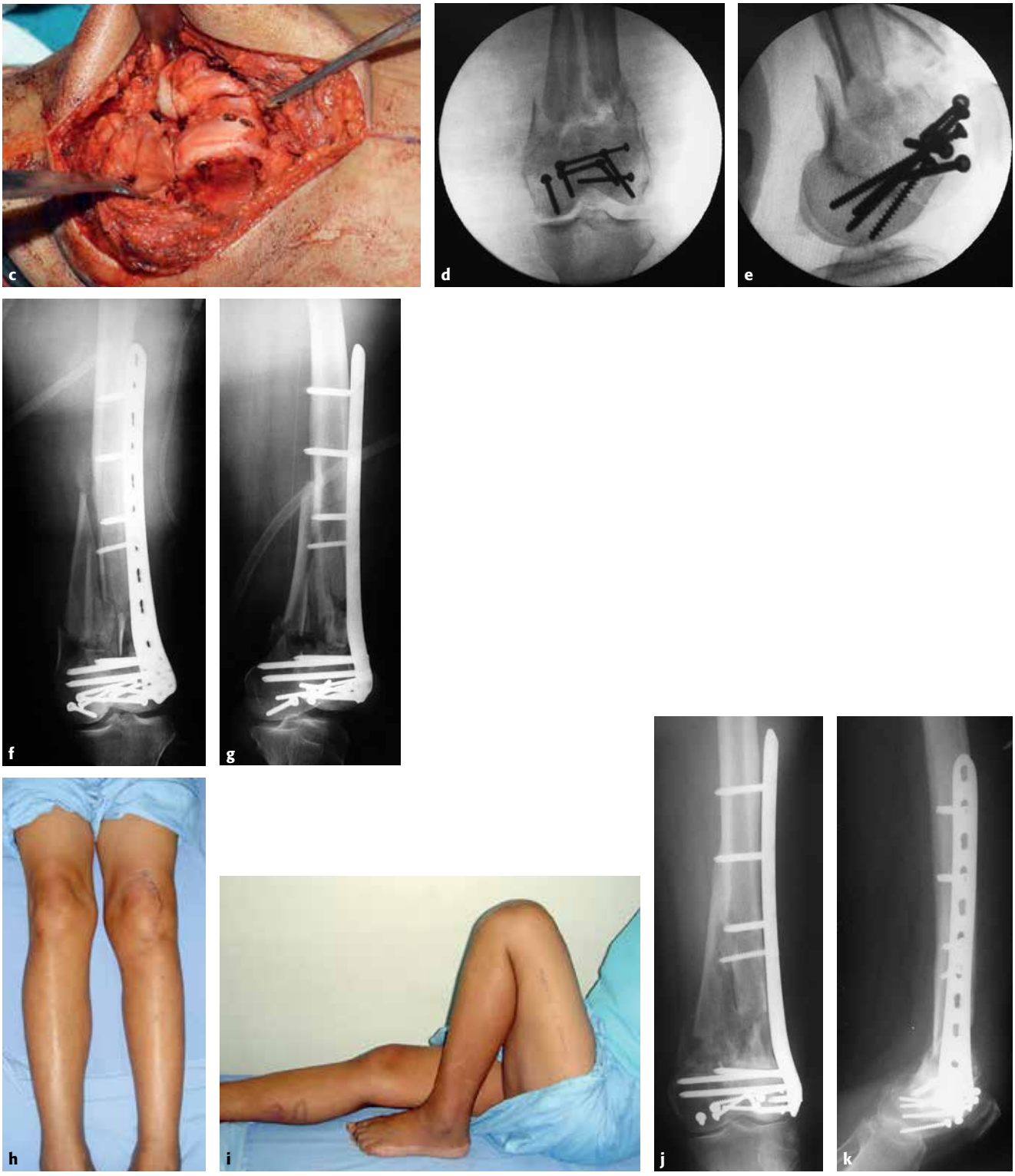

Fig 3.3.2-8a–k (**cont**) A 54-year-old woman was hit by a motor vehicle while walking.
c–e The articular fragments were fixed with countersunk 3.5 mm lag screws.
f–g Immediately postoperative x-rays demonstrated the correct mechanical axis, although the upper part of the plate was not well adapted to the bone due to variation of bone anatomy.
h–k Six months postoperatively the patient had good range of motion and x-rays showed bone consolidation.

Long plates with a long working length allow the distribution of bending stresses over a long segment of the plate and the stress per unit area is correspondingly low. This avoids high strain at the fracture site and reduces the risk of plate failure (**Fig/Animation 3.3.2-9**).

In simple (type A) fractures, repetitive bending stresses will be concentrated and centered on a short segment of a plate with a high risk of failure. If stress is concentrated on a screw hole, it may break more easily due to fatigue. The incidence of mechanical failure can be considerably reduced if longer plates are used despite short zones of comminution, so that stresses are deliberately distributed over a proportionately longer section of the plate. This is accomplished by fixing the end of the plate over longer segments, well away from the fracture, and spacing the screws. This produces an elastic construction [8, 9]. Fewer screws are needed, especially when using locked screws, since screw pull-out force increases with the distance to the fracture zone (see chapter 3.3.4) (**Fig 3.3.2-10**). This internal fixator principle is based on the locking head screws providing angular stability and minimizing the area of contact between plate and bone, thus interfering less with periosteal blood supply while enhancing axial stability. The LCP also displays a more even distribution of strength throughout the plate, reducing stress risers at a screw hole [10].

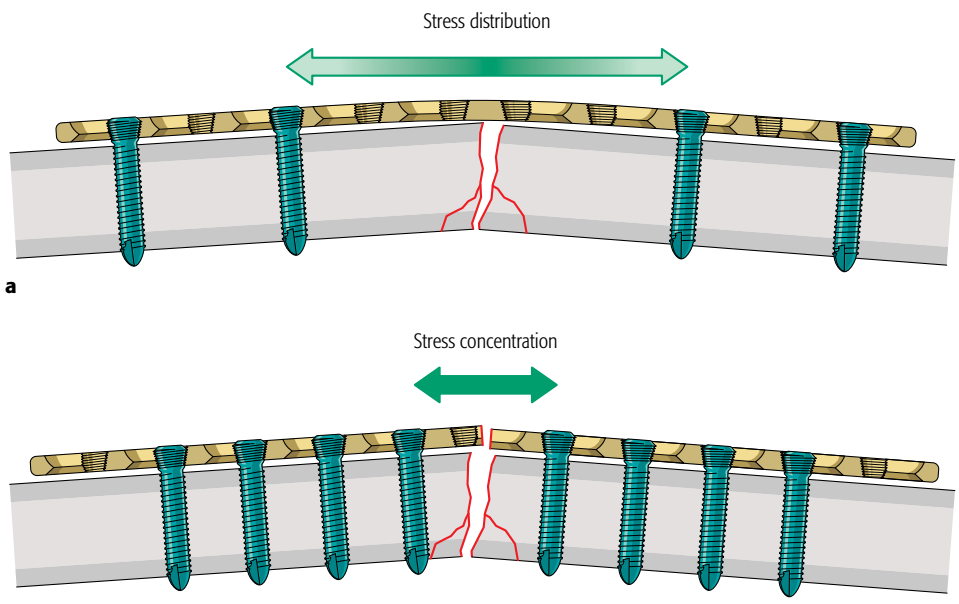

Fig/Animation 3.3.2-9a–b If there is a fracture gap, stress concentration on one screw hole may lead to fatigue failure.

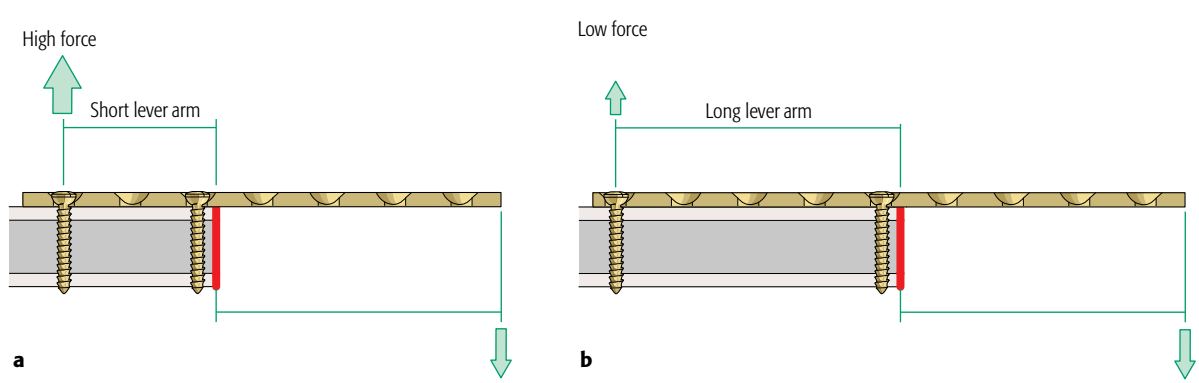

Fig 3.3.2-10 Long lever arms decrease screw loading.
a A short lever arm leads to a high pull-out force on the screw.
b Increasing the lever arm reduces the pull-out force.

4 Soft-tissue considerations

Biological plating provides relative stability, preserves vascularity around the fracture and allows controlled micromotion, resulting in more rapid and abundant callus formation, similar to that observed in intramedullary nailing or in nonoperative fracture treatment. However, the success of this operative approach greatly depends on how the surgeon handles the soft tissues and on how well the anatomical characteristics of any given fracture have been taken into consideration during the planning and execution of surgery. Newer, anatomical approaches reflect the trend to minimal exposure of the bone (see chapter 3.1.3).

The muscle envelope over the fracture site is rarely elevated from the intermuscular septum. The periosteum is left untouched and ligation of the perforating vessels should be avoided, if possible. The plate is gently inserted through a tunnel between muscle and bone, and over the periosteum.

It is most important not to damage the soft-tissue envelope around the fracture site.

The exposure can safely be extended to control the plate position, center the plate on the bone, and adjust fracture alignment at either end of the long-bridging plates. Excessive traction on the wound, to avoid a longer incision, is a poor surgical technique [11].

In the tibia, a plate can be introduced subcutaneously on the medial side. However, care should be taken not to place excessive tension on the delicate overlying skin: locking screws can result in the plate standing off the bone causing skin tension and wound healing problems [12]. For placement lateral to the tibial crest, more dissection with a sharp elevator is necessary at the proximal metaphysis. Screws are easily introduced through stab incisions but surgeons must be aware of the anatomy and potential to damage cutaneous nerves.

Other areas of application for minimal access plating include the humerus, distal femur, proximal and distal tibia [11]. These locations have distinct anatomical characteristics requiring exact plate positioning. Anatomically designed plates, in combination with locking head screws, have improved the ability to apply these techniques. The surgeon may find it necessary to combine direct open reduction of the articular components with indirect reduction and submuscular positioning of the plate for associated metaphyseal or diaphyseal fractures (**Fig 3.3.2-11**). If difficulties occur, a conventional approach is advisable and this still allows careful handling of the soft-tissues and minimal exposure of the bone itself. Even when using biological techniques, the surgeon must always be mindful of soft-tissue damage caused by the initial trauma. Soft-tissue retractors and reduction tools, such as plate holding forceps, should not be used since they leave large tracks and can cause significant soft-tissue stripping and crushing. We recommend pointed reduction forceps, ball spikes, picks, and joysticks as instruments for bone manipulation in combination with instruments of distraction.

Fig 3.3.2-11a–g Bridge plating with the less invasive stabilization system proximal lateral tibia (LISS-PLT) using minimally invasive plate osteosynthesis (MIPO).

a–b Multifragmentary articular proximal tibial fracture (41C3) extending into the tibia shaft.

c Intraoperative photograph showing the limited exposure for the articular reconstruction and the submuscular plate insertion as well as the small incisions for the more distal locking head screws. Surgeons must be aware of the position of the superficial peroneal nerve.

d–e Open reconstruction of articular components with independent lag screws. Bridging of the meta-/diaphyseal fracture zone with a 14-hole tibia LISS fixed with locking head screws to the distal main fragment. The large intermediate butterfly fragment has been reduced by two additional lag screws in AP direction.

f–g The patient was immediately allowed to freely move the limb and start partial weight bearing of 15–30 kg after 3 weeks. Follow-up x-rays after 1 year.
(With permission by Christoph Sommer.)

In grade III open fractures or closed injuries with considerable soft-tissue contusion, bridge plating is not the first choice for fixing a multifragmentary fracture in an emergency situation. Here, a bridging external fixator or the use of intramedullary nailing may be indicated (see chapters 3.3.3 and 3.3.1). Bridge plating techniques are often applied later, when the soft-tissue injury has stabilized (**Fig 3.3.2-12**).

The Masquelet technique, described in 1986 for the treatment of bone defects, uses a plate to bridge a bone defect (caused by injury or debridement), which is filled by an antibiotic cement spacer. The foreign body reaction results in a vascularized (induced) membrane, which serves as a pouch for cancellous autogenous bone grafting 6 to 8 weeks later [13].

The management of difficult fractures is demanding and requires experience, as well as careful planning of options and tactical steps. Major pitfalls are the correct axial and rotational alignment, as these can only be judged indirectly.

5 Summary

Techniques of indirect reduction in combination with bridge plating have proven, experimentally and clinically, to optimize healing in complex, multifragmentary fractures. Direct anatomical reduction and interfragmentary compression to provide absolute stability should be reserved for simple fractures with minimal soft-tissue injuries. With locking plates, the trend to minimally invasive surgery continues, so that submuscular tunneling and plate introduction will be facilitated by new reduction tools, and instruments for radiographic, endoscopic viewing and navigated surgery.

A prerequisite for successful biological plating is a sound knowledge supported by practical experience in the art and skill of conventional compression plating.

Fig 3.3.2-12a–h Closed fracture of the left lower leg (42B2).
a–b AP and lateral preoperative x-rays. Length and alignment of the bone was satisfactory. There was minor malrotation.
c–d AP and lateral postoperative x-rays. Using the distractor for indirect reduction, percutaneous bridge plating of the tibia and intramedullary splinting of the fibula were carried out. No attempt was made to achieve anatomical reduction. Intermediate screws were placed in the main fragments only. Great care was taken with skin closure at the medial malleolus to avoid tension from the underlying plate.
e–f AP and lateral views at 5 months. The fracture healed by indirect bone healing. Length and alignment were correct.
g–h AP and lateral views at 1 year. Remodeling was complete.

Classic references | Review references

6 References

1. **Perren SM.** The concept of biological plating using the limited contact-dynamic compression plate (LC-DCP). Scientific background, design and application. *Injury.* 1991;22(Suppl 1):1–41.
2. **Lies A, Scheuer I.** Die mediale Abstützung—Bedeutung und Möglichkeiten der Wiederherstellung bei Osteosynthesen. *Hefte Unfallheilkunde.* 1981;153:243–248. German.
3. **Bolhofner BR, Carmen B, Clifford P.** The results of open reduction and internal fixation of distal femur fractures using a biologic (indirect) reduction technique. *J Orthop Trauma.* 1996; 10(6):372–377.
4. **Baumgaertel F, Gotzen L.** [The "biological" plate osteosynthesis in multi-fragment fractures of the para-articular femur. A prospective study]. *Unfallchirurg.* 1994;97(2):78–84. German.
5. **Baumgaertel F, Perren SM, Rahn B.** [Animal experiment studies of "biological" plate osteosynthesis of multi-fragment fractures of the femur]. *Unfallchirurg.* 1994 Jan;97(1):19–27. German.
6. **Mast, J, Jakob R, Ganz R.** *Planning and Reduction Technique in Fracture Surgery.* Berlin Heidelberg New York: Springer; 1989.
7. **Tepic S, Remiger AR, Morikawa K, et al.** Strength recovery in fractured sheep tibia treated with a plate or an internal fixator: an experimental study with a two-year follow-up. *J Orthop Trauma.*1997 Jan; 11(1):14–23.
8. **Vidal J.** External fixation: current state of the art. In: Brooker HS, Edward CC, eds. *Treatment of Articular Fractures by "Ligamentotaxis" With External Fixation.* Baltimore: Williams & Walkins; 1979.
9. **Schmidtmann U, Knopp W, Wolff C, et al.** [Results of elastic plate osteosynthesis of simple femoral shaft fractures in polytraumatized patients. An alternative procedure]. *Unfallchirurg.* 1997 Dec; 100(12):949–956. German.
10. **Hunt SB, Buckley RE.** Locking plates: a current concepts review of technique and indications for use. *Acta Chir Orthop Traumatol Cech.* 2013; 80(34):185–191.
11. **Krettek C, Schandelmaier P, Miclau T, et al.** Transarticular joint reconstruction and indirect plate osteosynthesis for complex distal supracondylar femoral fractures. *Injury.* 1997; 28 Suppl 1:A31–A41.
12. **Krettek C, Schandelmaier P, Miclau T, et al.** Minimally invasive percutaneous plate osteosynthesis (MIPPO) using the DCS in proximal and distal femoral fractures. *Injury.* 1997; 28(Suppl 1):A20–A30.
13. **Helfet DL, Shonnard PY, Levine D, et al.** Minimally invasive plate osteosynthesis of distal fractures of the tibia. *Injury.* 1997; 28 Suppl 1:A42–A47; discussion A47–48.
14. **Giannoudis P, Faour O, Goff T, et al.** Masquelet technique for the treatment of bone defects: tips-tricks and future directions. *Injury.* 2011 Jun; 42(6):591–598.

7 Acknowledgment

We thank John H Wilbur for his contribution to this chapter in the second edition of the *AO Principles of Fracture Management.*

3.3.3 External fixator

Dankward Höntzsch

1 Introduction

The external fixator is one of the mainstays of operative fracture treatment. It allows "local damage control" for fractures with severe soft-tissue injuries and can be used for definitive treatment of many fractures. It provides relative stability that results in healing by callus formation. External fixation is an essential part of damage-control surgery in polytrauma, as it permits rapid stabilization of fractures with minimal additional (surgical) injury. A main indication is bone fixation in cases of bone infection. Deformity correction and bone transport are also possible with external fixation.

2 Why utilize the external fixator?

2.1 Advantages

There are various methods of internal fixation for the treatment of fractures but at certain times it is inappropriate to perform internal fixation as primary treatment. External fixation has the following advantages:

- Less damage to the blood supply of the bone
- Minimal interference with soft-tissue cover
- Rapid application in an emergency situation
- Stabilization of open and contaminated fractures
- Adjustment of fracture reduction and stability without surgery
- Minimal foreign body in the presence of infection
- Less experience and surgical skill required than for standard open reduction and internal fixation (ORIF)
- Bone transport and deformity correction possible

2.2 Indications for external fixation

2.2.1 Open fractures

External fixation is one option for the temporary or definitive skeletal stabilization of open fractures, in particular those with severe soft-tissue injury [1].

It is also useful in cases where there is a higher risk of infection, eg, delayed treatment and/or wound contamination. It has long been a useful device for managing such injuries and remains the gold standard for several reasons.

External fixation can be applied with minimal trauma, avoiding additional damage to soft tissues and bone vascularity.

2.2.2 Closed fractures

In closed fractures, external fixation is indicated for temporary bridging in severe polytrauma [2, 3] and severe closed soft-tissue contusions or degloving.

Delayed open reduction is recommended for some closed fractures with severe soft-tissue injury and polytrauma. In these cases, a temporary external fixator may be applied outside the zone of injury and, ideally, outside the zone of potential surgery to maintain the alignment of the limb while treating the soft tissues.

2.2.3 Polytrauma

External fixation should be considered for damage-control surgery in polytrauma. It can be performed rapidly and, because it is a minimally invasive technique, it will minimize any additional surgical insult to the patient [2, 3].

External fixation can be used for almost every long bone and large joint fracture. The main advantage of this approach is the rapid achievement of relative stability that helps to control pain, decrease bleeding, lessen systemic inflammatory response syndrome [3], and facilitate nursing care.

2.2.4 Articular fractures

Perfect joint reconstruction with interfragmentary compression and absolute stability, allowing early pain-free motion, is the treatment goal for articular fractures. This goal can

be achieved by ORIF or, for simple fracture patterns, by a combination of interfragmentary lag screw fixation with an external fixator. This is generally a temporary measure designed to protect delicate soft-tissues associated with an unstable or complex articular fracture, or to cope with joint dislocations that do not permit primary definitive internal fixation or ligament repair. Any major joint can be bridged in this way [4, 5] but it is most common in the wrist, knee and ankle.

2.2.5 Bone or soft-tissue loss

External fixators provide the surgeon with the unique opportunity to manage major soft tissue and bone loss by primary shortening of the limb followed by secondary distraction osteogenesis to restore limb length. In some cases this will avoid the need for major plastic surgical reconstruction.

2.2.6 External fixator as a tool for indirect reduction

The external fixator can be used as a tool to perform indirect reduction during minimally invasive osteosynthesis [6]. Once the fracture has been reduced, the position is maintained by locking the external fixator while the internal fixation plate or intramedullary nail is inserted and secured. In some situations, when the internal fixation does not provide adequate stability, the external fixator can be left in situ for a short period to provide additional support.

One way to achieve minimally invasive intraoperative reduction is to apply the modular external fixator as an external reduction device.

External fixators or femoral distractors have proven their value for intramedullary nailing of the tibia. Steinmann pins are inserted in the proximal tibial, posterior to the entry point for the intramedullary nail, and in the calcaneus, and joined by long tubes. This achieves well-balanced local traction with which length, alignment, and rotation can be adjusted; the intramedullary nailing can be performed without obstruction, with the knee joint in flexion or extension (**Video 3.3.3-1**).

3 External fixation principles

3.1 Biomechanical aspects

The surgeon must understand the biomechanical principles to correctly apply an external fixation device to achieve adequate stability. At least two pins must be inserted into each main fragment through an anatomical safe zone. Pins should be spread as wide apart as possible. If the soft-tissue situation allows, pins are inserted as close to the fracture focus as possible but should not enter the fracture hematoma or degloved areas. If delayed internal fixation is planned, the pins should avoid potential incisions and surgical approaches (the zone of surgery). The connecting tube should be placed as close as possible to the bone to increase stability.

Video 3.3.3-1 Application of a distraction frame with tibial nailing.

The stiffness of the frame depends upon the following factors (**Fig 3.3.3-1**):

- Distance of the pins/Schanz screws from the fracture focus: closer means stiffer
- Distance between the pins/Schanz screws inserted in each main fragment: further apart means stiffer
- Distance of the longitudinal connecting tube/bar from the bone: closer means stiffer
- Number of bars/tubes: two are stiffer than one
- Configuration (low to high stiffness): uniplanar/A-frame/biplanar
- Combination of limited internal fixation (lag screw) with external fixation: only rarely indicated as mixing elastic with stable fixation is for temporary use only
- Thickness of Schanz screws or Steinmann pins—6 mm vs 5 mm pins (double bending stiffness)

Unstable external fixation will delay fracture healing. However, too much stiffness or rigidity of the external fixator construction may also delay fracture healing.

It may be necessary to dynamize a stable fixator configuration and increase load through the fracture site by partial or full weight bearing and/or by modifying the frame construction [7].

3.2 Pin insertion technique

When inserting a Steinmann pin or Schanz screw the following is important:

- Know the anatomy and avoid nerves, vessels, and tendons
- Do not place pins or screws into a joint
- Avoid the fracture focus and hematoma
- Avoid degloved and contused skin
- Predrill the cortex to avoid burning the bone (ring sequestrum is produced)
- Insert a Schanz screw of the correct length to allow appropriate frame construction

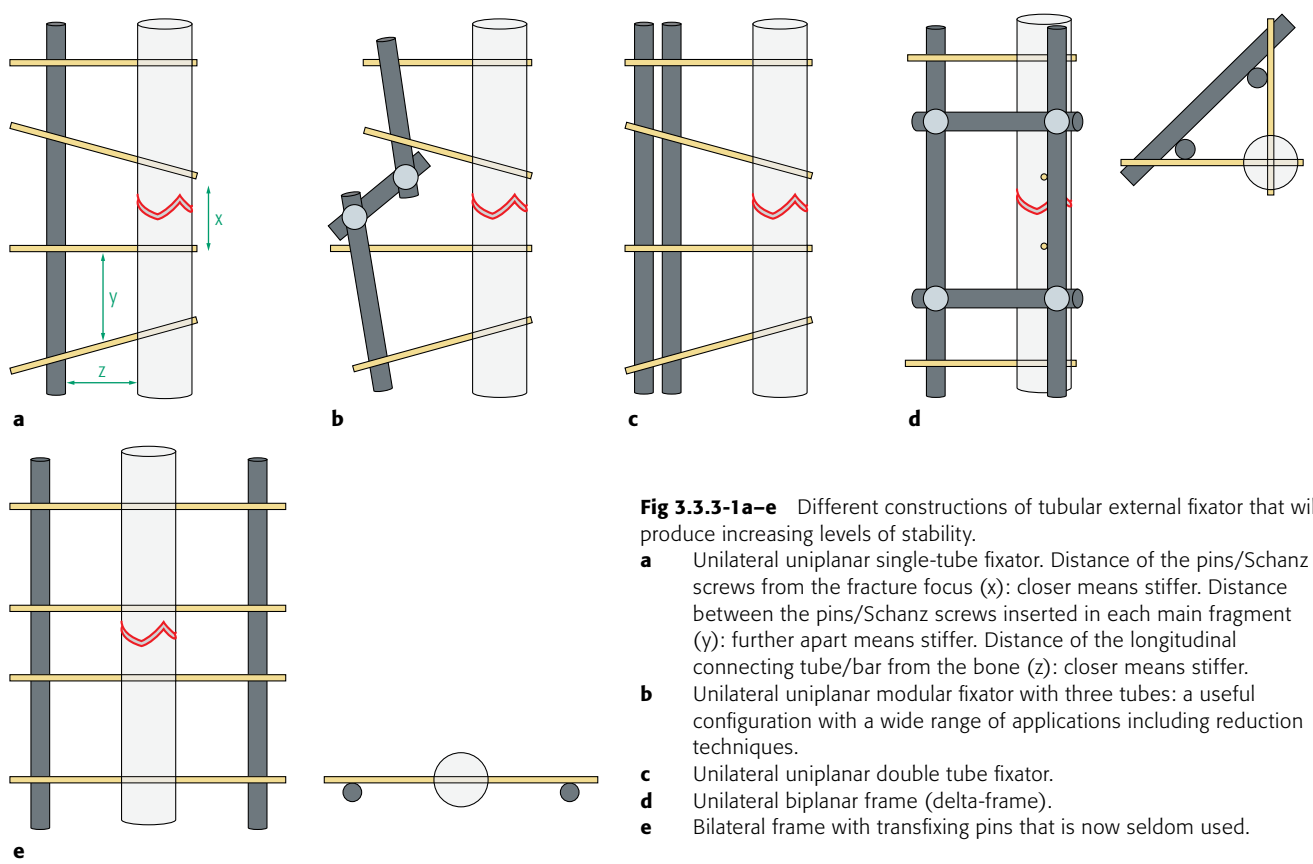

Fig 3.3.3-1a–e Different constructions of tubular external fixator that will produce increasing levels of stability.

a Unilateral uniplanar single-tube fixator. Distance of the pins/Schanz screws from the fracture focus (x): closer means stiffer. Distance between the pins/Schanz screws inserted in each main fragment (y): further apart means stiffer. Distance of the longitudinal connecting tube/bar from the bone (z): closer means stiffer.

b Unilateral uniplanar modular fixator with three tubes: a useful configuration with a wide range of applications including reduction techniques.

c Unilateral uniplanar double tube fixator.

d Unilateral biplanar frame (delta-frame).

e Bilateral frame with transfixing pins that is now seldom used.

3.2.1 Diaphysis

It is essential to avoid thermal damage to the bone when inserting a pin or Schanz screw into hard cortical bone.

The sharper the drill bits or screws, the less heat is generated. The temperature rises as the insertion speed increases. Burning the bone can be a serious problem and may result in early loosening due to ring sequestrum formation and/or infection. A correctly inserted pin or screw should find purchase in the opposite cortex but not protrude too far beyond it.

3.2.2 Metaphysis

In metaphyseal bone, heat generation is not such a problem. It may be safer to use self-drilling screws since it is easy to miss the predrilled hole. Joint penetration must be avoided because of the danger of pin-track infection spreading into a joint. The surgeon must be aware of the insertion of the joint capsule.

3.2.3 Safe zones

To avoid injuries to nerves, vessels, tendons, and muscles, the surgeon must be familiar with the anatomy of the different cross-sections [8] of the limb and make use of the safe zones for pin placement (**Fig 3.3.3-2**).

In the tibia, it is not necessary to place the Schanz screws at the anterior tibial crest in a uniplanar application. Stability in the tibial crest is high due to the thick cortex. However, excessive purchase in the cortex is usually not required because of the adequate thickness of the anteromedial tibial wall and bicortical anchorage of the Schanz screws. The drilling of a hole in the thick tibial crest may be associated with excessive heat generation and subsequent necrosis of the bone. Insertion of a Schanz screw at the tibial crest may be difficult as the tip of the drill bit may slip medially or laterally, damaging the soft tissues. In the distal tibia, there is a risk of damage to the tendons of the tibialis anterior and extensor digitorum muscles and the most distal pin sites also have the highest infection rate. There is, however, a safe zone on the anteromedial aspect of the tibia, where Schanz screws can remain for a long period without infection.

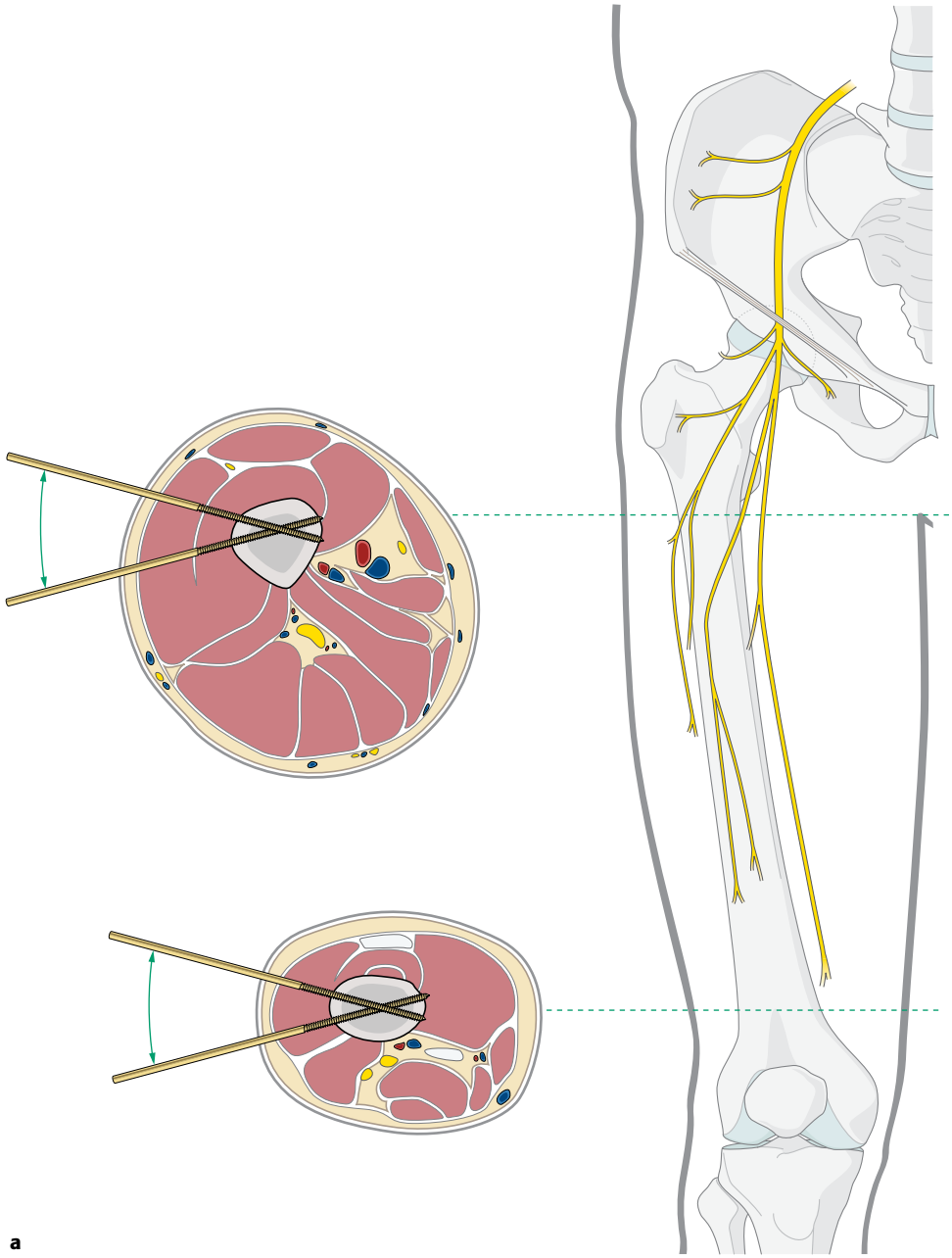

a

Fig 3.3.3-2a–c Safe zones for insertion of external fixation pins.
a Femur.

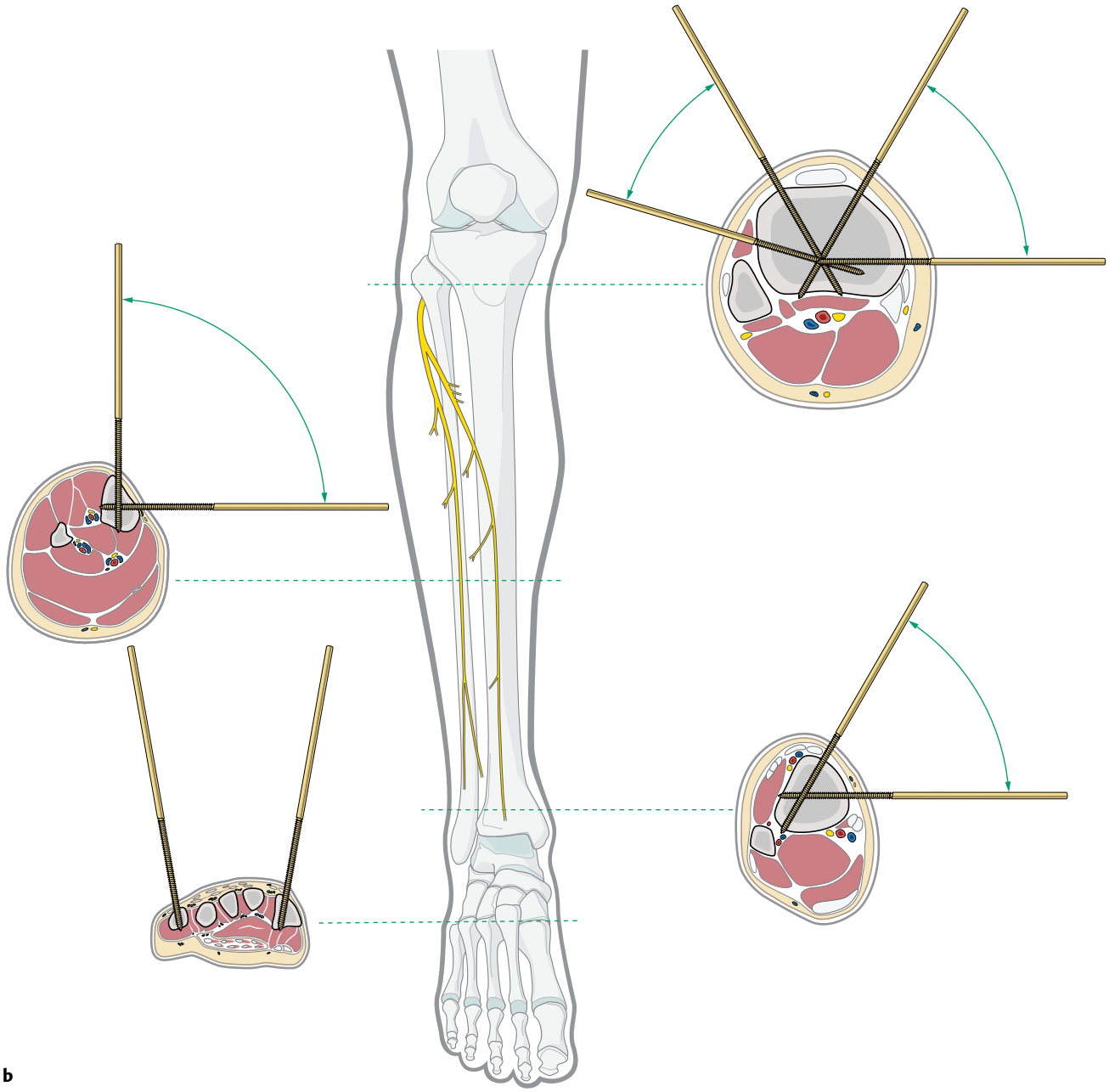

b

Fig 3.3.3-2a–c (**cont**) Safe zones for insertion of external fixation pins.
b Tibia.

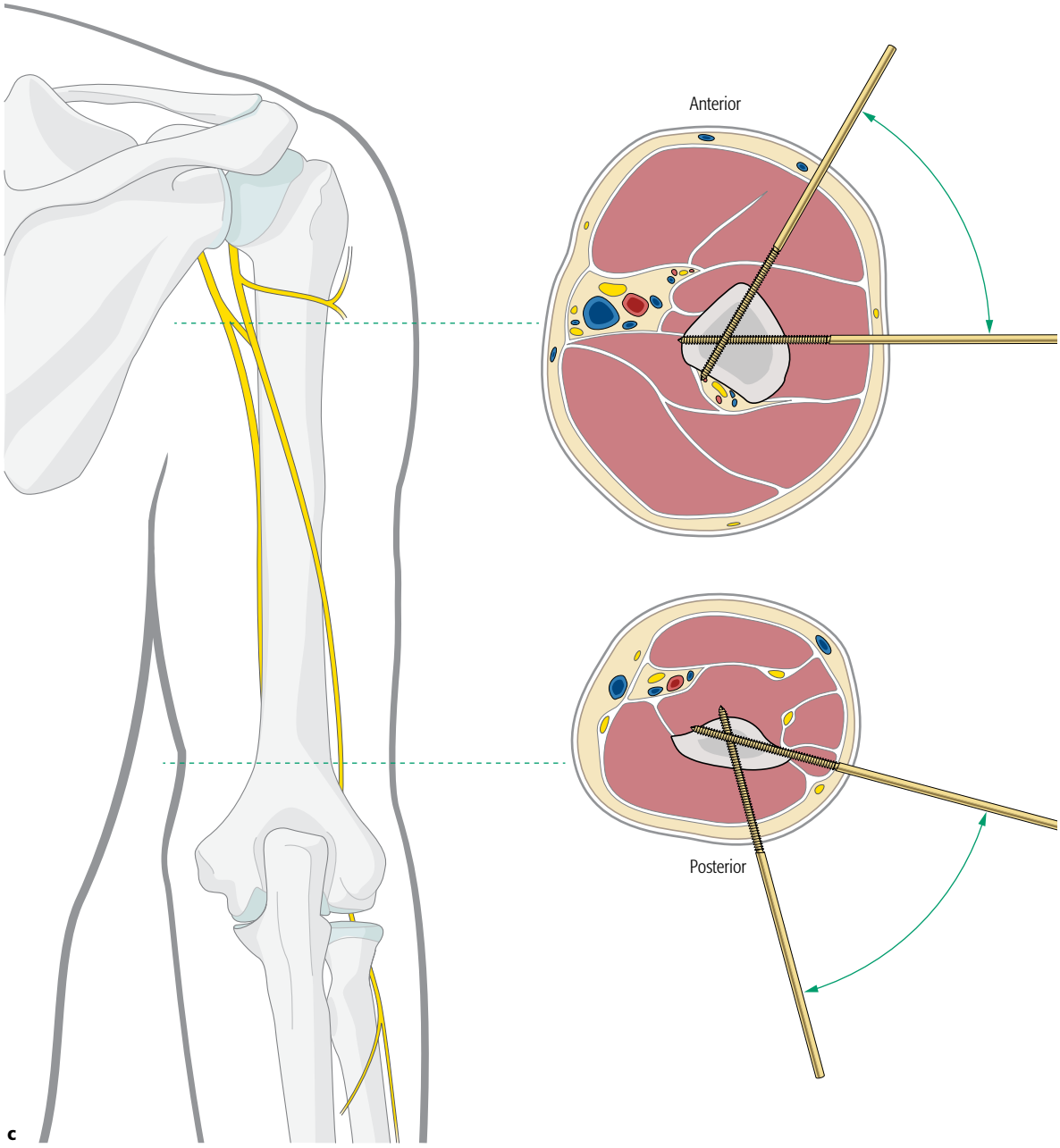

Fig 3.3.3-2a–c (**cont**) Safe zones for insertion of external fixation pins.
c Humerus, posterior view.

4 Elements

4.1 Tube-rod system

4.1.1 Schanz screws

Schanz screws are partially threaded pins. These are available in different diameters and lengths (shaft, threaded part) and with different tips. Standard Schanz screws have trocar-shaped tips (**Fig 3.3.3-3a**). They always require predrilling.

Self-drilling and self-tapping Schanz screws have a sharp and specially designed tip that drills and cuts the thread in one pass: they are designed for use in metaphyseal bone (**Fig 3.3.3-3b**), Schanz screws are available in steel, titanium, or with a hydroxyapatite coating. The hydroxyapatite allows bone growth right up to the pin (osseo-integration) and reduces the incidence of pin loosening. These pins are used in cases where the external fixator is likely to be in place for a prolonged period.

4.1.2 Steinmann pins

Steinmann pins are used as transosseous pins. They have a trocar tip and insertion always requires predrilling in cortical bone.

4.1.3 Rods/tubes

The frames consist of systems in four sizes, depending on the size of the rod (**Fig 3.3.3-4**):

- **Large:** 11 mm tubes/rods with Schanz screws from 4 to 6 mm
- **Medium:** 8 mm tubes/rods with Schanz screws from 3 to 6 mm
- **Small:** 4 mm tubes/rods with Schanz screws from 1.8 to 4 mm
- **Mini:** 2 mm system for fingers; it is presently available in the conventional design and includes multipin clamps for K-wires and 2 mm longitudinal rods

These systems are compatible with each other. The large 11 mm system contains both steel tubes and carbon fiber rods. The other systems include carbon fiber rods (medium) or steel and carbon fiber rods (small and mini). The modules of the system are supplemented by precontoured, curved carbon fiber rods. Additional T-shaped combinations are available for difficult regions, such as the wrist.

4.1.4 Clamps

Clamps provide the connection between the tubes or rods and the pins. Rods or tubes can also be connected to each other using the appropriate clamps (tube-to-tube). If a single clamp allows the connection of both tubes and rods, they are called combination clamps. Both single-pin and multi-pin clamps are available. The newest and most commonly used clamps are illustrated in **Fig 3.3.3-5**. These are available in three sizes with identical clamp design and application technique. The main feature of the new clamp is that it is open on one side and can be "snapped on". This means that once snapped onto a rod, it can be moved around axially and laterally without the need to be tightened. This greatly facilitates handling, especially for the modular reduction technique. The configurations described later in this chapter can also be constructed with other clamps that have similar functions or with older models.



Fig 3.3.3-3a–b Schanz screws.
a Standard trocar tip.
b Self-drilling tip.

Fig 3.3.3-4 Stainless steel tubes and carbon fiber rods for the large (11 mm) system.

4.2 Monolateral external fixation system

This is a system for traumatology and orthopedics (**Fig 3.3.3-6**), where the bone fragments are held by twin-pin clamps or special clamps. A central body for distraction and compression or a central-threaded component can be attached for lengthening and/or segmental transport procedures.

4.3 Hybrid external fixator

The hybrid external fixator is used in fractures close to a joint. It is called "hybrid" because it combines tensioned fine-wire fixation and an external ring at the joint with pin fixation in the diaphysis (**Fig 3.3.3-7**). It requires tensioned K-wires for the ring and conventional Schanz screws for the shaft. Generally, 3/4 circumference rings are used. Hybrid ring fixators have mainly been used in proximal and distal tibial fractures (**Video 3.3.3-2**).

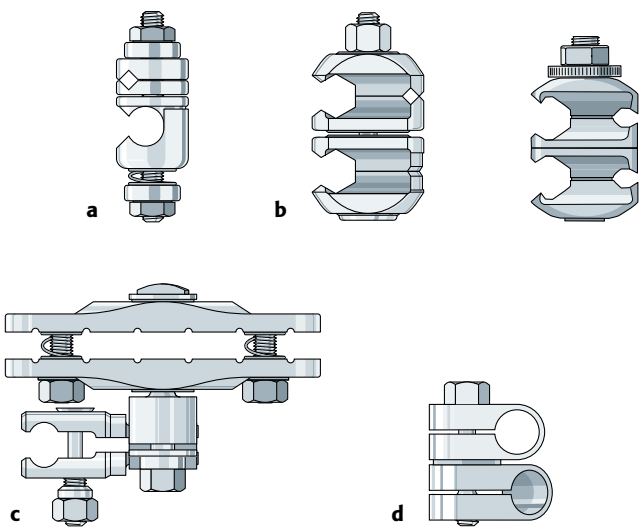

Fig 3.3.3-5a–d Clamps.
a Attachable, self-holding clamp used for combining a Schanz screw with a tube or rod.
b Attachable combination clamp used for combining two rods or tubes or Schanz screws.
c Universal multipin clamp.
d Closed tube-to-tube clamp used for combining two rods or tubes.

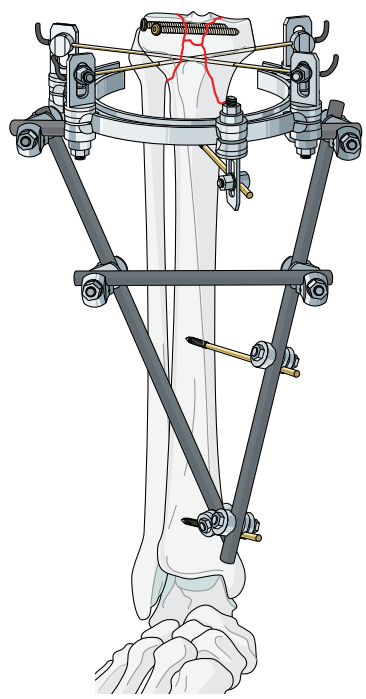

Fig 3.3.3-7 Hybrid fixator used on a tibial plateau fracture. It is also useful for distal tibial periarticular fractures. The V-frame provides good stability.

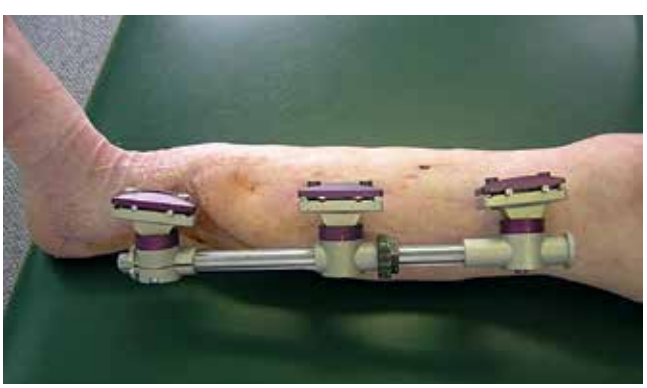

Fig 3.3.3-6 Monolateral external fixation system for segment transport on the tibia.

Video 3.3.3-2 Application of the hybrid fixator. Tensioning of a fine wire.

4.4 Circular ring fixator

Full ring systems offer the advantage that the axis of loading and the axis of correction simultaneously pass through the center of the ring system and on the longitudinal axis of the bone [9]. Lengthening, segment transport, simple, and especially complex fracture treatment is possible with circular ring systems (**Figs 3.3.3-8–9**) and this technique allows for early weight-bearing. For the treatment of acute fractures we prefer simpler unilateral methods. Segment transport and lengthening procedures are possible with unilateral systems but complex continuous correction in several planes is difficult to achieve, so a circular ring fixator is recommended.

As the ring fixator is an external fixator, it provides relative stability. When pins are inserted across different planes in multiplanar fixation, the construct provides great stability. The stiffness of the construction can vary depending on the configuration of the fixation, the number of rings used, and usage of different types of pins, such as K-wires or Schanz screws. Depending on the assembly, the fracture can be distracted or compressed, and deformities can be corrected. A common use for the ring fixator is distraction osteogenesis to correct bone loss, shortening, and deformity.

An enhancement for patient care is the connection of rings with a hexapod system. A computer program calculates movement of the six oblique bars to allow reduction of any malalignment. The indications for ring and hexapod systems are specialized. For more information on ring and hexapod systems, specialized textbooks and teaching material are available.

4.5 Hinged external fixator

Hinged external fixators maintain reduction of joint dislocations or fracture dislocation and allow some (controlled) motion at the joint to help prevent joint stiffness. They are most commonly used in the elbow (see section 6.5 in this chapter).

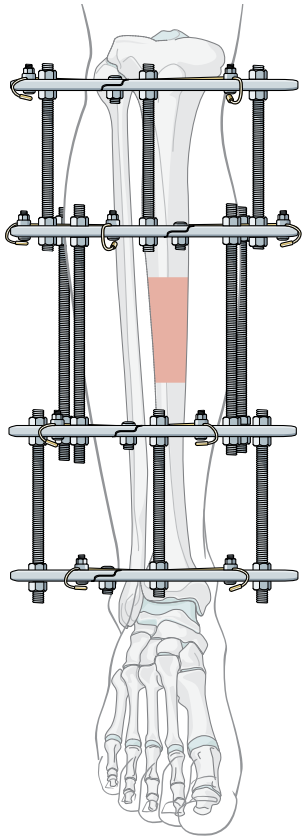

Fig 3.3.3-8 A circular frame on the tibia

Fig 3.3.3-9 Clinical photo of a ring system on the tibia.

5 Frame construction

5.1 Terminology of frame construction

There are different ways to classify a frame construction, depending upon:

- Function
- Design
- Plane in which it is applied
- Indication

5.1.1 Unilateral frame

A unilateral frame is the most common way to stabilize fresh diaphyseal fractures with an external fixator.

The frame is applied in one plane, ie, either anteromedial or medial for the tibia and anterolateral or lateral for the femur (**Fig 3.3.3-1c**). The pins are placed through the skin on one side and penetrate both the near and far cortex. Pins must be inserted away from the joints and be outside the joint capsule reflections to avoid the risk of joint sepsis. Two bars are mounted, either both in one plane or in two different planes, and joined together.

5.1.2 Bilateral frame or A frame

A Steinmann pin is inserted through the skin on one side, penetrates both cortices, and emerges through the skin on the opposite side. It is not recommended for the definitive treatment of fractures but can be a useful temporary fixation.

5.1.3 Spanning external fixation frame (joint bridging)

Spanning external fixation is indicated for damage-control surgery when the patient (polytrauma), or the limb, or the fracture cannot be definitively managed immediately.

It is used to span areas of severe soft-tissue injury or complex articular fractures and fracture dislocations (**Fig 3.3.3-10**). The stability allows time for soft tissues to settle, while computed tomographic (CT) scans and preoperative planning are performed. Unilateral frames are mostly used and the pins should be placed where possible outside the zone of injury and outside the zone of (future) definitive surgery.

5.1.4 Lengthening frame

The external fixator can be modified to allow for distraction osteogenesis. Ilizarov introduced this technique with the ring fixator. The same principle of slow distraction can be applied with the tubular external fixator and monolateral systems with the limitation that angular and rotational corrections cannot be performed simultaneously unless lengthening is performed over an intramedullary nail.

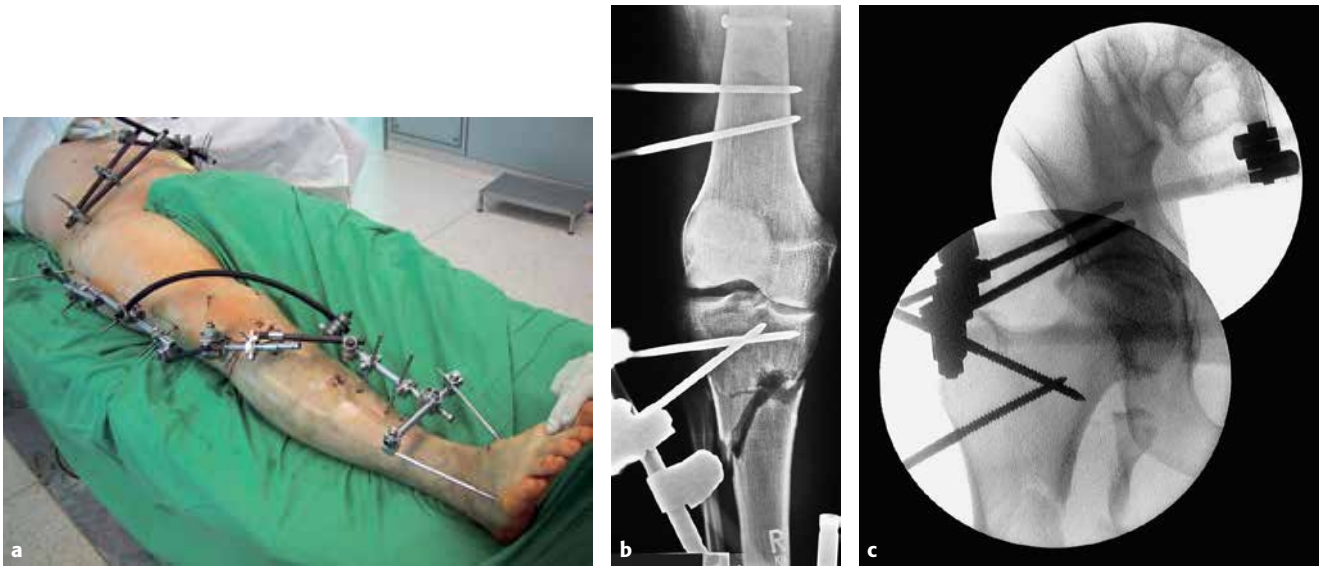

Fig 3.3.3-10a–c Fractures of the pelvic ring, proximal femur, and proximal tibia, all fixed with temporary external fixators, bridging the knee and ankle joints.

5.2 Modular reduction technique

The modularity of the external fixator makes it versatile and allows it to be used both as an indirect reduction tool and fixation device.

5.2.1 The principle

Schanz screws are inserted into each main fragment with the pin close to the fracture placed in slightly different plane or, in the case of joint-bridging configurations, into each of the two bones supporting the bridge (in some cases possibly more than two) (**Fig 3.3.3-11**) [10].

If single pin clamps are used, there is a great advantage that the position and orientation of the Schanz screws are unrestricted.

The Schanz screws within one fragment are then firmly connected to a tube or rod. This produces a partial frame for each main fragment/affected bone. The two partial frames are then connected by means of tube-to-tube clamps. As long as the tube-to-tube connections are open, reduction can be performed in all planes. The desired reduction, once achieved, can be checked clinically and/or radiologically, the tube-to-tube clamps can be tightened and the system is stable (**Videos 3.3.3-3–4** and **Fig/Animation 3.3.3-12a–c**)

5.2.2 Modifications

The two Schanz screws in any one main fragment can be held in place by double pin or multipin clamps. These double or multipin clamps can be applied on one side or on both sides of the fracture. The partial frame can also be formed by a ring or a partial ring system (hybrid fixator).

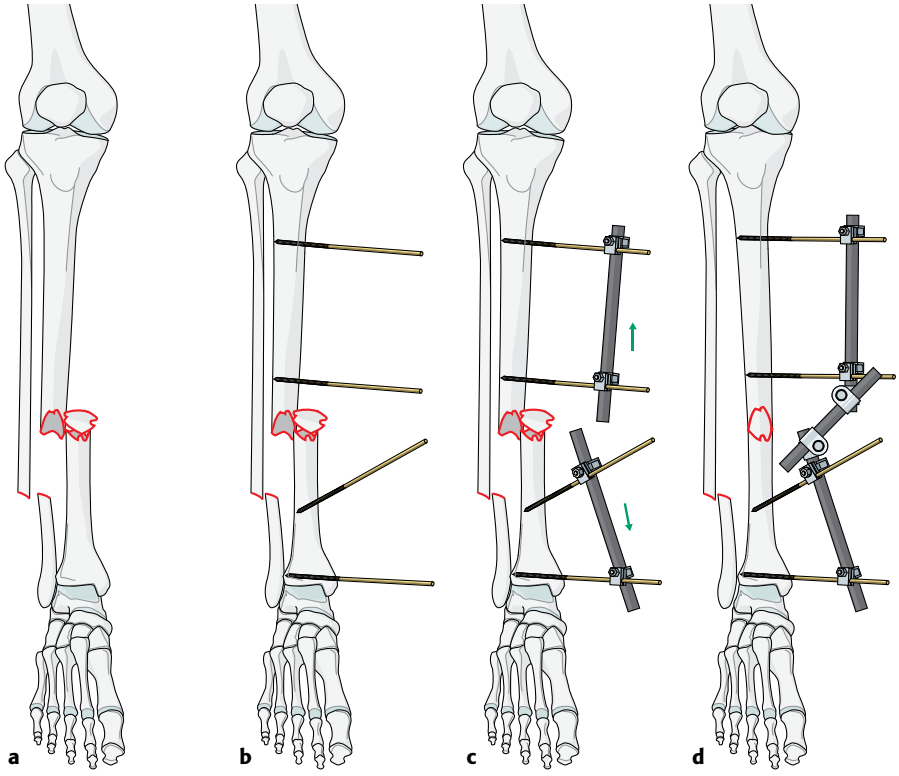

Fig 3.3.3-11a–d The modular reduction technique.
a Type B diaphyseal tibial fracture.
b Two pins are inserted in each main fragment outside the zone of injury.
c Fixed to a bar by universal clamps, two handles are created that help reduction.
d After reduction the tube-to-tube clamps of the third tube are tightened.

5.2.3 Advantages

The advantage of modular external fixation is that all long bones, areas adjacent to joints, and the joints themselves (joint bridging) can be reduced, bridged, and stabilized.

The Schanz screws can be positioned freely, which allows the most favorable, anatomical insertion site for the Schanz screws and the most favorable zone for the fracture pattern or soft-tissue injury. Manipulation of the main fragments is facilitated by leverage and indirect reduction techniques which preserve bone and soft-tissue vascularity. Primary and secondary adjustments to the reduction can be performed at any time with this technique.

6 Special applications

6.1 Arthrodesis

One of the special applications of external fixation has always been the fusion of a joint by applying compression through a bilateral frame. This principle is occasionally used for ankle, knee, and elbow fusion, especially in the presence of infection [11]. The threaded rod system or the removable compression device for the tubular system allows for repeated application of axial compression, which increases stability in the less dense bone of the metaphysis.

6.2 Infection

External fixation may be the ultimate way of stabilizing an acutely infected fracture or infected nonunion because the fixation pins can usually be inserted distant from the focus of infection.

External fixation may be the only method that can provide stability, which is essential for successful treatment in this situation. After debridement and removal of all dead bone and necrotic tissue, the techniques for application of the external fixator are essentially the same as for fresh fractures.

6.3 Corrective osteotomies

External fixation of osteotomies for deformity correction is generally used in cases of poor or compromised soft-tissue cover, ie, when internal fixation is associated with high risk (see chapter 5.2). The other indication is for osteotomies combined with bone transport.

Video 3.3.3-3 Modular external fixation of the tibia.

Video 3.3.3-4 Modular external fixator on a tibia with soft-tissue damage around the knee joint. Final treatment of a tibial fracture shown preoperatively, operative technique and after treatment with external fixator and healing with external fixator treatment.

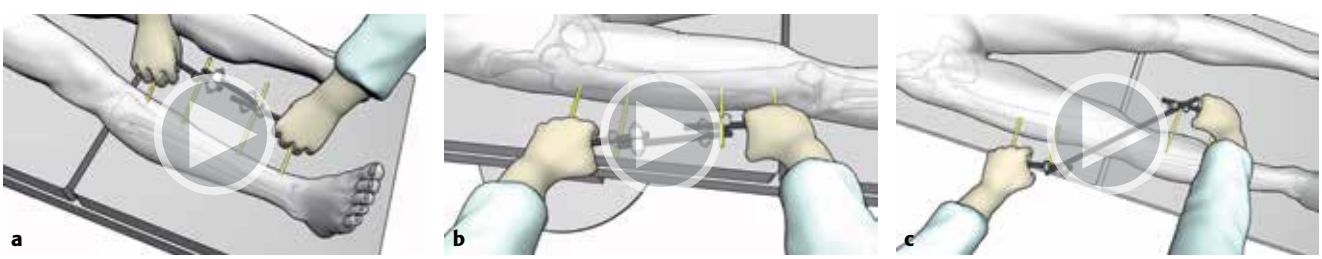

Fig/Animation 3.3.3-12a–c Modular external fixator shown with:
a Tibia.
b Femur.
c Knee bridging.

The combination of poor soft tissues and a complex deformity will usually need correction using a circular frame system.

6.4 Bone transport—distraction osteogenesis

Callus distraction is based on the principle described by Ilizarov [9]. By preserving the periosteum, carefully osteotomized bone can slowly be distracted (0.5–1 mm/day) and new bone will form in the gap. Slower rates of distraction result in bone healing while faster rates exceed the strain tolerance of the tissue and bone does not form. Transport or distraction callus, like fracture callus, passes through all phases of maturation until complete bone union is achieved. This principle can be used for three indications, which may occur in combination:

- Lengthening
- Segment transport into a defect
- Correction osteotomy

The fixators best suited to these applications are the ring fixators with or without combinations of partial rings as well as unilateral fixators.

6.5 Joint reduction and maintaining motion

Hinged external fixation is an important supplement to ORIF and ligament repair for selected complex unstable elbow injuries, including the chronic or unreduced elbow dislocation. When surgical repair does not provide adequate stability, redislocation or subluxation may occur with or without a cast or splint. External fixation with a hinged device will keep the elbow reduced while allowing controlled motion. Maintenance of reduction is the first priority. Instability is harder to salvage than loss of motion. Axis wire location should be determined precisely, using the image intensifier. Slight misplacement of the hinge significantly affects hinge behavior (**Fig 3.3.3-13**).

7 Postoperative management

7.1 Pin-track care

The reaction at the pin insertion site depends upon the position and stability of the pin [12] and aftercare by the nursing team and patient.

The modular reduction technique is favorable from this point of view because it permits the best anatomical site to be selected in relation to the fracture pattern [10]. If there is a "steady state" at the pin-insertion site, without signs of infection, the external fixator can be left in place for a long time.

It is important that hospitals have clear protocols for the management of pin sites with experienced nurses teaching patients to take care of the pin sites on their own.

Infection and loosening of pins can be significantly reduced by avoiding thermal damage and local hematoma formation during insertion and if after-care includes the use of alcoholic antiseptic to clean the pin sites together with occlusive pressure dressings [13]

7.2 Pin-track infection

Pin-track care starts with correct pin insertion. Predrilling is always recommended for the conventional Schanz screw and the pin should always be inserted by hand to reduce thermal necrosis. Undue soft-tissue tension around the pins

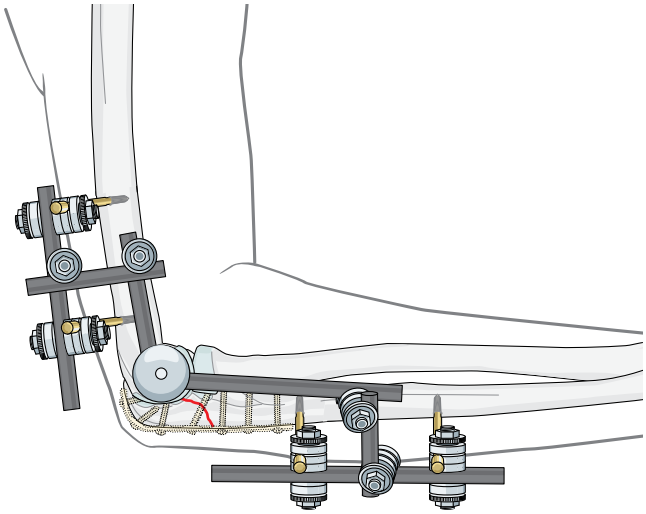

Fig 3.3.3-13 Placement of hinged elbow external fixator.

must be released during surgery. Correct care of the pin-track sites is important to reduce the risk of pin-track complications. In cases of persistent pin-track infection, the pin has usually lost its firm hold in the bone. A seam of bone resorption can be seen on the x-rays and mechanically the pin appears to be loose. This problem can be solved by removing the loose pin and placing a new one at another site.

7.3 Dynamization

With a few exceptions (bridging, emergencies, tensioning), external fixator constructs can be partially loaded from the beginning. As healing progresses, the load is increased until full weight bearing is achieved. Observations over many years have shown that it is not necessary to build additional dynamization elements into the fixator system. Partial and full weight bearing under external fixation is the best and most effective method of dynamization.

8 For how long should the external fixator be used?

8.1 Change of procedure

There are three basic treatment choices:

- Definitive treatment with the external fixator until solid bone healing
- Early conversion to internal fixation
- Conversion to nonoperative treatment, eg, plaster, orthosis, caliper

If a change to internal fixation is predicated, this must be done early—within 2 weeks—as this results in a remarkably lower complication rate than a change at a later stage.

Any surgery that is planned around or after temporary external fixation must follow a few rules:

1. All pin sites must be clean if new internal fixation is placed around old sites of external fixation. Sometimes this requires 2-stage surgical procedures to first clean the old pin sites followed by the definitive fixation procedure.
2. Any pin sites more than 10–14 days are assumed to be colonized and should go through a sterile cleaning and debridement procedure before definitive fixation is placed near these sites.
3. If there is any doubt about the sterility of these pin sites, or if they have been frankly infected, then a “pin holiday” of at least 10 days is used after a sterile debridement procedure before placing new internal fixation.
4. Prophylactic antibiotics must be administered and cover the bacteria responsible for any previous pin-site infections.
5. Close postoperative follow-up is performed during the first 6 weeks.

If there is evidence of pin-track problems, it may be best to identify the organism, administer antibiotics, make a change of pin and pin site, and continue treatment using an external fixator. Pin-site care should be reviewed with the patient to ensure that it is optimal. If late removal of the fixator and change to internal fixation is necessary, a “pin holiday” is recommended. This means that the external fixator is removed, the pin sites cleaned and debrided and the limb is then immobilized in a splint; surgery is delayed until the pin sites have settled. Appropriate antibiotics are administered.

8.2 Definitive fixation

The initial emergency application of an external fixator establishes temporary stabilization of a limb, allowing the soft tissues to recover. As soon as the soft tissues appear stable, the external fixator can be replaced by a definitive internal fixation. Ideally, this should take place within 10 days. A conversion procedure is not mandatory if the frame is still stable and there are no signs of complications

In cases of poor skin coverage or critical soft-tissue concerns, open reduction will be associated with a high risk of infection. Therefore, the external fixator may be retained as the definitive fracture treatment.

The progress of fracture healing must be monitored carefully and if there is no progress an alternative approach should be considered.

Classic references | Review references

9 References

1. **Perren S.** Basic aspects of internal fixation. In: Müller ME, Allgöwer M, Schneider R, eds. *Manual of Internal Fixation*. Berlin Heidelberg New York: Springer-Verlag; 1990:1–112.
2. **Pape HC, Krettek C.** [Damage control orthopedic surgery]. *Unfallchirurg.* 2003 Feb; 106(2):85–86. German.
3. **Giannoudis PV.** Surgical priorities in damage control in polytrauma. *J Bone Joint Surg Br.* 2003 May; 85(4):478–483.
4. **Jakob RP, Fernandez DL.** The treatment of wrist fractures with the small AO external fixation device. In: Uhthoff HK, ed. *Current Concepts of External Fixation of Fractures.* Berlin Heidelberg New York: Springer-Verlag; 1982; 307–314.
5. **Fernandez DL.** Treatment of articular fractures of the distal radius with external fixation and pinning. In: Saffar P, Cooney WP, eds. *Fractures of the Distal Radius.* London: Martin Dunitz Ltd; 104–117.
6. **Schütz M, Müller M, Regazzoni P, et al.** Use of the less invasive stabilization system (LISS) in patients with distal femoral (AO 33) fractures: a prospective multicenter study. *Arch Orthop Trauma Surg.* 2005 Mar; 125(2):102–108.
7. **Lazo-Zbikowski J, Aguilar F, Mozo F, et al.** Biocompression external fixation. Sliding external osteosynthesis. *Clin Orthop Relat Res.* 1986 May; (206):169–184.
8. **Faure C, Merloz PH.** *Zugänge für die Fixatuer-externe-Osteosynthese. Atlas anatomischer Querschnitte.* Berlin Heidelberg New York: Springer-Verlag; 1987. German.
9. **Ilizarov GA.** [Basic principles of transosseous compression and distraction osteosynthesis]. *Ortop Travmatol Protez.* 1971 Nov;32(11):7–15. Russian.
10. **Fernandez Dell'Oca AA.** External fixation using simple pin fixators. *Injury.* 1992;23 Suppl 4:S1–54.
11. **Mears D.** Clinical techniques in the lower extremity. In: Mears D, ed. *External Skeletal Fixation.* Baltimore London: Williams & Wilkins; 1983; 210–338.
12. **Green S.** Complications of external fixation. In: Uhthoff HK ed. *Current Concepts of External Fixation of Fractures.* Berlin Heidelberg New York: Springer-Verlag; 1982.
13. **Davies R, Holt N, Nayagam S.** The care of pin sites with external fixation. *J Bone Joint Surg Br.* 2005 May; 87(5):716–719.

10 Acknowledgment

We thank Suthorn Bavonratanavech and Alberto Fernandez for their contributions to this chapter.

3.3.4 Locking plates

Christoph Sommer

1 Introduction

The introduction of locking plates was driven by the aim of maximizing blood supply to the fracture. When using conventional plates and screws, the stability of the bone-implant construct is dependent upon friction between the plate and the bone. This can only be achieved by pressing a plate down onto the bone surface by tightening conventional screws.

Considerable structural changes occur in the cortex directly underneath a plate. These changes were first attributed to "stress protection" by a metallic implant that was much more rigid than bone. Further research [1, 2] gave rise to the theory that disturbed blood flow within the cortical bone was responsible for the remodeling process observed underneath every plate that was pressed against bone by screws.

The under surface of the limited-contact dynamic compression plate (LC-DCP) was designed to reduce the area of contact between the plate and bone and significantly reduced the vascular changes caused by pressure on the cortex. However, the LC-DCP is also pressed against the bone to create friction (**Fig/Animation 3.3.4-1a**). To eliminate the ill effects of any plate to bone contact, a completely different approach was chosen. Screws that rigidly lock into the plate hole when tightened mean that the plate is no longer pressed against the underlying bone (**Fig/Animation 3.3.4-1b**) [3]. Similar in principle to the external fixator, this different technique of applying a plate was termed the internal fixator principle, as the implant functions more like a fixator than a plate with soft tissues and skin covering the whole construct. Since these devices are designed to avoid the devascularization associated with conventional plating, theoretically, they should offer higher resistance to infection. However, this hypothesis has not been proven.

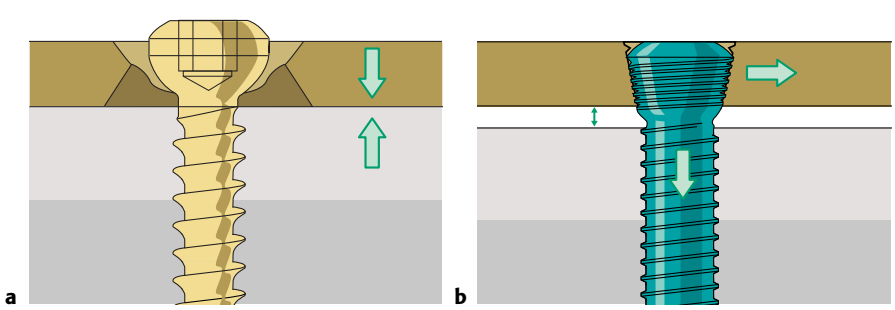

Fig/Animation 3.3.4-1a–b The plate-bone interface.
a Conventional plates gain stability by friction as the screw presses the plate against the cortex. The periosteum is crushed, resulting in avascular areas.
b Locking head screws mechanically couple to the plate, which is not pressed against the bone. The periosteum and blood supply are therefore maintained.

The history of the development of locking plate technology is illustrated in **Fig 3.3.4-2**.

The concept of locking plates is not new and the first known patent was in 1931 by the French surgeon, Paul Reinhold. The first modern implant designed to fulfil the new requirements was the small PC-Fix (point contact fixator) for forearm bones. The PC-Fix was a narrow plate-like implant with a specially designed under surface having only small points that come into contact with bone. The screws were self-tapping, unicortical and were available in one length only. The conical screw head locked firmly in the corresponding conical plate hole when tightened. The result of further developments was the less invasive stabilization system (LISS) [4]. This implant, in contrast to the PC-Fix, was conceived for fractures in the metaphyseal areas—initially for the distal femur and later for the proximal tibia. Its shape conforms to the anatomical contours of the specific area of the bone and so separate implants are required for the right and left sides. Additional contouring is not required, as the "plate" fixator does not necessarily need to touch the bone. The locking head screws (LHS) have a conical head with a fine thread, fitting perfectly in the corresponding threaded conical plate hole. The stability achieved using LHS relied on a stable couple between screw head and plate hole, and was not dependent on the friction between the plate and the bone (**Fig/Animation 3.3.4-1**). Initially the system consisted of unicortical, self-drilling/self-tapping screws, which are inserted percutaneously using an aiming arm. However, failure rates were high in clinical application and bicortical, self-tapping screws are now recommended. This implant was designed and instrumented for application via a minimally invasive, submuscular approach.

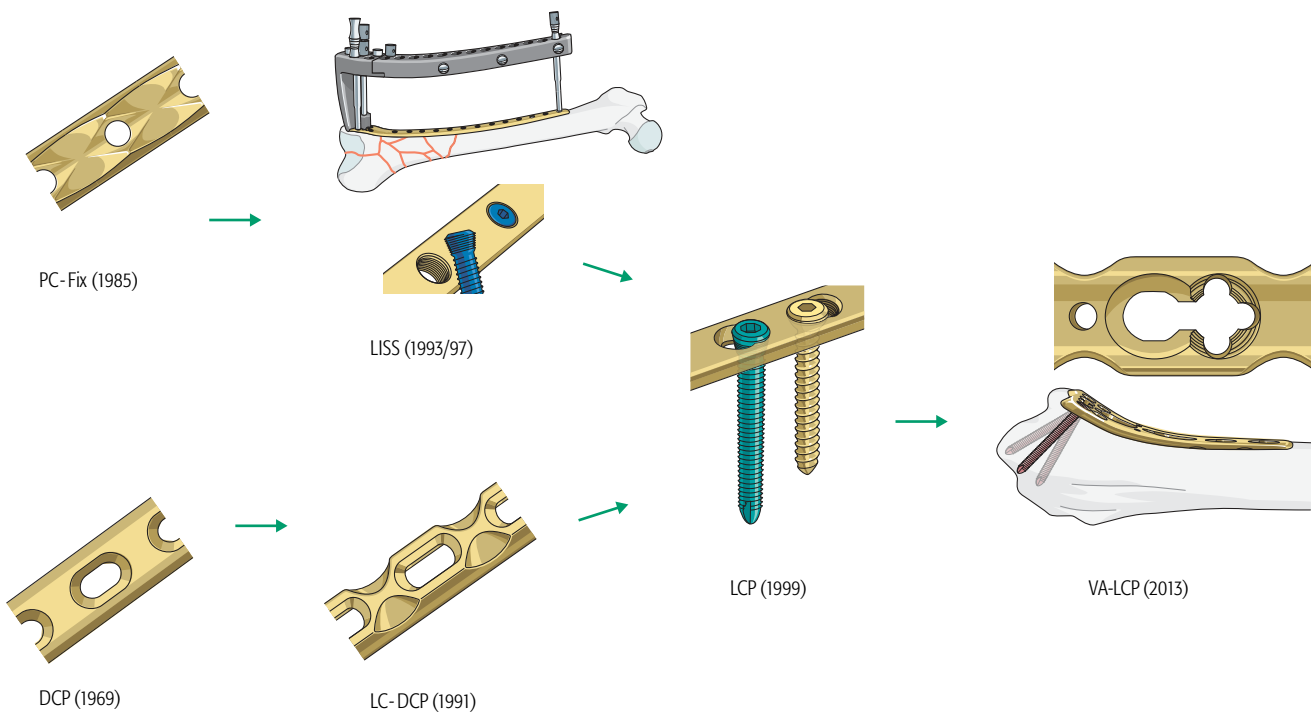

Fig 3.3.4-2 The evolution of plate systems.
Conventional plate development in the 1960s to 1980s was followed by locking plate development in the 1990s until they were integrated to produce the locking compression plate (LCP). The latest step was the introduction of variable angle (VA) technology.

The locking compression plate (LCP) was developed in 1999. This implant is a combination of the LC-DCP and LISS [5, 6]. The holes of both plates have been "fused" into a combination hole (combi-hole), allowing insertion of either conventional or locking screws (**Fig 3.3.4-3**). Within a few years, this LCP technology was implemented in existing plates from the large to the mini-fragment sets, replacing the old dynamic compression unit holes with the new LCP combination holes. Globally, surgeons became familiar with this new technology and its advantages as well as disadvantages [7].

The most recent development is variable angle (VA) technology (**Fig 3.3.4-4**). The spherical head together with the specially slotted plate hole allows angulation of the screw direction (maximal 15°) in relation to the normal 90° (perpendicular) angle to the plate surface. The holding strength of the VA screw in the plate hole is about 70% of the non-VA LHS, but still strong enough to achieve stability when guidelines for application are followed.

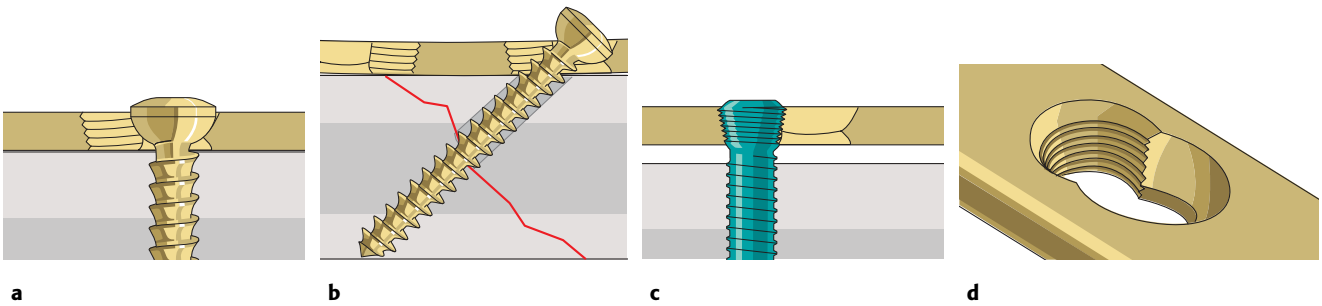

Fig 3.3.4-3a–d Locking compression plate combination hole combining two proven elements:
a–b Half of the hole has the design of the standard DCP/LC-DCP (dynamic compression unit: DCU) for conventional screws (including lag screws).
c–d The other half is conical and threaded to accept the matching thread of the locking head screw to provide angular stability.

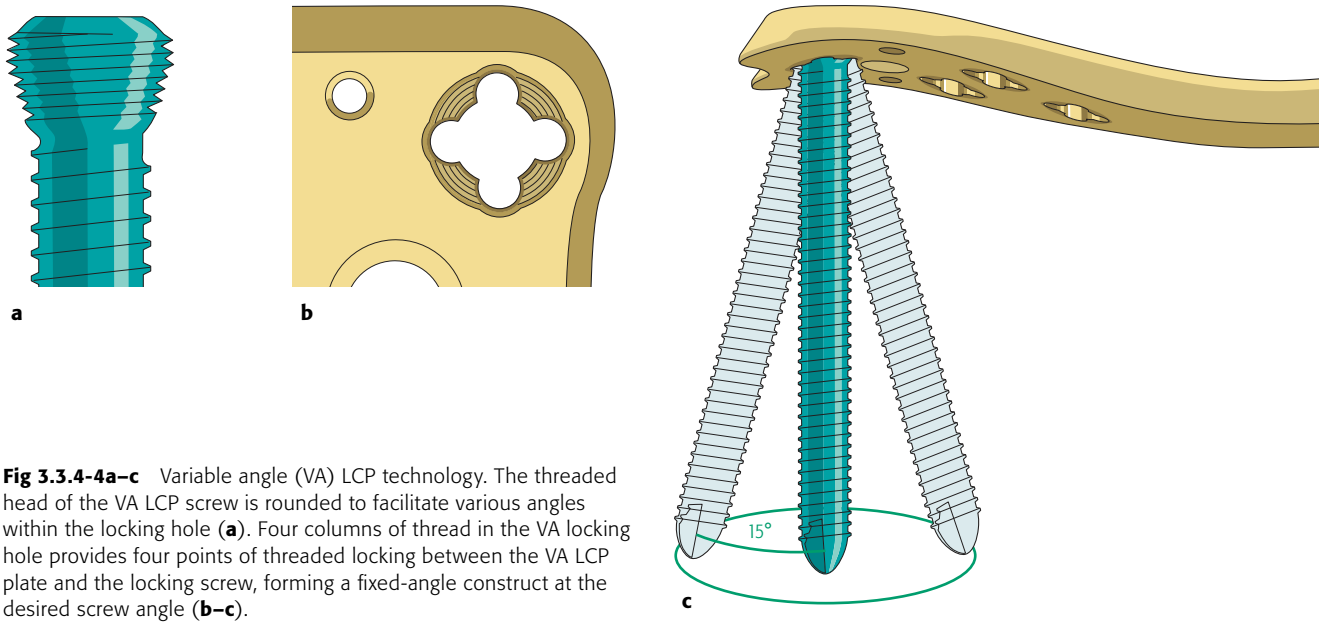

Fig 3.3.4-4a–c Variable angle (VA) LCP technology. The threaded head of the VA LCP screw is rounded to facilitate various angles within the locking hole (**a**). Four columns of thread in the VA locking hole provides four points of threaded locking between the VA LCP plate and the locking screw, forming a fixed-angle construct at the desired screw angle (**b–c**).

2 Indications

2.1 General considerations

The essential difference between a conventional plate and a locking plate is not in the plate itself but in the fact that the screws are locked into the plate, therefore the plate and screws together act as one unit.

This means that the construct is less dependent upon the interface between the screw threads and the bone. Thus, there are two key situations where a locking plate should provide a considerable advantage over a conventional plate: poor bone quality, such as found with osteoporosis; and situations where the morphology of the fracture reduces the amount of bone available for fixation (**Table 3.3.4-1**). The classic example is multifragmentary metaphyseal fractures close to the joint surface.

2.2 Poor bone stock

The most important indication for using locking screws is poor bone stock.

Fractures in osteoporotic (or pathological) bone: In poor bone, a conventional screw can easily be overtightened during insertion, damaging the thread hole so the screw gets poor purchase. This may result in early, or even primary, fracture instability (**Fig 3.3.4-5**). The thinner cortical bone in older adults also offers low resistance to pull out and toggle even if initial fixation is obtained. Conventional plating has a higher failure rate in osteoporotic bone, classically seen with sequential screw loosening and migration (**Figs 3.3.4-6–7**, **Videos 3.3.4-1–2**). In contrast, a locking screw can never be overtightened in the bone because of the automatic stop by the locking process at the end of the screw insertion. Locking plates by definition cannot fail on the individual screw–bone interface level (**Fig 3.3.4-8**, **Videos 3.3.4-3–4**); all screws have to pull out together with the plate (**Fig 3.3.4-9**).

Indications	Disadvantages of conventional screws (plates)	Advantages of locking screws	Positive effect using locking screws
Osteoporotic bone (or pathological bone, eg, in revision surgery)	Easy overtightening during insertion which destroys the thread in the bone.	Overtightening (in the bone) is not possible due to locking mechanism, even when overtightened in the plate hole, which is avoided by using the TLA and correct technique.	Reduced risk of primary loss of reduction.
	Easy screw loosening under load (axial, bending, or torsional) before fracture has healed.	Screw loosening in plate hole unlikely if properly placed (correct 90°angle, TLA).	Reduced risk of secondary loss of reduction.
Metaphyseal fracture	Can angulate easily in the plate holes even in good bone quality.	LHS cannot angulate in plate hole. Screws act like multiple small "blades" of an angled blade plate.	Reduced risk of secondary loss of reduction (angulation).
	Short end segment of bone with a short plate creates a short lever arm. Conventional screws cannot withstand high pull-out or bending forces. High risk of sequential screw loosening and migration.	Locking plates by definition cannot fail on the individual screw–bone interface level. All screws have to pull-out together and with the plate.	Reduced risk of secondary loss of reduction with instability.
	Conventional screws do not perfectly fit anatomically preshaped periarticular plates and sufficient plate-bone contact is not achieved.	Stability of fixation does not rely on a perfect fit of the plate to the bone and therefore, using locking screws in preshaped plates, the stability is sufficient.	Perfect primary stability, reduced risk of secondary loss of stability.
Minimally invasive plate osteosynthesis	Bone is pulled to the plate creating malalignment (angulation or torsion) if the plate is not precisely contoured to the bone surface (not possible because surface is not visualized).	Well-reduced fracture stays reduced when using locked screws (distance between plate and bone does not change).	Reduced risk of primary loss of reduction.
Periprosthetic fracture	Monocortical application not sufficient.	Monocortical screws can be added.	Reduced risk of secondary loss of reduction.
	Conventional plates cannot be combined with locking attachment plate or wire-holding buttons.	Combination with locking attachment plate or wire holding buttons possible.	

Table 3.3.4-1 Indications for the use of locking screws and the clinical rational.
Abbreviations: LHS, locking head screw; TLA, torque-limiting attachment.

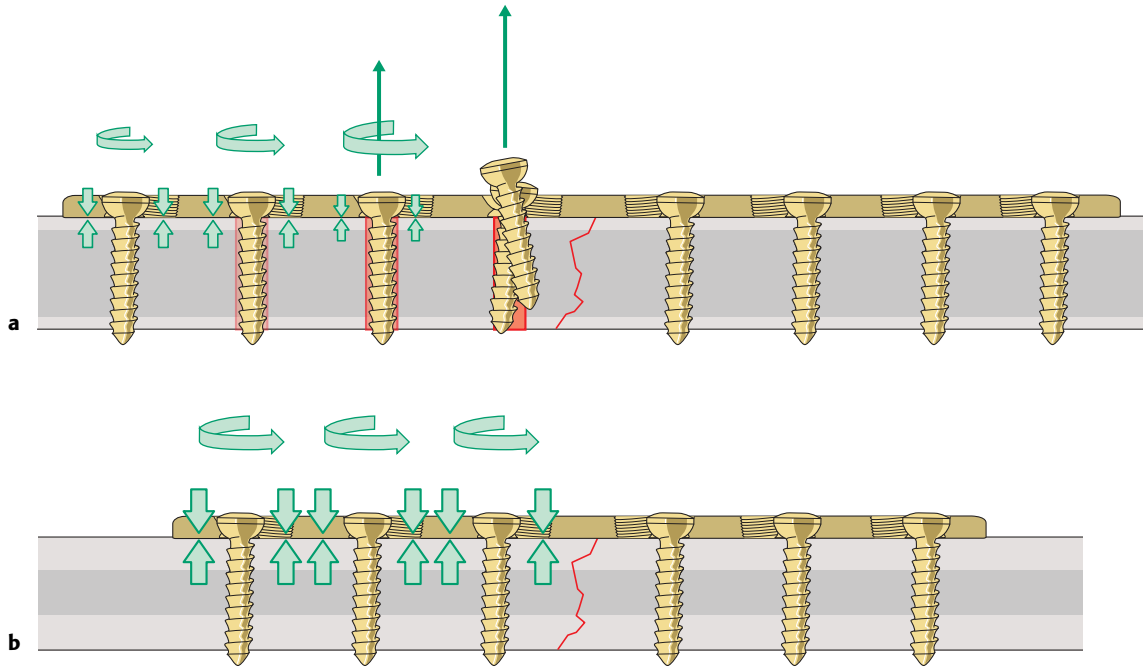

Fig 3.3.4-5a–b Conventional screw (over-) tightening in osteoporotic and normal bone.

a In osteoporotic bone with thin cortex in the diaphysis, the afforded torque on the screw during insertion (to achieve sufficient friction between plate and bone) often exceeds stability of the screw-bone interface resulting in a primary destruction of the thread in the bone. The screw has no hold at all and wiggles out of the screw hole early.

b In good bone, the conventional screws can be tightened fully creating the necessary friction between plate and bone for a stable fixation.

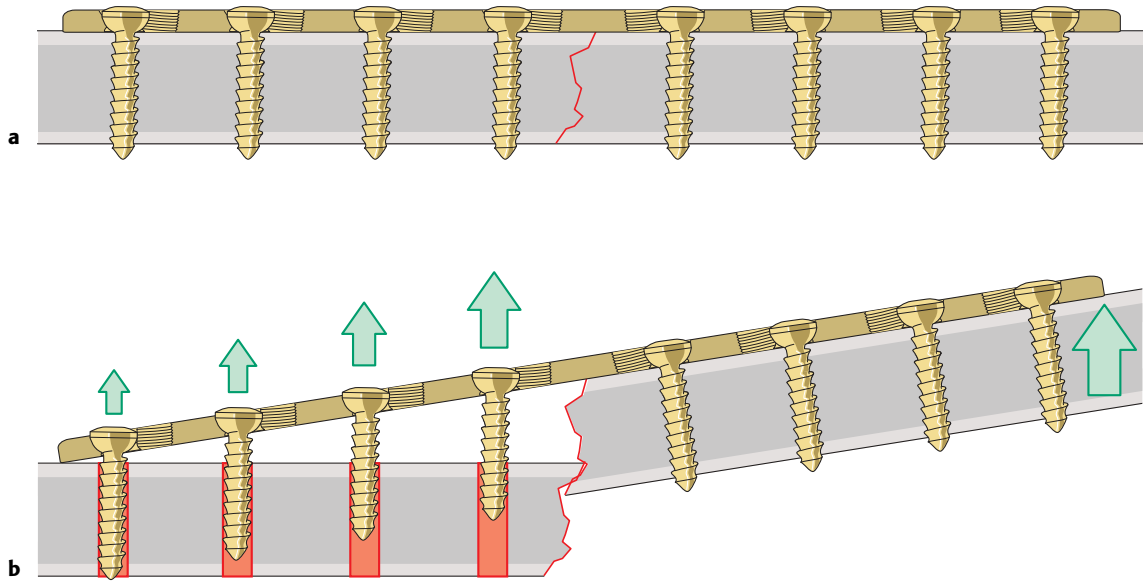

Fig 3.3.4-6a–b Sequential conventional screw loosening in osteoporotic bone. Even with correct tightening conventional screws can loosen in osteoporotic bone under cyclic loading. Bending moments on the plate are transferred to axial pull-out forces on the screws. This is maximum at the screws close to the fracture, leading to early loss of reduction.

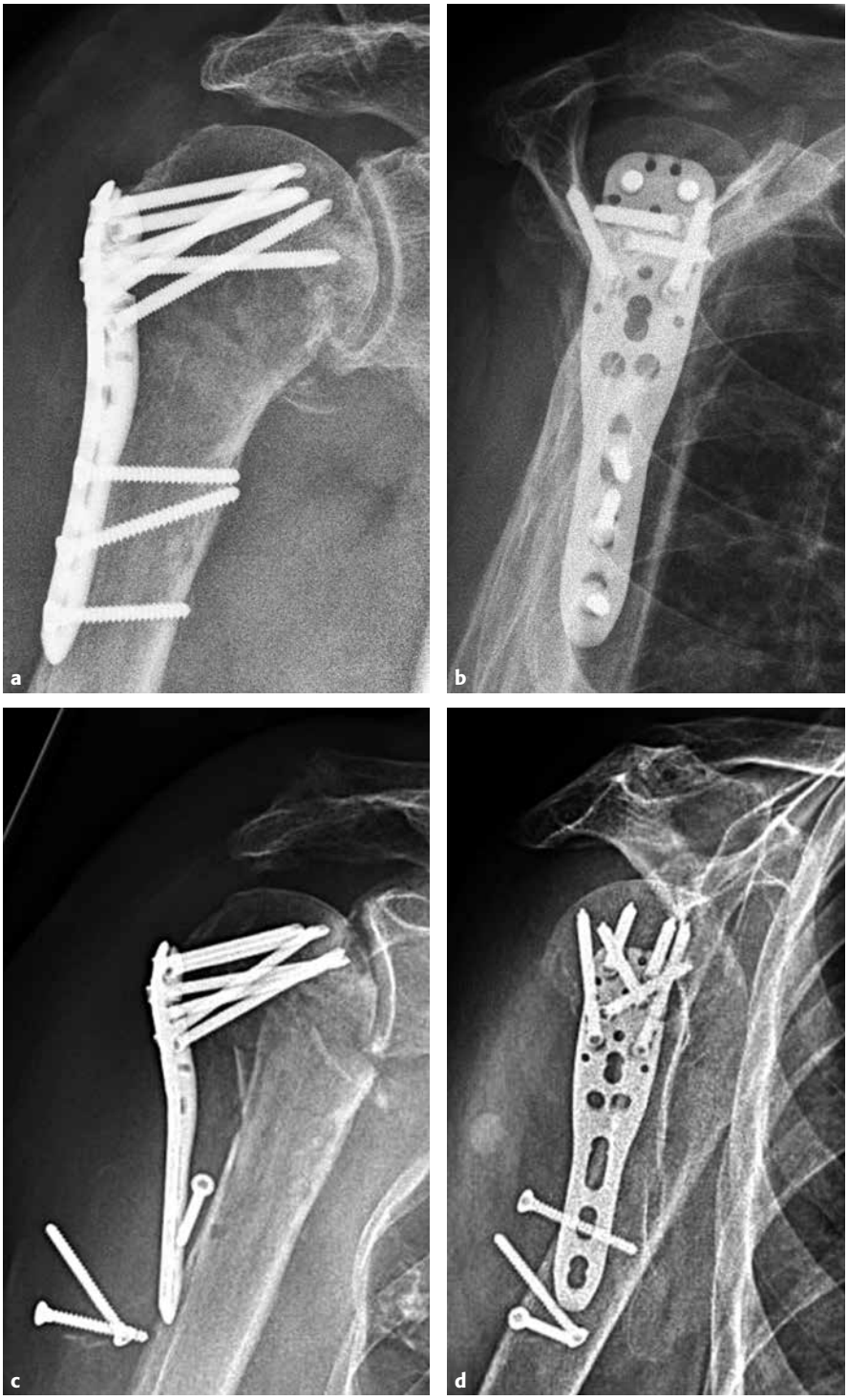

Fig 3.3.4-7a–d Early loosening of conventional screws in an osteoporotic humeral shaft. Conventional screws in osteoporotic bone can loosen early even under minimal loading. Locking head screws in this plate (or a longer plate and more conventional screws) may have prevented this implant failure.

Video 3.3.4-1
a Failure of conventional screws–sequential pullout.
b Failure of conventional screws–short plate.
c Strength of longer plate with conventional screws.

Video 3.3.4-2 Failure of conventional screws under repetitive stress.

Video 3.3.4-3 Improved strength with locking screws–no pullout.

Video 3.3.4-4 Improved strength (no pullout) with locking screws under repetitive stress.

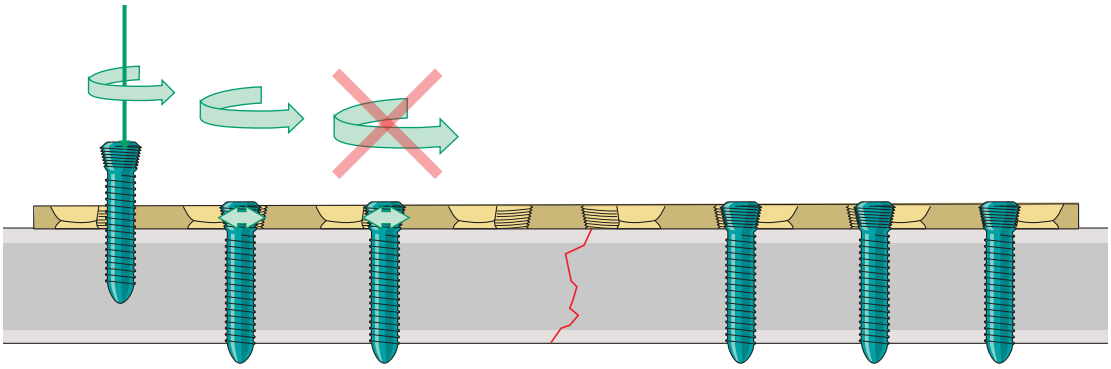

Fig 3.3.4-8 Locking screw insertion without overtightening in osteoporotic bone. Due to the locking mechanism between the screw head and plate hole, the LHS can never be overtightened in the bone. A LHS, when implanted, always advances into the bone following the created thread in the bone until the conical screw head automatically blocks further turning of the screw. Locking head screws can be overtightened in the plate hole causing deformation of the threads and jamming with difficulties for later implant removal.

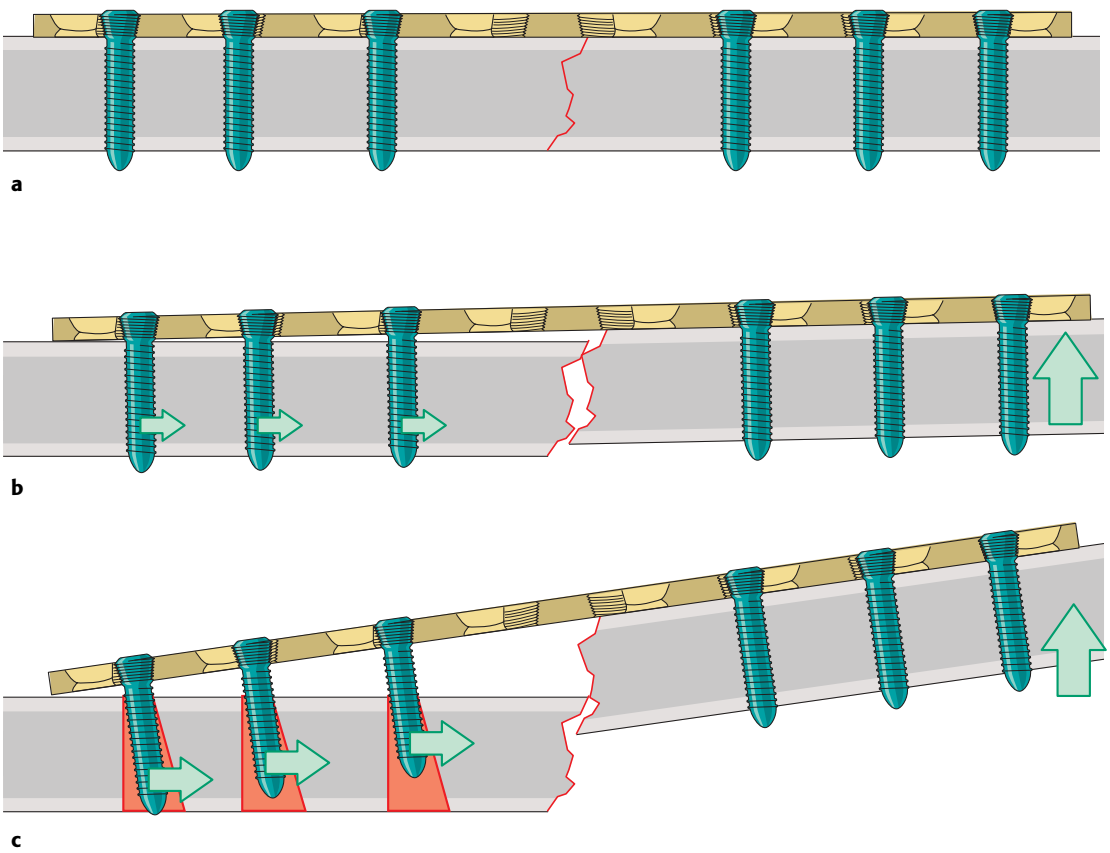

Fig 3.3.4-9a–c En bloc pull-out and cut through of locking screws in osteoporotic bone. A plate fixed to the bone with LHS provides much higher resistance against bending (and torsional) moments. The screws cannot angulate in the plate holes and therefore a large amount of bone substance has to be destroyed before bending pull-out occurs. The advantage is that loss of reduction is less likely. The disadvantage is that loss of reduction results in more bone loss (osteolysis) than seen with conventional plates.

Periprosthetic/periimplant fractures: Special monocortical screws without a tip (periprosthetic screw) (**Fig 3.3.4-10**) and other devices, such as the locking attachment plate (LAP), have been developed to allow screw insertion when the intramedullary canal is occupied by a nail or prosthesis. The VA locking screws also provide this option.

Fractures in small or soft bones require operative stabilization, such as fractures of sternum, ribs (**Fig 3.3.4-11**), scapula, face, or skull.

Revision surgery after failed plate/screw osteosynthesis: Following failed osteosynthesis with a plate and screws, the bone is often weakened by existing screw holes and osteolysis, so there is often limited space to apply new screws. Locking screws can still provide stability with monocortical insertion or in an eccentric position in the bone.



Fig 3.3.4-10 Periprosthetic locking head screw. The screw tip of this monocortical short LHS is flat for placement in the vicinity of a prosthetic stem. The threads advance as close to the stem as possible maximizing working length of the screw.

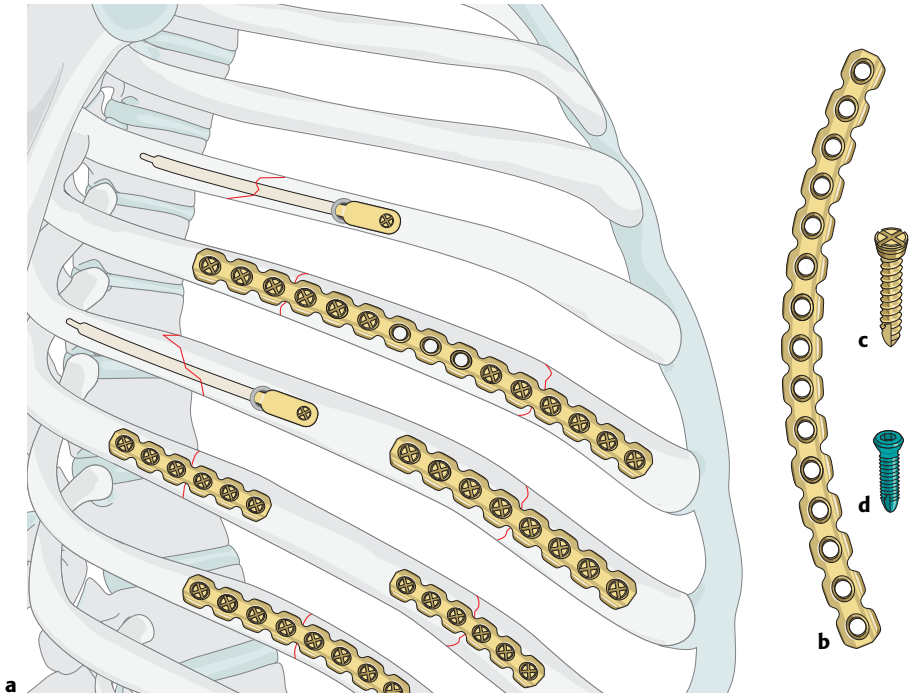

Fig 3.3.4-11a–d Locking plates for rib fractures. Fixation of rib fractures is secure with a locking plate system. The thin bone and anatomical diversity of the bone of the ribs is a perfect indication for the locking technology.

a Hemithorax with multiple broken ribs and a flail segment. Fixation with precontoured locking compression plates (LCP) and intramedullary nails.
b Curved precontoured LCP.
c Self-tapping locking head screw.
d Self-tapping conventional screw. These are not commonly used as screw loosening may result in intrathoracic migration of the loose screw.

2.3 Periarticular fractures

The second main indication for the use of locking screws is a fracture close to a joint.

The short periarticular bone segment can only be fixed with the short part of the plate. Fixation is improved by increasing the number of screws with a T-plate or L-plate but there is still a short lever arm that creates high pull-out and bending forces on the screws. Conventional screws may loosen and back-out or angulate within the plate holes, even with good bone quality. This results in early loss of reduction and instability (**Fig 3.3.4-12**). In these short bone segments, implants with angular stability are essential. This can be provided by an angled blade plate or locking screws when the plate, together with the periarticular screws, act like a "modular" angled blade plate (**Fig 3.3.4-13**). The poorest bone quality in fragility fractures is typically in the metaphysis and older adult patients with fractures in these regions benefit from the use of locking plates. For nearly all regions in the human body, anatomically preformed "periarticular" plates have been developed. The periarticular plate holes allow for the insertion of conventional or locking screws, but it is advantageous to use locking screws in the metaphysis, especially if the plate does not fit perfectly to the bone surface.

2.4 Minimally invasive plate osteosynthesis

Minimally invasive plate osteosynthesis (MIPO) is a third indication for locking plates, as these plates are easier to insert and fix compared with conventional plates and precise contouring of the plate is not required. When performing MIPO it may be difficult to position the plate in the ideal place on the bone.

Poorly contoured and/or eccentrically placed plates using conventional screws may result in early loss of stability due to poor contact between the bone and the plate or malreduction as the bone is pulled onto the poorly contoured plate when the conventional screws are tightened. This can result in axial malalignment or rotational deformity when pulling the bone to an eccentrically placed plate in the diaphysis (**Figs 3.3.4-14–15**). Using locking screws in these situations may prevent primary loss of reduction (**Fig 3.3.4-16**).

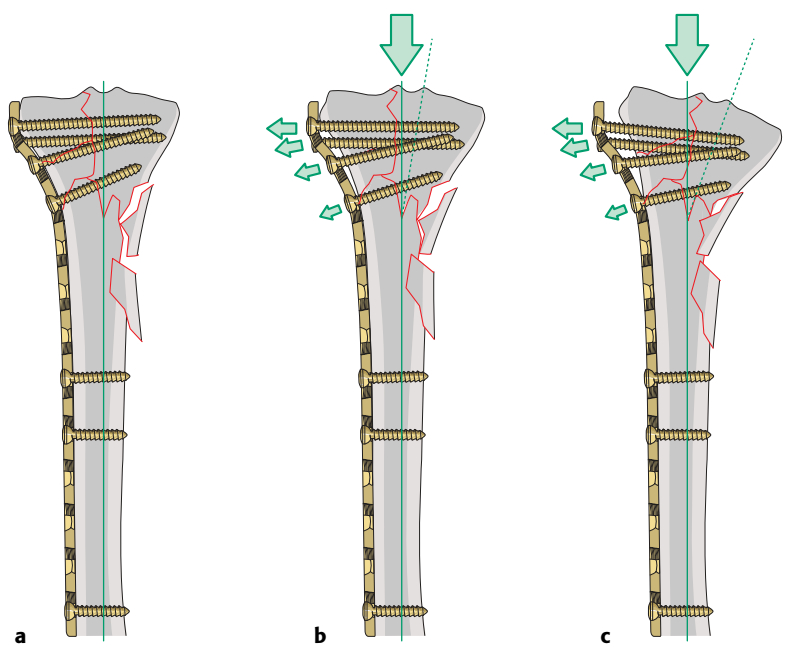

Fig 3.3.4-12a–c Secondary loss of reduction with conventional screws. In short end segments, the lever arm of the plate is short creating high pull-out forces in conventional screws. These tend to loosen early in a sequential manner, the friction between plate and bone is lost and the plate comes off the bone. This occurs because the articular block can be angulated in the coronal plane and the screws are not locked in the plate holes.

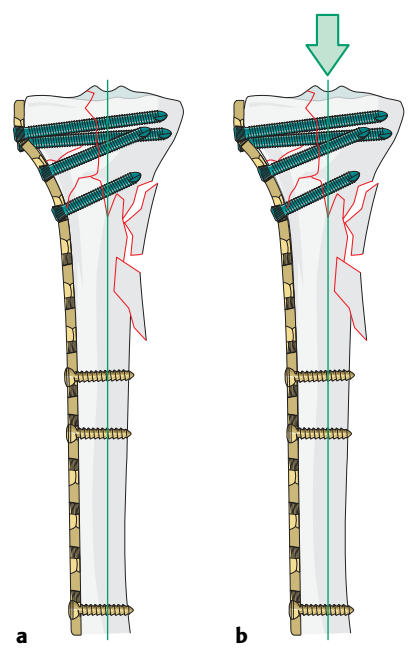

Fig 3.3.4-13a–b No secondary loss of reduction occurs with LHS which provide angular stability and therefore cannot angulate in the plate holes. The plate and all LHS combine into one unit which stays stable even in short end segments of the bone and when there is no inherent stability of the far cortex due to fragmentation.

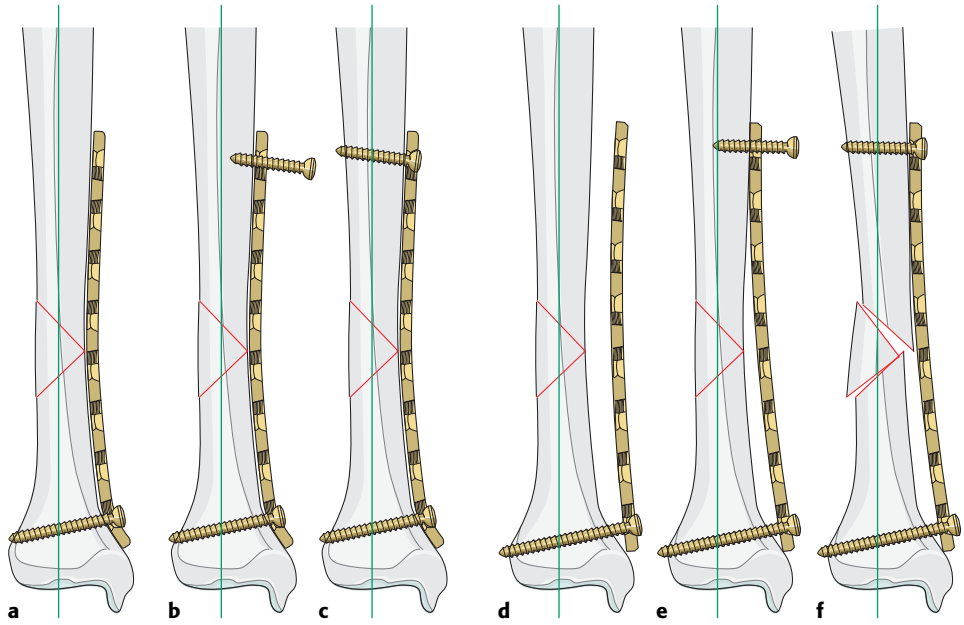

Fig 3.3.4-14a–f Primary loss of reduction with conventional screws. For the medial distal tibial plate, it is often necessary to insert a conventional screw close to the medial malleolus otherwise the plate can stand off the bone and result in skin tension when the wound is closed.

a–c If the plate is perfectly contoured (which is difficult with MIPO techniques) the insertion of conventional screws will maintain the reduction.

d–f However, if the plate is not contoured perfectly, inserting conventional screws will displace an already reduced fracture creating either an axial or torsional (or both) malalignment.

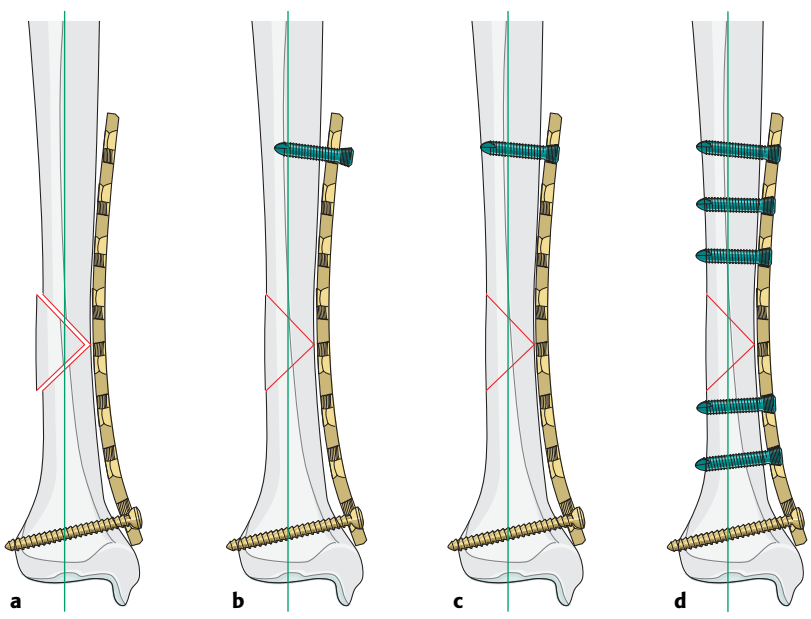

Fig 3.3.4-15a–d No primary loss of reduction with LHS. Fixing a fracture with an imperfectly contoured plate (what happens during minimal invasive plating without direct vision onto the bone surface) and LHS will not displace the already aligned fracture. When using conventional screws (for reduction and/or approximation of the plate to the bone), they must be inserted first.

3 Principles of locking screw application

3.1 General characteristics

The LHS is designed to lock tightly into the plate. This provides axial and angular stability of the screw relative to the plate. Fracture fixation with a locked plate is less dependent on the bone quality or the anatomical region for anchorage (**Fig/Animation 3.3.4-17**). Unlike the conventional screw, this screw-plate combination does not require friction between the plate and the bone to stabilize the fracture. If used as an internal fixator, ie, LHS on both sides of the fracture, force will be transferred from one bone segment to another via the plate-screw construct. In this situation, the LHS is exposed to bending load rather than tensile forces (**Fig/Animation 3.3.4-18**). Furthermore, the locking plate does not have to be contoured precisely to the shape of the bone, as tightening of the LHS does not press the implant against the bone (**Fig/Animation 3.3.4-19**). This prevents malreduction during tightening of the LHS and helps preserve periosteal vascularity underneath the implant (**Fig/Animation 3.3.4-20**).

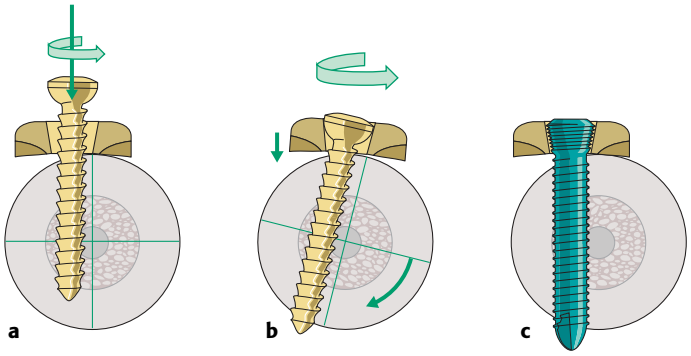

Fig 3.3.4-16a–c Primary loss of rotation with conventional screw vs LHS.
a–b A slightly eccentric plate position, which happens mainly in minimally invasive plating, will directly rotate an already correct and aligned fracture when the first conventional screw is tightened.
c This does not occur using an LHS.

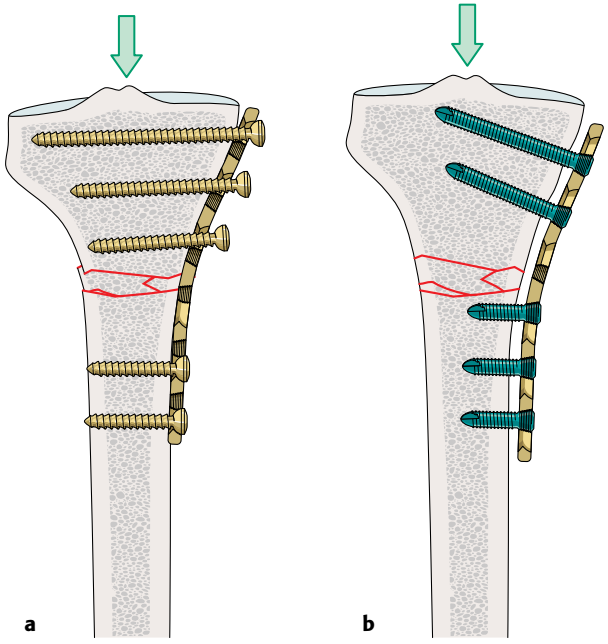

Fig/Animation 3.3.4-17a–b Loosening of conventional screws from the plate occurs sequentially, but hardly ever with locking head screws.

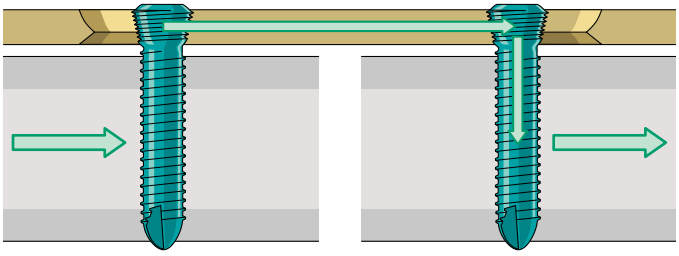

Fig/Animation 3.3.4-18 With locking head screws the load transmission occurs through the screws and the plate. Both are therefore exposed to bending load.

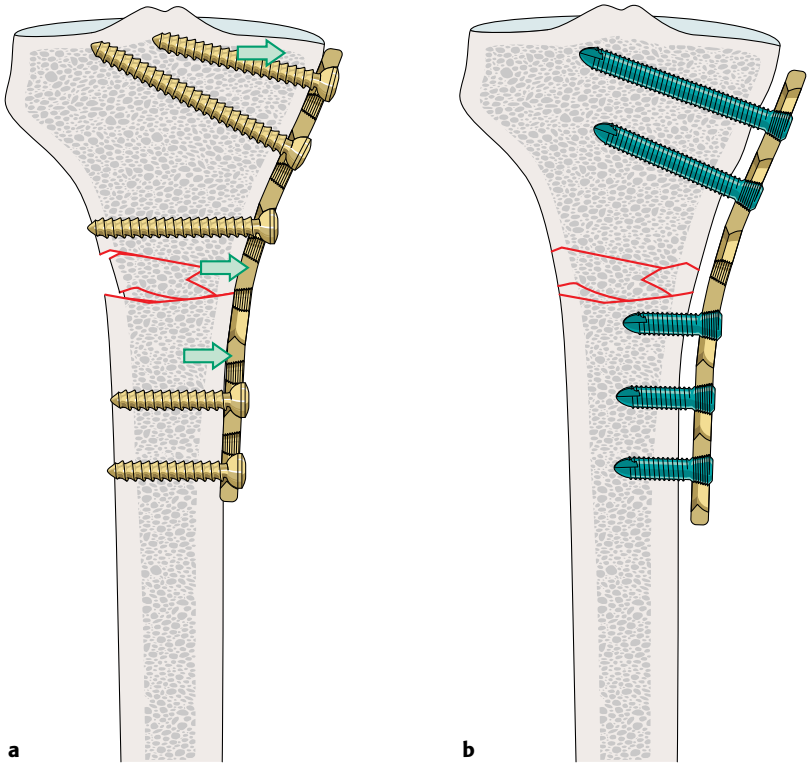

Fig/Animation 3.3.4-19a–b The LCP with LHS does not require precise contouring.

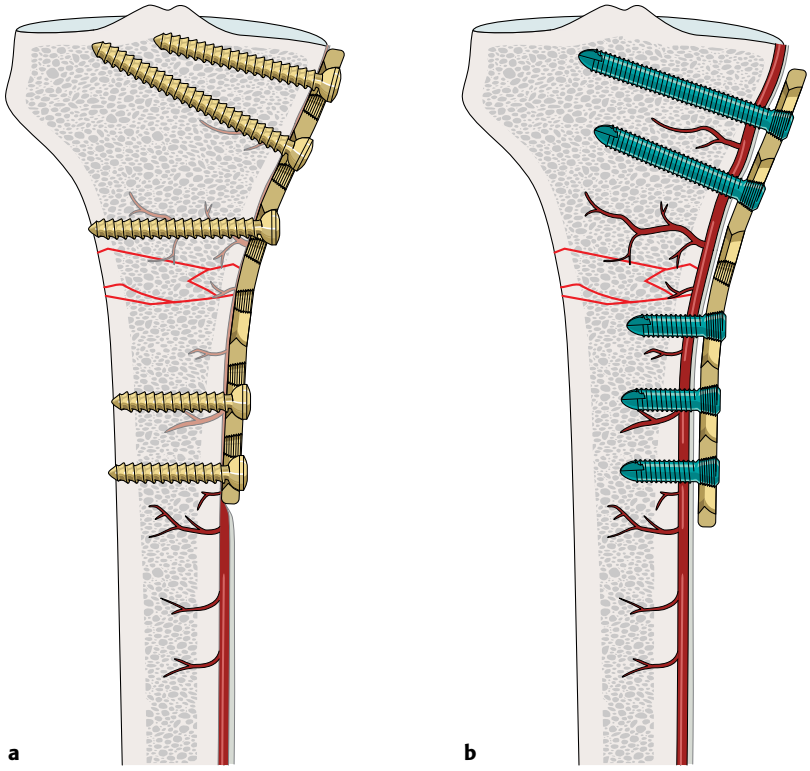

Fig/Animation 3.3.4-20a–b The LCP with LHS is not pressed against the bone. This helps preserve periosteal blood supply.

3.2 Types and functions of locking head screws

There are a number of rules for the application of the LHS. (**Table 3.3.4-2**):

- They must be used with a locking plate.
- Never use an LHS as a lag screw.
- Do not cross an unreduced fracture with an LHS, except a central articular defect in a multifragmentary articular fracture (type C3).

The correct mode of application is:

- Centered in the plate thread hole and at the correct angle using a precisely placed threaded drill sleeve (for LHS) or cylindrical drill sleeve (for VA screws only) or periarticular guide block (eg, PHILOS plate).
- Use of the correct torque-limiting attachment (TLA) for screw tightening is mandatory. This can be part of the screwdriver or power tool attachment. Overtightening can result in the screw jamming in the plate due to deformation of the thread of the screw head or plate hole. There may also be primary damage to the screwdriver recess in the screw head. All these lead to great difficulty in removing the screw and plate.

Different types of screws (**Fig 3.3.4-21**)

- Self-tapping LHS
- Self-drilling, self-tapping LHS
- Variable angle, self-tapping LHS (VA screws) (**Fig 3.3.4-4**)

Different functions of locking screws (**Fig 3.3.4-22**)

- Plate fixation screw: fixation of plate to bone. Usually applied in one or both of the two main fracture fragments.
- Position screw: keeps two (or more) well-reduced articular or metaphyseal fragments in correct relative anatomical position to each other. This function is always combined with the function of a plate fixation screw.

Function	Type of screw	Effect	Prerequirements
Lag screw • Free, plate-independent • Plate lagging screw	Cortex screw* Cortex (shaft) screw† Cancellous bone screw†	Interfragmentary compression	Gliding hole, threaded hole for a fully threaded screw or a partially threaded screw
Eccentric screw = axial compression screw	Cortex screw Cancellous bone screw	Interfragmentary compression	Dynamic compression unit and hemispheric screw head of conventional screw
Plate fixation	Cortex screw Cancellous bone screw	Friction between bone and plate	Adequate bone quality and precise fit of the plate to the bone surface
	LHS	Locking into plate, angular stability, screw loosening less common	Precise screw trajectory using threaded drill sleeve or guide, adequate tightening using torque-limiting attachment
Position screw • Free, plate-independent • Through a plate hole	Cortex screw Cancellous bone screw, fully threaded LHS (only through a plate)	Maintaining the relative position between two bones or bone fragments	Temporary fixation of the two bones/fragments during tapping and screw insertion
Reduction screw	Cortex screw Cancellous bone screw	Reduction onto the plate Reduction of a butterfly fragment at opposite side of the plate	No interfragmentary compression, only adaptation of the bone fragments
	LHS	Reduction onto the plate	Screwdriver with screw holding sleeve covering the screw head

* Using self-tapping screws as lag screws are not recommended.
† Partially threaded titanium screw.

Table 3.3.4-2 Different functions and rules for screws.
Abbreviation: LHS, locking head screw.

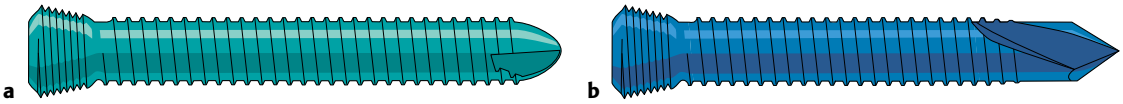

Fig 3.3.4-21a–b Different types of LHS.
a The conventional LHS is green—self-tapping but not self-drilling— commonly used in a bicortical application.
b Rarely, a blue-colored self-drilling/self-tapping screw can be used in a monocortical mode (traditionally used for the LISS when inserted through the drill sleeves of the aiming jig). This screw is not advised for bicortical application because the tip must penetrate further through the far cortex and may cause soft-tissue damage (**Fig 3.3.4-18**).

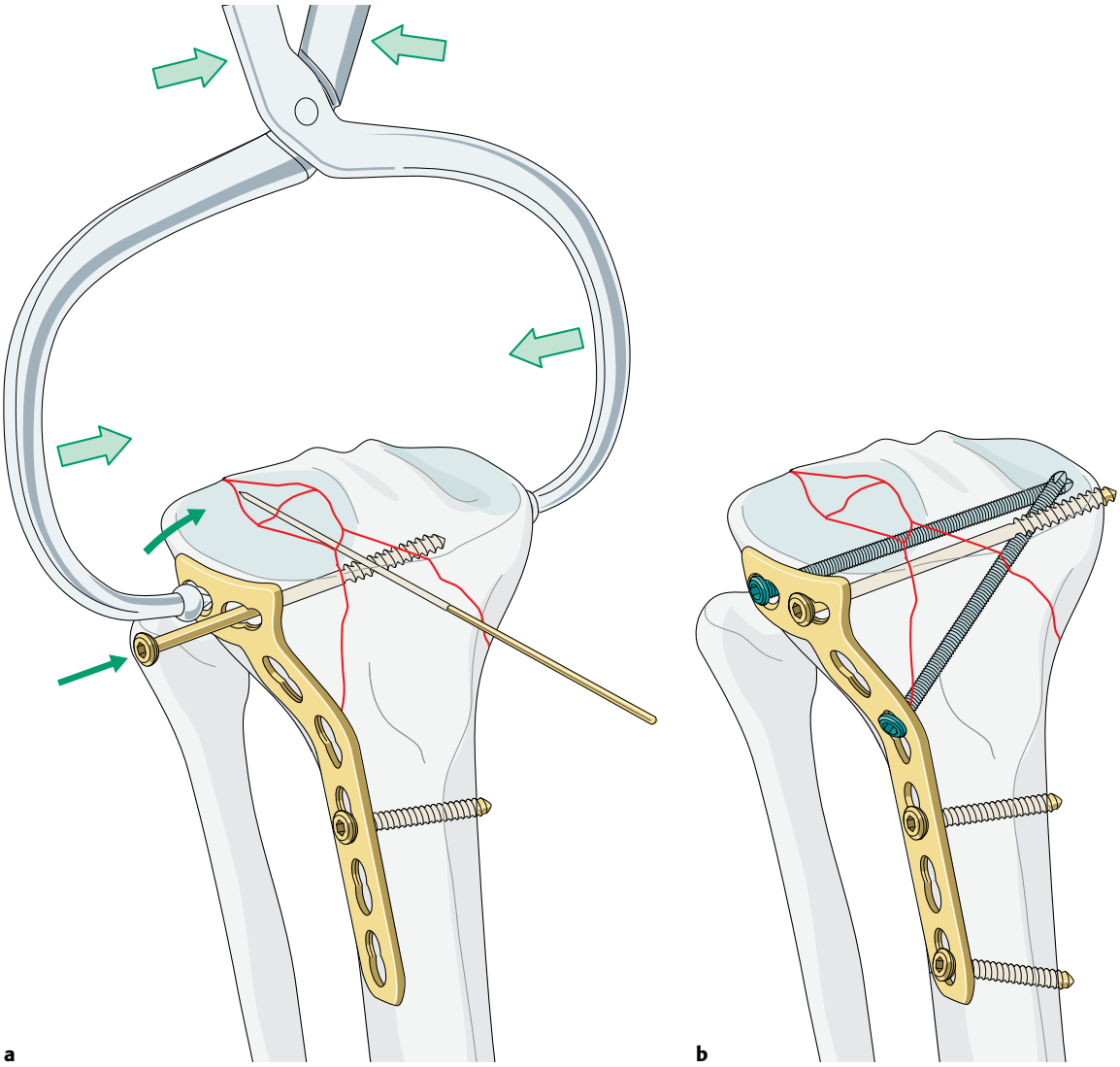

Fig 3.3.4-22a–b Fixation of a proximal tibial fracture showing the different functions of screws.
a The fracture is reduced and held with a combination of clamps and K-wires. Standard screws are used to fix the plate and provide compression across the articular fracture.
b Locking head screws are then used to complete the fixation and function as a position screw across the multifragmentary articular fracture and as plate screws.

3.3 Monocortical or bicortical locking head screws

The bicortical LHS is recommended in most situations in the diaphysis, as the screw has a much longer working length. This is especially advised in osteoporotic bone (**Fig 3.3.4-23**).

Only self-tapping LHS are used for bicortical application. Self-drilling/self-tapping screws in bicortical application are not recommended as they can irritate and damage soft-tissue structures with their sharp screw tip (**Fig 3.3.4-24**).

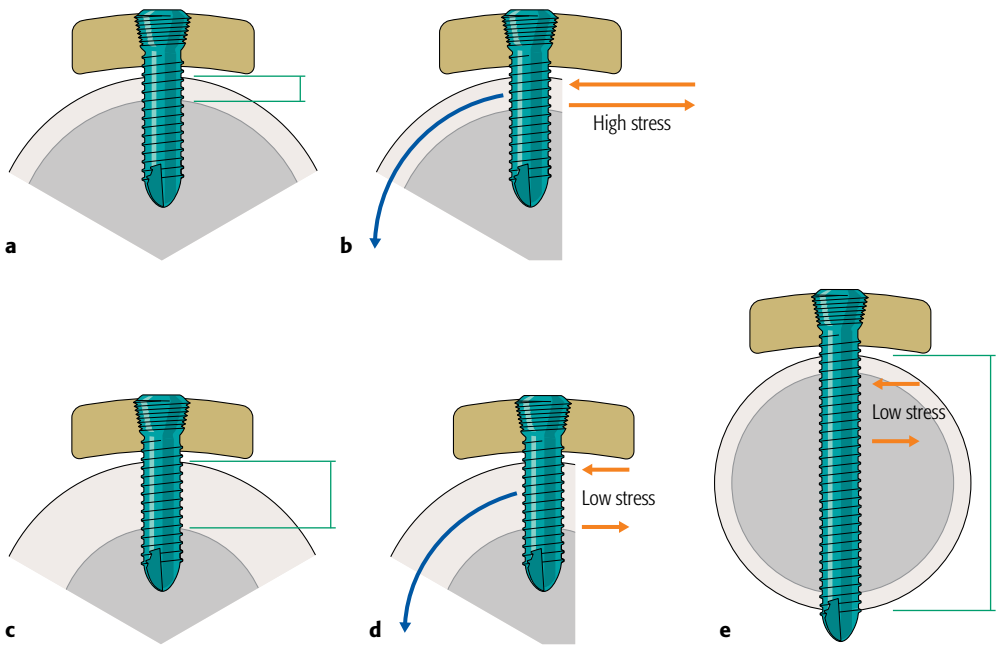

Fig 3.3.4-23a–e Working length of locking head screws. Length of screw thread in contact with bone influences stress at screw-bone interface. A short working length exists when there is thin bone cortex or monocortical screw insertion. This results in high stress at the interface (**a–b**). A long working length exists when there is thick bone cortex or bicortical screw insertion. This results in low stress at the interface (**c–e**).

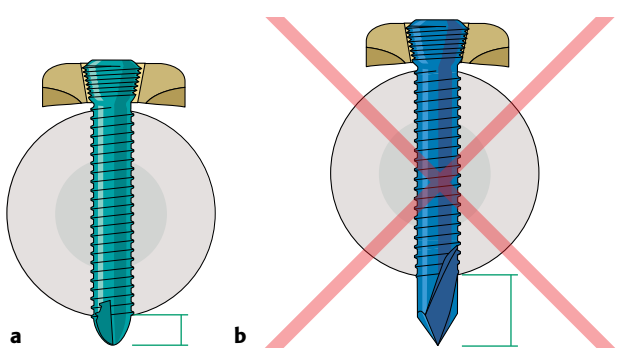

Fig 3.3.4-24a–b Self-drilling and self-tapping bicortical locking head screws (LHS). Bicortical application is reserved for the self-tapping LHS (**a**) and should be avoided using a self-drilling self-tapping LHS (**b**).

"Subbicortical" periarticular LHSs are used close to joints and traverse the full distance of the cancellous bone but do not penetrate the opposite cortex (**Fig 3.3.4-25**). This guarantees the longest working length but prevents:

- Soft-tissue irritation on the opposite side of the bone (eg, extensor tendons at the wrist when using a palmar distal radial plate, or femoral origin of MCL when using lateral distal femoral plate) (**Fig 3.3.4-26**)
- Intraarticular screw tip penetration on the opposite side of the bone (eg, proximal humerus or distal humeral lateral condyle)
- Screw tip penetration into the tibiofibular syndesmosis in distal tibia or fibular plating

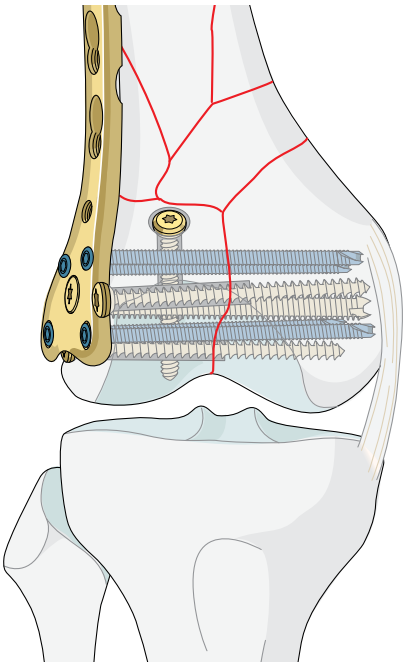

Fig 3.3.4-25 Correct length of locking head screws (LHS) in the distal femoral metaphysis. Especially in poor bone quality, the LHS in the metaphysis should have the longest possible working length. However, the screw tips should not penetrate the opposite cortex irritating soft-tissue structures such as ligaments or tendons. They are neither monocortical nor bicortical, what could be named as "subbicortical" (= nearly bicortical).

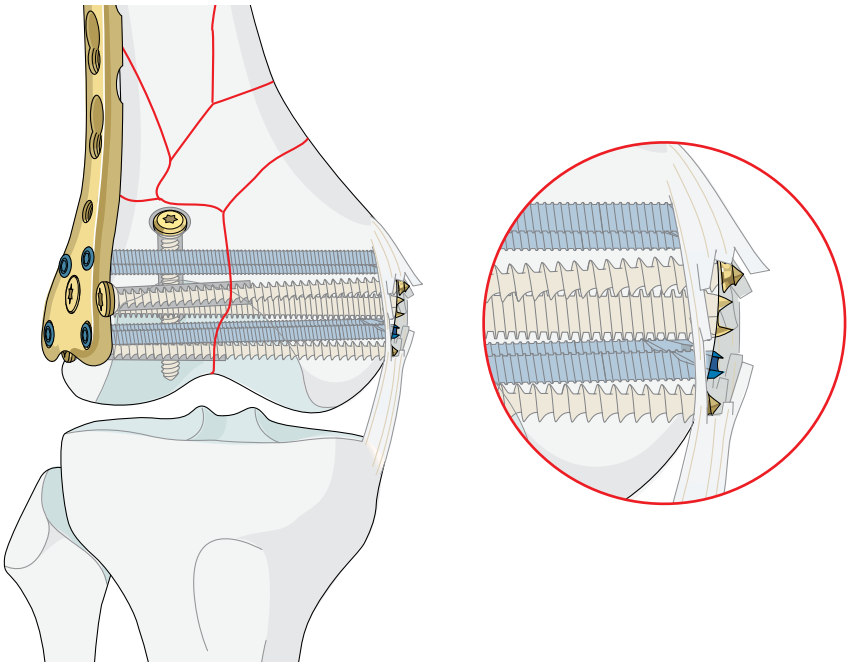

Fig 3.3.4-26 Locking head screws (LHS) that are too long in the distal femoral metaphysis. Bicortical LHS in certain locations, such as distal femur (or distal radius) may irritate important soft-tissue structures and therefore should be avoided in these regions.

Screws that are too short in poor bone result in early loss of reduction and deformity (**Fig 3.3.4-27**).

Monocortical screws are occasionally used in the following circumstances:

- Periprosthetic fracture: The periprosthetic screw (flat screw tip) (**Fig 3.3.4-10**) increases working length of the screw compared with the normal LHS.
- Temporary reduction plates: Small plates (2.4, 2.7, or 3.5) may be used to hold a reduction during definitive fixation with a nail or larger plate. Monocortical screws are helpful and do not block reamers, nails, or screws in the medullary canal.
- Supplementary fixation in good diaphyseal bone (fixation that relies on monocortical screws alone is not advised).
- Long spiral fracture: may enhance fixation to allow for the use of a shorter plate (**Fig 3.3.4-28**).

3.4 Number of screws

Rules for the use of bicortical LHS:

- Two bicortical screws in each main fragment can be used with a longer plate in good bone quality and with an expected short healing time (good vascularity, good reduction, and a low-energy injury). The position of the screws must be perfectly centered to the bone (not tangential). There is little room for error and less experienced surgeons should always consider using more than two screws.
- Three bicortical screws in each main fragment should normally be used.
- Four (or more) bicortical screws are advised in osteoporotic bone, especially in bones with torsional loading (eg, humerus).
- Using a locked screw in the last screw hole at the end of the plate can produce a stress riser and may be associated with an increased risk of periimplant fracture, particularly in osteoporotic bone. Surgeons should consider using a bicortical conventional screw in this position. If it is inserted after LHS, care should be taken not to overtighten the screw [8].

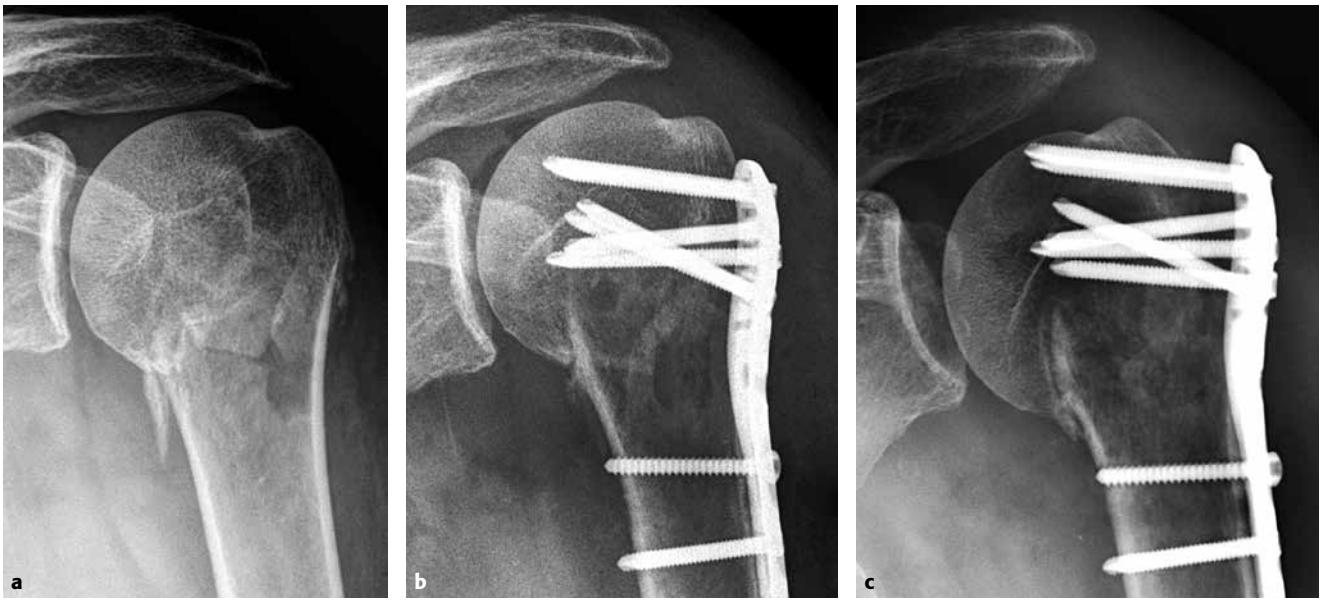

Fig 3.3.4-27a–c Short locking head screws in a humeral head with early varus malangulation.
a–b In an osteopenic humerus, the bone which has adequate quality to provide a stable screw-bone interface is sited close to the cartilage near the subchondral region. The LHSs inserted in the humeral head should be long enough to anchor the screw tips in this more solid bone.
c If chosen too short, as in this case after 6 weeks, early instability with varus collapse can occur.

4 Locking compression plate

4.1 General characteristics

The unique feature of the LCP is the combi-hole, which can accommodate either a conventional screw or LHS. The first part of the combi-hole has the design of the conventional DCP/LC-DCP compression hole (dynamic compression unit) which accepts a conventional screw to produce axial compression or the placement of an angled lag screw through the plate. The second part is conical and threaded to accept the LHS and its position is close to the plate center in straight plates or close to the location of fracture in periarticular plates (**Fig 3.3.4-8**).

All conventional plates from the different systems (4.5, 3.5, 2.7, and smaller) (LC-DCP, L-plates, and T-plates, as well as reconstruction plates) have been made with the combi-hole, but without any change in the overall plate dimensions. The periarticular portion of most anatomically preshaped LCP's consists of round, conical, threaded plate holes for the insertion of LHSs but they can also accept conventional screws if desired.

In some new plate systems, VA technology is incorporated in the plate holes to allow insertion of variable angle locking screws at 15° to the perpendicular screw trajectory.

4.2 "Hybrid" application of locking compression plate

When both locking and nonlocking screw types are used in one plate, it can be called "hybrid" application [9]. In the last 10 years, this method of application has been increasingly practiced. Several biomechanical and clinical studies on large bones have shown that the combination of locking and conventional screws is effective. The capacity to resist torsional forces is significantly higher when the locking plate is applied with the hybrid technique to the lateral distal femur [10]. It is first fixed distally to the condyles with a conventional screw(s), then augmented with locking screws. This may be because the broad, anatomically preshaped part of the plate gives additional torsional stability when pressed against the bone. If there is good bone stock, conventional screws can be used to fix the plate to the diaphysis.

Similar results were reported on patients undergoing a medial high-tibial osteotomy with lateral hybrid plating [11]. However, incorrect application of hybrid plating systems can run the risk of failing to achieve either absolute or relative stability. This may create an environment with high strain. The result is implant failure and delayed or nonunion [12].

Fig 3.3.4-28a–c Monocortical locking head screw (LHS) in a long spiral fracture (**a**). Using monocortical screws to supplement bicortical LHS, the afforded total length as well as the working length of the plate can be reduced to the desired length (**b**). Four-year follow-up x-ray (**c**).

Careful preoperative planning with a clear aim to produce absolute or relative stability is essential when using an LCP as a hybrid plating system. Optimal interfragmentary or plate-to-bone compression must be achieved before the application of the locked screws (lag first, lock second).

4.3 Biomechanics of the locking compression plate

The LCP can be used to provide the six standard functions of a plate:

- Compression
- Protection
- Buttress
- Tension band
- Bridging
- Reduction

All these functions can be provided by using conventional screws or with hybrid fixation using a combination of locking and conventional screws. With locking screws alone, an LCP can function as a protection, buttress, tension band, or bridge plate but cannot be used as a compression plate or reduction tool.

In any individual case, one of the different plate functions should be ideal and the surgeon must plan according to the fracture location, fracture pattern, bone quality, and the soft-tissue situation. The correct execution of the preoperative plan depends upon many factors, including the method and quality of reduction, length of plate, the number and type of screws, and their sequence of insertion (**Table 3.3.4-3**). To produce the different plate functions, conventional screws only, locking screws only, or both screw types ("hybrid" application) may be used.

	Simple fracture (A-type and B2-type)		**Multifragmentary fracture (B3-type and C-type)**
Biomechanical principle	**Interfragmentary compression**	**Splinting ± reduction lag screw**	**Splinting**
Reduction technique	Mainly direct	Indirect or percutaneous direct*	Preferably indirect
Insertion	At least partly open	Open, less invasive, MIPO	Closed, minimally invasive
Contouring of the plate	Has to be precise to bone surface	Accurate contouring not needed with LHS	Accurate contouring not needed with LHS
Plate span ratio†	8–10 (in transverse or short oblique fracture), 2–3 (in long spiral fracture)		2–3 (in long fracture zone), 4–8 (in short fracture)
Screw type	For compression: cortex screws in eccentric position or lag screw For plate fixation: cortex screw in neutral position or LHS‡	Cortex screws or LHS‡	Cortex screws or LHS‡
Monocortical/bicortical screws	Cortex screws: bicortical LHS: bicortical. Monocortical screws around implants for periprosthetic fractures		
LHS in the diaphysis	Bicortical, self-tapping screws Monocortical self-drilling "periprosthetic" screws for periprosthetic fractures Monocortical self-drilling/self-tapping screws are optional in good bone in diaphysis (eg, LISS with aiming arm)		
LHS in the metaphysis	Self-tapping screws (as long as possible, but not perforating opposite bone surface)		
Plate screw density	≤ 0.6–0.8	≤ 0.4–0.5	≤ 0.4–0.5
Screws per main fragment (n)	≥ 3 (2 exceptionally)	≥ 3 (2 exceptionally)	≥ 3 (2 exceptionally)
Cortices per main fragment (n)	≥ 5–6	≥ 4	≥ 4
Screw position	Close to the fracture, aiming for absolute stability	Middle segment (≥ 2 plate holes) without screws, no lag screws (splinting method)	Fracture zone without screws, but screws close to the fracture
Empty plate holes over the fracture (= plate working length)	0–2	≥ 2	≥ 2

* When splinting simple fractures, reduction must be accurate: gap free or at least gap < 1–2 mm (= near anatomical).
† Plate span ratio = plate length/fracture length.
‡ In epiphysis/metaphysis and/or in poor bone and/or in MIPO technique.

Table 3.3.4-3 Guidelines for plate fixation in simple and multifragmentary diaphyseal and metaphyseal fractures.
Abbreviations: LHS, locking head screw; LISS, less invasive stabilization system; MIPO, minimally invasive plate osteosynthesis.

The method of fracture treatment and type of stability produced leads to different types of fracture healing and the LCP allows the surgeon to select the correct biomechanical environment for the fracture, producing either absolute or relative stability. With proper use, the LCP can significantly contribute to the improvement of the clinical outcome following operative treatment of fractures. The first published results on the use of LCP have been promising but have identified difficulties and complications [5], many of which were due to application errors [13] despite the publication of guidelines for the correct use of the LCP [6]. Clinical experience with the use of LCPs has grown [14–17].

4.4 Absolute stability with the locking compression plate

Anatomical reduction and interfragmentary compression of simple fracture patterns (type A or type B2) can be achieved with the LCP. The reduction should result in no fracture gap and the plate is placed on the tension side of the bone. This plating technique is currently reserved for the articular segments of fractures or simple diaphyseal fractures where anatomical healing is needed. Plate fixation of both bone forearm fractures is a common example. With good bone quality and direct, anatomical reduction, there is no need to use locking screws [18] and the fracture can be fixed with conventional screws following AO principles. However, experienced surgeons know that absolute stability may be lost in the early stage of bone healing, leading to some instability with callus formation (irritation callus). In a recent retrospective study [19] of simple (type A and type B2) humeral shaft fractures treated with compression plating techniques, more than 40% of the healed cases showed callus formation with secondary bone healing. This demonstrated that planned absolute stability was only achieved in 60% of cases and that absolute stability is not mandatory for good healing of simple diaphyseal humeral fractures. The most important and statistically significant factor for healing was the size of fracture gap on radiographs [19] ($P = .001$) and this emphasizes that anatomical reduction and compression is essential if the surgeon is to achieve absolute stability.

The LCP using both conventional and locked screws can be used in a number of situations:

Simple metaphyseal fractures in osteoporotic bone: The fracture is reduced and held by one or more lag screws, carefully tightened due to poor bone. The LCP functions as a protection plate and is fixed with one or two conventional screw(s) to each main fracture fragment to approximate the plate to the bone. Further plate fixation is carried out adding bicortical LHSs following the guidelines in (**Table 3.3.4-3**). Alternatively, the protection plate is approximated to the bone by manual push (instead of conventional screws first) and then fixed entirely with LHS on both sides (**Fig 3.3.4-29**).

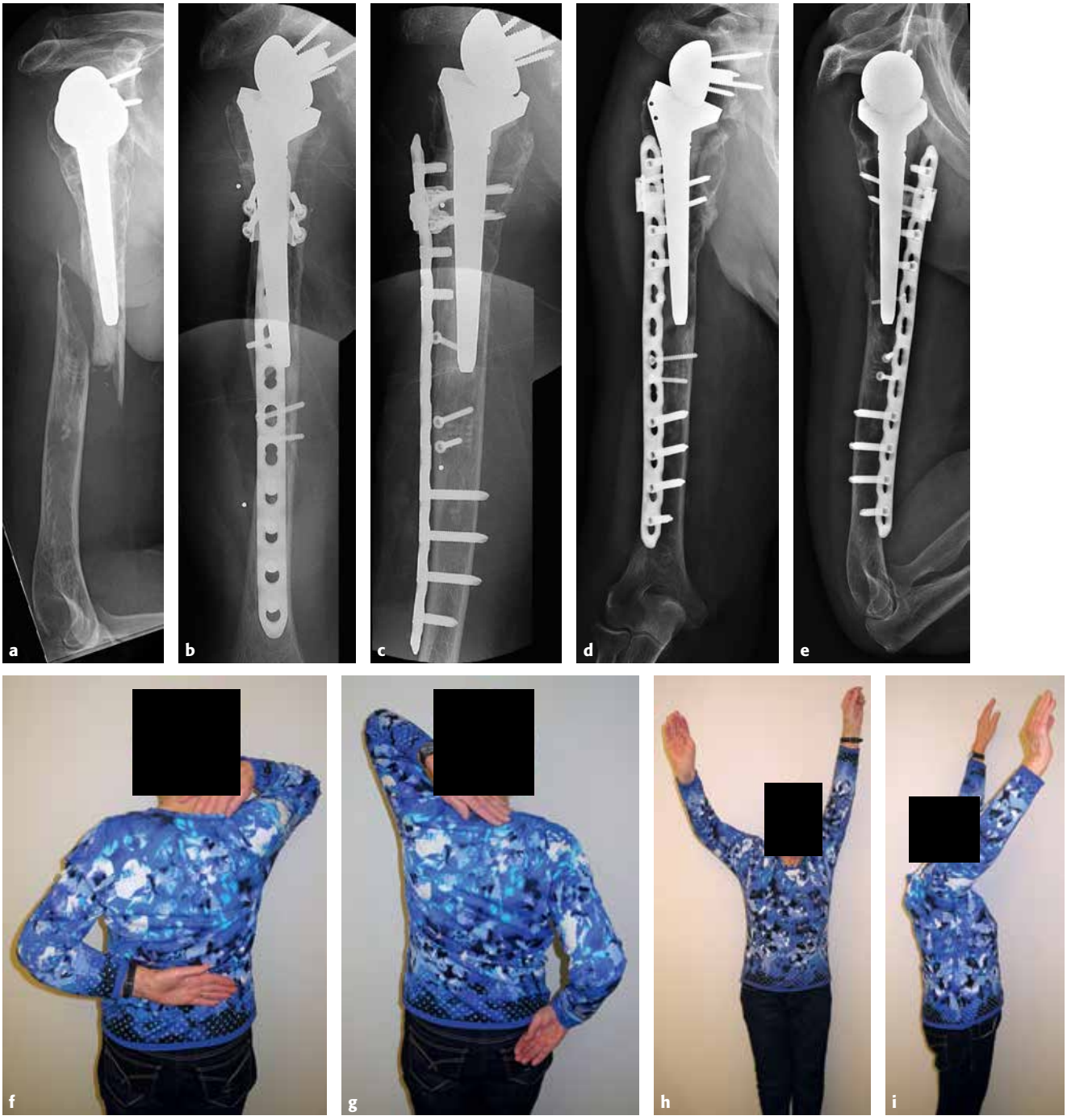

Fig 3.3.4-29a–i Periprosthetic 12A1 fracture in osteoporotic bone treated with a compression technique using a locking compression plate (LCP) with locking head screw (LHS) for entire plate fixation.

a An 85-year-old woman with a simple periprosthetic fracture below a shoulder prosthesis, and severe osteoporosis with thin cortical bone.

b–c The fracture is approached with an open incision, anatomically reduced and maintained by three 3.5 mm lag screws carefully tightened. These screws reduce the fracture until plate application, but can not provide strong interfragmentary compression because of the poor bone quality. The forces are neutralized with a long narrow LCP 4.5 which is fixed to the bone by LHSs only. In the proximal piece, short monocortical periprosthetic screws are used, and the fixation is enhanced by a locking attachment plate. To reduce the risk of periimplant fracture distally, one monocortical screw is used at the plate end.

d–i One year follow-up images.

Periarticular fractures (with or without articular involvement): The anatomically precontoured plate is fixed to the articular part with LHSs providing angular stability. Interfragmentary compression is achieved using a lag screw or with the plate using a conventional screw in a dynamic screw hole or the articulated tensioning device. The definitive fixation to the diaphyseal main fragment is entirely done with conventional screws in good bone (**Fig 3.3.4-30**) or with one or two conventional screws followed by 2–3 bicortical LHS in poor bone (**Fig 3.3.4-31**). If there is an articular fracture, this is reduced first and compressed by independent lag screws or screws through the plate. Occasionally, the articular fracture is compressed by reduction forceps applied onto the plate, using it as a "washer." Some plating systems are instrumented with special compression devices that attach onto the plate itself. Following reduction and compression, LHSs are inserted and function simultaneously as position screws to hold the articular fracture reduction and plate fixation screws (**Fig 3.3.4-32**).

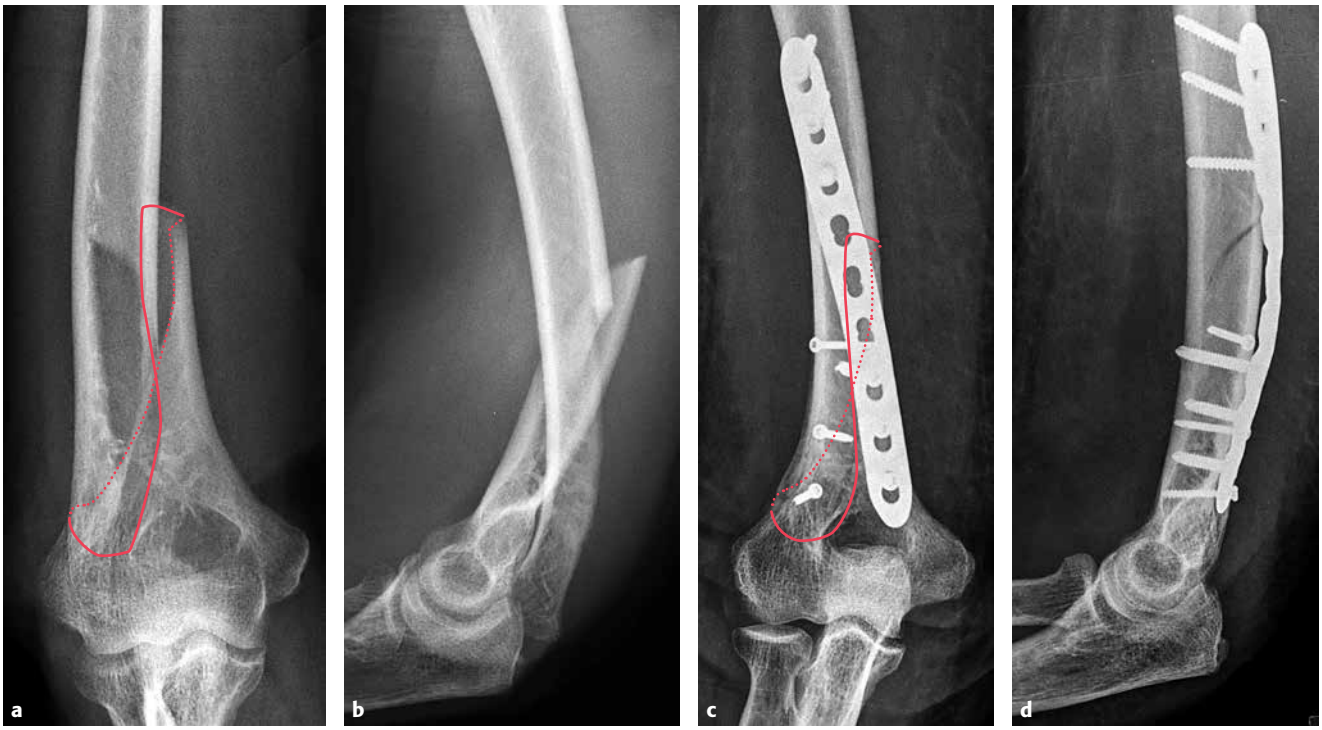

Fig 3.3.4-30a–d A 12A1 distal humeral fracture treated with a compression technique with a locking compression plate (LCP) and locking head screws (LHS) in the metaphysis and conventional screws in the diaphysis.

a–b A 75-year-old woman, with simple torsional fracture at the distal metadiaphysis of the humerus with moderate bone quality.

c–d Open anatomical reduction and fixation by three 3.5 mm lag screws is followed by fixation distal of the precontoured and twisted narrow LCP 4.5 with three bicortical LHS. The main fracture is additionally compressed by insertion of a conventional screw at the proximal plate end in eccentric position, followed by two other conventional screws to finish the fixation.

Fig 3.3.4-31a–h A 42A1 distal tibial fracture in osteoporotic bone treated using a compression technique with locking compression plate (LCP) in "hybrid" application.

a–b A 76-year-old woman, suffers a low-energy trauma with simple torsional fracture at the distal tibial metadiaphysis. Total knee arthroplasty in place makes intramedullary nailing impossible.

c A distal anterolateral approach is performed; the fracture in the distal part visualized and anatomically reduced with reduction forceps. A reduction screw (lag screw principle, carefully tightened in this poor bone) keeps this position until the plate is inserted through the distal approach submuscularly at the proximal end. Preliminary fixation distally is achieved, and then a conventional cortical screw is inserted percutaneously in the most proximal plate hole to bring the well-centered plate close to the bone.

d–f Final fixation is carried out with locking head screws only due to poor bone quality. Where possible, periprosthetic fractures should have the whole bone plated, as is the case here. The fracture fixation worked but guidelines should be followed.

g–h After 1 year, healing occurs indirectly with callus formation despite compression technique being applied. This construct with one (plate) independent lag screw "protected" by this rather flexible and long LCP with, few but well-separated screws in the diaphysis provides only for a short time (if at all) absolute stability. With partial loading, even when protected with a cast or walking splint, this absolute stability is lost. Relative stabilty results with micromotion at the fracture side and consequent callus formation mainly at the opposite side of the plate (posteromedial).

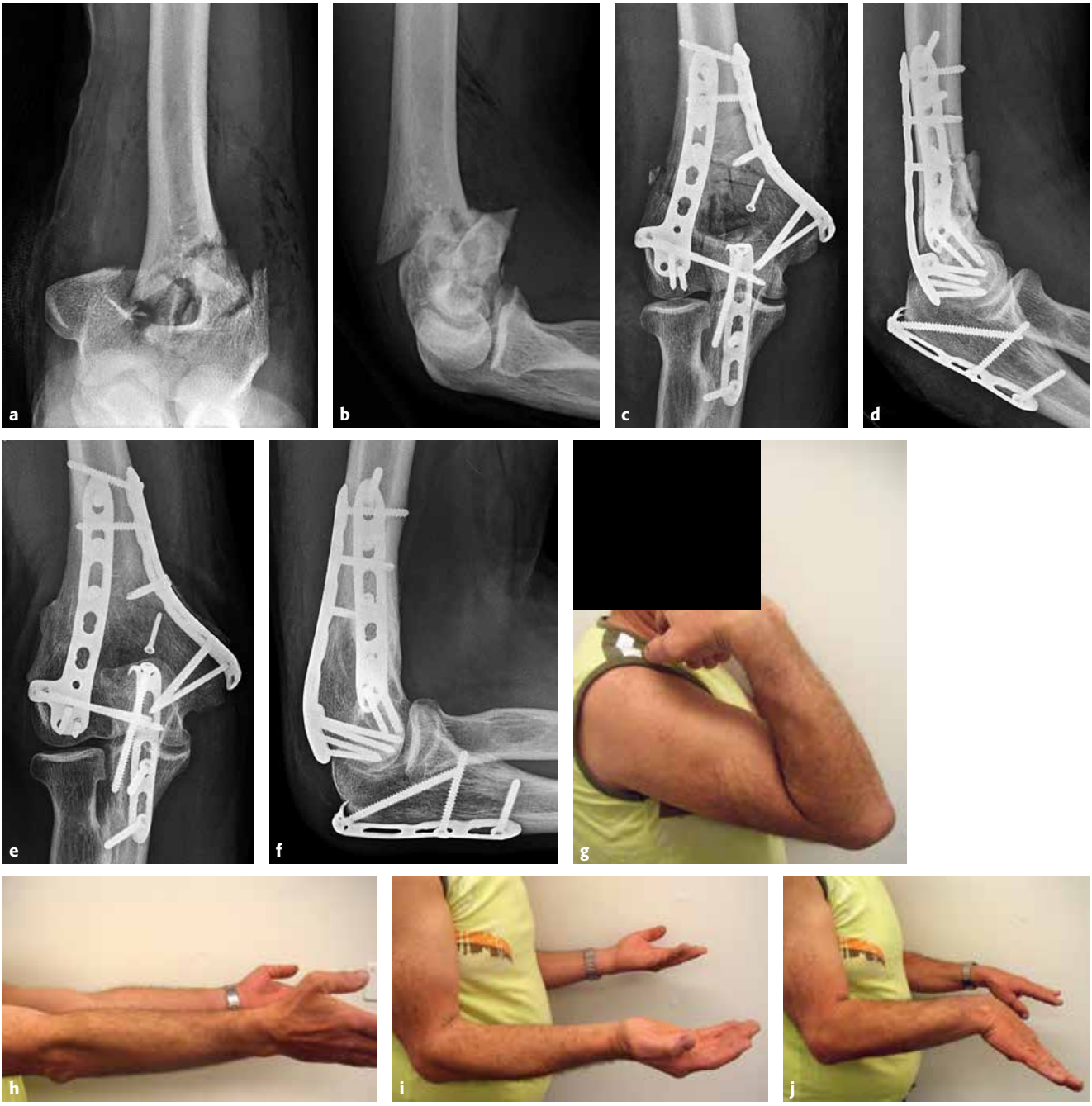

Fig 3.3.4-32a–j A 13C3 fracture treated with a compression technique with locking compression plate (LCP).
a–b A 54-year-old man, fell from a motorbike, sustained a dorsal grade 2 open distal multifragmented intraarticular humeral fracture.
c–d Dorsal approach was used with olecranon osteotomy. The anatomically reduced and compressed articular part is fixed with locking head screws (LHS) functioning on one hand as position screws for the articular fragments and on the other as fixation screws for the plate, providing angular stability to overcome secondary flexion collapse. The dorsal and ulnar aspects of the metaphysis (simple fracture lines) are compressed over the plate using a conventional cortical screw in both the most proximal plate holes. Definitive diaphyseal plate fixation is carried out with conventional screws on the ulnar side, where the plate fits perfectly to the bone, and two LHS on the radial side, where the plate had a slight distance to the bone surface.
e–f After 6 months, healing occurred directly (articular part) and indirectly with callus at the anterior metaphysis.
g–j One year follow-up images.

Minimal invasive plating (MIPO) of a simple type A fracture: Metaphyseal and diaphyseal fractures with simple fracture patterns can be treated successfully using MIPO (**Fig 3.3.4-33**). The length of the incisions in the soft tissues can be minimized to preserve the blood supply of the skin and underlying tissues as much as possible. It is crucial to achieve a perfect, anatomical reduction of the simple fracture. Several reduction techniques can help achieve this goal. Pointed reduction forceps correctly placed through small incisions, in combination with percutaneous lag screws, help obtain a gap-free reduction prior to the insertion and fixation of the plate. Conventional screws, one each at both plate ends, are first used to approximate the plate to the bone. Locking head screws are added percutaneously for definitive fixation. An alternative technique is to reduce the fracture but not use lag screws. A longer plate and fewer screws are used to provide more flexible fixation, producing relative stability and secondary bone healing with callus formation.

Experience with MIPO has shown that the quality of reduction is the most important factor for successful and timely healing.

Combining conventional screws and LHSs in one (and the same) fracture fragment ("hybrid" application) must follow one simple rule: do not tighten a conventional screw if an LHS is already inserted and locked.

This means that either the conventional screws are inserted first, followed by the LHSs, or an already inserted and locked LHS must be disengaged (turned back until the screw head is not engaged in the threaded plate hole) before a conventional screw is added in the same fragment. This technique is used in MIPO to approximate an inserted and fixed plate (with LHSs) that stands off the bone putting tension on the adjacent soft tissues or wound.

4.5 Relative stability with the locking compression plate

Multifragmentary metaphyseal and diaphyseal fractures are best treated using relative stability because:

- Anatomical reduction and interfragmentary compression cannot be achieved.
- Direct reduction damages the local vascularity of bone and soft tissue.
- Relative stability allows functional rehabilitation and results in healing of multifragmentary fractures by callus formation.

Fig 3.3.4-33a–o A 42B2 distal fracture treated with a compression technique with locking compression plate (LCP) in "hybrid" application.
a A 55-year-old man suffered a ski accident with a closed injury. A distal metadiaphyseal fracture of the tibia was present close to the joint.
b–c A minimally invasive plate osteosynthesis technique kept the iatrogenic damage to the soft tissues minimal.

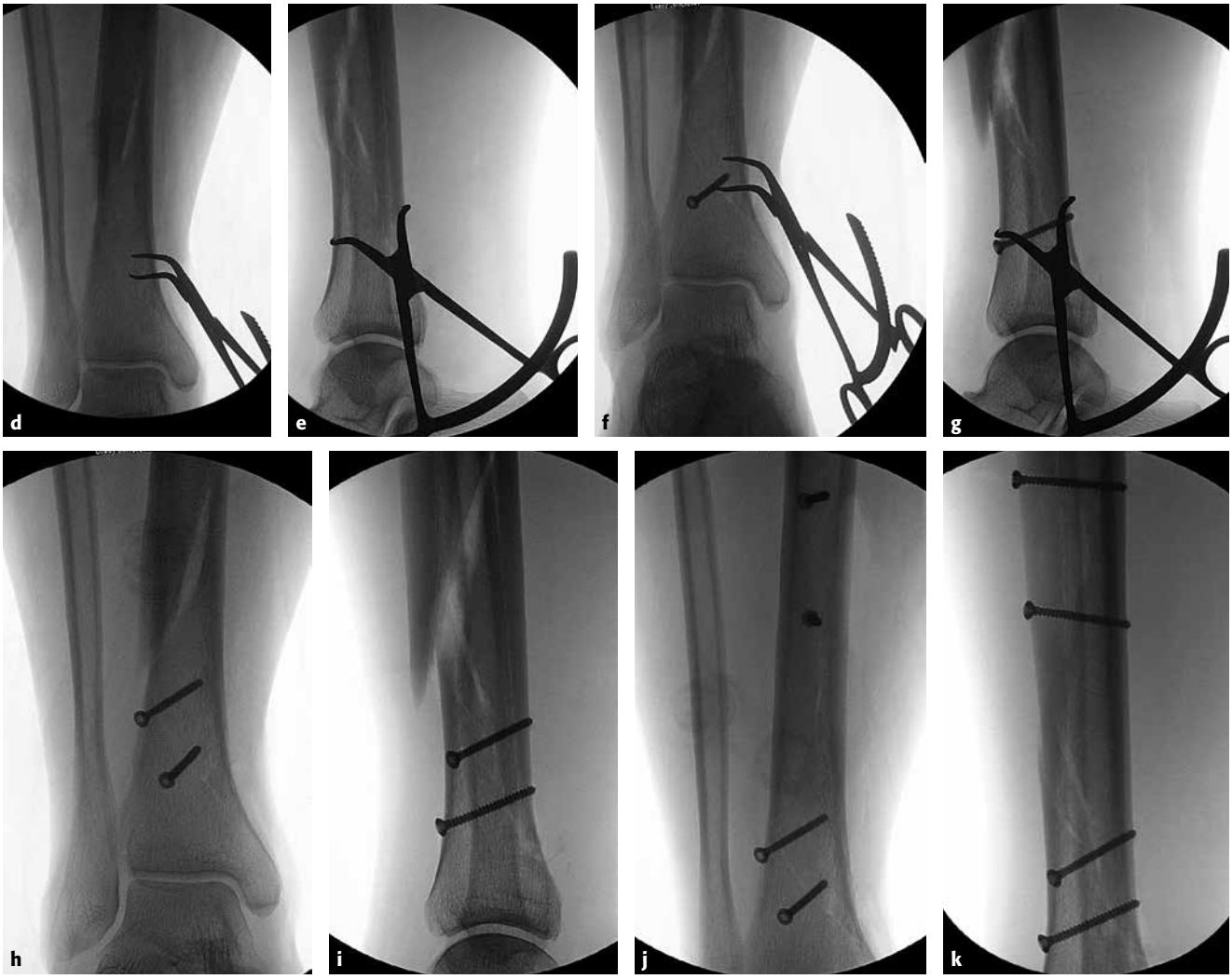

Fig 3.3.4-33a–o (**cont**) A 42B2 distal fracture treated with a compression technique with locking compression plate (LCP) in "hybrid" application.
d–g Most important was the reduction of the two simple fracture planes between the two main and the long butterfly fragments. One option is to use a pointed reduction forceps inserted by two stab incisions in ideal position.
h–k The gap-free (ideally: anatomical) reduction can be retained by percutaneously applied "retention" screws, at least one per fracture plane. These screws allow for removing the reduction forceps which will be a hindrance for plate insertion.

Fig 3.3.4-33a–o (**cont**) A 42B2 distal fracture treated with a compression technique with locking compression plate (LCP) in "hybrid" application.

l–n Then the inserted plate preliminary fixed distally with a conventional screw to approximate the plate close to the bone. Next, another conventional screw is applied at the proximal end of the plate which has to be centered perfectly in the lateral view. The well-aligned plate then is definitively fixed to the bone using LHS distally ("subbicortical" in the syndesmotic region) and proximally (bicortical). The one conventional screw at the proximal end of the plate is preferred to a LHS because it guarantees a tight fit of the plate to the bone, not irritating the soft tissues and it reduces the local stress to the bone thus decreasing the risk of later periimplant fracture.

o One year follow-up imaging.

By splinting fractures with plates, three main factors influence the stability of the fixation and the loading conditions of the plate-bone construct (**Table 3.3.4-3**, **Fig 3.3.4-34**):

- Length of the plate
- Working length of the plate
- Number, position, and design of the screws [6, 20]

4.5.1 Length of the plate

Bridge plate constructs are often long plates with few screws used to produce relative stability. A long plate improves the moment arm of the screws. This leads to a low pull out force acting on each screw which is especially helpful in osteoporotic bone (**Video 3.3.4-1b–c**). Utilizing a minimal invasive technique with subcutaneous or submuscular plate insertion, a long plate can be used without the need of additional soft-tissue dissection and devascularization. In general, the length of a plate depends upon the length of the fracture zone.

Empirically, the plate length should be two to three times the length of the overall fracture length in multifragmentary fractures and eight to ten times longer in spiral, oblique, or transverse fractures.

4.5.2 Working length of the plate

To avoid premature failure of a locking plate, the working length (length between the two screws bordering the fracture zone) should be optimized [20]. For a simple fracture pattern, when the gap size is small (< 1 mm) increasing the working length of a plate will minimize the chances of plate failure as the deformation of the plate under load (strain) will be small and distributed over a longer area and there will be load sharing with the fracture (**Fig 3.3.4-35**). In a situation with a short working length of the plate (no hole free at fracture level), the construct is stiff and the bone does not contact on the opposite side of the plate even under moderate loading. Load-sharing does not take place and maximal strain develops in the middle of the plate (**Fig 3.3.4-36**, **Video 3.3.4-5**). A longer working length of the plate decreases the stiffness of the construct and allows the small fracture gap on the opposite side of the plate to close, even with moderate loading. This brings the main bone segments into direct contact (**Video 3.3.4-6**). By further loading, the axial forces will be directly transmitted from one to the other main fragment without further strain on the plate (load sharing) (**Fig 3.3.4-37**).

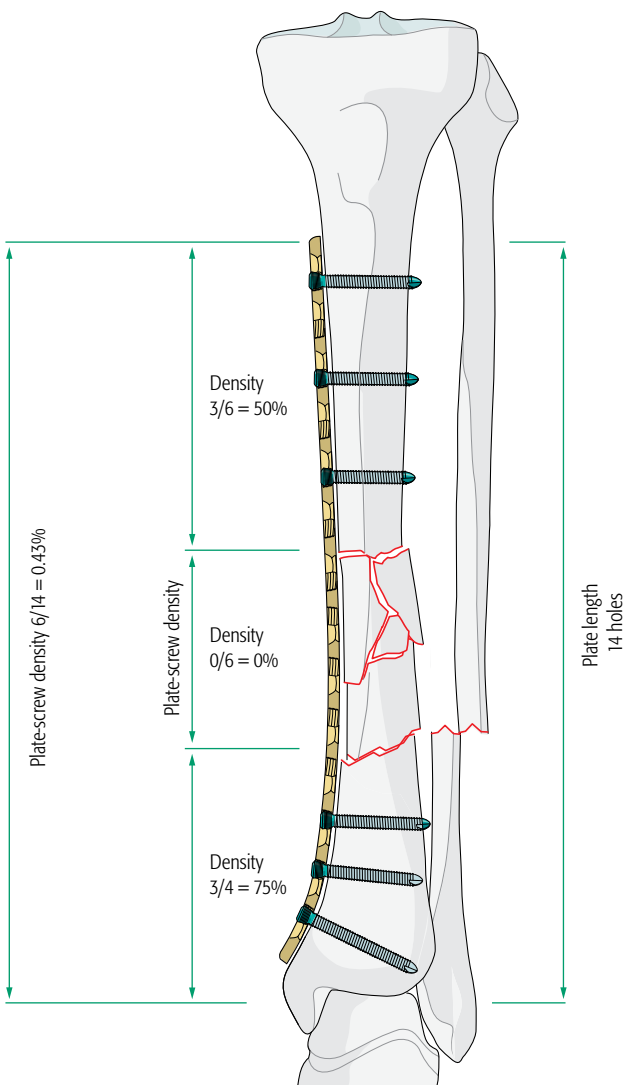

Fig 3.3.4-34 Importance of the plate-span ratio and plate-screw density in bridge plating technique. The schematic drawing shows a mechanically sound fixation of a multifragmentary diaphyseal fracture in the lower leg. The ratio between the length of the plate and the length of the fracture is known as the plate-span ratio. In this case, the ratio is high enough, ie, approximately 3, indicating that the plate is three times longer than the overall fracture segment. The plate-screw density is shown for all the three bone segments. The proximal main fragment has a plate-screw density of 0.5 (three of six holes occupied); the segment over the fracture has a density of 0 (none of four holes occupied); and the distal main fragment has a density of 0.75 (three of four holes occupied). The higher plate-screw density in the distal main fragment has to be accepted, since for anatomical reasons there is no way of reducing it. The overall plate-screw density for the construct in this example is 0.43 (six screws in a 14-hole plate).



Fig 3.3.4-35a–c Short and long plate working length in a 1 mm gap model. The mean maximal von Mises stress in a 12-hole LCP 4.5 as a function of the bridging length (0–4 plate holes free) in a 1 mm gap model load-sharing situation (Karl Stoffel, MD, personal communication in 2003) **[21]**.

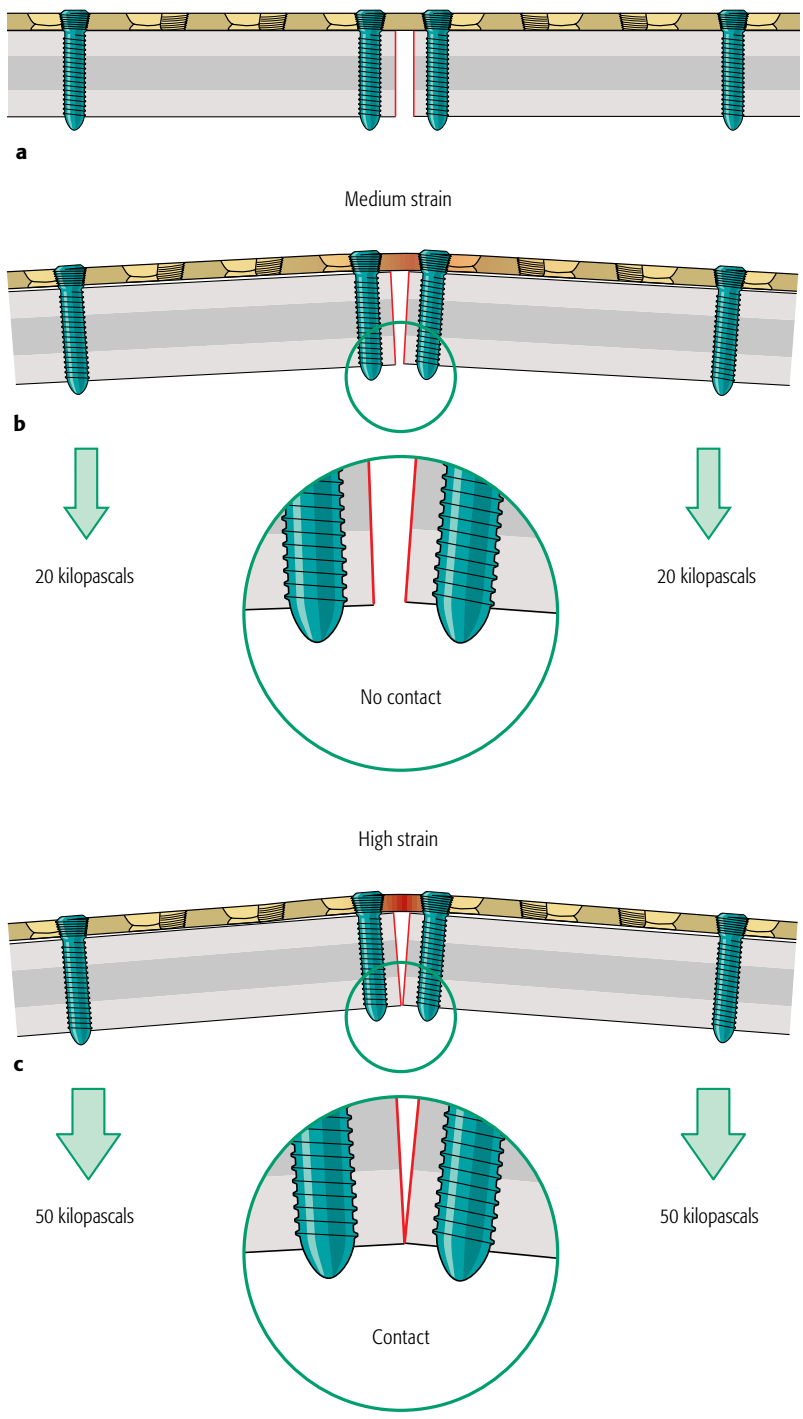

Fig 3.3.4-36a–c Short plate working length in a small gap model.
a In a situation with shortest working length of the plate (no hole free at fracture level) the construct is stiff.
b Therefore no bone contact on the opposite side of the plate will occur even in moderate loading.
c Load sharing only takes place at high strain. This situation must be avoided as plate failure before fracture union is likely.

Video 3.3.4-5 High strain environment with small fracture gap.

Video 3.3.4-6 Low strain environment with small fracture gap.

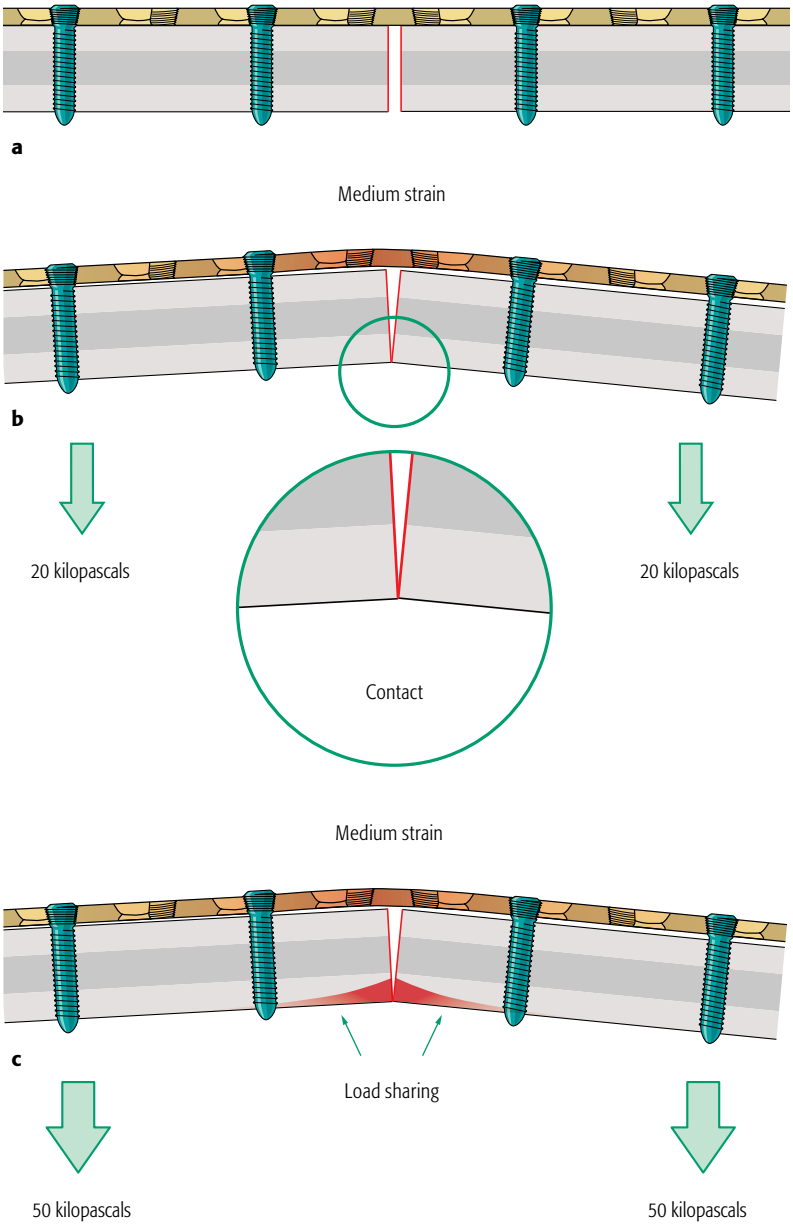

Fig 3.3.4-37a–c Long plate working length in small gap model.

a The longer working length segment at the fracture level decreases the stiffness of the construct.

b Even by moderate loading, the small fracture gap is closed on the opposite side of the plate quite easily which brings the main bone segments into direct contact.

c By further loading the axial forces will be directly transmitted from one to the other main fragment without further strain onto the plate (load sharing).

When the gap size is large, which is present in multifragmentary fractures or poorly reduced simple fractures, no direct bone contact occurs even under high load. Therefore, load sharing, which helps protect the plate against failure, does not happen. The strain on the plate is high under loading and even gets higher when the working length of the plate is increased by leaving more plate holes free at the fracture level (**Fig 3.3.4-38**). The lowest strain in the plate occurs when the screws are as close as practical to the fracture [21] (**Fig 3.3.4-39**). By placing the screws farther from the fracture, higher strain occurs in the free plate segment as well as in the screws (especially close to the fracture) and the screw-bone interface (**Fig 3.3.4-40**). Implant failure becomes more common.

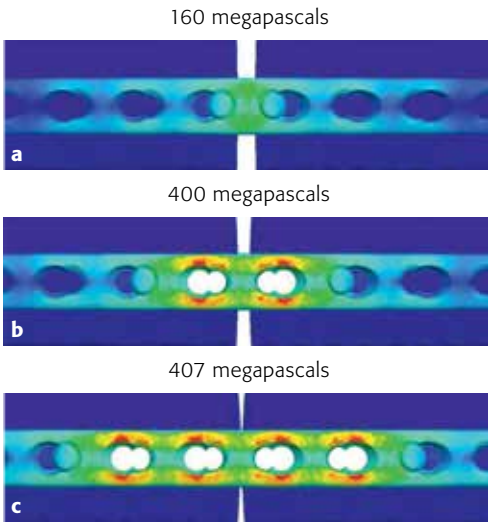

Fig 3.3.4-38a–c Short and long plate working length in 6 mm gap model. The mean maximal von Mises stress in a 12-hole LCP 4.5 as a function of the bridging length (0–4 plate holes free) in a 6 mm gap model. No load-sharing situation (Karl Stoffel, MD, personal communication in 2003) **[21]**.

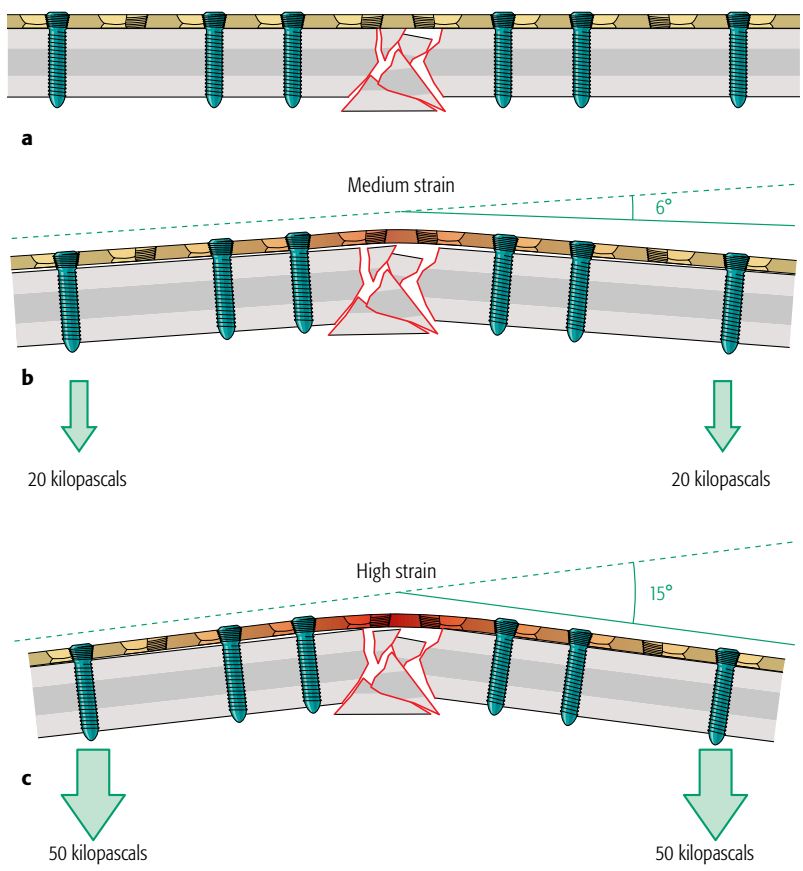

Fig 3.3.4-39a–c Short plate working length in a comminuted fracture or large gap model. The drawn angles are intentionally oversized for better graphical demonstration and understanding.

a In comminuted fractures there will never be direct contact of the main fragments on the opposite side of the plate (no load sharing). Placing the screws as close to the fracture as possible will reduce the flexibility of the construct to a desired limit.

b Under minimal loading (20 kilopounds, simulating partial weight bearing), the plate experiences minimal deformation.

c Under higher loading (50 kilopounds, simulating half-body weight), the plate experiences more deformation.

4.5.3 Technique of bridge plate application using locking compression plate

Conventional or locking screws can be used successfully with LCP to produce a bridge plate and relative stability. In the upper extremity, especially the humerus, where high torsional loads are expected, LHSs can be added for better resistance against rotational forces. In lower extremity injuries, minimally invasive plating techniques have become standard in the last two decades.

Locking head screws provide several advantages when short segments of bone need to be fixed and bone quality is poor, reducing the pull-out strength of conventional screws. For metaphyseal fixation, some of the new plate systems provide a guide block for the periarticular part of the plate. This ensures perfect screw trajectory (important for tight locking) in soft metaphyseal bone and an aiming jig for easier percutaneous screw application in diaphyseal bone. In good quality diaphyseal bone, conventional screws are usually effective (**Fig 3.3.4-41**). With an extremely long multifragmentary zone, even when the screws are placed as close to the fracture as possible, fixation may be too flexible with only a single plate. This results in a high-strain environment that leads to plate deformation or delayed healing or nonunion. In such a situation, it might be necessary to add a second plate on the opposite side of the bone (or alternatively: an external fixator until healing) (**Fig 3.3.4-42**).

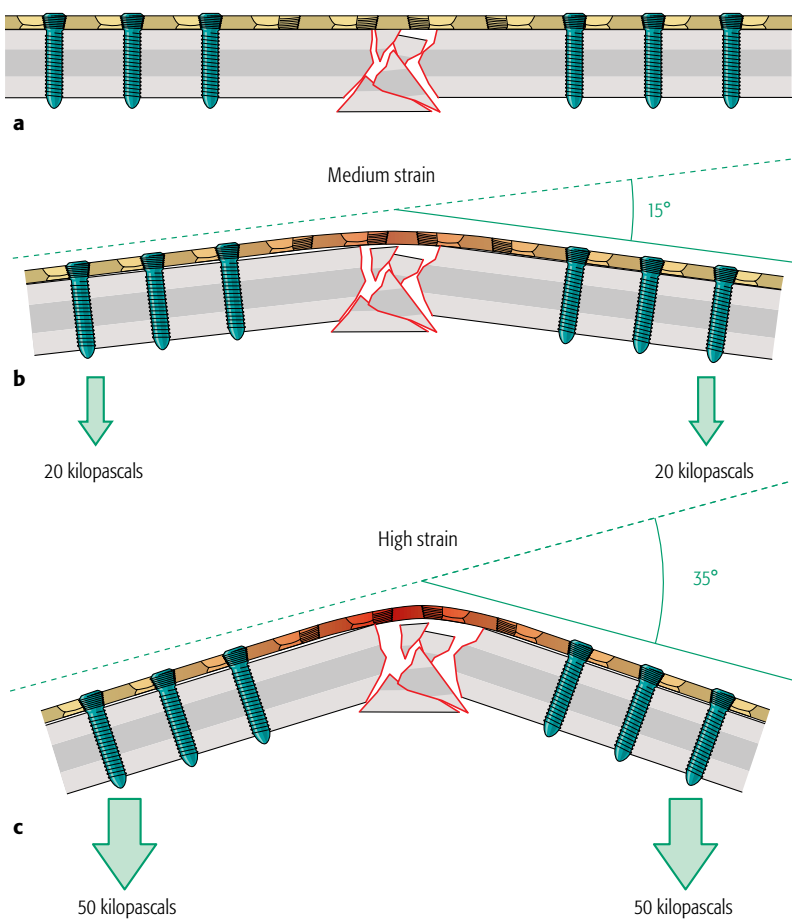

Fig 3.3.4-40a–c Long plate working length in a comminuted fracture or large gap model. The drawn angles are intentionally oversized for better graphical demonstration and understanding.

a By placing the screws farther from the fracture (compared to **Fig 3.3.4-39**), the construct becomes more flexible.

b Under minimal loading (20 kilopounds, simulating partial weight bearing), the plate becomes more elastically deformed compared to a situation with closer screws. It will be similarly deformed as in a situation with closer screws and higher loading, as shown in **Fig 3.3.4-39b**.

c Under higher loading (50 kilopounds, simulating half-body weight), the plate will be deformed much more and the mechanical axis will be even more separated from the plate resulting in more eccentrical loading. This results in even higher stress in the free plate segment as well as in the screws (especially those close to the fracture) which cannot be compensated with increased bridging length. Implant failure becomes more common. Therefore, the screws should be inserted as close as possible to the comminution.

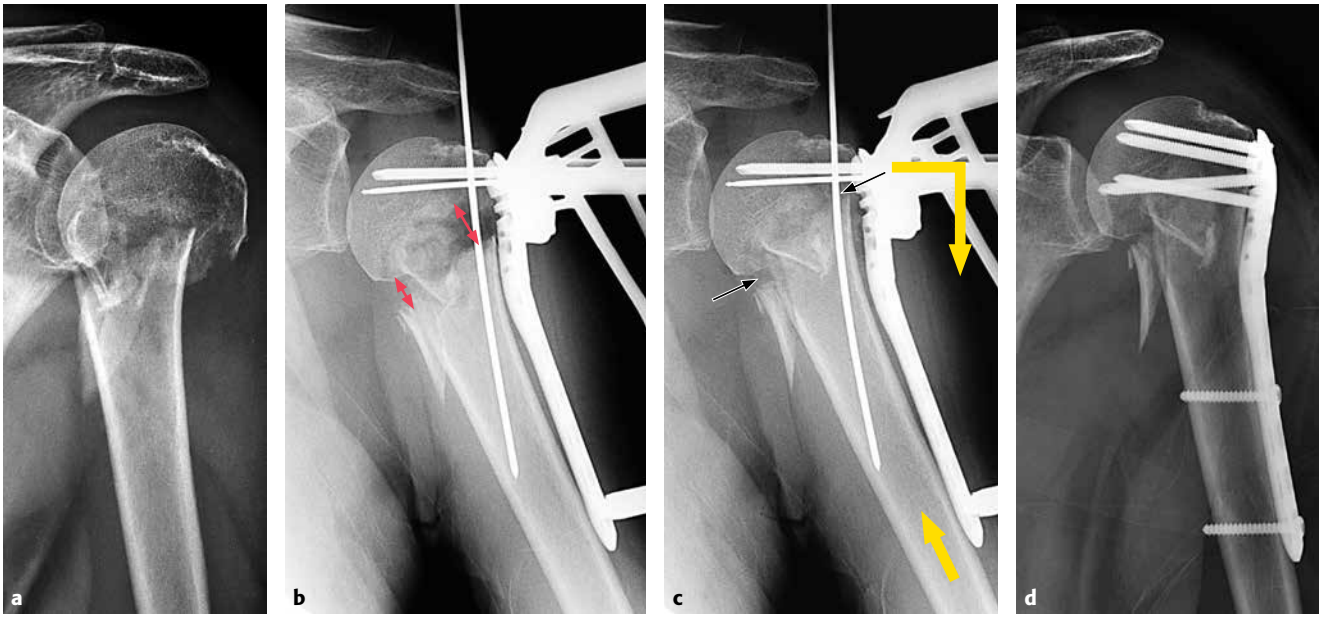

Fig 3.3.4-41a–e An 11A3 fracture treated with a bridging technique with PHILOS plate (MIPO).

a An 84-year-old woman fell during skiing and sustained a subcapital humeral fracture with medial comminution.

b After axial alignment and K-wire fixation, a PHILOS (5-hole plate) is inserted through a delta-split approach with the aiming jig. Preliminary proximal fixation is performed using a K-wire and one locking head screw. It is important to not fix the fracture in distraction (red arrows).

c This must be reduced by slightly shortening the limb manually over the jig and the elbow (broad yellow arrows). Despite the medial comminution some buttress (anterior, posterior and/or central) can be achieved by this reduction manoeuvre (black arrows).

d Only then are the diaphyseal screws placed. In good bone, as in this case with appropriate thickness of the cortex, conventional screws are sufficient. Using a 5-hole plate with a longer lever arm will allow the surgeon to use only two screws in the diaphysis. An additional screw close to the fracture in the distal fragment will provide more stability and reduce the risk of screw pull out.

e One year follow-up image.

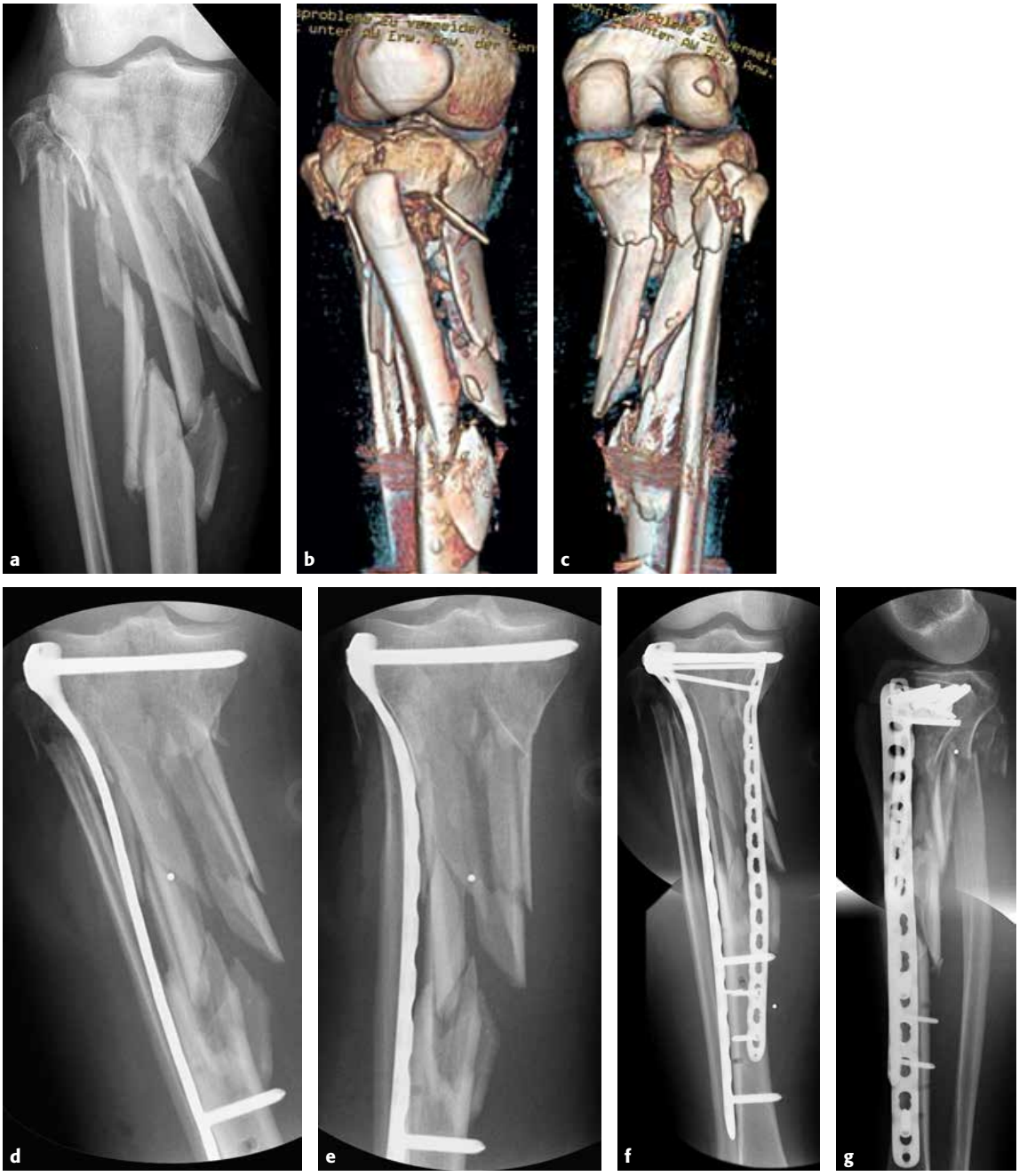

Fig 3.3.4-42a–k A 41C3.3 fracture treated with a bridging technique with two locking compression plates (LCP).

a A 36-year-old polytraumatized woman with bilateral proximal intraarticular tibial fractures after suicide jump off a bridge. She has a closed fracture which also manifests a compartment syndrome.

b–c Immediate knee-bridging external fixator and fasciotomy was followed by further imaging with computed tomography. Definitive stabilization on day 8 with minimal extraarticular proximal access medially and laterally.

d–g After reduction of the articular end block with K-wires as joysticks and a large King tong reduction forceps, the long LCP 4.5 L-plate was inserted submuscularly laterally and fixed with LHS proximally and percutaneously distally, as close as possible to the comminution zone. This construct is very flexible. This is captured intraoperatively and documented under image intensifier manually applying varus and valgus bending moments. This lateral plate alone could never withstand the physiological bending moments during the healing phase. A second medial bridging plate (LCP 3.5 straight, slightly contoured) is inserted percutaneously as well to protect the fracture from varus collapse. Due to the long-working length of these two plates and the comminution zone, relative stability is provided with indirect healing by callus formation.

Fig 3.3.4-42a–k (**cont**) A 41C3.3 fracture treated with a bridging technique with two locking compression plates (LCP).
h–k Two-year follow-up images.

4.6 Locking compression plate for both absolute and relative stability

Combining two principles with one plate is reserved to combination type fractures in one bone, where one fracture is ideally fixed with absolute stability and the other fracture is best treated with relative stability. Two typical situations are:

- Articular fracture in combination with a multifragmentary metaphyseal fracture. These type C2 or type C3 fractures require anatomical reduction of the articular fracture and fixation with absolute stability while the multifragmentary metaphyseal (or diaphyseal) component is ideally bridged with minimal soft-tissue dissection and fixed with relative stability. Depending upon bone quality, the approach and reduction technique, LHSs alone or in combination with conventional screws may be used (**Fig 3.3.4-43**).
- Segmental metaphyseal-diaphyseal fracture with one simple and one multifragmentary fracture in a single bone. The simple fracture requires anatomical reduction and fixation with absolute stability while the same plate is used to bridge the multifragmentary part, providing relative stability (**Fig 3.3.4-44**).

The two different principles—absolute and relative stability—are incompatible in the same fracture zone, so these cases require careful preoperative planning and application of the AO principles. The adaptability of the LCP makes it an excellent implant for this type of complex fracture fixation.

4.7 Failure modes of locking plates

The LCP is a successful implant when used correctly but no implant has a 100% success rate and no fracture has a 100% union rate. The surgeon must be aware that because of the mechanical couple between the plate and the screw, the LCP has a different mode of failure than plates fixed with conventional screws. Cut out of the screws from the bone is less common and the risk of this complication can be reduced further by careful application of the plate using the principles and techniques described above. In general, monocortical screws should be avoided as should eccentric positioning of the plate on the diaphysis.

If fracture healing is delayed, there may be prolonged load bearing through the implant leading to metal fatigue with bending or breakage of the plate and/or breakage of the screws. The screws typically break at the junction between the plate and screw. Because all the screws need to fail simultaneously, cut out of the screws is less common. However, in osteoporotic bone or in patients with neuropathy, eg, those with diabetes, simultaneous failure of all screws at the bone-screw interface can result in severe instability, gross movement at the fracture site, and massive osteolysis due to bone destruction from the fixed screws moving like a "windscreen wiper" through the bone. Surgeons must be aware of this mode of failure as revision surgery can be difficult because of bone loss. If there are early signs of failure with osteolysis around the locking screws, patients must be followed up under close outpatient review and early revision surgery considered.

The second mode of failure that is less common with conventional screws is penetration of screw tips into the joint. Fixation of periarticular fractures in osteoporotic bone is challenging and the LCP is often the best implant. However, some implant loosening, loss of reduction and impaction (collapse) in osteoporotic, metaphyseal bone is common. In this situation, conventional screws placed in the subchondral bone often back out. However, this cannot happen with LHSs and so the tips of the screws may penetrate the joint. The proximal humerus and distal radius are the two most common sites for this complication. Frequently, the tips of the screw only penetrate 1–2 mm and remain within the articular cartilage and no damage ensues. However, these cases must be followed up closely and if the patient develops symptoms, such as pain or clicking, or radiological signs of chondrolysis, urgent removal of the screw is required. Remember, patients with neuropathy may not complain of pain.

Surgeons must also be aware that implant removal can be more difficult if the LHS is jammed in the thread hole of the plate. The risk of this problem can be reduced by the use of a torque-limiting screwdriver (which is mandatory) and ensuring that the correct guides are used so the screw joins the plate at the correct angle. The problem with jammed screws appears to be much more common with titanium implants as their biocompatibility allows bone ingrowth between the screw thread and the plate thread. Surgeons planning to remove LCPs must be aware of the different techniques available for removing jammed screws and have appropriate instruments available before surgery.

Fig 3.3.4-43a–g A 41C3.3 fracture treated with a combination technique with locking compression plate (LCP).

a–b A 39-year-old ski racer involved in a high-speed injury, with closed comminuted proximal tibial fracture with extension to midshaft. The patient also manifested a compartment syndrome. Initial step was a knee-bridging external fixator and fasciotomy.

c–e Main reconstruction with anatomical reduction and compression fixation of the proximal (articular) part using a lateral standard approach, followed by submuscular insertion of a long LCP-PLT. Proximal fixation with long "subbicortical" locking head screw (LHS) keeping the articular fragments in position as well as providing angular stability to prevent later medial collapse with varus deformity. Distally, LHS were applied percutaneously after final torsional and axial alignment in the sagittal plane has been checked clinically and under image intensifier. Primary bone healing occurred fast in the articular part; secondary healing was delayed but completed without further intervention.

f–g After 15 months the remodeling process was nearly finished.

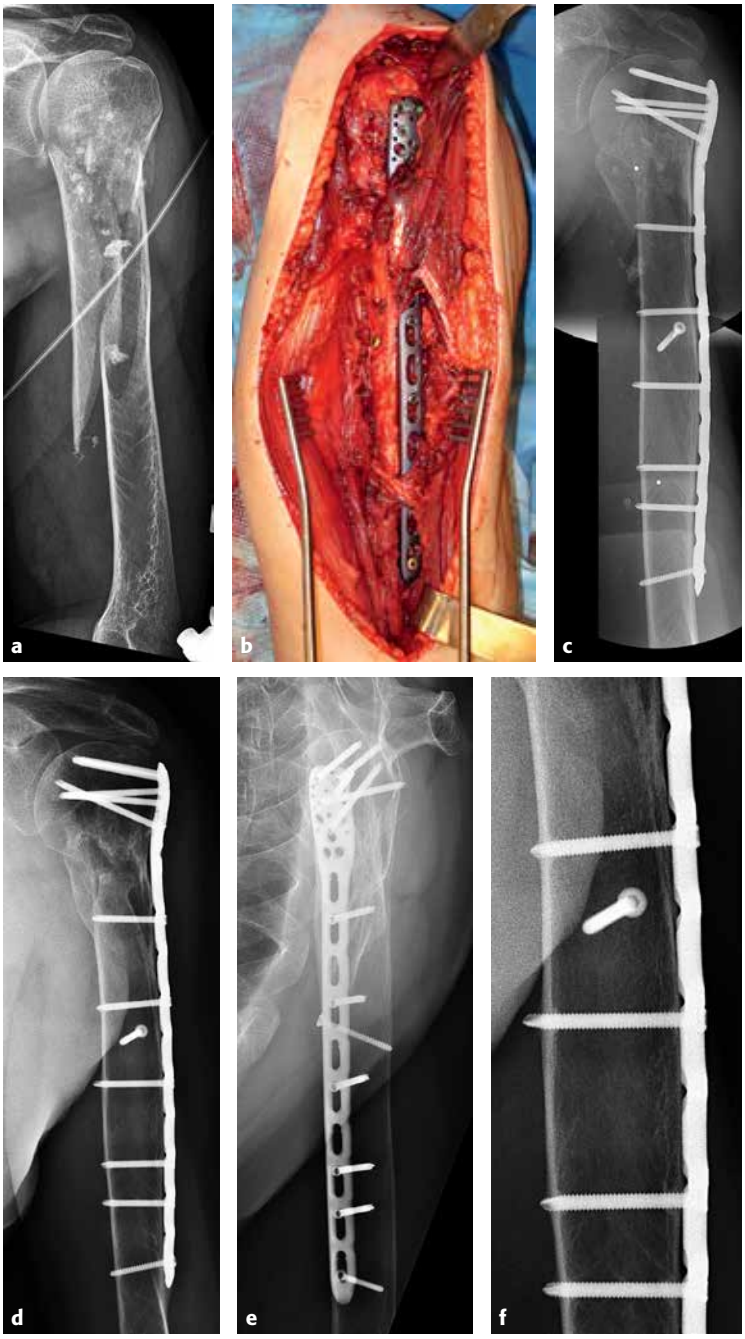

Fig 3.3.4-44a–f 11A2 and 12A1 fractures treated with a combination technique with locking compression plate (LCP).

a A 67-year-old man on a bicycle was hit by a car and sustained a segmental humeral fracture: subcapital multifragmentary fracture in combination with a simple torsional midshaft fracture. Severe osteoporosis was visible on x-rays.

b–c High stability was provided by perfect reduction of this long spiral fracture leading to a load-sharing construct. An open approach was chosen preserving the deltoid attachment and some perforating vessels in the splinted brachialis muscle. An anatomical reduction was achieved distally, retention by a lag screw (carefully tightened) and neutralization by a long PHILOS plate was performed. Due to the thin cortex, most screws used were bicortical locking head screw (LHS) except the most distal one. This cortex screw should reduce the stress on the bone at that level preventing a periimplant fracture in the future. The proximal fracture multifragmented block was biologically aligned and bridged with the plate using long LHSs in the head.

d–f After 2.5 years healing was uneventful, with primary healing distally and secondary osteopenia below the plate (stress shielding) and secondary bone healing with callus at the subcapital level.

5 Summary

The development and introduction of locking plate technology in the last 20 years has revolutionized operative fracture care. The use of LCPs requires a clear understanding of the principles governing their function. Use of angular stability, MIPO techniques, and hybrid screws allow applications that provide the optimum fracture stability for healing. Careful preoperative planning and precise surgical execution with LCPs using both conventional screws and LHSs provide correct plate length, working length, and screw type for the best fracture healing outcomes [22].

Classic references | Review references

6 References

1. **Perren SM.** Basic aspects of internal fixation. In: Müller ME, Allgöwer M, Schneider R, et al. eds. *Manual of Internal Fixation*. Berlin Heidelberg New York: Springer Verlag; 1991:1–112.
2. **Perren SM, Buchanan J.** Basic concepts relevant to the design and development of the point contact fixator (PC-Fix). *Injury.* 1995;26(Suppl 2):1–4.
3. **Tepic S, Perren SM.** The biomechanics of the PC-Fix Internal fixator. *Injury.* 1995; 26(Suppl 2):5–10.
4. **Schütz M, Südkamp NP.** Revolution in plate osteosynthesis: new internal fixator systems. *J Orthop Sci.* 2003;8(2):252–258.
5. **Sommer C, Gautier E, Müller M, et al.** First clinical results of the Locking Compression Plate (LCP). *Injury.* 2003 Nov;34 Suppl 2:B43–54.
6. **Gautier E, Sommer C.** Guidelines for the clinical application of the LCP. *Injury.* 2003 Nov;34 Suppl 2:B63–76.
7. **Wagner M, Frigg R.** *AO Manual of Fracture Management, Internal Fixators, Concept and Cases Using LCP and LISS.* 1st ed. Stuttgart: Thieme; 2006.
8. **Bottlang M, Doornink J, Byrd GD, et al.** A nonlocking end screw can decrease fracture risk caused by locked plating in the osteoporotic diaphysis. *J Bone Joint Surg Am.* 2009 Mar 01;91(3):620–627.
9. **Gardner MJ, Griffith MH, Demetrakopoulos D, et al.** Hybrid locked plating of osteoporotic fractures of the humerus. *J Bone Joint Surg Am.* 2006 Sep;88(9):1962–1967.
10. **Stoffel K, Lorenz KU, Kuster MS.** Biomechanical considerations in plate osteosynthesis: the effect of plate-to-bone compression with and without angular screw stability. *J Orthop Trauma.* 2007 Jul;21(6):362–368.
11. **Staubli AE, De Simoni C, Babst R, et al.** TomoFix: a new LCP-concept for open wedge osteotomy of the medial proximal tibia—early results in 92 cases. *Injury.* 2003 Nov;34 Suppl 2:B55–B62.
12. **Egol KA, Kubiak EN, Fulkerson E, et al.** Biomechanics of locked plates and screws. *J Orthop Trauma.* 2004 Sep;18(8):488–493.
13. **Sommer C, Babst R, Müller M, et al.** Locking compression plate loosening and plate breakage: a report of four cases. *J Orthop Trauma.* 2004 Sep;18(8):571–577.
14. **Haidukewych GJ, Ricci W.** Locked plating in orthopaedic trauma: a clinical update. *J Am Acad Orthop Surg.* 2008 Jun;16(6):347–355.
15. **Tan SL, Balogh ZJ.** Indications and limitations of locked plating. *Injury.* 2009 Jul;40(7):683–691.
16. **Hunt SB, Buckley RE.** Locking plates: a current concepts review of technique and indications for use. *Acta Chir Orthop Traumatol Cech.* 2013;80(3):185–191.
17. **Bonyun M, Nauth A, Egol KA, et al.** Hot topics in biomechanically directed fracture fixation. *J Orthop Trauma.* 2014;28 Suppl 1:S32–S35.
18. **Takemoto RC, Sugi MT, Kummer F, et al.** The effects of locked and unlocked neutralization plates on load bearing of fractures fixed with a lag screw. *J Orthop Trauma.* 2012 Sep;26(9):519–522.
19. **Yi JW, Oh JK, Han BS, et al.** Healing process after rigid plate fixation of humeral shaft fractures revisited. *Arch Orthop Trauma Surg.* 2013 Jun;133(6):811–817.
20. **Claes L.** Biomechanical principles and mechanobiologic aspects of flexible and locked plating. *J Orthop Trauma.* 2011 Feb;;2 (Suppl 1:S4-S7.
21. **Stoffel K, Dieter U, Stachowiak G, et al.** Biomechanical testing of the LCP—how can stability in locked internal fixators be controlled? *Injury.* 2003 Nov;34 Suppl 2:B11-19.
22. **Ricci WM.** Use of locking plates in orthopaedic trauma surgery. *JBJS Rev.* 2015 Mar 17;3(3):pii: 01874474-201503030-00003.

7 Acknowledgments

We thank several surgical leaders for helping us to understand and to apply locking plate technology: Thomas Rüedi, Martin Altmann, Röbi Frigg, Emanuel Gautier, and Karl Stoffel. We also thank Michael Wagner and Michael Schütz for their contributions to this chapter in the second edition of the *AO Principles of Fracture Management*.

Section

4

General topics

Section 4
General topics

4.1	Polytrauma: pathophysiology, priorities, and management Peter V Giannoudis	311
4.2	Open fractures Rami Mosheiff	331
4.3	Soft-tissue loss: principles of management Yves Harder	357
4.4	Pediatric fractures Theddy Slongo, James Hunter	379
4.5	Antibiotic prophylaxis Susan Snape	421
4.6	Thromboembolic prophylaxis Hans J Kreder	429
4.7	Postoperative management: general considerations Liu Fan, John Arraf	437
4.8	Fragility fractures and orthogeriatric care Michael Blauth, Markus Gosch, Thomas J Luger, Hans Peter Dimai, Stephen L Kates	451
4.9	Imaging and radiation hazards Chanakarn Phornphutkul	481

4.1 Polytrauma: pathophysiology, priorities, and management

Peter V Giannoudis

1 Definition

Polytrauma has been defined as "a syndrome of multiple injuries exceeding an Injury Severity Score (ISS) of 16 with sequential systemic reactions that may lead to dysfunction or failure of remote organs and vital systems that have not been directly injured". However, an international consensus in 2014 [1] suggested that polytrauma be redefined as the presence of two injuries that are greater or equal to 3 on the Abbreviated Injury Scale (AIS) and one or more of the following additional conditions:

- Hypotension (systolic blood pressure ≤ 90 mm Hg)
- Unconsciousness (Glasgow coma scale [GCS] score ≤ 8)
- Acidosis (base deficit ≤ 6.0)
- Coagulopathy (partial thromboplastin time ≥ 50 seconds or International Normalized Ratio ≥ 1.4)
- Age (70 ≥ years)

2 Importance of fractures

At the beginning of the 20th century surgical stabilization of long-bone fractures in multiple-injured patients was not routinely performed. The major reason behind this approach was the fear of fat embolism syndrome (release of fat and intramedullary [IM] contents into the peripheral circulation). Nowadays, the consequences of this syndrome are believed to be secondary to the breakdown of fat to free fatty acids, the release of toxic mediators, and subsequent immunoinflammatory reactions leading to an increased vascular permeability. This results in alveolar hemorrhage, edema, extravasation of polymorphonuclear leukocytes, and the development of respiratory insufficiency (adult respiratory distress syndrome [ARDS]) [2].

The first evidence for the beneficial effects of long-bone fracture stabilization became available from World War I with use of the Thomas splint for the management of femoral shaft fractures resulting in improved survival rates. Subsequently, the advent of antibiotics together with advances in intensive care and anesthesia, implant design, and the implementation of standardized fracture fixation techniques by the AO supported a more operative approach for fracture fixation. However, for many decades, the philosophy prevailed that the injured patient was "too sick to operate on" and patients were treated with skeletal traction and enforced bed rest. However, in the early 1980s a prospective randomized study by Bone et al [3] demonstrated the benefits of early femoral fracture fixation, with a reduction in the incidence of respiratory failure leading to a reduced length of stay in intensive care and in hospital. This study set the foundation for the philosophy of early total care (ETC) that subsequently prevailed. Consequently, the previously held belief among surgeons that the patient was too sick to operate on was now replaced with the opposite view that the patient was "too sick not to operate on". Early total care became the optimum treatment in surgery for fracture fixation and further developments in intensive care medicine reinforced early fracture fixation in patients with polytrauma.

The ETC strategy was widely used but several reports in the literature described adverse outcome after ETC in some groups of patients with an increased incidence of ARDS and multiple organ failure. In response to these observations, the concept of damage-control orthopedics (DCO) for the management of multiple-injured patients was developed. This approach was based on the principle of "damage limitation" [4].

Early total care and DCO became a hot topic of discussion between European and North American surgeons as to which multiple-injured patient would benefit most from either surgical strategy.

Recently, the concept of early appropriate care was introduced to emphasize that fracture fixation should not take place during resuscitation but should be delayed a short time until the patient is fully resuscitated with a return to normal physiological parameters. Early appropriate care also considers the surgical fixation of unstable pelvic and spinal fractures during this phase. Thus, it is now recognized that ETC and DCO are complementary to each other and used for different groups of patients [5].

Although ETC and DCO made a major impact on trauma care, it took several years to appreciate the fact that unstructured management of trauma patients is associated with avoidable death and disability. The introduction of trauma centers in the US and the more recent development of regional trauma networks (RTN) in Australia and England have demonstrated the beneficial effect of organized trauma care systems on outcomes. The structure of the national system in England is based on the fundamental components suggested by the Committee on Trauma of the American College of Surgeons consisting of:

- Leadership (at all levels of trauma care delivery)
- Prehospital and in-hospital triage
- Designated and accredited trauma care facilities (major trauma centers (level I), trauma units (level II), local emergency hospitals (level III), transport services, rehabilitation units)
- Human resources (planning and development, administrative and clinical teamwork)
- Education-prevention-public awareness, good communication (at all levels of the trauma system)
- Rehabilitation plus data collection
- Audit and research with quality assurance monitoring [6]

Fractures have an important impact on the severity of the systemic reaction to trauma due to:

- Hemorrhage: prolonged states of shock as well as exsanguinating hemorrhage are frequently associated with unstable pelvic ring injuries, femoral shaft fractures, multiple long-bone fractures, and open injuries.
- Contamination: open fractures must always be considered as contaminated. If a wound can only be debrided after some delay or if debridement is not radical enough, the wound will become a perfect culture medium for bacteria resulting in local and sometimes systemic infection.
- Dead, ischemic tissue with a hypoxic zone at the margin: in unstable, displaced open fractures, especially after high-energy impact, a radical soft-tissue debridement is necessary as soon as possible to remove this source of pro-inflammatory mediators.
- Ischemia-reperfusion injury: prolonged hypovolemic shock and compartment syndrome related to fractures with or without vascular injuries are prone to ischemia-reperfusion injury with microvascular damage due to oxygen radicals. Blunt tissue contusions may activate xanthine oxidase; ischemia will produce the substrate xanthine/hypoxanthine, and reperfusion will add the co-substrate oxygen resulting in the formation of destructive free-oxygen radicals. A dangerous triad is established.
- Stress and pain: unstable fractures cause pain and stress which, via afferent input to the central nervous system, stimulate a neuroendocrine, neuroimmunological, and metabolic reflex arcs [7].
- Interference with intensive care: unstable fractures prevent effective patient postures (eg, upright chest), and pain-free patient movement.

In general terms the major aims of fracture management in the polytrauma patient are:

- Control of hemorrhage
- Control contamination sources
- Prevention of ischemia-reperfusion injury
- Pain relief
- Facilitate ventilation, nursing, and physiotherapy

These aims can be fulfilled by hemostasis, debridement, fasciotomy or revascularization, fracture fixation, and tension-free wound coverage.

For stabilization of long bones, external or internal fixation are options depending on the circumstances.

3 Pathophysiology

Trauma initiates a series of physiological reactions involving the cardiovascular, immune, and coagulation systems with the aim to maintain homeostasis and survival. The cardiovascular system initially exhibits a hypodynamic flow secondary to hypovolemic shock, which becomes hyperdynamic when resuscitation has been successfully completed [8]. Activation of the immune inflammatory system results in the development of both the systemic inflammatory response syndrome (SIRS) and the counter antiinflammatory response syndrome (CARS). Under ideal circumstances a

fine balance between those two immune reactions is maintained and the recovery is uneventful. An exaggerated SIRS might lead to ARDS, multiple organ dysfunction syndrome (MODS), or even death while a decompensated CARS could contribute to immunosuppression and development of early sepsis [9]. The response of the coagulation system to trauma and hemorrhage is complex and involves a controlled interaction between the vasculature, circulating platelets, coagulation proteins, and the fibrinolytic mechanism. Coagulation is initiated either by reactions between components of the blood alone (the intrinsic pathway) or by reactions that also involve tissue components (the extrinsic pathway). Normally, a fine balance is sustained between keeping blood in a fluid state and the development of clots.

3.1 Primary response to severe trauma

Local and systemic reactions are initiated in the immediate aftermath of severe trauma. Fractures, soft-tissue injury, organ damage (lung, liver, bowel, etc), hypoxia, acidosis, and painful stimuli all contribute to these reactions. The main physiological response aims at stopping hemorrhage and maintaining blood flow to vital organs.

The first response to injury is characterized by the release of adrenocorticosteroids and catecholamines by the neuroendocrine system inducing an increase in heart rate and respiration rate together with leukocytosis and fever. Stimuli from aortic and carotid receptors trigger the renin-angiotensin system in an effort to maintain blood pressure through vasoconstriction. At the same time the metabolic rate is reduced to minimize energy expenditure [10].

The first clinical priority is to stop hemorrhage, prevent hypoxia and hypercarbia (which result in acidosis), and avoid hypothermia. All of these result in secondary damage to key organs, such as the brain and they are considered precursors of SIRS.

Following trauma, numerous adaptations in inflammatory and immunological functions occur. Proinflammatory and antiinflammatory mediators are released regulating cellular and vascular responses. Polymorphonuclear (PMN) granulocytes, monocytes, and lymphocytes are activated and elicit local molecular responses associated with vascular endothelial adhesion. This adhesion process is mediated by the expression of adhesion molecules and is vital for the subsequent extravasation of PMN leukocytes. If this occurs systemically, rather than at the local site of injury, PMN leukocytes lose their autoregulation and release toxic enzymes causing remote organ injury in the form of ARDS or MODS. Failure to rapidly restore normal physiological parameters can lead to dysregulation of the immune system, paving the way for an exaggerated systemic inflammatory response and, at a later stage, immune paralysis. Thus, many of the serious, early complications of polytrauma, such as ARDS, MODS, sepsis, and thromboembolism are now considered to be associated with immune dysfunction. Interleukin-6 (IL-6) is believed to be a useful marker for assessing these alternations of the immune system, as it has been found to have a consistent pattern of expression and plasma half-life. A cutoff value of 200 pg/dL was shown to be significantly diagnostic of an “SIRS state”. Significant correlations between adverse events and both the IL-6 level and SIRS have been observed [11].

Recently, the ongoing quest to identify biomarkers of the immune responses following trauma has led to the recognition of a large family of mediators, the so-called damage-associated molecular patterns (DAMPs). Alarmins and pathogen-associated molecular patterns (PAMPs) are part of DAMPs and represent danger signals capable of activating innate immune responses after trauma. Their pathophysiological contribution in trauma-related induced systemic activation is currently under further investigation and is not yet fully understood [12].

3.2 Coagulopathy of trauma

Coagulopathy is common after severe trauma* and develops early, often before the patient arrives in hospital.

It is due to a combination of factors including:

- Hypovolemic shock due to bleeding
- Damage to vascular endothelium
- Thrombin-thrombomodulin complex generation within injured tissues
- Decreased activated protein C
- Activation of anticoagulant and fibrinolytic pathways
- Hypothermia

Additionally, hemodilution resulting from resuscitation with high volume of crystalloids can also lead to defective coagulation [13].

Coagulopathy along with the presence of acidosis and hypothermia is termed the "lethal triad" and is associated with an increased mortality rate (**Fig 4.1-1**). Early recognition and treatment of trauma-induced coagulopathy is essential to reach successfully the end points of resuscitation.

*Several names have been used to describe this coagulation disorder as acute traumatic coagulopathy, early coagulopathy of trauma, acute coagulopathy of trauma-shock, trauma-induced coagulopathy and trauma-associated coagulopathy.

3.3 Response to surgery: "the second hit"

The primary response to trauma involves the upregulation of several immune-physiological processes to maintain homeostasis and survival. The release of mediators and the induction of SIRS is dependent primarily on the severity of the trauma sustained (the "first-hit phenomena"). Any subsequent activation of various molecular cascades during therapeutic or diagnostic interventions, surgical procedures, and posttraumatic or postoperative complications are termed "second" or "third" hits (**Fig 4.1-2**) [14].

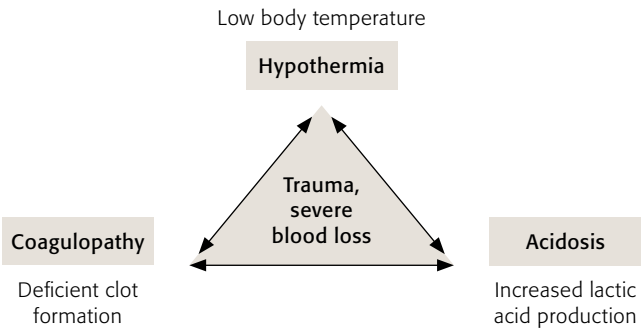

Fig 4.1-1 The lethal triad of death.

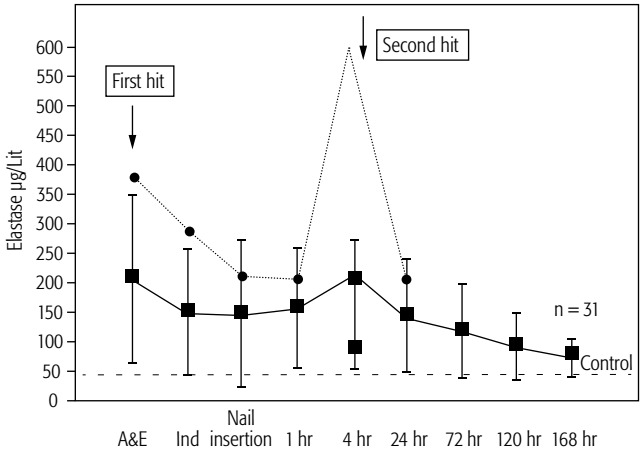

Fig 4.1-2 Levels of elastase release in patients undergoing femoral nailing at different time points (author data). Graph demonstrates the second hit phenomenon. The patient with the dotted line demonstrates excessive increase 4 hours after nailing compared with the rest of the patient population (N = 31).

It has been clearly shown that early, prolonged surgical interventions (second hits) are associated with increased risk of bleeding and stressful stimuli capable of magnifying the already evolving SIRS. In some cases, this may become uncontrollable and lead to the development of ARDS and MODS. While we cannot influence the response to the first hit, the surgeon with organized resuscitation and careful timing and planning of surgical interventions can reduce the endogenous physiological responses to this second hit, thus minimizing the risk of complications [15]. The application of the concept of damage-control surgery (DCS) in this setting is useful and life saving. Both conventional and immunological markers can quantify the presence of SIRS on admission. **Table 4.1-1** includes the conventional parameters defining SIRS. Alternately, on days 0 and 1 after major trauma, levels of IL-6 > 200 pg/dL are associated with a SIRS state [11].

4 Resuscitation

Hemorrhage is the most common cause of preventable death following trauma. Resuscitation protocols emphasize that early control of hemorrhage, including immediate control of external hemorrhage—cABC is key to patient survival.

It is paramount that the physician clinically assesses the extent of traumatic hemorrhage using a combination of patient physiology, anatomical injury pattern, mechanism of injury, and the patient's response to initial resuscitation. It has been estimated more than 50% of polytrauma patients are transfused with more than 15% of them receiving substantial transfusions [16].

A patient in hemorrhagic shock with an unidentified source of bleeding should undergo immediate assessment of the chest, abdominal cavity, and pelvic ring, which represent the major sources of occult, acute blood loss in trauma.

Body temperature	> 38 or < 36° C
Heart rate	> 90 beats/min
Respiratory rate	> 20/min or $PaC0_2$ < 32 mm Hg
White blood cell count	> 12,000 or < 4000 cells/mm^3

Table 4.1-1 Parameters defining the systemic inflammatory response syndrome (SIRS) (each parameter when present scores 1 point). More than two points defines a patient in an SIRS state.

Currently, in organized trauma care systems, computed tomographic (CT) scanners have replaced conventional radiographic imaging techniques (plain x-rays and ultrasonography) during the primary survey. Early whole-body (trauma) CT (WBCT) allows identification of the source of hemorrhage and targeted surgery or interventional radiology to stop the bleeding. The number to treat is just 17: for every 17 patients with an ISS >16 undergoing trauma CT, there will be one additional survivor and the sicker the patients, the more they are likely to benefit from early CT scan [17].

However, it is important to note that there must be a clear clinical indication for WBCT as it involves a significant dose of radiation. The WBCT should not be used as a "screening tool" based on mechanism of injury alone.

Serum lactate or base deficit measurements are sensitive tests to estimate and monitor the extent of bleeding and shock. The amount of venous lactate produced by anaerobic glycolysis is an indirect marker of oxygen debt and tissue hypoperfusion; the severity of arterial blood base deficit values offer an indirect estimation of global tissue acidosis due to impaired perfusion. Standard coagulation monitoring comprises the early and repeated determination of PT, APTT, platelet counts, and fibrinogen.

Detection of coagulation abnormalities with viscoelastic testing has recently been introduced. Early variables of clot firmness assessed by viscoelastic testing have been reported to be good predictors for the requirement for massive transfusion and for mortality in trauma patients [18]. Portable coagulometers and thromboelastometry allow "point of care" testing in the trauma room, critical care, or operating room and provide real-time data on coagulopathy to guide patient management.

Systolic blood pressure of 80–90 mm Hg should be the target until major bleeding has been stopped in the initial phase following trauma without brain injury.

In the presence of a traumatic brain injury (GCS ≤ 8), maintenance of mean arterial pressure ≥ 90 mm Hg is recommended. This is best achieved by intravenous administration of small (250 mL in an adult) boluses of warmed crystalloid and avoiding large volumes of these fluids if at all possible, as this is associated with dilutional coagulopathy and MODS.

It must be emphasized that this approach of "permissive hypotension" must be time-limited. Rapid hemorrhage control is essential.

Early application of measures to reduce heat loss and keep the hypothermic patient warm are essential to restore and maintain normothermia.

In patients with ongoing bleeding, massive transfusion protocols have been developed to allow prompt administration of red blood cells, fresh frozen plasma and platelets. The aim is to replace blood loss and coagulation factors that are being consumed. Latest evidence suggests that the optimal ratio of blood, FFP, and platelets is 1:1:1 and this is associated with improved survival rates [19]. Thromboelastography and fibrinogen levels together with standard coagulation tests may be used to guide the administration of additional fibrinogen concentrate or cryoprecipitate. The hematologist has become an integral member of the trauma team.

Massive transfusion is defined as the replacement of a patient's total blood volume within 24 hours, or as the acute administration of more than half the patient's estimated blood volume per hour.

The goal of treatment is to promptly restore the blood volume and to preserve the composition of blood with regard to clotting and oxygen-carrying capacity, biochemistry, and oncotic pressure. At the start of resuscitation, cross-match, coagulation tests, full blood count, and biochemistry must be performed. Hospitals receiving patients with major trauma should have a massive transfusion protocol in place. These will vary according to local resources but should allow immediate transfusion of group O-negative blood with rapid availability of blood (packed red blood cells), thawed fresh frozen plasma and platelets in a 1:1:1 ratio. All transfusions should be warmed.

Pharmacological agents have also been used as adjuncts to hemorrhage control. The CRASH-2 trial demonstrated that tranexamic acid, an antifibrinolytic drug with a good safety profile, administered within 3 hours of either blunt or penetrating trauma, significantly reduces transfusion requirements and mortality. Early administration is essential and ideally it should be given prehospital or early after arrival at hospital. A loading dose of 1 g of tranexamic acid is administered, followed by an infusion of 1 g over 8 hours [20].

Lately, the concept of damage-control resuscitation (DCR) has been introduced in the civilian trauma setting. The origin of DCR comes from the military's experience of management of major hemorrhage during recent conflicts in Afghanistan and Iraq. Damage-control resuscitation was defined as "a systematic approach to major trauma combining immediate control of external hemorrhage with a series of clinical techniques from point of wounding to definitive treatment to minimize blood loss, maximize tissue oxygenation, and optimize outcome" [21]. The main components of DCR are external hemorrhage control, time-limited permissive hypotension, limitation of crystalloid administration with early use of blood and blood products (massive transfusion protocols), early use of tranexamic acid, preventing hypothermia, and early DCS.

A multidisciplinary approach to the management of the multiple-injured patient remains the basis of ideal patient care.

Development and implementation of evidence-based management protocols reduces variation and improves both process and outcome.

5 Timing and priorities of surgery

Two important phases characterize the early management of multiple-injured patients: the prehospital and the in-hospital phase. Appropriate and timely decisions and interventions during these two phases are essential for an optimum outcome.

The primary objective is survival, which requires a secure airway and sufficient oxygenation to maintain function of the vital organs. The advanced trauma life support protocol has become the gold standard for initial assessment and treatment in the early pathway of polytrauma patients but has been adapted in many trauma systems to allow assessment and treatment to occur in parallel rather than sequentially. Primary resuscitation includes vital life-saving interventions (**Fig 4.1-3**). These may include:

- Decompression of body cavities (tension pneumothorax, cardiac tamponade, epidural hematoma)
- Control of exsanguinating hemorrhage (massive hemothorax or hemoperitoneum, crushed pelvis; whole limb amputation, mangled extremity)

Following completion of the initial assessment and early interventions, patients should be stratified in terms of their physiological state into one of four categories:

- Stable
- Borderline
- Unstable
- Extremis

This will guide the subsequent strategy for their management (**Table 4.1-2**). Any deterioration in the patient's clinical state or physiological parameters should prompt rapid reassessment and adjustment of the strategic approach. Achieving end points of resuscitation is paramount for the stratification of the patient into the appropriate category. End points of resuscitation include normal hemodynamics and oxygen saturation, lactate level less than 2 mmol/L, no coagulation disturbance, normal temperature, urinary output more than 1 mL/kg per hour and no requirement for inotropic support.

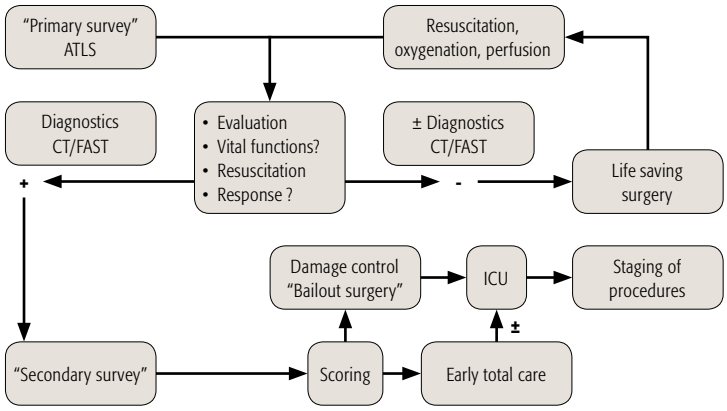

Fig 4.1-3 Initial assessment and management pathway for polytrauma patients. Abbreviations: ATLS, advsnced trauma life support; CT, computed tomography; FAST, focused assessment with sonography for trauma; ICU, intensive care unit.

5.1 Indications for damage-control surgery

If there is poor response to resuscitation, and physiological parameters do not return to normal, definitive surgery should be avoided and the concept of damage control applied. The rationale behind this concept is to save life by deferring prolonged and traumatic definitive surgery and focus on restoring physiology [22]. Damage-control surgery is indicated in 10–20% of polytrauma patients (**Table 4.1-3**).

Briefly stated there are three different conditions for selecting DCS:

- Physiological criteria: hypothermia, coagulopathy, and acidosis
- Complex pattern of severe injuries, such as chest injury, pelvic fractures, bilateral femoral fractures, complex extremity fractures, older polytrauma patients: expecting major blood loss and prolonged reconstructive procedures that is likely to be beyond the patient's physiological reserve.
- Mass casualties: When the number of patients to be treated, during a mass casualty event, overwhelms the available resources to provide early total care and so time-limited surgery to save life and limb is performed to allow as many casualties as possible to receive care.

Damage control can be used in two circumstances:

- Reactively: "bail-out" surgery, which means aborting invasive procedures in a patient at imminent risk of death.
- Preemptively: calculated early decision to accomplish definitive repair in staged sequential procedures due to inadequate resuscitation or a high risk of physiological deterioration.

	Parameter	Stable/safe	Borderline/at risk	Unstable	In extremis
Shock	Blood pressure, mm Hg	100 or more	80–100	60–90	< 50–60
	Blood units, 2 hours	0–2	2–8	5–15	>15
	Lactate levels	Normal range	Around 2.5	> 2.5	Severe acidosis
	Base deficit, mmol/L	Normal range	No data	No data	> 6–8
	ATLS Classification	I	II–III	III–IV	IV
Coagulation	Platelet count, µg/mL	> 110,000	90,000–110,000	< 70,000–90,000	< 70,000
	Factor II and V, %	90–100	70–80	50–70	< 50
	Fibrinogen, g/dL	> 1	Around 1	< 1	DIC
	D-Dimer	Normal range	Abnormal	Abnormal	DIC
Temperature		> 34°C	33°C–35°C	30°C–32 °C	30 °C or less
Soft-tissue injuries	Lung function; PaO_2/FiO_2	350–400	300–350	200–300	< 200
	Chest trauma scores; AIS	AIS I or II	AIS 2 or more	AIS 2 or more	AIS 3 or more
	Chest trauma score; TTS	0	I–II	II–III	IV
	Abdominal trauma (Moore)	< or = II	< or = III	III	III or > III
	Pelvic trauma (AO/OTA Classification)	A type (AO)	B or C	C	C (crush, rollover abd.)
	Extremities	AIS I–II	AIS II–III	AIS III–IV	Crush, rollover extrem.
Surgical strategy	Damage control (DCO) or Definitive surgery (ETC)	ETC	DCO if uncertain ETC if stable	DCO	DCO

Table 4.1-2 Criteria and stratification of the four categories that a polytrauma patient can be assigned base on their physiological state. Abbreviations: AIS, Abbreviated Injury Scale; ATLS, advanced trauma life support; DCO, damage-control orthopedics; DIC, disseminated intravascular coagulopathy; ETC, early total care.

Patient selection for damage-control surgery
Hypothermia: < 34° C
Acidosis: pH < 7.2
Lactate: > 4 mmol/L
Coagulopathy
Blood pressure < 70 mm Hg
Transfusion approaching 15 units
Injury severity score > 36

Table 4.1-3 Criteria for patient selection for damage-control surgery.

Damage-control procedures include control of hemorrhage by ligation or packing, splinting of long-bone and pelvic fractures (with external fixators or splints), and reducing the risk of infection by fecal diversion, irrigation, and wound debridement. Damage-control surgery should be time-limited with the aim of completing all necessary surgery and getting the patient to the intensive care unit as soon as possible for stabilization of physiological systems. After physiological restoration in the intensive care unit, staged definitive surgery can take place under planned and controlled circumstances.

Following DCS there is a window of opportunity between day 5 and day 10 after trauma for definitive stabilization of fractures (**Table 4.1-4**). During this period, there exists an immunological window of opportunity between the phase of hyperinflammation (SIRS) and the period of immunosuppression (CARS). The period of immunosuppression lasts for about 2 weeks, so that secondary reconstructive procedures can be planned for the third week after trauma.

5.2 Indications for early total care

Definitive osteosynthesis of long-bone fractures on day 1 is recommended only when all end points of resuscitation have been accomplished.

Early total care does not mean immediate total care: fractures should be temporarily splinted and time should be taken to ensure adequate resuscitation of the patient.

This means return to normal oxygenation, vital signs, temperature, coagulation, and normal microcirculation resulting in aerobic metabolism, as measured by pH, base deficit, and venous lactate. In some cases, this may take 24 or even 36 hours to achieve but will still leave a safe window for fracture surgery. This approach has been termed "early appropriate care" [23]. In this situation, the appropriate type of osteosynthesis should be selected based on the personality of the fracture and the surgeon's expertise. **Table 4.1-5** illustrates criteria for early total care. With this approach, early definitive fracture fixation will be possible in most patients with polytrauma. Evidence from clinical experience as well as in the literature [2, 3, 24] supports the view that early fracture fixation in polytrauma is beneficial in terms of mortality and morbidity as it:

- Reduces the incidence of ARDS, fat embolism, pneumonia, MODS, sepsis, and thromboembolic complications
- Facilitates nursing and intensive care: upright chest position, early mobilization, less analgesia

Timing	Resuscitation state/physiological status	Surgical intervention
Day 1	Normal, no fluctuation	Early total care
	Transient response	Damage control
	No response-inotropes	Life-saving surgery
Day 2–3	Hyperinflammation (↑SIRS)	"Second look" only
Day 4–10	Safe window of opportunity	Definitive surgery
Day 11–21	Immunosuppression (↑CARS)	Avoid surgery
Day 22+	Normal physiology	Secondary reconstructive surgery

Table 4.1-4 Timings of surgical intervention in the polytrauma patient. Abbreviations: CARS, compensatory antiinflammatory syndrome; SIRS, systematic imflammatory response syndrome.

Indications for early total care
Stable hemodynamics
No need for vasoactive/inotropic stimulation
No hypoxemia, no hypercapnia
Lactate < 2 mmol/L
Normal coagulation
Normothermia
Urinary output > 1 mL/kg/hour

Table 4.1-5 Criteria for patient selection for early total care.

6 Specific injury patterns

A number of specific injury patterns should be considered for DCS. Decision making can be difficult and is best done in consultation with the various key specialties (general surgery, intensive care medicine, anaesthesia, etc) and take place at the bedside where all factors can be taken into account (**Figs 4.1-4–7**) [25]. This is not the time for remote patient management.

Fig 4.1-4 a–c A 40-year-old man involved in motor vehicle crash. At the scene: Glasgow coma scale: 7; blood pressure (BP): 70/30 mm Hg; heart rate (HR): 120/min; RR: 40/min; and Sats: 72% on air. The man had obvious injuries to lower extremities (**a–b**) and difficulty breathing. He was intubated and ventilated at the scene. A peripheral large intravenous access + 1.5 L of crystalloid immediately were given. He was transferred by ambulance to the local hospital. The rescue took 30 minutes.

Resuscitation management:
- Needle decompression of left chest cavity and bilateral chest drains (**c**)
- IV access and arterial line/monitoring and blood samples tests
- Fluid resuscitation (massive transfusion protocol)
- Biochemical profile was BP 115/70 mm Hg; HR: 112/bpm; oxygen saturation: 98–10% (on 50% O2); hemoglobin 10.6; platelets 130,000; and lactate 5.8
- Responded well and CT scans were performed

Trauma CT findings
- Bilateral flail chest, liver laceration (small), left open fracture of radius and ulna (grade I)
- Fracture of left acetabulum—posterior column and posterior wall-posterior hip dislocation, left open fracture of tibia and fibula (grade IIIA)
- Open fracture of right femur (grade IIIa), open fracture of right tibia and fibula (grade IIIB), comminuted open fracture of right talus; injury severity scale = 50

When the patient returned from CT, the BP level dropped to 95/65 mm Hg; lactate 3.1, and resuscitation continued.

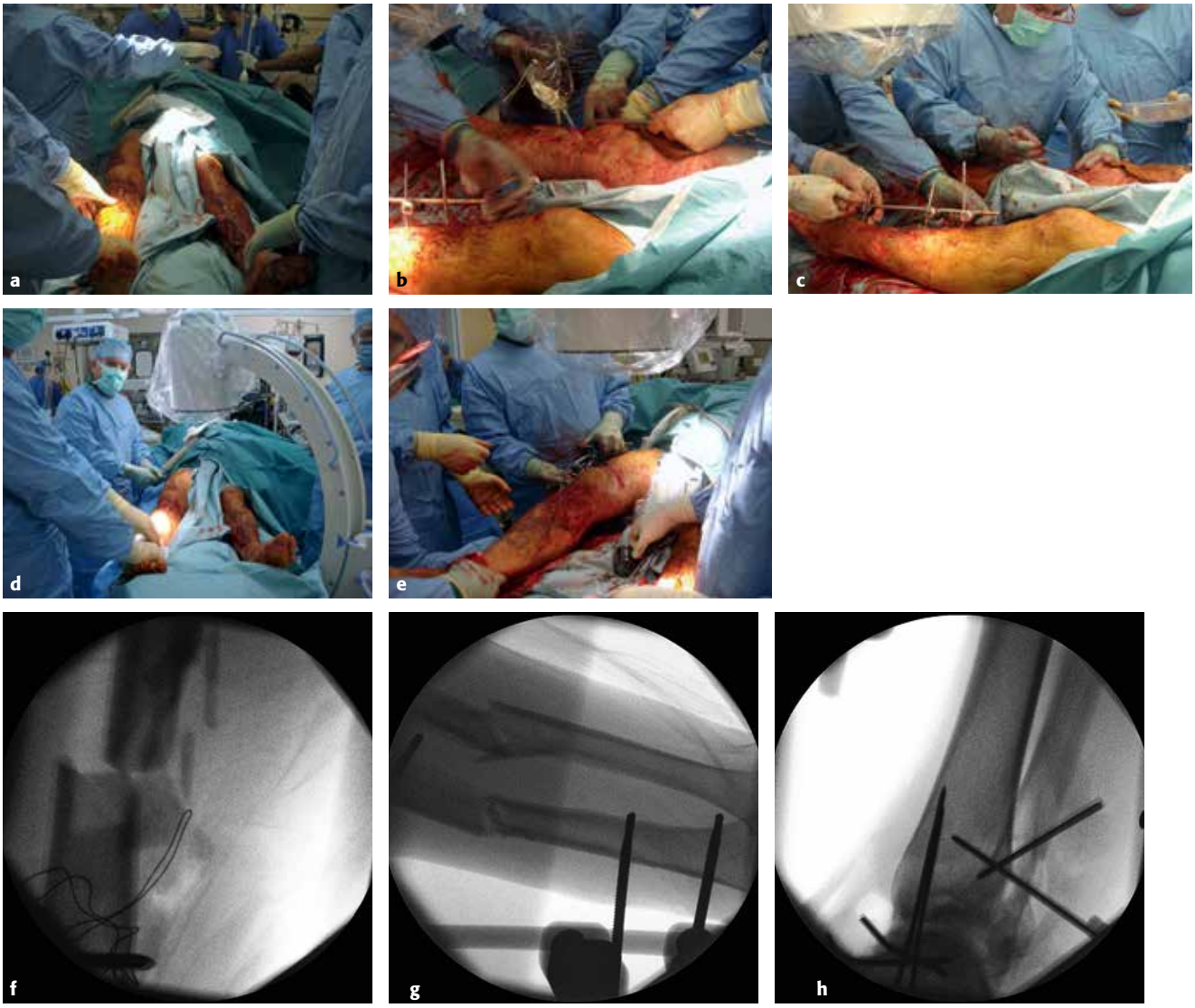

Fig 4.1-5a–h The patient was taken to the operating room (OR) for damage-control surgery. Two surgical teams worked together to debride and stabilize upper and lower limb fractures with external fixators. He was kept in OR for 2 hours and was then transferred to the intensive care unit for supportive care.

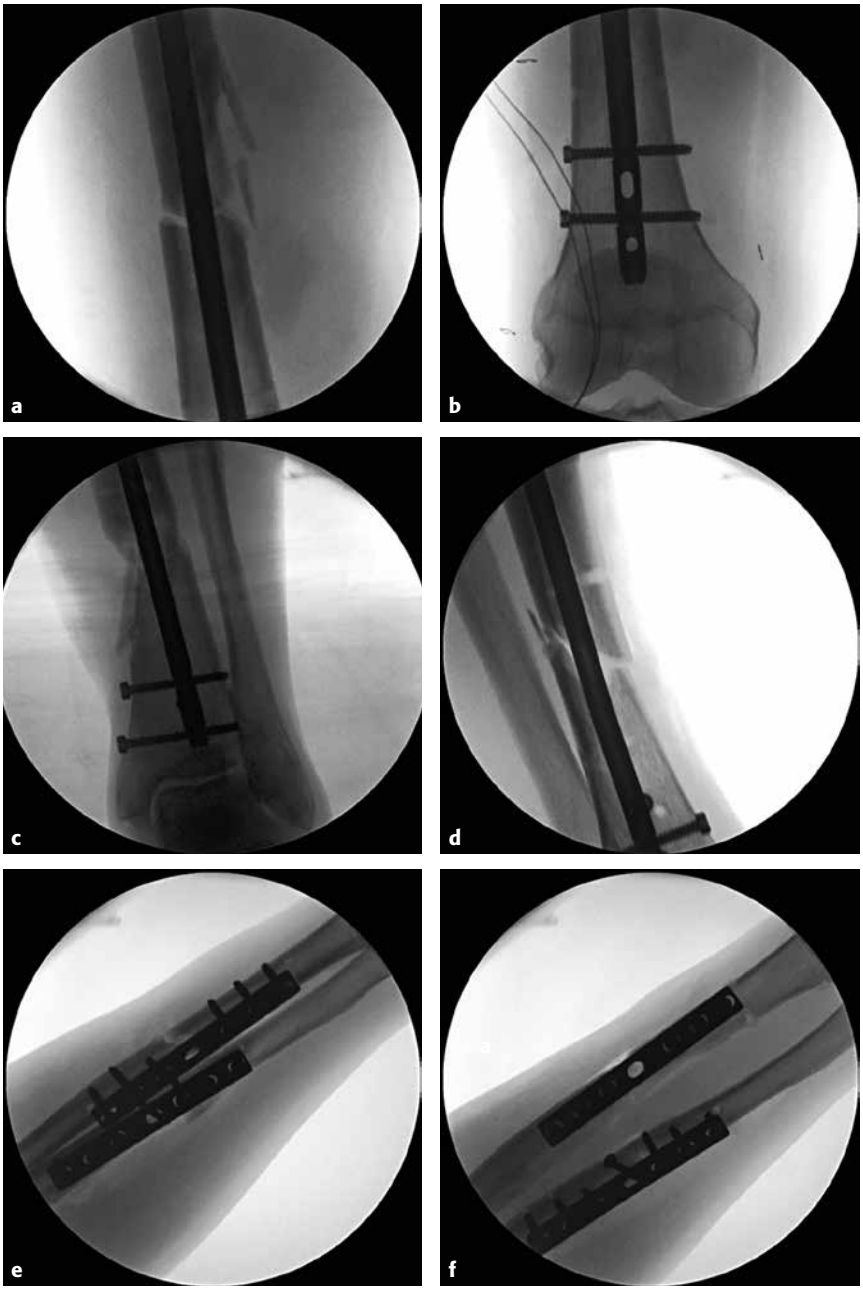

Fig 4.1-6a–f Subsequently, the patient had staging of procedures:
- Day 4: external fixators removed and intramedullary nails placed in right femur and right tibia; open reduction and internal fixation was performed on left forearm; further debridement and application of negative-pressure wound therapy (NPWT) to left and right leg wounds. Image intensifier films of definitive stabilization of right femoral shaft fracture (**a–b**), left tibial fracture (**c–d**), and forearm (**e–f**) taken at day 4.
- Postadmission day 6: right medial gastrocnemius flap to right anterior leg wound with NPWT to both leg wounds.

Fig 4.1-7a–d Postadmission day 7: K-wires removed from right ankle; open reduction and internal fixation performed on right talus, left acetabulum, and right knee with superficial skin graft to right knee. X-rays showing definitive stabilization of acetabular fracture (**a–b**) and right ankle/talus fracture (**c–d**).

6.1 Severe pelvic fractures and hemorrhage control

Open or closed displaced pelvic fractures can produce exsanguinating hemorrhage into the retroperitoneum, the peritoneal cavity, or into the soft tissues when there is a degloving injury (eg, Morel-Lavallée lesion). These patients benefit from application of a pelvic binder or sheet at the scene of the injury. Aggressive resuscitation with a massive transfusion protocol is essential and must include early administration of tranexamic acid. Prompt reduction and fixation of the pelvic ring with an external fixator or a pelvic compression clamp (C-clamp) can be performed as indicated after the initial assessment and interventions in the resuscitation room. However, a well-applied pelvic binder (sheet) can provide excellent circumferential splinting of the pelvis and obviate the need for early pelvic fixation. If the hemodynamic response is good, the diagnostic work-up can be completed and pelvic reconstruction can be done as staged surgery.

If the patient remains unstable, the source of hemorrhage needs to be identified and stopped. Two options are available: direct surgical control by pelvic packing or interventional radiology and embolization. The choice will be determined by multiple factors including facilities, experience, and the site(s) of hemorrhage. If laparotomy is required, the possibility of abdominal compartment syndrome must be kept in mind [26]. After recovery in the intensive care unit, one or two "second-look" procedures are often required, followed by definitive stabilization of the pelvis and closure of the abdominal wall.

6.2 Traumatic brain injury with long-bone fractures

Following traumatic brain injury, it is vital to prevent further (secondary) brain damage [27] due to hypotension and hypoxemia and to maintain optimal cerebral perfusion.

Epidural or acute subdural hematomas require urgent surgical evacuation and hemostasis. Patients with traumatic brain injury and GCS < 9 after craniotomy may need intracranial pressure monitoring after life-saving surgery [28]. Given a good response to resuscitation, early fracture fixation has a positive effect in brain-injured patients, as it facilitates nursing care, reduces painful stimuli (afferent input), and decreases the need for sedation and analgesia.

Concerns that early fixation of long-bone fractures in patients with traumatic brain injury may—under the circumstances just described—increase mortality rate, are not evidence-based [29].

Regardless of the treatment protocol followed, if secondary brain damage is to be avoided, many neurosurgeons recommend intracranial pressure monitoring in the intensive care unit and in the operating room during surgical procedures, since aggressive intracranial pressure management may be correlated to improved outcomes. Treatment protocols should be based on the clinical assessment of individual patients rather than mandatory time policies for fixation of long-bone fractures.

6.3 Severe chest injury with long-bone fractures

Locked IM nailing continues to be the gold standard of treatment in both closed and open femoral shaft fractures. However, instrumentation of the IM cavity increases the IM pressure leading to release of mediators and intravasation of fat (emboli) in the peripheral circulation and the lungs. This has been clearly demonstrated by transesophageal echocardiography. Intramedullary nailing is well tolerated by patients with isolated fractures who have been fully resuscitated but may cause more problems in the under-resuscitated patient and those with multiple injuries, where rapid deterioration in pulmonary function may occur. Decision making and choice of surgical technique to stabilize the long bones are controversial in this situation.

Two recent, prospective randomized studies [30, 31] were performed to investigate this issue. In one study [30] performed in North America, three of the 63 multiple-injured patients who received a reamed nail developed ARDS compared with two of 46 patients in the unreamed group. This difference was not statistically significant ($P = .42$). However, the power for this difference was 5% and it was calculated that 39,817 patients are needed in each group to detect a difference. The authors [30] concluded that the overall incidence of ARDS was low with primary stabilization of femoral shaft fractures with IM nailing. There was no difference in the incidence of ARDS between the reamed and unreamed groups, given the sample size.

In the other study [31] performed in Europe, multiple-injured patients with femoral shaft fractures were randomized to either initial (< 24 hours) IM femoral nailing or external fixation and later conversion to an IM nail. Of 165 patients recruited, 94 underwent IM nailing and 71 external fixation. One hundred twenty-one patients were stable and 44 patients were in borderline condition. After adjusting for differences in initial injury severity between the two treatment groups, the odds of developing acute lung injury were 6.69 times higher in borderline patients who underwent IM nailing compared with those who underwent external fixation,

$P < .05$. The authors [31] concluded that IM stabilization of the femoral fracture can affect the outcome in patients with multiple injuries. In stable patients, primary femoral nailing is associated with shorter ventilation time. In borderline patients, it is associated with a higher incidence of lung dysfunction compared with those who underwent external fixation and later conversion to IM nail (**Fig 4.1-8**) [2, 5].

6.3.1 Rib fracture fixation

A flail chest (fracture of 3 or more consecutive ribs at multiple sites) is a severe chest injury and recent investigations are pointing towards this as being an injury that may be helped by chest wall stabilization. Rib fracture fixation, for flail chest injuries, by orthopedic, trauma or thoracic surgeons, is at the present time being studied by a number of multicenter randomized trials. Stabilization of a flail segment by small locking plates may improve pulmonary function such that ventilator time, ICU time and pain control are all less for the patient with a flail chest. New research, over the next few years, will help direct patient care for this life threatening condition [32, 33].

6.4 Blast injuries

Blast injuries are less common than gunshot wounds but their number is growing in both civilian and military settings. Blast injuries are different from gunshots mainly because of their multiple mechanisms of injury [34]. They tend to involve more body regions, and generally tend to be of higher injury severity scores. Although the surgical management of individual injuries may be similar to that of other types of trauma, the overall management of these patients as individuals as well as in the context of mass casualty event is worthy of consideration.

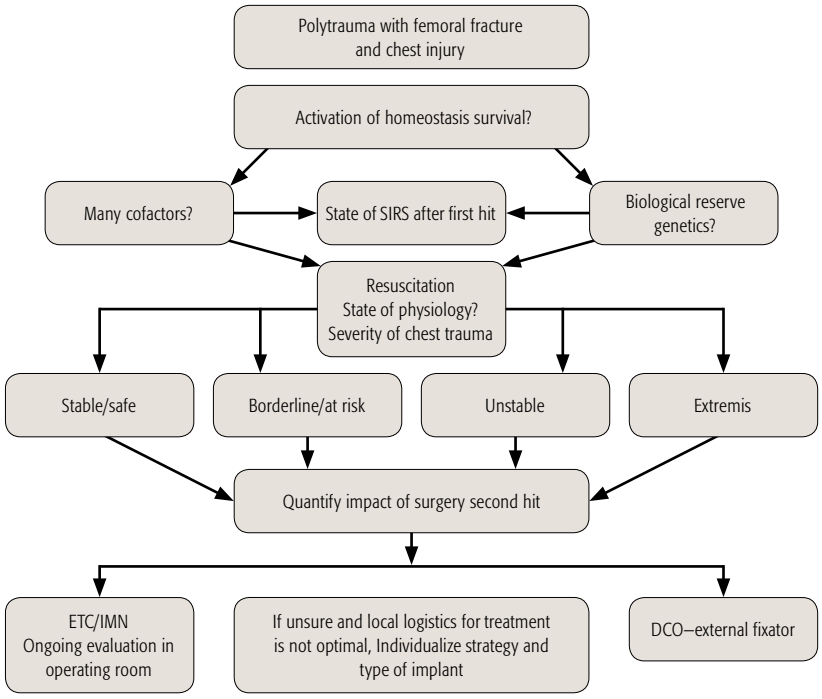

Fig 4.1-8 Algorithm for management of patients with chest injury.
Abbreviations: SIRS, systematic inflammatory response syndrome; ETC, early total care; IMN, intramedullary nail.

The primary blast effect is related to the rapid pressure wave created during the detonation of an explosive. The scene location and the type of explosive used have a direct effect on the severity of the injuries. Lung injury is common and due to pressure differentials across the alveolar-capillary interface cause disruption, hemorrhage, pulmonary contusion, pneumothorax, hemothorax, pneumomediastinum, and subcutaneous emphysema [35]. The second most common type of primary blast injury is that to the hollow viscera. The intestines, most usually the colon, are affected by the detonation wave. Mesenteric ischemia or infarct can cause delayed rupture of the large or the small intestine; these injuries are difficult to detect initially. Rupture, infarction, ischemia, and hemorrhage of solid organs such as the liver, spleen, and kidney are generally associated with very high blast forces or proximity of the patient to the blast center [35].

Secondary blast effects comprise the core of the orthopedic injuries observed in warfare [36] and also in civilian attacks [37]. Secondary blast effects are related to penetrating injuries caused by fragments ejected from the explosives and/or by foreign bodies impregnated within it. The extent of this effect depends on the subject's distance from the detonation center, the shape and size of the fragments, and the number of foreign bodies implanted or created by the explosive. In contrast to most warfare injuries, the improvised explosives used in civilian settings have multiple added fragments including screws, bolts, nails, and other objects that may increase the damage caused by penetrating injuries. Open fractures, severe soft tissue injuries, and multi-organ penetrating injuries are the more common pattern seen in the severely injured victim [38].

Tertiary blast injury refers to the blunt trauma component of the explosion. Flying or falling objects can cause additional traumatic elements to those described above. When structural collapse takes place, a high casualty and mortality event occurs [39].

The quaternary blast effect is a recently added one, and includes the thermal and chemical damage caused by fire and noxious substances occurring at the vicinity of the explosion. Confined-space explosions significantly increase these types of injuries (**Fig 4.1-9**) [40].

6.5 Limb salvage versus amputation

The development of microsurgical techniques for free vascularized tissue transfer has increased the chances of saving mangled extremities or nearly amputated limbs. In polytrauma, such salvage procedures are rarely indicated as these complex reconstructive procedures are time consuming and result in a significant "second hit" in patients with significant immune and physiological compromise.

The mangled extremity severity score may assist in decision making [34]. There are only rare indications for heroic salvage attempts. These require a multistage concept with initial debridement, revascularization, fasciotomies, and fracture fixation, followed by repeated debridement and early soft-tissue reconstruction during a "window of opportunity".

When the decision is made to amputate, this should be performed at a level of healthy tissue, combined with primary open wound management. The primary amputation is a wound debridement and all healthy tissue should be preserved; the surgeon should not attempt to fashion flaps at this early stage. Delayed surgery to construct a stump with optimal function is performed some days later when the patient's condition has stabilized.

7 Summary

The management of polytrauma patients is evolving and improving [35]. Patients treated within organized regional trauma networks are reported to have improved outcomes. The physiological state of patients must be assessed quickly while performing resuscitation and the treatment strategy for fractures is now based on the patient's physiological response to the injury and resuscitation. Damage-control orthopedics and ETC should be complementary and the key is to select the right strategy for the right patient at the right time.

Fig 4.1-9a–f Open intraarticular fractures pose treatment dilemmas. These injuries are associated with significant morbidity due to increased risks of infection, nonunion, malunion, joint stiffness and possible amputation. In spite of the open nature of the injury, as with other articular fractures, joint reconstruction and stable fixation should be a primary goal of treatment.

a Blast injury with multiple penetrating wounds from shrapnel.
b Open Gustilo type IIIA subtrochanteric femoral fracture.
c Open Gustilo type IIIA diaphyseal tibial fracture.
d–f Two-year follow-up; the fractures are united after open reduction and internal fixation of both.

Classic references | Review references

8 References

1. **Pape HC, Lefering R, Butcher N, et al.** The definition of polytrauma revisited: an international consensus process and proposal of the new 'Berlin definition'. *J Trauma Acute Care Surg.* 2014 Nov;77(5):780–786.
2. **Balogh ZJ, Reumann MK, Gruen RL, et al.** Advances and future directions for management of trauma patients with musculoskeletal injuries. *Lancet.* 2012 Sep 22;380(9847):1109–1119.
3. **Bone LB, Johnson KD, Weigelt J, et al.** Early versus delayed stabilization of fractures: a prospective randomized study. *J Bone Joint Surg Am.* 1989 Mar; 71(3)A:336–340.
4. **Giannoudis PV.** Surgical priorities in damage control in polytrauma. *J Bone Joint Surg Br.* 2003 May;85(4):478–483.
5. **D'Alleyrand JC, O'Toole RV.** The evolution of damage control orthopedics: current evidence and practical applications of early appropriate care. *Orthop Clin North Am.* 2013 Oct;44(4):499–507.
6. **American College of Surgeons Committee on Trauma.** *Resources for the Optimal Care of the Injured Patient.* Chicago: American College of Surgeons; 2006.
7. **Lord JM, Midwinter MJ, Chen YF, et al.** The systemic immune response to trauma: an overview of pathophysiology and treatment. *Lancet.* 2014 Oct 18;384(9952):1455–1465.
8. **Giannoudis PV, Dinopoulos H, Chalidis B, et al.** Surgical stress response. *Injury.* 2006 Dec;37 Suppl 5:S3–9.
9. **Lasanianos NG, Kanakaris NK, Dimitriou R, et al.** Second hit phenomenon: existing evidence of clinical implications. *Injury.* 2011 Jul; 42(7):617–629.
10. **Sears BW, Stover MD, Callaci J.** Pathoanatomy and clinical correlates of the immunoinflammatory response following orthopaedic trauma. *J Am Acad Orthop Surg.* 2009 Apr;17(4):255–265.
11. **Giannoudis PV, Harwood PJ, van Griensven M, et al.** Correlation between IL-6 levels and the systemic inflammatory response score: can an IL-6 cutoff predict a SIRS state? *J Trauma.* 2008 Sep;65(3):646–652.
12. **Giannoudis PV, Mallina R, Harwood P, et al.** Pattern of release and relationship between HMGB-1 and IL-6 following blunt trauma. *Injury.* 2010 Dec; 41(12):1323–1327.
13. **Schöchl H, Grassetto A, Schlimp CJ.** Management of hemorrhage in trauma. *J Cardiothorac Vasc Anesth.* 2013 Aug;27(4 Suppl):S35–43.
14. **Morley JR, Smith RM, Pape HC, et al.** Stimulation of the local femoral inflammatory response to fracture and intramedullary reaming: a preliminary study of the source of the second hit phenomenon. *J Bone Joint Surg Br.* 2008 Mar;90(3):393–399.
15. **Giannoudis PV, Tan HB, Perry S, et al.** The systemic inflammatory response following femoral canal reaming using the reamer-irrigator-aspirator (RIA) device. *Injury.* 2010 Nov;41 Suppl 2:S57–61.
16. **Patel SV, Kidane B, Klingel M, et al.** Risks associated with red blood cell transfusion in the trauma population, a meta-analysis. *Injury.* 2014 Oct;45(10):1522–1533.
17. **Huber-Wagner S, Lefering R, Qvick LM, et al.** Effect of whole-body CT during trauma resuscitation on survival: a retrospective, multicentre study. *Lancet.* 2009 Apr 25;373(9673):1455–1461.
18. **Kunio NR, Differding JA, Watson KM, et al.** Thrombelastography-identified coagulopathy is associated with increased morbidity and mortality after traumatic brain injury. *Am J Surg.* 2012 May;203(5):584–588.
19. **Ball CG.** Damage control resuscitation: history, theory and technique. *Can J Surg.* 2014 Feb;57(1):55–60.
20. **CRASH-2 collaborators, Roberts I, Shakur H, et al.** The importance of early treatment with tranexamic acid in bleeding trauma patients: an exploratory analysis of the CRASH-2 randomized controlled trial. *Lancet.* 2011 Mar 26;377(9771):1096–1101, 1101.e1–2.
21. **Hodgetts TJ, Mahoney PF, Kirkman E.** Damage control resuscitation. *J R Army Med Corps.* 2007 Dec;153(4):299–300.
22. **Moran CG, Forward DP.** The early management of patients with multiple injuries: an evidence-based, practical guide for the orthopedic surgeon. *J Bone Joint Surg Br.* 2012 Apr;94(4):446–453.
23. **Vallier HA, Wang X, Moore TA, et al.** Timing of orthopaedic surgery in multiple trauma patients: development of a protocol for early appropriate care. *J Orthop Trauma.* 2013 Oct;27(10):543–551.
24. **Goris RJ, Gimbrère JS, van Niekerk JL, et al.** Early osteosynthesis and prophylactic mechanical ventilation in the multi-trauma patient. *J Trauma.* 1982 Nov; 22(11):895–903.
25. **Giannoudis PV, Pape HC.** Damage control orthopedics in unstable pelvic ring injuries. *Injury.* 2004 Jul;35(7):671–677.
26. **Ertel W, Oberholzer A, Platz A, et al.** Incidence and clinical pattern of the abdominal compartment syndrome after "damage control" laparotomy in 311 patients with severe abdominal and/or pelvic trauma. *Crit Care Med.* 2000 Jun;28(6):1747–1753.
27. **Chesnut RM, Marshall LF, Klauber MR, et al.** The role of secondary brain injury in determining outcome from severe head injury. *J Trauma.* 1993 Feb;34(2):216–222.
28. **Stocker R, Bernays R, Kossmann T, et al.** Monitoring and treatment of acute head injury. In: Goris RJA, Trentz O, eds. *The Integrated Approach to Trauma Care*. Berlin Heidelberg New York: Springer-Verlag;1995;96–210.
29. **Brundage ST, McGhan R, Jurkovich GT, et al.** Timing of femur fracture fixation: effect on outcome in patients with thoracic and head injuries. *J Trauma.* 2002 Feb;52(2):299–307.
30. **Canadian Orthopaedic Trauma Society.** Reamed versus unreamed intramedullary nailing of the femur: comparison of the rate of ARDS in multiple injured patients. *J Orthop Trauma.* 2006 Jul;20(6):384–387.
31. **Pape HC, Rixen D, Morley J, et al.** Impact of the method of initial stabilization for femoral shaft fractures in patients with multiple injuries at risk for complications (borderline patients). *Ann Surg.* 2007 Sep;246(3):491–499.
32. **Ollivere B.** Current concepts in rib fracture fixation. *Bone Joint.* 2016;5(5):2–7.
33. **Swart E, Laratta J, Slobogean G, et.al.** Operative treatment of rib fractures in flail chest injuries: a meta-analysis and cost-effectiveness analysis. *J Orthop Trauma.* 2017;31(2):64–70.
34. **Weil YA, Peleg K, Givon A, et al.** Penetrating and orthopaedic trauma from blast versus gunshots caused by terrorism: Israel's National Experience. *J Orthop Trauma.* 2011 Mar;25(3):145–149.

35. **Wightman JM, Gladish SL.** Explosions and blast injuries. *Ann Emerg Med.* 2001 Jun;37(6):664–678.
36. **Covey DC.** Blast and fragment injuries of the musculoskeletal system. *J Bone Joint Surg Am.* 2002 Jul;84-a(7):1221–1234.
37. **Barham M.** Blast injuries. *N Engl J Med.* 2005 Jun;352(25):2651–2653; author reply–3.
38. **Ad-El DD, Eldad A, Mintz Y, et al.** Suicide bombing injuries: the Jerusalem experience of exceptional tissue damage posing a new challenge for the reconstructive surgeon. *Plast Reconstr Surg.* 2006 Aug;118(2):383–387; discussion 388–389.
39. **Teague DC.** Mass casualties in the Oklahoma City bombing. *Clin Orthop Relat Res.* 2004 May(422):77–81.
40. **Leibovici D, Gofrit ON, Stein M, et al.** Blast injuries: bus versus open-air bombings—a comparative study of injuries in survivors of open-air versus confined-space explosions. *J Trauma.* 1996 Dec;41(6):1030–1035.
41. **Johansen K, Daines M, Howey T, et al.** Objective criteria accurately predict amputation following lower extremity trauma. *J Trauma.* 1990 May;30(5):568–572; discussion 572–573.
42. **Hildebrand F, van Griensven M, Huber-Lang M, et al.** Is there an impact of concomitant injuries and timing of fixation of Major fractures on fracture healing? A focused review of clinical and experimental evidence. *J Orthop Trauma.* 2016;30:104–112.

9 Acknowledgments

We thank Otmar Trentz for his contribution to the second edition of the *AO Principles of Fracture Management* and Rami Mosheiff for the section on blast injuries.

4.2 Open fractures

Rami Mosheiff

1 Introduction

Open fractures imply a communication between the external environment and the fracture. Four components characterize the injury:

- Fracture
- Soft-tissue damage
- Neurovascular compromise
- Contamination

The extent of each component must be assessed individually to achieve a comprehensive understanding of the injury, upon which a treatment plan can be based.

Improved understanding of open fracture pathology, techniques of fracture fixation, soft-tissue care, and antimicrobial treatment has resulted in a significant reduction of morbidity and mortality associated with open fractures. Yet, the most severe open fracture types, even with experienced trauma surgeons, are still fraught with complications and poor outcome.

Complex injuries, regardless of the location and extent, are managed by early aggressive debridement. Early definitive reconstruction can be initiated once the deliberation over whether to salvage or amputate has been resolved. This requires experience and special skills, cooperation of plastic, vascular, and orthopedic surgeons, support staff and services, and specialized equipment in modern trauma centers [1].

2 Historical perspective

The concept of open fracture care has evolved from the experience of war surgeons, dating back many centuries. Only a century ago, the high mortality rate of patients with open fractures in major long bones frequently led to early amputation to try and prevent death. At the onset of World War I, the mortality rate from open femoral fractures was still more than 70%. The nature of the wounds sustained on the battlefield prompted Trueta to recommend "closed treatment of war fractures" in 1939. This included open wound treatment and subsequent enclosure of the extremity in a cast. Trueta was revolutionary in his approach to handling soft-tissue injuries associated with open fractures. Contrary to the general opinion at the time, he believed that the greatest danger of infection lay in the muscle and not in the bone. He recommended wound debridement with excision of necrotic tissue. His method of leaving wounds open persisted as further experience was accumulated during World War II. In 1943, the use of penicillin on the battlefield quickly reduced the rate of wound sepsis. However, overreliance on the efficiency of antibiotics resulted in less emphasis on debridement. Prompted by the complications of inadequately debrided wounds, the concept of delayed closure was adopted. Hampton recommended closure between the fourth and seventh day after injury depending upon the wound being clinically clean. Larger defects continued to be left open to heal by second intention.

Major advances over the last century have moved the focus of management of such injuries beyond the preservation of life and limb to the restoration of function and prevention of complications. Nevertheless, there is no place for complacency. In the most severe open tibial fractures associated with vascular injury, the documented amputation rates still exceed 50% [2].

3 Etiology and mechanism of injury

Open fractures tend to be caused by more severe trauma than closed fractures. However, fractures due to low-energy indirect torsional trauma can penetrate the skin from within, particularly where the bone lies close to the skin and is not protected by a muscular envelope. Severe open fractures usually occur as a result of direct high-energy trauma, either in road traffic collisions or falls from height. The degree of trauma induced is related to the energy imparted by the sudden deceleration at the time of impact. A prime example is the open fracture of the lower extremity in a motorcyclist (**Fig 4.2-1**). High-energy incidents frequently cause multiple, severe injuries to other parts of the body (head, chest, and abdomen) and the management of these may take precedence over the open fracture(s) (see chapter 4.1).

Despite progress in the management of fractures and in surgical reconstruction of soft-tissue injuries, patients with severe traumatic soft-tissue defects still represent a major surgical challenge, requiring an interdisciplinary approach. Due to the etiology of trauma, the soft-tissue damage is often more extensive than apparent at first. This zone of injury must be defined and inexperienced surgeons tend to underestimate the extent of soft-tissue injury. This may result in the patient entering the wrong therapeutic pathway. The multidisciplinary treatment strategy including timing for complex injuries of the extremities is guided by the injury pattern, ischemic time, and the general condition of the patient.

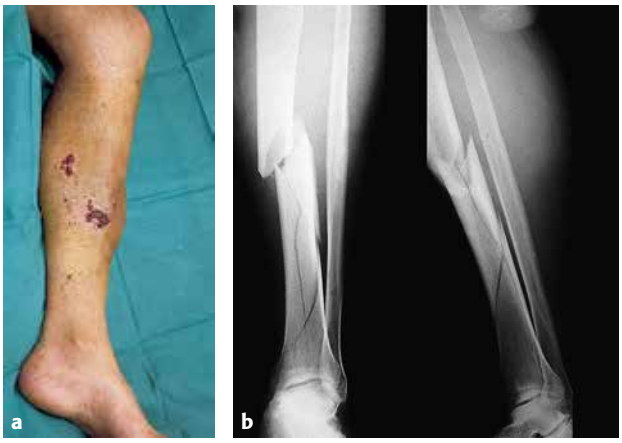

Fig 4.2-1a–b Open tibial fracture after high-energy motorcycle injury.
a Moderate size skin wound on the medial aspect of the lower leg with some closed degloving of the skin.
b Complex fracture of the tibia.

Crush injury occurs when a force is applied to an immobilized portion of the body. Localized ischemia may occur as vessels are occluded by the external pressure. Crush injury of muscles is often associated with systemic effects of the ischemia and may result in severe electrolyte disturbance and myoglobinuria. The systemic effects are directly related to the severity and duration of tissue damage. They are manifested as an ischemic phase followed by reperfusion of the damaged area once the pressure is relieved (ischemia-reperfusion injury). Products of cellular death are then circulated, causing direct toxicity to organs, such as the brain, lungs, or kidneys.

Penetrating injuries comprise a wide spectrum of soft-tissue injuries, from low-energy stab wounds to the systemic devastation of war-related blast injuries. The effectiveness of any specific weapon relies on its capacity to dissipate kinetic energy to the recipient tissue (**Fig 4.2-2**). The severity of injury is closely related to the affected structures and their location, the degree of energy dissipation, the behavior of the penetrating object within the tissue, and the degree and type of contamination. These determine the amount of damage, fatality, and long-term disability. It is imperative to understand the mechanisms leading to these injuries and the associated pathology.

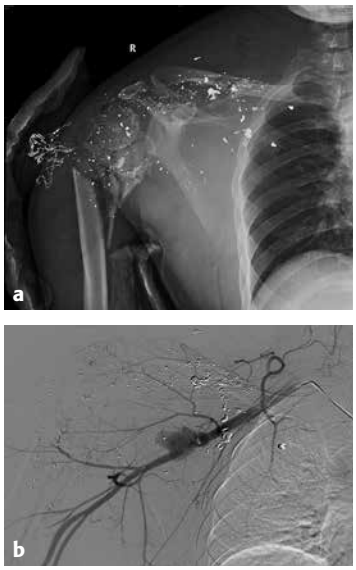

Fig 4.2-2a–b The severity of the damage resulting from a gunshot injury is related to the amount of energy dissipated at the time of impact.
a A gunshot can result in severe musculoskeletal damage as in this close range high-velocity rifle injury to the shoulder.
b Vascular injuries are common in high-energy gunshot wounds and should be actively excluded.

Explosive blasts result in high morbidity and mortality. In recent conflicts, injuries to the musculoskeletal system accounted for 54–70% of injuries, and up to 78% of these were related to explosions. Injury to the human body occurs when the rapid expansion of gas surrounding the point of explosion propagates a supersonic shock wave in all directions from the blast. The spectrum of injuries related to blasts is categorized relative to the mechanism (**Fig 4.2-3**). Shear forces cause disruption of the skin in most areas of the body. These injuries are due to high energy and are frequently associated with injuries to the deeper tissues, including fractures, disruption of muscle attachments, tearing of nerves, and avulsion of vessels. This multiplanar degloving must be recognized and treated by systematic evaluation and debridement of each tissue layer (**Fig 4.2-4**).

Fig 4.2-3 Blast injuries are different from gunshots mainly because of their multiple mechanisms of injury. They tend to involve more body regions and generally tend to be of higher severity scores.

Fig 4.2-4a–g An 80-year-old patient who was run over by a bus.
a–b The high-energy shear force resulted in a significant soft-tissues disruption.
c–e The "fix and cover" technique was implemented: open reduction and locking compression plate fixation of the tibial fracture which was covered by a rotational flap. Repeated debridement and skin grafts were needed due to the severe soft-tissue injury.
f–g Two years after injury, the united fracture and healed soft tissues are shown.

4 Epidemiology

The frequency of open fractures observed in any area varies according to geographical and socioeconomic factors, population size, and the system of trauma care. The incidence of open fractures in Edinburgh, Scotland has been documented in detail [3]. This unit treats all fractures in a mixed urban and rural population and the frequency of open fractures was 21 per 100,000 population per year (**Table 4.2-1**). The highest rate of diaphyseal open fractures was seen in the tibia (22%), followed by the femur (12%), radius and ulna (9%), and humerus (6%). In major long bones, open fractures were far more common in the diaphysis than the metaphysis (15% versus 1%).

In a later 15-year study, the same group reviewed 2,386 open fractures [4]. The majority of open fractures were the result of low-energy injuries, with only 22% caused by road traffic accidents or falls from height. High-energy open fractures were more common in younger men and low-energy open fractures were more common in older women. These data are likely to be similar in other developed countries, but will be different in emerging countries that have different demographics and social conditions.

The burden of open fractures in military conflicts is much higher. In a recent epidemiological study [5], a total of 1,281 soldiers sustained 3,575 extremity combat wounds. Fifty-three percent of these were penetrating soft-tissue wounds and 26% were fractures. The 915 fractures were evenly distributed between the upper (461 [50%]) and lower extremities (454 [50%]), and 82% were open fractures. The most common fracture in the upper extremity was in the hand (36%) and in the lower extremity, it was the tibia and fibula (48%). Explosive munitions accounted for 75% of the mechanisms of injury.

Location	Total fractures	Open fractures	Open fractures, %
Upper limb	15,406	503	3.3
Lower limb	13,096	488	3.7
Shoulder girdle	1,448	3	0.2
Pelvis	942	6	0.6
Spine	683	0	0.0
Total	31,575	1,000	3.17

Table 4.2-1 Relative frequencies of open fractures [3].

5 Microbiology

The immediate effect of a high-velocity injury producing an open fracture is contamination of the soft and hard tissues. In addition, there may be hypovolemic shock, further reducing the blood supply to bone and the muscle. The result is poor tissue oxygenation and devitalization of soft tissue and bone. This produces a perfect medium for bacterial multiplication and infection.

In civilian practice, most acute infections following open fractures are caused by pathogens acquired in the hospital (nosocomial infection). Gustilo and Anderson [6] reported in 1976 that most of infections in their prospective study of 326 open fractures developed secondarily. When left open for an extended period (≥ 2 weeks), wounds were prone to nosocomial contaminants, such as Pseudomonas species and other gram-negative bacteria. Patzakis et al [7] found that only 18% of infections were caused by the same organism isolated in the initial perioperative cultures. This contrasts with a 73% correlation in an earlier study [7]. Therefore, there is no benefit in obtaining preoperative or intraoperative cultures of open tibial fracture wounds. Additionally, postdebridement wound cultures fail to isolate the infecting organism in 58% of cases [8]. Thus, early postfracture wound cultures are also not recommended. In general, multiple wound culture specimens (five or more) should be obtained from deep tissue using sterile techniques when clinical signs of infection are present. This phenomenon of hospital-acquired bacteria and their prominent role in the pathogenesis of infection emphasizes the importance of infection control measures and early wound coverage (5–7 days).

Many factors contribute to the final outcome of an open fracture. Diabetes [9], HIV status [10], and smoking [11] are associated with delayed union and higher rates and increased severity of infections. It is important to consider these factors in the treatment plan and when counseling patients on their prognosis. An appropriate medical or specialist consultation to optimize glycemic control or to initiate HIV treatment, as well as counseling on smoking cessation, may improve the outcome.

6 Classification

An open fracture classification should be comprehensive and based on the mechanism of injury, severity of soft-tissue damage, fracture pattern, and the degree of contamination.

The classification of open fractures as described by Gustilo and Anderson [6], and later modified by Gustilo et al [12], is the most frequently quoted system in contemporary literature and is used widely. Open fractures are divided into three types in ascending order of severity, based on skin and soft-tissue damage (**Table 4.2-2**). A later modification subdivided type III injuries based on the degree of contamination, the extent of periosteal stripping, and the presence of arterial injury (**Fig 4.2-5**, **Table 4.2-3**).

This classification is relatively simple and remains a useful tool, although not accurate. It has been validated with regard to time to union, incidence of nonunion, and the need for bone grafting. Its major disadvantage derives from the subjective nature of injury description resulting in high interobserver variability [13].

Type	Description
I	Skin wound less than 1 cm
	Clean
	Simple fracture pattern
II	Skin wound more than 1 cm
	Soft-tissue damage not extensive
	No flaps or avulsions
	Simple fracture pattern
III	High-energy injury involving extensive soft-tissue damage
	Or multifragmentary fracture, segmental fractures, or bone loss irrespective of the size of skin wound
	Or severe crush injuries
	Or vascular injury requiring repair
	Or severe contamination including farmyard injuries

Table 4.2-2 Gustilo-Anderson classification of open fractures [6].

Type	Description
IIIA	Adequate soft-tissue cover of bone despite extensive soft-tissue damage
IIIB	Extensive soft-tissue injury with periosteal stripping and bone exposure
	Major wound contamination
IIIC	Open fracture with arterial injury requiring repair

Table 4.2-3 Gustilo classification of type III open fractures [6].

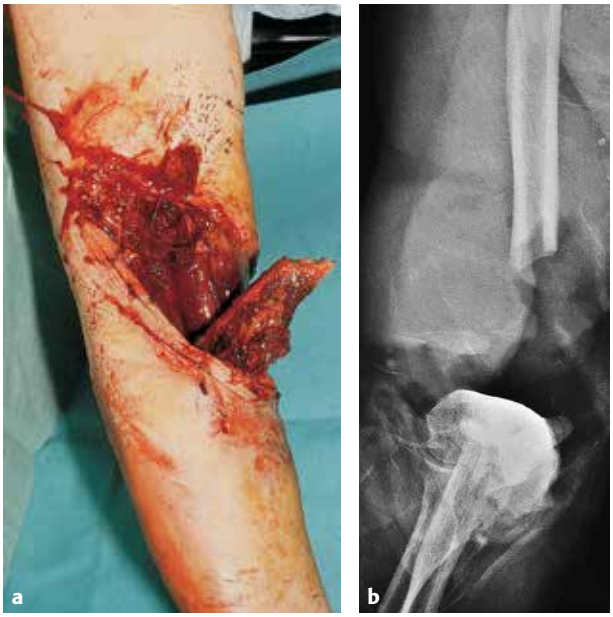

Fig 4.2-5a–b Gustilo type IIIC open fracture of the distal humerus after a high-energy motor vehicle collision. There was disruption of the brachial artery and vein and neuropraxia of the median, radial, and ulnar nerves (12C3, IO4-MT4-NV-4).

Bowen and Widmaier [14] studied 174 patients with open fractures of the long bones and found the Gustilo and Anderson classification, age, and the number of comorbidities to be significant predictors of infection. The patients were divided into three classes on the basis of the presence or absence of 14 medical and immunocompromising factors, including an age of 80 years or older, current smoking, diabetes, malignant disease, pulmonary insufficiency, and systemic immunodeficiency. Infection rates were found to be 4% for patients in class A (no compromising factors), 15% for patients in class B (one or two compromising factors), and 31% for patients in class C (three or more compromising factors).

Other classification systems have been proposed. The AO/OTA Fracture and Dislocation Classification is detailed and incorporates the Müller AO/OTA Classification of fractures in long bones. It provides grading systems for injuries of the skin, muscles and tendons, and neurovascular damage, each of which is divided into five degrees of severity (see chapter 1.4). It is designed to provide a comprehensive definition of an injury and allow accurate comparison. When used in a large database this classification permits more accurate comparison of injury types, making it a useful research tool. However, its complexity may make it impractical for everyday clinical practice.

The classification of open fractures is most reliably done in the operating room at the completion of primary wound care and debridement.

7 Goals of treatment

The treatment of high-energy injuries aims at preserving life, limb, and function, in that order of priority. The intermediate objectives are:

- Prevention of infection
- Fracture stabilization
- Soft-tissue coverage

As these goals are interdependent, a coordinated treatment plan with early surgical intervention is required. The restoration of normal function is extremely difficult to achieve in the presence of compartment syndrome, ischemia, or nerve and muscle injury. The coordination of the reconstructive procedures with the rehabilitation of the injured limb is mandatory to obtain maximal possible function.

The basic management principles established in the second half of the 20th century remain essentially unchanged:

- Initial emergency treatment: temporary splinting of the fracture, wound dressing, antibiotic therapy, tetanus immunization
- Primary surgical treatment: debridement, irrigation, and fracture stabilization
- Delayed surgical treatment: wound closure/cover within an appropriate time scale
- Rehabilitation and follow-up

Other adjuvant treatment modalities may be applied where appropriate, for example, local administration of antibiotics, vacuum-assisted therapy or flap coverage. Areas of controversy include the timing of definitive surgery, the type and duration of antibiotic administration, and indications for the use of newer adjuvant treatments.

8 Open fracture care

Achievement of these goals requires a disciplined, logical, and sequential management approach. This commences with good prehospital care and is followed by careful assessment and experienced clinical judgment in the emergency department and operating room. Primary surgical intervention focuses on the prevention of infection by staged wound debridement and fracture stabilization. Secondary surgical procedures address the issues of early skin and soft-tissue reconstruction together with bone reconstruction. Rehabilitation with early movement and mobilization is initiated as soon as possible as an integral part of this staged management protocol (**Table 4.2-4**).

1	Initial assessment	ABC s (according to ATLS)
		Emergency department management
		Wound dressing and fracture splinting
2	Primary operations	Staged wound debridement
		Fracture stabilization
3	Secondary operations	Skin and soft-tissue reconstruction
		Bone reconstruction
4	Rehabilitation	

Table 4.2-4 Stages of care for open fractures.
Abbreviations: ABC, airway, breathing, circulation; ATLS, advanced trauma life support.

For the treatment of complex open fractures, a multidisciplinary team, including orthopedic and plastic surgeons, is required [15]. Hospitals that lack a team with the requisite expertise to treat complex open fractures should have arrangements for immediate referral to the nearest specialist center. The primary surgical treatment (wound debridement and skeletal stabilization) of these complex injuries takes place at the specialist center whenever possible. In some advanced countries, specialist centers for the management of severe open fractures are organized on a regional basis as part of a regional trauma system. Usually these centers also provide the regional service for major trauma.

The characteristics of an open injury that should prompt referral to a specialist center are based on:

- Fracture patterns:
  - Transverse or short oblique tibial fracture with fibular fracture at a similar level
  - Multifragmentary tibial fractures with fibular fracture(s) at a similar level
  - Segmental tibial fractures
  - Fractures with bone loss
- Soft-tissue injury patterns:
  - Skin loss of such an extent that a direct tension-free closure is not possible
  - Degloving
  - Injury to the muscles that requires excision of devitalized muscle
  - Injury to one or more of the major arteries of the leg

The specialist center needs to:

- Provide intensive care and other trauma facilities for the multiple-injured patient
- Include orthopedic trauma surgery with special expertise in complex fractures and bone reconstruction
- Include plastic and microvascular surgery with expertise in vascular reconstruction
- Provide facilities for simultaneous debridement by orthopedic and plastic surgical teams
- Ensure orthopedic and plastic surgical planning of a management strategy to ensure efficient and optimal patient care
- Provide dedicated operating room sessions for combined orthoplastic management
- Include microbiology and infectious disease consultants with expertise in musculoskeletal infection
- Include facilities for emergency musculoskeletal imaging with angiography and interventional radiology
- Provide a service for, or have access to, artificial limb fitting and rehabilitation for amputees
- Have access to physical and psychosocial rehabilitation services
- Include an audit of outcome as part of the care pathway
- Aim to reach a throughput of 30 such cases per year to maintain appropriate skill and experience levels
- Provide multidisciplinary ward rounds and combined orthoplastic clinics

8.1 Initial assessment and management

When evaluating a patient with a high-energy extremity injury, the first priority is to identify and treat life-threatening injuries. The survival of the patient is the ultimate goal and even a severe limb injury must be kept within this "whole patient" perspective. When the immediate life-threatening conditions have been managed, the assessment of the viability of the injured limb comes next.

The assessment of any traumatized extremity must include:

- History and mechanism of injury
- Vascular and neurological status of the extremity
- Size of the skin wound
- Muscle crush or loss
- Periosteal stripping and bone vascularity
- Fracture pattern, fragmentation, and/or bone loss
- Contamination
- Compartment syndrome

Meticulous assessment of these components enables the surgeon to give an accurate description of the injury.

Some of the components of the injury are immediately evident; evaluation of others can only be performed at the time of initial debridement or subsequent debridements.

> Assessment is an ongoing process with continuing reevaluation.

Management begins at the trauma scene, where prehospital personnel should splint the limb and protect the wound with a moist sterile dressing. Thereafter, to protect the wound from further bacterial contamination, the dressing should be disturbed as little as possible.

The vascular status may be assessed by evaluation of pulses, capillary refill, limb color, temperature, and the presence of bleeding from wounds. The most important clinical sign is the presence or absence of pulses. There may be sufficient collateral circulation for the skin to remain pink while there is critical ischemia of the underlying muscles. Doppler assessment of the ankle-brachial index can be helpful

(> 0.9 is normal). A CT angiography study may also be required but should not lead to delay in treatment.

In the emergency department, only a superficial assessment of soft-tissue injuries can be performed. The history, dimensions, and location of all open wounds should be recorded. A photograph of the open wound helps to document its characteristics (**Fig 4.2-6**) and prevents multiple examinations that increase the risk of bacterial contamination.

Open fractures may be missed if the examining physician does not elevate the extremity to inspect it circumferentially.

Extensive or contaminated wounds should be lavaged with an adequate quantity of sterile saline solution. Superficial foreign bodies, such as leaves and grass, which are immediately accessible, should be removed from the wound before it is covered. The surgeon must use a sterile technique to minimize the contamination of the wound during the initial inspection phase. A clean moist sterile dressing should be applied to the wound and not be removed until the patient is in the operating room. The reduced limb is then placed in a well-padded splint.

Pulses should be documented before and after alignment. Pulses often improve with realignment; persistently diminished pulses may indicate a vascular injury and mandate further evaluation with a Doppler assessment or arteriogram. Gross motor function and sensation of the foot and leg should be documented whenever possible. Tetanus prophylaxis should be provided in any open fracture.

8.2 Antibiotics

8.2.1 Systemic administration

Most orthopedic surgeons treat severe, open extremity trauma with antibiotics that cover both Gram-positive and Gram-negative organisms. First-generation cephalosporins lower the infection rate in the treatment of open fractures [7, 16] and guidelines are given in chapter 4.5 but each institution should take local microbiology advice on the appropriate empirical treatment, as antibiotic resistance will vary from unit to unit. The use of an additional agent aimed at Gram-negative organisms (gentamicin or equivalent) remains controversial, except in cases of severely contaminated wounds, eg, barnyard wounds. Initial "prophylactic" administration of antibiotics should not exceed 72 hours to avoid selecting out resistant strains of bacteria.

8.2.2 Local administration

In a series of 1,085 open fractures, it was demonstrated that the additional use of local aminoglycoside-impregnated polymethylmethacrylate (PMMA) beads significantly reduced the overall infection rate to 3.7% compared with 12% when only intravenous antibiotics were used [17]. When the types of open fractures were analyzed separately, the reduction of infection was statistically significant only in the Gustilo type III fractures (6.5% versus 20%, respectively, for PMMA beads and intravenous antibiotics).

The advantages of the "bead pouch" technique include:
- High local concentration of antibiotics
- Low systemic concentration, which protects the patient from the adverse effects of aminoglycosides
- Reduced need for the use of systemic aminoglycosides

Fig 4.2-6a–b It is important to document the injury with a photograph. There is a small lesion injury following a crush injury to the forearm with a fracture of the radius and ulna (2R2C3, 2U2C3). Note the ischemic hand distal to the wound indicating a vascular injury.

Polymethylmethacrylate cement is the most commonly used antibiotic delivery vehicle. Typically, 40 g of PMMA is mixed with 3.6 g of tobramycin, molded into 5–10 mm spheres, and strung on nonabsorbable suture or wire. Alternatively, a cement block spacer may be formed for placement in a segmental bone defect. Most often aminoglycosides are used because of their broad spectrum activity and heat stability; however, vancomycin and cephalosporins have also been used. With the support of the hospital pharmacy, these beads can be prepared sterile and peel-packed for immediate use. This technique reduces secondary bacterial contamination by nosocomial pathogens, which have been shown to be responsible for many of the infections in Gustilo type III open fractures.

More recently, delivery of local antibiotics through bioabsorbable vehicles, such as calcium sulfate, demineralized bone matrix, and fibrin clots has shown promise in preventing infection in animal models [18]. These delivery vehicles eliminate the need for removal of PMMA cement and may reduce the number or volume of autografts while providing osteoconductive and/or osteoinductive material to aid in fracture healing.

8.3 Timing of surgery

The objectives of the initial surgical intervention are:

- Preservation of life and limb
- Wound decontamination by debridement and lavage
- Definitive injury assessment
- Fracture stabilization

The stages of open fracture management in the operating room are shown in **Table 4.2-5**.

The surgical treatment of open fractures is generally thought to be a surgical emergency. Most surgeons attempt to bring patients with open fractures to the operating room within 6–8 hours of the time of injury. This early intervention is believed to reduce the risk of infection and other complications. The 6–8 hour rule is based on basic scientific information that suggests that contaminated wounds not treated within this time frame will have sustained enough bacterial multiplication to result in early infection. However, the clinical evidence for the "6-hour rule" is lacking and some healthcare systems have accepted that a delay to surgery may be acceptable if this allows the primary surgery to be performed by a dedicated team of orthopedic and plastic surgeons who will also provide definitive care [19].

8.4 Primary surgery

8.4.1 Debridement and irrigation

Definitive injury assessment is completed in the operating room with the patient under anesthesia. The limb is reexamined clinically and additional x-rays are obtained as necessary. Traction views may be helpful and it is best to take formal x-rays of the whole bone rather than coned views with an image intensifier. The limb is cleansed with a "trauma scrub". This involves scrubbing the limb and wound with soap and saline to remove all gross dirt, debris, and contamination. The limb is then formally prepared and draped.

The concept of "the zone of injury" is important. This delineates the true dimensions of the wound as opposed to the skin wound, which is merely the window through which the true wound communicates with the exterior (**Fig 4.2-7**). In many instances this window may be small while the underlying zone of soft-tissue injury is large. This is particularly true in fractures that have ample coverage of muscle (eg, femoral or humeral shaft fractures, posterior wounds with tibial fractures).

Assessment	Assessment of wound and limb, including traction x-rays and planning
Wound management	Trauma scrub
	Surgical preparation and draping
	Surgical wound debridement
	Wound lavage
Fracture management	Surgical preparation and draping: rescrub
	Fracture stabilization
	Wound dressing and splintage

Table 4.2-5 Stages of open fracture management in the operating room.

Fig 4.2-7 Without detailed assessment of the wound, a full evaluation of the true extent of the zone of injury is impossible.

The initial surgical management should be performed by an experienced surgeon: inadequate initial debridement has been shown to contribute to poor outcomes following open fractures.

This often requires surgical extension of the traumatic wound, which must be planned carefully to minimize any further damage and should take into account the planned fixation (**Fig 4.2-8**) and potential plastic surgery procedures for wound coverage. In the tibia it is recommended that incisions are extended horizontally to the nearest "fasciotomy line" with further vertical extensions along these lines. This technique preserves perforating vessels and maximizes the reconstructive options for the plastic surgeon.

The goal of surgical debridement and irrigation of the traumatic wound is to remove all foreign material, all devitalized soft tissue and loose bits of bone, and to reduce the bacterial load. The debridement starts with careful excision of the skin margins of the traumatic wound. The subcutaneous tissue, fascia, and muscle are then methodically debrided as necessary to produce a clean, viable wound. Muscle of dubious viability must be resected to healthy tissue as assessed by color, consistency, capacity to bleed, and contractility. Major neurovascular structures should be preserved and repaired, if necessary. The bone ends should be exposed and carefully cleaned and rongeured.

The wound is then irrigated with warm saline or Ringer solution in an attempt to further reduce the bacterial load. Larger wounds benefit from larger volumes of irrigation. The traditional recommendation of 10 L is reasonable for Gustilo type III open wounds.

At the completion of debridement and irrigation, the injury should be reassessed. With the information about the severity of the wound now clearly available, the open fracture can be accurately classified.

However, it may not be possible to make the final distinction between Gustilo type IIIA and type IIIB wounds until the time of wound coverage. If in doubt, a second or third debridement after 24–48 hours should be planned. For blast injuries, serial debridement is always required because of penetration of tissues by multiple fragments. The "90% rule" is a useful rule of thumb: each debridement will remove 90% of contaminants so that 10% is left after the first debridement, 1% after the second debridement, and 0.1% after the third.

Fig 4.2-8a–d Primary wound care in the operating room of a small wound associated with a femoral shaft fracture.
a The initial trauma scrub in the operating room consists of a formal scrub of the limb with soap and saline.
b The limb is then formally prepared and draped and the wound is carefully debrided, starting with the skin and progressing layer by layer to bone. The traumatic wound may require surgical extension to allow full assessment and complete debridement.
c The bone ends are exposed and debrided.
d The wound is copiously irrigated.

8.4.2 Fracture stabilization

There is little debate about the need for reduction and stable fixation in the management of open fractures. As soon as primary wound care has been completed, treatment should proceed to fracture reduction and fixation. A stable fracture prevents further injury to the soft tissues, facilitates wound and patient care and allows early motion and function of the extremity. In multiple-injured patients who are fit for early total care, early fracture fixation is associated with reduced risks of pulmonary complications and multiple organ failure caused by the systemic inflammatory response syndrome. Depending upon the extent of injury, the fracture pattern, the location, and the general condition of the patient, temporary or definitive fixation will be chosen. Fracture stabilization can be accomplished with intramedullary (IM) nailing, external fixation, or plate and screw fixation. The choice of method depends on the fractured bone, location of the fracture (eg, intraarticular, metaphyseal, diaphyseal), soft-tissue injury, and surgeon's expertise.

The fracture in a Gustilo type I injury may be treated in the same way as a comparable closed fracture. In most cases this involves surgical fixation. The outcome of these injuries is similar to that of their closed counterparts.

Gustilo types II and III open fractures are almost inevitably displaced and unstable, which usually dictates surgical fixation. Restoring the limb to its normal length, alignment, and rotation as well as providing stability makes the ideal environment for soft-tissue healing and therefore reduces the risk of wound infection. Anatomical realignment reduces dead space and hematoma volume. Restoring stability at the fracture site prevents further damage from mobile bone fragments. The inflammatory response is dampened, exudates and edema are reduced, and tissue revascularization is encouraged.

The selection of the method of fixation remains controversial. Careful preoperative planning is essential as the surgical approach, implants, or external fixators should be placed in a way that does not compromise further orthopedic or plastic surgery procedures.

Articular fractures require anatomical reduction and fixation with absolute stability, while the nonarticular segment can be realigned and fixed with relative stability. Metaphyseal and diaphyseal fractures can be managed with various techniques. The individual bone, the fracture pattern and location, the degree of periosteal stripping and the nature of the soft-tissue envelope all influence decision making. There are situations where judicious use of joint spanning external fixators for temporary fixation is useful. The fixator can be used to maintain length and alignment until swelling has subsided and the condition of the soft tissue has improved. Ideally, the fixator should be placed well outside the zone of injury and the zone of future surgery. As soon as the soft-tissue condition permits, definitive fixation can be provided.

Regardless of whether the plan is to perform temporary or definitive fracture fixation, this fixation should proceed immediately after the completion of the debridement and irrigation. The limb should be prepared and redraped as for a new procedure. The surgeons should rescrub, regown, and reglove. A different set of sterile instruments than those used for the debridement is necessary.

Plates

Open diaphyseal fractures of the radius and ulna as well as the humerus are best managed with plate fixation. Plate fixation of lower extremity diaphyseal fractures is generally not recommended. In particular, plate fixation of open tibial shaft fractures has been reported to be associated with a high rate of infection of 20–40% [20, 21]. However, plating is the treatment of choice for many open periarticular fractures in both the upper and lower extremities and preshaped anatomical locking plates combined with less invasive approach can be effective (**Fig 4.2-9**). Staged protocols for the treatment of open, severe, high-energy proximal tibial fractures [22] involve initial treatment with a joint-spanning external fixator, followed by delayed open reduction and internal fixation, once the soft-tissue envelope has healed sufficiently.

Percutaneous plating of the tibia offers an alternative method for stabilizing complex fractures with severely compromised soft tissues, especially those injuries with periarticular extension.

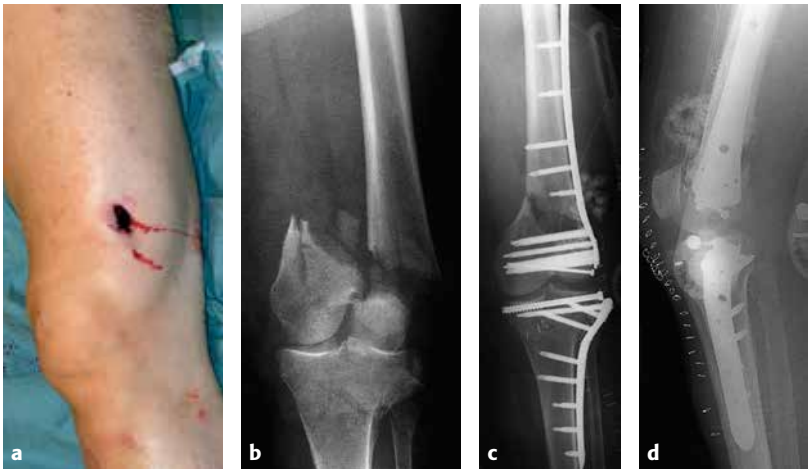

Fig 4.2-9a–d
a–b Gustilo type IIIA open fracture of the distal femur (33C2) and proximal tibia (41C1).
c–d Treatment with wound care, open reduction and internal fixation, and less invasive stabilization system of both the distal femur and the proximal tibia.

Intramedullary nails

Locked IM nailing is the treatment of choice for most diaphyseal fractures in the lower extremity with a good evidence base [23, 24]. The technique has particular value for open fractures and allows unrestricted access to the limb, and facilitates soft-tissue management (**Fig 4.2-10**). Intramedullary nails can be inserted with no further disruption of the soft-tissue envelope and preserves the remaining extraosseous blood supply to cortical bone.

Fig 4.2-10a–f The stabilization of an open segmental fracture of the tibia and fibula by a closed unreamed nail (UTN 8 mm)

a A 30-year-old mason with a complex tibial fracture with two intermediate segments after crush injury (42C3).

b A large laceration at the distal end of the leg and extensive abrasions over the tibial crest. Neurovascular status: intact. Classified as IO3-MT3-NV1.

c A postoperative x-ray after stabilization of the tibia with a statically locked 8 mm UTN.

d Thirty-six hours after open reduction and internal fixation a cancellous autograft was added to the distal fracture and the soft-tissue defect was covered by a free musculocutaneous flap.

e Uneventful soft-tissue and fracture healing; follow-up x-rays at 1 year.

f Excellent functional result.

The decision to ream the canal prior to nail insertion is controversial. Reaming has the potential to cause additional damage to the endosteal blood supply but without reaming a smaller nail will be used, resulting in less stable fixation and an increased risk of implant breakage. A recent review by Bhandari et al as reported by Mundi et al [25] provides the latest guidelines for management of complex open tibial shaft fractures. The current clinical evidence does not support the superiority of reamed or unreamed nailing in the treatment of open tibial shaft fractures (**Fig 4.2-11**) [26].

Despite the extensive utilization of both external fixation and IM nailing in the treatment of open fractures, there is a relative paucity of high-quality studies [27] comparing the efficacy of these treatment methods. A recent metaanalysis found increased rates of malunion and reoperation for external fixation compared with unreamed IM nailing, but demonstrated no difference in the rate of union or deep infection [27]. Although it appears that IM nailing does not lead to improved healing or infection rates, it is often used in preference to external fixation because it offers superior maintenance of alignment, lower secondary surgery rates, and better tolerance by patients.

External fixation

External fixation is useful for stabilizing open fractures and can be applied in almost every situation. Historically, external fixation has been used as the definitive fixation of open fractures, but it is now used more commonly for temporary fixation. The advantages of external fixation are:

- It can be applied relatively easily and quickly.
- It provides relatively stable fracture fixation.
- There is no further damage done, if applied correctly.
- It avoids implantation of hardware in the open wound.
- The reduction can be adjusted without major surgery.

Fig 4.2-11a–h The reaming of the intramedullary cavity has been considered for some time as an unsafe procedure in the treatment of open fractures due to the possibility of dissemination of infection and the destruction of circulation. However, studies have shown lower rates of infections, nonunions, and implant failures in comparison with unreamed nails [25, 26].
a–b The use of reamed nailing for a type II open fracture.
c–d Irrigation and debridement.
e Reaming and nailing.
f–h Immediate full weight bearing.

The major problems with external fixation are related to pin-track infections, malalignment, delayed union, and poor patient compliance.

External fixators are particularly useful in fractures with severe soft-tissue damage and contamination, where metallic implants, with the risk of bacterial adherence, are best avoided. Wounds from military conflict fit these criteria. External fixation is an option in diaphyseal fractures that are not amenable to IM nailing. Ring fixators can be useful for periarticular fractures. Joint spanning external fixation is a popular strategy for temporary fixation of fractures of the proximal and distal tibia as well as for fractures around the elbow and wrist (**Fig 4.2-12**).

Definitive fracture stabilization

External fixation is still commonly used for temporary stabilization in cases of massive soft-tissue damage or as a part of a damage-control protocol. Conversion to definitive fixation with an IM nail should be performed as soon as possible. If the delay is longer than 14 days, then debridement and a "pin holiday" of casting or bracing between the removal of the external fixator and the IM nailing should be planned to allow granulation of pin sites. Even with this protocol, infection may occur in 9% of patients with a 90% union rate [28]. A shorter duration of external fixation (≤ 28 days) resulted in a significantly reduced rate of infection than with longer external fixation (> 28 days).

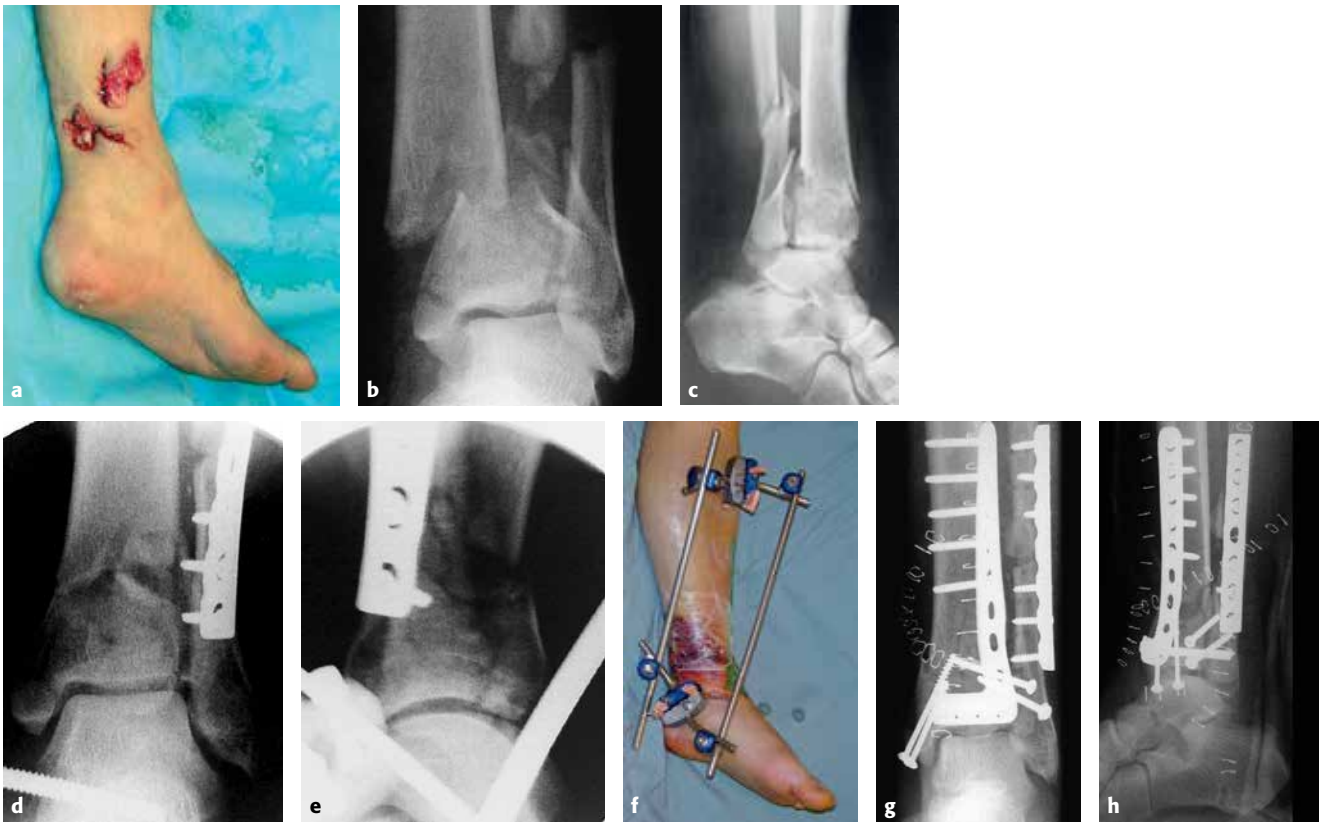

Fig 4.2-12a–h
a–c Intraarticular open fracture of the distal tibia (43C2).
d–f Initial management consisted of primary wound care, plating of the fibula, and temporary spanning external fixation.
g–h Definitive open reduction and internal fixation on day 6 when swelling is subsiding and the wound appears safe for further surgery.

Conversion to IM nailing should be undertaken as soon as the patient is able to tolerate the procedure and there is adequate soft-tissue coverage. In the management of pin-track infections, a "pin holiday" of > 10 days should be used, with debridement, irrigation, and antibiotics, to allow for pin-track granulation before IM nailing.

External fixation is an option for definitive management of open tibial diaphyseal fractures (**Fig 4.2-13**) and the circular frame can be a useful device but requires meticulous pin-site care and follow-up.

9 Wound dressing

Surgical extensions of the open wound can be closed primarily, if it is possible to do so without tension. Coverage of the open wound is controversial in terms of timing and technique. The generally accepted principle is that the open wound should be left open. This will prevent anaerobic conditions in the wound, facilitate drainage, and allow repeated debridement [29]. Recently, there has been renewed interest in primary closure of the open traumatic wound. Primary wound closure, given a clean wound, may be associated with less morbidity, shorter hospital stay, and lower costs, without the wound infection rate increasing.

Fig 4.2-13a–d The application of an external fixator in a Gustilo type IIIA open tibial and fibular fracture involving the tibial plateau and most of the shaft.

a Extensive multifragmentary fracture of proximal tibia and fibula extending into the shaft in a 47-year-old man caught under a rock (41B1, 42C2, 4F1B).

b Lag screw fixation of the articular fracture and unilateral external fixation, x-rays after 5 months and after removal of one bar.

c Follow-up after removal of the external fixator. Well-consolidated fracture.

d Clinical situation 8 months after injury. Good function.

The current standard of care for all open fracture wounds is to be left open initially. Delayed wound closure with coverage is accomplished by 2–7 days.

There are several strategies available for temporary coverage of an open wound after the initial procedure. Negative-pressure wound therapy (NWPT) exposes the wound bed to negative pressure in a closed system. The system removes fluid from the extravascular space, reduces edema, improves microcirculation, decreases tissue bacterial levels, and enhances the proliferation of reparative granulation tissue, thus improving wound healing [30]. An open-cell polyurethane foam dressing is placed into the wound and ensures an even distribution of negative pressure (**Fig 4.2-14**). The results of this technique in open fracture wound care are good. If wound coverage is delayed, NPWT may reduce the need for tissue transfer and muscle flaps [31]. However, prolonged negative pressure wound treatment is associated with high-infection rates [32] and should not be used as a substitute for early definitive plastic surgical coverage of the wound.

The antibiotic "bead pouch" technique [33] is an alternative and the efficacy of one wound dressing over another has not been established in randomized trials.

Serial wound debridement is frequently necessary. If there is any question about the viability of the wound after the initial debridement, a second look procedure should routinely be performed. In high-energy or severely contaminated injuries, serial debridement may be necessary every 24–48 hours until wound viability is ensured.

Fig 4.2-14a–c An open-cell polyurethrane foam dressing for temporary wound coverage in bilateral open tibial fractures; low-pressure vacuum drainage (negative-pressure wound therapy pump) is started following surgery.

10 Soft-tissue reconstruction

Soft-tissue reconstruction should be performed within 7 days after injury and, ideally, within 72 hours [34]. Combined orthopedic and plastic surgical treatment provides good results [35]. Surgical planning should follow a reconstructive ladder with adoption of the least complex method of soft-tissue coverage that will allow definitive wound management with a single plastic surgical procedure. The choice of flap coverage depends on the size and 3-D structure of the defect, available (recipient) vessels, available donor sites, and the general condition of the patient (**Fig 4.2-15**). This may involve local muscle of fasciocutaneous flaps or free-tissue transplantation (see chapter 4.3). There is some evidence that the application of recombinant human bone morphogenetic protein placed into the fracture site at the time of delayed wound coverage in open tibial shaft fractures reduces the risk of delayed union [36] but this is not yet firmly established as routine clinical practice.

11 Outcomes, pitfalls, and complications

The ultimate goal of open fracture management is to return the patient to normal function as soon as possible. The benefit of an aggressive approach, involving early fracture stabilization and early tissue reconstruction, is that joint and soft-tissue immobilization is avoided and early movement is facilitated. The patient and the rehabilitation team need to work together to maximize early motion of the injured limb.

The pitfalls are numerous. Infection remains a major risk and delayed union and nonunion occur more often after open rather than closed fractures. In severe injuries, particularly those with bone loss, nonunion can be predicted. Surgical intervention to reconstruct bone defects and stimulate fracture healing should be performed early. Bone grafting, when used, is usually delayed for about 6 weeks after injury when the soft tissues have healed properly. Autogenous cancellous bone grafting is the usual strategy for managing bone defects following the Masquelet technique. Complex defects may require specialized techniques including Masquelet technique, fibular transfer, free composite graft, or distraction osteogenesis.

Fig 4.2-15 The decision to use rotational muscle flaps or free flaps depends on the anatomical location of the wound, the severity of the soft-tissue lesion, and the expertise of the surgical team. In distal third tibial fractures, free muscle flaps such as the latissimus dorsi, the rectus abdominis, and the gracilis muscle are often necessary.
a Latissimus dorsi free flap harvest.
b Medial distal tibial wound that requires a free flap.
c Long-term result of such a free flap.
d Another latissimus free flap in a patient with a ring fixator in place.
e Long-term result of such a free flap.

12 Special situations

12.1 Open fractures with vascular injuries

Open fractures associated with major arterial injuries that require repair are classified as Gustilo type IIIC injuries. The principles of management of open fractures have to be combined with the principles of management of vascular injuries. Gustilo type IIIC open fractures are frequently associated with devastating damage to the bone and soft tissues. Despite strict adherence to principles and techniques, poor functional outcomes are frequent. Gustilo type IIIC open tibial fractures have a particularly poor prognosis because of the large zone of injury and the relatively fragile soft-tissue envelope.

Gustilo type IIIC open fractures require extremely careful assessment. The decision to either salvage or amputate depends on the consensus judgment of the patient and experienced orthopedic, plastic, and vascular surgeons. Salvage is technically possible in many cases. However, salvage is not always the correct choice, particularly for type IIIC open tibial fractures or in patients with polytrauma where saving life comes before saving limb. Vascular surgeons can usually revascularize the distal portion of the limb with a vein or bypass graft; direct arterial suture is rarely possible. The limb can be realigned and stabilized by the techniques described in this chapter. Plastic surgery techniques can provide soft-tissue coverage. However, in the tibia, the severity of the injury to the soft-tissue envelope and bone may result in an infected nonunion. If salvage is chosen, the patient may be subject to a long course of repeated painful and psychologically distressing surgical procedures. The functional outcome may be poor and no better than amputation [37]. The problem lies in determining which limbs can be salvaged and which are better amputated (**Fig 4.2-16**). The factors that are important in the decision making include:

- General condition of the patient (the presence of shock)
- Warm ischemia time (more than 6 hours)
- Age of the patient (older than 30 years)
- Cut to crush ratio (blunt injuries have a large zone of crush)

Numerous objective scoring systems have been proposed to aid in the identification of injuries suitable for limb salvage but these have not proven to be accurate for use in clinical practice [38].

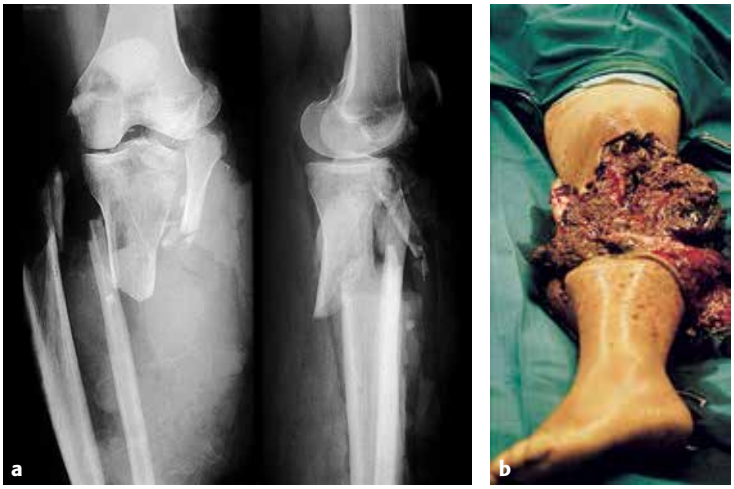

Fig 4.2-16a–b A mangled lower extremity in a 19-year-old woman with polytrauma after a motorcycle crash. There was no circulation or sensory motor activity distal to the injury (IO5-MT5-NV5). A primary amputation was performed.

The lower extremity assessment project (LEAP) study [37] group followed 569 patients to investigate the outcome of limb salvage versus reconstruction for severe lower extremity trauma, and to elucidate the variables important for predicting the outcome. Patients who underwent limb salvage and primary amputees were found to have similarly poor outcomes [39]. Perhaps more important, the LEAP series demonstrated that overall functional outcomes were affected more by a patient's economic, social, and personal resources than by the treatment course or by variables such as fracture healing and joint function. The variables that were associated with a poor prognosis included smoking, nonwhite race, poverty, lack of private health insurance, poor social support, poor self-efficacy, and involvement in a disability claim. Although several of these variables are difficult to change, assisting the patient early on in the course of recovery with psychosocial support may lead to improved overall function [40].

In cases suited for an attempt at salvage, urgent revascularization is the immediate goal. Delay for angiography should be avoided unless the level of vascular injury is not clear. The first step is to obtain proximal control of bleeding and surgeons must avoid "blind" clamping of vessels, which may increase arterial damage and injure nearby structures. The ideal strategy is to insert a temporary vascular shunt, stabilize the fracture and then perform vascular repair (**Figs 4.2-16–18**).

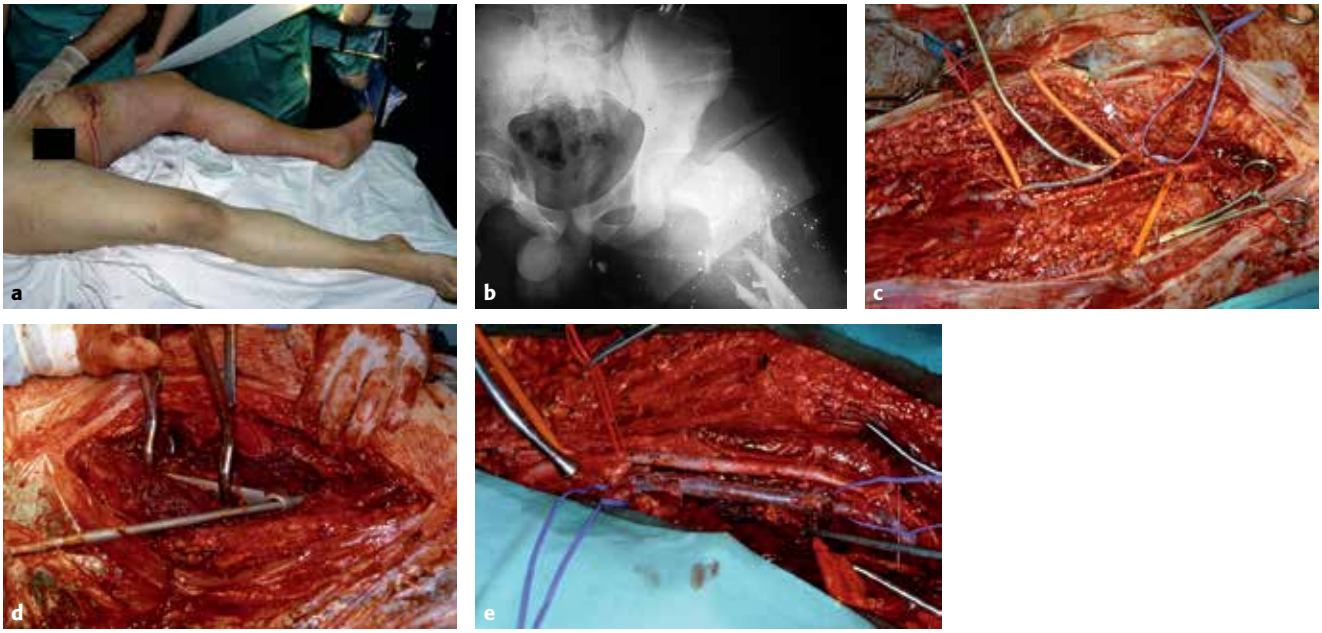

Fig 4.2-17a–e Several tactics may be used once the diagnosis of a Gustilo type IIIC open fracture of the proximal femur is obvious.
a Dysvascular left leg with a femoral fracture—note the mottling in the leg.
b X-ray showing severe fracture in the proximal femoral region.
c A temporary shunt of the superficial femoral artery is a good option to restore circulation while the fracture is stabilized.
d Definitive plate fixation of the fracture.
e Restoration of the arterial and venous flow with a reversed vein graft.

Fig 4.2-18a–f The decision whether the limb can be saved depends on many factors, such as age, prior condition, vascular lesion, presence of other lesions, among others. The decision making is more problematic in patients with bilateral severely injured mangled lower limbs. In these cases, a multiteam approach and modern microsurgical reconstructive techniques are utilized in an attempt to salvage at least one of the lower limbs.

a Blast injury with bilateral Gustilo type IIIC open fractures.

b–d At 2-year follow-up.

e–f At 11-year follow-up.

Fasciotomy is usually mandatory following an arterial repair, as reperfusion will result in swelling and can cause a compartment syndrome. Fasciotomy early in the procedure is recommended as this facilitates surgical exposure of vessels and bone.

12.2 Gunshot injuries

The severity of the damage resulting from a gunshot injury is related to the amount of energy dissipated at the time of impact ($E=\frac{1}{2}mv^2$). High-velocity rifles and close-range shotguns may cause devastating injuries because of the high energy of the impact, the secondary cavitation produced, and the secondary missile effects of shattered bone fragments. These wounds require aggressive and repeated wound debridement and external fixation is often the safest method of fracture stabilization.

Most gunshot wounds encountered in civilian practice are caused by low-velocity handguns and are less severe, unless neurovascular structures are damaged. Cavitation is not significant and, although there may be considerable bone fragmentation, the secondary missile effects are minimal and bone fragments are rarely stripped of their soft-tissue attachments and blood supply. These wounds can be managed by debridement and the fracture treated as one would treat a closed fracture. Bullets lodged in joints should be removed to avoid lead arthropathy and systemic lead poisoning (**Fig 4.2-19**).

Fig 4.2-19a–f
a–b Entrance and exit wounds of a high-velocity gunshot wound to the thigh.
c–f A proximal femoral fracture treated with statically locked intramedullary nailing.

12.3 Bone loss

Extensive traumatic bone loss is best managed at major trauma centers. Safe transfer of the patient should occur at an early stage, following adequate resuscitation. Significant bone loss is associated with extensive soft-tissue trauma and a multidisciplinary approach between orthopedic and plastic surgeons is essential. Complex soft-tissue reconstruction procedures may be required. Treatment must take account of the amount of bone loss, any associated soft-tissue injuries, and the general health and wishes of the patient. Amputation must always be considered as an option. In general, the management of the bone loss will require prolonged treatment times, especially with complex techniques such as bone transport. The patient must understand from an early stage that the treatment is likely to be long and difficult, the goal being a solid bone union, acceptable mechanical alignment, equal limb length, and acceptable restoration of function.

The use of circular external fixators in the management of bone loss is well established. The technique allows for the simultaneous treatment of bone loss, infection, nonunion, and deformity. The results of the initial management of traumatic bone loss can result in two scenarios:

1. Bone transport to maintain the overall length of the bone (with a defect that is typically > 6 cm in length). A bone segment is transported 1 mm per day with the external fixator, to eventually come in contact with the other bone segment. The trailing defect fills with regenerate bone. At the time of bone contact ("docking"), a local bone graft is often inserted to facilitate healing at this site [41].
2. Bone shortening (with a defect that is typically < 6 cm in length). The restoration of length may be achieved with an external fixator alone or in conjunction with an IM nail and is usually performed through a metaphyseal corticotomy remote from the fracture. The soft-tissue where the bone has been lost will usually be traumatized and require reconstruction but the shortening often allows local flaps and avoids the need for free-tissue transplant [42].

Osteocutaneous flaps for segmental defects of the tibia can be used for bony defects of > 6 cm in length. The available osteocutaneous flaps include the fibula and the iliac crest; however, the iliac crest is limited to a length of 10 cm. Free osteocutaneous flaps have the advantage of preservation of blood supply and thus provide viable bone without the need for creeping substitution. Free osteocutaneous flaps in the acute setting should be considered for a tibial defect of > 6 cm, with or without an associated soft-tissue defect, and when preservation of length is desired.

Cement with local antibiotics has also been used successfully in the management of large segmental bone loss in open fractures. The Masquelet technique [43, 44] involves a two-stage protocol in which antibiotic-impregnated PMMA cement spacers are inserted into segmental defects to maintain length of a bone and to induce a synovium-like foreign-body membrane. This membrane provides a contained space for future cancellous bone grafting and has been shown to secrete various growth factors that promote healing of the bone graft (**Fig 4.2-20**). This technique appears to be more effective in bones with surrounding muscle, such as the femur, than in subcutaneous bones such as the tibia.

12.4 Open joints

As with other articular fractures, joint reconstruction and stable fixation to allow early movement is key. Prevention of infection requires either arthroscopic or open irrigation of the joint [45] and all contaminants must be removed. Long-term retention of metallic foreign bodies can result either in a local reaction [46] or, in rare cases, in systemic toxicity such as lead poisoning [47]. These mandate early removal even in asymptomatic patients.

Fig 4.2-20a–e The reconstruction of diaphyseal bone defects still represents a major clinical challenge. Recently, Masquelet proposed a procedure combining induced membrane and cancellous autograft.

a–b At the first operation, radical soft-tissue and bone debridement is performed and a cement spacer is implanted. For optimum membrane induction the cement should maintain the space of reconstruction.

c In the first stage of the Masquelet technique, the soft-tissue envelope is repaired (with vascularized flap transfer, if required).

d–e At the second stage, approximately 6–8 weeks later, the cement spacer is removed and the defect is filled with cancellous autogenous bone graft.

13 Summary

An open fracture communicates with the surrounding external environment and this allows bacterial contamination with a high risk of infection. Open fractures represent about 3% of all limb fractures and most frequently occur as a result of high-energy trauma. Coexisting multiple injuries are common. The severity of injury can be classified and is the most important factor in predicting the outcome. The ultimate goal of treatment is the early return of the normal function of the limb while avoiding complications. Meticulous surgical technique and good decision making following the basic principles of soft tissue and fracture management are essential at every step. The surgical techniques are demanding and depend upon the availability of resources, including orthopedic, plastic, and microvascular surgical expertise. There are many possible pitfalls that may lead to disastrous complications. However, in most cases, these pitfalls can be avoided by careful attention to detail and the application of rational and mature clinical judgment.

Classic references **Review references**

14 References

1. **Norris BL, Kellam JF.** Soft-tissue injuries associated with high-energy extremity trauma: principles of management. *J Am Acad Orthop Surg.* 1997 Jan;5(1):37–46.
2. **Lange RH, Bach AW, Hansen ST Jr, et al.** Open tibial fractures with associated vascular injuries: prognosis for limb salvage. *J Trauma.* 1985 Mar;25(3):203–208.
3. **Court-Brown CM, Brewster N.** Epidemiology of open fractures. In: Court-Brown CM, McQueen MM, Quaba AA, eds. *Management of Open Fractures.* London: Martin Dunitz; 1996;25–35.
4. **Court-Brown CM, Bugler KE, Clement ND, et al.** The epidemiology of open fractures in adults: a 15-year review. *Injury.* 2012 Jun;43(6):891–897.
5. **Owens BD, Kragh JF Jr, Wenke JC, et al.** Combat wounds in operation Iraqi Freedom and operation Enduring Freedom. *J Trauma.* 2008 Feb;64(2):295–299.
6. **Gustilo RB, Anderson JT.** Prevention of infection in the treatment of one thousand and twenty-five open fractures of long bones: retrospective and prospective analysis. *J Bone Joint Surg Am.* 1976 Jun;58(4):453–458.
7. **Patzakis MJ, Bains RS, Lee J, et al.** Prospective, randomized, double-blind study comparing single-agent antibiotic therapy, ciprofloxacin, to combination antibiotic therapy in open fracture wounds. *J Orthop Trauma.* 2000 Nov;14(8):529–533.
8. **Lee J.** Efficacy of cultures in the management of open fractures. *Clin Orthop Relat Res.* 1997 Jun;(339):71–75.
9. **Aderinto J, Keating JF.** Intramedullary nailing of fractures of the tibia in diabetics. *J Bone Joint Surg Br.* 2008 May;90(5):638–642.
10. **Harrison WJ, Lewis CP, Lavy CB.** Open fractures of the tibia in HIV positive patients: a prospective controlled single-blind study. *Injury.* 2004 Sep;35(9):852–856.
11. **Harvey EJ, Agel J, Selznick HS, et al.** Deleterious effect of smoking on healing of open tibia-shaft fractures. *Am J Orthop (Belle Mead NJ).* 2002 Sep;31(9):518–521.
12. **Gustilo RB, Mendoza RM, Williams DN.** Problems in the management of type III (severe) open fractures: a new classification of type III open fractures. *J Trauma.* 1984 Aug;24(8):742–746.
13. **Brumback RJ, Jones AL.** Interobserver agreement in the classification of open fractures of the tibia. The results of a survey of two hundred and forty-five orthopaedic surgeons. *J Bone Joint Surg Am.*1994 Aug;76(8):1162–1166.
14. **Bowen TR, Widmaier JC.** Host classification predicts infection after open fracture. *Clin Orthop Relat Res.* 2005 Apr;(433):205–211.
15. **BOAST 4.** The management of severe open lower limb fractures. BOA/BAPRAS Standards for the management of open fractures of the lower limb, 2009. Available at: http://www.boa.ac.uk/en/publications/boast. Accessed July 2, 2011.
16. **Patzakis MJ, Harvey JP Jr, Ivler D.** The role of antibiotics in the management of open fractures. *J Bone Joint Surg Am.* 1974 Apr;56(3):532–541.
17. **Ostermann PA, Seligson D, Henry SL.** Local antibiotic therapy for severe open fractures: a review of 1085 consecutive cases. *J Bone Joint Surg Br.* 1995 Jan;77(1):93–97.
18. **Beardmore AA, Brooks DE, Wenke JC, et al.** Effectiveness of local antibiotic delivery with an osteoinductive and osteoconductive bone-graft substitute. *J Bone Joint Surg Am.* 2005 Jan;87(1):107–112.
19. **Weber D, Dulai S, Bergman J, et al.** Time to initial operative treatment following open fracture does not impact development of deep infection: a prospective cohort study of 736 subjects. *J Orthop Trauma.* 2014 Nov;28(11):613–619.
20. **Bach AW, Hansen ST Jr.** Plate versus external fixation in severe open tibial shaft fractures. A randomized trial. *Clin Orthop Relat Res.* 1989 Apr;(241):89–94.
21. **Clifford RP, Beauchamp DG, Kellam JF, et al.** Plate fixation of open fractures of the tibia. *J Bone Joint Surg Br.* 1988 Aug;70(4):644–648.
22. **Kyle JJ, Steven CL.** Staged open treatment of high-energy tibial plateau fractures. *Tech Knee Surg.*2005;4:214–225.
23. **Court-Brown CM, Christie J, McQueen MM.** Closed intramedullary tibial nailing. Its use in closed and type I open fractures. *J Bone Joint Surg Br.* 1990 Jul;72(4):605–611.
24. **Brumback RJ, Ellison PS Jr, Poka A, et al.** Intramedullary nailing of open fractures of the femoral shaft. *J Bone Joint Surg Am.* 1989 Oct;71(9):1324–1331.
25. **Mundi R, Chaudhry H, Niroopan G, et al.** Open Tibial Fractures: Updated Guidelines for Management. *JBJS Rev.* 2015 Feb 3;3(2).
26. **Study to Prospectively Evaluate Reamed Intramedullary Nails in Patients with Tibial Fractures Investigators, Bhandari M, Guyatt G, Tornetta P 3rd, et al.** Randomized trial of reamed and unreamed intramedullary nailing of tibial shaft fractures. *J Bone Joint Surg Am.* 2008 Dec;90(12):2567–2578.
27. **Giannoudis PV, Papakostidis C, Roberts C.** A review of the management of open fractures of the tibia and femur. *J Bone Joint Surg Br.* 2006 Mar;88(3):281–289.

28. **Bhandari M, Zlowodzki M, Tornetta P 3rd, et al.** Intramedullary nailing following external fixation in femoral and tibial shaft fractures. *J Orthop Trauma.* 2005 Feb;19(2):140–144.
29. **Zalavras CG, Patzakis MJ.** Open fractures: evaluation and management. *J Am Acad Orthop Surg.* 2003 May–Jun;11(3):212–219.
30. **Morykwas MJ, Simpson J, Punger K, et al.** Vacuum-assisted closure: state of basic research and physiologic foundation. *Plast Reconstr Surg.* 2006 Jun;117(7 Suppl):121S–126S.
31. **Tan Y, Wang X, Li H, et al.** The clinical efficacy of the vacuum-assisted closure therapy in the management of adult osteomyelitis. *Arch Orthop Trauma Surg.* 2011 Feb;131(2):255–259.
32. **Bhattacharyya T, Mehta P, Smith M, et al.** Routine use of wound vacuum-assisted closure does not allow coverage delay for open tibia fractures. *Plast Reconstr Surg.* 2008 Apr;121(4):1263–1266.
33. **Keating JF, Blachut PA, O'Brien PJ, et al.** Reamed nailing of open tibial fractures: does the antibiotic bead pouch reduce the deep infection rate? *J Orthop Trauma.* 1996;10(5):298–303.
34. **Godina M.** Early microsurgical reconstruction of complex trauma of the extremities. *Plast Reconstr Surg.* 1986 Sep;78(3):285–292.
35. **Tielinen L, Lindahl JE, Tukiainen EJ.** Acute unreamed intramedullary nailing and soft tissue reconstruction with muscle flaps for the treatment of severe open tibial shaft fractures. *Injury.* 2007 Aug;38(8):906–912.
36. **Govender S, Csimma C, Genant HK, et al.** Recombinant human bone morphogenetic protein-2 for treatment of open tibial fractures: a prospective, controlled, randomized study of four hundred and fifty patients. *J Bone Joint Surg Am.* 2002 Dec;84-A(12):2123–2134.
37. **Bosse MJ, MacKenzie EJ, Kellam JF, et al.** An analysis of outcomes of reconstruction or amputation after leg-threatening injuries. *N Engl J Med.* 2002 Dec 12;347(24):1924–1931.
38. **Bosse MJ, MacKenzie EJ, Kellam JF, et al.** A prospective evaluation of the clinical utility of the lower-extremity injury-severity scores. *J Bone Joint Surg Am.* 2001 Jan;83-A(1):3–14.
39. **MacKenzie EJ, Bosse MJ, Pollak AN, et al.** Long-term persistence of disability following severe lower-limb trauma: results of a seven-year follow-up. *J Bone Joint Surg Am.* 2005 Aug;87(8):1801–1809.
40. **Cannada LK, Jones AL.** Demographic, social and economic variables that affect lower extremity injury outcomes. *Injury.* 2006 Dec;37(12):1109–1116.
41. **Mekhail AO, Abraham E, Gruber B, et al.** Bone transport in the management of posttraumatic bone defects in the lower extremity. *J Trauma.* 2004 Feb;56(2):368–378.
42. **Paley D, Herzenberg JE, Paremain G, et al.** Femoral lengthening over an intramedullary nail. A matched-case comparison with Ilizarov femoral lengthening. *J Bone Joint Surg Am.* 1997 Oct;79(10):1464–1480.
43. **Masquelet AC, Fitoussi F, Begue T, et al.** [Reconstruction of the long bones by the induced membrane and spongy autograft]. *Ann Chir Plast Esthet.* 2000 Jun;45(3):346–353. French.
44. **Pelissier P, Masquelet AC, Bareille R, et al.** Induced membranes secrete growth factors including vascular and osteoinductive factors and could stimulate bone regeneration. *J Orthop Res.* 2004 Jan;22(1):73–79.
45. **Dougherty PJ, Vaidya R, Silverton CD, et al.** Joint and long-bone gunshot injuries. *J Bone Joint Surg Am.* 2009 Apr;91(4):980–997.
46. **Eylon S, Mosheiff R, Liebergall M, et al.** Delayed reaction to shrapnel retained in soft tissue. *Injury.* 2005 Feb;36(2):275–281.
47. **Linden MA, Manton WI, Stewart RM, et al.** Lead poisoning from retained bullets. Pathogenesis, diagnosis, and management. *Ann Surg.* 1982 Mar;195(3):305–313.

15 Acknowledgements

We thank Peter O'Brien and Rami Mosheiff for their contributions to the second edition of the *Principles of Fracture Management.*

4.3 Soft-tissue loss: principles of management

Yves Harder

1 Introduction

Over the last two decades, considerable advances have taken place in the management of soft tissues following extremity trauma. Several factors have contributed to this evolution, including:

- Concentration of clinical expertise in trauma centers
- Improvement in stabilization techniques and implant devices
- Development and refinement of procedures for reconstructing soft-tissue defects

However, the treatment of these injuries remains a surgical challenge and injury to the soft tissues is a key component of extremity trauma (particularly if associated with high energy) dictating both the initial, and sometimes the definitive, management of the injury, as well as being essential for bone healing [1].

Increased awareness of the importance of the soft-tissue injury and its impact on the final outcome has raised a series of questions about the assessment of the lesion, classification schemes, predictive indices, stabilization of the fracture, and the management of bone defects. Definitive answers to these questions should promote an optimal combination of techniques for bone repair and/or reconstruction and soft-tissue management.

The variation in injury patterns makes it difficult to devise a standard decision-making algorithm: every injury with a significant soft-tissue defect is unique and requires a personalized solution taking into account local factors at the injury site (the soft tissue and fracture), patient factors, and healthcare facilities [2].

Improved understanding of the blood supply to the muscles and skin, with its clinical application for wound coverage by using customized flaps of various tissues, has increased the reconstructive options available for the treatment of soft-tissue loss (**Fig 4.3-1**).

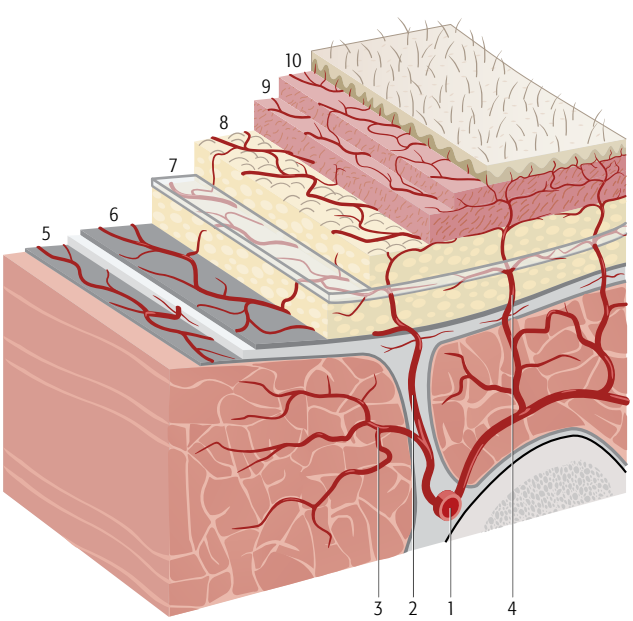

Fig 4.3-1 The cutaneous circulation passing through septa (direct cutaneous system) or perforating muscles (musculocutaneous system). Subdivision into horizontal plexuses. The segmental artery (1) splits into the septocutaneous (2), muscular (3), and musculocutaneous (4) branches. The septocutaneous and musculocutaneous vessels perforate the deep fascia (muscle fascia). The cutaneous vessels consist of perforating vessels (2, 4), of which only the vessels perforating the muscle are true perforators. After muscle perforation, these vessels continue to run perpendicular to the skin. These give rise to three horizontal arterial plexuses: the fascial plexus, which can be subfascial (5) and prefascial (6), the subcutaneous plexus within the superficial fascia of the skin (7), and the cutaneous plexus, which has three elements: a subdermal (8), dermal (9), and subepidermal (10) one.

2 Evaluation of soft-tissue defects

The following description details the clinical, radiographic, and laboratory assessment of the patient and the soft-tissue injury.

2.1 The patient

A systematic examination is essential to assess the injury correctly. A thorough case history is combined with a detailed examination of the injured limb and a general examination of the patient, which must be clearly recorded. The aim is to rapidly obtain a diagnosis that is as accurate as possible (**Fig 4.3-2**). However, clinical priorities may sometimes delay assessment, since life-threatening conditions need to be handled first. The evaluation of an unconscious patient will often be incomplete as certain aspects of the injury, such as nerve damage, cannot be assessed.

The history should include the mechanism, energy, and time of injury. General factors that influence decision making must also be evaluated. These include age, gender, head injury, vascular disease, diabetes, tetanus immunization, viral infection (eg, HIV, hepatitis B or C), and psychosocial factors, such as cognitive status, compliance, as well as addiction to drugs, nicotine, or alcohol.

2.2 The soft tissues

The value of the assessment of injured soft tissues and the classification of their severity greatly depends on the examiner's experience. Therefore, senior surgeons should be involved in this process. Often, full assessment of the extent of soft-tissue injury can only be carried out in the operating room during irrigation and debridement and/or primary fixation. The examination will allow the surgeon to evaluate the severity of the soft-tissue injury and define the "zone of injury." Photographs can be helpful for communication and reduce the need for repeated exposure of any wounds.

The assessment of soft-tissue injuries must address the following issues:

- Site, size, extent, and character of the wound (eg, crush, abrasion, defect, degloving)
- Wound contamination and/or presence of foreign bodies
- Condition of the skin (color, capillary refill, turgor, and temperature)
- Systematic evaluation of surrounding structures (eg, nerves, vessels, muscles, tendons, bone, cartilage)
- Condition of the adjacent tissues including joints above and below the injury

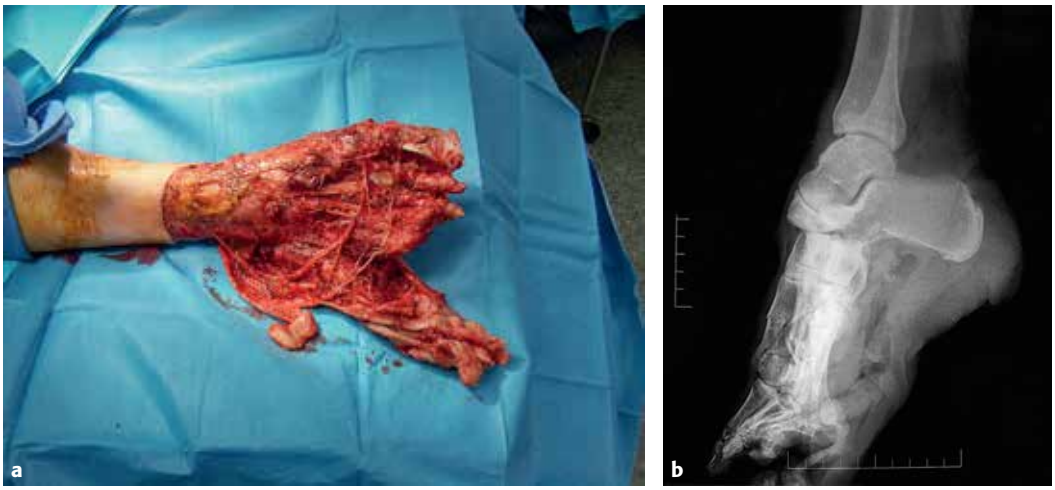

Fig 4.3-2a–b A 47-year-old man with severe trauma to the right foot and distal tibia. Considerable skin loss and degloving including skin, subcutaneous tissue, muscle, and bone.
a Dorsal view of the foot.
b Lateral x-ray.

Capillary refill is examined by applying light pressure on the skin with a finger or instrument, which is then quickly released (**Fig 4.3-3**). Scarification of the skin with a sharp needle or a scalpel may sometimes be helpful to judge dermal bleeding. Perfusion is then evaluated by judging color (eg, light red or bluish) and flow of dermal bleeding. Absent capillary bleeding is suggestive of nonviable tissue. Nevertheless, skin may reperfuse after trauma.

Bluish discoloration will indicate some injury to the skin, which may survive, whereas greyish discoloration of the skin will indicate changes beyond the skin's ischemic tolerance. All these clinical signs should be used to assess perfusion of normal skin or of a flap (**Table 4.3-1**). Muscle viability may be determined by assessing the four "C"s:

- Color
- Contractility (by mechanical or electrical) stimulation
- Consistency
- Capacity of the muscle to bleed

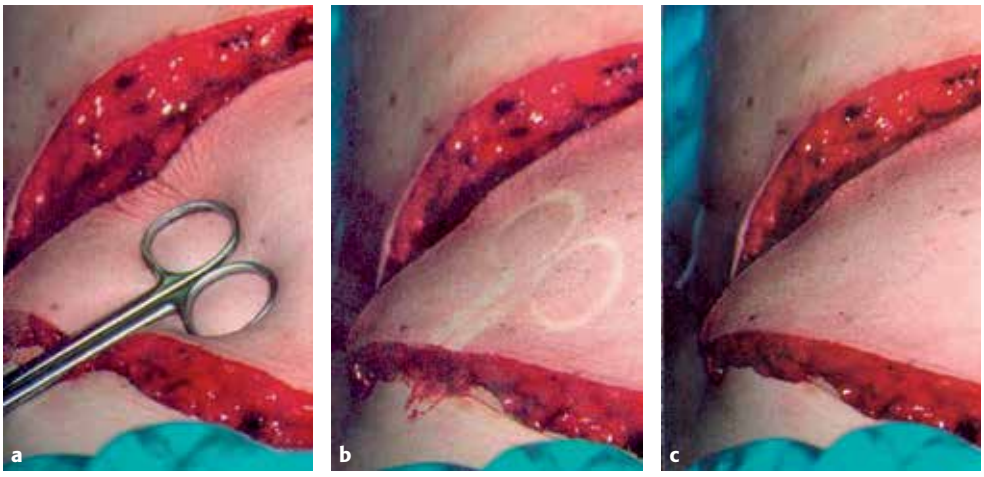

Fig 4.3-3a–c Capillary refill.
a By gently pressing scissors onto the region of interest, capillary refill can be tested.
b Observation of the imprint of the scissors.
c Fading of the imprint. A fading within about 3 seconds is normal. Rapid or slowed fading may indicate venous occlusion or arterial inflow obstruction, respectively.

	Bruise	Inflammation/infection	Arterial insufficiency	Venous congestion
Color	Purple	Red	Pale	Dark red, purple
Capillary refill	Normal	Accelerated	Slow to absent	Accelerated
Turgescence	Increased	Increased	Decreased	Increased
Surface temperature	Normal	Increased	Decreased	Normal to increased

Table 4.3-1 Clinical signs indicating compromised skin perfusion.

Absent pulses may suggest a severely injured artery proximal to the region of interest. This clinical finding cannot be ignored and must be acted on immediately. The presence of a pulse more distally does not guarantee intact vascularity because collateral vessels may maintain a palpable pulse. When a wound is situated over a tendon, the examination should include testing the tendon's function actively and passively. If in doubt, wound exploration must be carried out in the operating room and the surgeon must be prepared to repair the tendon. The viability of muscle and tendons cannot always be judged in a freshly injured patient. Necrotic tendons that are exposed over a period of days will macerate and develop a greenish discoloration. Deformity of the limb and crepitation are typical for a fractured bone, which must be verified by radiography. The following clinical signs may indicate significant injury to nerves and must be assessed immediately:

- Severe pain and dysesthesia may be due to compartment syndrome or an expanding hematoma causing nerve compression
- Massive contusion or transection of a nerve resulting in paralysis and functional deficit of a limb, foot, or hand, eg, drop foot (common peroneal nerve), wrist drop (radial nerve), claw hand (ulnar nerve), monkey hand (median nerve), or traumatic paresis of the brachial plexus
- Absence of 2-point discrimination to touch
- Lack of response to strong and painful stimuli and absence of peripheral reflexes
- Absence of sweating in the sensory distribution of the nerve

Full assessment of a soft-tissue injury often requires further investigations. Several nonclinical techniques are available to assess the injury and viability of skin (**Table 4.3-2**).

Once assessed, the soft-tissue injury must be classified using a system that includes the soft tissues such as the Gustilo-Anderson classification or the AO soft-tissue classification.

2.3 The fracture

Evaluation of the fracture requires two orthogonal x-rays centered on the zone of injury. Radiology should include the joints above and below the fracture. Complex articular and metaphyseal fractures often require additional imaging with CT scan.

Planning of surgical fixation is essential and a key strategic decision is between temporary or definitive skeletal stabilization. The technique and timing of soft-tissue reconstruction will play a key role in this decision. So it is essential that the surgical team that will perform the definitive soft-tissue reconstruction are involved in planning. Surgical approaches, as well as internal or external fixation devices, must be positioned and/or introduced in such a way that they do not compromise later orthopedic or plastic reconstructive procedures.

Definitive fixation is not mandatory during the initial surgical intervention. Often, temporary stabilization of a limb is performed using an external fixator. This damage-limitation approach provides skeletal stability to allow the extent of soft-tissue injury to demarcate itself and then recover. The external fixator should bridge the injured zone to maintain length and alignment. This may require placing fixators across joints and preliminary joint-spanning external fixators may be used for open supracondylar femoral fractures with or without tibial plateau fractures, open pilon fractures, as well as open tibial shaft fractures. Definitive fixation is performed at a later date, when swelling has settled and the full extent of the soft-tissue wound has been assessed and/or reconstructed. Definitive fixation may involve internal fixation with plates and screws, intramedullary nails, or conversion to a definitive external fixator, such as a circular frame.

	Invasiveness	Reliability	Quantification	Ease of handling
Temperature	No	Some	Some	Yes
Tissue oxygenation	Yes	Yes	Yes	Some
Acoustic Doppler	No	Some	No	Yes
Laser Doppler flowmetry	No	Some	Some	Some
Duplex, color Doppler	No	Yes	Yes	No
CT imaging	Yes	Yes	No	No
Fluorescent dyes	Yes	Yes	Some	No

Table 4.3-2 Advantages and disadvantages of nonclinical techniques to assess skin blood flow.

3 Limb salvage versus early amputation

In recent years, rescue times have decreased and neurovascular repair techniques have improved so that limb salvage of severely injured limbs with critical ischemia has become a more frequent option. A number of classification and scoring systems have been developed to help define whether limbs are salvageable or not. These include the mangled extremity severity score (MESS) [3], the limb salvage index (LSI) [4], the nerve injury, ischemia, soft-tissue injury, skeletal injury, shock, and age of the patient score (NISSSA) [5], and the Hanover fracture scale [6]. The scores emphasize the technical capability of salvaging limbs, but do not address functional outcomes or quality of life after limb salvage or amputation. The lower extremity assessment project (LEAP) is the only large study to do so [7]. Therefore, the various scoring systems have often been of limited value in the treatment of an individual patient.

In clinical practice there are clear cases that cannot be salvaged (**Fig 4.3-4**). However, the trauma surgeon is commonly confronted with severe limb injuries that technically can be salvaged. However, limitations of skill, timing or resources preclude this. When limb salvage is not possible, the key is to plan the level of amputation to preserve as much function as possible and guarantee the best possible prosthetic rehabilitation. If the limb is technically salvageable, the question confronting the surgeon is whether the patient will be functionally better off following reconstruction and limb salvage than following amputation.

Fig 4.3-4 A 37-year-old man with massive degloving caused by farming equipment. This lower limb is not salvageable.

Upper extremity: The prevailing opinion is that in the upper extremity every attempt should be made to salvage the limb (**Fig 4.3-5**). Unfortunately, there are cases when amputation is still the best option. Some cases are clearly not salvageable, including massive crush injuries with segmental bone and soft-tissue loss as well as extensive neurovascular injury. Other situations are more questionable, such as when there is traumatic loss of both the flexor and extensor compartments of the forearm. Most patients prefer a nonfunctional limb to a prosthesis in the upper extremity, thus reconstruction is more often attempted. During the initial assessment of an injured upper extremity, the surgeon should make a thorough inventory of the intact muscles, vessels, and nerves to facilitate the decision-making process. There has been tremendous technical progress in advanced prostheses in recent years. Consequently, a poorly functioning or nonfunctional hand, or a hand that causes chronic pain and has no sensation is often not as good as a good stump, especially if it is on the nondominant side. Such conditions, most often in young men, hinder reintegration into the workplace and myoelectric prostheses (ie, an "intelligent" replacement of the arm or of the hand that can be controlled by selective muscle contraction), could be a valuable option in the near future. The role of hand or arm allotransplantation has not yet been established routinely and remains a procedure to be performed in very rare and highly selected cases.

Lower extremity: The surgeon should approach severe trauma to the lower extremity with a different set of criteria than for the upper extremity because of the differences in perception of body image and the function of available reconstructive options. In some cultures, the integrity of the body and especially of the limbs may be even more important than function and this fact should not be ignored. Function should be considered from a broad perspective. Prosthetic function must be compared with the potential functional outcome of a salvaged limb. In the upper extremity, a variety of tendon or muscle transfers are possible, which may restore the function of the hand. In contrast, in the lower extremity, there are fewer options. Moreover, many good foot or ankle prosthetic replacements are available, which can replicate different functions of the foot.

The absolute indications for amputation are:

- Unstable polytrauma patient where prolonged attempts at limb salvage will put their life at risk
- Nonreconstructible vascular injury with critical ischemia
- Crush injury comprising a wide zone of the extremity, such as hydraulic press injury
- Overwhelming infection or necrotizing fasciitis
- Severe muscle, nerve and/or tendon loss over multiple compartments
- Resource issues in a country with compromised health care facilities

The patient's age, comorbidities, and general state of health at the time of the injury should be considered as relative indications for amputation and discussed on an individual base.

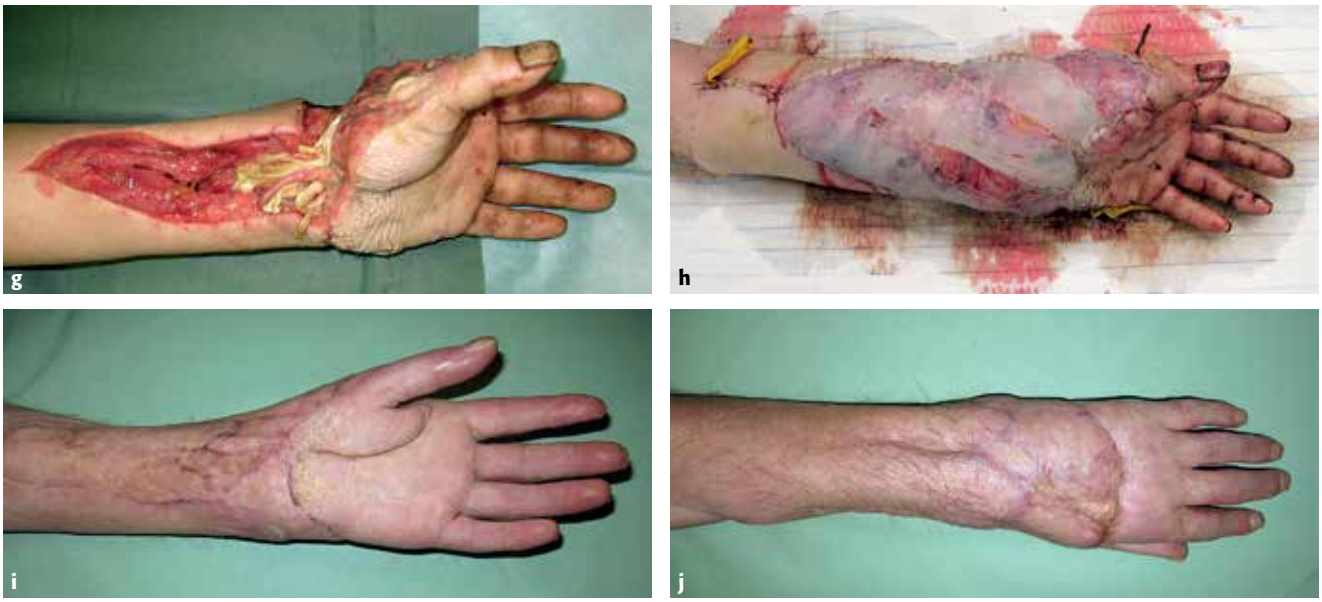

Fig 4.3-5a–j A 50-year-old man suffering from a treadmill amputation of his left nondominant hand. The attempt to salvage the hand was successful.

a Dorsal view of the hand 45 minutes after amputation. Note the extensive dirt, particularly at the tendon level.
b Palmar view.
c Dorsal view of the hand and the stump after thorough surgical debridement.
d Dorsal view after replantation of the hand including internal fixation, anastomosis of two arteries (radial and ulnar artery), three veins (the radial and an ulnar concomitant vein; deep draining system), and the cephalic vein (superficial draining system). Note the bluish skin flap at the hand's dorsum.
e Dorsal view 2 weeks after replantation. Part of the skin flap has developed necrosis and has been debrided.
f Palmar view after replantation. Note the extensive cutaneous skin defect.
g Palmar view with exposed flexor tendons.
h Palmar view 3 days after coverage of the defect using a chimeric-free muscle flap (latissimus dorsi and serratus anterior muscles) and split-thickness skin graft.
i Palmar view: follow-up at 12 months. Note the good color and texture match of the skin-grafted flap, the slight bulkiness of the flap dorsally, and the well-perfused hand with normal trophicity. Functional adduction of the fingers (intrinsic muscles).
j Dorsal view: follow-up at 12 months. Note the good color and texture match of the skin-grafted flap that has significantly atrophied.

If a lower extremity is considered to be technically salvageable, then a decision must be reached whether salvage should be attempted or not. In most situations, the functional outcome should be the primary determinant of salvage or amputation.

Surgeons should carefully assess the entire environment and circumstances in which the patient lives. They must, whenever possible, present the likely outcome of salvage versus amputation to the patient and his/her relatives, and allow them to participate in the decision-making process. Surgeons should consider the following when presenting options to the patient and/or family [7]:

- Occupation and activity of the patient
- Availability of suitable prosthetics and rehabilitation facilities
- General health, psychosocial factors, compliance, and expectations of the patient who may have to undergo multiple procedures to reconstruct the limb (eg, age, smoking, medication, diabetes, nutritional state)
- Risks associated with limb salvage procedure(s): anesthetic risks, bleeding, vascular occlusion, infection, wound breakdown, malunion, nonunion, persistent pain, multiple surgeries, long rehabilitation time, possibility of secondary amputation, long process of professional, and/or social reintegration
- Risks associated with amputation: wound breakdown, phantom sensation, phantom pain, and/or replacement costs of prosthetics
- Time it may take to reconstruct a limb versus recovery time from an amputation
- Function of the limb if all reconstructive efforts (fracture healing, soft-tissue coverage, etc) are successful
- Function of the prosthesis in the context of the patient's occupation and activities, as well as the social and cultural environment of the patient (eg, in some cultures, amputees are ostracized from society)

Patients must be made to feel that there is no right or wrong choice, only alternative ways of restoring function. Some patients and physicians will view amputation as a failure. This should be discouraged. Restoration of preinjury activities is the goal. By carefully considering the path to this goal, both patient and physician can reach the best decision.

4 Early management

Soft-tissue trauma, including thermal injury, consists of a wide range of lesions from minor to life-threatening that necessitate immediate and coordinated action by all surgical specialties involved. Prehospital triage should aim to get the patient as quickly and safely as possible to the right hospital with the facilities to provide definitive care for the injuries. So the organization of the healthcare system will have an important impact on outcomes.

4.1 Organizational aspects of the initial care

Communication with emergency department personnel should begin before the patient's arrival at the hospital. The mechanism of injury (eg, high-energy trauma vs low-energy trauma, blunt trauma vs penetrating trauma) may determine the destination of the patient. This early triage can help avoid unnecessary delays to definitive treatment [8]. In cases of severe soft-tissue injury, either as an isolated trauma or polytrauma, it is essential to include a soft-tissue specialist, preferably a plastic surgeon or a surgeon with a vast experience in soft-tissue management and reconstructive surgery, as early as possible [9]. An early interdisciplinary approach will help to correctly diagnose and classify the severity of soft-tissue lesions and plan appropriate treatment [10].

5 Interdisciplinary decision making and staging of treatment

Patients with severe, traumatic soft-tissue defects require an interdisciplinary approach [11]. The soft-tissue damage in many cases is more extensive than initially apparent and requires early assessment by experienced surgeons. Delay may result in more complicated surgical and postoperative courses, prolonged hospitalization time, and ultimately higher costs.

5.1 Role of the trauma or orthopedic surgeon

Regardless of specialization, orthopedics or trauma, it is crucial that a senior and experienced surgeon is responsible for continuing care of a specific patient. Injuries of the hand nearly always require primary consultation from a hand surgeon or surgeon trained in hand surgery. The decision to include a specialist for the management of the soft tissues should be made liberally and as early as possible to set the priorities and timing for surgical interventions.

5.2 Role of the plastic surgeon

A plastic surgeon should be included in the decision-making process at an early stage, ideally when the patient is still in the emergency department. Early formulation of a detailed treatment plan is of crucial importance and will improve outcome. Even with the appropriate clinical expertise and use of the relevant scores, amputation will be necessary in selected cases of severe soft-tissue injuries to preserve the patient's "life before limb".

5.3 Decision making for limbs at risk

Once a complex injury has been fully evaluated and surgical reconstruction appears feasible, key therapeutic priorities must be set by the team:

- Temporary vascular shunting?
- Fracture fixation before vascular repair or vice versa?
- Immediate soft-tissue coverage versus delayed soft-tissue coverage?

Generally, the procedure will start with a meticulous inspection of the wound ("inventory") in the operating room. This is also an opportunity to obtain high-quality traction x-rays of the fracture. Radical debridement of all foreign bodies, necrotic tissue including dead bone fragments, followed by wound irrigation is then performed. Only then, will it be possible to fully assess the extent of the injury and this may result in modification of the provisional surgical plan. The likely surgical exposure and the type of fracture fixation (definitive vs temporary; internal vs external) have to be decided upon and take into account subsequent debridement and later reconstructive procedures (eg, pedicle or free flap surgery). Nerve lesions are rarely treated at this early stage except in the hand. However, the specialist should be consulted with regard to how the severed nerve ends should be tagged so that they can be easily relocated during subsequent surgery. Their exact position must be recorded in the operation record, preferably with a drawing (**Fig 4.3-6**).

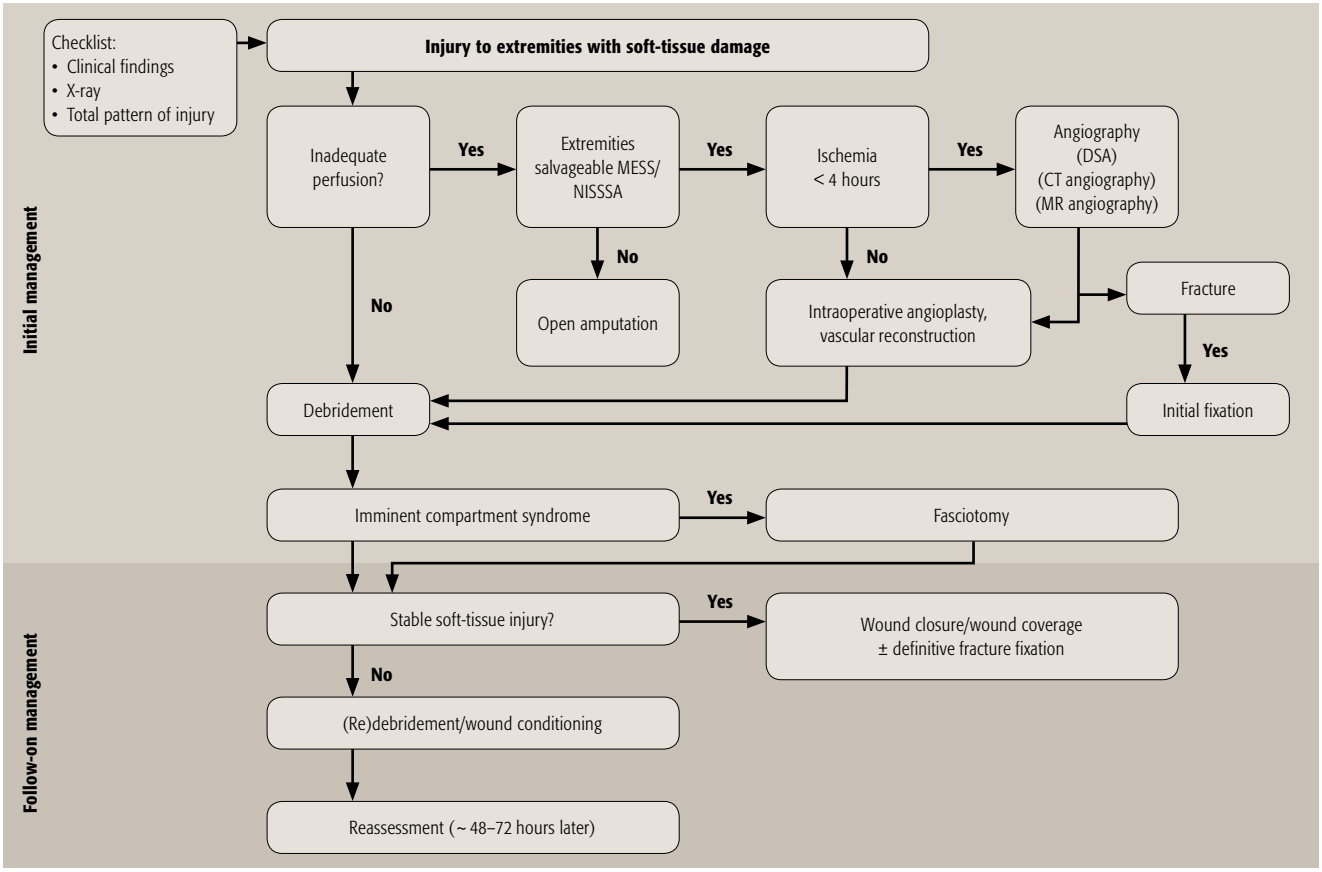

Fig 4.3-6 Algorithm for the management of complex soft-tissue injuries. Note that repeated reassessment is indicated until a stable wound is obtained.
Abbreviations: CT, computed tomography; DSA, digital subtraction angiography; MESS, mangled extremity severity score; MR, magnetic resonance; NISSSA, nerve injury, ischemia, soft-tissue injury, skeletal injury, shock, and age score.

5.4 Staging of therapeutic procedures

Several reasons may lead to a staged treatment of a complex injury of the extremity:

- Severity of the bone or joint injury and/or soft tissue injury—primary definitive repair appears too extensive and risky
- Patient condition, usually due to multiple injuries that require stabilization according to the principle of damage-control surgery
- Facilities are not suitable, experienced surgical team not available, inadequate equipment in the operating room, lack of postoperative treatment capacity, ie, intensive care unit

A well-defined staged treatment plan is required in this situation. The first stage includes intraoperative evaluation of the injury, surgical debridement and wound irrigation. Stabilization of fractures will often be achieved by external fixation. The placement of fixator pins is crucial, as they should be outside the zone of injury and not interfere with any subsequent surgical procedure (outside the zone of potential surgery). Depending on the general recovery of the patient, a second look debridement is usually planned for 24–48 hours, although some complex blast injuries may require this even earlier [12]. In patients with isolated limb trauma, the second stage may include definitive stabilization of the open fracture, including bone and soft-tissue replacement with nonvascularized or vascularized tissue (graft vs flap) or this may be planned for day 3–5 after injury. If the type of fixation has to be changed from an external to an internal fixator (eg, intramedullary nail or plate osteosynthesis), it should be done as early as possible, ideally within the first 5 days after the injury, as this will reduce the risk of infection. Patients with severe polytrauma requiring intensive care may not be fit for major reconstructive surgery within this time frame. Temporary wound management should continue often with negative-pressure wound dressings until the patient is fit for reconstructive surgery.

6 Soft-tissue reconstruction

Debridement is the cornerstone of surgical treatment of open wounds. Over time, trauma-associated wounds develop a biofilm that results from bacterial proliferation and synthesis of molecules composing the extracellular matrix. This biofilm is an infection risk and has to be included in the surgical debridement.

Debridement involves the systematic surgical removal of all foreign bodies, contaminated or nonviable, necrotic tissue from a wound with the ultimate goal to create a clean or even sterile wound. It requires wide local excision with only healthy tissue remaining and so is similar to the resection of a tumor.

The balance of providing adequate fracture fixation and the preservation of soft tissue must be individually assessed in each case. It is important to stabilize the bone, and yet prevent further damage to the local blood supply of the bone and soft tissues. Planning and a good knowledge of vascular anatomy are essential. A small but poorly placed incision for minimally invasive surgery can still damage the critical blood supply to a local flap. Factors to be considered when planning for bone stabilization include:

- Anatomical location and characteristics of the fracture
- Condition of skin and soft tissues including degloving as well as the site and size of wounds
- Degree of contamination
- Presence of other injuries
- Overall condition of the patient

6.1 Principles of soft-tissue reconstruction

Soft-tissue reconstruction should provide safe defect coverage that is also able to restore form and function and avoid donor site deformity. A few decades ago, the immediate and definitive stabilization of fractures with primary wound closure were the goal of treatment; today's trend is toward staged procedures with repeated debridement, wound conditioning and delayed closure or reconstruction of the soft tissues to reduce wound-healing complications. Sound soft-tissue reconstruction is based on knowledge of the five basic principles of soft-tissue reconstruction [13, 14]:

1. **Timing**: Once the surgical plan is established, the timing of the procedure has to be determined. Since most reconstructive procedures can wait for 1 or 2 days, this time should be used for planning and optimizing the patient's condition, eg, proper glycemic control in patients with diabetes. An interdisciplinary approach and good communication between the different teams is essential for setting priorities and the best timing for treatment. The timing and approach for secondary bone grafting, for example, will be influenced by the type of soft-tissue reconstruction and the surgeon must know the location of the vascular pedicle when he/she returns to expose the fracture and place a graft.

2. **Replace like with like**: When filling a defect, it is preferable to replace the part lost with the same tissue, eg, bone for bone, fat for fat, muscle for muscle, and skin for skin to restore normal shape and contour in terms of function, thickness, and texture as well as color and sensation of the skin. If this cannot be accomplished, the most similar tissue is chosen to reconstruct the defect with minimal donor site morbidity.
3. **Tissue bank**: The human body is a precious "tissue bank" but with limited resources. Donor site morbidity must always be included in the plan to ensure that the damage caused by harvesting does not turn out to cause more problems than the original defect. In case of limb amputation, the removed part may provide valuable tissues for reconstruction.
4. **Functional and esthetic aspects**: While esthetic aspects are less important in extremity trauma than in facial reconstruction, the restoration of function in the weight-bearing zone has to be taken into consideration and the exact placement of incisions should be planned to avoid scars within pressure zones or hinder subsequent surgery.
5. **Back-up plan**: During the intervention, adjustment of the original plan may become necessary if an unexpected situation is encountered. Since any reconstructive procedure carries a risk of failure, it is important to always have an alternative plan.

6.2 Reconstructive ladder—linear concept versus new modular approach

The original idea of the reconstructive ladder was to provide a sequence of different surgical treatment options that can be applied according to their complexity (**Fig 4.3-7**). This principle was first applied to reconstruct complex orbitofacial defects and the concept was adopted by orthopedic surgeons to reconstruct limb defects [15]. The pitfall with this rather rigid reconstructive ladder is that it implies that the simplest technique should be used first, and only proceeds to the next rung if the "simpler" one has failed or is not possible. Today, this has been modified so that the solution with the best chance of success should be applied, not the simplest one. Wound closure or cover with questionable stability should be avoided, even though the procedure is technically easy to perform and appears as the least invasive for the patient, as it will most probably only postpone the need for major surgery to a less favorable point in time when complications have arisen. As an example, a split-thickness skin graft for a considerable defect at the heel, a most important weight-bearing zone, may be an acceptable solution for a person who does not walk. However, a manual worker with a similar defect certainly will be much better served with a more extensive procedure, such as a flap that matches the local requirements. Poorly vascularized structures such as exposed bone and tendons were originally considered indications for reconstruction by a flap, since they do not provide the matrix, ie the vascularity for a skin graft in contrast to muscle, fascia, subcutaneous tissue, and dermis. The availability of negative-pressure wound therapy combined with a skin graft has, however, recently challenged this point of view [16]. The decision needs to include an evaluation of the potential long-term result and stability, donor site morbidity and rehabilitation time, together with the patient's general condition, available resources, and the surgeon's skill.

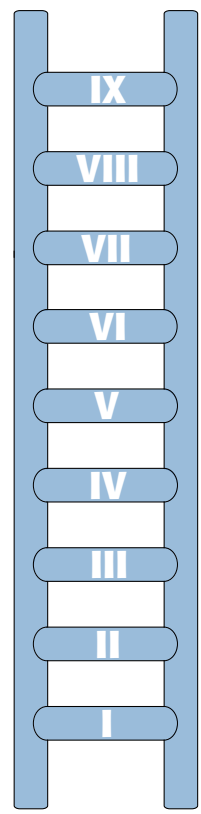

Fig 4.3-7 Classic reconstructive ladder. The simplest method which is likely to achieve stable closure or coverage should always aim to avoid complications. The next rung is only climbed, if a simpler method fails.

I Healing by secondary intention.
II Primary closure.
III Delayed primary closure.
IV Split-thickness skin graft.
V Full-thickness skin graft.
VI Tissue expansion.
VII Random pattern flap.
VIII Pedicled flap.
IX Free flap.

One rung of the traditional ladder at best represents one option of the different reconstructive procedures and it is now suggested that the single rungs of the ladder be replaced with reconstructive modules that may combine different techniques of wound cover (**Fig 4.3-8**) [17]. All types of soft-tissue reconstruction can be combined, arranged, and used as modules to provide an individually tailored solution. In the future, tissue engineering may become a module as well.

7 Types of soft-tissue reconstruction

7.1 Skin grafts

Skin grafts are cutaneous tissue compounds that are completely separated from their blood supply and donor site attachments before being grafted to another area of the body. Often, they are used when wounds cannot be completely closed after compartment releases or at the donor site of a flap (**Fig 4.3-9**).

Skin graft is indicated in wounds where primary closure is not an option and a flap is neither necessary nor feasible. Skin grafts are easy to harvest with minimal additional time for surgery and postoperative hospital stay, and, if correctly used, may offer excellent functional and cosmetic outcome. Skin grafts are indicated for any soft-tissue defect that has a viable wound bed, which will generate a neovascular blood supply for the graft, eg, granulation tissue, muscle, fascia, paratenon, adventitia, and periosteum.

The integration of a skin graft is known as engraftment or graft-take. New vascular connections between the wound bed of the recipient site and the skin graft allow healing by first intention: the lost skin is permanently replaced by healthy skin with normal tissue architecture of both epidermis and dermis. There are four distinct phases to skin graft adherence:

1. Fibrin adherence
2. Serum imbibition
3. Inosculation
4. Neovascularization and revascularization

Skin grafts are basically classified in split-thickness skin grafts and full-thickness skin grafts.

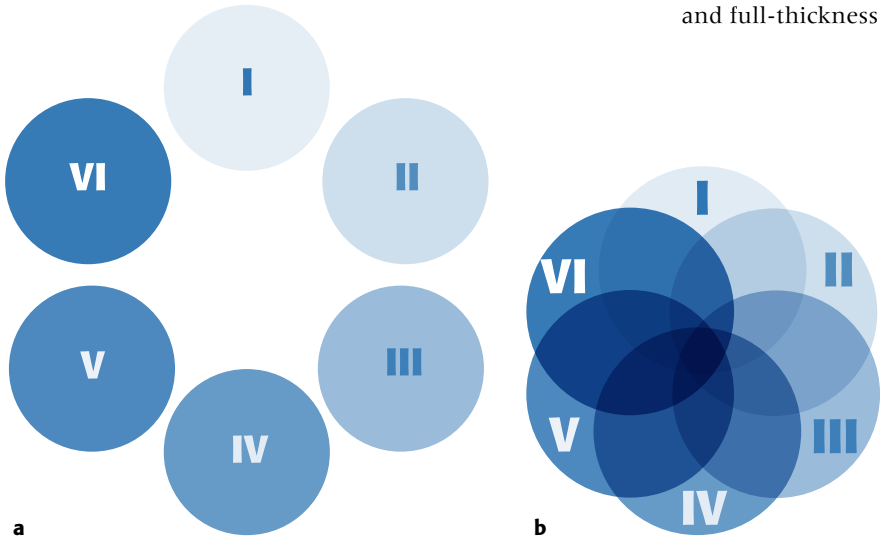

Fig 4.3-8 Reconstructive modules focus on an interaction of all methods to provide the best result.
I Split-thickness skin graft.
II Full-thickness skin graft.
III Tissue expansion.
IV Random pattern flap.
V Pedicled flap.
VI Free flap.
a The different options of the reconstructive armamentarium are represented as circles.
b Modular evolution: the different techniques of wound closure and cover interact to provide the best result. Different combinations are possible, eg, pedicled and free flap, split-thickness skin graft, and free flap etc.

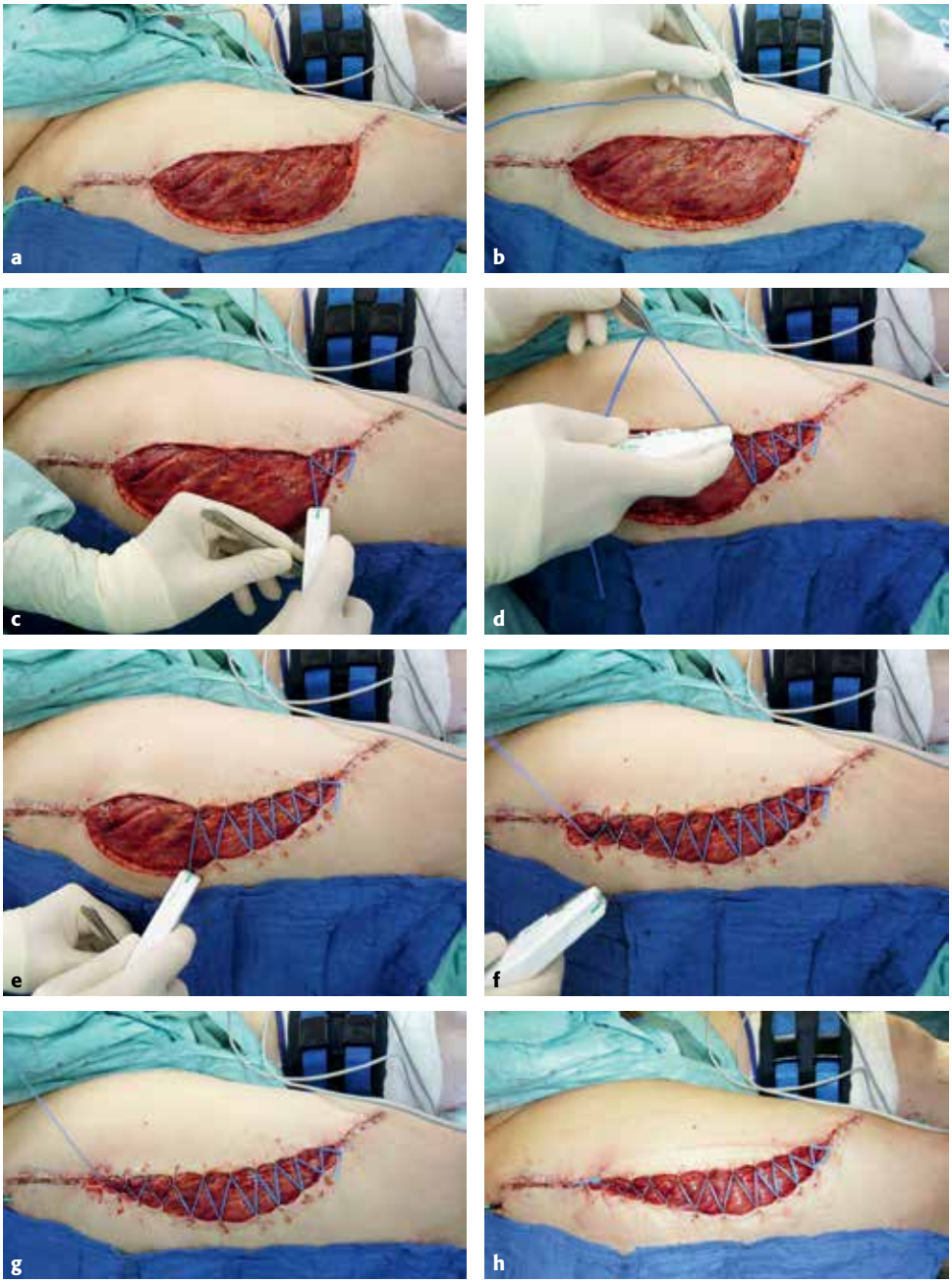

Fig 4.3-9a–h Wound closure with an elastic vessel loop or prefabricated single-use systems. This technique is used to reapproximate wound edges in wounds that show excessive swelling and no substantial skin loss. The large elastic vessel loop is stapled to the wound edges in a shoelace fashion. By providing gentle traction while swelling decreases, this method can help close these kinds of wounds within a few days.

a Surgical wound after elevation of a anterolateral thigh flap. Proximally and distally, the wound has been closed primarily.

b The end of the vessel loop is knotted and stapled onto the skin.

c–g Alternating sides, the elastic vessel loop is now placed and stapled in a zigzag manner across the wound. Despite being held in place by staples, the elastic vessel loop can still slide through the eyelets created by the staples.

h Having applied the last staple, the elastic vessel loop is fixed by tying the end into a knot that prevents the loop from slipping through the last staple. There is the possibility of tightening these "shoelaces" every other day to further approximate the wound edges.

Full-thickness skin grafts are composed of epidermis and the entire dermis. They are usually harvested from areas with sufficient laxity to permit direct closure of the donor site. The thicker the dermis, the better the nature of normal skin will be achieved after grafting. This is due to the increased collagen content and the higher number of dermal vascular plexuses and epidermal appendices contained within the deeper layers of the dermis.

Split-thickness skin grafts are composed of epidermis, including the basal membrane, and a variable thickness of dermis. Split-thickness skin grafts are most commonly used when the defect needing to be covered is of substantial size, precluding the use of a thicker full-thickness skin graft. Accordingly, split-thickness skin grafts will tolerate less ideal conditions in comparison to full-thickness skin grafts. The donor sites of split-thickness skin grafts heal spontaneously within 7–14 days from epithelial remnants within hair follicles and other dermal appendices of the deeper dermal layers. Donor sites usually allow for reharvesting once healing is complete.

Split-thickness skin grafts can be used as a meshed or unmeshed graft. In an unmeshed graft, a scalpel is often used to create small slits or fenestrations that allow the drainage of serosanguinous fluid from the wound bed through the graft. A graft-meshing device is used to generate a meshed skin graft that allows the graft to be expanded to cover up to three times the surface area. This is useful to cover large defects. However, meshing the skin graft delays the ultimate epithelialization and is cosmetically less attractive.

Degloving injuries are part of crush-avulsion trauma and are associated with severe morbidity. The skin is sheared-off from its underlying blood supply and will die if there is inadequate collateral circulation from the dermal plexus. It may be difficult, even for experienced surgeons, to determine if degloved skin is viable. If the degloved skin appears to show dermal bleeding at the wound edges before or after trimming, it is preserved. The absence of dermal bleeding makes spontaneous revascularization unlikely. The immediate use of degloved skin as a full-thickness skin graft (by excision of subcutaneous fat) or as a split-thickness skin graft is an option [18]. The grafts are immediately applied, provided the wound bed is vascularized and clean. Otherwise, the harvested skin grafts are packed in sterile gauzes and stored in a refrigerator at 4°C. Once wound conditioning has been achieved, the stored grafts may be applied after 2–5 days.

A skin graft must remain immobilized long enough to allow for successful revascularization and engraftment to the wound bed. It is essential to avoid shearing, which will prevent the new formation of microvessels or disrupt newly formed microvessels between the wound bed. The edges of the skin graft are held with sutures, staples, or tissue adhesives.

Bolstering of the graft to the wound is achieved with dressings that provide uniform pressure over the entire graft site to:

- Minimize dead space
- Reduce hematoma and seroma formation—immobilize the graft to decrease the risk of shear forces

Ideally, the dressing should be simple to apply and economical in terms of dressing material and necessary personnel. Many types of dressings have been proposed and include simple sterile gauze, cotton balls, resin molds, and foam pads. Bolster dressings are useful over joints or other areas, where motion is difficult to avoid as well as in wounds with irregular contours such as deep concave areas, where it is difficult to secure a dressing. It is useful to apply a nonadherent material directly to the graft to act as an interface. The bolster dressing is fixed with a semi-occlusive dressing material or tie-over dressing that results from sutures placed radially around the wound. For larger, irregularly contoured wounds with difficult topography or wounds with high levels of exudate, the application of a negative-pressure-wound-therapy device is useful.

7.2 Flaps

A flap is a unit of one or more tissues that maintains its own blood perfusion through a vascular pedicle. Flaps are required to cover tissue defects that have poor vascularity or which expose implants. Flaps range from a simple advancement of skin and subcutaneous tissue (pedicled flaps) to composite units that may consist of any type of tissue including skin, subcutaneous tissue, muscle, bone, fascia, and even nerve and tendon. For distant transplantation, the donor-site vessels are reconnected by micro-anastomosis of an artery, at least one vein and sometimes a sensory nerve (microvascular flap).

Flaps are commonly classified by (**Table 4.3-3**) [19]:

- Anatomy of vascular supply (eg, source vessel)
- Method of transfer (eg, technique of flap elevation and movement)
- Tissue composition (eg, tissues that constitute the flap)

Classification parameter	Subdivisions		Further subdivision/ comment
Type of vascular supply	Random (nonspecific blood supply of the dermal and subdermal plexuses)	Components: skin and subcutaneous tissue, muscle rarely	Width-to-length ratio differs according to anatomical region
	Axial (at least one specific arteriovenous system)	One or more of the following components: skin, muscle, fascia, bone	Pedicled: single-pedicled, multipedicled
			Free (microvascular)
			Perforator
Type of transfer	Local	Advancement	Pedicled: single-pedicled, bipedicled (pedicled and microvascular)
			V-Y
			Y-V
		Rotation	About a pivot point
		Transposition	About a pivot point
		Interpolation	About a pivot point
	Regional	–	Base of the pedicle in contiguity with the defect
	Distant	Pedicled (attached)	Cross-finger, cross-leg, island
		Free (detached)	Microvascular
Type of tissue composition	Skin	–	–
	Subcutaneous tissue	–	–
	Fascia	–	–
	Bone and periosteum	–	–
	Cartilage	–	–
	Nerve	–	–
	Composite	Fasciocutaneous	–
		Musculocutaneous	–
		Osteoseptocutaneous	–
		Neurocutaneous	–
Time of flap preparation	Immediate	–	–
	Delayed	Surgical delay	–
		Delay due to tissue expansion	–
		Physical delay	–
		Chemical delay	–
Type of pedicle	Skin	Single-pedicled	–
		Bipedicled	–
	Nonskin	Subcutaneous tissue	–
		Fascia	–
		Muscle	–

Table 4.3-3 Classification and nomenclature of flaps according to different characteristics. Table modified according to Selected Readings in Plastic Surgery, Volume 9, Number 2, 1999, page 2, University of Texas, Southwestern Medical Center at Dallas, Baylor University Medical Center.

7.2.1 Local flaps (pedicled flaps)

Local flaps are used to close defects that are immediately adjacent to the flap's donor site. They are classified according to the respective technique of transfer, including advancement, rotation, transposition, and interpolation.

- Advancement flaps are advanced along the long axis of the flap, from the base toward the defect. V-Y advancement is a modification of the advancement flap (eg, VY posterior thigh flap to cover ischial pressure sore).
- Rotation flaps are rotated about a pivot point into the defect (eg, rotation flap to cover sacral pressure sore).
- Transposition flaps are rotated about a pivot point into the defect with lateral movement (eg, cheek advancement flap).
- Interpolation flap are rotated about a pivot point into the defect that is nearby but not directly adjacent to the donor site, so that its pedicle must pass over or under the intervening tissues (eg, Z-plasty).

Local flaps usually consist of skin and subcutaneous tissue and lack any defined alignment or axial orientation of feeding arterioles and their respective draining veins. The viability of the transferred flaps depends on the perfusion within dermal and subdermal plexuses, and the design of the flap (length-to-width ratio). In the lower extremity and the hand, width-to-length ratios of 1:1 to 1:2 are acceptable (**Fig 4.3-10**). As an option, the ratio can be increased in favor of length by the techniques of surgical delay or tissue preconditioning. The overall distance of possible advancement mainly depends on the elasticity of the skin. The skin of the donor site should be rather loose and the flap's contour should be integrated within anatomical or cosmetic units to achieve an optimal result. However, in acute extremity trauma that includes soft tissues, one must consider that the skin and subcutaneous tissue adjacent to the directly injured soft tissue is within the zone of injury and its vascularity may be jeopardized, particularly after flap dissection.

Axial pattern flaps are characterized by a well-defined vascular pedicle consisting of one artery, two concomitant veins, and lymph vessels that are sometimes accompanied by a nerve. This vascular bundle runs in the subcutaneous fat immediately above the muscle and its fascia and parallel to the skin surface or within the muscle. The longitudinal course of the arteries allows elevation of a circumscribed unit of skin and subcutaneous tissue or a muscle with or without overlying skin. Taylor [20] defined the concept of angiosomes, ie, composite anatomical vascular territories of the skin that are supplied by vessels originating from segmental cutaneous (eg, superficial circumflex iliac artery) or muscle arteries (eg, fibular artery) that are interconnected. There are a large number of potential axial pattern flaps (~ 400) that are based upon vessels perforating muscles (ie, true musculocutaneous perforators) or vessels running along septa (eg, septocutaneous perforators) [21].

7.2.2 Regional flaps (pedicled flaps)

Regional flaps are characterized by a pedicle that remains in continuity with the tissue defect while the transferred tissue (eg, skin, muscle, bone) originates from the same extremity. If the pedicle consists of the vascular bundle, and sometimes an accompanying nerve and more or less of the surrounding adipose tissue (eg, pedicle without skin), the flap is called an island flap. Accordingly, these flaps have a longer arc of rotation compared with local flaps.

Typical regional flaps are the lateral arm flap, the radial forearm flap, the distally based sural flap, the lateral supramalleolar flap, the medial plantar flap (instep flap), the gastrocnemius flap (medial and lateral head), and the soleus flap (**Fig 4.3-11**).

Currently, there is no clinical evidence of the superiority of muscle flaps over fasciocutaneous flaps in trauma surgery. The dissection of a fasciocutaneous flap is more demanding than the dissection of a muscle flap and therefore more time consuming. Muscle flaps can also be combined with a skin island (musculocutaneous flaps) or if muscle alone is used, the flap needs to be covered with a skin graft (usually meshed split thickness skin graft). Muscle flaps have a higher density of microvascular networks and hence a better perfusion, but have not yet been proven in clinical practice to release higher concentrations of antibiotics at the recipient site or to promote better bone healing. If the soft-tissue defect is associated with a cavity, muscle flaps are preferred because of their bulkiness and capacity to fill the cavity. Esthetic outcome of either flap type can be satisfactory but muscle flaps may require a debulking procedure once the fracture has healed.

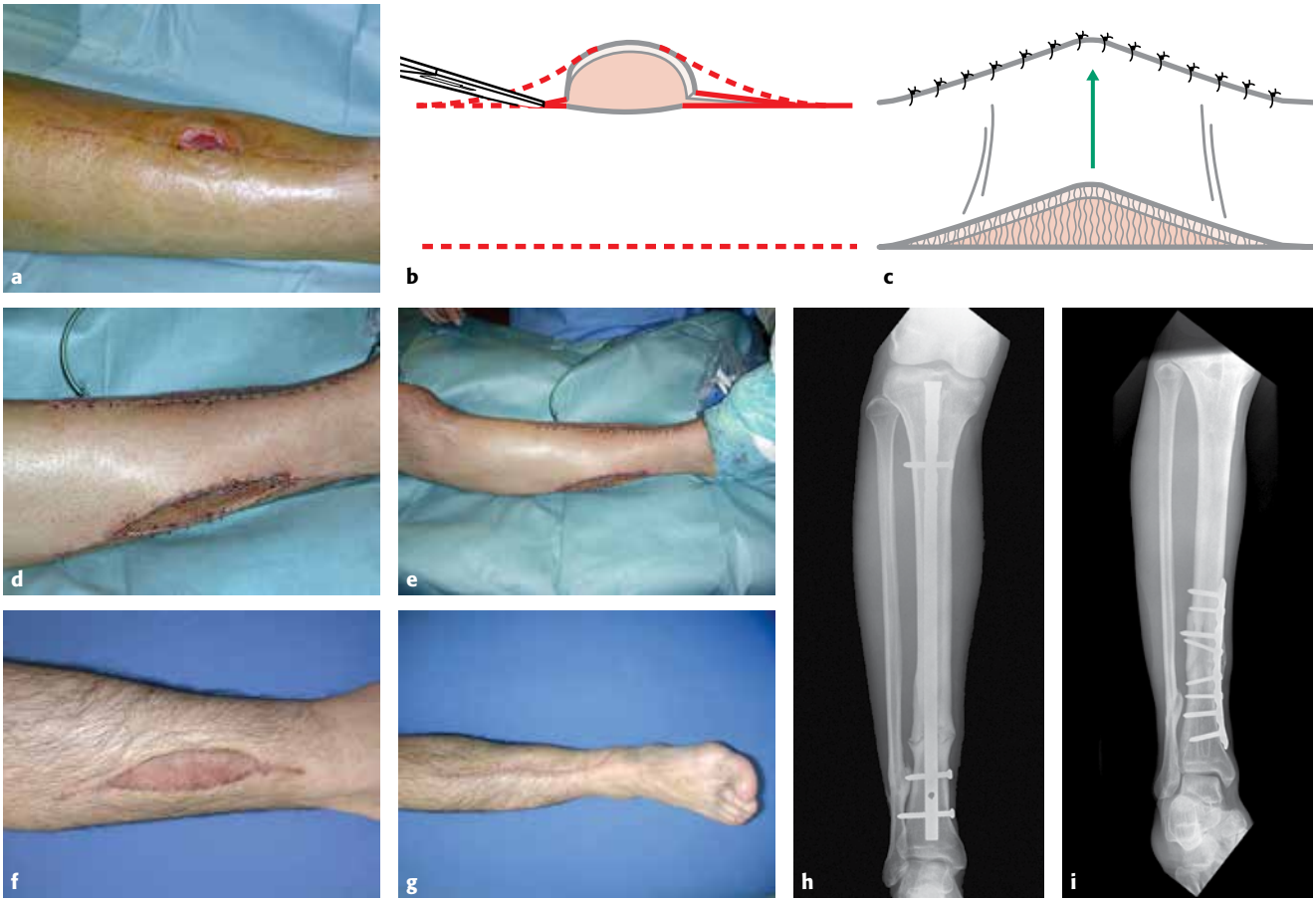

Fig 4.3-10a–i A 38-year-old man with a chronic wound associated with a hypertrophic nonunion 1.5 years after an open fracture of the distal third of the right leg (Gustilo IIIA).

a View of the leg with a longitudinal scar along the tibial crest. At the transition of the middle to the distal third of the leg, supposedly well-vascularized wound of about 4 cm in diameter with macroscopically clean granulation tissue.

b–c Schematic drawing of a bipedicled (cranial and caudal inflow) fasciocutaneous flap transposed medially into the defect.

d Intraoperative photograph after excision of the granulation tissue and transposition of the bipedicled flap. Tension-free closure using subdermal and transcutaneous stitches.

e The donor site is covered with a meshed split-thickness skin graft.

f At 6-month follow-up, perfectly integrated split-thickness skin graft.

g Well-healed anterior tibial scar.

h Fracture of the right lower leg immediately before extraction of the nail and plate fixation showing a hypertrophic nonunion.

i Complete healing of the fracture at 6 months.

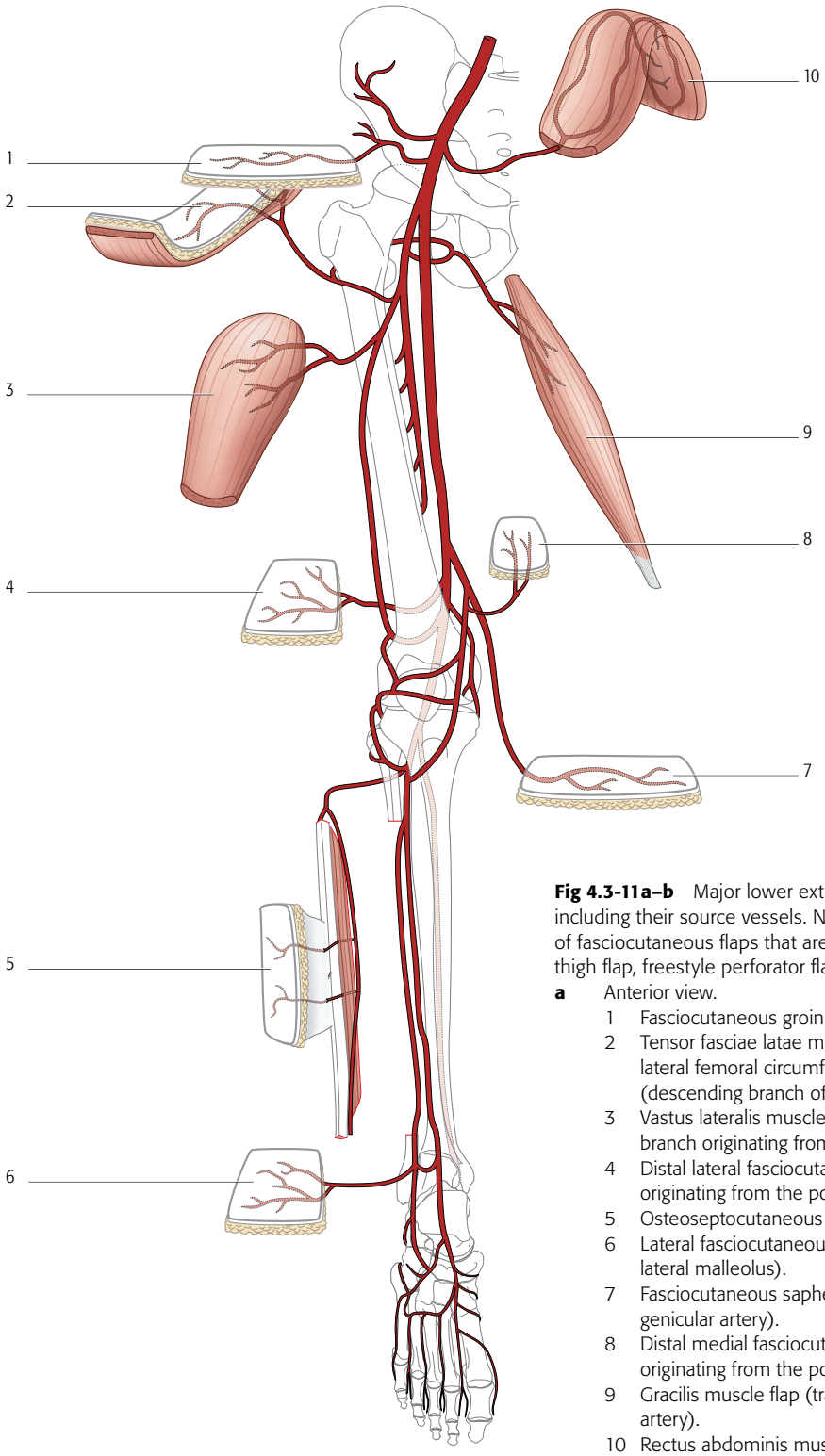

Fig 4.3-11a–b Major lower extremity vessels and sketch of respective flaps including their source vessels. Note that this sketch does not show the multitude of fasciocutaneous flaps that are based on perforating vessels (eg, anterolateral thigh flap, freestyle perforator flaps).

a Anterior view.

1 Fasciocutaneous groin flap (superficial iliac circumflex artery).
2 Tensor fasciae latae musculocutaneous flap (transverse branch of the lateral femoral circumflex artery); anterolateral fasciocutaneous thigh flap (descending branch of the lateral femoral circumflex artery).
3 Vastus lateralis muscle flap (perforating vessels from the descending branch originating from the deep femoral artery).
4 Distal lateral fasciocutaneous thigh flap (lateral collateral artery originating from the popliteal artery).
5 Osteoseptocutaneous fibula flap (fibular artery).
6 Lateral fasciocutaneous supramalleolar flap (arterial arch surrounding the lateral malleolus).
7 Fasciocutaneous saphenous flap (terminal branch of the descending genicular artery).
8 Distal medial fasciocutaneous thigh flap (medial collateral artery originating from the popliteal artery).
9 Gracilis muscle flap (transverse branch of the medial femoral circumflex artery).
10 Rectus abdominis muscle flap (deep inferior epigastric artery).

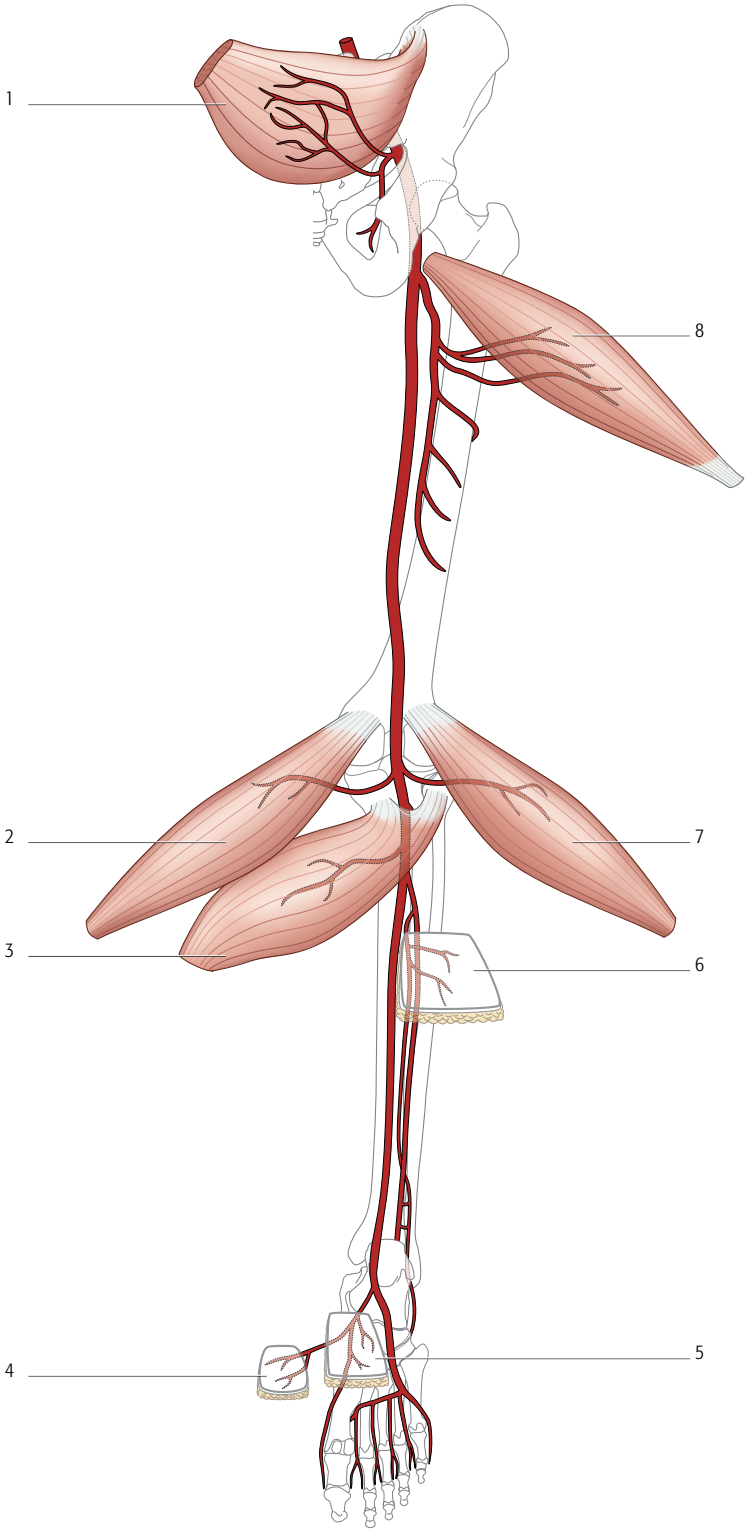

Fig 4.3-11a–b (**cont**) Major lower extremity vessels and sketch of respective flaps including their source vessels. Note that this sketch does not show the multitude of fasciocutaneous flaps that are based on perforating vessels (eg, anterolateral thigh flap, freestyle perforator flaps).

b Posterior view.

1 Gluteus maximus muscle flap (inferior and superior gluteal artery).
2 Medial gastrocnemius muscle flap (medial sural artery).
3 Soleus muscle flap (branches originating from the tibial and fibular artery).
4 Medial fasciocutaneous foot flap (cutaneous branch originating from the medial plantar artery).
5 Fasciocutaneous instep flap (medial plantar artery).
6 Sural fasciocutaneous flap (sural artery with reversed flow).
7 Lateral gastrocnemius muscle flap (lateral sural artery).
8 Biceps femoris muscle flap (branches originating from the deep femoral artery).

7.2.3 Distant flaps (microvascular flaps)

In the late 1980s, microvascular flap surgery became a standard procedure. This facilitated many limbs being saved because it had become possible to "repair" almost any defect at any site of the body. The microvascular flaps commonly used in trauma surgery include muscle flaps (eg, gracilis, latissimus dorsi), musculocutaneous flaps (eg, latissimus dorsi), and fasciocutaneous flaps (eg, scapular/parascapular flap, anterolateral thigh flap, lateral arm flap, and radial forearm flap). The range of flaps has increased dramatically and now almost every muscle and/or the overlying skin can be raised as a microvascular flap and customized to the soft-tissue defect. Continued refinements in microvascular flap surgery are focused upon reducing donor site morbidity and suitability at the recipient site (tissue composition, volume, texture, and color) (**Fig 4.3-12**).

8 Postoperative care and secondary surgery

8.1 Postoperative care

Postoperative management includes sterile dressing, immobilization and splinting of the involved extremity, elevation (to the level of the heart), and close observation of neurovascular status and flap perfusion. Patients with uncomplicated wounds that are well bandaged may be mobilized immediately after surgery.

For skin grafts, the goal is to have maximum adherence between graft and wound bed to permit vascular ingrowth. Any mobilization that causes shear forces at the graft-wound interface must be prevented. Vertical positioning of the reconstructed area and vertical forces have to be avoided to prevent damage to the newly formed and immature microvessels. Ideally, mobilization should be postponed for 4–5 days until the skin graft has adhered to the wound bed and is stable. Thereafter, cautious mobilization is allowed, using a circular bandage or a compression stocking.

Postoperative immobilization of the patient will usually take 2 days for pedicle flaps and 5 days for microvascular flaps. This depends on several factors, including flap type and site, patient comorbidities, and patient compliance. The affected limb should be wrapped with an elastic bandage or a compression stocking. If a free flap has been transferred to the lower extremity, a training phase of progressively increasing intervals of about 30 minutes per day with the leg dependent is recommended. In general, the weight-bearing status is dictated by the fracture rather than the soft tissues.

Once postoperative wound healing is completed after 2–3 weeks and postoperative edema has regressed, compression bandages may be substituted for custom-made compression garments that should be worn during daytime to prevent swelling of the flap. Atrophy of muscular and musculocutaneous flaps takes about 3 months. Fasciocutaneous flaps flatten as the lymphatic drainage improves and not secondary to atrophy. Thus, volume decrease takes longer than in muscle flaps.

If a fracture fixation associated with complex reconstruction of the soft tissue is not stable enough, additional splints and plasters have to be added for additional protection of the soft tissues. In addition, soft-tissue reconstructions that include repair of tendons, vessels and/or nerves may require specific temporary static or dynamic immobilization. In general, splints and casts bear the risk of compressing the skin overlying a bony protuberance. A pedicle flap as well as a skin graft or flap that has reduced or no sensibility is at risk of pressure sores.

8.2 Secondary surgery

If revision or secondary surgery is needed for bone, tendon, or nerve reconstruction, complete wound healing should be achieved before further surgery. At 6 weeks, the Masquelet bone-grafting procedure can be used beneath a flap to provide bone at a site of bone loss [22]. This should be planned and/or performed with the surgeon who made the flap to insure that a safe corridor for bone placement is used. Bear in mind that fasciocutaneous flaps will integrate (engraft) much better within the surrounding tissues compared with muscle flaps, which usually remain dependent upon their pedicle.

Fig 4.3-12a–f Free fasciocutaneous radial forearm flap.

a Open bimalleolar fracture initially treated by external fixation. Subsequent skin necrosis developed, exposing the medial malleolus.

b After debridement and switching from external fixator to open reduction and internal fixation. Exposed implant material and bare tibial bone.

c Marking of the rectangular skin island proximally to the wrist's crease. Superficial veins are also marked to be included within the vascular pedicle.

d Immediately after defect coverage using a free fasciocutaneous radial forearm flap and a small meshed split-thickness skin graft to cover the pedicle proximally and to prevent it from coming under too much tension.

e Six months after soft-tissue reconstruction. The forearm skin is well integrated within the surrounding skin of the ankle. The appearance of the split-thickness skin graft remains slightly hyperpigmented and shiny, with a permanent diamond-shaped pattern.

f Six months after flap harvesting. Soft-tissue padding is missing after split-thickness skin grafting of the donor site. The flexor carpi radialis and palmaris longus tendons are well covered.

Classic references | Review references

9 References

1. **Norris BL, Kellam JF.** Soft-tissue injuries associated with high-energy extremity trauma: principles of management. *J Am Acad Orthop Surg.* 1997 Jan;5(1):37–46.
2. **Volgas DA, Harder Y** *Manual of Soft-tissue Management in Orthopaedic Trauma.* 1st ed. Stuttgart and New York: Thieme.
3. **Johansen K, Daines M, Howey T, et al.** Objective criteria accurately predict amputation following lower extremity trauma. *J Trauma.* 1990 May;30(5):568–573.
4. **Russell WL, Sailors DM, Whittle TB, et al.** Limb salvage versus traumatic amputation. A decision based on a seven-part predictive index. *Ann Surg.* 1991 May;213(5):473–480; discussion 480–481.
5. **McNamara MG, Heckman JD, Corley FG.** Severe open fractures of the lower extremity: a retrospective evaluation of the Mangled Extremity Severity Score (MESS). *J Orthop Trauma.* 1994;8(2):81–87.
6. **Tscherne H, Oestern HJ.** [A new classification of soft-tissue damage in open and closed fractures]. *Unfallheilkunde.* 1982 Mar;85(3):111–115. German.
7. **Mackenzie EJ, Bosse MJ.** Factors influencing outcome following limb-threatening lower limb trauma: lessons learned from the lower extremity assessment project (LEAP). *J Am Acad Orthop Surg.* 2006;4(10):205–210.
8. **Sampalis JS, Denis R, Fréchette P, et al.** Direct transport to tertiary trauma centers versus transfer from lower level facilities: impact on mortality and morbidity among patients with major trauma. *J Trauma.* 1997 Aug;43(2):288–295; discussion 295–296.
9. **Pape HC, Hildebrand F, Krettek C.** [Decision making and priorities for surgical treatment during and after shock trauma room treatment]. *Unfallchirurg.* 2004 Oct;107(10):927–936. German.
10. **Bernhard M, Becker TK, Nowe T, et al.** Introduction of a treatment algorithm can improve the early management of emergency patients in the resuscitation room. *Resuscitation.* 2007 Jun;73(3):362–373.
11. **Schaser KD, Melcher I, Stöckle U, et al.** [Interdisciplinarity in reconstructive surgery of the extremities]. *Unfallchirurg.* 2004 Sep;107(9):732–743. German.
12. **Karanas YL, Nigriny J, Chang J.** The timing of microsurgical reconstruction in lower extremity trauma. *Microsurgery.* 2008;28(8):632–634.
13. **Mathes SJ, Nahai F.** *Reconstructive Surgery: Principles, Anatomy, and Technique.* 1st ed. St Louis London: Quality Medical Publishing, Churchill-Livingstone; 1997;3:1193–1206.
14. **Millard DR.** *Principalization of Plastic Surgery.* 1st ed. Boston: Little, Brown & Co; 1986.
15. **Levin LS.** The reconstructive ladder. An orthoplastic approach. *Orthop Clin North Am.* 1993 Jul;24(3):393–409.
16. **Harvin WH, Stannard JP.** Negative-pressure wound therapy in acute traumatic and surgical wounds in orthopedics. *JBJS Rev.* 2014 Apr 22;2(4).
17. **Wong CJ, Niranjan N.** Reconstructive stages as an alternative to the reconstructive ladder. *Plast Reconstr Surg.* 2008 May;121(5):362e–363e.
18. **McGrouther DA, Sully L.** Degloving injuries of the limbs: long-term review and management based on whole-body fluorescence. *Br J Plast Surg.* 1980 Jan;33(1):9–24.
19. **Mathes SJ, Nahai F.** Classification of the vascular anatomy of muscles: experimental and clinical correlation. *Plast Reconstr Surg.* 1981 Feb;67(2):177–187.
20. **Taylor GI, Palmer JH.** The vascular territories (angiosomes) of the body: experimental study and clinical applications. *Br J Plast Surg.* 1987 Mar;40(2):113–141.
21. **Taylor GI.** The angiosomes of the body and their supply to perforator flaps. *Clin Plast Surg.* 2003 Jul;30(3):331–342.
22. **Gage M, Yoon R, Gaines R, et al.** Dead space management after orthopedic trauma: tips, tricks and pitfalls. *J Orthop Trauma.* 2016 Feb;30(2):64–70.

10 Acknowledgments

We thank Alain Masquelet and William de Haas for their contributions to the second edition of the *AO Principles of Fracture Management* and to David Volgas coeditor of the *Manual of Soft Tissue Management in Orthopedic Trauma* book.

4.4 Pediatric fractures

Theddy Slongo, James Hunter

1 Introduction and epidemiology

Injuries of the musculoskeletal system are common in children and usually related to the normal activities of childhood, including play and sports. Musculoskeletal injuries are the second most common cause (after head injuries) of permanent disability in childhood. One in seven children seen in the emergency department presents with a fracture. We must be aware that young children are sustaining more severe injuries because of new, high-velocity sports and sport equipment (eg, rollerblades, skateboards, high-tech bicycles). Mann and Rajimaira [1] reviewed 2,650 long-bone fractures in children, 30% of which involved the physis. Up to 50% of physeal injuries occur in the distal radius. The second most commonly injured area is the distal humerus, of which about 50% of fractures are treated operatively [2]. The overall incidence of fractures depends greatly on the activities of a child. Children participating in sports are more likely to sustain diaphyseal fractures and injuries to the physis.

All orthopedic, trauma, and pediatric surgeons must have a basic knowledge of children's fractures.

A child is not just a small adult. The main differences lie in the physical properties of the skeleton and its ability to grow.

The aim in this age group must be to provide, from the beginning, treatment that is effective, definitive, and appropriate to childhood injury. Repeated reduction maneuvers and anesthesia are to be avoided. Children, after injury, should be able to return to full activity without undue pain or long-term problems.

2 Growth and development

Immature bone is resistant to mechanical forces and can respond quickly to injury. Provided the essential zones of the growth plate are not directly involved, growth of the immature skeleton has a positive influence on fracture repair. Two different regulatory systems exist for growth:

- Longitudinal growth (length) is regulated by the epiphyseal system.
- Circumferential growth (diameter and thickness) is regulated by the periosteal/endosteal system.

Both systems follow the rules established by Roux in 1895 [3]. While disturbances in circumferential growth are rarely encountered, longitudinal overgrowth or premature growth arrest may be observed after practically any injury. Injury can sometimes stimulate extra growth but this is generally temporary and rarely causes significant deformity. Transient growth arrest occurs after most physeal injuries, leading to the formation of growth arrest lines, which are visible on x-ray. Permanent growth arrest is rare but serious.

In general, it may be assumed that:
- Pediatric fractures tend to heal rapidly and reliably.
- Malunions remodel adequately in most instances, depending on the age of the child, degree of displacement, and location of the fracture (segment).
- Apart from physeal injuries with growth arrest, only failures of treatment lead to permanent angulation of the immature skeleton. This applies mainly to diaphyseal fractures.

2.1 Regulation of epiphyseal growth

The physis (growth plate) is the primary center responsible for the longitudinal growth of bones. It can be divided into two sections: the epiphyseal zone where proliferation predominates and the metaphyseal zone without proliferation [4]. In the epiphyseal zone the proportion of the matrix surpasses that of the cellular elements, while the contrary is the case for the metaphyseal zone [5]. According to Trueta and Morgan [6], the growth plate can be divided into five zones:
- Bone matrix
- Proliferation
- Mature and hypertrophic cartilage
- Mineralized cartilage
- Cell degeneration and bone formation

The physis is surrounded by the perichondrium, which is responsible for the circumferential growth of the cartilaginous zone, and therefore of the epiphyseal/metaphyseal end of a bone. The blood supply in this zone is of major importance. The epiphysis, metaphysis, and perichondrium are supplied by three separate nutrient arteries.

The metaphyseal area of the physis shows little resistance to bending and shear force because of its high cellular ratio. Consequently, injury usually occurs through this part of the growth plate while the epiphyseal portion of the growth plate remains intact. Thus, growth disturbance is rare. Injuries through the metaphyseal area of the physis produce type I and type II Salter-Harris fractures, which are discussed in more detail later in this chapter.

Growth disturbance following such injuries is rare and the etiology of this serious complication is not fully understood, but is probably related to severe crushing accompanying the fracture as well as undulations in some physes.

Another important function of the physis of long bones is the modeling of articular surfaces through modified growth of the articular cartilage. Any injury to the epiphysis must be considered as an articular injury.

2.2 Growth and remodeling in the diaphysis

The diaphysis gains its rigidity by tubular calcification in the middle of the immature shaft. Du Hamel [7] described the circumferential growth of the diaphysis by periosteal apposition accompanied by endosteal resorption. The thickness and size of the ossified tubes is directly related to the mechanical stress, which seems to influence the remodeling process. Toward the neighboring joints, the tubular structure widens and the metaphysis broadens through periosteal appositional growth.

2.3 Growth disturbances

If the growth plate is open, there are two possible patterns of growth disturbance. In one situation, bone growth is stimulated; in the other, the activity of the physis is reduced by partial or total premature closure. While the latter situation is permanent, growth stimulation is temporary and occurs only during the repair phase of an injury or a bone/articular infection to the adjacent diaphyseal or metaphyseal bone [8].

Careful attention must be given to all periepiphyseal injuries, not just to physeal fractures.

Growth arrest can occur after any physeal injury and in exceptional circumstances can follow simple metaphyseal fractures. The risk of growth disturbance must be communicated to parents. Secondary injury through treatment that is too vigorous should be avoided.

2.4 Potential to remodel

In the upper extremity, longitudinal growth mainly occurs at the proximal humerus and distal radius/ulna (the shoulder and wrist, respectively). The proximal and distal growth centers of the upper humerus and distal radius and ulna account for most growth in the extremity. Thus, the remodeling potential in these areas is considerable. Fractures around the elbow, especially the distal humerus, however, have much less remodeling potential. The proximal ulna has no real growth plate, it is an apophysis and not responsible for longitudinal growth. This is the reason why Monteggia lesions with fracture or bowing of the proximal ulna have a low remodelling capacity.

The opposite is true of the lower limb. Most growth occurs around the knee (at the distal femur and proximal tibia) and this is where the greatest degree of remodeling will take place. However, the extent of remodeling is less than observed in the upper limb. A fracture of the distal femoral or proximal tibial epiphysis is always related to high-energy trauma with a major risk of growth disturbance.

2.4.1 Factors affecting remodeling potential

Four major factors have a bearing on the potential for angular remodeling:

- Skeletal age
- Individual potential of a specific growth plate (eg, proximal humerus > distal humerus)
- Proximity to the joint
- Orientation to the axis of the joint

2.4.2 Remodeling of specific fractures

The capacity of a child's fracture to remodel after malunion depends on multiple factors, including the age of the child, site of the injury, direction of the deformity in relation to the nearby joints, and the integrity of the growth plates. Rotational deformity will not remodel and tolerance of this deformity will depend upon the degree of compensatory rotation available at either the hip or shoulder. General guidelines for remodeling of specific fractures are shown in **Table 4.4-1**.

Fracture	Age of patient (years)	Angulation (degree)	Malrotation (degree)	Displacement	Reference
Humerus, proximal	< 5	70	–	Complete	[9]
	5–12	40–70	–		[9]
	> 12	40	–	50%	[9]
Humerus, shaft	Any age	20–30 (varus)	15 (internal rotation)	–	[10]
	Any age	20 (sagittal)	–	–	[10]
Forearm, shaft	< 9	15	45	Complete	[11]
	> 9	10	30	Complete	[11]
Femur, shaft	0–2	30 (varus/valgus) 30 (sagittal)	–	–	[12]
	3–5	15 (varus/valgus) 20 (sagittal)	–	–	[12]
	6–10	10 (varus/valgus) 15 (sagittal)	–	–	[12]
	≥ 11	5 (varus/valgus) 10 (sagittal)	–	–	[12]
Tibia, shaft	< 8	5 (valgus) 10 (varus)	–	–	[13]
	> 8	5 (valgus) 10 (varus)	–	–	[13]

Table 4.4-1 Acceptable malalignment after nonoperative management. Note that the evidence-base is weak and recommendations, in particular about rotation, should be considered with caution.

3 Clinical examination of the injured child

3.1 Case history

The aim must be to perform a focused clinical examination without causing pain. This includes obtaining a history, with the help of the parents, and an examination of all vital parameters according to the advanced trauma life support (ATLS) protocol, when appropriate. The history should carefully establish the mechanism of injury. Nonaccidental injury should be excluded with the help of the case history. Unnecessary or painful manipulations should be avoided and pain relief should be provided before radiological examination.

3.2 Polytrauma

The algorithms for initial treatment should follow ATLS guidelines and are similar to those of the adult (see chapter 4.1). Long-bone stabilization facilitates nursing and rehabilitation but does not affect lung function in children, and so early total care is often appropriate. Thus, early or immediate stabilization of all major long-bone fractures, the unstable pelvis, and the spine has high priority. External fixation allows rapid stabilization in children with polytrauma. A child's cardiovascular system can compensate for blood loss for a long time, followed by a sudden circulatory collapse that may be difficult to manage.

After successful resuscitation, the severely injured child should be transferred as rapidly as possible to a specialized center.

Spinal column injuries are infrequent in children and represent only about 3% of all pediatric injuries. However, postmortem studies in children younger than 16 years who died of high-energy trauma have shown that the incidence of spinal fractures is about 12% [1]. The upper cervical spine is the most commonly injured vertebral zone. Pain, torticollis, limitation of motion, and muscle spasm should raise suspicion of an injury to the cervical region. Flexion forces tend to produce more severe spinal cord injuries than extension forces in the cervical region.

In the traumatized child, the pelvic ring is assessed after the spine has been protected. Most pediatric pelvic fractures are stable. Adequate x-rays should be obtained and computed tomographic (CT) scans may be needed to complete the evaluation.

Acetabular fractures represent approximately 6% of all pelvic fractures. It is important to recognize fractures of the triradiate cartilage, as this can produce a central growth arrest resulting in acetabular dysplasia with lateral subluxation of the femoral head. This usually occurs in children younger than 8 years, an age in which such injuries are hard to recognize.

3.3 Limb injuries

To prevent pain, manual examination should be systematic and gentle.

> An alert child will usually indicate where it hurts. Direct questions may warn the child of a forthcoming (painful) examination, causing distress and making further examination impossible. Sometimes, examination may have to be restricted to simple observation plus the absolutely essential peripheral neurovascular examination.

Any suspicion of a possible fracture should be followed up by an x-ray examination.

4 Imaging in children

X-ray evaluation of each suspected lesion must include at least two views taken at 90° to each other. Both projections should include the joint above and the joint below the suspected fracture area. Unlike adult practice, if the first x-ray clearly shows a grossly displaced fracture that will require formal treatment under anesthesia, a second view may not be required, thereby preventing further painful positioning. In this situation a clear examination of the adjacent joints under image intensification is mandatory.

When the diagnosis is unclear, comparison views of the other side are a last resort and not generally recommended to protect children from undue radiation. All emergency departments should have an atlas of normal appearances and variants; consideration should be given to repeated x-ray after an interval or referral to a specialist in children's fractures. Suspected fractures should be immobilized for 5–7 days and then reexamined with further x-rays as indicated. Follow-up x-rays are also indicated in fractures with a high incidence of secondary displacement, such as the lateral humeral condyle.

Other diagnostic tools, such as ultrasound, CT scan, or magnetic resonance imaging (MRI) should be used appropriately and after consultation with a radiologist. A CT scan results in a relatively high dose of radiation and must be used with caution in children, particularly those younger than 2 years as there may be a significant risk to the thyroid and thymus glands. However, CT scanning is most helpful in evaluating the head, spine, and pelvis. The risks and benefits for each individual patient must be considered. Ultrasonography is increasingly used for the diagnosis of intraarticular injuries in the younger child with a large mass of cartilage, for example the lateral humeral condyle. An MRI gives excellent images but will require anesthesia in smaller children.

5 Classification of children's fractures

Articular and periarticular fractures in children are injuries that inevitably involve the physis.

Both the treatment and prognosis for physeal injuries depend on the type of injury.

5.1 Physeal injuries—Salter-Harris classification

The most frequently used classification of physeal injuries is that of Salter-Harris [14], which describes five different types. It fails, however, to differentiate injuries to the zone of Ranvier at the periphery of the physis. These may be due to ligamentous avulsion or open abrasive trauma. Rang [15] proposed that these be included retrospectively in the Salter-Harris classification as type VI (**Table 4.4-2**).

Salter-Harris type I	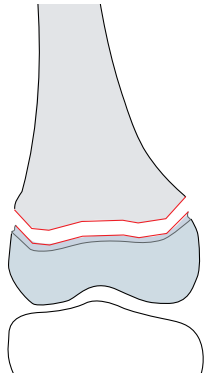	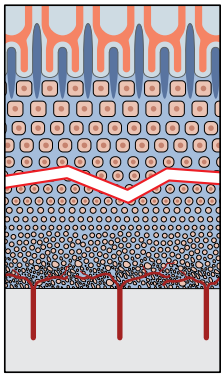	The fracture passes along the growth plate, passing through the junction of the zones of hypertrophy and provisional ossification. The fracture line does not involve growth zones, and growth disturbance is unlikely.
Salter-Harris type II	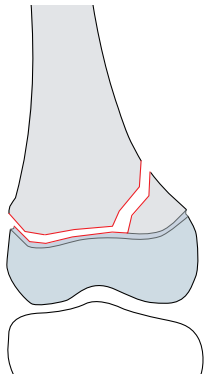	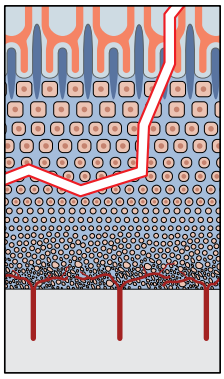	This is a shear injury of the growth plate with a partial metaphyseal fracture (Thurston-Holland fragment). This type accounts for 70% of physeal injuries. Like the type I fracture, this injury does not involve the growth zones, and growth disturbance is unlikely.
Salter-Harris type III	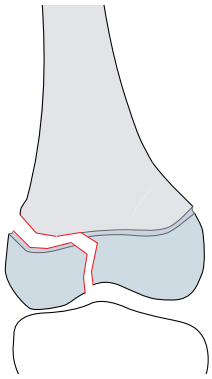	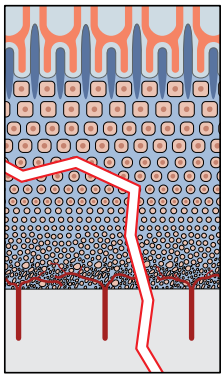	There is a partial physeal separation with an intraarticular epiphyseal fracture. The fracture traverses the growth zones. If reduction is not perfect, growth disturbance is highly likely. Open reduction is necessary.
Salter-Harris type IV	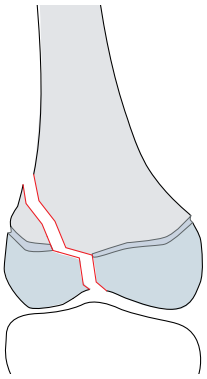	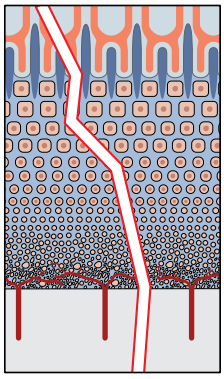	The fracture passes from the joint surface through all layers of the physis and through the metaphysis. The growth zone is involved. Anatomical reduction and fixation is required.

Table 4.4-2 The amended Salter-Harris classification.

Salter-Harris type V	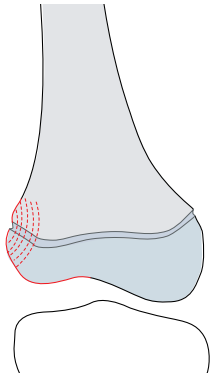	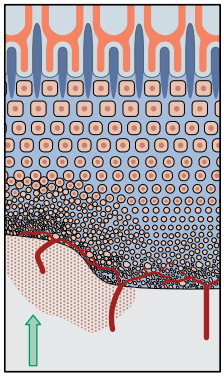	There is impaction of the articular surface and growth plate. This type of injury is often diagnosed in retrospect. Partial growth arrest occurs.
Salter-Harris type VI	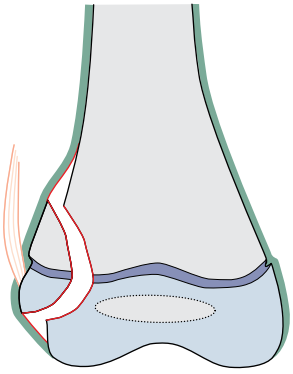	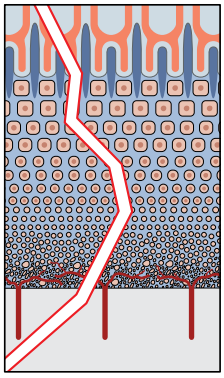	Avulsion fracture at the insertion of a ligament, taking with it a portion of the perichondral ring (Ranvier zone). Accurate reduction and fixation are required; nevertheless growth disturbance can occur.
Salter-Harris type VII	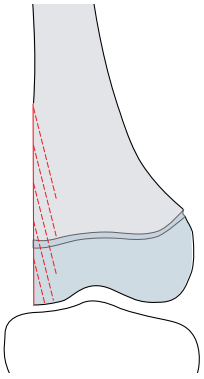	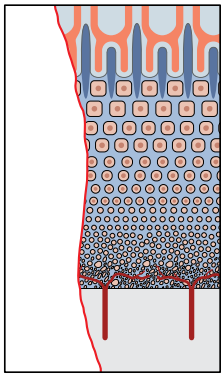	Open abrasive injury of the periphery of the growth plate; this often causes physeal bridging.

Table 4.4-2 (**cont**) The amended Salter-Harris classification.

5.2 AO Pediatric Comprehensive Classification of Long-Bone Fractures

Because the Salter-Harris classification only describes fractures of the epiphyseal zone, the Pediatric Expert Group of AO introduced a special classification that is appropriate to immature bones and describes all the bone segments of the long bones.

This is built upon the classification of adult fractures in its specific, essential features and also integrates classifications such as that by Salter-Harris and other well-known systems (**Fig 4.4-1**).

This system was validated and published as the AO Pediatric Comprehensive Classification of Long-Bone Fractures, and essentially comprises the elements that follow [16, 17].

5.2.1 Bone and segment

The bone is coded in the same order as in the AO/OTA Fracture and Dislocation Classification for adults:

1. Humerus
2. Radius/Ulna
3. Femur
4. Tibia/Fibula

The segments within the bones also follow a similar coding scheme:

1. Proximal
2. Diaphyseal
3. Distal

However, their identification differs from adults. For pediatric long-bone fractures, the metaphysis is identified by a square whose sides have the same length as the widest part of the physis in question. For paired bones (radius/ulna and tibia/fibula), both bones must be included in the square. Consequently, the three segments (**Fig 4.4-2**) can be defined as:

Segment 1	Proximal epiphysis and metaphysis
Segment 2	Diaphysis
Segment 3	Distal metaphysis and epiphysis

Pediatric malleolar fractures are rare and have a different morphology than those of adults. These are placed in segment 3.

5.2.2 Fracture type

The original severity code (A-B-C) used in adults [1] is replaced by a different classification of fractures:

E	Epiphysis
M	Metaphysis
D	Diaphysis

This terminology is accepted worldwide and is relevant to pediatric fractures.

Using the E-M-D code makes it possible to identify intraarticular and extraarticular fractures without ambiguity, since epiphyseal fractures are intraarticular fractures by definition. Metaphyseal fractures are identified by the position of the square (the center of the fracture lines must be located in the square) with one side over the physis.

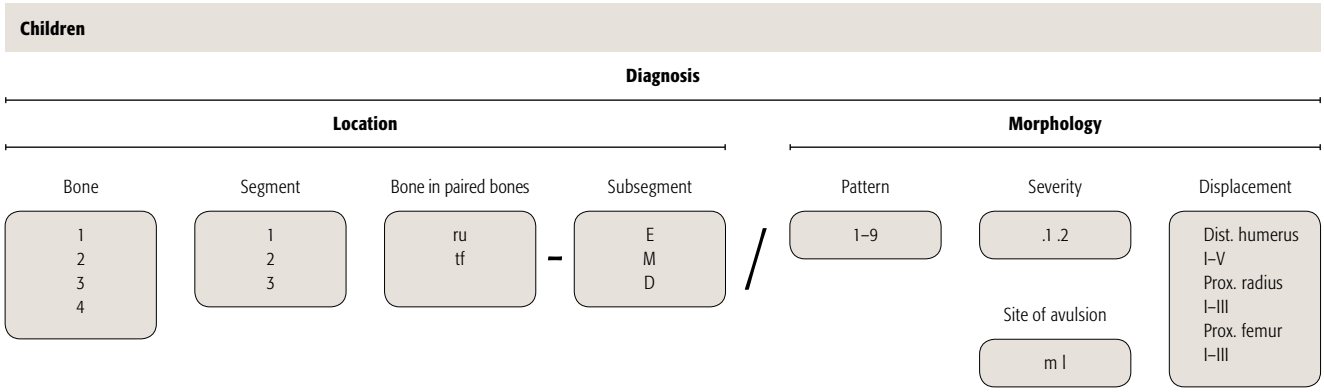

Fig 4.4-1 Overall structure of the AO Pediatric Comprehensive Classification of Long-Bone Fractures.

5.2.3 Child code

Specific pediatric features (also called child patterns) are noted in a child code. For easier recognition, this code is preceded by a forward slash "/" within the entire classification code (**Fig 4.4-1**). Relevant child patterns are specific to one of the fracture types, E, M, or D, and hence grouped accordingly (**Tables 4.4-3–5**).

5.2.4 Fracture severity code

The severity of the fracture is graded not so much because of its influence on healing (as in adults), but because of the need to investigate the indications for various methods of osteosynthesis. This code distinguishes between:

.1	Simple
.2	Wedge or complex (comminuted), two main fragments and at least one intermediate fragment

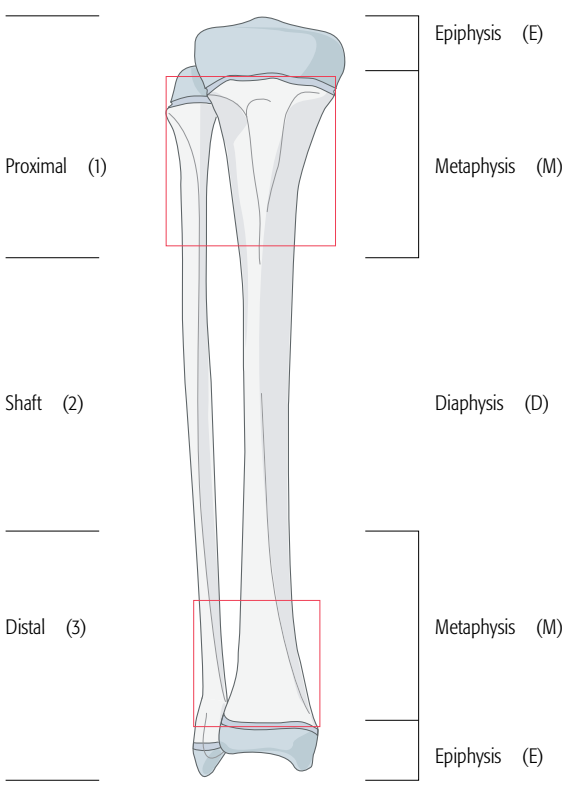

Fig 4.4-2 Definition of long-bone segments and types. Children have a larger metaphyseal segment than adults and so the squares must be placed over the widest part of the physes.

5.2.5 Exceptions and additional codes

Not all pediatric fractures can simply be classified according to the above pattern, thus a few more definitions and rules are needed:

- Fractures of the apophysis are recognized as metaphyseal injuries.
- Transitional fractures with or without a metaphyseal wedge are classified as epiphyseal fractures.
- Intraarticular and extraarticular ligament avulsions are epiphyseal and metaphyseal injuries, respectively.
- Supracondylar humeral fractures (code 13-M/3) are given an additional code regarding the grade of displacement in four levels (I–IV), modified from von Laer [8]:

I	Incomplete fracture: On a strictly lateral view x-ray Rogers' line will be within the capitulum. The AP view will reveal a gap of 2 mm at most in the valgus or varus position.
II	Incomplete fracture: Dislocation is in antecurvation or recurvation with intact posterior (extension fracture) or anterior cortex (flexion fracture). On a strictly lateral view x-ray Rogers' line lies outside the capitulum.
III	Complete fracture: There is no continuity of the cortex, but still contact between fracture surfaces.
IV	Complete fracture: There is no continuity of the cortex and no contact between fracture surfaces.

- Radial head fractures (21-M/2, 21-M/3, 21-E/1, or 21-E/2) are given an additional code regarding the axis deviation and level of displacement:

I	No displacement, no angulation
II	Angulation and displacement of up to half the shaft's diameter
III	Angulation and displacement more than half of the bone diameter or fully displaced

- Femoral neck fractures: Epiphysiolysis and epiphysiolysis with a metaphyseal wedge are coded as normal type E epiphyseal Salter-Harris I and II fractures E/1 and E/2. Fractures of the femoral neck are coded as normal type M metaphyseal fractures:

I	Midcervical
II	Basicervical
III	Transtrochanteric

E/1	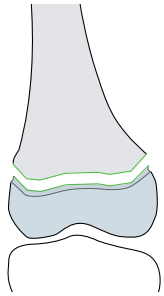 Salter-Harris type I	**E/6**	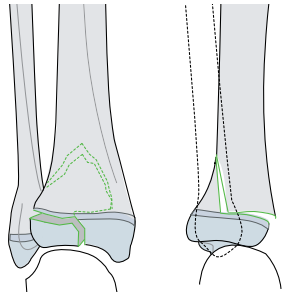 Triplane fracture
E/2	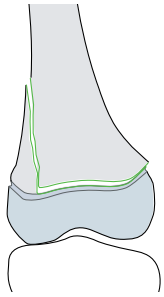 Salter-Harris type II	**E/7**	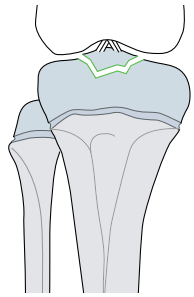 Ligament avulsion
E/3	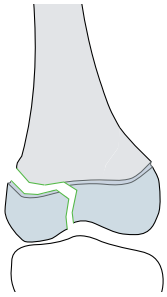 Salter-Harris type III	**E/8**	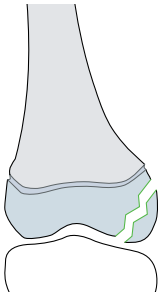 Flake fracture
E/4	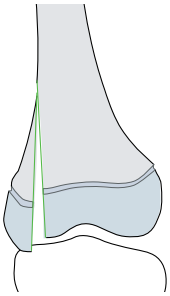 Salter-Harris type IV	**E/9**	Other fractures, eg, abrasive injury
E/5	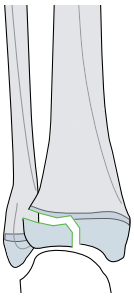 Tillaux (biplane) fracture		

Table 4.4-3 AO Pediatric Comprehensive Classification of Long-Bone Fractures: patterns of epiphyseal fractures in children.

M/2

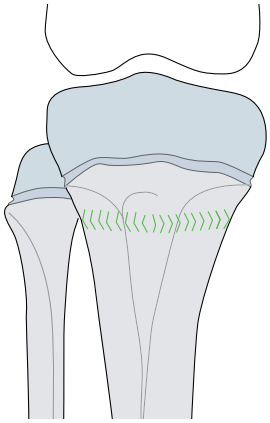

Buckle or torus greenstick fracture

M/3

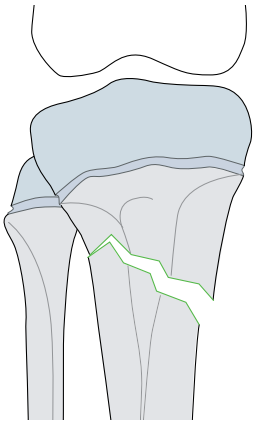

Complete fracture

M/7

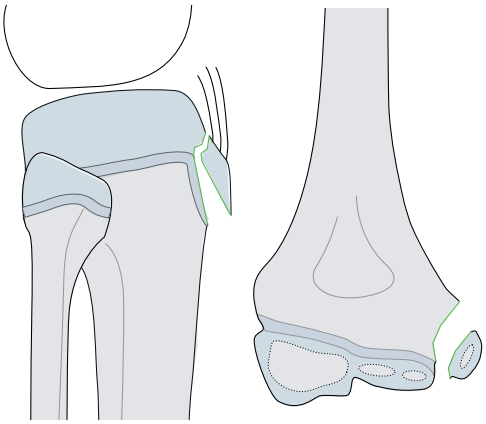

Osteoligamentous and apophyseal injury

M/9

Other fractures

Table 4.4-4 AO Pediatric Comprehensive Classification of Long-Bone Fractures: patterns of metaphyseal fractures in children. The numbers correspond to the equivalent epiphyseal injury and therefore are not sequential.

D/1	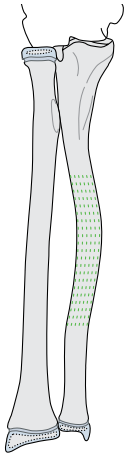	Bowing fracture
D/2	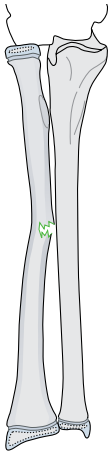	Greenstick fracture
D/4	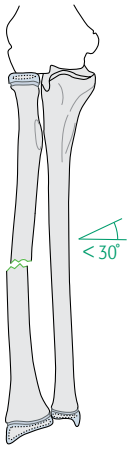	Complete transverse fracture
D/5	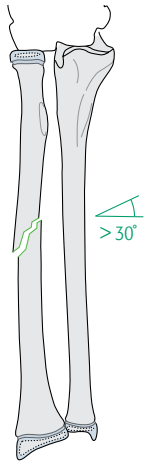	Complete oblique/ spiral fracture
D/6	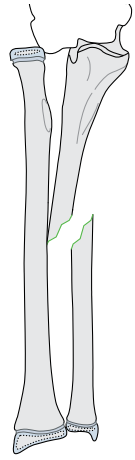	Monteggia fracture
D/7		Galeazzi fracture
D/9		Other fractures

Table 4.4-5 AO Pediatric Comprehensive Classification of Long-Bone Fractures: patterns of diaphyseal fractures in children. Similar to adult fractures, oblique fractures are identified when the angle between the fracture line and the line transverse to the bone axis is greater than or equal to 30°. Similarly, the code "/9" should be used for fractures that may not belong to well-defined categories.

6 Treatment of fractures in children

6.1 Aims

The goal of each fracture treatment must be:

- Quick and effective relief of pain
- Reconstruction of normal anatomy and function
- Early mobilization and resumption of the child's activities
- Avoidance of unnecessary and repeated reduction attempts
- Avoidance of late complications
- Treatment appropriate to the child's age and the type of injury
- Achieving an optimal result with a minimum of invasion

6.2 Closed treatment

6.2.1 Nonoperative stabilization

Most upper limb fractures in children and adolescents are treated by closed reduction and casting. Traction is reserved for femoral fractures in children younger than 3 or 4 years, although these are increasingly being stabilized by operative means. The only way to splint and hold reduction is by applying a well-molded cast. Generally, this will need to be a full circular cast, generously padded and possibly split. Splints and back slabs may be adequate for nondisplaced fractures.

Nonoperative treatment is only indicated for stable fractures; if there is a potential sign for instability (oblique fracture line, same level in paired bones, fully displaced fractures), definitive operative treatment should be considered.

6.2.2 Operative stabilization

If there is an indication for stabilization, in most cases this can be achieved through closed minimally invasive treatment. Minimally invasive osteosynthesis techniques, such as elastic stable intramedullary nails (ESIN), K-wires, cannulated screws, and sometimes even plates should always be considered in the treatment of children's fractures.

Children cannot be relied upon to report pain, sensory alterations, circulatory disturbances, or other signs of impending complications. Regular and competent clinical observation is required. The circulation and neurological status distal to the fracture must be checked frequently and thoroughly.

6.3 Open treatment

Fractures that cannot be reduced or maintained in a satisfactory position should be approached operatively, irrespective of the child's age, unless satisfactory remodeling can be assured. Multiple different attempts at closed management and percutaneous or intramedullary fixation (eg, unstable forearm fractures or irreducible femoral fractures) should be avoided. Displaced intraarticular fractures should be treated by open anatomical reduction and stable fixation.

The following injuries/fractures are widely accepted as an indication for open/surgical treatment and internal or external stabilization:

- Open fractures
- Polytrauma
- Head and spinal injuries
- Femoral neck fractures
- Intraarticular physeal injuries (displacement > 2 mm)
- Irreducible fractures if several attempts are not successful
- Fractures associated with burns or other severe soft-tissue injuries

6.4 Open fractures

As in adults, open fractures are surgical emergencies and must be treated aggressively to prevent infection and permanent disability. The various soft-tissue classifications used in adults are also applicable to open fractures in children (see chapter 1.5; 4.2). Type IIIC open lower limb injuries are associated with a high amputation rate in adults, and limb salvage is often impractical.

In children, all efforts should be made to salvage limbs.

Early amputation should only be performed to save life. Children tolerate tissue loss far better than adults.

A thorough and aggressive debridement comprising excision of all damaged and devitalized tissue (muscle, skin, bone, etc) is mandatory. The wound should be irrigated copiously both before and after debridement.

6.5 Surgical fracture stabilization

Good outcomes can be achieved following children's fracture fixation without using large and bulky implants. The tendency of children to move rather than rest is a benefit to their management, and physiotherapy is rarely required. In addition, children's fractures can be splinted postoperatively without fear of long-term stiffness; chronic regional pain syndrome rarely follows fracture surgery.

For diaphyseal fractures, ESIN is the standard method of treatment in children up to 50 or 60 kg. For the epiphyseal area, a number of different implants—mostly wires and screws—can be applied [18].

Small-fragment screws (exceptionally 6.5 mm in the proximal femur), cannulated screws, and K-wires are used in the treatment of periarticular and articular fractures. Plates are rarely applied to immature bone, as retrieval is a major operation but is necessary to prevent complete overgrowth. External fixation is popular especially for open and metaphyseal fractures and in the treatment of femoral fractures. Damage to the physis must be avoided. Generally, the growth plate should be traversed with K-wires and not with lag screws. Ideally, K-wires should be inserted at low speed and should cross the physis at a right angle.

When placing wires across the growth plate, repeated drilling, starting several wires from a single point, and very peripheral insertion must be avoided to minimize damage to the proliferation zone.

Generally, the K-wires can be removed after 3–4 weeks. If it is necessary for a screw to cross the physis then it must be removed as soon as possible.

In articular fractures, the fragments should be reduced anatomically and fixed with absolute stability using interfragmentary lag screws parallel to the physis, either in the metaphysis, epiphysis, or both (type E/3 and E/4) [19]. These screws should always be removed if growth potential remains. K-wires do not exert compression, carry an increased risk of infection, and must be supported by a cast.

The technique of ESIN with the titanium elastic nail (TEN) can be applied to practically all diaphyseal fractures in children between the ages of 3 and 4 years and puberty, depending upon the size, physical development, and weight of the child (maximum 50–60 kg). Using the end caps, the indication for ESIN technique can be extended to more complex fractures and older children (**Fig 4.4-3**). External fixation is used in about 10–12% of cases, mainly for older, heavier children and for complex and unstable open fractures of the femur or tibia (**Fig 4.4-4**).

Plates are reserved for exceptional indications—preferably using minimally invasive techniques—as well as for secondary corrections. In 1993, a population-based study showed that the percentage of plate application in pediatric trauma fell from 60% to 5% [19].

Implant removal in the metaphyseal area should only be performed after fracture healing with visible callus on x-ray. In the diaphyseal region, especially when ESIN technique is used, a complete consolidation and recorticalization should be achieved. In the forearm, elastic nails should be removed at 6 months. Refractures occur in children and this is particularly true with the use of external fixation.

Fig 4.4-3a–h Instruments, implant, and clinical case with titanium elastic nail (TEN) and end caps.
a–b Self-tapping end cap and end cap adapter.
c End caps in place in a transparent model; recognize that only the distal part of the thread has bone contact.
d–h Long spiral femoral fracture treated with titanium elastic nails and additional end cap stabilization with final films showing healing.

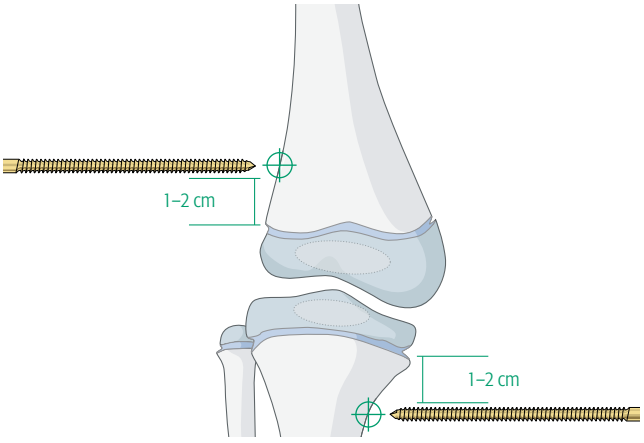

Fig 4.4-4 When inserting the pins for the external fixator, it is important to remember that the growth plate is about 4 mm thick. In order not to overheat the growth plate, the Schanz screws must be inserted by hand about 1–2 cm from the growth plate in the metaphyseal area. In the epiphyseal area fine wires and Schanz screws can be inserted by hand without damaging the growth plate.

7 Specific fractures

7.1 Humerus

7.1.1 Humerus, proximal

Malalignment or functional deficit after fractures of the proximal humerus is rare, as there is great potential for correction of both angulation (up to 60° in children younger than 12 years) and displacement (full displacement can be accepted if 2–3 years of growth remain). This allows full remodeling in most cases, including full displacement with bayonet apposition, provided 2 years of growth remain. The exceptional range of motion of the shoulder joint compensates for any remodeling that does not occur, including rotational deformity. These fractures are therefore treated nonoperatively. Between 10 and 12 years of age, up to 60° angulation can be medically tolerated but may not be accepted by the parents. With older children (girls > 12 years and boys > 14 years), only 50% displacement can be tolerated. For this reason, fully displaced fractures should be reduced. Fixation using a retrograde ESIN offers excellent stability and early mobilization. Rarely, interposition of the biceps tendon occurs, which will demand open reduction and internal ESIN fixation. After open reduction of the proximal humeral fracture, ESIN is the stabilization of choice as it allows relatively early movement and avoids the complications of K-wire fixation, which should only be used in exceptional cases because of the requirement for additional immobilization and the dangers of wound problems, infection, and wire migration.

The technique involves starting on the lateral, distal humerus, taking care to avoid and protect the radial nerve, and inserting two nails up to the distal fracture line. Then closed or open reduction is performed. Once the reduction is perfect, then advance the two nails by gentle hammering across the fracture into the proximal fragment (**Fig 4.4-5a–f**).

7.1.2 Humerus, shaft

Fractures of the humeral shaft occur more often in older children. Most cases are treated nonoperatively because of the high remodeling potential and tolerance of angulation. However, in older children the indication for TEN stabilization is rapidly increasing for socioeconomic reasons: comfort of the child, early mobility, and resumption of schooling.

Radial nerve injuries are not in themselves an indication for surgery. As in adult practice, exploration is required if nerve involvement follows interventions that may have entrapped the nerve.

Indications for nonoperative therapy:
- Stable, nondisplaced fracture in any age group
- Stable fractures with angulation < 30°
- Stable fracture with acceptable displacement in any age group

Immobilization for 3–4 weeks in a collar-and-cuff type sling is recommended. If a reduction under anesthesia is required, we recommend definitive fixation.

Indications for operative treatment:
- Polytrauma patient (even younger children)
- Children older than 10–12 years
- Unstable, displaced fracture, if a reduction under anesthesia is required

The authors' preferred method is ESIN. No additional immobilization is needed and the intramedullary nails are removed after 3–4 months.

7.1.3 Humerus, distal

Injuries to the elbow are common in childhood. Extraarticular (supracondylar) and intraarticular (condylar) fractures must be distinguished. To the inexperienced eye, the diagnosis may be difficult due to the many physes. A reliable, indirect sign of an intraarticular injury is the "fat pad sign" or lipohemarthrosis. Comparative x-rays should be avoided as they do not compensate for a lack of anatomical knowledge. In supracondylar fractures, the presence or absence of malrotation will be decisive for the choice of treatment. The pediatric long bone classification algorithm for supracondylar fractures is helpful in decision making [16, 17]. Ultrasound examination is increasingly used, especially for intraarticular fractures in young children.

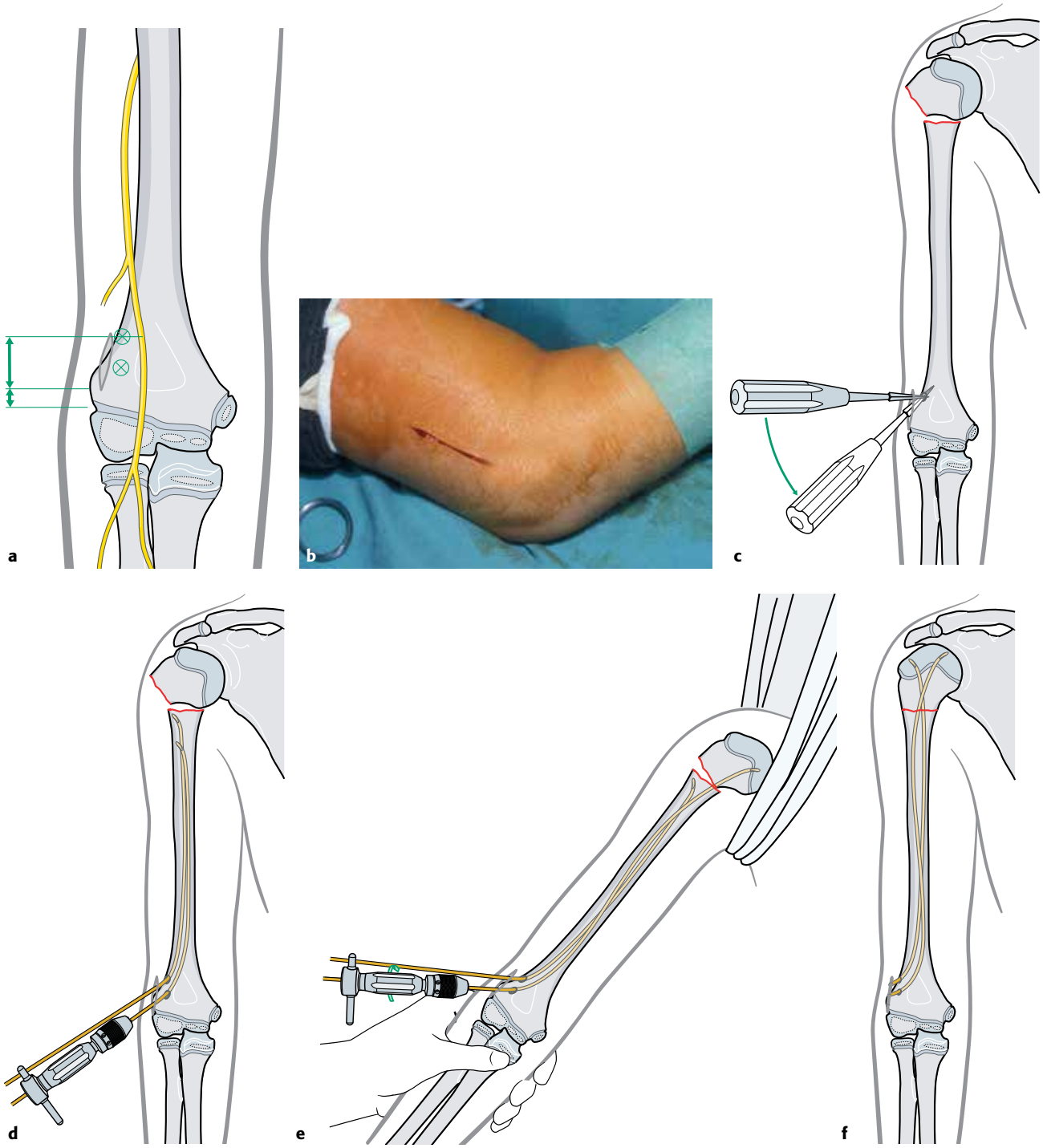

Fig 4.4-5a–f Proximal humeral physeal separation and proximal metaphyseal fractures are treated by the elastic stable intramedullary nail method; this is a simple and child-friendly technique as shown in the illustration.

a The lateral approach to the distal humerus 1 cm above the growth plate.
b Clinical approach.
c Completely displaced metaphyseal fracture and opening of the bone with an awl.
d One nail is prebent in a C-shape, the other one is prebent in an S-shape, according to the monolateral technique.
e Indirect reduction by manipulating the humerus and internal reduction with titanium elastic nails.
f Final situation with perfect reduction.

Supracondylar fractures

For supracondylar fractures, the distinction must be made between those with and without malrotation because this affects treatment. Fractures without malrotation (13 – M/3.1 I + II) can usually be reduced and immobilized without anesthesia in a collar-and-cuff sling, while most fractures with malrotation (13 – M/3.1 III + IV) should be reduced closed, but under anesthesia, and fixed with percutaneous K-wires.

In general, reduction should be followed by percutaneous K-wire stabilization, as extreme positions to maintain reduction are associated with compartment syndrome. The configuration of wires can be crossed or lateral. If only lateral wires are used, care must be taken to stabilize both columns. The wires must be divergent and large-diameter wires should be used (at least 2 mm); a third wire may be required (**Fig 4.4-6**).

A lateral small external fixator is an excellent option in case of irreducible fracture to avoid open reduction. It can be useful in cases with severe swelling, late presenting (neglected) cases, secondary displacement after pinning, especially with rotational failure, and neurological and/or vascular problems (**Fig 4.4-7**) [18, 19].

Open reduction can be performed through various approaches. Neurovascular exploration requires an anterior approach. The most superficial approach to the humerus is lateral and a finger can be slid across to remove soft tissue and ensure reduction. A medial approach can be added to this. Many surgeons prefer a posterior approach directly through the triceps brachii tendon. This leads to the fracture but divides the intact soft-tissue hinge in most cases and should be avoided where possible.

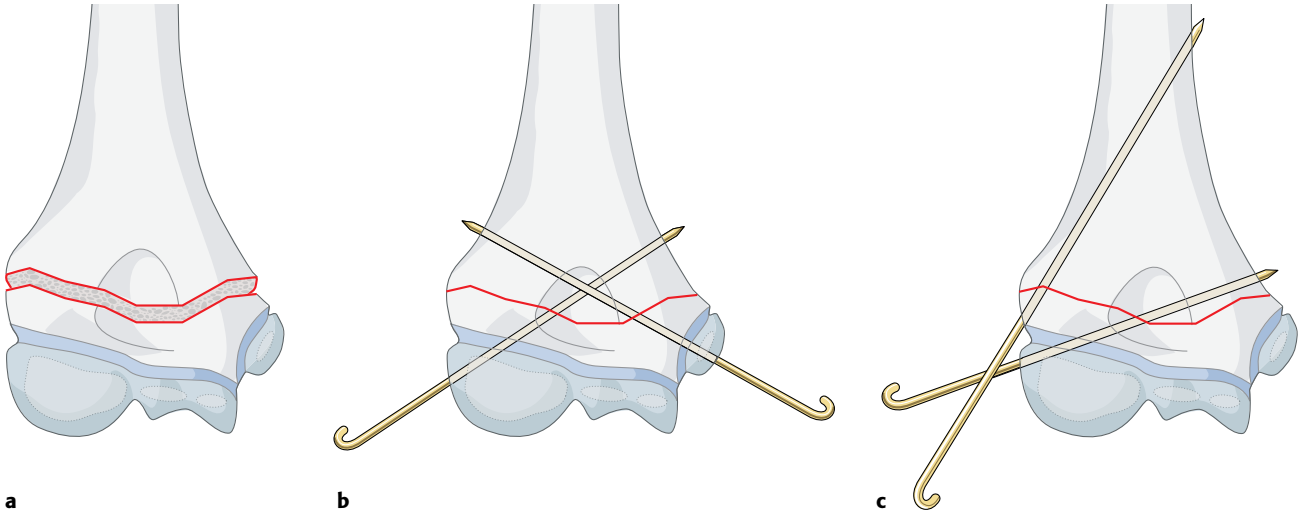

Fig 4.4-6a–c

a Supracondylar fracture.

b After closed reduction, percutaneous K-wire fixation can be performed with wires introduced from the medial and lateral side. Care must be taken to avoid the ulnar nerve. The wires must cross within the bone and should aim to traverse the olecranon fossa. Thus, each wire engages four cortices.

c If two K-wires are used from the lateral side, 2.0 mm wires must be used. These must diverge so that one engages the medial column having crossed the olecranon fossa. The second wire should be more vertical, engaging the lateral column. The wires should cross outside the bone.

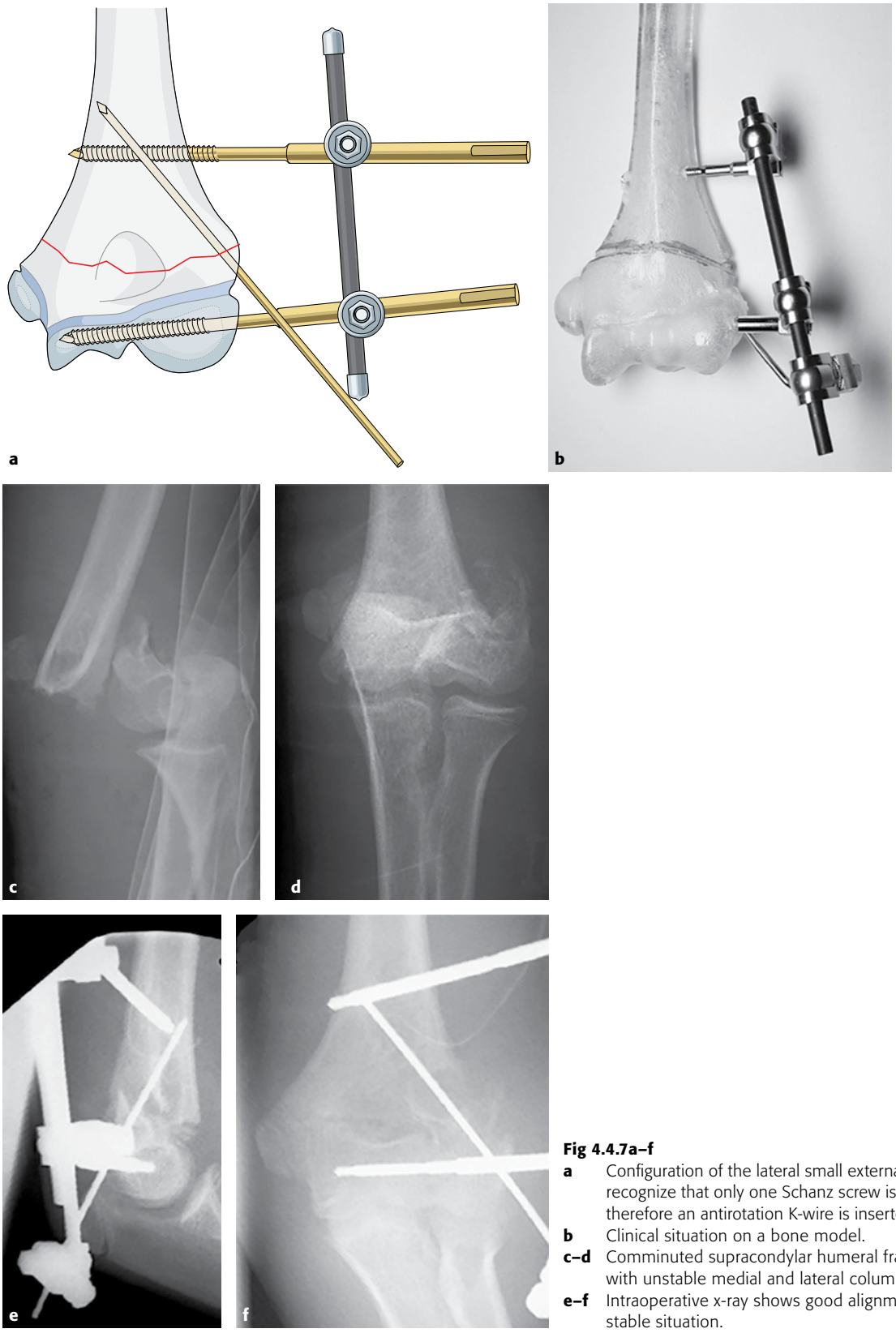

Fig 4.4.7a–f

a Configuration of the lateral small external fixator stabilization; recognize that only one Schanz screw is used per fragment, therefore an antirotation K-wire is inserted from the lateral side.

b Clinical situation on a bone model.

c–d Comminuted supracondylar humeral fracture (13-M/3.2 IV) with unstable medial and lateral columns.

e–f Intraoperative x-ray shows good alignment in both views and stable situation.

Brachial artery exploration is only required for the white, pulseless hand that persists after reduction.

The collateral circulation around the elbow is excellent and even if the brachial artery is occluded, distal perfusion is normally satisfactory. If the hand is pink with good capillary refill (the pink, pulseless hand), investigations such as ultrasound and angiography are not required. If exploration is required for a white, pulseless hand, it should be accompanied by fasciotomy as reperfusion injury and compartment syndrome will lead to ischemic contracture.

Cubitus varus is caused by malreduction and insufficient fixation, in particular failure to correct rotation. If both columns are stably reduced, it will not occur (**Fig 4.4-8**).

Condylar fractures

Fractures of the lateral humeral condyle are Salter-Harris type IV injuries. The diagnosis can often be difficult, particularly when the medial fracture line only goes as far as the thick cartilage. Completely displaced fractures are, as a rule, easy to recognize and must be treated by open reduction and internal fixation, either with a metaphyseal lag screw or two diverging K-wires (**Fig 4.4-9**). The stability of the elbow joint should be checked after fixation. The approach can be lateral or posterolateral. It is imperative to ensure that the blood supply to the fragments, which are covered to a large extent by cartilage, is not destroyed.

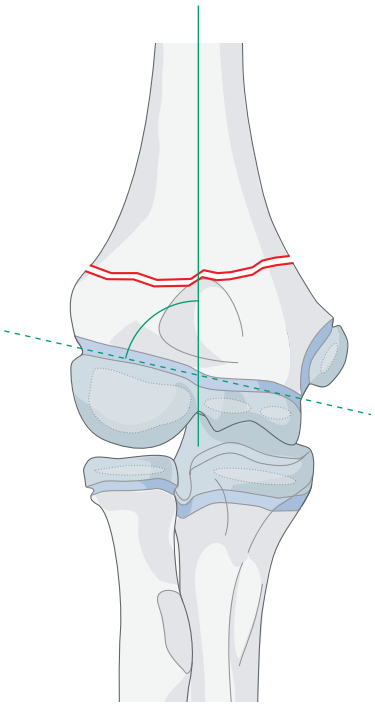

Fig 4.4-8 Baumann's angle is the angle between the lateral condylar physis and the long axis of the humerus shaft. After reduction and fixation, Baumann's angle should be equal to that of the uninjured side (usually 70–75°). More than 75° denotes varus malposition. Correct rotational alignment is best judged on a lateral x-ray view.

A displaced fracture that has been missed inevitably results in pseudarthrosis. This can lead to cubitus valgus and ulnar nerve problems, or cubitus varus through instability and overgrowth of the lateral condyle.

Injuries of the medial condyle are extremely rare. The trochlea ossifies late, which can be mistaken for an epicondylar fracture. The treatment corresponds to that of the lateral condyle. A combination of fractures of both the lateral and medial condyle leads to a Y-fracture, an injury that usually only occurs in older children. In contrast to adults, they seldom have intraarticular comminution. Unstable T-fractures should be treated by open reduction in the usual manner from a posterior approach, whereas in younger children, after the fixation of both articular fragments, a K-wire fixation is sufficient. The joint and physis must be fixed precisely.

Medial epicondylar fractures

Fractures of the medial epicondyle are mostly the result of an elbow dislocation that has reduced spontaneously (**Fig 4.4-10**). In these cases, recognizing the dislocation and the fractured epicondyle can be difficult. Occasionally, this is displaced within the joint and incongruity of the joint should lead to the diagnosis. The degree of displacement of the medial epicondyle that requires fixation is still being debated. Less than 0.5 cm of displacement can be accepted. More than 1 cm cannot be accepted, as instability of the elbow may result.

7.2 Forearm

7.2.1 Proximal forearm, radial head, and neck

Fractures of the proximal end of the radius make up about 10–15% of elbow fractures. These can be metaphyseal or physeal (Salter-Harris I or II). True head fractures (Salter-Harris III or IV) are rare and must be corrected operatively as these fractures can lead to considerable growth disturbances. Diagnosis is only difficult in children before ossification. Indirect signs on x-rays and ultrasound examination are helpful. The blood supply to the radial head is like that of the femoral head and at risk from displaced fractures and their treatment. These fractures can be accompanied by growth disturbance and even avascular necrosis.

The radial neck tolerates angulation well but displacement poorly.

This is because a small displacement increases the radius of curvature within the annular ligament and blocks forearm rotation. Below the age of 10 years, 40–50° of angulation can be accepted. Above this age, consideration should be given to correction of more than 30° angulation.

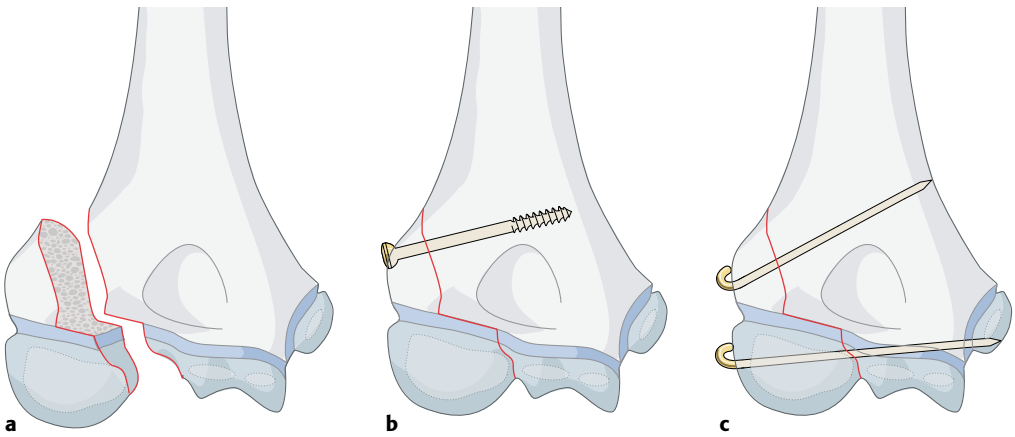

Fig 4.4-9a–c
a Lateral condylar fracture of the distal humerus (Salter-Harris type IV).
b If the metaphyseal fragment is large enough, a metaphyseal lag screw can be inserted via a posterolateral approach.
c In younger children, K-wires can be used and should be inserted exactly as illustrated.

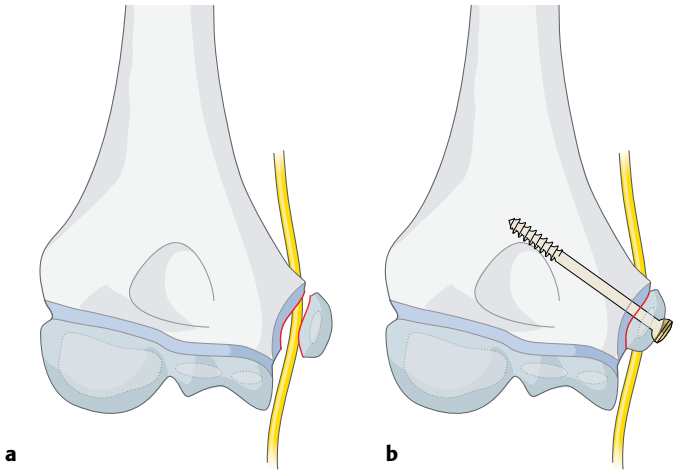

Fig 4.4-10a–b Apophyseal injury to the medial epicondyle of the distal humerus. K-wires are used in younger children but in a nearly mature child a screw should be used. Great care is needed to ensure a smooth surface over which the ulnar nerve will lie.

Open reduction of the radial head is rarely required if the method of Métaizeau is applied [20]. Using an elastic nail or a K-wire slightly bent at the end, most of these fractures can be reduced, closed, and held in that position (**Fig 4.4-11**).

Completely displaced fractures require a separate thick K-wire or Steinmann pin used as a joystick to facilitate reduction. Postoperative treatment does not require a cast, and forearm rotation exercises should be started immediately.

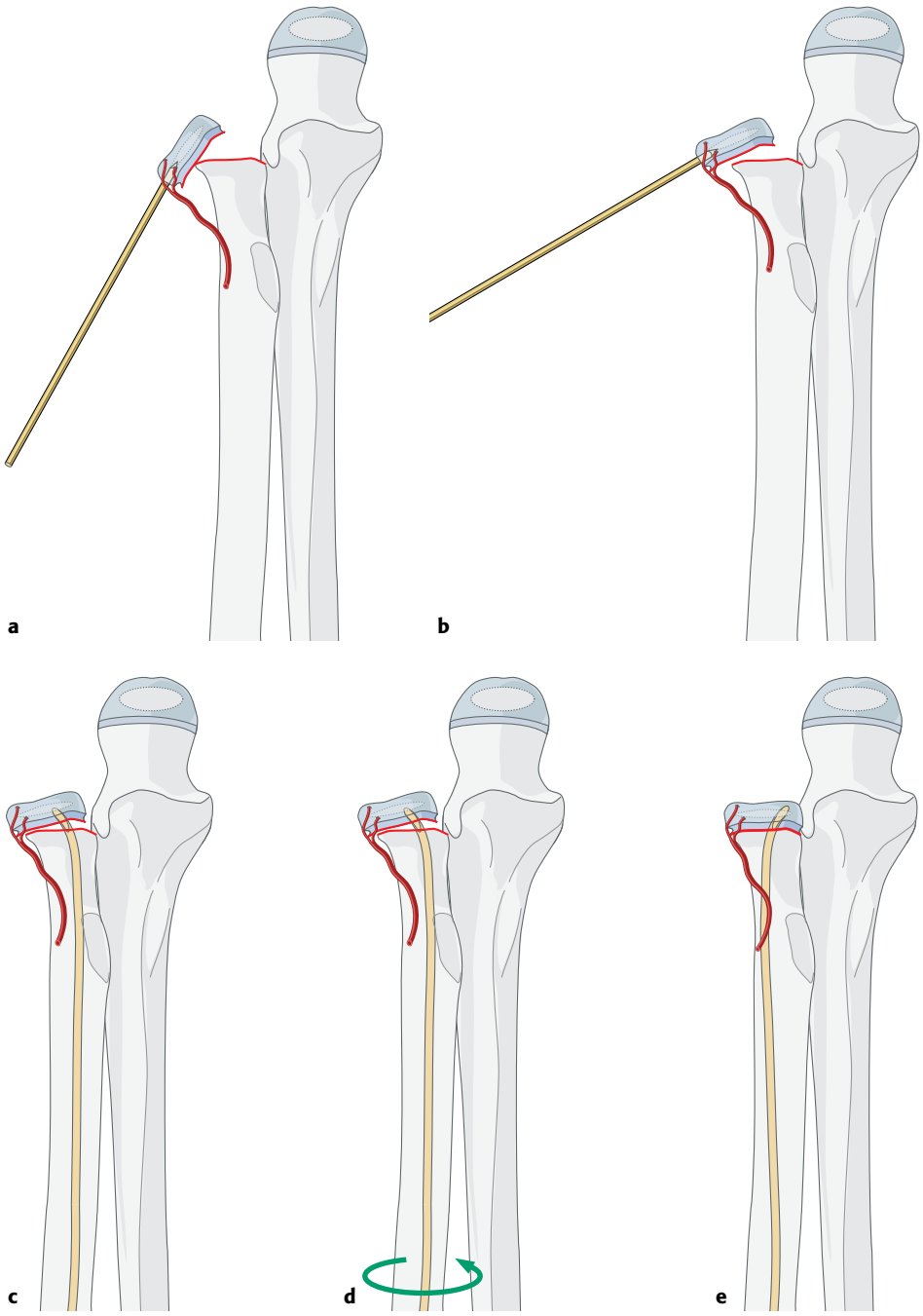

Fig 4.4-11a–e Métaizeau et al [20] recommend gentle partial reduction with a percutaneous probe, followed by completion of the reduction using the rotation of a cranked tip of a titanium elastic nail.

7.2.2 Monteggia injuries (D/6)

The classic Monteggia fracture is a combination of an isolated fracture of the ulna with a dislocation of the radial head. In a small child the ulnar fracture may be proximal, appearing like a fractured olecranon, which may hide the dislocated radial head.

The aim of treatment of Monteggia injuries is the exact reduction of the radial head.

In the case of a stable greenstick fracture of the ulna, closed reduction and immobilization in a cast (in supination) may be adequate. X-ray control after 1 week is required. In an unstable situation, the ulna must be reconstructed anatomically, which automatically reduces the radial head. This can usually be accomplished by elastic nailing, although in rare cases a small plate may be used.

Monteggia lesions occur frequently in younger children. In this age group the lesion is often overlooked because the ulna is not visibly fractured but plastically deformed. Bowing of the ulna must be corrected and the reduction maintained (which can be difficult) for radial head reduction (**Fig 4.4-12**).

Fig 4.4-12 Monteggia lesions in young children.

a Ulnar greenstick fracture must be recognized. This leads to a radial neck dislocation.

b Normal, lateral x-ray of a young child's forearm. The center line of the radial shaft must go through the center of the capitellum, also the ulna must be straight.

c Bowing fracture of the ulna (plastic deformation). Recognize that the ulna is not straight and the center line of the radial shaft is out of the center of the capitellum.

7.2.3 Forearm, shaft

In patients older than 6 years, unstable both-bone fractures of the forearm shaft should be approached surgically, as the functional results after nonoperative treatment are often poor [21]. Many surgeons have lowered their age limit for intervention to 4 (or even 3) years. The reason for this extended indication is frequently the family's socioeconomic situation (both parents are working/school and sport). This approach is justifiable with the use of elastic nails that allow a minimally invasive technique (**Fig 4.4-13**). This method has replaced conventional plating, which should be reserved for older adolescents with an unstable fracture and little growth potential.

7.2.4 Radius, distal

Displaced distal radial fractures are of two distinct types. First, fractures of the metaphysis or at the metaphyseal/diaphyseal junction. If fully displaced, closed reduction and K-wire stabilization is the treatment of choice, and prevents secondary displacement and angulation (**Fig 4.4-14**). The advantages of this treatment have been demonstrated by several case series and randomized controlled trials. Other metaphyseal fractures can be managed by closed reduction and a cast. The second type, physeal fractures, should be reduced and held in a plaster. Only rarely are they so unstable as to require a wire.

> If physeal fractures displace secondarily, they should be left to remodel as remanipulation is associated with growth arrest.

Remodeling of the distal radius consistently brings good results even if things do not go well. Reliable remodeling of 15° of sagittal plane deformity and 1 cm of shortening has been reported [22]. In younger children 30° of dorsal angulation will remodel. In children younger than 10 years full displacement of the radius will remodel with no functional deficit.

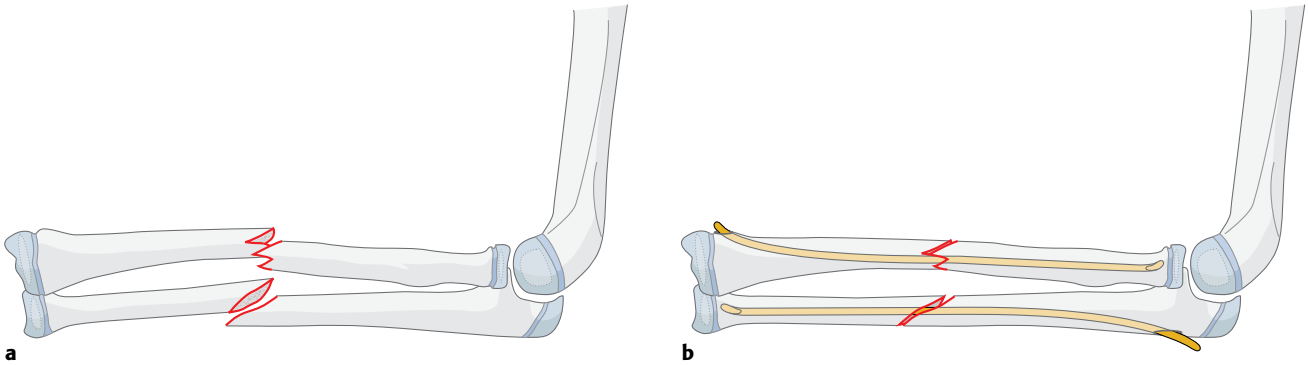

Fig 4.4-13a–b Closed reduction and stabilization by elastic stable intramedullary nail is preferred for unstable, both-bone forearm fractures. Postoperative treatment is usually functional without a cast, although an antalgic splint can be indicated. Plate fixation is rarely required.

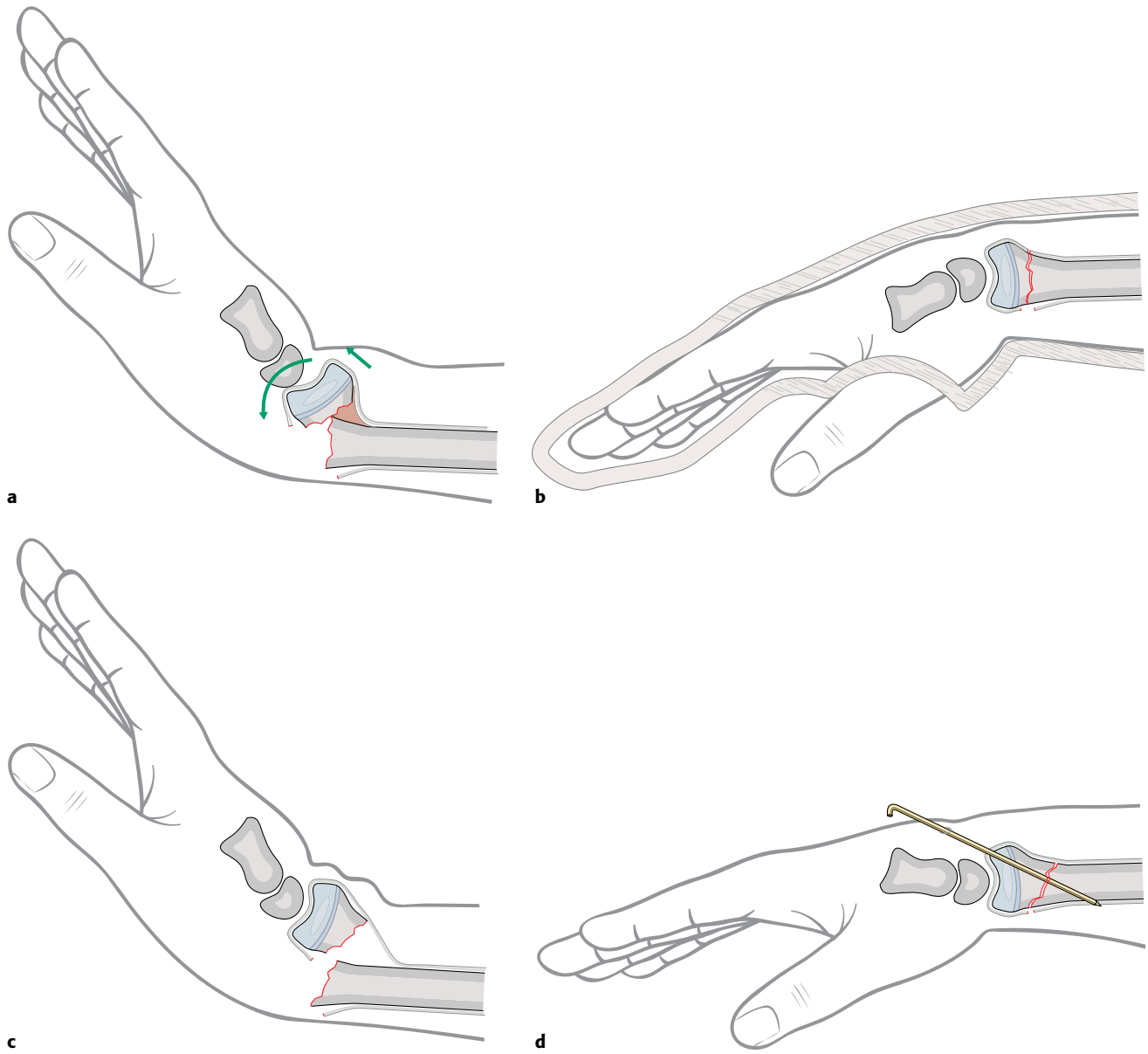

Fig 4.4-14a–d

a Angulated distal radial fracture with intact periosteal hinge on the posterior surface.
b Manipulated and put into a plaster cast with 3-point contact (a curved plaster cast produces a straight bone).
c If the fracture is widely displaced, then the periosteal hinge is ruptured.
d These fractures are unstable and may require K-wire fixation.

7.3 Femur

7.3.1 Femur, proximal

Fractures of the femoral neck are an absolute indication for open anatomical reduction and stable internal fixation as an urgent measure. The surgeon must be aware of the blood supply of the femoral head (**Fig 4.4-15**).

Immediately after the fracture, most of the retinacular vessels are usually still intact. Displacement of the fracture leads to kinking of these precious vessels, which is thought to cause occlusion and thrombosis (**Fig 4.4-15**).

The hemarthrosis may lead to increased pressure within the joint, which further threatens the epiphyseal vascularity.

Closed manipulation of the displaced femoral neck fracture should be avoided to prevent further compromise of any remaining blood supply.

Stable internal fixation is achieved by inserting up to three 3.5 or 4.5 mm cortex screws, threaded K-wires, or 6.5 or 7.0 mm cannulated cancellous bone screws. If the metaphyseal segment of the head fragment is less than 2–3 cm, the screws should cross the physis to get sufficient and safe fixation. More stable fixation can be achieved by using a fixed angle device such as the pediatric 130° fracture LCP (3.5/5.0) which gives angular and rotational stability. The hip capsule is exposed in the interval between the gluteus medius and tensor fasciae latae muscles (Watson-Jones approach) and then opened by a T-shaped capsulotomy. Great care must be taken when passing the retractors around the femoral neck to avoid damage to the retinacular vessels bound to the bone beneath the periosteum. Once reduced, the fracture is fixed with K-wires and the reduction checked, particularly at the level of the calcar, by flexing and rotating the hip. After definitive fixation, the capsular incision is never fully closed to avoid the danger of recurrent joint tamponade. The use of cannulated cancellous bone screws greatly facilitates this type of fixation. The author's preferred fixation technique for fractures lower in the neck is the pediatric 130° fracture LCP (**Fig 4.4-16**).

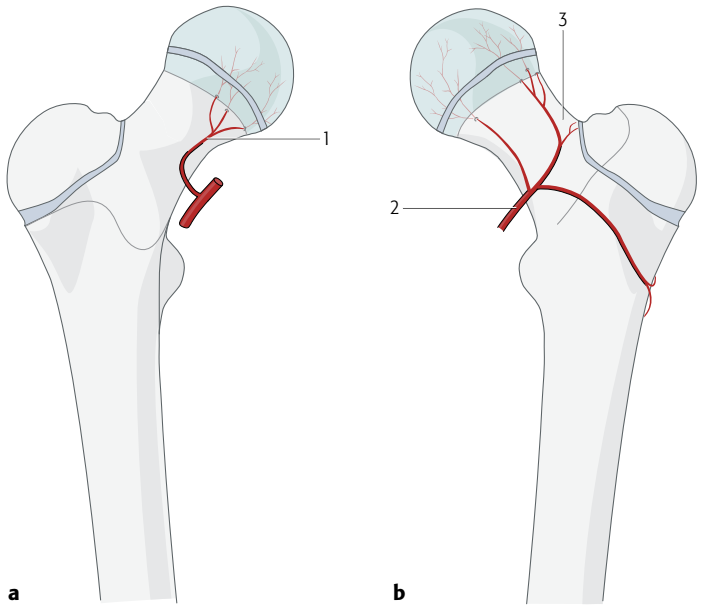

Fig 4.4-15a–b The blood supply of the femoral head.
a The anterior vessels from the lateral circumflex femoral artery (1) supply only the anterior, inferior part of the femoral head.
b The posterior vessels supply 5/6 of the head from branches of the medial circumflex artery (2). Note that the superior vessels transverse the neck close to the piriformis fossa (3). Damage to these vessels will result in avascular necrosis in children and so adult-type intramedullary nails are contraindicated in childhood.

Fig 4.4.16a–f Basicervical fully displaced femoral neck fracture in a 14-year-old boy.

a AP pelvis view.

b Axial cross-table view.

c Demonstrates the intraoperative reduction technique by a transgluteal, lateral approach, using the joystick technique.

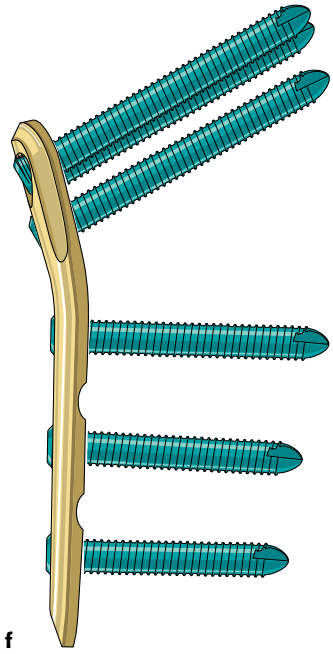

Fig 4.4.16a–f (**cont**) Basicervical fully displaced femoral neck fracture in a 14-year-old boy.

d–e The postoperative AP and axial view 4 weeks after stabilization with a good reduction. Partial weight bearing was allowed.

f For proximal fracture stabilization a 130° LCP pediatric hip plate 3.5 and 5.0 is available.

Surgeons must be prepared to cross the physis with their fixation if required (**Fig 4.4-17**). Two or three screws crossing this large physis are unlikely to cause growth arrest. Only basicervical fractures can be fixed without crossing the physis.

Pertrochanteric and subtrochanteric fractures are best treated with plate osteosynthesis, preferably with a fixed-angle device (pediatric 130° fracture LCP with 5, 7, or 9 holes). These fractures can also be treated by ESIN, especially in pathological fractures connected with cysts. In this situation, the medial intramedullary nail must be driven past the calcar to the femoral head physis, and the lateral nail must be anchored in the greater trochanter. Occasionally, it can be useful to use three thin intramedullary nails, placing two of them medially or laterally depending on the type and position of the fracture. These procedures are technically difficult and not for occasional use.

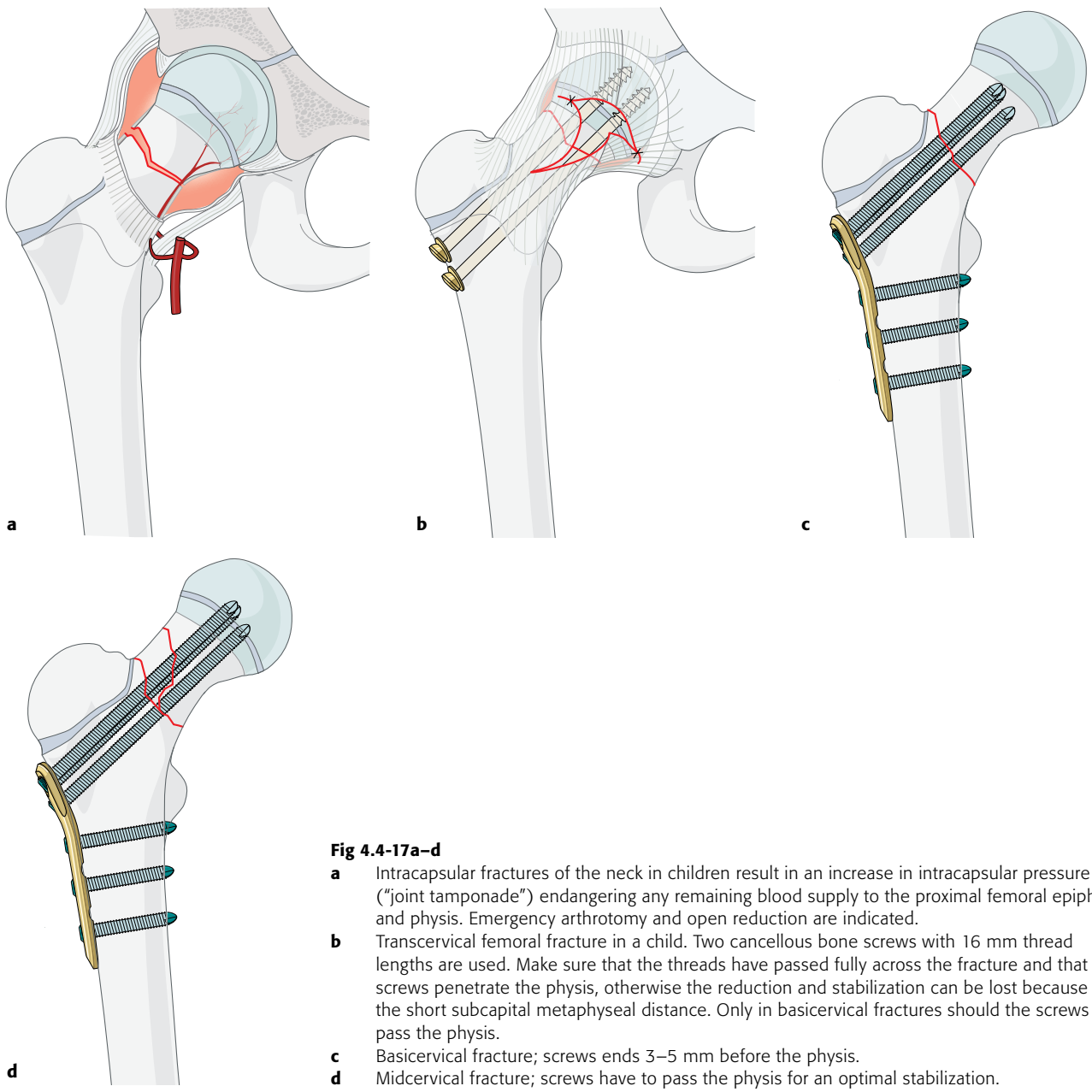

Fig 4.4-17a–d

a Intracapsular fractures of the neck in children result in an increase in intracapsular pressure ("joint tamponade") endangering any remaining blood supply to the proximal femoral epiphysis and physis. Emergency arthrotomy and open reduction are indicated.

b Transcervical femoral fracture in a child. Two cancellous bone screws with 16 mm thread lengths are used. Make sure that the threads have passed fully across the fracture and that the screws penetrate the physis, otherwise the reduction and stabilization can be lost because of the short subcapital metaphyseal distance. Only in basicervical fractures should the screws not pass the physis.

c Basicervical fracture; screws ends 3–5 mm before the physis.

d Midcervical fracture; screws have to pass the physis for an optimal stabilization.

Treatment of pertrochanteric and subtrochanteric fractures with proximal femoral nails designed for adults is contraindicated because of the significant risk of avascular necrosis of the femoral head from damage to the blood supply during insertion of the nail.

In addition, the hard cancellous bone can be shattered by the insertion of this kind of implant.

7.3.2 Femur, shaft

With the introduction of flexible nails by the Nancy group, the treatment of femoral shaft fractures in children has completely changed during the last 30 years [20–22]. Today, most patients between 5 years old and puberty are treated with the ESIN method. Simple transverse, short oblique and spiral fractures are most suitable (**Fig 4.4-18**, **Video 4.4-1**) for this procedure. With experience, more complex multifragmentary (type 32-D/5.2) fractures may also be treated with this method (**Fig 4.4-19**). The use of the end caps is recommended for the additional and safe stabilization of these fractures, particularly in older heavier children. This simple additional implant increases the axial stability and prevents the collapse of the fracture. Transverse fractures, however, are a contraindication for end caps [23].

Although the external fixator is an alternative [24], even in childhood, the refracture rate is high. Elastic intramedullary nailing relies on the fact that children heal rapidly and some soft tissues are intact to act as tethers [21].

Fig 4.4-18a–h A 9-year-old boy with a multifragmentary femoral shaft fracture.
a Injury film.
b Preoperative traction film under image intensifier.
c–d Intraoperative documentation of the reduction and titanium elastic nail fixation. Recognize the good and wide spreading of the nails over a long distance because of the end caps pressure.

Fig 4.4-18a–h (**cont**) A 9-year-old boy with multifragmentary femoral shaft fracture.
e–f At 4-week follow-up with good alignment and good callus formation, weight bearing was allowed.
g–h Full consolidation after 4 months.



Video 4.4-1 Insertion of titanium elastic nails in the femur.

Fig 4.4-19a–h
a–b Displaced, unstable, spiral, subtrochanteric femoral fracture in a young adolescent.
c–d Treatment with elastic stable intramedullary nailing: closed reduction on the traction table and stabilization with prebent titanium elastic 3.5 mm nails.
e–f Postoperative x-ray taken at 8 weeks, full-weight bearing after 6 weeks.
g–h Postoperative x-ray taken at 6 months, after implant removal.

In children around puberty or with heavier children older than 12–13 years, the ESIN method has its limits due to the narrow medullary canal. In this age group and especially for transverse and oblique fractures as well as multifragmentary fractures, the adolescent lateral femoral nail (ALFN) with a strict lateral trochanteric entry point is the implant of choice (**Fig 4.4-20a–i**). The nail diameter of 8.2 or 9 mm in addition to the helical/anatomical shape respects the special anatomy of the femur in this age group [25].

Plate osteosynthesis should be reserved for exceptional situations (ie, older children and secondary treatment). In the older adolescent who is too heavy for elastic intramedullary nailing, plating is an option in femoral shaft fracture management. If possible the MIPO technique should be used.

Classic antegrade intramedullary nailing from the piriform fossa, with or without reaming, should not be performed in the growing child or adolescent as nail introduction can cause avascular necrosis of the femoral head.

Fig 4.4-20a–i Adolescent lateral femoral nail. Bilateral femoral fracture in a 14-year-old girl, right side transverse, left multifragmentary.
a Drawing of the pediatric femoral nail.
b Injury film with bilateral femoral fractures.

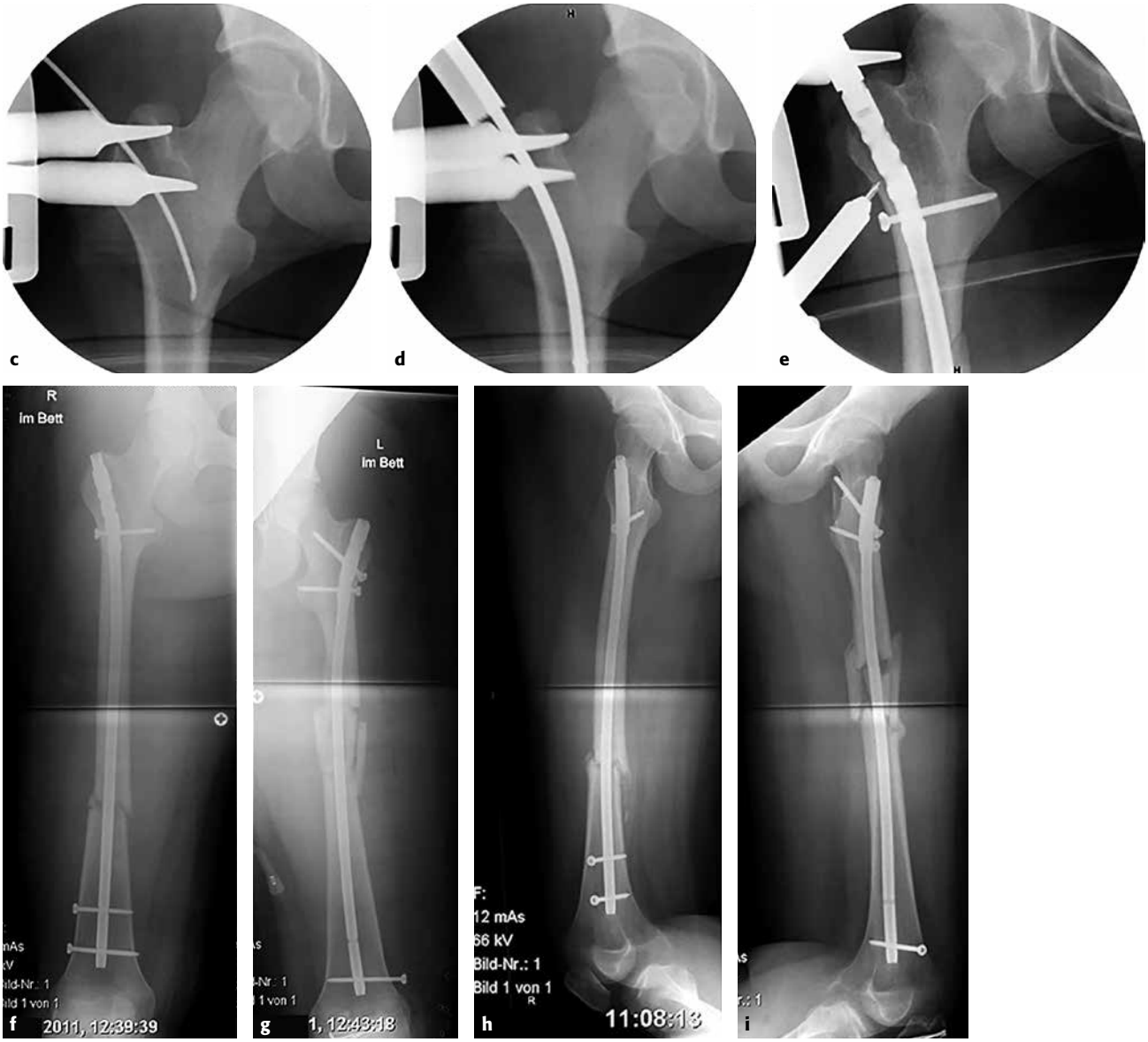

Fig 4.4-20a–i (**cont**) Adolescent lateral femoral nail. Bilateral femoral fracture in a 14-year-old girl, right side transverse, left multifragmentary.
c–e Different steps of the lateral entrance of the nail.
f–g Postoperative AP view.
h–i Postoperative lateral view, both with good alignment and length.

7.3.3 Femur, distal

Fractures of the distal femur are mostly Salter-Harris type II (33-E/1.II) fractures. The reduction and fixation may be difficult, and often requires an open procedure. Definitive fixation can be obtained by crossed, threaded K-wires, which may go across the physis, or by cancellous bone screws introduced parallel to the physis in the metaphyseal fragment. The use of cannulated screws may facilitate this procedure (**Fig 4.4-21**). Repeated attempts at closed reduction will damage the growth plate. Growth arrest commonly follows this fracture, despite the fact that this is a Salter-Harris II injury that should have a low incidence. This injury tends to be high energy and the undulations in the growth plate mean that the proliferative layer is brought into the injury zone.

In very young children a fracture in this bone segment can be a sign of nonaccidental injury.

Fig 4.4-21a–h Salter-Harris type I fracture of the distal femur in a 12-year-old boy. This fracture is like a knee dislocation and can result in nerve and vessel damage.
a–b AP and lateral injury film.
c Intraoperative image of the reduction and K-wire fixation. In this technique, the wires are intraarticular during healing which creates a portal for joint infection. Healing in the distal femur takes twice as long as in the distal humerus.

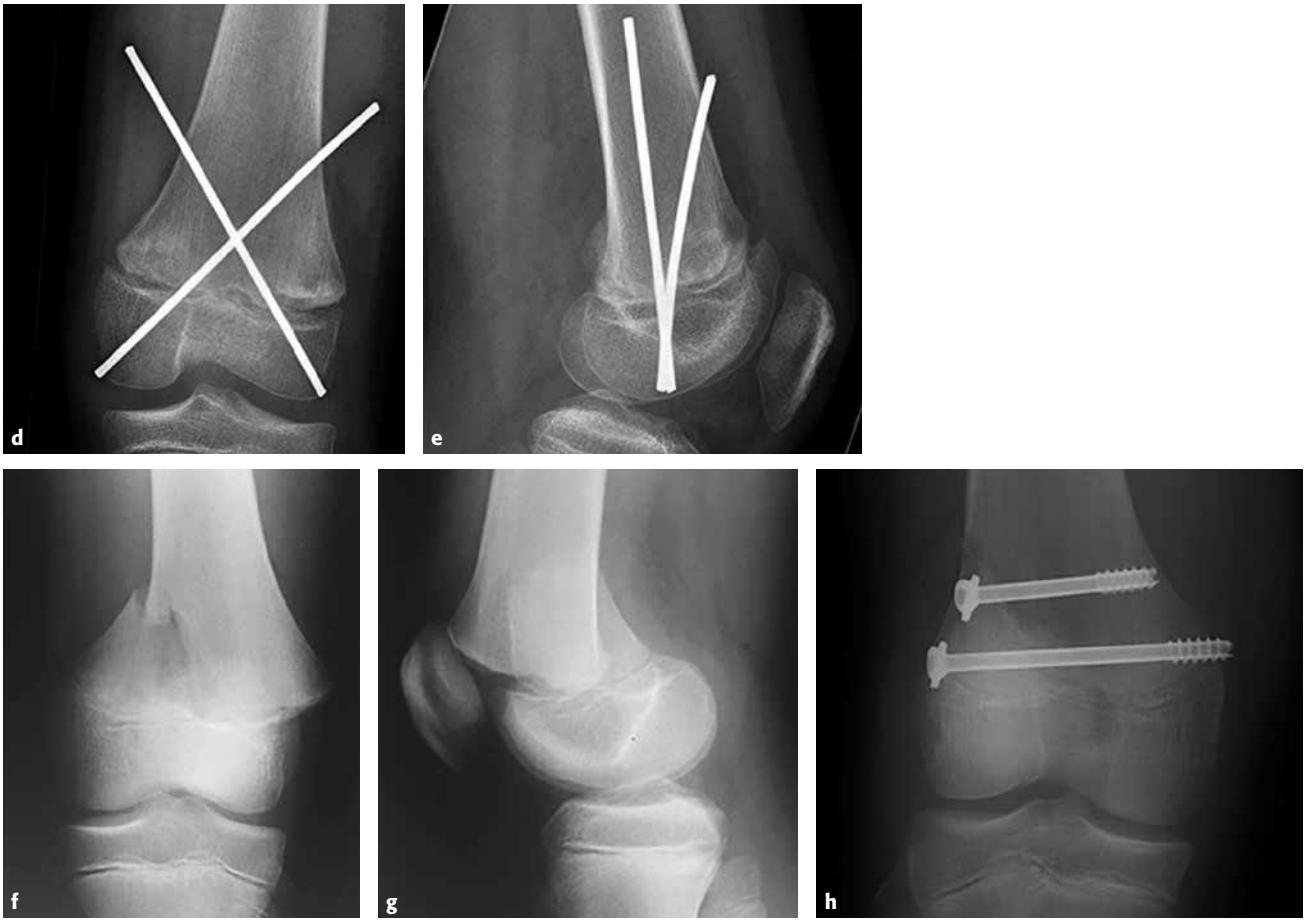

Fig 4.4-21a–h (**cont**) Salter-Harris type I fracture of the distal femur in a 12-year-old boy. This fracture is like a knee dislocation and can result in nerve and vessel damage.

d–e Alternative technique; the wires are advanced proximally so that the distal ends are in the bone. This prevents joint infection (be aware of the vessels on the medial side).

f–g Injury film of a Salter-Harris type II fracture in a 13-year-old girl with a short metaphyseal wedge.

h X-ray after closed reduction and percutaneous cannulated lag screw fixation.

7.4 Tibia

7.4.1 Tibia, proximal epiphysis

Fractures of the tibial tuberosity are due to direct trauma and are rare. These injuries are easily overlooked, especially in the young child, which may lead to a progressive genu recurvatum deformity. Visible fractures must therefore be fixed by (cannulated) lag screws (**Fig 4.4-22a–d**); in very small children a tension band wire may suffice (**Fig 4.4-22e**).

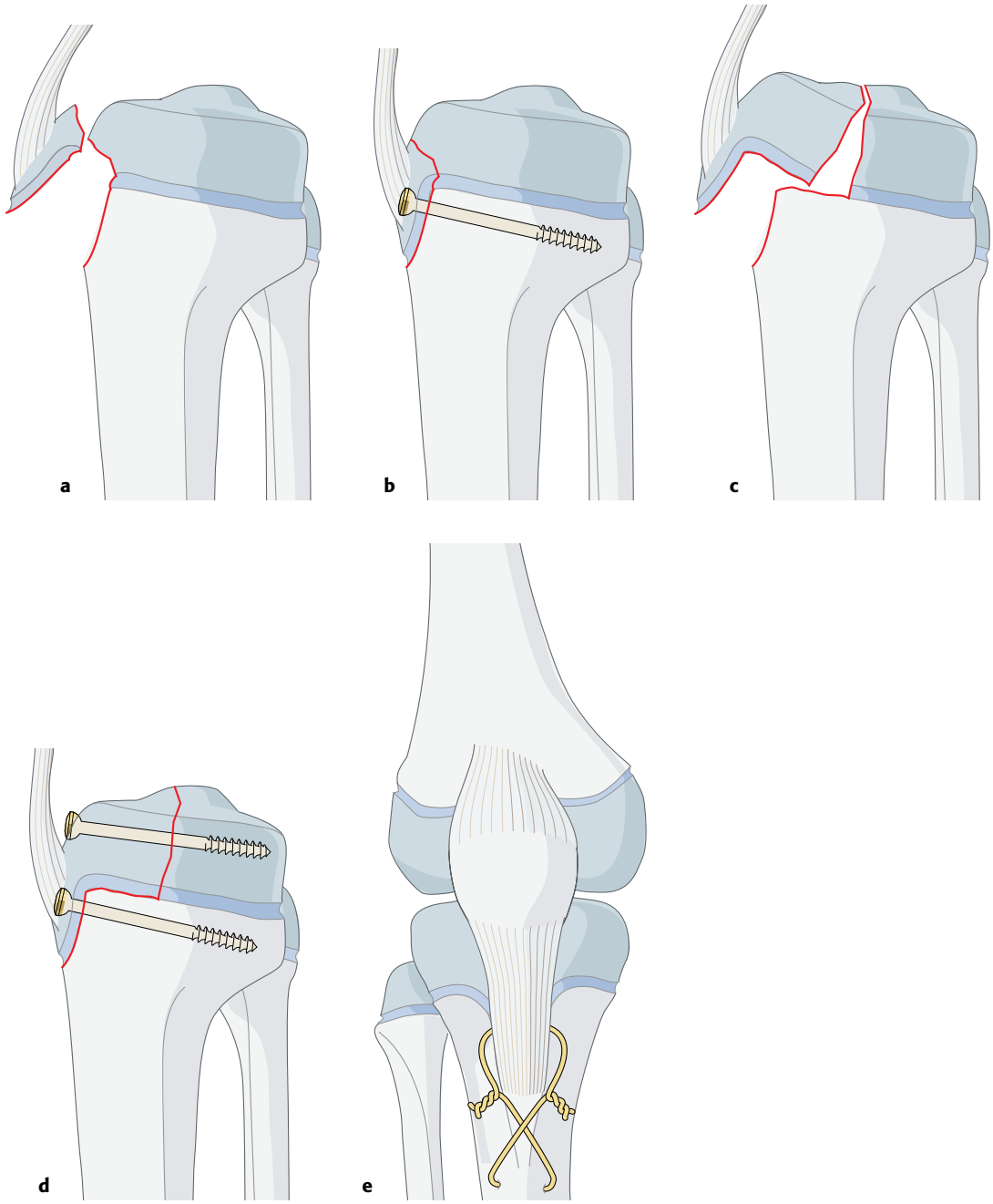

Fig 4.4-22a–i
a–d Avulsion of the tibial tuberosity in an adolescent requiring anatomical reduction and lag screw fixation.
e In a younger child, a wiring or suture technique is indicated.

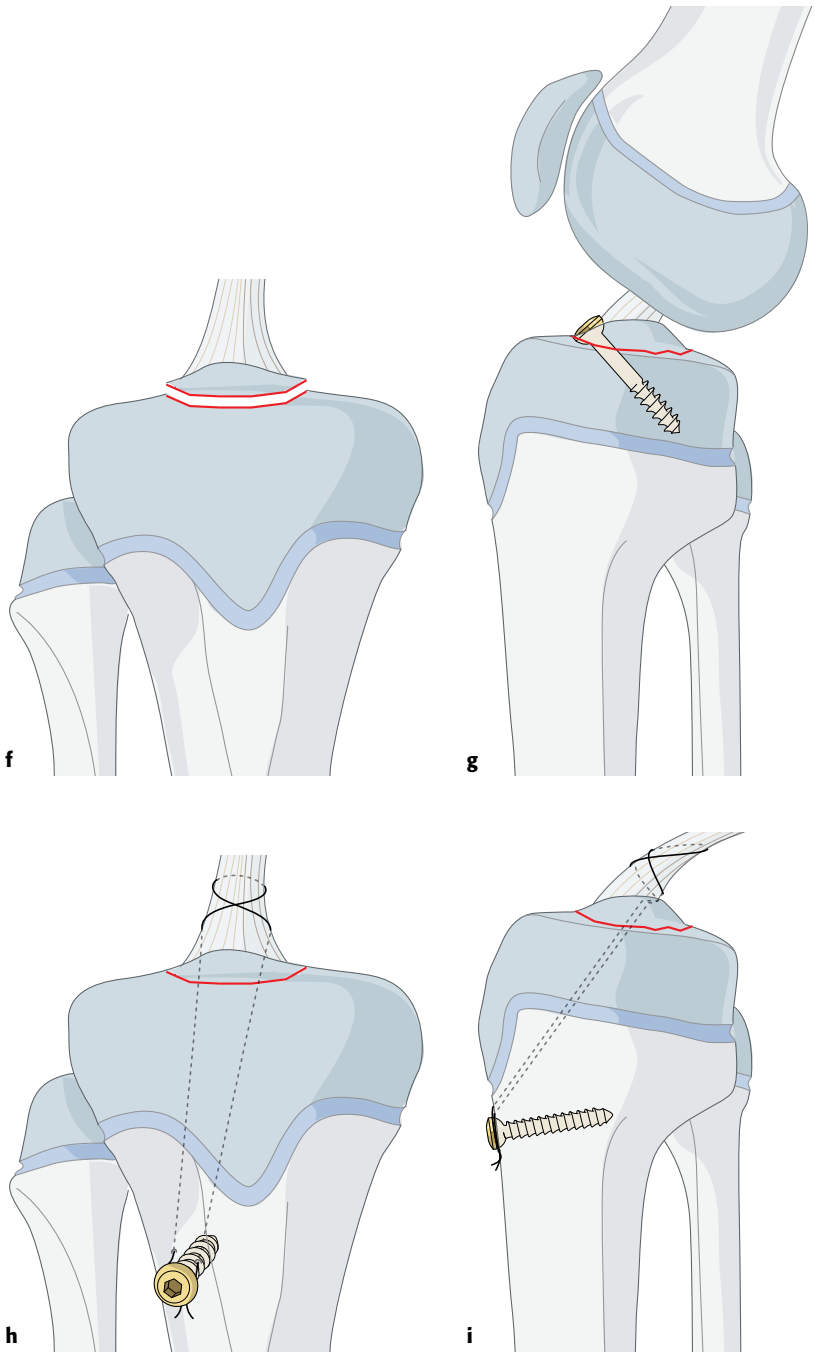

Fig 4.4-22a–i (**cont**)
f–g Displaced fracture of the anterior tibial spine. Stabilization with a short lag screw.
h–i A large avulsed fragment may be held by an alternative technique. A resorbable thread is placed into the anterior cruciate ligament insertion, passed out through the base of the avulsed fragment, then through two drill holes across the physis to exit the anterior tibial cortex, where it can be tightened and tied over a small cortex anchor screw.

Displaced fractures of the anterior tibial spine are due to avulsion of the anterior cruciate ligament and in children and adolescents should be reduced and adequately fixed. This can be achieved arthroscopically or through a small arthrotomy. Either way the fragment must be replaced under the intermeniscal ligament. To fix the fragment, lag screws may be used through an intraarticular approach (**Fig 4.4-22f–g**). An alternative is to use cerclage with resorbable suture material introduced through two parallel drill holes (**Fig 4.4-22h–i**). Recessing the fragment is an important part of the procedure as the anterior cruciate ligament has always been stretched before avulsion of the tibial spine. Postoperatively, the knee should be immobilized with a splint in neutral position for 4–5 weeks (axial weight bearing allowed), a method that can also be considered for treatment of a minimally displaced fragment.

7.4.2 Tibia, shaft

Fractures of the tibial shaft are the most frequent fractures of the lower extremity. Nonoperative treatment in a cast is the standard management. Care must be taken with isolated tibial fractures. Due to the intact fibula, varus angulation is common. This deformity appears to correct itself over time in most instances. Isolated tibial shaft fractures are usually immobilized in an above-knee cast, while angulation may be corrected by wedging of the cast about 1 week after the injury.

In stable fractures of both fibula and tibia that do not require major reduction, a cast is a safe and reliable method of treatment. More unstable lower leg fractures may be subject to progressive shortening, which is not as easily corrected as axial malalignment.

Displaced or unstable tibial shaft fractures must be reduced with the patient under general anesthesia. If open reduction is required, or if the fracture is unstable following closed reduction, then definitive operative fixation with ESIN [20, 21] or an external fixator is appropriate. In more complex fractures and in heavier or obese children, plating remains a well-established and proven alternative. Classic intramedullary nailing should not be performed so as to avoid physeal and apophyseal damage.

Compartment syndrome appears to be more common in adolescent patients with closed tibial fractures. This is probably because the fascia is particularly strong and inelastic in this age group, and the normal diastolic blood pressure is lower than in adults.

In case of a manifest or impending compartment syndrome, fractures of the lower leg must be operatively stabilized following fasciotomy.

Distal metaphyseal valgus fractures are rare and may be associated with a fibular fracture. These injuries have a tendency to progressive valgus deformity and delay of medial consolidation. Malalignment must be corrected early by a cast or by applying a medial external fixator to compress the fracture gap.

While nonoperative treatment, as a rule, is to be preferred, the following indications require an operative approach:

- Grossly unstable fractures
- Progressive varus or valgus angulation
- Open fractures
- Severe closed soft-tissue injuries including degloving
- Compartment syndrome
- Tibial fractures in the polytraumatized child

7.4.3 Tibia, distal epiphysis, and metaphysis

Growth-plate disturbance and/or growth arrest can occur after any distal fracture of the tibia. This applies to Salter-Harris types I and II fractures as well as more complex injuries.

The treatment of nondisplaced or minimally displaced fractures is primarily nonoperative by cast. With major displacement, a closed reduction under anesthesia may be attempted. However, consent should be obtained for operative fixation under the same anesthetic. For fixation of the fragments, K-wires or percutaneous 3.5 or 4.0 mm screws may be used (**Fig 4.4-23a–g**).

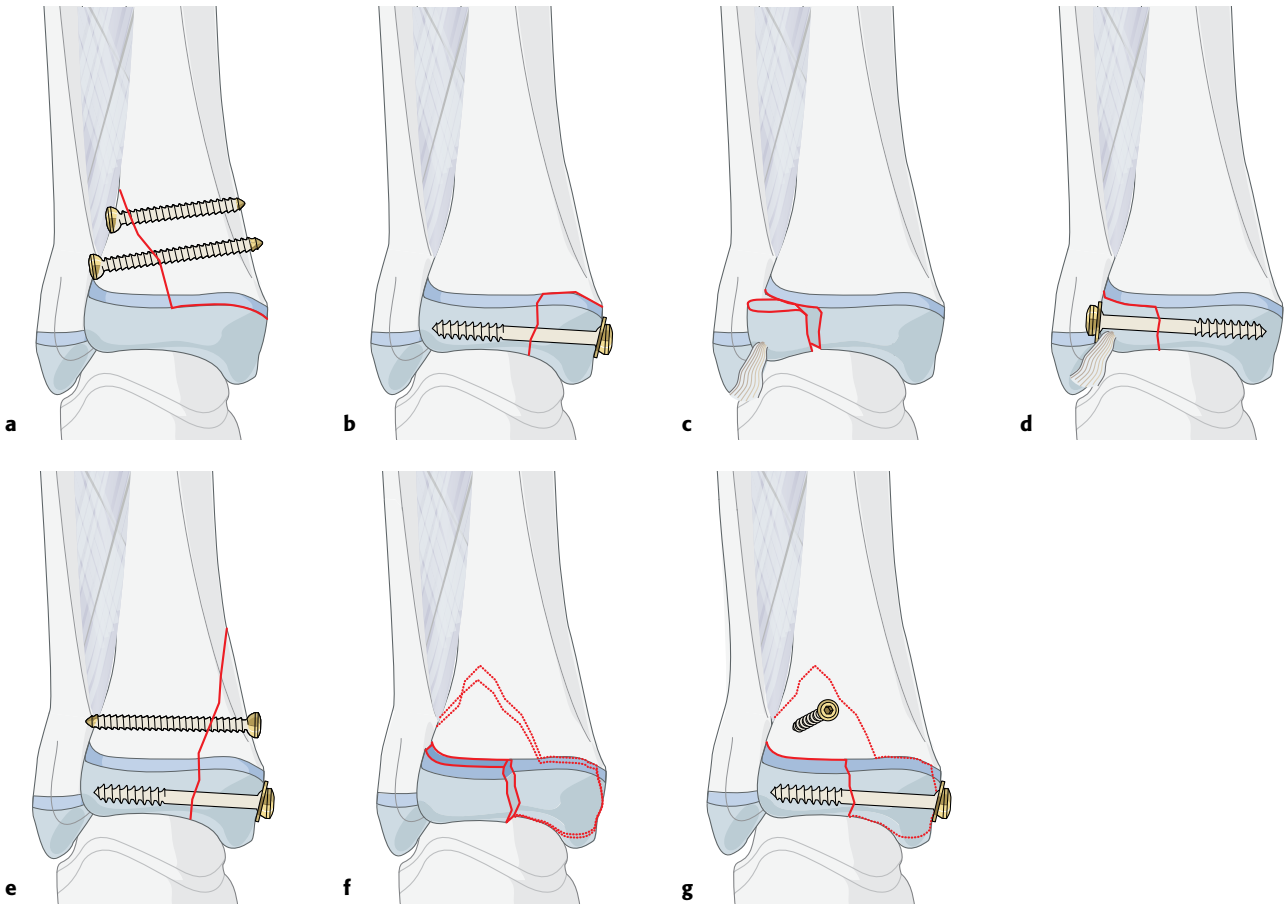

Fig 4.4-23a–g Ankle injuries.
a Salter-Harris type II injury can be stabilized with one to two cannulated cancellous bone screws across the metaphyseal fracture.
b Salter-Harris type III fracture of the medial malleolus after anatomical reduction and fixation with a 4.0 mm cancellous bone screw totally within the epiphysis.
c–d Biplane fracture of the tubercle of Tillaux fixed using an intraepiphyseal lag screw.
e Salter-Harris type IV injury fixed using two screws, above and below the growth plate, providing absolute stability.
f–g The triplane fracture has a complex configuration and various forms. The lag screws—metaphyseal or epiphyseal—must be correctly placed, respecting the fracture planes. Additional stabilization of the fibula is usually not necessary in children.

During transition from adolescence to skeletal maturity the physeal plates slowly fuse which may lead to unusual fracture patterns. Two typical injuries may be observed: the biplane or juvenile Tillaux (purely physeal), and the triplane (that also includes a metaphyseal part) fractures (**Fig 4.4-24**). The fracture line may extend into the joint or the medial malleolus. Any fracture gap of more than 2.0 mm should be operated upon to obtain an anatomical reduction. Small-fragment cannulated screws are most appropriate for stable fixation. The screws can cross the physis as growth is ending when these fractures have occurred. A preoperative CT scan is helpful for defining the fracture, assessing displacement, and planning fixation.

In very young children a fracture in this bone/segments can be a sign of nonaccidental injury.

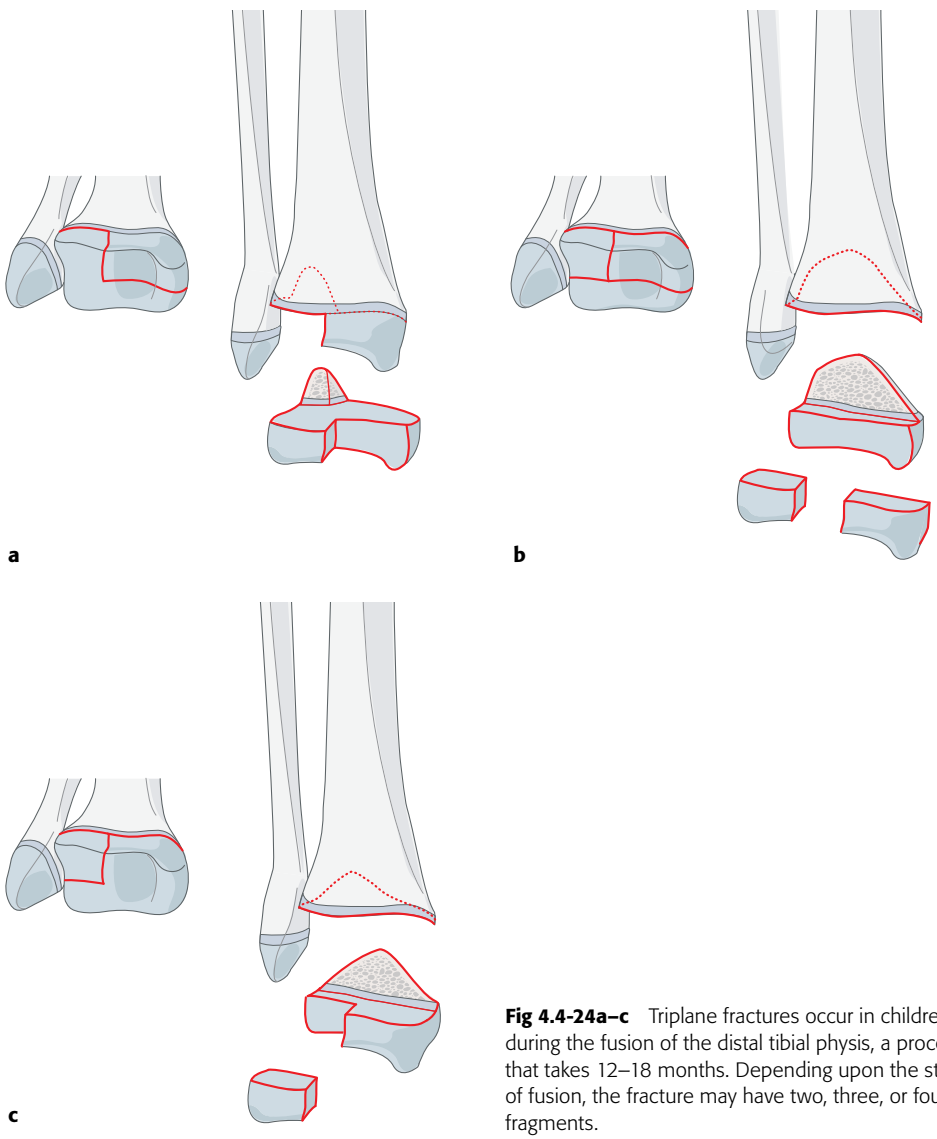

Fig 4.4-24a–c Triplane fractures occur in children during the fusion of the distal tibial physis, a process that takes 12–18 months. Depending upon the stage of fusion, the fracture may have two, three, or four fragments.

Classic references | Review references

8 References

1. **Mann DC, Rajmaira S.** Distribution of physeal and nonphyseal fractures in 2,650 long-bone fractures in children aged 0–16 years. *J Pediatr Orthop.* 1990 Nov-Dec;10(6):713–716.
2. **Slongo T, et al.** [Klassifikation und Dokumentation der Frakturen im Kindesalter]. *Zentralblatt Kinderchir.* 1995;4:157–163. German.
3. **Roux W.** *Gesammelte Abhandlungen über Entwicklungsmechanik der Organismen.* Leipzig: Engelmann; 1895. German.
4. **Schenk RK.** Histomorphologische und physiologische Grundlagen des Skelettwachstums. In: Brunner C, Weber BG, Freuler F, eds. *Die Frakturenbehandlung bei Kindern und Jugendlichen.* 1st ed. Berlin Heidelberg New York: Springer-Verlag; 1978. German.
5. **Hunziker EB, Schenk RK.**) Physiological mechanisms adopted by chondrocytes in regulating longitudinal bone growth in rats. *J Physiol.* 1989 Jul;414:55–71.
6. **Trueta J, Morgan JD.** The vascular contribution to osteogenesis. I. Studies by the injection method. *J Bone Joint Surg Br.* 1960 Feb;42-B:97–109.
7. **Duhamel HL.** *Sur le Dévelopement et la Crue des Os des Animaux.* Paris, Histoire de l'Académie Royale des Sciences; 1742;354–370. French.
8. **von Laer L.** Growth and growth disturbances. In: von Laer L, ed. *Pediatric Fractures and Dislocations.* 1st ed. Stuttgart New York: Georg Thieme Verlag; 1991.
9. **Beaty JH.** Fractures of the proximal humerus and shaft in children. *Instr Course Lect.* 1992;41:369–372.
10. **Kwon Y, Sarwark Jr.** Proximal humerus, scapula and clavicle. In: Beaty JH, Kasser JR, eds. *Rockwood and Wilkins' Fractures in Children.* 5th ed. Philadelphia: Lippincott Williams & Wilkins; 2001:741–806.
11. **Price CT, Mencio GA.** Injuries to the shaft of the radius and ulna. In: Beaty JH, Kasser JR, eds. *Rockwood and Wilkins' Fractures in Children.* 5th ed. Philadelphia: Lippincott Williams & Wilkins; 2001:443–482.
12. **Kasser JR, Beaty JH.** Femoral shaft fractures. In: Beaty JH, Kasser JR, eds. *Rockwood and Wilkins' Fractures in Children.* 5th ed. Philadelphia: Lippincott Williams & Wilkins; 2001:941–980.
13. **Heinrich SD.** Fractures of the shaft of the tibia. In: Beaty JH, Kasser JR, eds. *Rockwood and Wilkins' Fractures in Children.* 5th ed. Philadelphia: Lippincott Williams & Wilkins; 2001:1077–1119.
14. **Salter RB, Harris WR.** Injuries involving the epiphyseal plate. *J Bone Joint Surg Am.* 1963;45:857.
15. **Rang M.** *Children's Fractures.* 2nd ed. Philadelphia: Lippincott Raven; 1983.
16. **Slongo T, Audigé L, Schlickewei W, et al.** Development and validation of the AO pediatric comprehensive classification of long bone fractures by the Pediatric Expert Group of the AO Foundation in collaboration with AO Clinical Investigation and Documentation and the International Association for Pediatric Traumatology. *J Pediatr Orthop.* 2006 Jan-Feb;26(1):43–49.
17. **Slongo T, Audigé L, Clavert J, et al.** The AO comprehensive classification of pediatric long-bone fractures: a web-based multicenter agreement study. *J Pediatr Orthop.* 2007 Mar;27(2):171–180.
18. **Slongo T.** [Radialer externer Fixateur zur geschlossenen Behandlung problematischer suprakondylärer Humerusfrakturen Typ III und IV bei Kindern und Jugendlichen.] *Oper Orthop Traumatol.* 2014;26:75–97. German.
19. **Slongo T, Schmid T, Wilkins K, et al.** Lateral external fixation—a new surgical technique for displaced unreducible supracondylar humeral fractures in children. *J Bone Joint Surg Am.* 2008 Aug;90(8):1690–1697.
20. **Metaizeau JP, Lascombes P, Lemelle JL, et al.** Reduction and fixation of displaced radial neck fractures by closed intramedullary pinning. *J Pediatr Orthop.* 1993 May-Jun;13(3):355–360.
21. **Dietz HG, Schmittenbecher PP, Slongo T, et al.** *AO Manual of Fracture Management. Elastic Stable Intramedullary Nailing (ESIN) in Children.* 1st ed. Stuttgart New York: Georg Thieme Verlag; 2006.
22. **Prévot J, Lascombes P, Ligier JN.** [The ECMES (Centro-Medullary Elastic Stabilising Wiring) osteosynthesis method in limb fractures in children. Principle, application on the femur. Apropos of 250 fractures followed-up since 1979]. *Chirurgie.* 1993-1994;119(9):473–476.
23. **Slongo T, Audigé L, Hunter JB, et al.** Clinical evaluation of end caps in elastic stable intramedullary nailing of femoral and tibial shaft fractures in children. *Eur J Trauma Emerg Surg.* 2011; 37:305–312.
24. **Weinberg AM, Hasler CC, Leiner A, et al.** External fixation of pediatric femoral shaft ractures: reatment and results of 121 fractures. *Europ J Trauma.* 2000;26:25–32.
25. **Reynolds RAK, Legakis JE, Thomas R, et al.** Intramedullary nails for pediatric diaphyseal femur fractures in older, heavier children: early results. *J Child Orthop.* 2012; 6:181–188.

4.5 Antibiotic prophylaxis

Susan Snape

1 Introduction

Despite applying aseptic principles to the practice of surgery, surgical site infections still occur, not only after open fractures but also after clean surgical procedures such as internal fixation of closed fractures or joint replacement surgery.

Antimicrobial prophylaxis is mainly indicated in procedures associated with a high rate of infection, such as clean contaminated or contaminated operations [1].

The criteria for a clean surgical wound include [2]:

- Elective procedure (ie, not emergency) with primary wound closure
- Absence of acute inflammation
- No break in aseptic technique
- Absence of transection of colonized surfaces (ie, respiratory, alimentary, or genitourinary tracts)

Clean surgery is associated with an infection rate of 1.5% (in a series of 47,000 procedures) [3]. In such surgery, antibiotic prophylaxis is generally not indicated because the benefits of antibiotics are outweighed by the risks in terms of allergy, antibiotic-associated diarrhea, *Clostridium difficile* infection, increases in antibiotic resistance, selection for multiresistant organisms, and lack of cost-effectiveness.

Dirty operations are characterized by pus, previously perforated hollow viscus, or open injuries more than 4 hours old. These, by definition, are infected and hence require treatment.

Perioperative antibiotic prophylaxis has become the standard practice in surgery using implants [4].

Elek and Conen [5] first demonstrated the role of foreign bodies in increasing the incidence of wound infection. In the presence of suture material, a 10,000-fold lower inoculum of *Staphylococcus aureus* still led to skin abscesses in human volunteers. Using an animal model, Zimmerli et al [6] demonstrated that implant material increased the risk of infection. They suggested this was due to locally acquired defects in granulocyte function.

Prophylaxis of surgical site infection not only depends on the appropriate antibiotic but also on operating room discipline, appropriate surgical technique, and proper awareness, and avoidance of the risk factors summarized in **Table 4.5-1** [7] with a comprehensive review and recommendations available online from the World Health Organization [8].

Antibiotic prophylaxis should not distract surgeons from careful aseptic surgery, avoidance of risk factors, adequate operating room ventilation, operating room discipline, and meticulous surgical technique.

Risk factor	
Patient	**Operation**
Extremes of age	Length of surgical scrub
Poor nutritional state	Skin antisepsis
Obesity (> 20% over ideal body weight)	Preoperative shaving
Diabetes mellitus	Preoperative skin preparation
Smoking; other addictions	Length of operation
Coexisting infections at other sites	Antimicrobial prophylaxis
Bacterial colonization (eg, nasal colonization with *Staphylococcus aureus*)	Operating room ventilation
Immunosuppression (steroid or other immunosuppressive drug use)	Inadequate instrument sterilization
Prolonged postoperative stay	Foreign material in surgical site
Coexistent severe disease that either limits activity or is incapacitating	Surgical drains
Malignancy	Surgical technique including hemostasis, poor closure, tissue trauma
Emergency patient rather than elective surgical patient	Postoperative hypothermia
Alcoholism	Poor operating room discipline

Table 4.5-1 Factors that influence the risk of surgical site infection.

An expert group [9] has published the quality standard for antimicrobial prophylaxis in surgical procedures. Parenteral antimicrobial prophylaxis should be administered in orthopedic procedures with implantation of prosthetic material.

The risk of infection varies according to the type of fracture and the surgical procedure:

- Patients undergoing joint replacement, or with closed fractures, have an infection rate of 0–5% [10].
- In patients with open fractures, the incidence of wound infection correlates directly with the extent of soft-tissue damage. Fractures graded by the Gustilo classification,have infection rates of:
  - 0–2% for type I
  - 2–7% for type II
  - 7% for type IIIA
  - 10–50% for type IIIB
  - 25–50% for type IIIC fractures [11]

In Gustilo type III open fractures, there is extensive soft-tissue damage. In this situation, surgery often takes place in a heavily contaminated field. Therefore, short-term empirical treatment, and not only prophylaxis, should be administered.

2 Microbiology of bone-implant infections

The microbiology of prosthetic joint infections is well known. As in other types of implant-related infections, staphylococci are the predominant infecting agents. This is mainly due to:

- Presence of staphylococci within lower layers of skin, which are not reached by antiseptic skin preparation
- Staphylococci possessing virulence factors that bind to host proteins, such as fibrin and fibronectin, and facilitate adherence of staphylococci to implants [12]

In patients undergoing joint replacement surgery, the most common infecting agents are coagulase-negative staphylococci (30–41%) and *S aureus* (12–39%) [13]. No organism is detected in 5–12% of infections [14].

In fracture surgery, *S aureus* largely predominates in comparison with other microorganisms. Coagulase-negative staphylococci infections are less prevalent than in joint replacement procedures.

Boxma et al [15] performed a randomized trial of single-dose antibiotic prophylaxis versus placebo in surgery for closed fractures. In the placebo group, the infecting microorganisms were:

- *S aureus* 64%
- Coagulase-negative staphylococci 3%
- Streptococci 8%
- Mixed Gram-positive cocci 5%
- Gram-negative bacilli 6%
- Mixed Gram-positive/Gram-negative microorganisms 8%
- Mixed aerobic/anaerobic bacteria 5%

Patients with open fracture are exposed to a wide range of environmental organisms covering the spectrum of Gram-positive, Gram-negative, and anaerobic bacteria including *Clostridium tetani*. Dirty wounds are often exposed to what is termed fecal or farmyard flora. Furthermore, wound infections among combat casualties with tibial fractures have been associated with drug-resistant aerobic Gram-negative organisms, including *Acinetobacter baumannii*, *Pseudomonas aeruginosa*, and fungi [16].

3 Antimicrobial drugs for prophylaxis

Various antimicrobial substances have been shown to be effective in perioperative prophylaxis.

The following aspects of antimicrobials should be considered when choosing an antibiotic prophylaxis regimen [17]:

- The drug(s) should be active against the most common infecting microorganisms involved in implant-associated infection.
- The susceptibility pattern of infecting microorganisms differs in various hospitals. Each hospital needs up-to-date analysis of the resistance pattern of surgical site isolates and prophylactic antimicrobial agents tailored accordingly.
- The risk of causing allergic reactions or adverse effects should be minimal.
- Antimicrobial substances with a high potency to produce resistant strains should be avoided, for example, strong β-lactamase inducers like cefoxitin or ceftazidime.
- The potency of different antimicrobials to precipitate symptomatic *Clostridium difficile* infection need be reviewed.

- Speed of administration. For example, while vancomycin requires at least 1 hour to infuse (otherwise "red-man syndrome" occurs), the alternative glycopeptide agent, teicoplanin, can be given as a bolus, allowing operating time to be optimized.
- Fracture classification will alter the choice of antibiotic regimen.
- If drugs have similar efficacy, cost should be considered.

The Hospital Infection Control Practices Advisory Committee (HICPAC) [18] recommendations for preventing the spread of vancomycin resistance clearly discourage the use of glycopeptides in routine surgical prophylaxis. Importantly, a metaanalysis of six randomized controlled trials [19], involving 2,886 patients, evaluated the effectiveness of teicoplanin compared with first- or second-generation cephalosporins for perioperative antiinfective prophylaxis. No differences were found between teicoplanin and cephalosporins with respect to the development of infection at the site of surgery. This data support the recommendation to reserve glycopeptide use for patients who are allergic to β-lactam antibiotics or who are colonized with methicillin-resistant *S aureus* (MRSA).

In closed and open Gustilo types I and II fracture surgery, first- or second-generation cephalosporins, such as cefazolin, cefamandole, or cefuroxime, are a rational choice. If a hospital has concerns about *Clostridium difficile* infection, then flucloxacillin in conjunction with gentamicin is a preferable combination. If the patient is allergic to β-lactam antibiotics (ie, penicillins, cephalosporins, and carbapenems) or known to be colonized with MRSA, the glycopeptide antibiotics vancomycin or teicoplanin are alternative options.

In Gustilo type III fracture surgery, there may be gross contamination of the wound. In a prospective study [20] of 227 patients with open fractures, prophylaxis with clindamycin was compared with cloxacillin. Unacceptably high rates of infection were reported in grade III fractures for both clindamycin (29.0%) and cloxacillin (51.8%), demonstrating the need for additional Gram-negative coverage in higher Gustilo type fractures [20]. Another randomized prospective study [21] compared the efficacy of intravenous ciprofloxacin with ceftazidime/gentamicin. This study enrolled 163 patients with 171 open fractures (type I [65], type II [54], and type III [52]). In types I and II fractures, the infection rate for the ciprofloxacin group and the ceftazidime/gentamicin group was 5.8% and 6.0%, respectively. While ceftazidime/gentamicin also demonstrated good efficacy among those with type III fractures (7.7% infection rate), ciprofloxacin was associated with an unacceptably high infection rate (31%) [21]. Furthermore, animal model studies [22] have demonstrated a delay in fracture union with the use of ciprofloxacin prophylaxis, hence this antibiotic is not recommended for routine use. In conclusion, prophylactic antibiotics used in Gustilo type III fractures need to be broad spectrum covering all likely pathogens [23].

4 Timing of prophylaxis

Timing of prophylaxis varies depending on the classification of the fracture. Patients with open fractures should be evaluated for their need of tetanus immunization [24]. For all open fractures, administration of parenteral antibiotics is warranted as soon as possible (and ideally within 3 hours of trauma) to reduce the risk of soft-tissue infection or osteomyelitis. Antibiotic efficacy administered either before or at the time of primary treatment was demonstrated in a metaanalysis including 1,106 patients with open fractures [25]. Use of prophylactic antibiotics was associated with an absolute risk reduction in infection of 0.07 (95% confidence interval [CI]: 0.03–0.10), when combined with wound irrigation, surgical debridement, and fracture stabilization.

For both open and closed fractures requiring insertion of metalwork, perioperative antibiotic prophylaxis is essential at the time of wound debridement. Optimal antibiotic efficacy is achieved by providing inhibitory antimicrobial tissue levels at the time of incision and during the entire surgical procedure.

In a seminal animal study, Burke [26] observed that the effective window for antibiotic prophylaxis may be just 3 hours. Even a 1-hour delay markedly decreased the efficacy of the single-dose prophylaxis dose. These conclusions from animal data have been confirmed with a large retrospective clinical study [27] of 2,847 wounds. The risk of surgical site infection increased sixfold when prophylaxis was given either too early (> 2 hours before surgery) or too late (> 3 hours after surgery).

Parenteral perioperative prophylaxis should be administered intravenously in a period beginning 60 minutes before incision [9, 17].

Antibiotic tissue levels are insufficient if the drug is administered less than 5–10 minutes before inflation of a tourniquet [28].

For adequate prophylaxis, antibiotics should be given at least 10 minutes before the tourniquet is inflated.

5 Duration of antibiotic use

The duration of therapy depends on the classification of the fracture.

5.1 Closed fractures

A systematic review [29] of antibiotic prophylaxis for surgery for proximal femoral and other closed long-bone fractures included data from 8,447 participants in 23 studies. In patients undergoing surgery for closed fracture fixation, single-dose antibiotic prophylaxis significantly reduced deep surgical site infection by 60% (risk ratio: 0.40; 95% CI: 0.24–0.67). Multiple dose prophylaxis had a similar effect with a 65% reduction in the relative risk of deep surgical site infection (risk ratio: 0.35; 95% CI: 0.19–0.62). Hence, the effect of a single dose of antibiotic is similar to that obtained from multiple doses, providing the chosen antibiotic is active from the beginning of surgery until the wound is sealed.

For closed fractures antibiotic prophylaxis should ideally not exceed 1 dose.

The caveat to this advice is if the duration of operation is longer than 4 hours or blood loss is more than 1,500 cc, then redosing with the recommended prophylaxis regimen for that operation is recommended (**Table 4.5-2**).

5.2 Open fractures

Open fractures traditionally receive longer courses of antibiotics. The EAST working-group guidelines [23] advocate that for type I and type II fractures antibiotics be discontinued a maximum of 24 hours after successful wound closure. For type III fractures, antibiotics should be administered until soft-tissue closure or for a maximum of 72 hours, whichever comes first. This recommendation is in part based on data that reports no additional reduction in risk of infection when antibiotics are continued beyond 3 days [30]. Indeed, in a randomized, double-blinded trial [31] of 248 patients aged 14–65 years, there was no significant difference in fracture-site infections between patients receiving a 1-day course of a first-generation cephalosporin compared with a 5-day course of either a first- or second-generation cephalosporin. Importantly, prolonged courses of more than one antibiotic for more than 24 hours following severe trauma are associated with resistant infections [32].

Common antibiotics	Recommended redosing interval/dose to give
Cefuroxime	4 h, give 1.5 g IV
Flucloxacillin	3 h, give 1 g IV
Gentamicin	Redosing not recommended
Pipericillin/tazobactam	2 h, give 4.5 g IV
Metronidazole	8 h, give 500 mg IV
Teicoplanin	Redosing not recommended

Table 4.5-2 Recommendations for redosing intervals for patients with major blood loss or for operations lasting > 4 hours. Abbreviation: IV, intravenous.

For open fractures Gustilo types I and II, duration of prophylaxis should not exceed 1 day. For open fractures Gustilo type III, duration of prophylaxis should not exceed 3 days.

6 Controversial issues

6.1 Breadth of spectrum of antibiotic prophylactic cover

For closed and Gustilo types I and II open fractures it should be the rule to choose as narrow a spectrum of coverage as possible. Indeed, an excellent study by Boxma et al [15] evaluated this rule by comparing ceftriaxone, a third-generation cephalosporin with regimens using older cephalosporins. Ceftriaxone had no advantage, apart from providing efficacious tissue levels for 24 hours with a single dose.

For closed, Gustilo types I and II open fractures, there is little evidence to suggest that antimicrobial substances with a broader in vitro antibacterial spectrum have any advantage compared to antibiotics with a narrower spectrum.

6.2 Use of glycopeptides (vancomycin and teicoplanin) in prophylaxis

Because of the emergence of vancomycin-resistant enterococci, vancomycin and teicoplanin should be strictly reserved for patients who are allergic to β-lactam antibiotics, MRSA-colonized patients, or centers with a high prevalence of MRSA [17, 18].

Linezolid should also be reserved for the treatment of patients with resistant staphylococci or multiresistant enterococci [33].

6.3 *Clostridium difficile* infection

Clostridium difficile infection is an important infection associated with healthcare. It results in severe diarrhea and in some instances, life-threatening colitis. It is not clear how many patients develop *Clostridium difficile* infection following antibiotic prophylaxis—reported rates span 0.2–8%, depending on the surgical procedure involved [17]. Restricting high-risk antibiotics (cephalosporins, fluoroquinolones, clindamycin, and carbapenems) contributes to a reduction in *Clostridium difficile* infection rates [34].

In a study of more than 1,800 patients [35] undergoing hip fracture surgery, reducing the number of prophylactic cefuroxime doses from 3 to 1 (with a concomitant dose of gentamicin) resulted in a significant decrease in *Clostridium difficile* infection from 4.2–1.6% ($P = .009$).

A cohort study [36] of 1,331 orthopedic patients undergoing elective orthopedic or trauma implant surgery demonstrated a change from cephalosporin to a gentamicin-based regimen reduced the frequency of *Clostridium difficile* infection from 8% to 3%, ($P = .02$) in trauma patients. This occurred without a significant change in incidence of deep-wound infections. The drive to reduce CDI in certain countries has prompted a change in antibiotic prophylaxis from cephalosporins to flucloxacillin and single-dose gentamicin. However, the unintended consequence is an increased incidence of acute kidney injury postoperatively when doses of 4 mg/kg gentamicin were used [37]. This result contrasts with Dubrovskaya et al [38] who evaluated the incidence of nephrotoxicity in patients receiving a single high dose (5 mg/kg) gentamicin for perioperative prophylaxis in orthopedic surgery. They reported that gentamicin was not an independent predictor of nephrotoxicity and hence is a safe option for perioperative prophylaxis. We have not found a rise in incidence of nephrotoxicity using lower doses of 2 mg/kg gentamicin (unpublished data).

Clostridium difficile infection is a risk for all patients receiving antibiotic prophylaxis. Restriction of high-risk antibiotics (cephalosporins, fluoroquinolones, clindamycin, and carbapenems) should be considered when deciding upon individual hospital prophylactic antibiotic guidelines.

6.4 Carriage of multiresistant organisms

All hospitals are experiencing a rise in the rate of antibiotic resistance. Increased use of antibiotics contributes to the development of more resistance [17]. Carbapenem antibiotics (meropenem, imipenem, ertapenem) were once considered the backstop of antimicrobial management. However, internationally, there has been an increase in carbapenem-resistant enterobacteria. Without judicious use of antibiotics and strict infection-control practices, bacterial strains that are resistant to multiple antibiotics will become part of the endemic flora of a hospital. While there is currently no evidence that the carriage of multiresistant organisms is associated with higher rates of postoperative surgical site infection than carriage of sensitive strains, infection with a multiresistant organism is often more difficult and costly to treat.

Patients with suspected multiresistant carriage should be isolated until results of screening can be obtained. If multiresistant organisms are present, a change in the choice of prophylactic antibiotics should be discussed with the local microbiology department [17]. If possible, their surgery should be planned as the last case of the day.

6.5 Decolonization of patients with *S aureus* nasal carriage

Patients with *S aureus* colonization of the nose have an increased risk for subsequent staphylococcal wound infection. Decolonization with mupirocin nasal ointment reduces staphylococcal carriage. A systematic review [39] has analyzed 19 studies that examined the ability of decolonization protocols to reduce orthopedic surgical site infections. All 19 studies, incorporating a mixture of elective orthopedic and trauma patients, showed a reduction in surgical site infections or wound infections by instituting an *S aureus* screening and decolonization protocol. Ten studies demonstrated *S aureus* screening and decolonization saved money compared with the cost of treating surgical site infections.

In contrast, the *S aureus* carriage status of emergency patients, including trauma patients, is often unknown. Many hospitals screen for MRSA, as this can be a national mandatory requirement; however, this does not capture methicillin-sensitive *S aureus*. Some institutions screen for carriage of any *S aureus* on admission to hospital and begin decolonization before results being available. Decolonization can then be discontinued if screening results are negative.

Elective patients should be screened for *S aureus* carriage and if present, patients should be decolonized. Patients with MRSA should be strictly isolated in hospital and their surgery should be planned as the last case of the day.

6.6 Local delivery of antibiotics

The local delivery of antibiotics, at sites of open fractures and as part of the treatment of osteomyelitis, is well established. However, many factors influence how local antibiotics are applied and treatment strategies have not yet been standardized. High-quality evidence regarding the use of local antibiotics is lacking. Indications, techniques, dosages, types of antibiotics, elution properties, and pharmacokinetics have yet to be clearly defined.

One well-recognized vehicle for local antibiotic delivery is antibiotic-loaded cement. This can be formed into beads, molded to fit a bone defect, or used to coat a guide wire or intramedullary nail (antibiotic nail). Alternatively, commercially prepared antibiotic impregnated beads may be placed in and around the fracture site. In a case series [40] of 1,085 consecutive patients with open fractures, 240 received only systemic antibiotics and 845 received systemic antibiotics plus local tobramycin-impregnated polymethylmethacrylate beads. The additional therapy was associated with a significant reduction in acute infection rates in Gustilo type IIIB and C fractures and a reduction in local osteomyelitis among fracture types II and IIIB. Beads are typically removed within 1–6 weeks.

Newer delivery vehicles and techniques are being evaluated. Antibiotic-impregnated calcium sulfate is absorbable, thus eliminating the need for a return trip to the operating room solely for the purpose of bead removal. This approach has been used as a combined bone substitute and antibiotic delivery system for the repair of bony defects in open fractures [41]. A systematic review [42] of antimicrobial bone graft substitutes in osteomyelitis treatment included 15 studies with variable levels of evidence. Nonetheless, these studies showed promising results with relatively high success rates of eradication of infection and low complication rates.

7 Guidelines for prophylaxis

Based upon international guidelines and systematic reviews [9, 17, 18, 23–25, 29], the following guidelines are outlined (**Table 4.5-3**).

Local community standards, bacterial resistance, and local bacterial flora will alter the antibiotic prophylaxis that is required. This must be discussed with local microbiologists.

Indication	Centers with concerns regarding *Clostridium difficile* infection		Centers without concerns regarding *Clostridium difficile* infection or patients with mild penicillin allergy		Patients with β-lactam allergy	
	Preoperative antibiotic prophylaxis	Perioperative antibiotic prophylaxis	Preoperative antibiotic prophylaxis	Perioperative antibiotic prophylaxis	Preoperative antibiotic prophylaxis	Perioperative antibiotic prophylaxis
Clean operations involving hand, knee, or foot not involving implantation of foreign materials	None	None	None	None	None	None
Internal fixation or arthroplasty for closed fractures	None	Flucloxacillin plus gentamicin at induction (some centers continue flucloxacillin up to 24 hours)	None	First- or second-generation cephalosporin at induction. (Some centers continue cephalosporin up to 24 hours)	None	Teicoplanin plus gentamicin at induction
Open fractures: Gustilo types I and II fractures	Co-amoxiclav regularly dosed until first debridement	Co-amoxiclav plus gentamicin at induction. Continue Co-amoxiclav regularly until soft-tissue closure up to a maximum of 24 hours	First- or second-generation cephalosporin regularly dosed until first debridement	First- or second-generation cephalosporin at induction. Continue first- or second-generation cephalosporin regularly until soft-tissue closure up to a maximum of 24 hours	Clindamycin 600 mg regularly dosed until first debridement	Clindamycin plus gentamicin at induction. Continue clindamycin regularly until soft-tissue closure up to a maximum of 24 hours
Grossly contaminated open fractures (eg, farmyard injury or open pelvic injury) Gustilo type IIIA-C fractures	Piperacillin/tazobactam regularly dosed until first debridement	Piperacillin/tazobactam plus gentamicin at induction. Continue piperacillin/tazobactam regularly until soft-tissue closure or for a maximum of 72 hours, whichever is sooner	Meropenem regularly dosed until first debridement	Meropenem plus gentamicin at induction. Continue meropenem regularly until soft-tissue closure or for a maximum of 72 hours, whichever is sooner	Ciprofloxacin plus metronidazole plus teicoplanin regularly dosed until first debridement	Ciprofloxacin plus gentamicin at induction. Continue ciprofloxacin plus metronidazole plus teicoplanin regularly until soft-tissue closure or for a maximum of 72 hours, whichever is sooner

Table 4.5-3 Guidelines for preoperative and perioperative antibiotic prophylaxis. All perioperative antibiotic doses are to be administered intravenously and less than 60 minutes before incision and before tourniquet use. (Please note that this table is constructed with recommendations for use of prophylactic antibiotics in Great Britain. Local recommendations for antibiotic use must be considered.)

Classic references **Review references**

8 References

1. **Kaiser AB.** Antimicrobial prophylaxis in surgery. *N Engl J Med.* 1986 Oct;315(18):1129–1138.
2. **Horan TC, Andrus M, Dudeck MA.** CDC/NHSN surveillance definition of healthcare-associated infection and criteria for specific types of infections in the acute care setting. *Am J Infect Control.* 2008 Jun;36(5):309–332.
3. **Cruse PJ, Foord R.** The epidemiology of wound infection. A 10 year prospective study of 62,939 wounds. *Surg Clin North Am.* 1980 Feb;60(1):27–40.
4. **Haas DW, Kaiser AB.** Antimicrobial prophylaxis of infections associated with foreign bodies. In: Waldvogel FA, Bisno AL, eds. *Infections Associated With Indwelling Medical Devices.* 3rd ed. Washington DC: American Society for Microbiology; 2000:395–406.
5. **Elek SD, Conen PE.** The virulence of Staphylococcus pyogenes for man: a study of the problem of wound infection. *Br J Exp Pathol.* 1957 Dec;38(6):573–586.
6. **Zimmerli W, Lew PD, Waldvogel FA.** Pathogenesis of foreign body infection. Evidence for a local granulocyte defect. *J Clin Invest.* 1984 Apr;73(4):1191–1200.
7. **Mangram AJ, Horan TC, Pearson ML, et al.** Guideline for Prevention of Surgical Site Infection, 1999. Centers for Disease Control and Prevention (CDC) Hospital Infection Control Practices Advisory Committee. *Am J Infect Cont.*1999 Apr;27(2):97–132.
8. **World Health Organization.** Global Guidelines for the Prevention of Surgical Site Infection. Available at: http://apps.who.int/iris/bitstream/10665/250680/1/9789241549882-eng.pdf?ua=1. Accessed April 24, 2017.
9. **Bratzler DW, Dellinger EP, Olsen KM, et al.** Clinical practice guidelines for antimicrobial prophylaxis in surgery. *Am J Health Syst Pharm.* 2013 Feb 1;70(3):195–283.
10. **Bodoky A, Neff U, Heberer M, et al.** Antibiotic prophylaxis with two doses of cephalosporin in patients managed with internal fixation for a fracture of the hip. *J Bone Joint Surg Am.* 1993 Jan;75(1):61–65.

11. **Gustilo RB, Merkow RL, Templeman D.** The management of open fractures. *J Bone Joint Surg Am.* 1990 Feb;72(2):299–304.
12. **Greene C, McDevitt D, Francois P, et al.** Adhesion properties of mutants of Staphylococcus aureus defective in fibronectin-binding proteins and studies on the expression of fnb genes. *Mol Microbiol.* 1995 Sep;17(6):1143–1152.
13. **Stefánsdóttir A, Johansson D, Knutson K, et al.** Microbiology of the infected knee arthroplasty: report from the Swedish Knee Arthroplasty Register on 426 surgically revised cases. *Scand J Infect Dis.* 2009;41(11-12):831–840.
14. **Zimmerli W, Trampuz A, Ochsner PE.** Prosthetic-joint infections. *N Engl J Med.* 2004 Oct;351(16):1645–1654.
15. **Boxma H, Broekhuizen T, Patka P, et al.** Randomised controlled trial of single-dose antibiotic prophylaxis in surgical treatment of closed fractures: the Dutch Trauma Trial. *Lancet.* 1996 Apr 27;347(9009):1133–1137.
16. **Hospenthal DR, Murray CK, Andersen RC, et al.** Guidelines for the prevention of infections associated with combat-related injuries: 2011 update. *J Trauma.* 2011 Aug;71(2 Suppl 2):S210–S234.
17. **Scottish Intercollegiate Guidelines Network (SIGN).** Antibiotic prophylaxis in surgery Edinburgh: SIGN; 2008. *(SIGN publication no.*104). [July 2008]. Available at: http://www.sign.ac.uk. Accessed July 5, 2016.
18. **Tablan OC, Tenover FC, Martone WJ, et al.** Recommendations for preventing the spread of vancomycin resistance. Recommendations of the Hospital Infection Control Practices Advisory Committee (HICPAC). *MMWR Recomm Rep.* 1995 Sep 22;44(RR-12):1–13.
19. **Vardakas KZ, Soteriades ES, Chrysanthopoulou SA, et al.** Perioperative anti-infective prophylaxis with teicoplanin compared to cephalosporins in orthopedic and vascular surgery involving prosthetic material K. *Clin Microbiol Infect.* 2005 Oct;11(10):775–777.
20. **Vasenius J, Tulikoura I, Vainionpää S, et al.** Clindamycin versus cloxacillin in the treatment of 240 open fractures. A randomized prospective study. *Ann Chir Gynaecol.* 1998;87(3):224–228.
21. **Patzakis MJ, Bains RS, Lee J, et al.** Prospective, randomized, double-blind study comparing single-agent antibiotic therapy, ciprofloxacin, to combination antibiotic therapy in open fracture wounds. *J Orthop Trauma.* 2000 Nov;14(8):529–533.
22. **Huddleston PM, Steckelberg JM, Hanssen AD et al.** Ciprofloxacin inhibition of experimental fracture healing. *J Bone Joint Surg Am.* 2000 Feb;82(2):161–173.
23. **Hoff WS, Bonadies JA, Cachecho R, et al.** East Practice Management Guidelines Work Group: update to practice management guidelines for prophylactic antibiotic use in open fractures. *J Trauma.* 2011 Mar;70(3):751–754.
24. **Luchette FA, Bone LB, Born CT, et al.** Eastern Association for the Surgery of Trauma (EAST) working group. Practice management guidelines for prophylactic antibiotic use in open fractures. Available at: http://www.east.org/tpg.html. Accessed July 5, 2016.
25. **Gosselin RA, Roberts I, Gillespie WJ** (2004) Antibiotics for preventing infection in open limb fractures. *Cochrane Database Syst Rev.* 2004;(1):CD003764.
26. **Burke JF.**) The effective period of preventive antibiotic action in experimental incisions and dermal lesions. *Surgery.* 1961 Jul;50:161–168.
27. **Classen DC, Evans RS, Pestotnik SL, et al.** The timing of prophylactic administration of antibiotics and the risk of surgical-wound infection. *N Engl J Med.* 1992 Jan 30;326(5):281–286.
28. **Oishi CS, Carrion WV, Hoaglund FT.** Use of parenteral prophylactic antibiotics in clean orthopedic surgery. A review of the literature *Clin Orthop Relat Res.* 1993 Nov;(296):249–255.
29. **Gillespie WJ, Walenkamp GH.** Antibiotic prophylaxis for surgery for proximal femoral and other closed long bone fractures. *Cochrane Database Syst Rev.* 2010 Mar 17;(3):CD000244.
30. **Patzakis MJ, Wilkins J.** Factors influencing infection rate in open fracture wounds. *Clin Orthop Relat Res.* 1989 Jun;(243):36–40.
31. **Dellinger EP, Caplan ES, Weaver LD, et al.** Duration of preventive antibiotic administration for open extremity fractures. *Arch Surg.* 1988 Mar;123(3):333–339.
32. **Velmahos GC, Toutouzas KG, Sarkisyan G, et al.** Severe trauma is not an excuse for prolonged antibiotic prophylaxis. *Arch Surg.* 2002 May;137(5):537–541; discussion 541–542.
33. **Razonable RR, Osmon DR, Steckelberg JM.** Linezolid therapy for orthopedic infections. *Mayo Clin Proc.* 2004 Sep;79(9):1137–1144.
34. **Vernaz N, Hill K, Leggeat S, et al.** Temporal effects of antibiotic use and *Clostridium difficile infections. J Antimicrob Chemother.* 2009 Jun;63(6):1272–1275.
35. **Starks I, Ayub G, Walley G, et al.** Single-dose cefuroxime with gentamicin reduces Clostridium difficile-associated disease in hip-fracture patients. *J Hosp Infect.* 2008 Sep;70(1):21–26.
36. **Al-Obaydi W, Smith CD, Foguet P.** Changing prophylactic antibiotic protocol for reducing Clostridium difficile-associated diarrhoeal infections. *J Orthop Surg (Hong Kong).* 2010 Dec;18(3):320–323.
37. **Bell S, Davey P, Nathwani D, et al.** Risk of AKI with gentamicin as surgical prophylaxis. *J Am Soc Nephrol.* 2014 Nov;25(11):2625–2632.
38. **Dubrovskaya Y, Tejada R, Bosco J 3rd, et al.** Single high dose gentamicin for perioperative prophylaxis in orthopedic surgery: evaluation of nephrotoxicity. *SAGE Open Med.* 2015 Oct;3:2050312115612803
39 **Chen AF, Wessel CB, Rao N.** Staphylococcus aureus screening and decolonization in orthopaedic surgery and reduction of surgical site infections. *Clin Orthop Relat Res.* 2013 Jul;471(7):2383–2399.
40. **Ostermann PA, Seligson D, Henry SL.** Local antibiotic therapy for severe open fractures. A review of 1085 consecutive cases. *J Bone Joint Surg Br.* 1995 Jan;77(1):93–97.
41. **Helgeson MD, Potter BK, Tucker CJ, et al.** Antibiotic-impregnated calcium sulfate use in combat-related open fractures. *Orthopedics.* 2009 May;32(5):323.
42. **van Vugt TA, Geurts J,Arts JJ.** Clinical application of antimicrobial bone graft substitute in osteomyelitis treatment: a systematic review of different bone graft substitutes available in clinical treatment of osteomyelitis. *Biomed Res Int.* 2016;6984656.

9 Acknowledgments

We thank Werner Zimmerli for his contribution to the second edition of the *AO Principles of Fracture Management.*

4.6 Thromboembolic prophylaxis

Hans J Kreder

1 Introduction

Factors that predispose to venous thrombosis were originally described by Virchow [1] in 1856 and include:

- Stasis
- Vascular injury
- Hypercoagulability

Patients undergoing orthopedic trauma surgery are at high risk for venous thromboembolism (VTE) [2]. The risk of VTE depends on multiple factors [3–5] including increasing age, obesity, medical conditions, underlying genetic factors, fracture location, type and duration of surgery, and duration of patient immobility.

Without thromboembolism prophylaxis, VTE occurs in 40–80% of patients hospitalized with major traumatic injuries [2]. More rapid patient mobilization, improved surgical and anesthetic techniques, along with thromboembolic prophylaxis have significantly reduced the risk of VTE [5–7].

Despite the routine use of prophylaxis, a significant number of patients still experience thrombotic events that can result in death or short-term and long-term morbidity due to:

- Deep vein thrombosis (DVT)
- Pulmonary embolism (PE)
- Postthrombotic syndrome (PTS)
- Recurrent VTE

2 Clinically important outcomes

2.1 Deep vein thrombosis

Venous thrombosis is thought to initiate at or shortly after traumatic injury. Venous thromboembolism most often occurs as DVT in the lower limbs, although it can occur in any vein of the body. Thrombosis isolated to the calf veins may remain asymptomatic with little risk of clot embolization but without prophylaxis these clots can extend into the popliteal veins or above in 15–25% of patients [8]. Deep vein thrombosis above the popliteal veins is clinically important because more than 50% are associated with PE [1, 2].

2.2 Pulmonary embolism

Pulmonary embolism involves obstruction of a pulmonary artery by a dislodged DVT that has traveled through the right ventricle, although fatal PE has been found without apparent DVT on postmortem examinations. Pulmonary embolism is a serious and potentially life-threatening complication that is associated with a mortality risk of approximately 10% [8].

2.3 Recurrent deep vein thrombosis and postthrombotic syndrome

Inadequately treated VTE can lead to recurrent DVT with the highest risk during the first year, although the risk persists for several years after acute DVT [8]. Risk factors for recurrent DVT include proximal location of prior DVT, obesity, old age, malignancy, and male gender [9]. Thrombophilia may also play a role [9, 10].

Postthrombotic syndrome is the most common long-term complication of VTE with an incidence of 20–50% after proximal DVT, with severe manifestations that have a profound impact on patient quality of life in 5–10% of cases [10, 11]. It is believed to be caused by persistent venous obstruction or valvular damage resulting in venous hypertension. Inflammation and vein wall fibrosis after DVT are involved in the development of PTS, but the pathophysiology is incompletely understood. Symptoms and signs of PTS vary from minor leg swelling to intractable pain, chronic edema and skin changes (lipodermatosclerosis), discoloration, and leg ulceration.

3 Diagnosis

3.1 Deep vein thrombosis

A clinical diagnosis of DVT cannot be relied upon because most orthopedic trauma patients have signs and symptoms consistent with DVT, such as leg swelling and pain. The risk of DVT is highest in the first 3 months after trauma and then returns to the baseline population risk between 12 and 15 months [12].

Routine screening of trauma patients for the presence of DVT cannot be supported based on the available evidence [13]. However, venous duplex ultrasonography is highly accurate for the detection of proximal DVT in symptomatic patients. Other imaging modalities, such as magnetic resonance venography and contrast-enhanced computed tomography (CT) venography are being explored but continue to have a high false-positive rate [13].

D-dimer is a product of fibrin degradation and levels are typically high in patients with VTE but are also elevated in other conditions. Thus elevated D-dimer levels are not specific for the presence of VTE, but a negative D-dimer test is highly sensitive for ruling out VTE, depending on the type of assay performed. In patients with a suspicion of DVT, a negative D-dimer test performed using a sensitive assay can effectively rule out the presence of clinically significant VTE that would require treatment.

3.2 Pulmonary embolism

The diagnosis of PE can be challenging in trauma patients with chest wall injuries, lung contusions, fat embolism, pneumonia, and systemic inflammatory response syndrome [14].

Routine screening for PE is not recommended for trauma patients receiving prophylaxis [14, 15]). For patients with a suspected PE, a duplex CT pulmonary angiography is definitive, but there are significant associated costs and potential morbidity [5].

3.3 Postthrombotic syndrome

Postthrombotic syndrome is primarily a clinical diagnosis in someone with a previous DVT [11]. One should wait at least 3–6 months following an acute DVT episode before considering the diagnosis of PTS [11]. A number of clinical scoring systems exist and can be used for making the diagnosis and for grading severity. The Villalta-Prandoni scale, Ginsberg measure, and Brandjes scale [11] are specific to PTS.

Risk factors for the development of PTS include [11]:

- Body mass index/obesity
- Older age
- Smoking
- Extent of original DVT (femoral and iliac versus popliteal)
- Recurrent DVT [10]
- Underlying thrombophilia [10]
- Residual thrombosis after DVT treatment and subtherapeutic treatment

4 Risk factors for deep vein thrombosis and pulmonary embolism

4.1 Patient risk factors

Numerous potential patient risk factors have been proposed over many years, with conflicting evidence for some of them [7, 16, 17]. A recent attempt to develop a validated risk model to predict VTE within 90 days of surgery identified seven risk factors, including the following patient-related factors:

- Increasing age
- Obesity
- Male gender
- Current cancer
- History of VTE
- Family history of VTE

Others have noted a consistent increase in risk for women using oral contraceptive medication, with variable risk depending on the specific formulation used. It is also accepted that various genetic factors increase the risk of VTE [18]. The inherited thrombophilia risk factors have been summarized by Westrichin in a recent instructional course lecture (**Table 4.6-1**).

Testing for these factors is not routinely required but should be considered in anyone with a strong family history or a history of VTE, especially if the episode occurred in people younger than 40 years [18].

4.2 Injury and surgery risk factors

Patients with polytrauma, hip fractures, spinal cord injury, pelvic or acetabular fractures, and lower extremity injuries are at high risk of VTE [2, 5, 13]. The risk may be higher for high thoracic spinal cord injuries versus other spinal cord injury levels. Traumatic brain injury in the context of polytrauma does not appear to increase the risk of VTE.

Longer duration of surgery is associated with increased VTE risk for all surgical specialty procedures, including orthopedic surgery [5]. Prolonged cardiothoracic, neurological, and gynecological operations are associated with an especially high risk.

Prolonged immobility, including prolonged extrication time after injury [19] increases the risk of VTE, even in the absence of injury.

4.3 Clinical scoring systems for VTE risk

Many scoring systems have been developed to try and to predict the risk of VTE and thereby to target therapy [4, 5]. However, the sensitivity and specificity of the scores are limited, and a patient categorized as low risk can still develop VTE, and many who are considered at high risk never develop symptomatic or clinically important VTE. Scoring systems are sometimes used in conjunction with other tests, such as D-dimer assay, and may help to guide therapy.

5 Basics of thromboembolic prophylaxis

5.1 Rationale for thromboembolism prophylaxis

Given that scoring systems are not accurate enough to identify individual patients who will develop symptomatic or clinically important VTE, routine thromboembolism prophylaxis administered to all orthopedic trauma patients (or any other group at high risk of VTE) represents the most effective strategy to reduce symptomatic and fatal thromboembolic events [5–7, 13]. Without prophylaxis, asymptomatic VTE is common in trauma patients affecting at least half of multiple-injured patients. While most thrombi remain asymptomatic and resolve spontaneously, some become symptomatic as DVT or PE, and to date it is not possible to predict which individual patient will develop clinically important VTE. Because therapy cannot be readily targeted on an individual patient basis, prophylaxis is recommended for all high-risk patient groups [7]. Surveillance screening for VTE of patients receiving prophylaxis is not recommended as it does not affect the risk of fatal and nonfatal PE, and is not cost-effective [13, 20].

Condition	Healthy, %	Venous thromboembolism, %	Relative risk of thrombosis, %
Activated protein C resistance/factor V Leiden mutation	5	21	3–7
Antithrombin deficiency	0.02–0.17	1	15–40
Protein C deficiency	0.3	3	5–12
Protein S deficiency	0.7	2	4–10
Prothrombin (FII) G20210A mutation	2	6	2–3
Factor VIII excess	11	25	6
Hyperhomocysteinemia > 18.5 µmol/L	5–10	10–25	3–4

Table 4.6-1 Inherited thrombophilia risk factors. (Adapted from Westrichin et al [18]).

5.2 Methods of prophylaxis

Prophylaxis can involve mechanical or chemical means to prevent clot formation in the venous system. An alternative is to try and to prevent embolization of a clot to the lungs by mechanical filters in the vena cava.

The important issues to consider in VTE prophylaxis include:

- Defining the population at risk of VTE that should receive routine prophylaxis
- Considering the potential risk of bleeding complications associated with specific injuries or the required treatment for the injuries
- Patient-specific factors, such as thrombophilia or use of anticoagulants
- What type of prophylaxis to use and for how long

5.2.1 Mechanical prophylaxis

Mechanical device options include pumps applied to the foot, calf, or up onto the thigh [18]. Standard, sequential, or rapid inflation compression techniques are available. Prophylaxis with sequential compression pumps reduced the risk of DVT in trauma patients versus no prophylaxis, with a more marked effect when chemical and mechanical prophylaxis were used together. However, neither reduced the risk of PE nor death.

There is little evidence to support the use of compression stockings in patients with hip fractures, or orthopedic patients undergoing surgery in general. Compression stockings have not been evaluated properly in a trauma population. Elastic compression stockings did not prevent PTS after proximal DVT [21].

Mechanical prophylaxis with sequential compression pumps is recommended in numerous guidelines for high-risk patients where chemical prophylaxis is contraindicated or in combination with chemical prophylaxis [6, 7, 13].

5.2.2 Chemical prophylaxis

Drugs can act at various steps in the coagulation pathway to prevent the formation and propagation of thrombus. Vitamin K antagonists represent the most common group of anticoagulant drugs that indirectly inhibit clot formation by binding with antithrombin III to cause inhibition of factor Xa and/or factor IIa. Newer nonvitamin K antagonist drugs that have a direct antithrombin action have recently been introduced with the potential benefit of decreasing the risk of bleeding.

Low-molecular-weight heparin (LMWH) acts primarily as a factor Xa inhibitor by binding with antithrombin III. It has become the most widely recommended prophylactic drug for orthopedic trauma patients [5, 6, 13, 22]. For trauma patients undergoing multiple procedures at intervals over their hospital stay, the short half-life of LMWH allows VTE prophylaxis to be maintained by administering the drug in the evenings, even if surgery is required the following day.

The use of warfarin in trauma patients is potentially problematic due to the delayed onset of anticoagulant effect, the need for blood test monitoring, and a longer half-life that demands interruption for patients undergoing multiple procedures on different days, leading to subtherapeutic prophylaxis. Warfarin is an option for prophylaxis in patients with isolated orthopedic injuries and for VTE treatment [23].

Antiplatelet agents, such as aspirin and clopidogrel, have not been studied in trauma patients, or in patients with orthopedic injury. While some guidelines include aspirin as a possible prophylactic agent for hip and knee replacement surgery, and hip fractures, it is not the preferred choice [7].

5.2.3 Inferior vena cava filter as primary thromboprophylaxis

Inferior venal caval filters (IVCF) have been recommended for PE prevention in trauma patients because VTE risk is high, insertion of a filter is relatively low risk, chemical VTE prophylaxis is sometimes delayed due to bleeding concerns, and retrievable IVCF have been developed to reduce the long-term risks associated with permanent filters. However, there is a lack of good quality evidence supporting the benefits of IVCF in terms of PE or mortality [7], and the cost associated with IVCF is high [13].

Inferior venal caval filters do have a role in prophylaxis for patients who require major pelvic or acetabular surgery and who have evidence of an existing proximal DVT because the clot might embolize intraoperatively [14]. After surgery these patients require full anticoagulation as soon as it is safe to do so to treat the proximal DVT. The filter should be removed (in days to weeks) once the patient has been safely anticoagulated.

Inferior venal caval filters in patients who can be safely anticoagulated does not appear to be beneficial.

6 Thromboembolism prophylaxis in specific fracture surgery

6.1 Methodology

Newer recommendations emphasize clinically important events, such as symptomatic proximal DVT and PE, as opposed to asymptomatic DVT demonstrated on imaging studies [20, 24]. Venous thromboembolism prevention must be balanced against the risk of complications, such as bleeding, and this is factored into some of the recommendations [7, 20].

Determining the duration of thromboembolism prophylaxis is challenging. There are some randomized studies to guide duration of thromboembolism prophylaxis but in many cases evidence is lacking (**Table 4.6-2**) [7]. A novel approach to assessing when therapy might be safely stopped involves the use of biomarkers, such as D-dimer, to determine when the risk of clotting has returned to baseline and prophylaxis is no longer required but there has been little research on biomarkers in orthopedic trauma patients [18].

6.2 Hip fractures

Patients with hip fractures are at high risk of VTE with a 0.4–7.5% rate of fatal PE. Low-molecular-weight heparin has been effective in reducing the risk of these events, with some evidence that fondaparinux, a new ultra LMWH that indirectly inhibits factor Xa, may be more effective than LMWH [25].

6.3 Polytrauma

Better studies are needed to allow strong evidence-based recommendations to be made for thromboembolism prophylaxis in multiple-injured patients [5, 6, 13]. Current recommendations are for chemical prophylaxis with LMWH to be initiated within 24 hours if there are no contraindications, such as excessive bleeding risk. Thromboprophylaxis appears to be safe in patients with traumatic brain injury and solid organ injuries, but a discussion with the relevant specialists may be helpful in deciding on thromboembolism prophylaxis in these cases [5, 13]. The risk of VTE in children after trauma approaches that of adults at the age of 16 years [3].

6.4 Spinal injuries

Spinal injuries are associated with a high risk of VTE, but good quality studies are lacking to guide evidence-based treatment. The risk of VTE is highest during the first 3 months after injury [12] and is higher with increased age, paraplegia, and prior VTE. The level of spinal cord injury appears to be important with particularly high rates of VTE associated with thoracic level injuries.

6.5 Fractures of the pelvis and acetabulum

The risk of VTE in patients with pelvic and acetabular fractures is particularly high without thromboembolic prophylaxis, with many of the thrombi located in the proximal deep veins of the lower extremity. Prophylaxis with LMWH should be started within 24 hours of injury provided there is no active hemorrhage but not within 12 hours of major surgery [13]. There is some debate regarding the usefulness of adding a pneumatic compression device to routine chemoprophylaxis, although there is some support in the literature for combined therapy [7, 13].

Condition	Prophylaxis	Duration
Hip fracture	LMWH, fondaparinux, LDUH, adjusted dose VKA, aspirin started within 24 hours of injury [7]	10–14 days, although there is some evidence that extended prophylaxis up to 20 days reduces VTE even further
Polytrauma	LMWH started within 24 hours, may be combined with PCD or PCD may be used alone if LMWH is contraindicated. Vena cava filter only if proven proximal DVT and LMWH contraindicated	At least 1 month recommended, but some centers discontinue prophylaxis upon discharge home [14]
Spinal cord injury	Same as for polytrauma	Same as for polytrauma. Extended prophylaxis should be considered up to 3 months in immobile patients
Pelvic/acetabular fracture	Same as for polytrauma	Same as for polytrauma
Complex lower extremity fractures above the knee	Same as for polytrauma	Same as for polytrauma
Isolated lower extremity fracture below the knee	No routine prophylaxis recommended unless important risk factors present (see above)	Not applicable

Table 4.6-2 Summary of prophylaxis recommendations for specific fractures and polytrauma.
Abbreviations: LMWH, low-molecular-weight heparin; LDUH, low-dose unfractionated herparin; VKA, vitamin K antagonist; VTE, venous thromboembolism; PCD, pneumatic compression devices; and DVT, deep vein thrombosis.

Patients who are transferred to a trauma center from a peripheral institution for definitive pelvic surgery may already have a preoperative VTE, especially if there was no standardized thromboembolic prophylaxis regimen used by the first hospital. Under these circumstances, duplex ultrasound screening should be considered at the tertiary care hospital to rule out proximal DVT before surgery. This represents an exception to the rule that routine screening for VTE is not recommended in patients receiving thromboembolic prophylaxis [7, 13].

In patients with a demonstrated proximal DVT, or in those with exceedingly high-bleeding risk, consideration should be given to the use of a vena cava filter before major surgery. The filter should not be a substitute for chemoprophylaxis if there is no contraindication to the latter [7].

6.6 Isolated lower extremity fractures

Hip fractures, femoral fractures, and complex lower extremity fractures above the knee that require surgery are associated with a relatively high risk of VTE and prophylaxis with LMWH is recommended for multiple-injured patients [7].

In lower leg injuries below the knee, clinically important, symptomatic VTE is rare with an incidence of less than 2% without prophylaxis, and with no significant change in risk when LMWH prophylaxis was used [24]. Most published guidelines recommend against routine prophylaxis for isolated injuries below the knee in patients who are otherwise ambulatory, whether or not cast immobilization for the limb is applied or surgery is performed [7, 24]. There may be increased risk for women taking oral contraceptive medication and those with preexisting peripheral arterial disease, high body mass index, cancer, and nonsteroidal antiinflammatory drugs use in the context of fractures distal to the knee [26].

7 Conclusion

Venous thromboembolism incidence is high in multiple-injured trauma patients and for those with musculoskeletal injuries to the spine, pelvis, and femur. Because there is no test accurate enough to target specific patients within these high-risk groups, thromboembolism prophylaxis is recommended for all patients. Generally, patients with isolated fractures below the knee do not need chemical prophylaxis, but instead early fracture fixation and mobilization.

Classic references | Review references

8 References

1. **Dalen JE.** Pulmonary embolism: what have we learned since Virchow?: treatment and prevention. *Chest.* 2000 Nov;122(5):1801–1817.
2. **Geerts WH, Code KI, Jay RM, et al.** A prospective study of venous thromboembolism after major trauma. *N Engl J Med.* 1994 Dec 15;331(24):1601–1606.
3. **Kim JY, Khavanin N, Rambachan A.** Surgical duration and risk of venous thromboembolism. *JAMA Surg.* 2015 Feb;150(2):110–117.
4. **Testroote M, Stigter W, de Visser DC, et al.**Low molecular weight heparin for prevention of venous thromboembolism in patients with lower-leg immobilization. *Cochrane Database Syst Rev.* 2008;(4):CD006681.
5. **Scolaro JA, Taylor RM, Wigner NA.** Venous thromboembolism in orthopaedic trauma. *J Am Acad Orthop Surg.* 2015 Jan;23(1):1–6.
6. **Barrera LM, Perel P, Ker K, et al.** Thromboprophylaxis for trauma patients. *Cochrane Database Syst Rev. Engl.* 2013;3:CD008303.
7. **Falck-Ytter Y, Francis CW, Johanson NA, et al.** Prevention of VTE in orthopedic surgery patients: Antithrombotic Therapy and Prevention of Thrombosis. 9th ed. American College of Chest Physicians Evidence-Based Clinical Practice Guidelines. *Chest.* 2012;141(2 Suppl):e278S–325S.
8. **Morris TA.** Natural history of venous thromboembolism. *Crit Care Clin.* 2011 Oct;27(4):869–884.
9. **Prandoni P, Barbar S, Milan M, et al.** The risk of recurrent thromboembolic disorders in patients with unprovoked venous thromboembolism: new scenarios and opportunities. *Eur J Intern Med.* 2014 Jan;25(1):25–30.
10. **Kreidy R.** Contribution of recurrent venous thrombosis and inherited thrombophilia to the pathogenesis of postthrombotic syndrome. *Clin Appl Thromb Hemost.* 2015 Jan;21(1):87–90.
11. **Kahn SR, Comerota AJ, Cushman M, et al.** The postthrombotic syndrome: evidence-based prevention, diagnosis, and treatment strategies: a scientific statement from the American Heart Association. *Circulation.* 2014 Oct 28;130(18):1636–1661.
12. **Godat LN, Kobayashi L, Chang DC, et al.** Can we ever stop worrying about venous thromboembolism after trauma? *J Trauma Acute Care Surg.* 2015 Mar;78(3):475–480; discussion 480–481.
13. **Sagi HC, Ahn J, Ciesla D, et al.** Venous thromboembolism prophylaxis in orthopaedic trauma patients. *J Orthop Trauma.* 2015 Oct;29(10):e355–e362.
14. **Geerts WH.** Venous thromboembolism in pelvic trauma. In: Tile M, Helfet D, Kellam J, Vrahas M, eds. *Fractures of the Pelvis and Acetabulum: Principles and Methods of Management.* 4th ed. Stuttgart: Thieme; 2015:377–399.
15. **Bates SM, Jaeschke R, Stevens SM, et al.** Diagnosis of DVT: Antithrombotic Therapy and Prevention of Thrombosis, 9th ed: American College of Chest Physicians Evidence-Based Clinical Practice Guidelines. *Chest.* 2012 Feb;141(2 Suppl):e351S–418S.
16. **Kahn SR, Lim W, Dunn AS, et al.** Prevention of VTE in nonsurgical patients: Antithrombotic Therapy and Prevention of Thrombosis, 9th ed: American College of Chest Physicians Evidence-Based Clinical Practice Guidelines. *Chest.* 2012 Feb;141(2 Suppl):e195S–226S.
17. **Gould MK, Garcia DA, Wren SM, et al.** Prevention of VTE in nonorthopedic surgical patients: Antithrombotic Therapy and Prevention of Thrombosis, 9th ed: American College of Chest Physicians Evidence-Based Clinical Practice Guidelines. *Chest.* 2012 Feb;141(2 Suppl):e227S–277S.
18. **Westrich GH, Dlott JS, Cushner FD, et al.** Prophylaxis for thromboembolic disease and evaluation for thrombophilia. *Instr Course Lect.* 2014;63:409–419.
19. **Rogers FB, Hammaker SJ, Miller JA, et al.** Does prehospital prolonged extrication (entrapment) place trauma patients at higher risk for venous thromboembolism? *Am J Surg.* 2011 Oct;202(4):382–386.
20. **Guyatt GH, Eikelboom JW, Gould MK, et al.** Approach to outcome measurement in the prevention of thrombosis in surgical and medical patients: Antithrombotic Therapy and Prevention of Thrombosis, 9th ed: American College of Chest Physicians Evidence-Based Clinical Practice Guidelines. *Chest.* 2012 Feb;141(2 Suppl):e185S–194S.
21. **Kahn SR, Shapiro S, Wells PS, et al.** Compression stockings to prevent post-thrombotic syndrome: a randomised placebo-controlled trial. *Lancet.* 2014 Mar;383(9920):880–888.
22. **Fowler RA, Mittmann N, Geerts W, et al.** Cost-effectiveness of dalteparin vs unfractionated heparin for the prevention of venous thromboembolism in critically ill patients. *JAMA.* 2014 Nov 26;312(20):2135–2145.
23. **Ageno W, Gallus AS, Wittkowsky A, et al.** Oral anticoagulant therapy: Antithrombotic Therapy and Prevention of Thrombosis, 9th ed: American College of Chest Physicians Evidence-Based Clinical Practice Guidelines. *Chest.* 2012 Feb;141(2 Suppl):e44S–88S.
24. **Selby R, Geerts WH, Kreder HJ, et al.** A double-blind, randomized controlled trial of the prevention of clinically important venous thromboembolism after isolated lower leg fractures. *J Orthop Trauma.* 2015 May;29(5):224–230.
25. **Eriksson BI, Bauer KA, Lassen MR, et al.** Fondaparinux compared with enoxaparin for the prevention of venous thromboembolism after hip-fracture surgery. *N Engl J Med.* 2001 Nov 1;345(18):1298–1304.
26. **Wahlsten LR, Eckardt H, Lyngbæk S, et al.** Symptomatic venous thromboembolism following fractures distal to the knee: a nationwide Danish cohort study. *J Bone Joint Surg Am.* 2015 Mar;97(6):470–477.

9 Acknowledgment

We thank David Helfet and Beate Hanson for their contributions to this chapter in the second edition of the *AO Principles of Fracture Management.*

4.7 Postoperative management: general considerations

Liu Fan, John Arraf

1 Introduction

The overall care plan for a trauma patient should cover the preoperative management, the surgical procedures, and postoperative care (**Table 4.7-1**). All too often, it is following surgical intervention that vigilance is relaxed and complications may occur. These, at best, deprive the patient of the full benefit of the procedure and, at worst, may seriously reduce a patient's quality of life.

Postoperative management is not limited to the time spent in hospital but must be continued at home and later at work and at leisure. To achieve this, three postoperative phases are recognized:

- In the first phase, immediately after surgery, emphasis is on pain control, mobilization, prevention, and early recognition of complications.
- In the second phase, after hospitalization, attention is centered upon integration into the social environment and mobilization.
- The final phase concludes treatment and returns the patient to his/her preoperative capabilities including work, education, and leisure activities.

2 First phase—immediate postoperative phase

2.1 Postoperative pain management

The International Association for the Study of Pain (IASP) defines pain as "an unpleasant sensory and emotional experience associated with actual or potential tissue damage, or described in terms of such damage" [1]. In addition to being an unpleasant experience for the patient, poorly controlled pain may have deleterious physiological consequences for the patient leading to increased morbidity [2].

With adequate analgesia the orthopedic patient will be able to mobilize and perform physical therapy better and recover more quickly.

The simplest and most common methods used to quantify pain are scales that measure the intensity of the pain. Among the most commonly used is the Visual Analog Scale (VAS), which consists of a straight line with the words "no pain at all" on one end and "worst pain imaginable" on the other (**Fig 4.7-1**). Patients quantify the severity of their pain by placing a mark along the scale [3]. Measurement can be improved by using a standard 10 cm line and then quantifying the pain from 0 to 10 for later comparison. By quantifying pain on VAS, pain can be classified as mild (VAS 1–4), moderate (VAS 4–7), or severe (VAS 7–10). However, surgeons should be aware that pain scores can be affected by anxiety, with more anxious patients reporting higher pain scores [4] and a significant correlation between high anxiety and high reported pain. This emphasizes the close interaction of psychosocial factors and pain. The World Health Organization's Analgesic Ladder can be adapted to suit the needs of the orthopedic patient (**Table 4.7-2**).

2.1.1 Analgesics

Acetaminophen has no antiinflammatory effect; it is an effective analgesic and antipyretic. Doses are 10–15 mg/kg orally every 4–6 hours. For adults, these may be doses of 500–1,000 mg (depending on availability) every 4–6 hours. Rectal suppositories may be given in doses of 15–20 mg/kg every 4 hours and it is now available for intravenous administration. The total daily dose of acetaminophen for adults from all sources must not exceed 4 g to prevent liver toxicity.

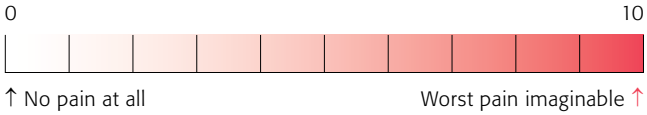

Fig 4.7-1 Numerical Visual Analog Scale.

Fracture type and fixation	Postoperative positioning	Additional limb support	Exercise, weight bearing	Comment
Humerus, proximal: "dynamic", unstable splinting by K-wire	Orthopedic sling, Gilchrist's bandage, abduction frame, etc	Immobilization for 3 weeks	Pendulum exercises starting at once, active-assisted mobilization after week 2 Partial functional use: week 3–6 Full functional use: week 6–10	Note: associated injuries (eg, rotator cuff)
Humerus, proximal: "stable" fixation: PHILOS, PHN	Arm placed on a cushion, orthopedic sling	Orthopedic sling for 2 weeks	Active-assisted mobilization starting at once Partial functional use: week 3–6 Full functional use: week 6–10	More details in **Table 6.2.1-1** Shoulder rehabilitation protocol
Humerus, shaft: "stable" fixation: intramedullary nail, plate	Arm placed on a cushion, elevated position	Orthopedic sling for 1 week	Active-assisted mobilization starting at once Partial functional use and limited rotation: week 4–6 Full functional use: week 6–10	Mobilization of the shoulder and elbow
Humerus, distal: stable ORIF	Arm placed on a cushion, elevated position	Upper arm splint or sling	Active-assisted mobilization starting at once Partial functional use and limited rotation: week 4–6. Full functional use: week 6–10	Mobilization of the shoulder, no forced passive manipulation
Olecranon: tension band	Arm placed on a cushion, elevated position	None	Active-assisted mobilization starting at once Partial functional use and limited rotation: week 4–6 Full functional use: week 6–12	Mobilization of the shoulder
Radial head: stable ORIF	Arm placed on a cushion, elevated position	Sling, exceptionally removable splint	Limited rotation: week 0–4 Partial functional use: week 4–6 Full functional use: week 6–8	Note: associated ligament injuries, mobilization of the shoulder
Forearm, shaft: stable plate fixation	Arm placed on a cushion, elevated position	None or light splint	Active-assisted mobilization starting at once Partial functional use: week 4–6 Full functional use: week 6–10	Note: mobilization of hand, wrist, elbow, and shoulder, splint for associated neurological injuries
Radius, distal: "stable" fixation: plate	Elevated position	Positioning splint	Active-assisted mobilization starting at once Partial functional use: week 4–6 Full functional use: week 6–10	Mobilization of adjacent joints (including shoulder)
Radius, distal: "unstable" fixation: K-wire	Elevated position	Palmar splint or cast	Mobilization of adjacent joints	–
Radius, distal: external fixation	Elevated position	Sling	Active exercises for mobile fingers	Release of distraction after 3–4 weeks, mobilization of the elbow and shoulder
Femur, neck: screw fixation or DHS	Leg extended in slight abduction (cushion between legs)	None	Young patients (< 60 years of age): 30 kg week 0–4; 50 kg week 4–6, then full weight bearing Older patients: full weight bearing	If stable: full weight bearing, consider compliance of the patient and bone quality
Femur: intertrochanteric/ pertrochanteric: DHS/PFNA	Leg extended in slight abduction (cushion between legs)	None	Young patients (< 60 years of age): partial weight bearing (toe-touch): 15 kg week 0–4, 30 kg week 4–6, then full weight bearing when pain has dissipated Elderly patients (> 60 years of age): full weight bearing	With intramedullary implant, full weight bearing can start immediately
Femur: subtrochanteric: PFNA, AFN, DCS, angled blade plate	Leg extended	None	Partial weight bearing: 15 kg week 0–6, 30 kg week 4–10 Elderly patients (> 60 years of age): full weight bearing	
Femur, shaft: stable fixation with locked intramedullary nail	Leg extended	None	Partial weight bearing: 15 kg week 3–4 All femurs nailed are full weight bearing. If plated, full weight bearing with active hip and knee movements	Dynamization is rarely indicated

Table 4.7-1 Guidelines for postoperative treatment of specific adult fractures according to AO principles. The aim of operative fracture treatment is functional restitution and early pain-free active mobilization. Surgery followed by immobilization is a poor combination.
Abbreviations: AFN, antegrade femoral nail; DCS, damage-control surgery; DHS, dynamic hip screw; ORIF, open reduction and internal fixation; PFNA, proximal femoral nail antirotation; PHILOS, proximal humerus internal locked system; PHN, proximal humeral nail.

Fracture type and fixation	Postoperative positioning	Additional limb support	Exercise, weight bearing	Comment
Femur, shaft: stable plate fixation	90°–90° positioning or CPM Note: protect common fibular nerve	None	Partial weight bearing: 15 kg week 3–6, 30 kg week 6–8 Full weight bearing: after week 8 Knee should be exercised without restrictions	Consider compliance of the patient and fracture pattern/ MIPO
Femur, distal: LISS/DCS angled blade plate	90°–90° positioning, (CPM) Note: protect the fibular nerve	Knee brace in case of associated ligamental lesions	Partial weight bearing: 15 kg week 0–6, 30 kg week 6–10 Full weight bearing: week 10–12 Knee should be moved without restrictions	"Stable" situation: full weight bearing from week 6–8
Tibia, proximal: LCP/L-plate LISS plate	Elevated position, (CPM)	(Dorsal splint or knee brace in extension)	Partial weight bearing: 15 kg week 3–6, 30 kg week 6–10 Full weight bearing: week 10–14 After 2–3 weeks in full extension, splint should be removed and knee flexion is begun but extension must be emphasized	Avoid resting knee flexion to prevent loss of knee extension
Patella: tension band	Elevated position, (CPM)	–	Isometric quadriceps exercises at once Partial weight bearing on fully extended leg: 30 kg week 0–6 Full weight bearing: week 6–8	Active-assisted flexion of the knee starting at once (to a maximum of 90°)
Tibia, shaft: intramedullary nailing	Elevated position	None	Partial weight bearing: 15 kg week 0–2, 30 kg week 2–4 Full weight bearing: when comfortable	Prevention of pes equinus
Tibia, shaft: plate fixation LC-DCP, LCP absolute stability	Elevated position	None	Partial weight bearing: 15 kg week 0–6, 30 kg week 6–10 Full weight bearing: week 10–12	Prevention of pes equinus, watch for clinical and radiological signs of instability
Tibia, shaft: plate fixation LC-DCP, LCP Relative stability	Elevated position	None	Partial weight bearing: 15 kg week 0-6 followed by progressive weight bearing as healing dictates	Prevention of pes equinus, watch for clinical and radiological signs of instability
Tibia, distal: pilon: different pilon plates	Elevated position, CPM	Postoperative U-splint to prevent pes equinus	Partial weight bearing (toe-touch): 15 kg week 0–6, 30 kg week 6–12 Full weight bearing: week 12–14	Active-assisted mobilization at once
Malleoli	Elevated position, (CPM)	Postoperative U-splint Associated ligamental injuries: cast for 6 weeks	Immediate full weight bearing as tolerated unless contraindication such as diastasis, diabetes, alcohol abuse, or neuropathy	In case of a position screw, dorsal extension and full weight bearing should be restricted until screw removal (week 12–16)
Calcaneus	Elevated position	Removable splint to prevent pes equinus	Nonweight bearing for 6 weeks then partial weight bearing 6–10 weeks Full weight bearing: after week 10–16	Active-assisted mobilization at once of the ankle, subtalar joint, and toes Diabetics with neuropathy should be splinted and have restricted weight bearing for 8–12 weeks

Table 4.7-1 (**cont**) Guidelines for postoperative treatment of specific adult fractures according to AO principles. The aim of operative fracture treatment is functional restitution and early pain-free active mobilization. Surgery followed by immobilization is a poor combination.
Abbreviations: AFN, antegrade femoral nail; DCS, damage-control surgery; DHS, dynamic hip screw; ORIF, open reduction and internal fixation; PFNA, proximal femoral nail antirotation; PHILOS, proximal humerus internal locked system; PHN, proximal humeral nail.

Nonsteroidal antiinflammatory drugs (NSAIDs) given even as a single dose preoperatively can significantly decrease morphine requirements by up to 29% over 24 hours [5]. This translates into a lower incidence of opioid-induced adverse effects, such as pruritus, nausea and vomiting. Unlike opioids, which exert their effect predominantly on rest pain, NSAIDs have shown considerable efficacy in minimizing pain associated with movement, thereby facilitating postoperative physiotherapy and minimizing postoperative physiological impairment [6]. Reducing postoperative opioid requirements may also decrease the likelihood of sedation and opioid requirements may also decrease the likelihood of sedation and opioid-induced respiratory depression. In addition to single preoperative doses, NSAIDs may also be given at regular scheduled intervals as appropriate (**Table 4.7-3**).

Some of the more common adverse effects of NSAIDs include gastric bleeding and ulceration, bleeding from the operative site, nephrotoxicity, bronchospastic hypersensitivity reactions, and the suppression of heterotopic bone formation. Nonsteroidal antiinflammatory drugs should be used with care in geriatric patients and avoided in patients with impaired renal function.

Of special interest is the effect of NSAIDs on bone healing. Although there is evidence from animal studies that NSAIDs inhibit bone healing via their antiinflammatory effect [9], there is increasing evidence that their short-term use in humans does not affect fracture healing [10].

COX-2 inhibitors are well known for their analgesic efficacy. Their lower potential to induce gastrointestinal bleeding and minimal effect on platelet function make them seem an attractive choice in the elderly orthopedic patient. However, their propensity for harm in patients at risk for cardiovascular disease precludes their use in this population [11].

Mild pain	Acetaminophen*, acetylsalicylic acid, or other NSAIDs +/– coanalgesics†
Moderate pain	Weak opioid analgesics such as oxycodone, codeine, or tramadol with acetaminophen +/– NSAIDs +/– coanalgesics
Severe pain	Potent opioid analgesics such as morphine or hydromorphone +/– acetaminophen +/– NSAIDs +/– coanalgesics +/– regional anesthesia techniques‡

* Acetaminophen = paracetamol
† Coanalgesics include antidepressants, anticonvulsants
‡ Regional anesthesia techniques include epidural analgesia, plexus catheters or single injection nerve blocks

Table 4.7-2 World Health Organization Analgesic Ladder for pain in orthopedics.
Abbreviations: NSAID, nonsteroidal antiinflammatory drug.

Because of concerns about cardiovascular problems, many COX-2 inhibitors have been withdrawn.

Neuromodulating drugs, such as amitriptyline, gabapentin, and pregabalin have been explored for their coanalgesic effect in the setting of postoperative pain. Turan et al [12] found that in the setting of spine surgery, a single oral dose of 1,200 mg gabapentin preoperatively decreased not only early postoperative pain scores but also resulted in a large reduction in morphine requirements and a significant reduction in opioid-related adverse effects postoperatively. Anticonvulsant drugs exert their diverse pharmacological effects on both ascending and descending pain pathways through a variety of mechanisms, including sodium and calcium channel blocking [13]. The dose of gabapentin for chronic pain ranges from 900–1,800 mg/day. These drugs may also have a place in the management of phantom pain following amputation and in the setting of elective amputation may be started a few days before surgery.

N-methyl-D-aspartate antagonists receptor antagonists, such as ketamine, magnesium and dextromethorphan, potentiate opioid analgesia through their modulation of pain pathways. Their use results in decreased morphine consumption and significantly decreased postoperative pain [14].

Opioid analgesics are a cornerstone of treatment for moderate to severe postoperative pain. Opioids exert their analgesic effects in the central nervous system at the μ-, κ-, and δ-receptors. All pure opioid analgesics cause a dose-dependent sedation and respiratory depression that is similar at equianalgesic doses. This phenomenon is exacerbated by the concomitant use of benzodiazepines, sedating antiemetics, and antihistamines.

Drug	Adult dose	Pediatric dose
Ibuprofen	Oral: 200–400 mg every 4–6 h, max 3.2 g/d	Oral: 4–10 mg/kg every 6–8 h to max 40 mg/kg/d
Indomethacin	Oral, rectal: 25–50 mg/dose, 2–3 times daily, max 200 mg/d	Oral: 1–2 mg/kg/d in 2–4 separate doses, max 4 mg/kg/d
Acetylsalicylic acid (ASA)	Oral: 650–975 mg every 4–6 h, max 4 g/d	Oral: 10–15 mg/kg every 4–6 h, max 60–80 mg/d
Naproxen	Oral: 500 mg initial dose, then 250 mg every 6–8 h, max 1,250 mg/d	Oral: 5–7 mg/kg every 8–12 h max 1,000 mg/d
Diclofenac	Oral: 50 mg, 3 times daily, max 200 mg/d	Oral: 2–3 mg/kg/d in 2–4 separate doses
Ketorolac	Intravenous: 10–30 mg every 6 h, max 120 mg/d Oral: 10 mg every 6 h, max 40 mg/d	Intravenous: 0.5 mg/kg every 6 h

Table 4.7-3 Nonsteroidal antiinflammatory drugs dosing [7, 8].

Codeine is a weak opioid frequently used in conjunction with acetaminophen for the treatment of mild to moderate pain. Codeine is a prodrug that undergoes hepatic O-demethylation to morphine, which is primarily responsible for its analgesic effect. Approximately 7–10% of Caucasians lack the enzyme cytochrome CYP2D6 that is necessary to convert codeine to morphine, and it is likely that this sizable segment of the population will not obtain pain relief from this drug. Conversely, in some populations up to 30% of patients have duplicate copies of the gene resulting in much higher and potentially dangerous serum morphine levels [15]. For this reason, codeine should not be used as a first-line analgesic unless the patient has a favorable history with this drug (**Table 4.7-4**).

Oxycodone and hydrocodone are oral opioid analgesics used in the treatment of moderate to severe pain. Unlike codeine, neither drug undergoes extensive metabolism prior to exerting their analgesic effect. Both oxycodone and hydrocodone are commonly used in conjunction with acetaminophen for the treatment of pain. Oxycodone, like morphine, is commonly used as a sustained-release preparation for around-the-clock dosing.

Morphine is the drug to which other opioids are compared. It penetrates the blood-brain barrier poorly, so that peak analgesic effects do not occur for 15–30 minutes after intravenous injection. It is hepatically conjugated and renally excreted as morphine-6-glucuronide. Because this metabolite can accumulate in renal failure and cause respiratory depression, morphine should be avoided in patients with renal insufficiency.

Meperidine is a synthetic opioid with 1/10 the potency of morphine. Its onset is significantly faster than morphine and it exerts a potent effect on the κ receptor, which makes it useful in low doses to treat shivering. Its major drawback, however, is its hepatic metabolism to normeperidine, which can induce seizures. For this reason, many institutions discourage its use and limit its dosage to 10 mg/kg daily. Normeperidine is renally excreted, making meperidine an unsuitable choice for patients with a history of either epileptic seizures or renal failure.

Drug	Equianalgesic parenteral adult dose, mg	Equianalgesic oral adult dose, mg	Duration of action, hours
Codeine	120	200	3–4
Oxycodone	5–10	30	2–4
Hydrocodone	–	5–10	2–4
Morphine	10	30–60*	3–4
Meperidine	100	300	2–3
Hydromorphone	1.5	6	2–4
Fentanyl	0.1	–	0.5

* 60 mg morphine for acute dosing, 30 mg for chronic dosing due to accumulation of metabolites.

Table 4.7-4 Opioid analgesics [8].*

Hydromorphone is 6–7 times as potent as morphine and is indicated for moderate to severe pain. It has a slightly faster onset than morphine and like morphine undergoes glucuronidation in the liver. Unlike morphine and meperidine, however, it is relatively devoid of toxic metabolites that depend on renal excretion making it a more appropriate drug in patients with renal insufficiency.

Fentanyl is a synthetic opioid analgesic with approximately 100 times the potency of morphine. It is also indicated in the treatment of moderate to severe pain. The onset of action is less than 30 seconds with a peak effect of 2–3 minutes when given intravenously. It has a relatively short duration of action. Like hydromophone, its lack of toxic metabolites makes it a suitable drug for patients with renal failure. However, its short duration of action makes it difficult to maintain a steady state of analgesia in patients using fentanyl as a patient-controlled analgesia (PCA).

Fear of causing addiction has traditionally been one of the major reasons that physicians avoid prescribing opioid analgesics and by 2015, overdoses attributed to opioid analgesics outnumbered deaths from trauma in the US [16].

> The incidence of addiction when prescribing opioids appropriately for the treatment of pain is remarkably low, likely far lower than the incidence of untoward cardiopulmonary adverse effects when pain is not adequately treated. However, surgeons should also be aware of the natural recovery period following trauma and prolonged, outpatient prescription of opioids (more than 3–4 weeks) during the recovery period should be discouraged and is rarely required to treat pain from acute trauma.

Another common reason for under prescribing opioid analgesics is the fear of inducing respiratory depression. This risk can be minimized by using PCA to deliver opioids, instead of larger intramuscular or intravenous injections. When PCA is compared with intramuscular administration of opioids, PCA is found to provide better analgesia with fewer pulmonary and cognitive complications [17]. Smaller, more frequent PCA doses will result in more consistent blood levels with fewer and smaller peaks and troughs in drug levels. Other

keys to avoiding oversedation in these patients are to minimize the use of unnecessary sedating medications. Benzodiazepines or sedatives should not be used unnecessarily and, even then, only in smaller doses. Opioid consumption is greatest during the first 24 hours and patients require closer monitoring during this time. In many institutions, patients will routinely be administered oxygen by nasal prongs once therapy with PCA is started.

2.1.2 Nerve blocks

Without question, the most profound analgesia will be obtained via neural blockade, whether it is a neuraxial or peripheral technique. With long-acting local anesthetics, the analgesic effects of a nerve block can be expected to last between 18 and 24 hours (following a single injection), or for several days if a catheter technique is chosen.

There are many studies confirming the analgesic advantages of neural blockade over general anesthesia, especially in patients with significant cardiac and pulmonary morbidity [18]. For patients with significant cardiac or pulmonary disease, the challenge may not be the anesthetic but rather the debilitating adverse effects of postoperative opioid analgesics. These patients may derive the greatest benefit from regional anesthesia, be it a single injection or a catheter technique. Regional anesthesia, however, is not without its drawbacks, and compartment syndrome is a potential problem in the limbs [19] (see chapter 1.5). One of the earliest symptoms is pain that is disproportionate to the degree of injury accompanied by pain on passive motion or neurological signs, such as numbness and paresthesia. Neural blockade may delay the diagnosis by masking these symptoms and signs. If the use of regional anesthesia cannot be avoided in patients at risk of compartment syndrome, then the local anesthetic concentration of the postoperative infusion may be lowered and the patient must be monitored with extra vigilance for the development of this syndrome. The use of compartment pressure monitoring may also be considered. In elderly patients with hip fracture, femoral nerve block has been shown to give good analgesia and significantly reduce opiate use and associated pulmonary complications.

2.2 Dressings

To allow the surgical wounds to dry as quickly as possible, they are covered in the operating room with sterile, absorbent gauze that allows for air circulation or a composite hydrophilic wound dressing. If used, suction drainage remains in place for about 24 hours if there are routine amounts of exudation. For larger volumes of exudate, as in pelvic or hip fractures, 48 hours may be required. Articular fractures are a special case and should be drained for no more that 8–12 hours. Beyond these times, the risk of infection is increased. If the wounds have bled extensively, the first change of dressings takes place 24 hours after surgery; otherwise they can remain in place for 48 hours and hydrophilic dressings may be left for longer. Thereafter, the dressings are changed daily to prevent the formation of a moist environment. Such changes are carried out under strict hygienic conditions. Chlorhexidine solutions with alcohol are recommended for skin disinfection. As soon as bleeding or secretion ceases, the wound is left uncovered. Even with sutures in place, the patient can bathe or undergo hydrotherapy if the wound is temporarily protected by a watertight dressing (eg, OpSite film, Tegaderm). Open wounds should be covered with an occlusive dressing (possibly including antibiotic beads to produce an antibiotic pouch) and left undisturbed, to reduce the risk of nosocomial infection, until the patient returns to the operating room. Alternatively, a negative-pressure dressing can be used (see chapter 4.3).

A recent development is the use of negative-pressure wound dressings for the management of closed wounds. Early clinical experience is good and these new dressings are currently being evaluated with prospective randomized controlled trials.

2.3 Elevation and support of the injured limb

Many surgeons have their own preferred regimens but the guidelines shown in **Table 4.7-1** are widely applicable.

> Immediately after operation, the treated extremity is positioned at the level of the heart to minimize swelling while maintaining perfusion.

Following osteosynthesis of the upper extremity, the limb is placed on a cushion. Flexion of the elbow should not exceed 75°. After any procedure, pressure from malpositioning and deformity must be prevented. The medial epicondyle of the elbow (ulnar nerve) and the head of the fibula (common peroneal nerve) must be well padded. Removable plaster bandages or splints, if they are used, must not lead to malpositioning nor inhibit early postoperative mobilization and physical therapy. Splints on the forearm and hand are placed in the position of safety to prevent contracture of the muscles and joints of the hand (see chapter 6.3.4).

In fractures close to the hip, the affected extremity is placed in moderate abduction and held in that position between cushions or in a padded splint. In distal and midshaft femoral fractures, the lower leg is supported with the knee joint in 30° of flexion (**Fig 4.7-2**). In all patients with lower limb fractures, it is essential to prevent pes equinus deformity of the ankle and foot by using appropriate splints.

The reduction of swelling may be reinforced with cooling (icing). Foot pumps are also effective for reducing leg swelling. In patients with a tendency toward pes equinus position, a U-splint is adapted to fit the lower limb. Splints with hinges that allow limited mobility are helpful either in gradual mobilization after an articular fracture, or if there have been associated ligamentous lesions.

The combination of surgery followed by protracted immobilization is inappropriate due to the increased rate of associated complications.

External splints should only be used to prevent malpositioning or additional injury, as well as to ensure soft-tissue healing.

2.4 Swelling, mobilization, and thrombosis prophylaxis

Early mobilization is important to reduce the risk of thrombosis. Prophylaxis against thrombosis may be used as described in chapter 4.6. Articular fractures require early mobilization and a continuous passive motion machine can be applied as soon as the wound condition allows (**Fig 4.7-2**). This can be particularly helpful for patients who are unable to mobilize the joint actively. Patients who have had an operation on the upper extremity should get up on the day of their surgery. If the lower extremity has been operated upon, ambulation is minimized until soft-tissue swelling has disappeared and the wound shows no signs of inflammation (**Videos 4.7-1–2**). The weight-bearing status of the limb depends on the following:

- Personality of the injury
- Function of implants used
- Coexisting injuries
- Preoperative morbidity and frailty
- Patient compliance

Although guidelines are helpful, the final decision is with the operating surgeon who should be in the position of knowing how reliable the fixation is. Be careful not to allow early mobilization to interfere with wound healing.

Video 4.7-1 Early mobilization from bed with physiotherapy is essential after fracture surgery.

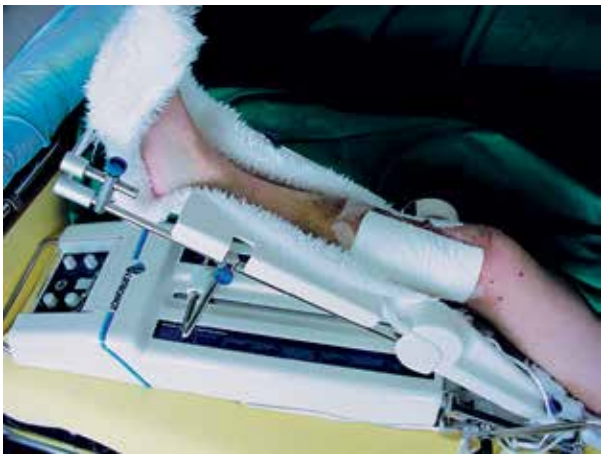

Fig 4.7-2 A continuous passive motion splint may be used for joint fractures.

Video 4.7-2 After surgery, the leg should be elevated and active mobilization of joints encouraged.

2.5 Antibiotics

The use of antibiotic prophylaxis and the treatment of contaminated wounds is covered in chapter 4.5.

2.6 Activity and weight bearing

Postoperative physical therapy begins on postoperative day 1. In long-bone injuries, the neighboring joints start active and active-assisted movement (**Video 4.7-3**). Continuous passive motion may also be used. At first, weight bearing (up to 15–20 kg) should take place with the assistance of crutches and walkers and only under the guidance of trained personnel. Prolonged delay in weight bearing may cause osteopenia and joint stiffness. Training in walking up and down stairs (**Video 4.7-4**) with canes is particularly difficult for patients and should be carefully supervised. Hydrotherapy is an important means of providing weightless and pain-free mobilization for patients with fractures of the spine, shoulder, pelvis, and hip; it also helps to build up confidence.

2.7 Radiographic assessment

During surgery x-rays are taken in at least two planes. Many patients require formal postoperative x-rays, as the image intensifier provides images of a narrow field and inferior quality. These serve to document fracture reduction and fixation, record the orientation of implants, and provide a basis for the evaluation of how fracture healing is progressing.

2.8 Communication

Throughout this first phase, the patient and relatives should be informed regularly and fully about the clinical state, the rate of progress, and what is to be expected along the timetable to recovery. The expectations of the patient and the family should be ascertained and the involved persons should be appropriately educated toward an understanding of the actual situation. All relevant support services should be involved at an early stage.

The following points should be established between patient and staff:

- The wound is healing without complication and pain is controlled.
- Intraoperative x-rays have been taken.
- Instructions have been given for ambulation with crutches (including stairs), and for further mobilization (**Video 4.7-5**).
- Information has been provided about symptoms and signs of possible complications.
- Instructions have been given to care providers about postoperative treatment and follow-up.

In addition, patients also find it helpful to have estimates of the following as it helps them to organize their life:

- Date of hospital discharge
- Time to resume walking without crutches
- Time to resume driving
- Return to occupation or education

Video 4.7-3 Active-assisted exercises reduce joint stiffness and help start muscle rehabilitation.

Video 4.7-4 Elderly patients must be given instructions on activities, such as stair walking, before discharge from hospital.

3 Second phase of postoperative fracture treatment

3.1 Clinical care outside hospital

The surgeon must ensure competent follow-up after hospital discharge. The patient must be provided with sufficient information to be able to decide, and carry out, the next steps in their rehabilitation. The follow-up physician must be aware of irregularities in the healing process and prevent them from becoming serious complications. The first postoperative consultation usually takes place around 14 days after surgery, conveniently at the time of suture removal. Sedentary work can be resumed as early as 2 weeks after the operation, provided injury-related restrictions are followed. A prerequisite is that adequate arrangements for transportation can be made.

3.2 Complex regional pain syndrome

The IASP introduced a new taxonomy in 1994 to more accurately describe the pain syndromes of reflex sympathetic dystrophy (CRPS I) and causalgia (CRPS II).The reason for these changes in taxonomy was to avoid terms that implied a pathophysiology where none had yet been elucidated [20]. These criteria were revised by expert consensus in 2003, becoming what is known as the "Budapest Criteria" for CRPS. These newer diagnostic criteria offer the advantage of greatly enhanced diagnostic specificity [21].

Video 4.7-5 Patients can be instructed how to partially bear weight by using scales.

CRPS I and CRPS II are neuropathic pain syndromes associated with sudomotor and vasomotor disturbances. The two pain syndromes have similar symptoms, the difference being that an identifiable nerve lesion is associated with CRPS II.

There is no specific test for the diagnosis of these conditions. The diagnosis depends on clinical findings and the exclusion of other conditions that could account for the clinical manifestation.

The Budapest IASP—approved diagnostic criteria for CRPS [21] requires adherence to all the following four points. There are two versions of diagnostic criteria. For clinical purposes, there is a positive diagnosis if (under category 3) more than two categories are fulfilled. For research purposes three or more categories must be fulfilled.

Budapest diagnostic criteria for CRPS [21]:

- Continuing pain that is disproportionate to any inciting event.
- Must report at least one symptom in three of the four following categories:
  - **Sensory**: reports of hyperesthesia and/or allodynia
  - **Vasomotor**: reports of temperature asymmetry and/or skin color changes and/or skin color asymmetry
  - **Sudomotor/edema**: reports of edema and/or sweating changes and/or sweating asymmetry
  - **Motor/trophic**: reports of decreased range of motion and/or motor dysfunction (weakness, tremor, dystonia) and/or trophic changes (hair, nail, skin)
- Must display at least one sign at the time of evaluation in two (clinical) or three or more (scientific) of the following categories:
  - **Sensory**: evidence of hyperalgesia (to pinprick) or allodynia (to light touch and/or deep somatic pressure and/or joint movement)
  - **Vasomotor**: evidence of temperature asymmetry and/or skin color changes and/or asymmetry
  - **Sudomotor/edema**: evidence of edema and/or sweating changes and/or sweating asymmetry
  - **Motor/trophic**: evidence of decreased range of motion and/or motor dysfunction (weakness, tremor, dystonia) and/or trophic changes (hair, nail, skin)
- There is no diagnosis that better explains the signs and symptoms.

Pain that seems disproportionate or out of the ordinary is the most consistent feature of CRPS. In one study [22], intense pain (more than 5/10) persisting 1 week after wrist fracture was highly predictive (46%) of developing CRPS versus 3.8% of patients who did not experience intense pain after a wrist fracture.

Although diagnostic tests can at times be helpful in the diagnosis of CRPS, it must be emphasized that the diagnosis of CRPS is entirely clinical. There must be objective clinical signs (not just the subjective report of pain), but the diagnosis does not depend on the presence or absence of a positive laboratory or radiological finding.

Plain x-rays may demonstrate cortical thinning and osteopenia secondary to increased osteoclast activity. These features have a periarticular predominance and are more pronounced than is expected from disuse alone. With progression of the disease, the osteopenia has a diffuse ground-glass appearance (**Fig 4.7-3**).

While the precise etiology of the changes involving the peripheral and central nervous systems has not been elucidated, our understanding of the role of the sympathetic nervous system in CRPS continues to evolve. The pathophysiology may differ between patients and even within a single patient over time [23]. Various mechanisms may include inflammation, oxidative stress, and/or perturbations of the sympathetic nervous system.

Fig 4.7-3 Pes equinus and severe bone dystrophy due to complex regional pain syndrome after malleolar fracture.

Most authors emphasize a multidisciplinary approach to the treatment of CRPS with analgesia, exercise, rehabilitation, and functional restoration being the mainstays [24].

The successful treatment of CRPS necessitates early diagnosis and early appropriate pain management to assist the patient in progressing and achieving the goals of exercise and physical therapy, together with psychological support.

If the patient fails to progress in a timely manner (ie, 2 weeks), then the incremental use of pain management strategies and psychological intervention are used to aid in their progression [20]. There must be an appropriate analgesia regimen, usually involving regular medication with increased doses at the time of physical therapy so that the patient will be able to tolerate such therapeutic modalities as desensitization, isometric exercises, resisted range of motion, and finally stress loading [20]. Passive range of motion exercises are contraindicated as they can have the detrimental effect of activating large α-β fiber types I and II mechanoreceptors. Even with appropriate analgesia and psychological therapy, it is common for patients to notice a temporary increase in pain and swelling at the start of physical therapy. They must be warned about this and reassured that it is normal.

It is recommended that patients experiencing significant symptoms of CRPS for more than 6–8 weeks undergo psychological assessment [20]. By developing coping skills via cognitive behavioral therapy and utilizing relaxation techniques, such as biofeedback, patients help to facilitate their pain management and eventually their physical therapy.

The primary goal in pain management of CRPS is to facilitate physical therapy because ultimately it is physical therapy that is responsible for improvement in the patient's condition. Pain management in CRPS proceeds aggressively, step by step. Pharmacotherapy is initiated to target the patient's symptoms. Bisphosphonates can reduce pain intensity and bone loss in patients with CRPS [25]. Neuropathic pain is a common feature of CRPS and tricyclic antidepressants, such as amitriptyline, are often initiated along with an anticonvulsant medication such as gabapentin or pregabalin. Antidepressants facilitate catecholamine neurotransmission within the central nervous system, which causes hyperpolarize dorsal horn neurons and an antinociceptive effect [26].

Other medications commonly include NSAIDs and oral opioids. Oral opioids may initially be given as shorter-acting compounds, for example, oxycodone combined with acetaminophen. These are particularly helpful if taken 30 minutes before physical therapy. If tolerance develops or the pain is not well managed with intermittent dosing, then sustained release opioid preparations are added. If the patient is no longer progressing in physical therapy with the aid of oral medication then he/she should receive more aggressive treatment, such as sympathetic or somatic nerve blocks [20]. Patients with sympathetically maintained pain should receive a sympathetic nerve block and if they respond well to a block then a course of 3–6 sympathetic blocks along with physical therapy may help achieve remission [20]. If the patient does not respond well to a sympathetic block then a somatic nerve block or a tunneled epidural catheter may be indicated to provide optimal analgesia for physical therapy.

If the patient is still unable to progress, consideration must be directed toward more invasive techniques. Neuromodulation in the form of spinal cord stimulation for CRPS I and II or peripheral nerve stimulation for CRPS II may be indicated if the patient only partially responds to sympathetic or somatic nerve blocks [20]. Intrathecal pumps may be used to deliver local anesthetics, opioids, or baclofen in patients who have failed neuromodulation [20] or have dystonia or long-standing disease.

CRPS remains a potentially devastating disease of unclear etiology. Early diagnosis is essential with immediate physical therapy and an appropriate analgesic regimen. This offers the highest chance of a good outcome. This treatment can be started by the orthopedic surgeon and with early intervention, many patients do not need to see a pain specialist.

If clinicians fail to consider the diagnosis early, an unfavorable outcome may result. Whether the patient presents with a mild or a fulminant picture of CRPS, remember that facilitating physical therapy is the primary goal of pain management and frequent reevaluation of the patient's progress in therapy is crucial to minimize disease progression.

3.3 Clinical and x-ray monitoring

The frequency and timing of follow-up visits to a physician are largely a matter of local arrangement but certain features are always essential.

During periodic visits for monitoring, special attention should be given to specific questions regarding routine patient activities like showering, bathing, sitting, lifting, work, and sports. These can be highly relevant to the patient's personal and professional life. The sooner problems in these areas are resolved, the sooner the patient may again be assimilated into his/her familiar environment. With good communication between patient and physician in this phase of fracture treatment, conditions are optimal for reassuming work, education and sports. Increased redness, swelling or local tenderness, arrest or reversal of progress, or decreased mobility associated with pain are clinical features to be considered as warning signs of possible complex regional pain syndrome, deep infection, or nonunion. Difficulty caused by activities that patients have previously been comfortable with (eg, weight bearing) is a valuable guide. Pain on weight bearing suggests that the fracture is still moving.

Radiographic monitoring at 4–6 week intervals must include full-length views in two planes; in special cases, additional views may be necessary. For fractures involving a joint surface, tangential views may be essential in the evaluation of articular congruity. In long-bone fractures, the neighboring joints should be included in the x-ray, which usually demands the use of a suitably long film. In the presence of hardware, fracture union can sometimes be difficult to assess on plain x-rays and computed tomographic scan can be helpful. Evaluation of postoperative x-rays must be performed based on the type of healing expected (primary or secondary). The surgeon must compare with previous x-rays and look at two key factors: the implant and the fracture. Evaluation of the implant should include position, displacement, bending, loosening or breakage. Osteolysis around screws is an important early sign of implant loosening. Evaluation of the fracture should include alignment, displacement of fragment, fracture line and bridging callus.

If primary bone healing is anticipated, the appearance of irritation callus or a widening of the fracture line may point to impending trouble and require modification of the management regimen.

With secondary bone healing, timely development of callus surrounding the fracture site and steadily maturing callus is encouraging.

Careful attention must be paid for secondary displacement, implant loosening, bone resorption, or failure and secondary displacement.

The surgeon should always be sure that union is progressing at a rate appropriate to the particular clinical situation, and be prepared to take action if this does not apply. Early bone grafting (week 6–12) in difficult fractures will prevent many nonunions.

Given positive clinical and radiographic findings, weight bearing may be gradually increased. When joints are involved, a simultaneous decision is made regarding the allowable freedom of motion.

3.4 Early removal of implants

Implants that may be removed to allow full mobilization (such as percutaneous K-wires, diastasis screws, hook plate on the clavicle, or external fixators) can be partially or completely removed after 12 weeks. This may allow full range of motion or weight bearing, for example, following the removal of a diastasis screw from a type C malleolar fracture.

4 Third phase—conclusion of the postoperative fracture treatment

Fracture treatment is complete when the patient regains full capacity for normal activities of daily living, work, and sports (if appropriate). This phase can take many months and visits to see the surgeon but is important for the continued well-being of the patient with continued encouragement and reassurance for a satisfactory outcome.

5 Implant removal

Implant removal for many patients represents the true completion of fracture treatment. At an early stage after surgery, the patient should be given a clear outline of the surgeon's opinion on the removal of implants. While giving due concern to the patient's own wishes, the expense, utility, and risks of implant removal must be considered and communicated. Before implant removal, further x-rays must be taken to:

- Confirm fracture healing is complete especially with primary bone healing.
- Evaluate the type, condition, and location of implants.
- Ensure correct and good quality implant removal equipment is available.

There are several indications for implant removal. Early removal may be necessary for implants, such as position screws. Late implant removal is more common in young patients, and over bony prominences under the skin, such as the olecranon, patella, and malleoli. In the upper extremity, implant removal is generally neither necessary nor recommended. The main indication for removal of hardware is implant–related soft-tissue irritation or pain. Allergic-type hypersensitivity reactions can occur but they are very rare with stainless steel implants and practically unknown with implants made of pure titanium (see chapter 1.3). External fixators and K-wires are always completely removed due to the danger of secondary displacement or migration, and pin-track infection.

When additional surgery is indicated (eg, arthrolysis, tenolysis, neurolysis, scar revision), the implants may be removed at the same time if fracture healing is complete.

Implants are usually left in place in elderly patients to prevent refracture through the previously fixed area. The risks and benefits of removal must be carefully estimated in patients with poor general health, immune deficiencies (eg, HIV, hepatitis, tuberculosis), or local circulatory disturbances (eg, diabetes mellitus, peripheral arterial disease). Implants in areas with a higher risk of iatrogenic nerve or vessel damage (eg, forearm, humerus, pelvis) are left in place.

When implant removal is indicated, timing is determined by the location of the fracture and the character of the implants used. The implants are usually left in place for at least 1–2 years (especially on tension surfaces, such as the patella or greater trochanter), during which the progress of fracture healing is monitored. X-rays must show complete fracture healing [27]. Patients must always be warned of the small risk of infection, refracture, and local nerve damage. Titanium implants can be difficult to remove because of bone ingrowth and a careful preoperative plan and full inventory of instruments will prevent intraoperative failure of hardware removal. Following removal and appropriate soft-tissue healing, full function and weight bearing may be resumed within a few days.

After removal of large plates, contact sports and heavy physical work should be postponed for at least 2–4 months. Thereafter, and possibly after another x-ray, fracture healing may be considered complete.

Classic references | Review references

6 References

1. **Mersky H, Bogduk N.** *Classification of Chronic Pain: Description of Chronic Pain Syndromes and Definitions of Pain Terms.* 2nd ed. Seattle: IASP Press; 1994.
2. **Smith AB, Ravikumar TS, Kamin M, et al.** Combination tramadol plus acetaminophen for postsurgical pain. *Am J Surg.* 2004 Apr;187(4):521–527.
3. **Schecter WP, Bongard FS, Gainor BJ, et al.** Pain control in outpatient surgery. *J Am Coll Surg.* 2002 Jul;195(1):95–104.
4. **Chen AF, Landy DC, Kumetz E, et al.** Prediction of postoperative pain after Mohs micrographic surgery with 2 validated pain anxiety scales. *Dermatol Surg.* 2015 Jan;41(1):40–47.
5. **Alexander R, El-Moalem HE, Gan TJ.** Comparison of the morphine-sparing effects of diclofenac sodium and ketorolac tromethamine after major orthopedic surgery. *J Clin Anesth.* 2002 May;14(3):187–192.
6. **Gilron I, Tod D, Goldstein DH, et al.** The relationship between movement-evoked versus spontaneous pain and peak expiratory flow after abdominal hysterectomy. *Anesth Analg.* 2002 Dec;95(6):1702–1707.
7. **Redmond M, Florence B, Glass PS.** Effective analgesic modalities for ambulatory patients. *Anesthesiol Clin North America.* 2003 Jun;21(2):329–346.
8. **Repchinsky C, Welbanks L, Bisson R.** *Compendium of Pharmaceuticals and Specialties.* Ottawa: Canadian Pharmacists Association; 2004.
9. **Gajraj NM.** The effect of cyclooxygenase-2 inhibitors on bone healing. *Reg Anesth Pain Med.* 2003 Sep-Oct;28(5):456–465.
10. **Kurmis AP, Kurmis TP, O'Brien JX, et al.** The effect of nonsteroidal anti-inflammatory drug administration on acute phase fracture-healing: a review. *J Bone Joint Surg Am.* 2012 May;94(9):815–823.
11. **Langford RM, Mehta V.** Selective cyclooxygenase inhibition: its role in pain and anesthesia. *Biomed Pharmacother.* 2006 Aug;60(7):323–328.
12. **Turan A, Karamanlioglu B, Memis D, et al.** Analgesic effects of gabapentin after spinal surgery. *Anesthesiology.* 2004 Apr;100(4):935–938.
13. **Tremont-Lukats IW, Megeff C, Backonja MM.** Anticonvulsants for neuropathic pain syndromes: mechanisms of action and place in therapy. *Drugs.* 2000 Nov;60(5):1029–1052.
14. **Parvizi J, Miller A, Gandhi K.** Multimodal pain management after total joint arthroplasty. *J Bone Joint Surg Am.* 2011 Jun;93(11):1075–1084.
15. **Kirchheiner J, Schmidt H, Tzvetkov M, et al.** Pharmacokinetics of codeine and its metabolite morphine in ultra-rapid metabolizers due to CYP2D6 duplication. *Pharmacogenomics J.* 2007 Aug;7(4):257–265.
16. **Dart RC, Surratt HL, Cicero TJ, et al.** Trends in opioid analgesic abuse and mortality in the United States. *N Engl J Med.* 2015 Jan 15;372(3):241–248.
17. **Egbert AM, Parks LH, Short LM, et al.** Randomized trial of postoperative patient-controlled analgesia vs intramuscular narcotics in frail elderly men. *Arch Intern Med.* 1990 Sep;150(9):1897–1903.
18. **Hu S, Zhang ZY, Hua YQ, et al.** A Comparison of regional and general anesthesia for total replacement of the hip or knee: a meta-analysis. *J Bone Joint Surg Br.* 2009 Jul;91(7):935–942.
19. **Rosenberg AD, Bernstein RL.** Perioperative anesthetic management of orthopedic injuries. *Anesthesiol Clin North Am.* 1999;17(1)171–182.
20. **Stanton-Hicks MD, Rezai AR, Burton AW, et al.** An updated interdisciplinary clinical pathway for CRPS: report of an expert panel. *Pain Practice.* 2002;2(1).
21. **Harden RN, Bruehl S, Perez RS, et al.** Validation of proposed diagnostic criteria (the "Budapest Criteria) for complex regional pain syndrome. *Pain.* 2010 Aug;150(2):268–274.
22. **Mosely GL, Herbert RD, Parsons T, et al.** Intense pain soon after wrist fracture strongly predicts who will develop complex regional pain syndrome: prospective cohort study. *J Pain.* 2014 Jan;(15):16–23.
23. **Taha R, Blaise G.** Update on the pathogenesis of complex regional pain syndrome: role of oxidative stress. *Can J Anaesth.* 2012 Sep;59(9):875–881.
24. **Koh TT, Daly A, Howard W, et al.** Complex regional pain syndrome. *JBJS Rev.* 2014 Jul 22;2(7).
25. **Brunner F, Schmid A, Kissling R, et al.** Bisphosphonates for the therapy of complex regional pain syndrome I: systematic review. *Eur J Pain.*2009 Jan;13(1):17–21.
26. **Rao SG.** The neuropharmacology of centrally-acting analgesic medications in fibromyalgia. *Rheum Dis Clin North Am.* 2002 May;28(2):235–259.
27. **Stafford P, Norris B, Nowotarski P.** Hardware removal: tips and techniques in revision fracture surgery. *Tech Orthop.* 2003;17(4):522–530.

7 Acknowledgments

We thank Christian Ryf for his contribution to this chapter in the second edition of the *AO Principles of Fracture Management*.

4.8 Fragility fractures and orthogeriatric care

Michael Blauth, Markus Gosch, Thomas J. Luger, Hans Peter Dimai, Stephen L Kates

1 Introduction

Life expectancy is dramatically increasing globally and the population is aging at an unprecedented rate. By 2050, people aged 60 years or older will exceed the number of younger people. This worldwide trend is believed to be irreversible and is coupled with lower birth rates and lower fertility.

The fastest growing demographic of the world population is those older than 80 years and in some countries more than 10% of patients with hip fracture are older than 90 years. In many orthopedic trauma departments, patients with fragility fractures now represent the largest group of patients (30%).

Fragility fracture was defined by the World Health Organization in 1998 as "a fracture caused by injury that would be insufficient to fracture normal bone; the result of reduced compressive and/or torsional strength of bone".

From a clinical perspective, a fragility fracture is defined as a fracture that occurs as a result of a minimal trauma, such as a fall from a standing height or less [1].

Osteoporosis is defined as "a systemic skeletal disease characterized by low bone mass and microarchitectural changes with a consequent increase in bone fragility and susceptibility to fracture" [2].

The most common fractures associated with osteoporosis are those at the hip, spine, distal radius and proximal humerus. Many other fractures after the age of 50 years are associated with low bone mass and should therefore be regarded as osteoporotic [2]. Over the years, many patients sustain multiple fractures (**Fig 4.8-1**), so osteoporosis can be considered a chronic disease with intermittent acute episodes (fracture).

The two major pillars in the treatment of fragility fractures are:

- Orthogeriatric comanaged care in the acute phase (30–35 days) including the rehabilitation process
- Lifelong secondary fracture prevention

1.1 Epidemiology

Osteoporosis is a major public health problem, affecting hundreds of millions of people worldwide.

It is estimated that an osteoporotic fracture occurs every 3 seconds worldwide. One in two women and one in five men aged 50 years and older will suffer a fracture in their remaining lifetime. The average lifetime risk for a 50-year-old adult of suffering an osteoporotic fracture has been estimated at 40–50% for women and 13–22% for men [3]. Approximately 50% of people with one osteoporotic fracture will have another, with the risk of new fractures rising exponentially with each fracture [4].

In general, the incidence of fragility fractures increases with age. However, the proportion of fractures at any site also varies with age. For example, the median age for distal radial fractures in women is 65 years and for hip fractures is 80 years [3].

1.1.1 Hip fracture

Hip fracture incidence has been shown to increase exponentially with age and the worldwide hip fracture incidence has been predicted to increase dramatically during the next three decades, mainly due to the increasing number of older people [5].

Estimates suggest that there are approximately 0.6 million hip fractures per annum in the European Union and about 0.3 million hip fractures in the US [6, 7].

Fig 4.8-1a–n An 88-year-old woman weighing 46 kg sustained a pertrochanteric fracture. Comorbidities were osteoporosis, heart failure, hypertension, depression, mild cognitive impairment, and problems swallowing. She lived alone and independently on low income with some help from her neighbors and a son. She used stairs to get to her second floor flat.

a–b Preoperative x-rays.

c A medial proximal tibial fracture was detected, most probably sustained at the same accident as the hip fracture and treated conservatively.

d–e The fracture healed after fixation with a proximal femoral nail antirotation (PFNA).

f Due to severe coxarthritis, total joint replacement was performed.

Fig 4.8-1a–n (**cont**)

g–i During her stay in the hospital, she fell and sustained a proximal humeral fracture that was treated nonoperatively with a typical varus malunion.

j–m Some time later, she suffered a periprosthetic fracture at the level of the tip of the stem ("problematic fracture") and at the site of the PFNA locking screw. Despite the rigid fixation and a remaining gap, the fracture healed eventually. At the time of this fracture, teriparatide was administered.

n Three years before the proximal femoral fracture, an osteoporotic spine fracture had been diagnosed. Unfortunately, no action had been taken with regard to secondary fracture prophylaxis.

In a recently published systematic review [8], it was shown that there is a greater than 10-fold variation in hip fracture risk and fracture probability among countries (**Fig 4.8-2**). The low incidence of osteoporosis in developing countries may be partly due to the lower life expectancy. However, by the year 2050, more than half of all hip fractures in the world will occur in Asia (**Fig 4.8-2**).

1.1.2 Vertebral fracture

Vertebral fractures are the most common osteoporotic fracture. However, the incidence of vertebral fractures is not well documented due to the fact that only approximately 30% of these fractures come to clinical attention, so-called clinical vertebral fractures [9]. Most vertebral fractures are asymptomatic and may be only detected on x-rays (radiographic or morphometric vertebral fractures).

1.1.3 Distal radial fractures

In contrast to hip or vertebral fractures, the incidence of distal radial fractures appears to increase rapidly during the early postmenopausal period and there is evidence of a plateau in the incidence of fracture during the mid-60s [10]. The average lifetime risk in a 50-year-old caucasian adult of suffering a distal radial fracture has been estimated at 20% for women and at 5% for men [3].

1.1.4 Proximal humeral fracture

The average lifetime risk for a 50-year-old white adult of suffering this type of fracture has been estimated at 13% for women and at 4% for men [11, 12]. In populations with sufficient epidemiological data on different fracture types, the overall age-adjusted incidence of humeral fractures is approximately 50–60% of hip fracture incidence rates.

2 Etiology

Bone strength reflects the integration of two main features: bone density and bone quality:

- Bone density is expressed as grams of mineral per area of volume and in any given individual is determined by peak bone mass and amount of bone loss.
- Bone quality refers to architecture, turnover, mineralization and damage accumulation, eg, microfractures. A fracture occurs when force exceeds the strain tolerance of bone and osteoporotic bone has a much lower strain tolerance than normal bone. In severe osteoporosis, even normal physiological strain may exceed this tolerance and result in fracture, eg, many vertebral fractures.

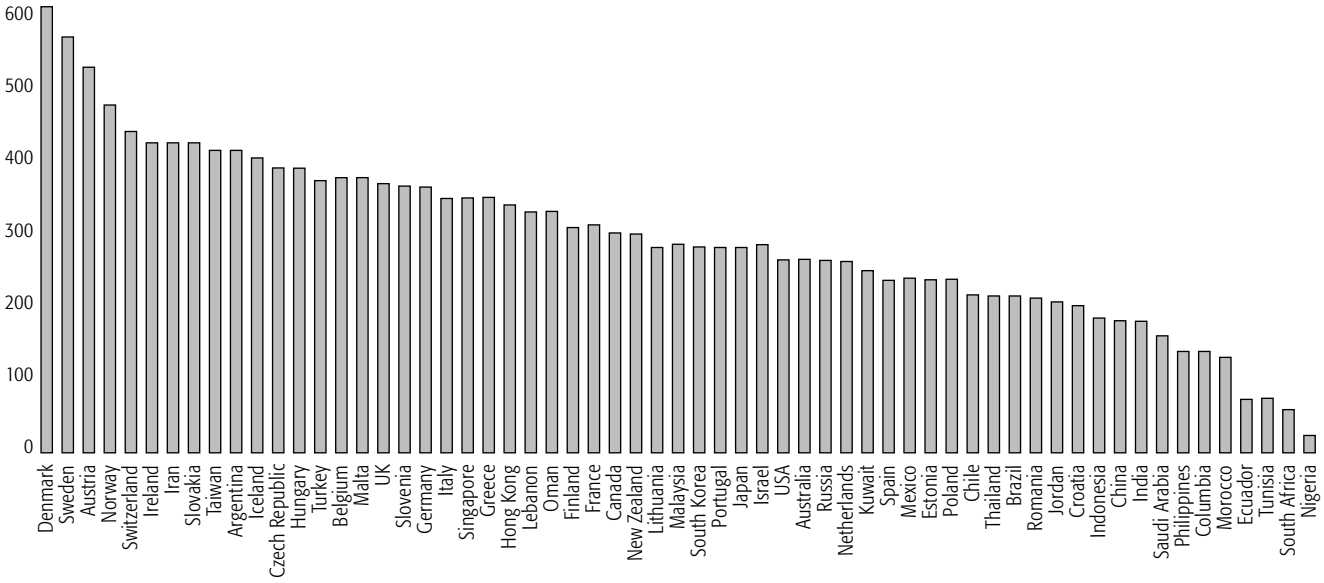

Fig 4.8–2 World standardized annual hip fracture rates for women (per 100,000). Adapted from Kanis, 2012 [8].

Osteoporosis influences both strength and stiffness of bone. Both decrease with age and degree of demineralization. This is true for cortical and cancellous bone. Osteoporosis involves a loss of bone mass, reduction in bone quality by deterioration of microarchitecture and reduced ability of bone to withstand loading. It is important to understand the difference between bone mineral density (which reflects the calcium content) and the deterioration of bone quality measurable in reduced resistance to loading. Usually, the quality of bone reduces much more with age in cancellous bone than in cortical bone.

2.1 Cortical bone

Cortical bone in a 25-year-old adult is dense, thick, and strong. The pattern of age-related cortical bone loss involves loss of cortical thickness that is more marked at the endosteum with an increase in medullary diameter; particularly in women (**Fig 4.8-3**).

The changes in outer and inner cortical diameter affect the bending and torsional characteristics of the whole bone. If we assume a diaphyseal bone is a tube, the formula $\Pi/4(R4\text{-}r4)$ describes the calculation of the bending stiffness of a tube (R, r = outer and inner radii of a tube). Bending stiffness depends on the inner and outer radius of the tube.

2.2 Cancellous bone

In cancellous bone, the change in bone structure is due to decreasing trabecular thickness, interruption of the trabecular network, reduction in the number of trabeculae, and reduction of trabecular connectivity. As well as age and hormonal changes, reduced physical activity also leads to deterioration of bone. There is vast evidence that mechanical usage influences bone mass (Wolff's law) but, unfortunately, exercise only leads to a minimal increase in bone mass.

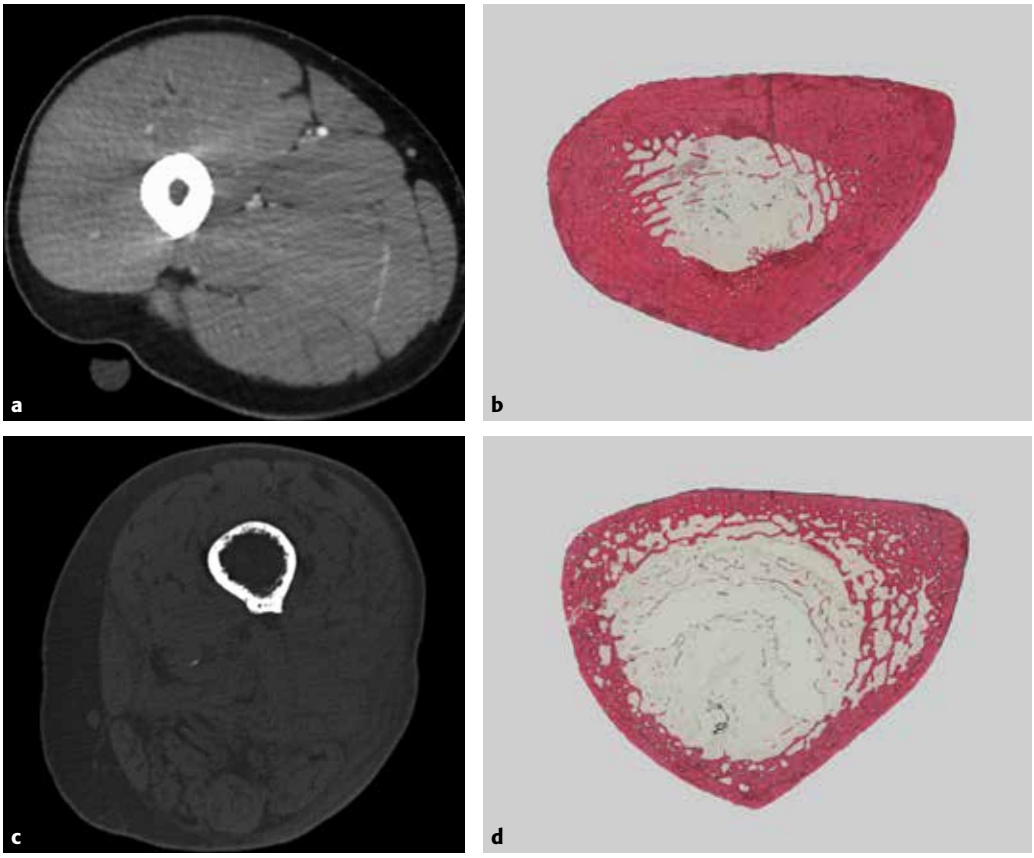

Fig 4.8-3a–d Age-related changes in cortical bone quality. Cortical bone loss between 30 and 80 years of age, with 8% decrease in elastic modulus, 11% decrease in ultimate strength, and 34% decrease in toughness.
a–b Cross-section images of cortical bone from a 30-year-old woman.
c–d Cross-section images of cortical bone from an 80-year-old woman.
(Images of histological sections (**b**, **d**) courtesy of Beat Schmutz, Davos, Switzerland.)

With aging, the bone trabeculae change in shape from flatter structures to more rod-like structures. These changes weaken the internal architecture of the cancellous bone making it more likely to fracture with minor trauma (**Fig 4.8-4**).

2.3 Significance for fracture fixation

Biomechanical studies have demonstrated that osteoporotic changes reduce implant anchorage. Decreased cortical thickness significantly affects the holding capacity of screws.

2.4 Measurement of osteoporosis

Dual-energy x-ray absorptiometry (DEXA) has become the standard method for measuring bone mineral density as a proxy measure and accounts for approximately 70% of bone strength. The World Health Organization operationally defines osteoporosis as bone density 2.5 standard deviations below the mean for young caucasian adult women. It is not clear how to apply this diagnostic criterion to men, children, and across ethnic groups.

Indications for obtaining a DEXA scan include:

- Long-term steroid use
- Early surgical menopause
- Postmenopausal women with alcoholism, heavy tobacco use, a body mass index < 18.5, or a family history of fragility fractures
- Baseline measurement for monitoring bone-protection therapy
- Follow-up measurement after bone-protection therapy

Clinically, in the acute fracture situation, the degree of osteoporosis should be estimated by consideration of preoperative x-ray imaging, intraoperative haptics while drilling or fixing bone and additional parameters such as gender, age, and comorbidities.

2.4.1 Falls

Most fractures are caused by falls. Therefore, falls, osteoporosis, and fractures must be addressed together. Several measures have been suggested for the prevention of falls in older patients including strength and balance training, home hazard assessment and modification, vision assessment, medication review, cardiac pacing when necessary, and cognitive behavioral interventions.

Risk factors for falls are similar to those for fracture: previous falls, weakness, poor balance, gait disorders, and taking certain medications, such as psychoactive drugs, anticonvulsants, and antihypertensive drugs.

2.4.2 Other mechanisms of injury

High-impact trauma has increased as people have become more active during their retirement, continuing to drive and enjoy outdoor activities more than was seen in the past. Falls down stairs are a particular hazard and can result in frail patients suffering high-energy and complex trauma.

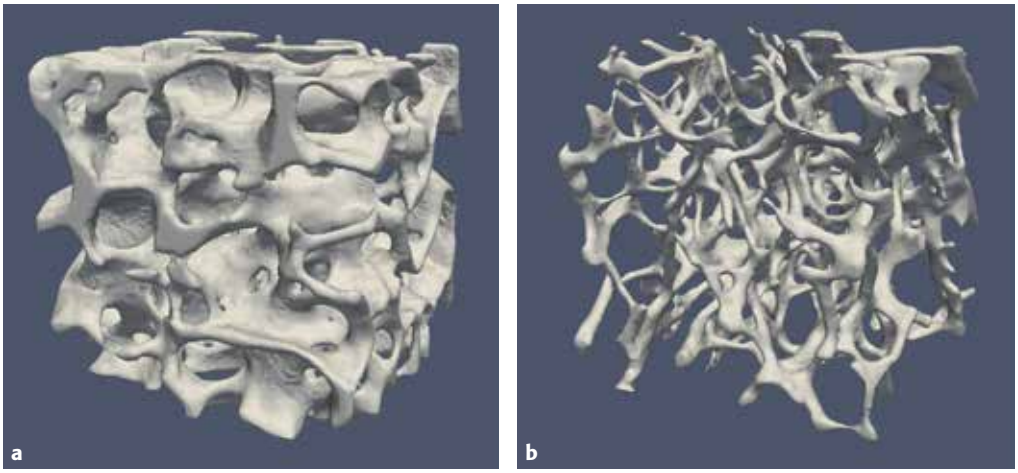

Fig 4.8-4a–b Age-related changes in trabecular bone quality. Besides drastic loss in bone mass, plate-like structures change into rod-like structures with aging as shown by these micro-computed tomographic images at age 35 (**a**) versus 73 (**b**) years. (Images by courtesy of Prof. Dr. Ralph Müller, Institute for Biomechanics at the ETH Zurich, Switzerland).

For care of the older patient with polytrauma, trauma centers have shown significantly better outcomes than acute care hospitals [12]. Injury patterns differ from younger patients with higher Injury Severity Scores and mortality, as well as more pelvic and upper extremity injuries [13]. Trauma registries have demonstrated that increased age is an independent variable for death in polytrauma with significant risk increases in patients older than 64 and 89 years (**Fig 4.8-5**).

3 The fragility fracture patient

A clinical definition of a fragility fracture patient is:

- Acute injury caused by a low-energy trauma
- Older than 70 or 80 years with reduced general health status

Factors that contribute to a reduced general health status include the number of comorbidities (two or more), cognitive state and functional disabilities that result in reduced mobility and increased need for social support. One of the common factors for many of these patients is that they are frail and have sarcopenia due to complex medical and rehabilitation problems. They have a higher need for specialist medical care.

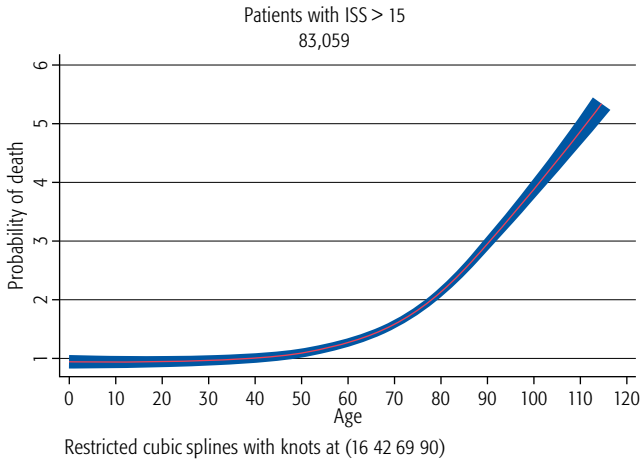

Fig 4.8–5 The impact of age on the probability of death following multiple trauma (ISS > 15). An analysis of 83,059 cases from the UK National Trauma Data Bank.
(Data supplied by the Trauma Audit and Research Network).

3.1 Relevant comorbidities

Fragility fractures are much more common in patients with preexisting medical conditions—comorbidities. Preexisting comorbidities also have a significant impact on outcomes of older trauma patients. While some of these comorbidities are apparent, others might remain unrecognized yet cause complications and result in an unfavorable outcome. Therefore, comorbidities should be assessed systematically and treatment goals should be set.

Established and helpful tools to assess the morbidity burden of an older patient are the Charlson Comorbidity Index with 19 items and the Cumulative Illness Rating Scale. Comorbidities should be documented at admission when the relevant information may be easiest to collect.

Common comorbidities in patients with fragility fractures include cardiac disease, dementia, renal dysfunction, pulmonary disease, hypertension, diabetes, and malignant disease.

Often, multiple comorbidities lead to the problem of polypharmacy. Each of these conditions is likely to be treated with at least one medication. The number of medications increases the risk of adverse drug reactions and unexpected drug-drug and drug-disease interactions. A special problem is the high prevalence of anticoagulation drugs in older adults.

These problems are best managed with an orthogeriatric team approach.

3.1.1 Preexisting conditions

Preexisting conditions cannot be changed fundamentally; they are common in fragility fracture patients and have to be recognized. The preoperative evaluation of geriatric patients should aim to identify all preexisting conditions but recognize that delay to treat most of these conditions is unlikely to reduce the risks of surgery. The key is to identify those that require immediate medical measures to lower the risks of surgery (see section 3.1.2 in this chapter). However, if the risk of surgery cannot be altered, surgery should be performed without further delay. Delaying surgery usually adds unnecessary risk [14]:

- Cardiac diseases: Hypertension, coronary heart disease, heart failure, atrial fibrillation, and valve disease are frequent among fragility fracture patients. In a stable patient, they present a higher risk for surgery but are not a contraindication. The challenge for the orthogeriatric team is the management of the medication, especially anticoagulation.

- Pulmonary diseases: Patients with severe pulmonary disease need strong collaboration with the anesthesiologist. Blood gases may help to estimate the pulmonary status. In cases where neuroaxial anesthesia is not feasible, severe pulmonary disease may be a contraindication for surgery.
- Renal dysfunction: 40% of patients with a hip fracture have chronic kidney disease (defined as an eGFR < 60), but all patients are at risk of acute kidney disease in the perioperative period. Inappropriate fluid management, nephrotoxic medication or computed tomographic scans with contrast agent increase the risk for acute kidney injury, which is also more common with increasing age, two or more comorbidities, and in those with chronic kidney disease.
- Diabetes: Hypoglycemia is more dangerous than hyperglycemia; nevertheless, blood glucose level should be lower than 200 mg.
- Dementia is an important risk factor for delirium and an independent risk factor for mortality. Patients should have a formal assessment of cognitive function on admission and there are a number of validated scoring systems, such as the abbreviated mental test score, that can be used.

3.1.2 Active conditions

Conditions that need medical stabilization before surgery are active geriatric medical conditions:

- Decompensated heart failure, acute cardiac ischemia
- Acute stroke
- Acute infection, such as pneumonia or septicemia
- Unstable angina
- Severe hypotension
- Acute bleeding, eg, gastrointestinal
- Rhabdomyolysis
- Acute kidney injury

Comorbidities, especially cardiopulmonary and renal conditions and medication, such as anticoagulants, may influence the type of anesthesia and timing of surgery. An anesthetist should be involved as early as possible to avoid any unnecessary delay.

As a rule, the time needed for medical stabilization should not exceed 72 hours. Any delay of surgery for more than 72 hours causes significant increase in complications. The team should define clear goals for the optimization, determine the responsibility, and set a time frame.

3.2 Functional disabilities

Beside medical comorbidities, older patients suffer from functional disabilities. They can be assessed systematically by using a standardized geriatric assessment. Functional needs and resources are helpful in terms of goal setting. Older adult patients often require the use of their upper extremities to assist with ambulation by using a cane or walker. It is impossible for older adult patients to limit their weight bearing on an injured extremity.

3.3 Frailty and sarcopenia

Frailty is a common clinical syndrome in older adults that results in an increased risk for poor outcomes including falls, disability, hospitalization, and mortality. In frail patients, the physiological reserve is limited and so the ability to compensate for poor medical or surgical management is drastically reduced.

Frailty is defined as a clinically recognizable state of increased vulnerability resulting from an aging-associated decline in reserve and function across multiple physiological systems, such that the ability to cope with every day or acute stressors is comprised [15].

At admission, frailty cannot be influenced. Nevertheless, it is important to assess it. Frail patients have a higher risk of complications and in-hospital death. Their functional outcome is drastically limited. All goals and treatment decisions should be considered carefully. The overall goal should be "not to harm these patients".

Sarcopenia is a syndrome characterized by progressive and generalized loss of skeletal muscle mass and strength that result in a risk of adverse outcomes, such as physical disability, poor quality of life, and death.

Depending on the definition used for sarcopenia, the prevalence in people 60–70 years of age is reported as 5–13% and ranges from 11–50% in people older than 80 years [16]. Usually, sarcopenia is a part of frailty. Nutrition, vitamin D3, and mobilization may help to avoid further progression of sarcopenia during a hospital stay.

3.4 Immobilization

Older adult patients do not tolerate prolonged bed rest either before or after surgery. This predisposes to problems, such as thromboembolism, decubitus ulcers, urinary tract, and chest infections.

Immobilization leads to a loss of 0.5% of muscle mass and up to 4% of muscle strength per day [17]. Nutrition and mobilization are the cornerstones in preventing sarcopenia due to immobilization.

3.5 Facilities

Older adult patients have specific needs and requirements that need to be met by specialized facilities to protect them from harm:

- Patient rooms, therapy rooms, bathroom facilities, and the floor must be accessible without obstacles and offer enough space and safety, eg, handrails to help patients with their personal hygiene.
- A therapy room located on the ward helps to avoid patient transportation.
- Facilities should be designed to avoid the development of delirium.
- Good lighting, contrasting colors, and other visual characteristics.
- Low beds, large clocks, and large windows for sufficient day light.
- Common areas where patients can meet, eat, and talk with each other.

4 Orthogeriatric comanagement

4.1 The Comorbidity Construct

The Comorbidity Construct [18] is a helpful tool to provide a better overview of older patients (**Fig 4.8-6**):

- The index disease leads to hospital admission.
- Comorbidities always have a strong relationship to the index disease.
- Gender is an issue, especially in terms of social and psychological conditions.
- The impact of age is not significant.
- The biological age of patients and estimated life expectancy are more relevant for the outcome.
- In older adult patients, intrinsic factors are a major contributor to falls.
- In older adult patients, morbidity burden is not only described by the comorbidities but also by the functional disabilities and geriatric syndromes.
- The complexity of these older adult patients result from a combination of their health problems and their nonhealth-related individual attributes.

4.2 Goal setting

Therapeutic decision making is much more complex in older adult patients. Fragility fracture patients are not homogeneous and the benefits and risks of treatment are not as clear as in younger patients. It is essential to find agreement for the treatment goals from all team members.

It is useful to set short-term as well as long-term goals. The long-term goal is the expected outcome in several weeks, eg, to live independently or to walk without using a walking aid. The goals may be changed due to medical complications or if a patient were to become unwilling or unable to continue or if they progress more slowly or quickly than expected.

4.3 Team approach and co-ownership

Comanagement requires that all core team members, ie, surgeons, anesthesiologists and geriatricians, are equal. Decisions are taken jointly. Leadership is not regulated by hierarchical structure but by medical qualification. Based on the knowledge and the expertise in the involved disciplines, leadership changes and depends on the clinical situation. However, each member has a specific role and expertise within the team.

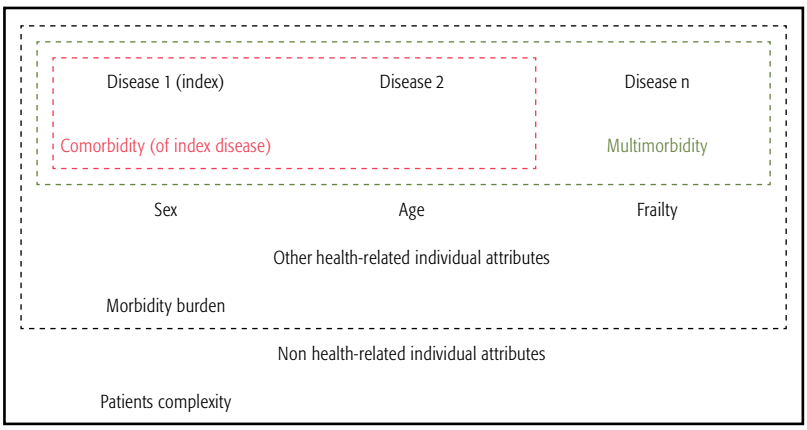

Fig 4.8-6 Comorbidity Construct.

All team members play their role at different phases of the treatment and even in different facilities. But they all must agree on the basic principles of treatment according to the guidelines and they all must feel responsible, in a sense of co-ownership, for the patient. They should know each other well and meet and communicate on a regular basis.

4.3.1 Orthopedic trauma surgeon

- Decides if an older patient requires treatment in a geriatric fracture facility or not according to the type of trauma, age, and relevant comorbidities.
- Starts the multidisciplinary process by contacting the geriatrician and anesthesiologist.
- Initiates the diagnostic workup regarding injuries.
- Takes part in the process of goal setting in cooperation with the geriatrician and anesthesiologist.
- Plans and performs surgery, and should choose the appropriate technique and implant to allow immediate full weight bearing following surgery.
- Cares for anticoagulation management, in cooperation with the geriatrician and the anesthesiologist.
- Cares for pain management, starting immediately after admission and including local anesthesia, enteral and parenteral drug treatment and nonpharmacological measures.
- Plans antibiotic management in the perioperative period.
- Responsible for rehabilitation plans together with a physiotherapist and geriatrician. Range of motion, assisted or active motion, and weight-bearing status need to be determined.
- Active management of wound infection.
- Takes part in the multidisciplinary ward round and team meetings.
- Together with other team members must audit the treatment process and adjust goals as necessary.

4.3.2 Geriatrician or medical leader

- Should be involved as soon as possible, ideally in the emergency department.
- Perform a physical examination, particularly focused on the cardiopulmonary, neurological and renal status. Collects medical history, especially comorbidities and medication. Cognitive function must be assessed using a tool such as the abbreviated mental test score. Basic assessment tools, like the Parker Mobility Score or CAM-Score, should be part of the clinical examination. Indicates further examinations, like laboratory tests, electrocardiography, chest x-ray or consulting other specialists based on this information.
- If surgery is required, the most important task is to identify and treat conditions that require preoperative optimization.
- Arranges preoperative fluid management.
- Must consider the patient's needs and living will. Both are essential aspects in terms of goal setting.
- Postoperatively, the geriatrician is in charge of medical treatment, particularly of the comorbidities.
- The geriatrician has an important role in the prevention and management of delirium.
- Management of medication.
- The geriatrician initiates calcium and vitamin D3 supplementation and considers specific osteoporosis drug treatment for every patient, eg, bisphosphonates.
- Assess risk factors for falls and develop a specific treatment plan to reduce the risk of subsequent falls and fractures.

4.3.3 Anesthesiologist

- Should be involved as soon as possible.
- Involved in acute pain relief in the emergency department, eg, local anesthesic nerve blocks.
- Clears (with the multidisciplinary team) the patient for surgery.
- Determines the type of anesthesia.
- Responsible for the immediate postoperative care of the patient.
- Benefits from cooperation between surgeons and geriatricians.

4.3.4 Orthopedic nurses

- Spend the most time with the patient. Therefore, the nursing staff have a major role in the multiprofessional team and stimulate patients in activities of daily living.
- Assess risk factors for falls, pressure sores and wounds, malnutrition, delirium and infections, manage incontinence and catheters. A specialized orthopedic nurse may be involved in secondary fracture prevention. They choose the appropriate walking aid, counsel their patients and relatives about fall risk factors and osteoporosis.
- Are involved in discharge planning together with families, carers, and social workers.

4.3.5 Physiotherapist

- Should mobilize the patient from bed on the first postoperative day.
- Helps to encourage recovery through mobilization.

- Trains older adult patients to use walking aids in the correct way.
- Helps with breathing therapy to decrease the risk of pulmonary infections.

4.3.6 Occupational therapist

- Trains patient in activities of daily living, the use of walking aids and special devices.
- Evaluates the home circumstances; this may involve a home visit.
- Prescribes tools and aids that help with activities of daily living.
- Should also be involved in the treatment of delirium. They have different options to work with confused patients and to help them to recover earlier from delirium.

4.3.7 Speech therapist

- Provides treatment, support and care for older adult patients who have difficulties with eating, drinking, and swallowing. Swallowing disturbances are more frequent in older adults. An assessment of swallowing should be integrated in the treatment process.

4.3.8 Medical social worker

- Stays in contact with the relatives, nursing homes, and rehabilitation centers.
- Evaluates home environment and social support of the patients.
- Is extremely important in terms of discharge planning.

4.3.9 Dietitian

- Malnutrition is frequent among older adult patients with fragility fractures.

4.3.10 Care coordinator or case manager

- Organizes team meetings and stays in contact with general practitioners (primary care physicians), nursing homes and rehabilitation centers.

4.3.11 Pharmacist

- Polypharmacy is a widespread phenomenon among older adult patients with a fragility fracture.
- Interactions and adverse drug reactions are strongly associated with the number of drugs. A pharmacist helps to reduce the risk of adverse effects caused by medication.

4.3.12 Psychiatrist

- Delirium is a frequent complication. A well-trained orthogeriatric team can care for patients suffering from delirium. However, there are some severe cases of delirium where a psychiatrist should be involved.
- Depression and fear of falling are other frequent symptoms. Older fragility patients often fear losing their autonomy.
- Patients with dementia may develop psychosis that requires expert psychiatric management.

4.3.13 Cardiologist or other specialists

In addition to the core team, other specialists should be involved as indicated. Examples include cardiologists for advice on the management of endovascular stents and anticoagulation and renal physicians when patients receiving long-term dialysis suffer fragility fractures.

4.4 Guidelines and protocols

"A Guide to Improving the Care of Fragility Fractures" [19] and BOA/BGS Blue Book (2nd edition, 2007) [20] may offer guidance. Protocols, checklists and clinical pathways are a practical part of guidelines and professional audit standards are also helpful to improve care.

4.5 Fast-track and urgent surgery

A well-organized "fast-track system" should limit the time in the emergency department to a maximum of 2 hours. Healthcare systems must ensure that sufficient operating room capacity is dedicated to fragility fractures and older adult patients with fractures. Delays to surgery increase health care economic costs and time to surgery has been shown to be an excellent measure of how well comanagement works.

4.6 Lifelong assistance

Several topics should be addressed during an open discussion involving the patient, relatives, home-care nursing, and nursing homes:

- Prescription of walking aids
- Adapting the home environment
- Secondary fracture prevention
- Mobility, exercises, and social integration
- Nutrition

One of the most important and most difficult discussions is about end-of-life care. Although the long-term prognosis for many patients with fragility fracture is good, some groups have a poor prognosis: 90% of patients with dementia who are admitted to a long-term nursing home survive for less than 1 year. It is important that their relatives are aware of this so that appropriate plans and advanced-care directives can be put in place.

5 Principles of medical treatment

5.1 Preoperative optimization

The standard evaluation process follows a predefined and consented pathway. Typical actions are:

- Proper hydration
- Strict hemoglobin, coagulation, and bleeding control
- Strict glucose control
- Correction of hyper and hypotension
- Avoidance of chronic obstructive pulmonary disease exacerbation with bronchodilators
- Management of cardiac dysrhythmias, such as atrial fibrillation
- Warming up in cases of hypothermia
- Monitoring the patients' psychological status to avoid delirium and subsequent complications
- Checking skin condition

5.2 Delay to surgery

The best way to avoid delay to surgery is agreed local guidelines. Regular multidisciplinary meetings are needed to streamline opinions and behaviors.

5.3 Fluid and electrolyte management

Electrolyte imbalance, especially hypokalemia and hyponatremia, are common in the both the preoperative and postoperative periods and reflect the limited reserve of the patients. This situation may worsen with diuretics and inappropriate administration of intravenous fluid and can also cause delirium. Isotonic fluids should be used exclusively and electrolyte management should be monitored regularly and adjusted appropriately.

5.4 Pain management

Adequate pain management enhances mobilization, lowers delirium rates, and may shorten the length of hospital stay. It may also be associated with reduced cardiovascular, renal, respiratory, and gastrointestinal tract morbidity [21]. Early onset of sufficient pain control—ideally at the scene of the injury—is of paramount importance and has been shown to reduce the rate of delirium by 35%.

Pain assessment is much more difficult in older adult patients, especially those suffering from cognitive dysfunction: undertreatment of patients with dementia is well documented.

Nonsteroidal antiinflammatory medications should be avoided because of potential adverse effects like acute kidney injury, worsening of heart failure, or peptic ulcers.

Paracetamol, dihydromorphine, morphine, metamizole, and piritamide are used as first-line therapy intravenously. Opiates must be carefully administered and titrated against response to reduce the risk of respiratory depression. Patients should be switched to oral administration of paracetamol, metamizole or hydromorphone as soon as possible. Opioids should only be used in low dosages, particularly in patients at high risk of delirium. When patients are cachectic or sarcopenic, dosages should be generally reduced. This is also true for patients with impaired renal function.

5.5 Regional anesthesia

There is evidence for adequate pain relief by regional anesthesia using femoral nerve blocks preoperatively [22–24]. Nerve blocks reduce the requirement for opiates and significantly reduce the incidence of pulmonary complications.

5.6 Fracture immobilization

Fractures of the lower extremity should be immobilized preoperatively by positioning the leg in a foam splint or by using pillows [25]. Skeletal or skin traction for fractures of the lower extremity tethers and confuses older adult patients and should only be applied in exceptional cases of neurovascular or soft-tissue problems caused by malalignment. In terms of pain relief, ease or quality of reduction at the time of surgery, no evidence of benefit from traction has been demonstrated [26]. The initial application of skeletal traction was noted as being more painful and costlier.

5.7 Anticoagulation

5.7.1 Clopidogrel (eg, Plavix) and "dual antiplatelet therapy"

- Surgical aspects:
  - The administration of clopidogrel is usually suspended during the perioperative period.
  - Hip fracture surgery should not be delayed for patients taking clopidogrel.
  - Meticulous surgical hemostasis is essential.
- Anesthesiological aspects:
  - Dual antiplatelet therapy with clopidogrel is a contraindication to neuroaxial anesthetic techniques because of the risk of epidural hematoma.
  - The anesthesiologist must be aware of the increased risk of bleeding and potential for blood transfusion.

- Patients who have recently had a coronary artery stent inserted should not have clopidogrel stopped. Consultation with a cardiologist and an individual, multidisciplinary risk-benefit analysis is recommended because of the high risk of life-threatening complications like stent thrombosis.
- If clopidogrel is suspended, regional anesthesia can be performed only after an interval of 7 days during ongoing therapy with aspirin.

5.7.2 Vitamin K antagonists (VKA, coumarins)

- Surgical aspects:
  - Anticoagulation with warfarin (eg, Coumadin), acenocoumarol (eg, Sintrom), and phenprocoumon (eg, Marcumar) should be reversed by vitamin K, until the coagulation parameters are in a subtherapeutic to normal range (INR ≤ 1.8–1.5).
  - Depending on the initial INR, urgency for surgery and actual bleeding risk, 2.5–5 mg and up to 10 mg of vitamin K are administered preferably intravenously. INR should be checked again after 4–6 hours.

5.7.3 Direct oral anticoagulants

- Surgical aspects:
  - The administration of direct oral anticoagulants (DOAC) are usually suspended during the perioperative period.
  - Urgent pre- and perioperative monitoring should include activated partial thromboplastin time for dabigatran, antifactor Xa and prothrombin time for rivaroxiban, as well as rotation thrombelastometry (ROTEM).
- Anesthesiological aspects:
  - If DOACs are suspended neuraxial anesthetic techniques can only be performed after > 24 hours depending on drug, dose and creatinine clearance.
  - Specific antidotes are eg, idarucizumab for reversion of dabigatran and andexanet alfa for reversion of the factor Xa inhibitor activity.
  - In the case of an increased bleeding prothrombin complex concentrate, activated prothrombin complex concentrate, fresh frozen plasma, fibrinogen concentrate, recombined factor VIIa, erythrocytes and thrombocytes are available.

6 Postoperative management

6.1 Dementia and delirium

Many older patients have difficulties being compliant with instructions because of frailty and/or cognitive dysfunction caused by dementia or delirium. Dementia and delirium are common comorbidities in the fragility fracture population.

Dementia is a chronic illness with relentless decline in cognitive status and is ultimately fatal.

Delirium is an acute illness and is potentially reversible, with a state of confusion related to an acute medical condition or disorientation due to a sudden change in environment.

It is important to recognize that patients with dementia may also get delirium with an increase in confusion and sudden decline in cognitive function from an acute medical condition that can be treated. Delirium is much more common in patients who have dementia and up to 60% of patients with a hip fracture have delirium in the perioperative period [27].

Delirium is an independent risk factor for length of hospitalization, an increase in functional impairments, complications, and admission to a nursing home [28]. Delirious patients cannot effectively participate in their rehabilitation following fracture and may be unable to follow instructions. Thus, surgery that allows immediate full-weight bearing is essential.

There are four key features that characterize delirium [28]:

- Disturbance of consciousness with reduced ability to focus, sustain, or shift attention.
- A change in cognition or the development of a perceptual disturbance that is not better accounted for by a preexisting, established, or evolving dementia.
- Disturbance develops over a short period (usually hours to days) and tends to fluctuate during the course of the day.
- There is evidence from the history, physical examination, or laboratory findings that the disturbance is caused by a medical condition, substance intoxication, or medication adverse effects.

The mortality rate is high (up to 30%). Only one-third of patients fully recover from delirium, the other two-thirds retain a decline in cognitive function.

Delirium is always an acute medical emergency. It requires an adequate diagnostic process. The best treatment for delirium is prevention. Guidelines for diagnosis of delirium can be useful when an experienced clinician is not available.

Common causes and risk factors for delirium are:
- Older age
- Brain disorders, eg, dementia, subdural hematoma, Parkinson disease
- Metabolic derangements, eg, hypoglycemia, hyponatremia
- Organ failure, eg, heart failure, renal failure
- Toxic agents, eg, alcohol, prescription medications
- Physical disorders, eg, trauma with systemic inflammatory response system, hypothermia
- Sensory deprivation and impaired perception of the environment, eg, taking away glasses and hearing aids
- Noisy and unfamiliar environment, frequent changes of environment, eg, trips to hospital
- Major fractures, eg, hip fracture
- Triggers like physical restraints, eg, traction, bed grids, splints, urinary catheters, and drains
- Medical complications and polypharmacy, eg, more than three medications
- Malnutrition
- Dehydration and derangement of electrolytes
- Pain
- Anesthesia
- Withdrawal of benzodiazepines or alcohol

6.2 Prevention of delirium

Treatment strategies are less effective than preventative measures.

Prevention is based on the following principles [28]:
- If possible, avoid triggers and worsening factors.
- Identify and treat possible causes.
- Provide optimal early rehabilitation to avoid further physical and cognitive decline.
- Early surgery and proactive geriatric treatment are crucial.

The following steps can be taken in clinical practice:
- Early volume and electrolytes repletion
- Avoid hypoxemia and hypothermia
- Provide sufficient pain therapy
- Review medication; look for inappropriate drugs
- Management of bowel and bladder function
- Adequate nutrition
- Early mobilization
- Minimize use of physical restraints for patient with limited mobility
- Early detection and treatment of postoperative complications
- Environmental modification and nonpharmacological sleep aids for patients with insomnia
- Orientation protocol and cognitive stimulation for patients with cognitive impairment
- Managing disruptive behavior, particularly agitation and combative behavior
- Monitoring high-risk patients with validated scores, like the confusion assessment method
- Therapy for delirium

There is no true treatment for delirium itself although acute medical conditions must be treated appropriately. Symptom control may be necessary to prevent harm or to allow evaluation and treatment. Delirium symptoms are still managed empirically and at this time there is no evidence in the literature to support a change to current practice.

In older hospitalized patients after hip surgery, low-dose haloperidol did not reduce the incidence of delirium but did reduce the severity and duration of episodes [29].

Medication must be reduced or discontinued as soon as possible and should be accompanied by the following measures:
- Protecting patients from falling by low beds, bed rails, alarms and close observation
- Providing contact to relatives

6.3 Blood transfusion management

The individual indication for transfusion of erythrocytes is derived from the hemaglobin (Hb) concentration, compensatory abilities, and risk factors:
- Transfusion is indicated if:
  - Hb ≤ 6 g/dL or 3.7 mmL/L
  - Hb 8–10 g/dL or 5.0–6.2 mmoL/L with signs of anemic hypoxia
- Transfusion is not indicated if:
  - Hb > 10 g/dL or ≥ 6.2 mmoL/L

6.4 Thromboprophylaxis

Venous thromboembolism is one of the leading causes of perioperative mortality in older adult patients with a fracture. Thus, perioperative thromboprophylaxis should be a routine aspect in the care of older adult patients with a fracture.

Commonly, low-molecular-weight heparins are used. Prophylaxis should be initiated either preoperatively or postoperatively, depending on time to surgery and type of anesthesia, eg, neuraxial.

Thromboprophylaxis should be continued at least until the patient is mobile. Some guidelines recommend extended thromboprophylaxis for up to 35 days postoperatively for patients with hip fracture although there is no clear evidence from randomized controlled trials. The risks and benefits for extended thromboprophylaxis should be assessed for each individual patient.

6.5 Malnutrition

The nutritional status should be checked for all patients with fragility fractures on admission. The most common problem is protein deficiency. For malnourished patients with hip fractures, oral supplements are recommended and may reduce unfavorable outcomes [30, 31], and may also influence mortality [32].

The following symptoms help to diagnose poor nutritional status:

- Weight loss: > 5% within 3 months or > 10% within 6 months
- Body mass index < 20 kg/m²
- Albumin level < 3.5 g/dL
- Mini-Nutritional Assessment

Step-by-step approach to treating malnourishment:

- Identify and treat possible causes
- Focus the nursing staff on malnourishment
- Assisting patients with eating
- Dietary supplements
- Parenteral nutrition or feeding tube, if enteral feeding is impossible

Recommendations for older adults:

- Calories: 1,500–2,000 kcal/day
- Protein: 12–14% of overall feed charge (0.9–1.1 g/kg body weight/day)
- Fat: maximum 30% of overall feed charge
- Carbohydrate: minimum 50% of overall feed charge
- Dietary fiber: minimum 30 g/day
- Fluids: 1.5–2 L/day

If malnourishment is identified, liquid dietary supplements should be given early. Oral dietary supplements are known to decrease mortality in older adult patients. In addition, postoperative oral dietary supplements may reduce complications in older adult patients with a hip fracture.

6.6 Rehabilitation

An acute geriatric unit with rehabilitation seems to be the most effective way to reintegrate patients into society following acute treatment in an orthopedic department. A multidisciplinary rehabilitation program improves physical outcomes, quality of life, and daily activities, reduces readmission rates and depression, and may also be associated with fewer falls [33, 34].

6.7 Secondary fracture prevention

Up to 40% of patients with hip fractures have previously suffered another osteoporotic fracture. Yet, undertreatment of osteoporosis is widespread, even among patients with fragility fractures.

A systematic approach, based on the fracture triangle—osteoporosis, falls, and force impact—is useful. All patients suffering a fragility fracture, including vertebral body fractures, should be identified and have access to a dedicated service that evaluates their risk of osteoporosis and gives appropriate advice on lifestyle measures, such as diet and exercise, falls prevention as well as medication if required.

6.7.1 Fall prevention

Each year, one in three people older than 65 years experiences at least one fall. And 9% of the falls result in an emergency department visit and 5–6% cause a fracture. Therefore, fall prevention has become a public health goal.

> Older adults tend to neglect their falls. They are often afraid that their relatives and their physicians will challenge their autonomy.

A previous fall is the strongest predictor for the next fall. Thus, from the clinical aspect, it is important to inquire about falls.

The reasons for falls are multifactorial. A standardized assessment may help to detect different risk factors. A comprehensive falls assessment program is recommended for all patients with falls in their history or fragility fractures, as it represents an essential tool for prevention of subsequent fractures. An excellent review of falls prevention in community-dwelling people was published by Tinetti and Kumar [35]. Common reasons for falls include the home environment, alcohol, medications, poor vision, balance issues, footwear, and cardiovascular problems.

6.7.2 Nonspecific treatment—vitamin D and calcium

All older adult patients with fragility fractures should be suspected of having a low level of vitamin D. Serum 25-hydroxy vitamin D levels below 32 ng/dL are considered insufficient, and below 10 ng/dL are considered deficient.

Vitamin D deficiency is typically accompanied by elevated levels of parathyroid hormone and a low-serum calcium level, ie, secondary hyperparathyroidism.

Fractures may not heal with low vitamin D levels as the body is unable to mineralize the osteoid deposited at the fracture site. Dosage of vitamin D3 for maintenance is 1,200–2,000 IU per day orally.

Calcium should only be consumed with vitamin D for proper absorption. Oral calcium supplementation: 500–1,000 mg/dL daily is recommended.

6.7.3 Specific medication for osteoporosis

Oral bisphosphonates can usually be started immediately after fracture repair. The fracture prevention effects of these medications are not reached until at least 6 months of therapy [36]. Oral bisphosphonates will not interfere with secondary bone healing but may interfere with primary bone healing and bone remodeling as they inhibit osteoclast function, which play a key role in this process.

Compliance with medication is reported to be low after 6 months with oral bisphosphonate therapy. This is due to upper gastrointestinal tract being upset and osteoporosis being an asymptomatic condition. Compliance can be improved with patient follow-up, including telephone calls, to encourage them to continue taking their tablets.

Intravenous treatment should be delayed at least 3 weeks postoperatively to prevent uptake of the drug at the fracture site. Intravenous therapy assures compliance and has an immediate onset of fracture protection but is costly and requires medical personnel to infuse the dose.

Orthopedic surgeons should be familiar with the basics of osteoporosis treatment:

- First choice: oral bisphosphonates, either alendronate or risidronate, from 3 weeks after the fracture. These can be switched to intravenous, eg, zoledronic acid 5 mg once a year.
- If osteoporotic fractures occur after treatment with bisphosphonates, the anabolic hormone teriparatide should be considered.
- Renal failure is the most important contraindication for drug treatment with bisphosphonates and teriparatide. Denosumab 60 mg sc every 6 months is another option. The antiresorptive effect is comparable with bisphosphonates.
- Following a fragility fracture, the diagnosis of osteoporosis and recommendations of how to proceed should be communicated in writing to the patient and primary care physician.

6.7.4 Reduction of the force effect

In the nursing or residential care setting, the use of hip protectors leads to a marginally significant reduction in hip fracture risk. However, the beneficial effect is not constant and lack of compliance remains a problem. For hospitals, nursing homes, or residential homes, a softer floor is an option. This floor surface can reduce the force of a fall by 50%.

7 Anesthesia

The geriatric and anesthetic preoperative assessments have a lot in common and both must work in synergy to speed up time to surgery and to avoid redundancies.

7.1 Risk stratification

Decision making about the type of anesthesia is based on the type and duration of the surgery proposed, preoperative anticoagulation, likelihood of delirium, and feasibility of neuroaxial anesthesia.

If there is a contraindication for spinal anesthesia, progression to general anesthesia is superior to a prolonged wait. In general, the intraoperative mortality risk is low. However, for high-risk cases it is useful for the surgical and anesthetic teams to discuss in advance the response to sudden cardiovascular collapse so that the teams are prepared.

7.2 Neuroaxial anesthesia

- Reduces the risk of delirium, thromboembolic events including fatal pulmonary embolism, myocardial infarction (tendency) and hypoxic complications [37].
- Increases the risk of intraoperative hypotension [38].
- Antiplatelet agents, such as clopidogrel, may interfere with neuroaxial anesthesia.
- Critical aortic stenosis is a contraindication for spinal anesthesia.
- Femoral or supraclavicular nerve blocks provide excellent anesthesia and postsurgical analgesia.
- Regional anesthesia can improve the overall outcome in the right patients and the right situations [37].

7.3 General anesthesia

- Lower incidence of hypotension and a tendency toward fewer cerebrovascular accidents [37].
- Respiratory diseases and general anesthesia are significant predictors of morbidity in patients with hip fracture.
- Sufficient preoperative hydration reduces the risk of hypotension during surgery.
- Chronological age is of lesser importance than is biological age (frailty) as far as the risks for perioperative complications are concerned.

8 Principles of surgical treatment

8.1 Time matters

Most studies recommend performing surgery within the first 24–48 hours of admission, which decreases the number of complications and mortality. Delays longer than 72 hours are associated with an increased risk of multiple complications and mortality risk [14].

The system of care must be optimized to avoid delay and iatrogenic illness. This guiding principle is often violated because of the general condition and compliance of the patient or because patients with fragility fractures are often given lower priority within healthcare organizations.

Keeping the operating time as brief as possible may also reduce the stress of surgery and its physiological burden on the patient.

8.2 Soft-tissue concerns

The musculoskeletal system of older adult patients is more vulnerable and less tolerant to stress of any kind:

- Skin may be thin and less elastic due to atrophy or malnutrition. This makes pressure sores and degloving more common. During positioning and draping, the surgeon must remember that the older adult patient's skin is fragile and can tear or be avulsed with minimal shear stresses. Shear forces during manual traction, removal of surgical drapes and localized pressure from splints and traction devices must be avoided (**Fig 4.8-7**).
- Trophic changes are common in arterial disease, which may result in ischemic changes and poor healing while venous hypertension produces edema, ulcers, and chronic skin changes in the lower legs.

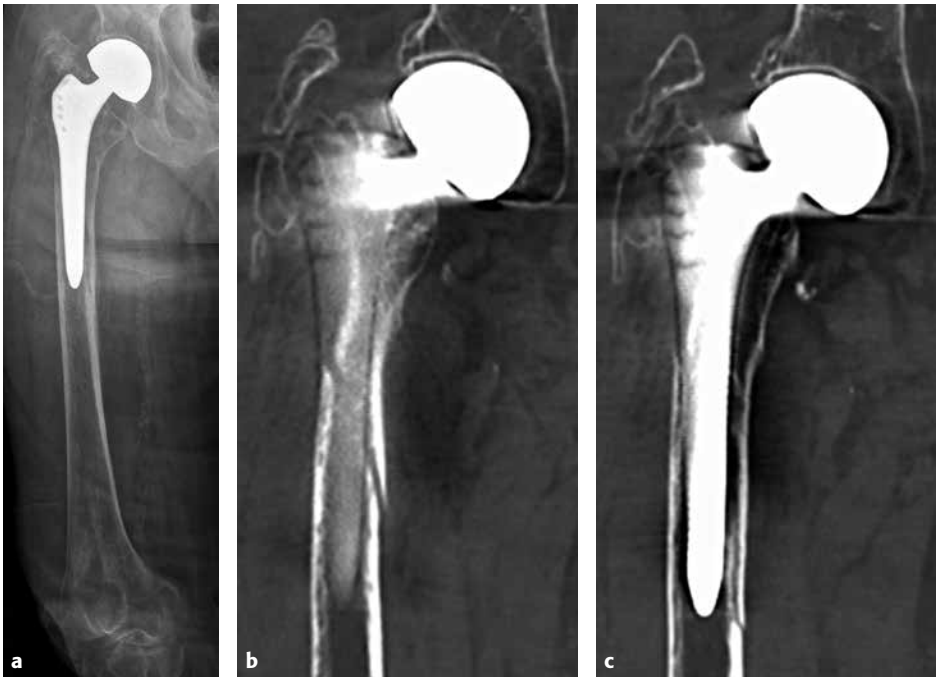

Fig 4.8-7a–i
a–c An 88-year-old woman with type B2 periprosthetic femoral fracture.

Fig 4.8-7a–i (**cont**)
d Revision hemiarthroplasty.
e–g Follow-up x-rays at 2 months.
h After removing the covers, a degloving of the lower leg skin by gentle traction for intraoperative reduction became apparent.
i Uneventful healing after 10 days.

8.3 Bone quality

Bony quality may vary substantially from the typical wide, osteoporotic tube with thin cortices to a thickened but brittle cortex in atypical femoral fractures in patients who have received bisphosphonates. Cortex perforation or bone fragmentation during application of clamps or lag screws is more likely to occur than in normal bone (**Fig 4.8-8**). Forceful reduction maneuvers and aggressive handling of bone may result in extension of the fracture beyond the original pattern. Clamps must be used with caution to avoid iatrogenic damage (**Fig 4.8-9**). Fracture patterns are often complex, with impaction occurring despite low-energy trauma.

8.4 Bone deformation

Bowing of the femur into varus and antecurvatum has a clinical impact in older adult patients with fractures and may make it challenging to use standard intramedullary and extramedullary implants [39]. Increased bowing of the femoral shaft is an important risk factor for fracture [40].

Geriatric bowing of the femoral shaft may be increased under the following conditions:

- Older adults with decreased bone mineralization
- Osteoporosis or osteomalacia may induce genu varum or bowing of the femur

8.5 Atypical femoral fracture

Atypical femoral fractures occur through abnormal bone and typically have thickened cortical bone, a simple transverse pattern and a periosteal reaction (beaking) on the tension side (lateral). They occur in both the subtrochanteric region and the femoral shaft following minimal or no trauma and many patients have prodromal pain for a few weeks before fracture [41]. They are associated with the long-term use of bisphosphonates but the same radiological appearance can occur with sclerotic metastases (usually breast or prostate cancer) and it has also been observed without bisphosphonate use, especially in patients of Asian ethnicities.

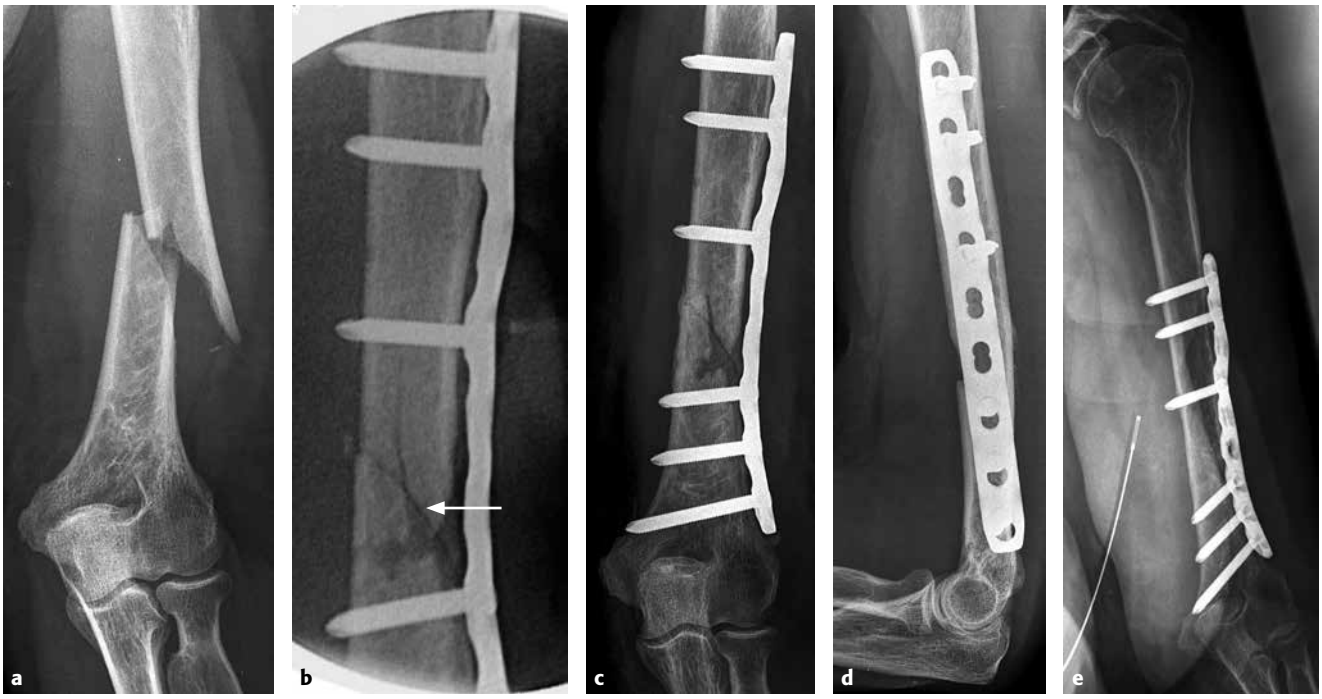

Fig 4.8-8a–e A 76-year-old woman with a simple 2-part fracture of the left humerus (**a**). After anatomical reduction, a 3.5 mm titanium lag screw was used to provide absolute stability (not displayed). After tightening the screw just a bit too much, a multifragmentary situation emerged (arrow) (**b**). The reduction was challenging and a bridging type of construct was chosen. Uneventful healing after 2 months (**c–d**) and 5 months (**e**). The patient did not have osteopenia (T-score L1-L4 0.4 and T-score femoral neck -0.9). DEXA scan describes the deterioration of bone quality only to a certain extent.

8.6 Indications for fixation

Almost all fractures of the femur and displaced fractures of the tibial shaft should be surgically managed. Ambulatory patients may benefit from ankle fracture fixation but nonoperative treatment remains an option [42] and most foot fractures can be managed without surgery in this age group. Most fractures below the knee can also be managed without surgery in nonambulatory patients. In this instance, carefully applied, well-padded splints or casts will suffice.

In the upper extremity, the need to preserve function to help the patient accomplish activities of daily living like eating, self-care, grooming, and ambulation should be considered. Surgical treatment must make a difference in terms of functionality to be indicated. In proximal humeral, olecranon and distal radial fractures, nonsurgical management often leads to acceptable, subjective functional results [43-46].

Nonsurgical management in older adult patients is less well tolerated than in younger individuals. Casts interfere with functionality and increase the risk of falls. Immobilization renders older adult patients dependent for basic activities like eating and grooming. Casts may prevent a patient from accomplishing daily activities and the patient may therefore require placement in a nursing home. Casts and braces tend to exacerbate delirium in this age group. Thus, the surgeon should always consider the option of nonoperative treatment if surgical fixation will not be sufficient to allow immediate full weight bearing without the additional support of a cast or splint.

Complete return to all activities after trauma is the general goal of treatment for those younger than 60 years. This does not apply to patients with fragility fractures. In this age group, the focus is on the restoration of individual functional demands.

8.7 The need for careful single time surgery

Hemiarthroplasty instead of fracture fixation for displaced intracapsular fractures of the hip and other primary joint replacement operations are good examples.

In a small group of bedridden, preterminal patients (6–10%), nonsurgical palliative management of hip and other lower leg fractures may be appropriate. These decisions should be team decisions involving the multidisciplinary team, the patient (if possible), and always the family.

Fig 4.8-9a–e
a A 70-year-old woman with a humeral shaft wedge fracture.
b Open reduction and reduction with multiple clamps.
c More manipulation led to an iatrogenic multifragmentary situation that was difficult to align and fix with a locking plate.
d–e Three-month result with excellent clinical function.

8.8 Weight bearing as tolerated and functional after treatment

Early postoperative mobilization and unrestricted weight bearing as tolerated are important principles for various reasons in this patient group. Prolonged bed rest or "sitting mobilization" are not good options. The daily loss of muscle mass while staying in bed is dramatic. Current surgical procedures and implants permit immediate unrestricted weight bearing. Reasons for immediate weight bearing include:

- Loss of muscle mass
- Restriction of weight bearing inflicts a significant physiological burden on older adult patients. The energy expenditure for ambulation without full weight bearing increases fourfold and leads to rapid exhaustion [47].
- Patients with fragility fractures are often physically unable to perform partial weight bearing due to sarcopenia, lack of proprioception, and weakness in the arms.
- Dementia and delirium make many patients noncompliant.
- Partial weight-bearing protocols are not evidence based.
- Pain, even when taking analgesia, will guide a patient to use the appropriate amount of load and safe progression with ambulation.
- Early weight bearing can promote fracture healing and union of the fracture without increasing loss of fixation [48, 49].

8.9 Fixation techniques

The major technical problem the surgeon faces is the difficulty in securing fixation of the implant to the osteoporotic bone. Bone mineral density correlates linearly with the holding power of screws. If the load transmitted at the bone-implant interface exceeds the strain tolerance of osteoporotic bone, microfracture and resorption of bone with loosening of the implant and secondary failure of fixation will occur. The common mode of failure of internal fixation in osteoporotic bone is bone failure rather than implant breakage.

The principles of fracture management are applicable to most fragility fractures, but the decrease in bone strength requires some adaptions to decrease the risk of failure.

Important techniques include:

- Relative stability, including bridging and buttress fixation
- Angular stability
- Intramedullary nails
- Controlled bone impaction
- Bone augmentation
- Joint replacement

8.9.1 Positioning

It is essential to carefully position the patient on the surgical table. Avoidance of pressure sores is of importance as sores significantly interfere with recovery. In most cases, the supine position is preferred in the elderly to allow for overall care by the anesthetist. When under regional anesthesia, the patient can breathe easier when supine.

8.9.2 Minimal invasive surgery

The main advantages of minimal invasive surgery techniques, including reduced soft-tissue dissection and less bleeding, apply even more in older adult patients.

8.9.3 Relative stability

In osteoporotic bone, it may not always be possible to obtain and maintain anatomical reduction and compression with absolute stability because the weakened cortical and cancellous bone may fail under compression.

As a simple rule, intramedullary devices should be preferred to extramedullary ones if fracture morphology and soft tissues allow this option.

Short plates with every screw hole filled will cause concentration of forces, which may exceed the strain tolerance of osteoporotic bone. Osteoporosis demands basic rules for the safe use of internal fixation [50, 51]:

- Simple transverse fractures are best addressed by intramedullary implants. If this is not possible, the fracture gap must be closed as much as possible. If plates are used, compression should be obtained with the plate and three to four holes should be left free and three to four bicortical locking head screws in each main fragment are needed after compression is obtained.
- Spiral 2-part fractures should be reduced as much as possible and preliminarily fixed with suture or cerclage wire or cables with minimal soft-tissue stripping. If screws are used, they should be tightened with caution as "reduction screws". The first plate screw should be inserted at the end of the fracture line. Again three to four bicortical locking head screws in each main fragment are necessary (**Fig 4.8-10**).
- Multifragmentary fractures require the first screws to be placed adjacent to the fracture zone. Long plates are used with four bicortical screws in each main fragment.

Fig 4.8-10a–f A 77-year-old woman with a pertrochanteric fracture (**a**). Fixation with a proximal femoral nail antirotation (**b**). The nail was removed 1.5 years later because of lateral thigh pain. Three years later, she sustained a spiral diaphyseal fracture (**c–d**). Minimally invasive reduction in lateral position and preliminary fixation with suture wire was performed. Definitive fixation with relative stability and distal femoral plate was performed, with the first proximal screw starting at the end of the fracture. Uneventful healing with a little callus formation (**e–f**). Ideally, a longer plate to protect the whole femur could have been used. A reasonable alternative was a long cephalomedullary nail.

8.9.4 Splinting the whole bone

Subsequent fractures adjacent to the end of plates, nails or prosthesis occur due to the stress riser between the stiff implant and the osteoporotic bone. If possible, the whole bone should be protected with the first fixation including the femoral neck in femoral diaphysis and periprosthetic fractures (**Fig 4.8-11**).

8.9.5 Implants

Locking implants (fixed or variable angle) as well as angular stable locking options for intramedullary nails all have biomechanically proven superior stability in bone with reduced cortical thickness.

Locking head screws cannot be overtightened and rendered unstable (because the thread gets destroyed). They should always be used in a bicortical mode because of the reduced working length with a single thin cortex.

These screws also have a larger core diameter than conventional screws, which results in higher pullout strength and overall strength. This is especially helpful in metaphyseal bone, where intramedullary nails may fail. The holding power of the locking head screws can further be increased by orienting them in different directions. This method is used with PHILOS, the screw-in-screw concept of the Multilock nail for the proximal humerus, and the anatomical distal femur and proximal tibia LCPs.

A blade for fixation of pertrochanteric fractures or distal femoral fixation is more stable than a screw. Inserting a blade condenses the bone around the implant while screw insertion always produces some bone loss.

Fig 4.8-11a–c A 92-year-old woman with a periprosthetic fracture (**a**). Open reduction and fixation with cerclage wires and revision arthroplasty with a long-stemmed implant with locking options was performed. The distal femoral plate protects the bone between the two prostheses (**b–c**).

8.9.6 Alignment

Correct anatomical alignment represents an important prerequisite for uneventful bone healing. Fixation of osteoporotic bones is less tolerant of any deviation than younger bone. Specifically, varus malalignment should always be avoided in femoral and tibial fractures.

8.9.7 Impaction

Bone impaction is a key element in the surgical management of osteoporotic fractures as it reduces the risk of implant failure. In many cases impaction is created by the trauma itself, eg, the valgus impacted fracture of the femoral neck. Controlled impaction can be attained by tensioning internal fixation devices. Implants, such as the dynamic hip screw, allow controlled impaction of the fracture while preventing penetration of the joint by the hip screw.

8.9.8 Augmentation with bone cement

Fixation in osteoporotic bone can be improved by augmenting the bone with a substitute. Augmented purchase of screws prevents hardware migration, cut out, cut through and pull out. It can also be used to support the bone structure and prevent it from collapsing, eg, vertebral body or tibial plateau fracture.

Polymethylmethacrylate bone cement still seems to be the material of choice and is used to fill voids that mainly result after reduction of fractures through cancellous bone that was impacted by the trauma. A typical example is vertebral body compression fractures treated after closed reduction with vertebroplasty. The same principle is applied around proximal tibial fractures and prevents them from collapsing.

In standardized implant augmentation, the cement is typically injected with specific cannula through perforated implants to improve the bone-implant interface by preventing high bone strain and distributing the force transmission to the bone in a load-sharing rather than load-bearing configuration (**Fig 4.8-12**). In nonstandardized implant augmentation, the cement is applied via the screw hole before the implant is inserted.

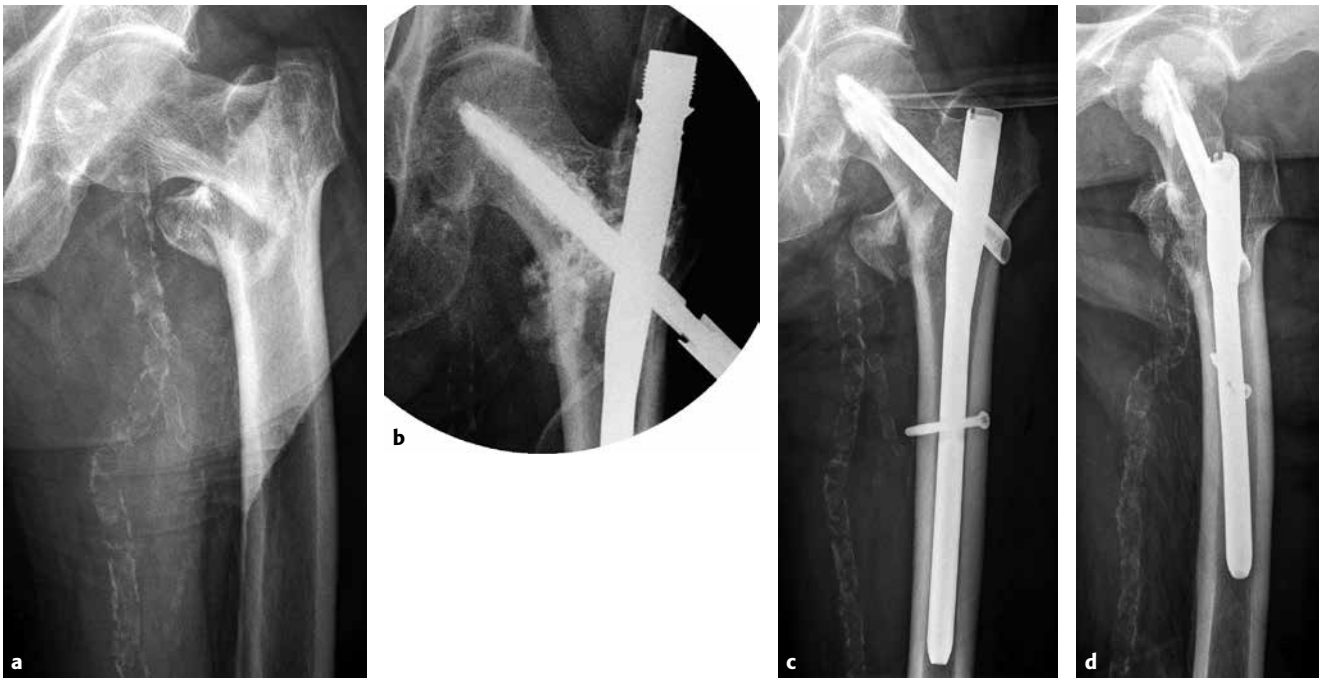

Fig 4.8-12a–d An 82-year-old man with a proximal femoral fracture (**a**). Closed reduction with a traction table was performed. After insertion of nail and blade, the decision was taken to augment the blade because of severe osteoporosis and very low resistance while inserting the blade. An intraoperative contrast dye test demonstrated no arthrogram, ie, no perforation into the hip joint (**b**). Polymethylmethacrylate (4 cc) was injected through a special cannula. Result after mobilization with center-center position of the head-neck-element and equally distributed cement (**c–d**).

Autografts

Cortical-cancellous bone autografts to assist fracture healing and to fill gaps can also be harvested in older adult patients, but because of osteoporosis they may have limited mechanical properties and there may be limited amounts of bone at the donor sites. Unless they are used to fill voids, grafts should be fixed to the bone with cortical screws or cables. As well, adjuncts such as bone cement can be used (**Fig 4.8-13**).

Allografts

Allograft bone has good mechanical properties but less osteogenic potential. In osteoporotic conditions, allografts are used to fill metaphyseal voids and prevent articular and other fragments from displacing. This can be helpful in fractures of the proximal and distal humerus, distal radius, and proximal tibia.

Strut allografts are also used in periprosthetic femoral fractures with poor bone quality to enhance the mechanical strength of the construct (**Fig 4.8-14**).

Joint replacement

Joint replacement (total or hemi) plays an important role in older adult patients. It is commonly used in the proximal femur, mainly with femoral neck fractures. The indication for replacement arthroplasty is not so clear in proximal humeral fractures. Studies of C3 fractures of the distal humerus show that a total elbow replacement is superior to open reduction and internal fixation in terms of functional results but there are no long-term (5-year plus) follow-up studies available yet. There are not yet enough comparative studies to give general recommendations in all periarticular areas.

9 Outcome

9.1 Bone healing

Fracture healing in osteoporotic bone comprises the normal stages and concludes with fracture union. However, the healing process may be prolonged and it seems obvious that there are differences in fracture healing in older age groups. Even though delayed fracture healing is not apparent in patients, the decreased healing capacity in osteoporosis may be reflected by an increased failure rate of implant fixation. Fracture healing is believed to require the migration of mesenchymal stem cells into the fracture callus. Mesenchymal stem cells from osteoporotic individuals may be fewer in number and have a lower proliferative response [52]. The number of stem cells is reduced in older adult patients, which might explain the age-related decrease in the number of osteoblasts. Bone cells from patients with osteoporosis may also be impaired in their long-term response to mechanical stress [53]. The periosteum itself is also less responsive with aging.

9.2 Mortality

After a hip fracture, mortality rates range from 12% to 35% in the first year, and is higher in men than in women. Mortality rates increase with age, the number of comorbidities, and low prefracture mental and physical function. Low bone mineral density is also a risk factor.

9.3 Orthogeriatric care

Comparison of a comprehensive medical and nursing approach to older adult patients with fracture against usual orthopedic care revealed dramatic improvements in time to surgery, length of hospital stay, readmission rates, and numerous complications. Rates of delirium are reduced, as are bleeding complications and infection rates. This approach seems to offer many benefits to patients and healthcare systems [54].

In a recent systematic review and metaanalysis based on 18 studies, Grigoryan et al [55] aimed to determine if orthogeriatric collaboration models improve outcomes. The overall metaanalysis found orthogeriatric collaboration was associated with a significant reduction of in-hospital mortality and long-term mortality. Length of stay was significantly reduced, particularly in the shared care model.

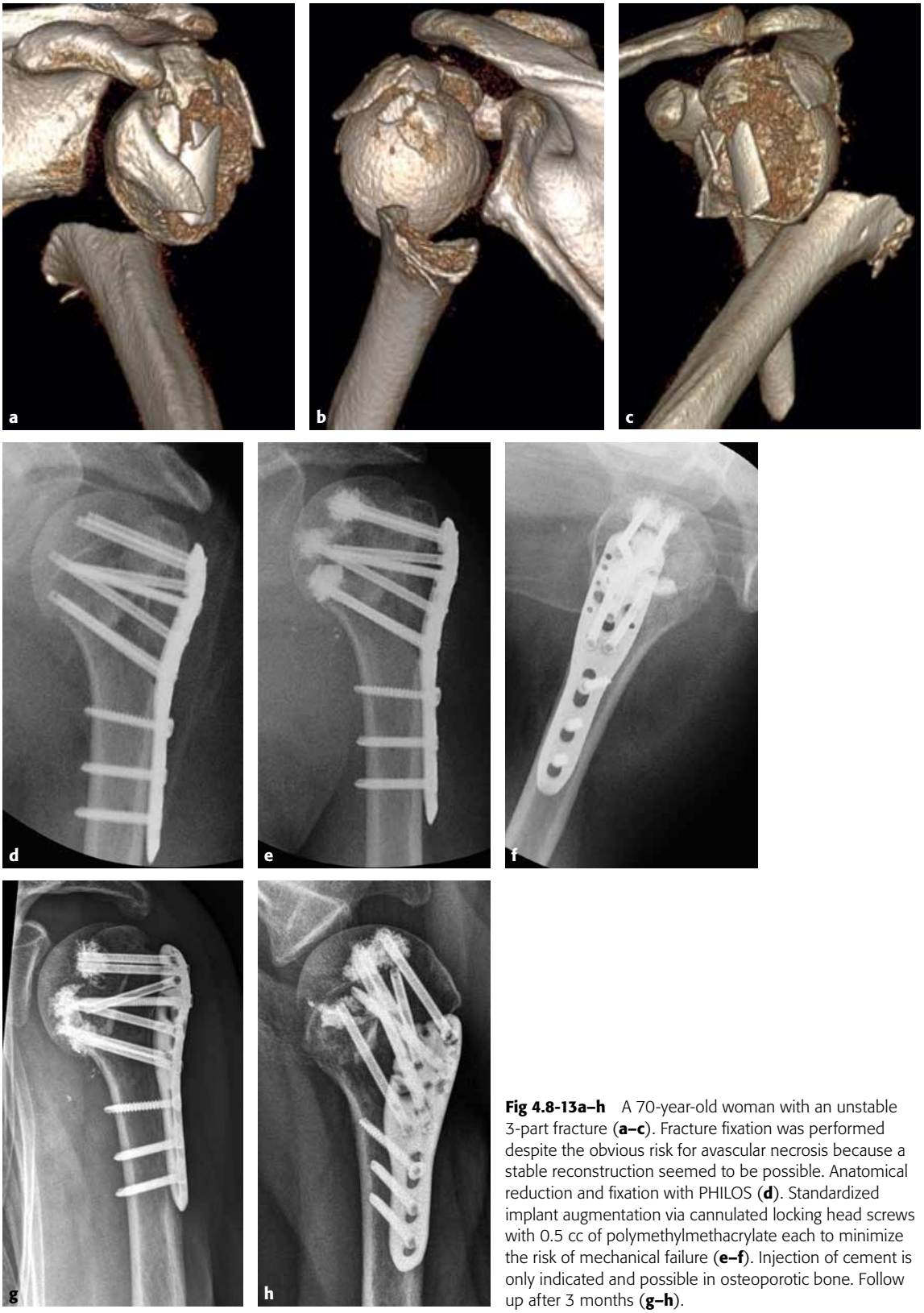

Fig 4.8-13a–h A 70-year-old woman with an unstable 3-part fracture (**a–c**). Fracture fixation was performed despite the obvious risk for avascular necrosis because a stable reconstruction seemed to be possible. Anatomical reduction and fixation with PHILOS (**d**). Standardized implant augmentation via cannulated locking head screws with 0.5 cc of polymethylmethacrylate each to minimize the risk of mechanical failure (**e–f**). Injection of cement is only indicated and possible in osteoporotic bone. Follow up after 3 months (**g–h**).

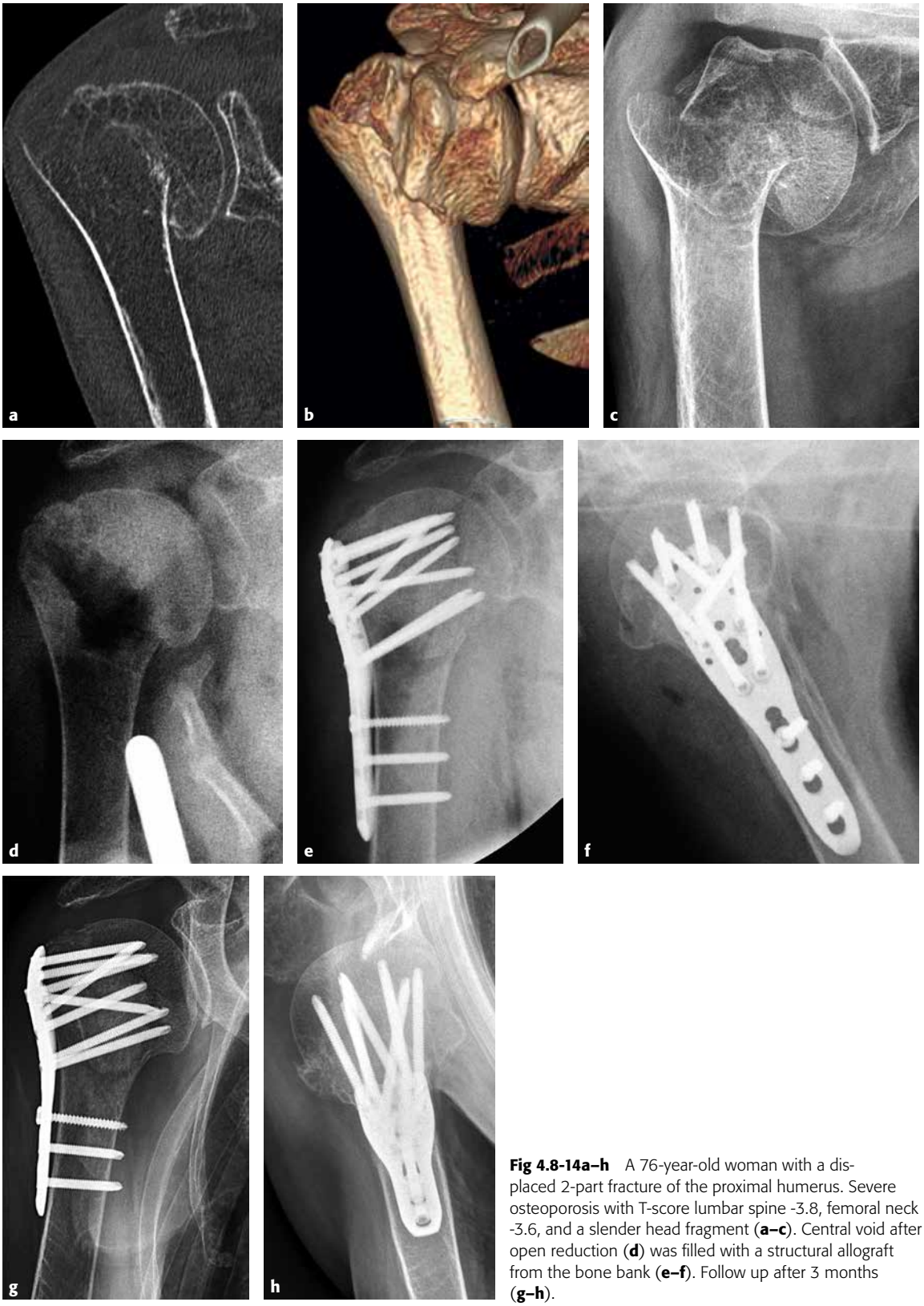

Fig 4.8-14a–h A 76-year-old woman with a displaced 2-part fracture of the proximal humerus. Severe osteoporosis with T-score lumbar spine -3.8, femoral neck -3.6, and a slender head fragment (**a–c**). Central void after open reduction (**d**) was filled with a structural allograft from the bone bank (**e–f**). Follow up after 3 months (**g–h**).

Classic references | Review references

10 References

1. **Brown JP, Josse RG, Scientific Advisory Council of the Osteoporosis Society of Canada.** 2002 clinical practice guidelines for the diagnosis and management of osteoporosis in Canada. *CMAJ.* 2002 Nov 12;167(10 Suppl):S1–34.
2. **Seeley DG, Browner WS, Nevitt MC, et al.** Which fractures are associated with low appendicular bone mass in elderly women? The Study of Osteoporotic Fractures Research Group. *Ann Intern Med.* 1991 Dec 1;115(11):837–842.
3. **Johnell O, Kanis J.** Epidemiology of osteoporotic fractures. *Osteoporos Int.* 2005 Mar;16 Suppl 2:S3–7.
4. **Klotzbuecher CM, Ross PD, Landsman PB, et al.** Patients with prior fractures have an increased risk of future fractures: a summary of the literature and statistical synthesis. *J Bone Miner Res.* 2000 Apr;15(4):721–739.
5. **Cooper C, Campion G, Melton LJ, 3rd.** Hip fractures in the elderly: a world-wide projection. *Osteoporos Int.* 1992 Nov;2(6):285–289.
6. **Hernlund E, Svedbom A, Ivergard M, et al.** Osteoporosis in the European Union: medical management, epidemiology and economic burden. A report prepared in collaboration with the International Osteoporosis Foundation (IOF) and the European Federation of Pharmaceutical Industry Associations (EFPIA). *Arch Osteoporos.* 2013;8:136.
7. **De Laet CE, Pols HA.** Fractures in the elderly: epidemiology and demography. *Baillieres Best Pract Res Clin Endocrinol Metab.* 2000 Jun;14(2):171–179.
8. **Kanis JA, Oden A, McCloskey EV, et al.** A systematic review of hip fracture incidence and probability of fracture worldwide. *Osteoporos Int.* 2012 Sep;23(9):2239–2256.
9. **Kanis JA, Johnell O, Oden A, et al.** The risk and burden of vertebral fractures in Sweden. *Osteoporos Int.* 2004 Jan;15(1):20–26.
10. **Owen RA, Melton LJ, 3rd, Johnson KA, et al.** Incidence of Colles' fracture in a North American community. *Am J Public Health.* 1982 Jun;72(6):605–607.
11. **Dimai HP, Svedbom A, Fahrleitner-Pammer A, et al.** Epidemiology of proximal humeral fractures in Austria between 1989 and 2008. *Osteoporos Int.* 2013 Sep;24(9):2413–2421.
12. **Meldon SW, Reilly M, Drew BL, et al.** Trauma in the very elderly: a community-based study of outcomes at trauma and nontrauma centers. *J Trauma.* 2002 Jan;52(1):79–84.
13. **Switzer JA, Gammon SR.** High-energy skeletal trauma in the elderly. *J Bone Joint Surg Am.* 2012 Dec 5;94(23):2195–2204.
14. **Lewis PM, Waddell JP.** When is the ideal time to operate on a patient with a fracture of the hip? : A review of the available literature. *Bone Joint J.* 2016 Dec;98-b(12):1573–1581.
15. **Xue QL.** The frailty syndrome: definition and natural history. *Clin Geriatr Med.* 2011 Feb;27(1):1–15.
16. **Morley JE.** Sarcopenia: diagnosis and treatment. *J Nutr Health Aging.* 2008 Aug-Sep;12(7):452–456.
17. **Wall BT, Dirks ML, van Loon LJ.** Skeletal muscle atrophy during short-term disuse: implications for age-related sarcopenia. *Ageing Res Rev.* 2013 Sep;12(4):898–906.
18. **Valderas JM, Starfield B, Sibbald B, et al.** Defining comorbidity: implications for understanding health and health services. *Ann Fam Med.* 2009 Jul-Aug;7(4):357–363.
19. **Mears SC, Kates SL.** A Guide to Improving the Care of Patients with Fragility Fractures, Edition 2. *Geriatr Orthop Surg Rehabil.* 2015 Jun;6(2):58–120.
20. **British Orthopaedic Association Standards for Trauma 1.** Patients sustaining a fragility hip fracture. Available at: https://www.boa.ac.uk/publications/boa-standards-trauma-boasts/#toggle-id-1. Access May 24, 2017.
21. **Liu SS, Wu CL.** The effect of analgesic technique on postoperative patient-reported outcomes including analgesia: a systematic review. *Anesth Analg.* 2007 Sep;105(3):789–808.
22. **Parker MJ, Griffiths R, Appadu BN.** Nerve blocks (subcostal, lateral cutaneous, femoral, triple, psoas) for hip fractures. *Cochrane Database Syst Rev.* 2002 (1):CD001159.
23. **Marhofer P, Greher M, Kapral S.** Ultrasound guidance in regional anaesthesia. *Br J Anaesth.* 2005 Jan;94(1):7–17.
24. **Luger TJ, Kammerlander C, Benz M, et al.** Peridural anesthesia or ultrasound-guided continuous 3-in-1 block: which is indicated for analgesia in very elderly patients with hip fracture in the emergency department? *Geriatr Orthop Surg Rehabil.* 2012 Sep;3(3):121–128.
25. **Rosen JE, Chen FS, Hiebert R, et al.** Efficacy of preoperative skin traction in hip fracture patients: a prospective, randomized study. *Orthop Trauma.* 2001;15(2):81–85.
26. **Parker MJ, Handoll HH.** Pre-operative traction for fractures of the proximal femur in adults. *Cochrane Database Syst Rev.* 2006 (3):CD000168.
27. **Robertson BD, Robertson TJ.** Postoperative delirium after hip fracture. *J Bone Joint Surg Am.* 2006 Sep;88(9):2060–2068.
28. **Inouye SK.** Prevention of delirium in hospitalized older patients: risk factors and targeted intervention strategies. *Ann Med.* 2000 May;32(4):257–263.
29. **Kalisvaart KJ, de Jonghe JF, Bogaards MJ, et al.** Haloperidol prophylaxis for elderly hip-surgery patients at risk for delirium: a randomized placebo-controlled study. *J Am Geriatr Soc.* 2005 Oct;53(10):1658–1666.
30. **Avenell A, Handoll HH.** Nutritional supplementation for hip fracture aftercare in older people. *Cochrane Database Syst Rev.* 2006 (4):CD001880.
31. **Eneroth M, Olsson UB, Thorngren KG.** Nutritional supplementation decreases hip fracture-related complications. *Clin Orthop Relat Res.* 2006 Oct;451:212–217.
32. **Duncan DG, Beck SJ, Hood K, et al.** Using dietetic assistants to improve the outcome of hip fracture: a randomised controlled trial of nutritional support in an acute trauma ward. *Age Ageing.* 2006 Mar;35(2):148–153.
33. **Shyu YI, Liang J, Wu CC, et al.** Interdisciplinary intervention for hip fracture in older Taiwanese: benefits last for 1 year. *J Gerontol A Biol Sci Med Sci.* 2008 Jan;63(1):92–97.
34. **Huusko TM, Karppi P, Avikainen V, et al.** Intensive geriatric rehabilitation of hip fracture patients: a randomized, controlled trial. *Acta Orthop Scand.* 2002 Aug;73(4):425–431.
35. **Tinetti ME, Kumar C.** The patient who falls: "It's always a trade-off". *JAMA.* 2010 Jan 20;303(3):258–266.
36. **Eriksen EF, Lyles KW, Colon-Emeric CS, et al.** Antifracture efficacy and reduction of mortality in relation to timing of the first dose of zoledronic acid after hip fracture. *J Bone Miner Res.* 2009 Jul;24(7):1308–1313.
37. **Luger TJ, Kammerlander C, Gosch M, et al.** Neuroaxial versus general anaesthesia in geriatric patients for hip fracture surgery: does it matter? *Osteoporos Int.* 2010 Dec;21(Suppl 4):S555–572.
38. **O'Hara DA, Duff A, Berlin JA, et al.** The effect of anesthetic technique on postoperative outcomes in hip fracture repair. *Anesthesiology.* 2000 Apr;92(4):947–957.

39. **Hwang JH, Oh JK, Oh CW, et al.** Mismatch of anatomically pre-shaped locking plate on Asian femurs could lead to malalignment in the minimally invasive plating of distal femoral fractures: a cadaveric study. *Arch Orthop Trauma Surg.* 2012 Jan;132(1):51–56.
40. **Sasaki S, Miyakoshi N, Hongo M, et al.** Low-energy diaphyseal femoral fractures associated with bisphosphonate use and severe curved femur: a case series. *J Bone Miner Metab.* 2012 Sep;30(5):561–567.
41. **Thompson RN, Phillips JR, McCauley SH, et al.** Atypical femoral fractures and bisphosphonate treatment: experience in two large United Kingdom teaching hospitals. *J Bone Joint Surg Br.* 2012 Mar;94(3):385–390.
42. **Willett K, Keene DJ, Mistry D, et al.** Close contact casting vs surgery for initial treatment of unstable ankle fractures in older adults: a randomized clinical trial. *JAMA.* 2016 Oct 11;316(14):1455–1463.
43. **Duckworth AD, Bugler KE, Clement ND, et al.** Nonoperative management of displaced olecranon fractures in low-demand elderly patients. *J Bone Joint Surg Am.* 2014 Jan 1;96(1):67–72.
44. **Arora R, Lutz M, Deml C, et al.** A prospective randomized trial comparing nonoperative treatment with volar locking plate fixation for displaced and unstable distal radial fractures in patients sixty-five years of age and older. *J Bone Joint Surg Am.* 2011 Dec 7;93(23):2146–2153.
45. **Twiss T.** Nonoperative treatment of proximal humerus fractures. In: Crosby LA, Nevasier, RJ eds. *Proximal Humerus Fractures.* Cham, Switzerland: Springer International Publishing; 2015.
46. **Rangan A, Handoll H, Brealey S, et al.** Surgical vs nonsurgical treatment of adults with displaced fractures of the proximal humerus: the PROFHER randomized clinical trial. *JAMA.* 2015 Mar 10;313(10):1037–1047.
47. **Westerman RW, Hull P, Hendry RG, et al.** The physiological cost of restricted weight bearing. *Injury.* 2008 Jul;39(7):725–727.
48. **Koval KJ, Sala DA, Kummer FJ, et al.** Postoperative weight-bearing after a fracture of the femoral neck or an intertrochanteric fracture. *J Bone Joint Surg Am.* 1998 Mar;80(3):352–356.
49. **Joslin CC, Eastaugh-Waring SJ, Hardy JR, et al.** Weight bearing after tibial fracture as a guide to healing. *Clin Biomech (Bristol, Avon).* 2008 Mar;23(3):329–333.
50. **Stoffel K, Dieter U, Stachowiak G, et al.** Biomechanical testing of the LCP—how can stability in locked internal fixators be controlled? *Injury.* 2003 Nov;34 Suppl 2:B11–19.
51. **Fulkerson E, Egol KA, Kubiak EN, et al.** Fixation of diaphyseal fractures with a segmental defect: a biomechanical comparison of locked and conventional plating techniques. *J Trauma.* 2006 Apr;60(4):830–835.
52. **Bergman RJ, Gazit D, Kahn AJ, et al.** Age-related changes in osteogenic stem cells in mice. *J Bone Miner Res.* 1996 May;11(5):568–577.
53. **Sterck JG, Klein-Nulend J, Lips P, et al.** Response of normal and osteoporotic human bone cells to mechanical stress in vitro. *Am J Physiol.* 1998 Jun;274(6 Pt 1):E1113–1120.
54. **Friedman SM, Mendelson DA, Kates SL, et al.** Geriatric co-management of proximal femur fractures: total quality management and protocol-driven care result in better outcomes for a frail patient population. *J Am Geriatr Soc.* 2008 Jul;56(7):1349–1356.
55. **Grigoryan KV, Javedan H, Rudolph JL.** Orthogeriatric care models and outcomes in hip fracture patients: a systematic review and meta-analysis. *J Orthop Trauma.* 2014 Mar;28(3):e49–55.

11 Acknowledgments

We thank Norbert Suhm, Tobias Roth, and Chang-Wug Oh for their contributions to the third edition and Peter Giannoudis and Erich Schneider for their contributions to the second edition of the *AO Principles of Fracture Management.*

4.9 Imaging and radiation hazards

Chanakarn Phornphutkul

1 Introduction

X-rays are an essential part of the evaluation of a trauma patient and further investigations, such as ultrasound, computed tomography (CT) and magnetic resonance imaging (MRI), help with accurate diagnosis and the planning of appropriate management. Whole body (trauma) CT (WBCT) used early in the investigation of the polytrauma patient allows rapid diagnosis of life-threatening injuries. However, there must be clear indications for its use because it significantly increases the dose of radiation [1]. The use of intraoperative image intensifiers puts the patient, the surgeon, and the surgical team at risk of radiation exposure [2]. The amount of radiation used has increased dramatically over the last few years with the advent of minimally invasive surgery. Intraoperative imaging provides visualization for the treating surgeon to perform accurate approaches for fracture reduction and fixation.

The risk and effects of radiation exposure are well recognized by the orthopedic community as almost half of respondents in one study [3] perceived themselves to be at either moderate or extreme risk for cataract formation due to occupational exposure. Distal radius surgery also poses problems when the surgeon's hands are often exposed to radiation [4]. Understanding both the benefits and hazards of radiation, it is necessary that surgical teams are able to set up image intensifiers, apply proper technique, and shield themselves to avoid unnecessary and dangerous exposure.

2 Role of imaging in operative fracture treatment

The main purpose of intraoperative imaging is to confirm fracture reduction, correct implant placement, and fixation. Extensive open reduction is now used less often, while indirect reduction, without exposure of the fracture and with biological preservation of soft tissues, is now more common. However, these techniques require more extensive radiological imaging during surgery. The image intensifier is an indispensable part of surgical equipment, but today the patient, the surgeon, and the surgical team are at greater risk of radiation exposure (**Table 4.9-1**) [5].

New image intensifiers produce small doses of radiation compared with older models, but inappropriate, prolonged, and repetitive use will lead to greater cumulative radiation exposure for individuals.

3 Hazards of radiation exposure

Ionizing radiation is produced from the decay of radioactive materials. This radiation breaks chemical bonds between atoms, which damages living cells in the human body. The body attempts to repair the damage but sometimes the damage cannot be repaired or is too severe or widespread to be repaired.

	K-wire distal radius	Intramedullary nail	External fixator lumbar spine
	Average radiation dose µSv (1/1,000 mSv)		
Eye	1.1 µSv	19.0 µSv	49.8 µSv
Thyroid	1.1 µSv	35.4 µSv	55.5 µSv
Hand	3.1 µSv	41.7 µSv	117.0 µSv
Gonads	–	–	–

Table 4.9-1 Exposure to radiation during orthopedic procedures. The normal yearly exposure to background radiation is 1–3 mSv per year.

3.1 Radiation effects

There are two types of deleterious radiation effects: nonstochastic and stochastic [6].

- Nonstochastic effects are dose related and the effects will not occur below a certain threshold and the severity depends on the dose. Deterministic effects require injury to multiple cells and have a threshold dose, below which the effect is not expressed. Cataracts, leukemia, thyroid cancer, and even death are examples of the nonstochastic effects that can result from high radiation exposures [7].
- Stochastic effects are not dose or threshold related; injury to any single or number of cells may result in production of the effect. Some radiation-induced cancer and genetic effects are stochastic. For example, the probability of radiation-induced leukemia is substantially higher after exposure to 1 Gy (100 rad) but this disease can occur at lower doses. Once the disease occurs, there will be no difference in the severity. Stochastic effects are believed to lack a threshold dose because injury to even a single cell could theoretically result in production of the effect. Since there is no evidence of a lower threshold for the appearance of stochastic effects, the prudent course of action is to ensure that all radiation exposures follow the principle "As Low As Reasonably Achievable" (ALARA).

3.2 Radiosensitivity

The risk of stochastic effects is higher in children compared with adults. This happens because immature cells are more radiosensitive. Studies [8, 9] have also concluded that there is a linear dose relationship between ionizing radiation exposure and the development of radiation-induced cancers. In children, the cumulative effect has a longer time span in which these late effects can develop, and also a longer time span to accumulate further exposures [8–10].

Pregnant patients also need special consideration. If exposed to radiation in the first 30 weeks of pregnancy, delayed effects may appear in the child. These include mental and behavioral retardation, with a delay period of approximately 4 years. If any procedure is required for pregnant patients, surgeons might consider some form of treatment that has less radiation exposure. For example, open reduction and internal fixation may be used rather than minimally invasive osteosynthesis (MIO) to minimize the risk to the fetus (**Table 4.9-2**).

Annual occupational radiation exposure limits (levels below are believed to have negligible risk of biological effects)	
Whole body	50 mSv = 5,000 mrem/yr
Lens of the eye	150 mSv = 15,000 mrem/yr
Thyroid	300 mSv = 30,000 mrem/yr
Extremities, skin	500 mSv = 50,000 mrem/yr

Annual radiation exposure for a human on earth:	1–3 mSv
One whole body CT scan	30 mSv
One whole body CT scan	50 chest x-rays (0.02 mSv)
One transatlantic flight	0.05 mSv/10-hour flight (2 chest x-rays)

Table 4.9-2 Baseline information for understanding radiation equivalents. Skin dose expressed in Grays (1 Gy = 1 Joule/kg) – Gy relates to deterministic effects (1 Gy = 1,000 mGy = 100 rads [traditional units]). Whole body dose expressed in Sievert (1 Sv = 1 Joule/kg) – Sv relates to stochastic effects cancer (1 Sv = 1,000 mSv = 100 rems, traditional units).

4 Mobile imaging intensifier or C-arm

4.1 The machine, x-ray source, and image intensifier

This C-shaped machine is composed of two ends. One end is the x-ray tube and collimation screen and the other is the photo receiver array (image intensifier). The x-ray tube produces radiation, which passes through the target reaching the image intensifier. The image is created and sent to the screen for visualization (**Fig 4.9-1**). The radiation that is produced by the x-ray tube will pass through the target. Some radiation passes through the target and reaches the image intensifier and some will be reflected and scattered. The rest of the radiation is absorbed by the target (**Fig 4.9-2**). The scattered portion is the radiation dose that may affect the surgeon and the operating team.

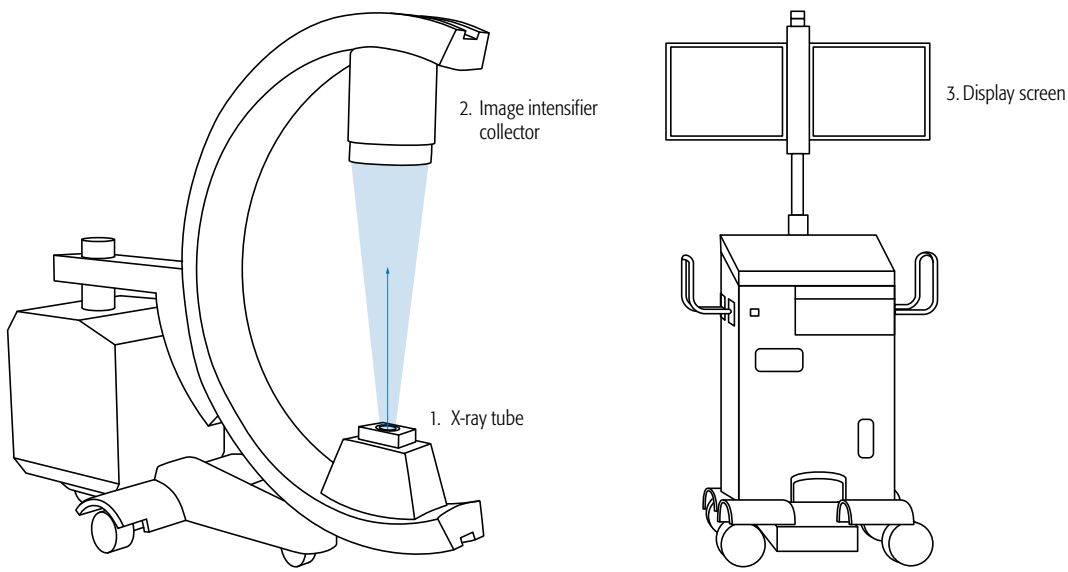

Fig 4.9-1 The x-ray apparatus: x-ray tube (1), image intensifier collector (2), and display screen (3).

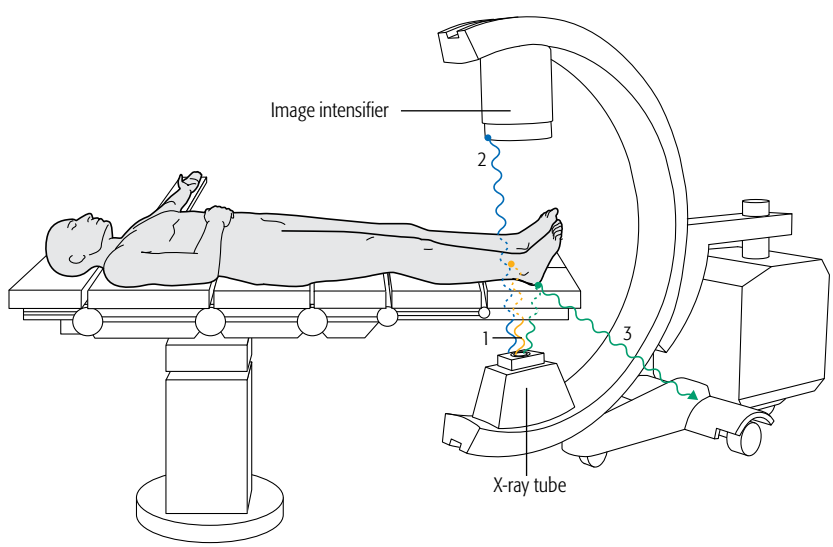

Fig 4.9-2 X-ray tube generates radiation (1). After passing through the patient, the transmission (2) reaches the image intensifier. Scatter (3) is reflected from the patient and exposes the surgical team.

The radiation power (kilovolt) and exposure (milliampere) are usually automatically set to produce an optimal image and will vary with the mass through which the beam passes. Obese patients or patient with large limbs produce more scattered radiation, reflected off the patient. Additional protective devices for the surgical team should be considered in these circumstances. The team should stand a safe distance away from the x-ray source during surgery (**Fig 4.9-3**).

4.2 Imaging mode

Imaging modes:

- Continuous mode
- Pulse mode

Historically, image intensification was performed in the continuous mode. Whenever the image intensifier pedal is pressed, a continuous x-ray beam is produced. Thirty image intensifier images are created per second. The modern image intensifier has the capability of pulsed image intensifier, whereby the x-ray beam is emitted as a series of short pulses rather than continuously. At reduced frame rates, pulsed image intensifier can provide substantial dose savings. Images may be acquired at 4–15 frames per second rather than the usual 30 frames per second. Therefore, pulsed image intensifier has a great advantage since the radiation exposure is lower at lower frame rates [11]. It may allow reduction of the radiation dose by up to 70%.

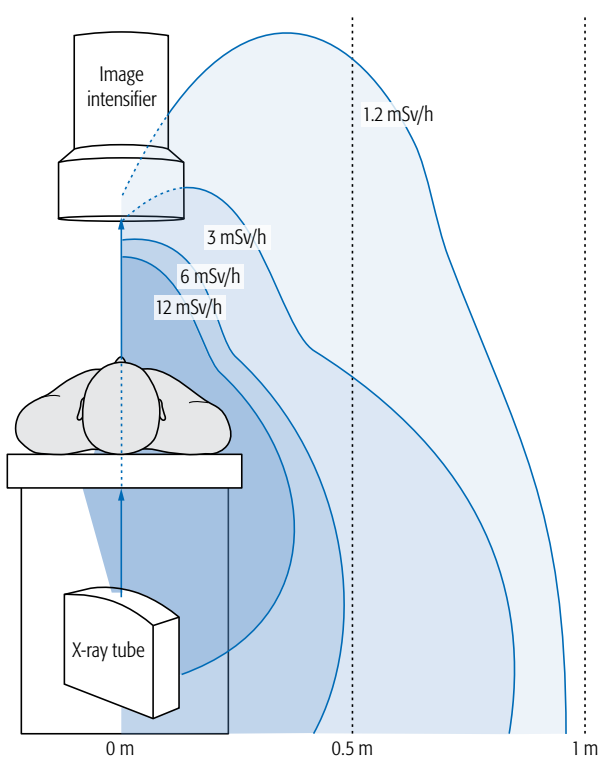

Fig 4.9-3 Scattered radiation diminishes with distance.

4.3 Collimation

The radiation risk is related to the dose and area of entrance into the patient. The iris diaphragm is a collimator, which serves to reduce radiation exposure to the patient and the surgical team. A collimated beam irradiates less tissue than an open beam (**Fig 4.9-4**).

5 Safety measures for radiation reduction

There are guidelines and recommendations from the International Commission on Radiological Protection (ICRP) on human protection against the risks of radiation hazards in the field of medicine, general industry, nuclear-related industry, and even from naturally occurring sources. The recommendations are based upon core principles:

- Justification of the practice
- Optimization of protection—ALARA principles
- Individual dose and risk limit

As Low As Reasonably Achievable principles are radiation safety principles for minimizing radiation dosage and release of radioactive materials by using all available methods. The ALARA principles are not only sound safety principles, but also a regulatory requirement for all radiation safety programs. The three major principles of ALARA are:

- Time—minimizing time exposure will directly reduce radiation dose.
- Distance—doubling the distance between your body and the radiation source will divide the radiation exposure by a factor of 4 (**Fig 4.9-3**).
- Shielding—using lead protection for x-rays and gamma rays is an effective way to reduce scattered radiation exposure.

5.1 Training

A trained image intensifier technician is required for safety purposes. They should understand the operating system, including the implications for radiation exposure of each operational mode. This will prevent incorrect and unnecessary use of the C-arm. An experienced operator can also reduce the number of recorded exposure images to an adequate minimum number required for necessary diagnostic details. Before the operation, the surgeon and the image intensifier technician should discuss how to position the patient and the C-arm during the procedure. The operating table should not obstruct image intensifier production.

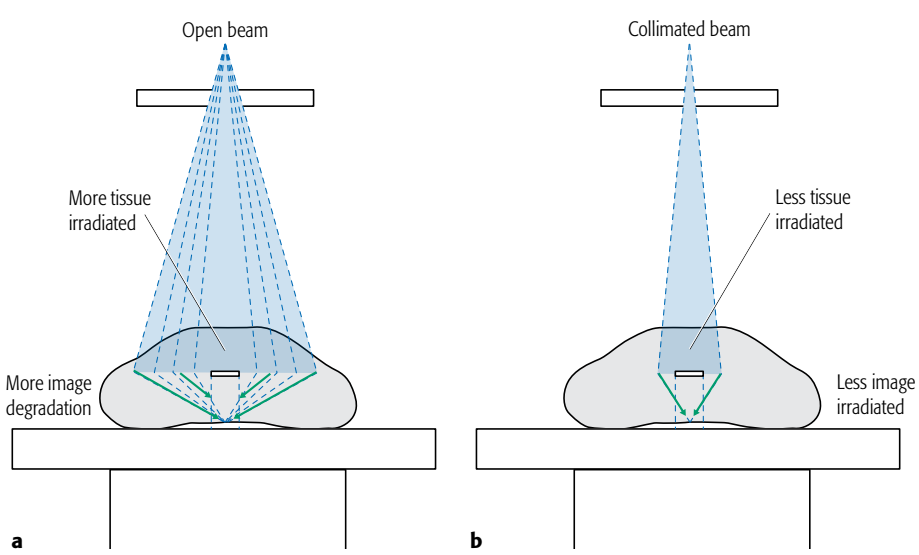

Fig 4.9-4a–b Collimation to reduce radiation exposure.

5.2 Protective equipment

Protective equipment also helps protect the surgical team from scattered radiation and are mandatory adjuncts during surgery. Sensitive body organs should be protected (**Fig 4.9-5**).

- Leaded glasses: To reduce the risk of cataracts, leaded eyeglasses are recommended for every case. They offer protection equivalents of a 0.15 mm lead sheet. They attenuate x-ray radiation, greatly reducing the ionizing radiation that reaches the eyes.
- Thyroid shields: Long-term exposure to radiation increases the risk of thyroid carcinoma. The use of a thyroid shield decreases the effective dose to the thyroid by up to 70 times [12, 13] and may reduce the total effective dose received by more than half [14].
- Gowns/aprons/skirts/vests: Helps to protect the body and can cover about 80% of active bone marrow from ionizing radiation. This offers a protection equivalent of 0.5 mm of lead and will reduce effective dose exposure by a factor of 16. Lead gowns should be circumferential for optimum effectiveness.
- Thin sterile lead gloves: Radiation exposure to the hands is much too common. Using thin, lead gloves will protect the hands but may reduce the tactile sensation of the fingers.
- Protection blankets: Children and pregnant patients are of major concern. Awareness of the use of x-ray should be paramount. Only necessary x-rays should be taken. Whenever x-ray is attempted, protective equipment must be used.
- Lead screens: Provide additional protection for the surgical team who are not wearing lead protection.
- Maintenance of protective equipment: A common mistake with protective equipment is folding the lead apron on a chair or table, which may cause breakage of the lead sheet in the apron. The apron must be clean and hang in a vertical position.

5.3 Positioning of patients, surgeons, ORP, and C-arm

Positioning of the patient is important to allow two planes of access for imaging. Planning before surgery will determine patient position and when to use the C-arm. Carbon fiber operating tables will reduce the amount of radiation. After the patient position has been set, C-arm settings and its position, using floor markings, will be confirmed to avoid unnecessary changes during the surgical procedure.

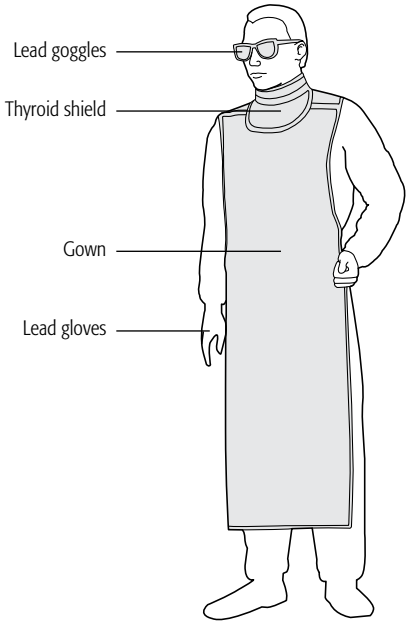

Fig 4.9-5 Dress code for radiation protection.

The main source of radiation exposure to the surgeon and the team is not direct radiation but rather the result of the reflected radiation from the patient that scatters to the surgical team.

The C-arm should be positioned to reduce the amount of scattered radiation. On an AP x-ray, if the x-ray tube is set above the operating table and projects downward, scattered radiation will be more toward the surgeon's upper body (**Fig 4.9-6**). Keeping the x-ray tube underneath the operating table will project scattered radiation more toward the floor and the lower extremities of the surgeon and team. This setting creates less radiation exposure and is preferred. With a lateral x-ray, the x-ray tube should be set on the opposite side of the surgeon. This setting will also reduce the scattered radiation exposure of the surgeon and team because the radiation is reflected to the opposite side (**Fig 4.9-7**).

Never use the C-arm with the image intensifier below or as a "hand table." Scattered radiation from metal surfaces and instruments will reach the eyes and thyroid of the surgeon.

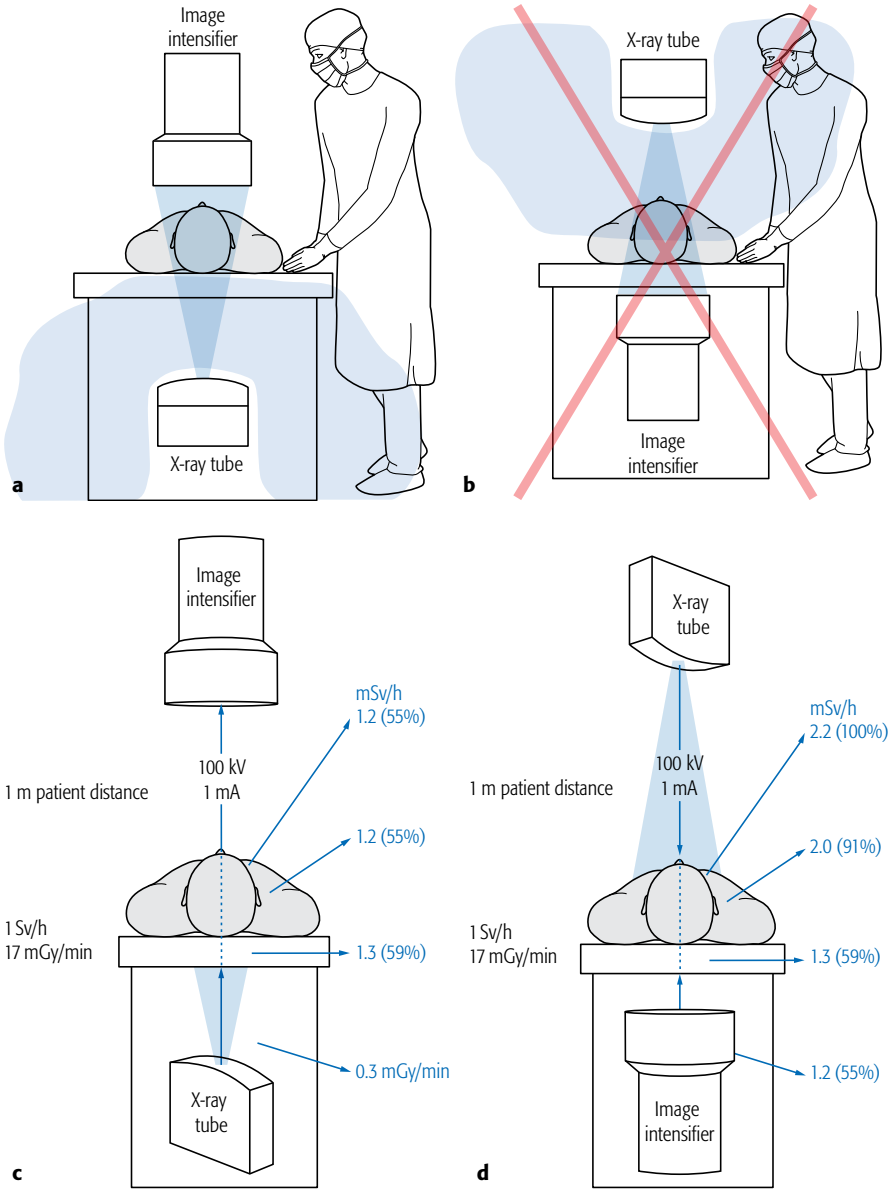

Fig 4.9-6a–d

a Minimize the distance between the image intensifier and the patient.

b Positioning the x-ray tube above the patient will create higher doses of radiation exposure due to reflected and scattered radiation.

c–d Positioning the x-ray tube below the operating table reduces high-dose rates to eye lens by three or more times.

The distance from the x-ray tube to the patient and surgical team is crucial. Standing further away from the x-ray source significantly reduces radiation exposure. According to the inverse-square law, when the distance between the x-ray source and the surgeon is doubled, the dose of radiation is reduced to a quarter. Moving as little as 0.5 m or one step back will reduce the amount of radiation exposure dramatically, and at 3 m there will be neglible radiation.

Distance from the radiation source is the best radiation protection.

The distance of the x-ray tube to the patient is called the source to skin distance (SSD). This distance is inversely proportion to the amount of radiation that the patient receives. When the SSD is increased, the patient radiation will decrease. The surgeon should move the image intensifier closer to the patient (minimize the air gap) to reduce the radiation dose (**Fig 4.9-6a**).

6 C-arm requirements and set-up in the OR

For patient and surgical team safety as well as minimization of radiation exposure, the team should ensure the following:

- Meticulous preoperative planning
- Proper positioning of the C-arm
  - Mark the floor with tape to ensure proper position
  - X-ray tube always underneath the operating table
  - Minimize the air gap between patient and image intensifier
- Appropriate C-arm settings
  - Use pulsed mode and avoid continuous mode
  - Use a laser pointer on the C-arm to find the center of the field
  - Collimate the target area
  - Use stored images to minimize the need for re-exposure
  - Use image processing of the C-arm images to magnify or adjust the contrast and sharpness to avoid reimaging
- A good image intensifier technician will:
  - Take a minimal number of images
  - Avoid continuous exposure
  - Inform the surgical team when an image is about to be taken
  - Stand on the same side of the image intensifier during x-ray
  - Wear proper protection
  - Prevent images being taken when surgical team members have their hands in the x-ray beam

7 Documenting imaging

7.1 Memory modes

The image intensifier has memory storage allowing users to store images for later use. Surgeons can review images and select the best or most appropriate ones to print for documentation. In hospitals with a digital medical recording system, images can be stored in the central memory bank as part of a permanent medical record. Secure storage and backup systems are required for safety and patient protection.

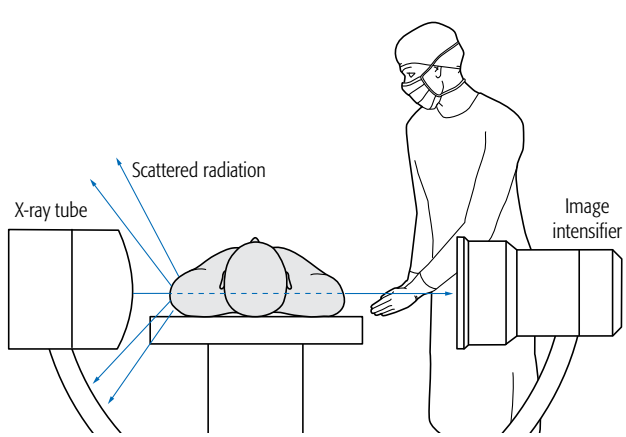

Fig 4.9-7 Lateral x-ray: The surgeon should stay on the opposite side of the x-ray tube.

7.2 Hardcopies

Image intensifiers produce images. To have immediate documentation, printing is the simplest way. After selecting appropriate images, the surgeon can print these and use them to explain to the patient and/or family members immediately after surgery. Postoperative plain x-rays are still recommended as the C-arm does not produce high-quality images and only has a narrow field of view.

8 Future intraoperative imaging: 3-D CT, navigation, and the hybrid OR

Newer generation C-arms can produce 3-D images. They allow better evaluation of fractures, especially in multiplanar joints. They can also be linked to computer navigation devices to reduce intraoperative radiation exposure. For example, a 3-D image intensifier can be used to check the proper reduction of a syndesmotic joint. It is difficult to determine the congruency of the tibio-fibular joint by conventional C-arm [15]. A 3-D CT image intensifier has been reported to be useful as a navigating tool to assist surgery, such as iliosacral screw placement [16] and spine surgery. However, radiation exposure to the patient with 3-D imaging is much higher than with normal image intensifiers.

9 Conclusion

Radiation is dangerous but risks can be minimized by observing the guidelines and recommendations of the ICRP. Details regarding the proper set up and the use of the image intensifier and protective equipment for the patient and the surgical team are paramount. Surgeons and the operating team must bear in mind that long-term exposure should be monitored appropriately to avoid future consequences.

Classic references | Review references

10 References

1. **Sierink JC, Treskes K, Edwards MJR, et al.** Immediate total-body CT scanning versus conventional imaging and selective CT scanning in patients with severe trauma (REACT-2): a randomised controlled trial. *Lancet.* 2016 Aug;388(10045):673–683.
2. **Tan GA, Van Every B.** Staff exposure to ionizing radiation in a major trauma centre. *Aust N Z J Surg.* 2005 Mar;75(3):136–137.
3. **Chow R, Beaupre LA, Rudnisky CJ, et al.** Surgeons' perception of fluoroscopic radiation hazards to vision. *Am J Orthop (Belle Mead NJ).* 2013 Nov;42(11):505–510.
4. **Hoffler CE, Ilyas AM.** Fluoroscopic radiation exposure: are we protecting ourselves adequately? *J Bone Joint Surg Am.* 2015 May 6;97(9):721–725.
5. **Fuchs M, Schmid A, Eiteljörge T, et al.** Exposure of the surgeon to radiation during surgery. *Int Orthop.* 1998;22(3):153–156.
6. **Ott M, McAlister J, VanderKolk WE, et al.** Radiation exposure in trauma patients. *J Trauma.* 2006 Sep;61(3):607–609; discussion 609–610.
7. **Hall EJ, Giaccia AJ.** *Radiobiology for the Radiologist:* Lippincott Williams & Wilkins. Philadelphia: 2006.
8. **BEIR VII Phase 2.** *Health Risks From Exposure to Low Levels of Ionizing Radiation.* Washington DC: The National Academies Press; 2006.
9. **Brenner D, Elliston C, Hall E, et al.** Estimated risks of radiation-induced fatal cancer from pediatric CT. *AJR Am J Roentgenol.* 2001 Feb;176(2):289–296.
10. **US National Research Council Committee on the Biological Effects of Ionizing Radiation (BEIR V).** *Health Effects of Exposure to Low Levels of Ionizing Radiation: BEIR V.* Washington DC: National Academies Press; 1990.
11. **Aufrichtig R, Xue P, Thomas CW, et al.** Perceptual comparison of pulsed and continuous fluoroscopy. *Med Phys.* 1994 Feb;21(2):245–256.
12. **Müller LP, Suffner J, Wenda K, et al.** Radiation exposure to the hands and the thyroid of the surgeon during intramedullary nailing. *Injury.* 1998 Jul;29(6):461–468.
13. **Tse V, Lising J, Khadra M, et al.** Radiation exposure during fluoroscopy: should we be protecting our thyroids? *Aust N Z J Surg.* 1999 Dec;69(12):847–848.
14. **Theocharopoulos N, Perisinakis K, Damilakis J, et al.** Occupational exposure from common fluoroscopic projections used in orthopaedic surgery. *J Bone Joint Surg Am.* 2003 Sep;85-A(9):1698–1703.
15. **Richter M, Zech S.** Intraoperative 3-dimensional imaging in foot and ankle trauma-experience with a second-generation device (ARCADIS-3D). *J Orthop Trauma.* 2009 Mar;23(3):213–220.
16. **Mosheiff R, Khoury A, Weil Y, et al.** First generation computerized fluoroscopic navigation in percutaneous pelvic surgery. *J Orthop Trauma.* 2004 Feb;18(2):106–111.

11 Acknowledgments

We thank Klaus Dresing for his contributions to this chapter in the second edition of *Minimally Invasive Plate Osteosynthesis.*

Section

5

Complications

Section 5
Complications

5.1	**Malunion** Mauricio Kfuri	**493**
5.2	**Aseptic nonunion** R Malcolm Smith	**513**
5.3	**Acute infection** Olivier Borens, Michael S Sirkin	**529**
5.4	**Chronic infection and infected nonunion** Stephen L Kates, Olivier Borens	**547**

5.1 Malunion

Mauricio Kfuri

1 Terminology and classification

Malunion occurs when a fracture has healed in a position of deformity that results in a visible cosmetic deformity and/or functional impairment. The degree of impairment depends upon the site and the magnitude of the deformity. The alignment must be evaluated in terms of bone length, axial rotation, and angulation in both the frontal and coronal planes.

Some malunions are better tolerated and compensated by the neighboring joints than others.

For example, malunions around the shoulder are much better tolerated than those around the ankle. This means that there are both absolute and relative indications for surgical correction of malunion.

The measure of a bone deformity takes into consideration the normal parameters of bone alignment and joint orientation. A malunion may be a result of a single plane malalignment or a complex deformity involving rotation and translation.

1.1 Length discrepancies

Length discrepancies cause few functional problems in the upper limb but are not well tolerated in the lower limbs. A leg-length difference of more than 2.5 cm is associated with an abnormal gait pattern and low back pain.

The indication for operative correction of leg length is not absolute and cannot be expressed in centimeters.

Decisions must be made on an individual basis. Shortening the (normal) lower limb by intertrochanteric osteotomy is a safe operation; corrections of up to 5 cm can be expected to have a low complication rate [1]. The same is true for the intertrochanteric single-step lengthening. Lengthening of up to 3.5 cm can be achieved but this operation is only indicated when other corrections at hip level are also necessary. A monoaxial lengthening device, such as the Wagner distractor, can be used to apply Ilizarov principles of compression followed by callus distraction. This allows safe metaphyseal and even diaphyseal lengthening of more than 5 cm. The combination of intertrochanteric shortening on one side and diaphyseal lengthening on the other is a sophisticated method of correcting differences of more than 6 cm (**Fig 5.1-1**).

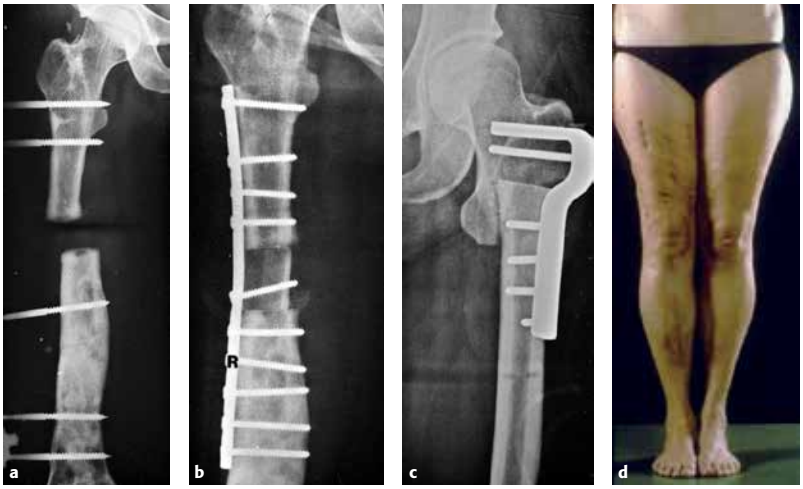

Fig 5.1-1a–d An 8 cm leg-length discrepancy after multiple nonunion operations.
a Lengthening of the right femur using the Wagner distractor.
b Interposition of bone graft and plating.
c A shortening intertrochanteric osteotomy of 4 cm of the left femur equalizes the leg length.
d The result is normal hip and knee function.

1.2 Intraarticular malunion

Painful and disabling articular incongruity with joint instability leading to progressive arthritic changes is an absolute indication for surgery, particularly in the lower extremity.

The decision as to whether secondary reconstruction, extraarticular correction osteotomy, arthrodesis, or joint replacement is performed depends on the following:

- Condition of the soft tissues
- Function of the joint
- Age and functional demands of the patient
- Socioeconomic factors
- Available surgical expertise and facilities

Intraarticular osteotomies are salvage procedures that should be considered in symptomatic patients with a functional range of motion (**Fig 5.1-2**).

In young patients with severe joint destruction, arthrodesis is still the method of choice. The technique of fusion should allow for total joint replacement (eg, hip and knee) at a later stage.

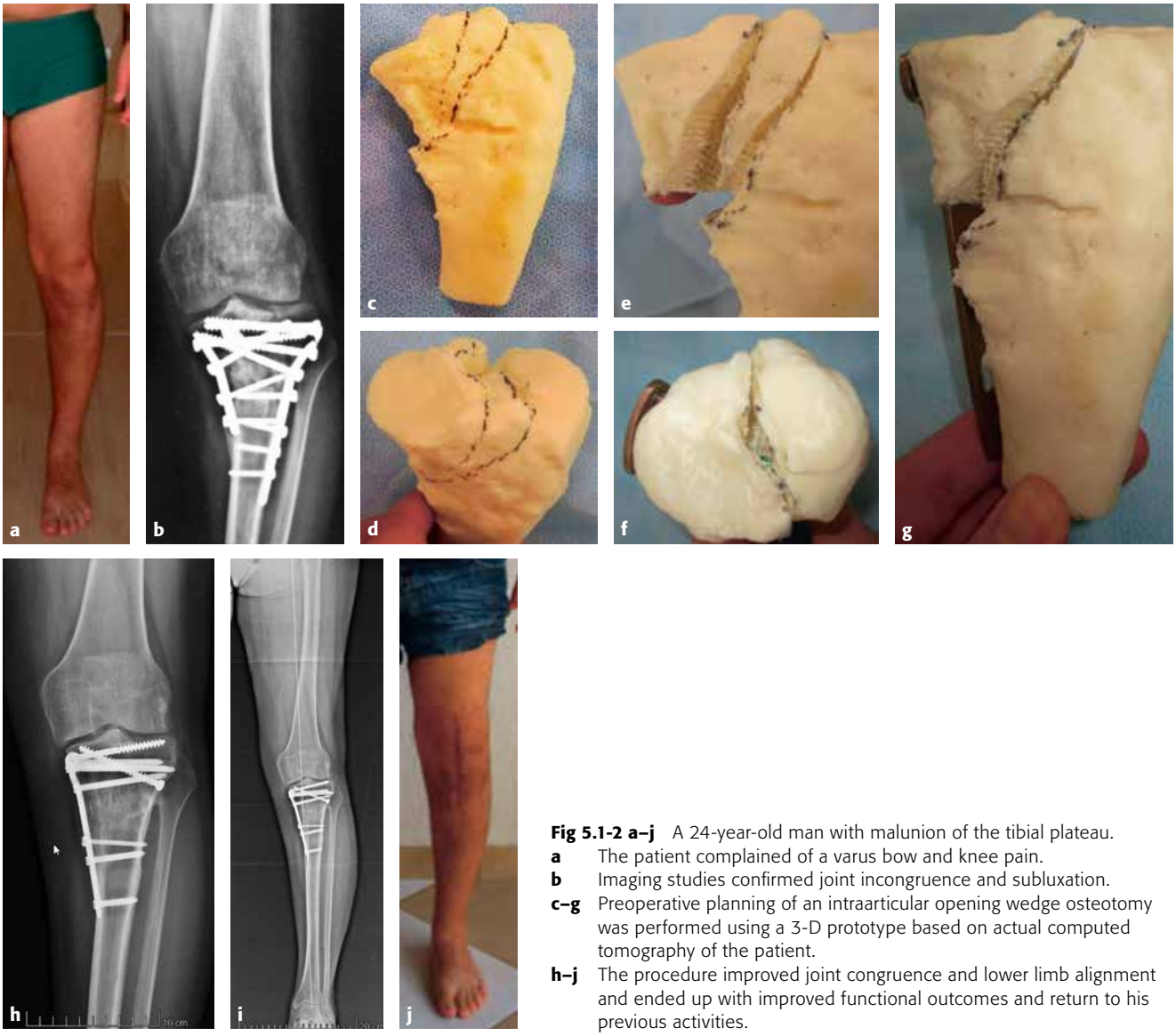

Fig 5.1-2 a–j A 24-year-old man with malunion of the tibial plateau.
a The patient complained of a varus bow and knee pain.
b Imaging studies confirmed joint incongruence and subluxation.
c–g Preoperative planning of an intraarticular opening wedge osteotomy was performed using a 3-D prototype based on actual computed tomography of the patient.
h–j The procedure improved joint congruence and lower limb alignment and ended up with improved functional outcomes and return to his previous activities.

1.3 Metaphyseal malunion

In the absence of pain and functional disability, there are only relative indications to correct a metaphyseal malunion.

Surgery may be indicated if the patient experiences joint instability, pain, and impairment in their daily living activities. Such a situation is discussed individually, taking particular account of the long-term prognosis. Both open and closed wedge osteotomy techniques have their own specific indications and single-plane osteotomy can be effective in the metaphysis. The plate is the implant of choice: external fixation and intramedullary nailing are rarely indicated **Fig 5.1-3**.

Fig 5.1-3 a–h A 49-year-old woman with a neglected Schatzker IV tibial plateau fracture. She complained of deformity and pain.
a Clinical photograph of short varus leg.
b X-ray shows preoperative standing alignment.
c–d Intraoperative x-rays show the intraarticular medial condyle osteotomy.
e–f AP and lateral postoperative x-rays show medial opening wedge corrective osteotomy.
g Postoperative standing whole limb alignment.
h Clinical photograph following correction.

1.4 Diaphyseal malunion

The main question in diaphyseal malunion is the level of corrective osteotomy. The primary goal is to restore alignment and function. However, the condition of soft tissues and the bone at the level of the deformity may be a high-risk factor.

Biomechanically, if the center of the hip, knee, and ankle joints are in correct alignment to one another, the deformity itself is often not problematic. A simple diaphyseal malunion can be corrected in the metaphyseal area where the healing potential is much greater. At the proximal tibia, two-plane metaphyseal osteotomies may be indicated to restore the normal inclination of the joint. In case of diaphyseal deformity and shortening, correction can be combined using a lengthening device **Fig 5.1-4**.

Fig 5.1-4 a–e A 57-year-old man complained of lower limb malalignment 3 years after a motorcycle injury.
- **a** Clinical photograph of lower limb malalignment.
- **b–c** Imaging studies confirmed an atrophic nonunion in the subtrochanteric area (**b**) and a complex malunion in the ipsilateral proximal tibia (**c**).
- **d** Moreover, the patient presented with a rotational malalignment.
- **e** The subtrochanteric nonunion was addressed using realignment of cervicodiaphyseal angle and rotation. Absolute stability was applied.
- **f** A dome osteotomy was performed in the tibial site to correct the translation of the tibia.
- **g** Limb length, rotation, and alignment was restored.

2 Decision making and planning

Any correction of a malunion must be carefully planned [2] and the surgeon must understand the 3-D deformity (see chapter 2.4). Good quality standard x-rays of the affected and the healthy limbs, including both adjacent joints or whole limb, are needed. For intraarticular corrections, computed tomography (CT) imaging including coronal, sagittal and 3-D reconstructions may be helpful. For very complex deformities, the construction of a 3-D model is useful. Planning will often identify unexpected technical problems and may sometimes identify the need for a double osteotomy (**Fig 5.1-5**). The need for a bone graft, bone substitute, or even growth factors must be anticipated and included in the plan.

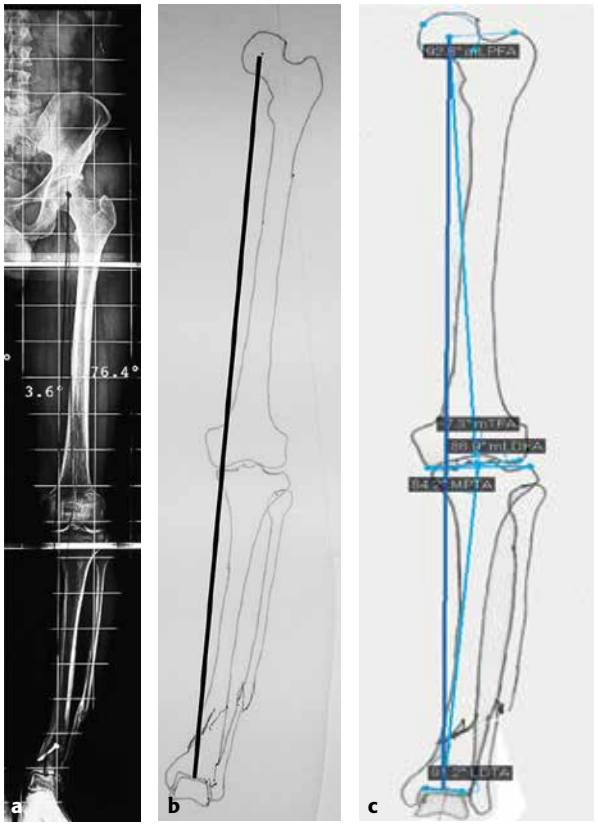

Fig 5.1-5a–g A 42-year-old man presented with a malunion on the distal aspect of the left tibia with medial deviation of the mechanical axis.
a–b X-ray and sketch showing malunion and medial deviation.
c Commercial software calculated the deviation of the mechanical axis and the alignment angles of reference.
d–e With a two-level tibial opening wedge osteotomy, it was possible to restore the alignment and angles of reference.
f–g Follow-up images at 4 years postoperatively.

3 Reduction and fixation techniques

3.1 Choice of implants

The same principles of stable internal fixation that are applied to acute fractures are fully valid for corrective osteotomies. If possible, absolute stability techniques should be used.

The surgical approach should include decortication which produces vascularized osteoperiosteal petals of bone that help stimulate healing of posttraumatic osteotomies. Bone grafting is not required if absolute stability is achieved but where this is not possible, autogenous bone grafting should be considered (**Fig 5.1-6**).

Interfragmentary compression is the key to safe healing, especially in sclerotic and poorly vascularized bone. Compression is best achieved by lag screws and plates. If soft tissues are not at risk, plates especially angled blade plates adapted to the deformed bone are ideal for axial compression of metaphyseal osteotomy surfaces. It is important to use an articulated compression device, which allows compression of the osteotomy surfaces before any screws are inserted. Respecting basic principles, anatomical locking compression plates (LCPs) with locking head screws might be indicated in the presence of severe osteoporosis in areas such as the proximal and distal humerus, distal radius and proximal and distal tibia. Careful planning of the order of screw insertion is essential. For osteotomies, an LCP is probably best used as a compression plate with the locking head screws providing angular stability. It is not appropriate to use an LCP as an internal fixator, as delayed union of the osteotomy is likely. An exception is Tomofix for high-tibial osteotomies [3].

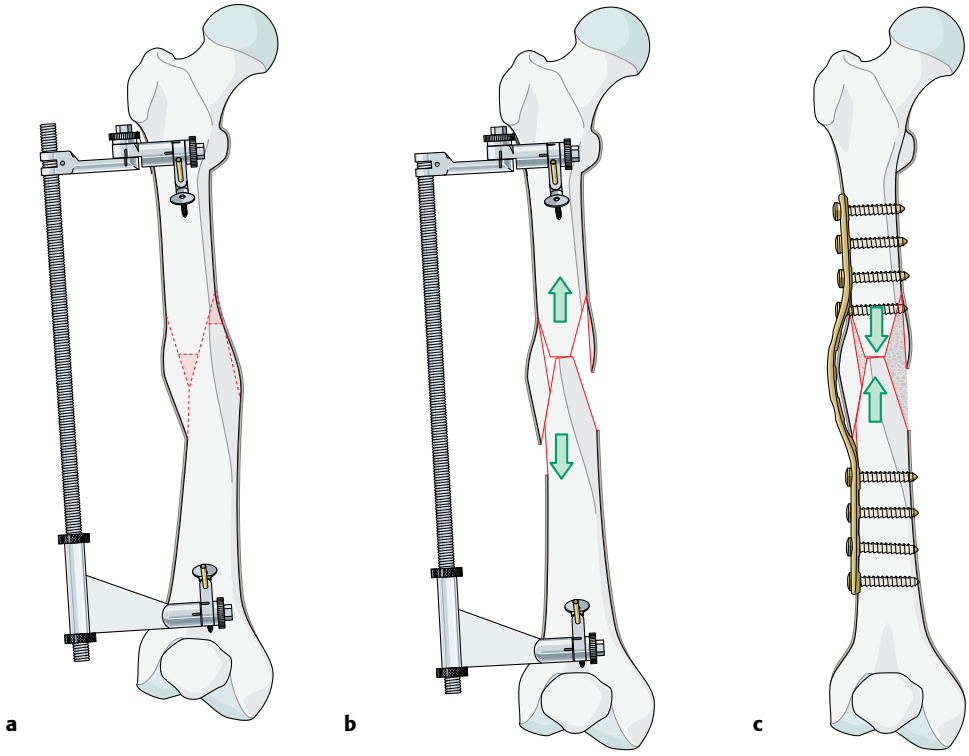

Fig 5.1-6a–c Correction and lengthening osteotomy of a malunited femoral shaft fracture.
a Decortication of the region of shortening, especially on the posterior aspect (linea aspera), and fixation of the distraction apparatus anterolateral, outside the area of future plating.
b Oblique osteotomy and distraction of the fragments until the desired length is achieved. Osteotomy of the tips of the fragments and adaptation on the level of the transverse osteotomy.
c A tension band plate (wave plate) compressing the osteotomy with the articulated compression device. Autogenous bone is grafted if the contact area is small and the decorticated fragments do not provide a sufficient, vascularized, bony bridge.

An external fixator can only compress the osteotomy surfaces adequately if a biplanar or circular frame construction is used. To avoid soft-tissue irritation that limits functional postoperative treatment, this fixation technique is generally restricted to the tibia.

Circular external fixators allow the correction of multiplanar deformities as well as the correction of limb length discrepancies. They are especially beneficial in complex cases, where the soft-tissue envelope is severely injured. The correction may be performed acutely or gradually, depending on the severity of the deformity and the surrounding soft tissues. The main drawback of circular frames is the length of time for treatment, which has a significant psychosocial impact, patient pain and discomfort, and stiffness of adjacent joints [4].

Stabilization of osteotomies with an intramedullary nail is restricted to the diaphysis, where it is effective for the correction of both axial and torsional malalignment. Intramedullary nailing often allows immediate weight bearing and more rapid functional recovery for the patient. The use of nails for the correction of metaphyseal malunion in the femur and the tibia is challenging, especially if there is already a nail in situ. The wider medullary canal and the short remaining metaphyseal fragment are likely to require additional fixation methods, like blocking screws (Poller screws). Reaming the canal is advisable to increase the area of nail-bone contact and to improve stability in all directions. Multiplanar diaphyseal malunions of the femoral shaft may be treated using the "clamshell" osteotomy [5]. This technique produces diaphyseal comminution at the area of the main deformity, restoring the alignment of the proximal and distal bone segments by using an intramedullary nail as a template for the anatomical axis.

In cases where hardware is still in situ, there must be good reasons for switching from one implant system to the other. With a plate still in place, the approach is direct and usually it is a logical and safe solution to again stabilize the osteotomy with a plate. However, as outlined above, correction of a metaphyseal malunion with a nail in situ can be technically difficult and planned removal of the nail, corrective osteotomy, and fixation with a plate may be the better option.

3.2 Metaphyseal and diaphyseal osteotomies

In the metaphyseal area, an osteotomy should be close enough to the joint (where the cortex is already thin) to break or crack it without causing displacement. The constantly cooled oscillating saw should not go all the way across the bone. Small drill holes (drill osteoclasis) may complete the cut while a large chisel helps to break the cortex for an open and closed wedge or single-plane osteotomy. A more stable fixation is needed after rotational osteotomies or displacement osteotomies.

In the diaphysis, corrective osteotomies have a tendency to delayed healing. Judet decortication to produce vital bone pieces at the level of the osteotomy is advisable during the surgical approach and may also help to loosen tight adhesions between the adjacent muscles and bone.

3.3 Single-plane osteotomy

The deformity of a long bone can sometimes be corrected by an osteotomy in a single plane, provided there is no large rotational deformity. This osteotomy is oblique and provides a large-healing surface that can be fixed with lag screws. Some increase in bone length can be achieved, but this technique is not appropriate if more than 2 cm of true shortening must be corrected.

Careful preoperative planning is essential as well as the use of the image intensifier during surgery (**Fig 5.1-7**). The limb is rotated under the guidance of the image intensifier and the plane of maximum bone deformity identified. This plane is marked with a K-wire at the apex of the deformity. The limb is then rotated through 90° so there is no apparent deformity visible on the x-ray. This is the plane of no deformity and will be the plane of the osteotomy. It is marked with a K-wire, which should be at 90° to the first K-wire. The osteotomy is centered at the apex of the deformity and the starting point and length of the osteotomy must be planned [6, 7]. The degree of rotational correction that this technique allows depends upon the obliquity of the osteotomy: a short-oblique osteotomy will cause more rotation than a long-oblique osteotomy and this can be calculated in advance [6]. The direction of the osteotomy will determine the direction of rotation and this requires careful planning. For example, a proximal lateral-to-distal medial osteotomy in the lower limb will cause the distal fragment to rotate internally; a proximal medial-to-distal lateral osteotomy in the lower limb will cause the distal fragment to rotate externally. During surgery the periosteum must be preserved. The osteotomy site is predrilled and then osteomized using an oscillating saw or osteotome. Thermal damage to the bone must be avoided. Once completed, the two fragments can be rotated around the plane of the osteotomy to correct the deformity. With a long-oblique osteotomy the bone may be lengthened up to 2 cm while maintaining bone contact. The two cross sections are compressed with one or two lag screws and a protection plate. Absolute stability allows early mobilization of the limb.

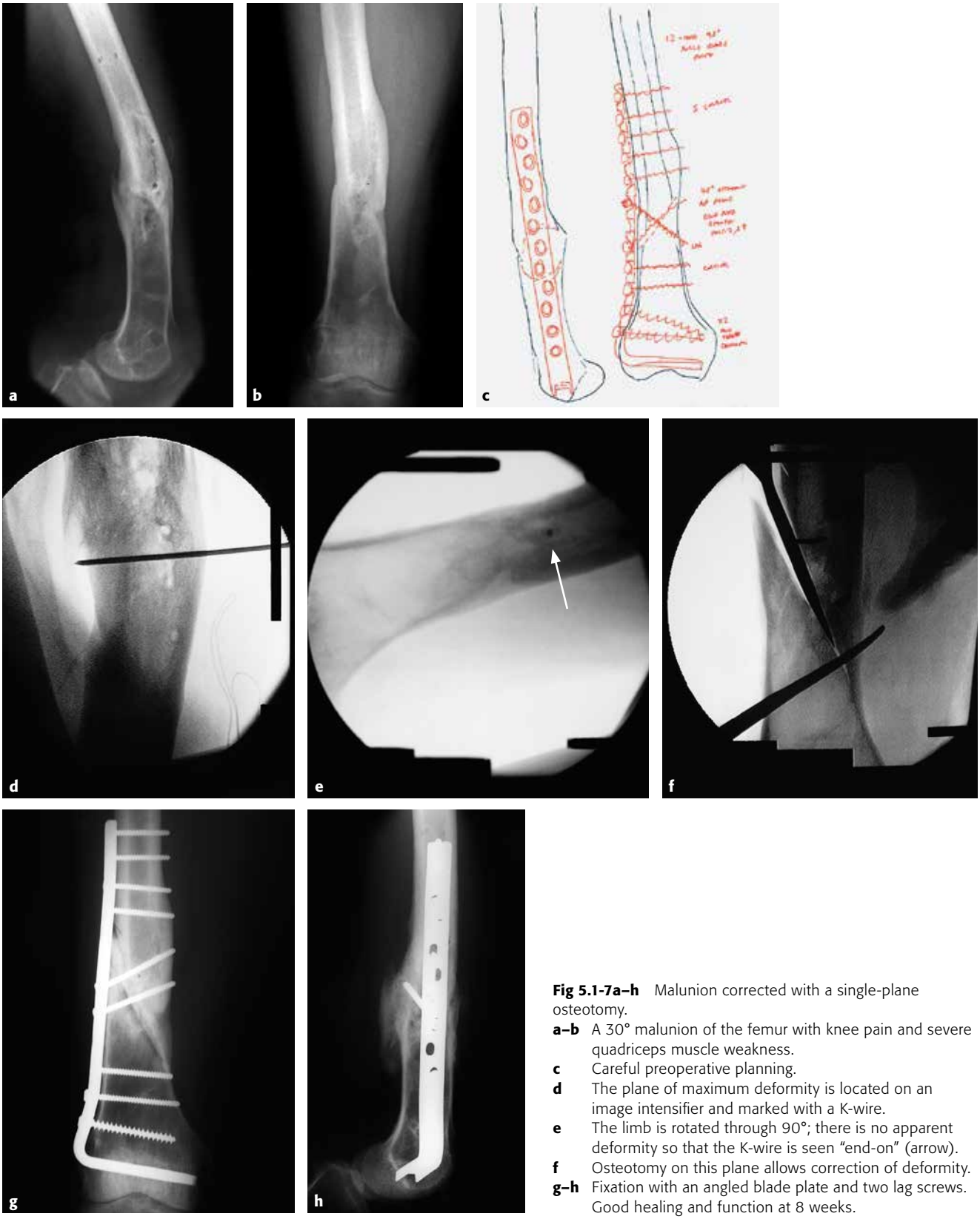

Fig 5.1-7a–h Malunion corrected with a single-plane osteotomy.

a–b A 30° malunion of the femur with knee pain and severe quadriceps muscle weakness.

c Careful preoperative planning.

d The plane of maximum deformity is located on an image intensifier and marked with a K-wire.

e The limb is rotated through 90°; there is no apparent deformity so that the K-wire is seen "end-on" (arrow).

f Osteotomy on this plane allows correction of deformity.

g–h Fixation with an angled blade plate and two lag screws. Good healing and function at 8 weeks.

4 Specific osteotomies—indications and techniques

4.1 Clavicle

Malunion of clavicle fractures is usually well tolerated. Shortening and angulation, causing brachialgia and local symptoms are uncommon but may also result in protraction of the shoulder, persistent pain, and muscle fatigue. Lengthening osteotomy, leading to an enlargement of the subclavicular space, can relieve any impingement of neurovascular structures. The LC-DCP 3.5 must be carefully contoured to the surface of the bone or into a slightly "waved plate." An alternative is the precontoured LCP with locking head screws. A cancellous bone graft is often indicated.

4.2 Humerus

4.2.1 Humerus, proximal

Bone avulsed by the rotator cuff and malunions of the proximal humerus can lead to impingement symptoms and shoulder stiffness. Subcapital osteotomies or reconstruction osteotomies to decompress the rotator cuff can be performed using tension band techniques and small, angulated plates or an LCP with locking head screws. The standard deltopectoral approach can be used for such osteotomies and/or an arthrodesis. Varus or rotational malunions lend themselves to subcapital correction osteotomies (**Fig 5.1-8**).

Malunion of the greater tuberosity usually causes impingement during abduction. After identification and mobilization of the supraspinatus and infraspinatus tendon insertions, a heavy stitch is placed through Sharpey's fibers. The greater tuberosity is then osteotomized and pulled distally. After testing shoulder mobility, the reduced fragment is secured with a lag screw, plate, and one or two tension band stitches.

In malunited four-part fractures, the anatomical relationship between the center of the humeral head and the tuberosities should be restored (**Fig 5.1-9**).

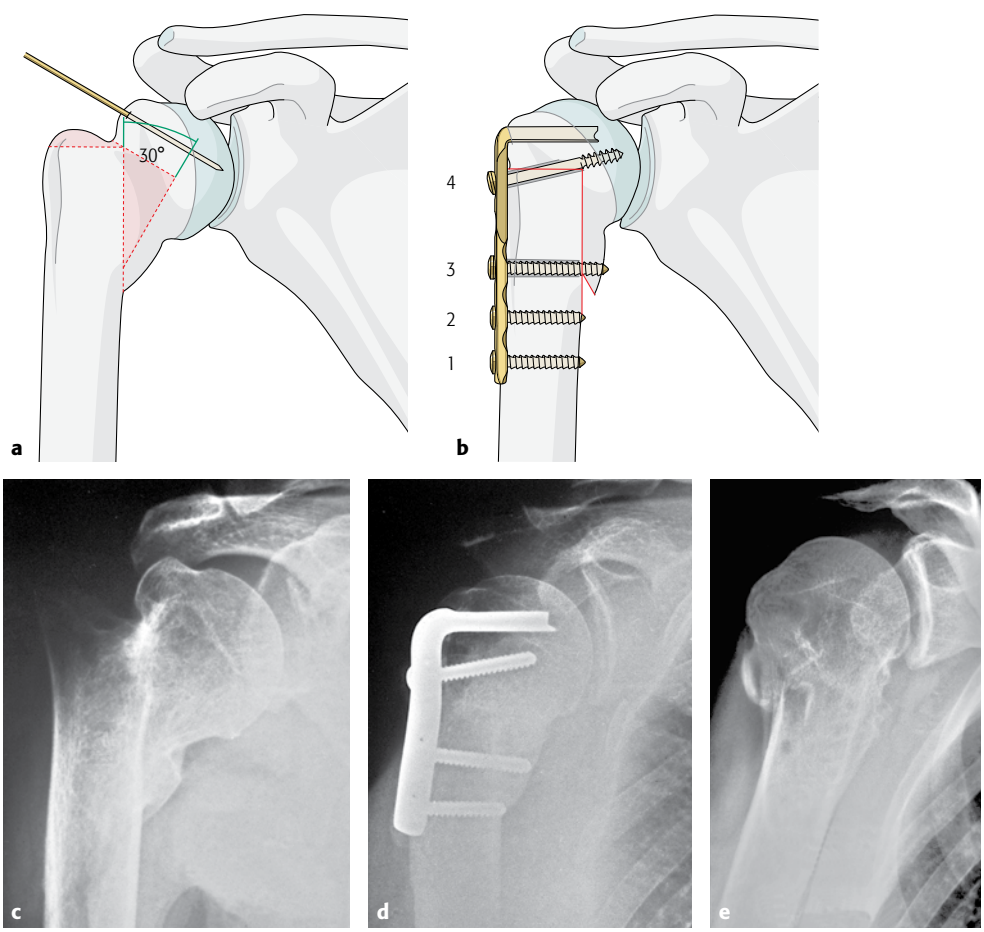

Fig 5.1-8a–e Varus malunion of the proximal humerus. Deformity of the proximal humerus after subcapital fracture.

- **a** Placement of the guide wire for the plate, respecting the calculated correction. Osteotomy of the humeral shaft. A wedge is excised allowing a correction of 30° valgus.
- **b** An angled blade plate for adolescents (an alternative is a 4-hole, 40 mm, 90° angled, cannulated blade plate 4.5) is placed into the proximal fragment. Reduction is performed with a pointed reduction forceps. Distal cortex screws (1, 2), then apply compression. Finally, two lag screws (3, 4) provide additional compression of the osteotomy.
- **c–e** Clinical case: a 62-year-old woman.
- **c** Preoperative x-ray.
- **d** Postoperative x-ray.
- **e** Result at the 2-year follow-up.

4.2.2 Humerus, shaft

Although frequent, malunited humeral shaft fractures rarely require correction. Serious malrotation is easily corrected by a subcapital osteotomy. Correction at the deformity and intramedullary nailing are valid alternatives.

4.2.3 Humerus, distal

The most frequent malunions are varus and valgus deformities. After failed arthrolysis, loss of elbow extension can be another indication for osteotomy (**Fig 5.1-10**) [8]. The lateral approach with stable plate fixation is a safe procedure using either an open or closed wedge technique. Intraarticular osteotomies of the distal humerus are rarely indicated and carry a high risk of necrosis of the intraarticular fragment (**Fig 5.1-11**).

In the presence of an ulnar nerve irritation, the medial approach with neurolysis of the ulnar nerve is indicated. A transposition of the nerve may be necessary.

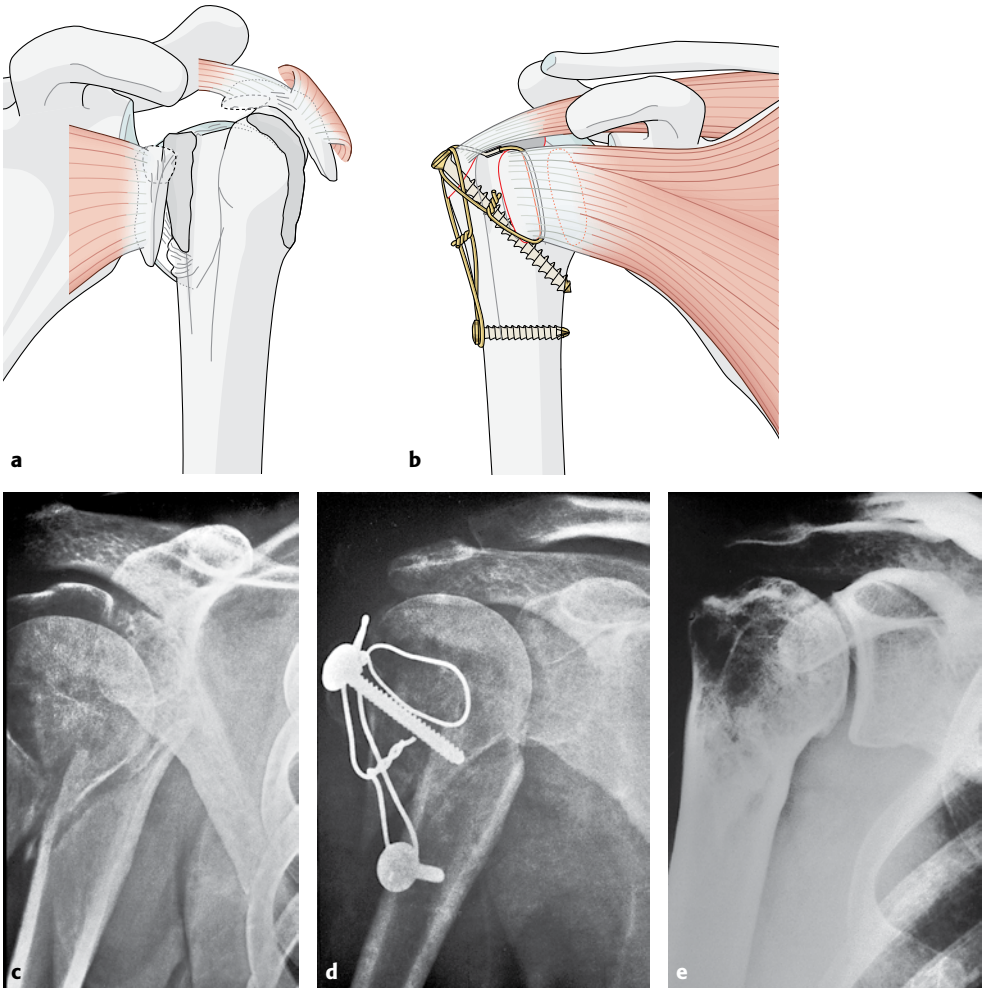

Fig 5.1-9a–e Malunited 4-part fracture.
a Malunited 4-part fracture with interposition of both tuberosities.
b Deltopectoral exposure, identification of the rotator cuff muscles, osteotomy of the tuberosities, reinsertion, and fixation by tension band wiring.
c–e Clinical case:
c Malunited 4-part fracture; painful, stiff joint 5 months after injury.
d Osteotomy and reinsertion of the two tuberosities, restoring the rotator cuff.
e Excellent shoulder function after 13 years. Slight impingement symptoms treated by local infiltrations of steroids.

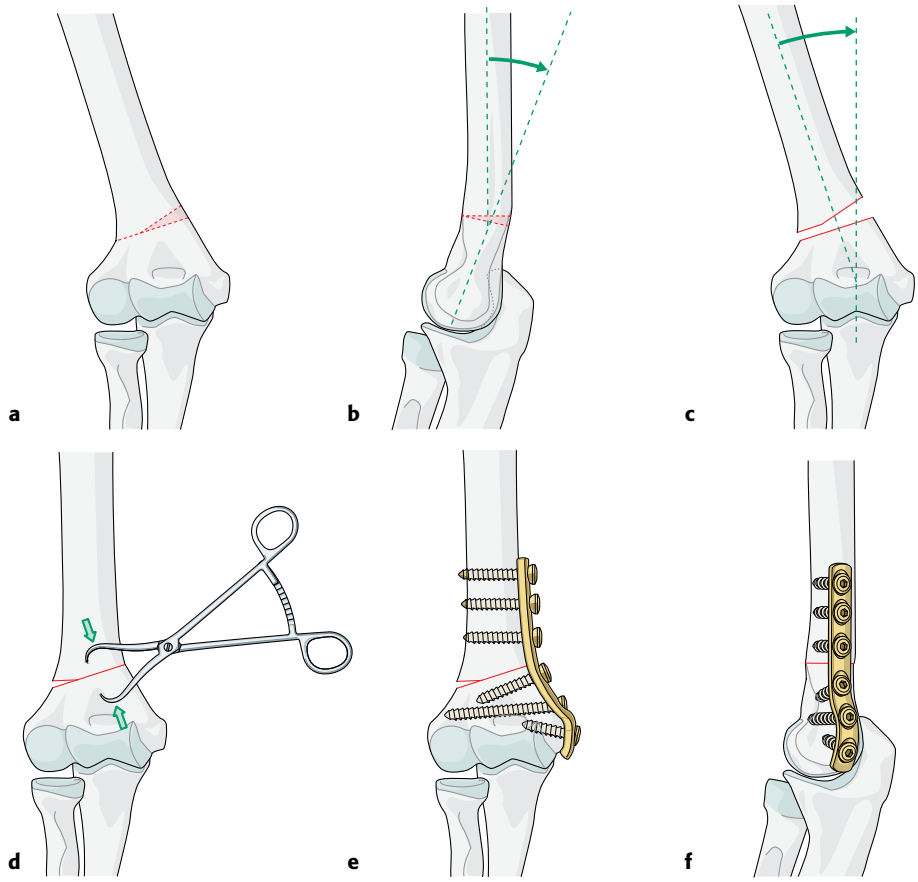

Fig 5.1-10a–f Varisation-extension osteotomy of a distal humerus with valgus and flexion deformity, via the ulnar approach.

a–d Closed wedge osteotomy proximal to the olecranon fossa with the basis of the wedge placed posteromedially; reduction by a pointed reduction forceps to check elbow movement.

e–f Contouring of a DCP 3.5 to the ulnar side of the humerus and fixation compressing the osteotomy.

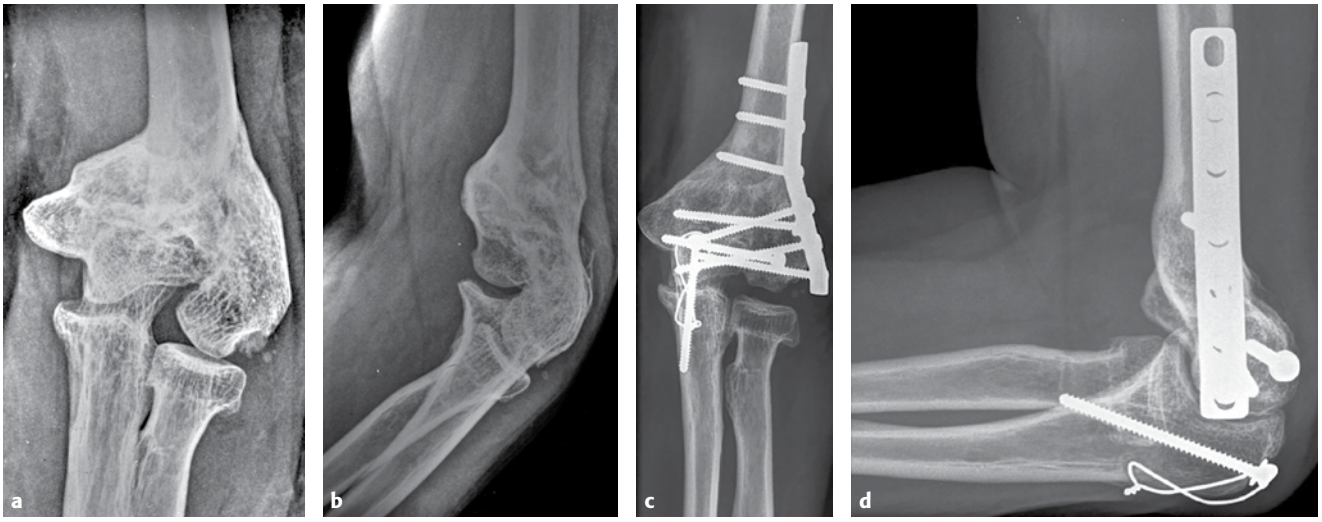

Fig 5.1-11a–d Malunited 13C3 fracture; unstable, nonfunctional elbow in varus and internal rotation after 1 year. Olecranon osteotomy was performed in prone position, the ulnar nerve was released, followed by osteotomy of the lateral condyle, correction of all deformities, length, varus (25°), flexion (30°), lag screw fixation, and supracondylar valgisation (**a–b**). The external rotational osteotomy was fixed with a DCP 3.5 (**c–d**). The elbow was stable and free of pain, and full extension was possible, with flexion gradually increasing.

In single-plane deformities, the oblique osteotomy (**Fig 5.1-10**) creates a bigger surface and optimal stability using the lag screw and protection plate technique. In multiplane deformity correction, a stepwise wedge resection is recommended, allowing temporary reduction by pointed reduction forceps to check elbow movement (**Fig 5.1-10d**).

4.3 Forearm

4.3.1 Radius and ulna, proximal

The unreduced radial head in a malunited Monteggia fracture is a difficult problem and causes considerable loss of forearm function. Corrective osteotomy of the ulna together with release of the radiohumeral joint leads to stable reduction of the radial head as long as there are no deformities of the proximal radius and capitellum.

4.3.2 Forearm, shaft

The forearm bones function like a joint, where even slight malalignment of one of the two bones disturbs pronation and supination, as well as elbow and wrist function.

In the shaft, angulation osteotomies restore the physiological distance and bow between ulna and radius; release of the interosseus membrane may be necessary but must be done cautiously and heterotopic bone is a significant complication.

Supination stiffness limiting the use of the forearm can be treated by rotational osteotomy of one or both forearm bones, depending on the nature and site of the stiffness.

4.3.3 Wrist

Malunion following fracture of the distal radius is frequent but often well tolerated by elderly patients. In the young patient, metaphyseal osteotomies of the radius may be indicated. The approach chosen depends on the direction of angulation but the palmar approach is preferred. Shortening is treated with an open wedge osteotomy. For stabilization, conventional plates or a LCP with locking head screws are used (**Fig 5.1-12**) [9, 10].

Shortening of the ulna alone is most commonly performed for ulnotriquetral impingement and jigs are available to allow precise shortening. It is occasionally required in the presence of minor axis deviation of the distal radius. Beware of irritation or compression of the median nerve. Intraarticular osteotomies may be performed on malunion of single intraarticular fragments of the radius. This is most common when there is a displaced coronal fracture (palmar or dorsal Barton fragment). Early postoperative movement is the rule.

4.4 Femur

4.4.1 Femur, proximal

In general, the indications for surgery in malunion of the proximal femur are varus and rotational deformities in combination with shortening. These result in limping, abductor weakness, and overuse of the neighboring joints. Intertrochanteric osteotomy restores the correct biomechanical situation in all planes [1, 11–13]. Leg length discrepancies can also be corrected at this site by shortening or lengthening.

Preoperative planning is essential and is based on AP and lateral x-rays of the proximal femur and the calculation of all correction angles, including the gain of leg length by creation of a valgus deformity with an open or closed wedge

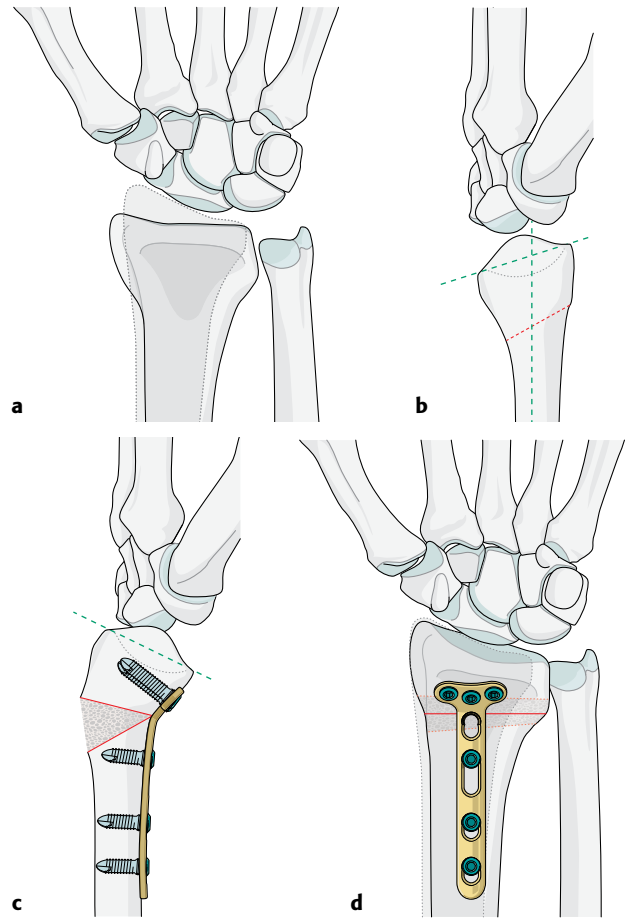

Fig 5.1-12a–d Malunion after fracture of the distal radius.
a–b 30° of dorsal angulation with shortening and radial angulation.
c–d A palmar approach and a transverse open wedge osteotomy of the radius were performed, correcting all deformation. Fixation with the LCP and locking head screws maintains reduction. A bone graft is often used.

osteotomy. This increases leg length and should restore biomechanical balance but the amount of correction is limited by current hip function and an abduction contracture must be avoided (**Fig 5.1-13**).

The implant of choice is the condylar blade plate. A 95° angled blade plate is usually effective but, depending on the amount of valgus necessary, the 120° or 130° angled blade plates may be required.

A locked intramedullary nail does not allow precise correction of complex deformities but may be indicated for purely rotational deformities.

The postoperative treatment is usually functional with 8 weeks of partial weight bearing.

Subtrochanteric osteotomy in different planes can be used to correct malunion and shortening. This osteotomy is technically demanding and experience in individual contouring of plates is required (**Fig 5.1-14**). Lengthening and reduction can be difficult; temporary interposition of artificial bone blocks may be helpful before interposing autogenous bone grafts [13].

Subtrochanteric shortening may be used to establish equal leg length [1, 13]. This is a low-risk operation for shortening of up to 5 cm; only one nonunion in 70 cases was observed. Preoperative planning is extremely important. The plate has to fit the greater trochanter and the femur exactly to achieve adequate contact and to avoid fracture of the lesser trochanter.

4.4.2 Femur, shaft

Diaphyseal malunion with serious angulation/rotation and shortening should be corrected at the level of the deformity. If there is major shortening, the plate is the implant of choice—intramedullary nailing of a sclerotic malunion is dangerous and reserved for minor correction.

Deformities and nonunions combined with severe shortening should be corrected with a versatile lengthening device, eventually combined with an intertrochanteric shortening of the other side (**Fig 5.1-1**). Midfemoral osteotomy can be dangerous with only one vessel in the leg at this level, thus should be done with great care.

4.4.3 Femur, distal

Malunions in a position of valgus, varus, apex anterior or posterior, and, exceptionally, rotational and intraarticular deformities are indications for surgery.

There are three techniques to correct malunion of the distal femur. In both the open and closed wedge technique, the rather thin contralateral cortex should remain intact to create some intrinsic stability. The single-plane osteotomy requires

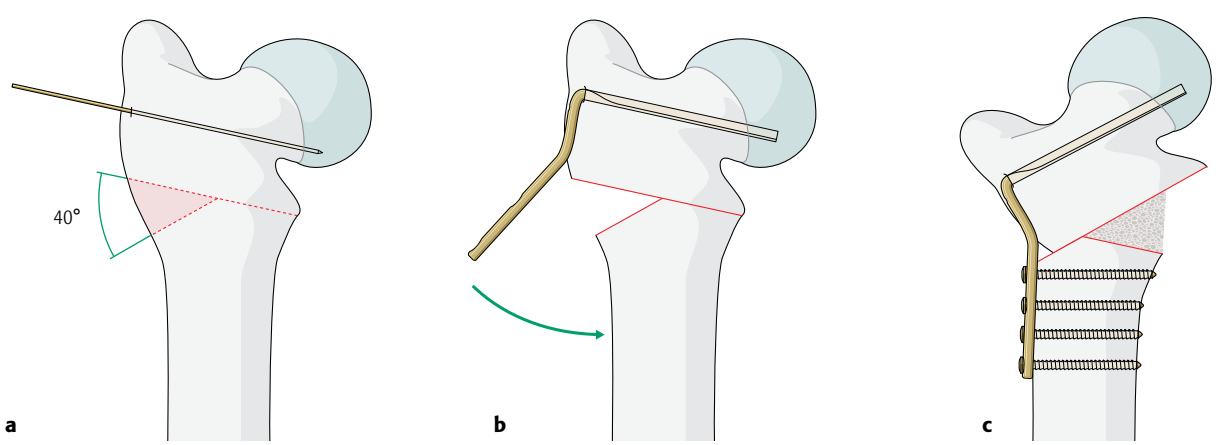

Fig 5.1-13a–c Intertrochanteric valgisation osteotomy for varus deformity after femoral neck fracture. Lateral approach; placement of K-wires for the control of anteversion, rotation, and the calculated angle for the seating chisel.

a Placement for the seating chisel, osteotomy parallel to the chisel, creating a large bony surface; stepwise removal of a lateral wedge.

b Introduction of a 120° angled blade plate after repeated reduction using the seating chisel as lever arm until the calculated correction is achieved without creating an abduction contracture.

c Stabilization of the osteotomy with compression using the tension band principle. The medial defect is filled with the removed wedge.

bicortical osteotomy but allows the use of lag screws to achieve absolute stability. The 90° angled blade plate with 10–20 mm offset is the ideal implant for medial application in valgus deformities, while the 95° condylar plate is designed for the lateral side of the distal femur. Both can be used for the open wedge technique [1]. As mentioned above, the vessel for the leg at this level is tethered and always at risk; therefore osteotomies should be done carefully. The techniques for osteotomy to correct varus and valgus deformity are illustrated in **Fig 5.1-15**.

Postoperative positioning of the knee in 90° flexion and early exercise (continuous passive movement is helpful) are recommended with restricted weight bearing for 6–8 weeks. Delayed union and nonunion are rare.

4.5 Tibia

4.5.1 Tibia, proximal

Indications for surgery are deformities of the proximal tibia in all three planes, intraarticular malunion after unicondylar fracture, as well as residual joint impaction in combination with ligamentous instability.

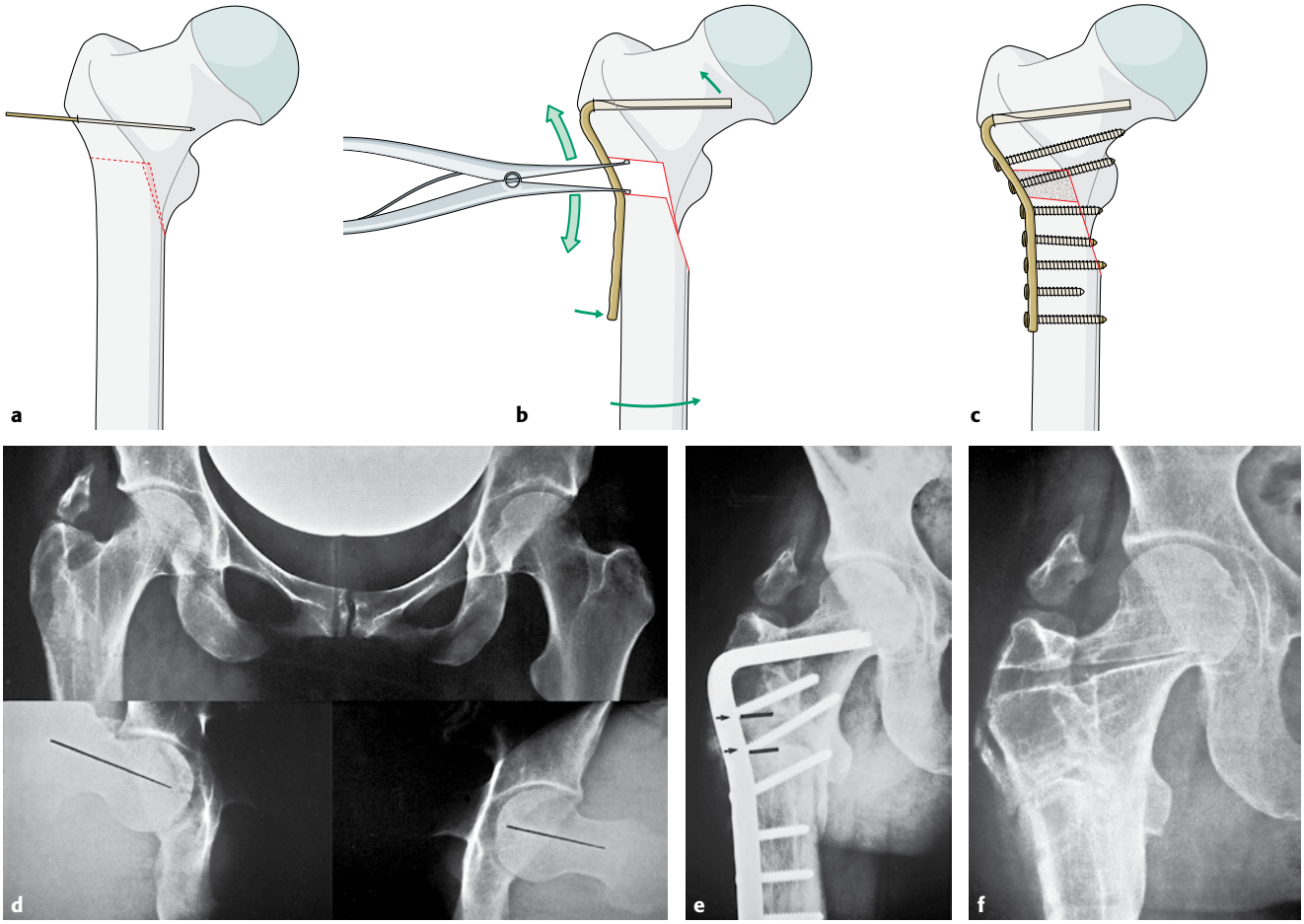

Fig 5.1-14a–f A 3-D subtrochanteric osteotomy of the proximal femur (valgisation, rotation, and lengthening).
a Placement for the seating chisel and adaptation of the osteotomy plane, respecting the desired corrections.
b Distraction with a strong bone spreader with the plate in situ.
c Interposition of corticocancellous bone grafts (from the ipsilateral iliac crest), internal fixation with contoured 95° condylar plate or a 6-hole 90° angled blade plate.
d–f Clinical case:
d Slight varus, shortening, and extreme malrotation after intramedullary nailing of the femoral shaft fracture in a 24-year-old woman.
e 50° derotation, 10° valgisation, and 1.6 cm lengthening; stable fixation with a condylar plate.
f Consolidated corrective osteotomy after implant removal.

Preoperative planning is essential. It is done on the basis of AP, lateral, and oblique views, as well as CT scan. The 3-D reconstruction and the use of 3-D printing to make models are particularly helpful in complex intraarticular deformities.

Posttraumatic malalignment and deformity of the tibial plateau is corrected with the open wedge technique to compensate for bone loss from impaction and to increase tension of the loosened ligaments. This is valid for valgus (most frequent), varus, and genu recurvatum and also for unicondylar and complex intraarticular malalignment. To achieve full correction, osteotomy of the fibula is usually required but seldom needs to be fixed. In the particular situation of genu recurvatum with a normal femoropatellar joint, the technical principles are the same but the osteotomy starts below the tuberosity; otherwise a reorientation of the patella is necessary. Early postoperative knee movement with restricted weight bearing for about 8 weeks is the rule (**Fig 5.1-16**).

Intraarticular malunions with circumscribed impaction of the joint surface can be elevated and buttressed in combination with an open wedge varisation osteotomy. Weight-bearing forces are thereby transferred to the less damaged part of the joint.

Valgus deformity is progressive due to unicompartmental degenerative changes after fracture or meniscectomy. The correction may be unicondylar or bicondylar (**Fig 5.1-3**), depending on the extent of the malunion.

Intraarticular osteotomy, as a single procedure, is rarely indicated. In most cases, axial correction by open wedge osteotomy of the proximal tibia is also required. Slight overcorrection of the axis is paramount to eliminate extreme forces on the partially destroyed compartment. This means a correction to neutral in varus osteotomy or to a few extra degrees of valgus in a valgus osteotomy.

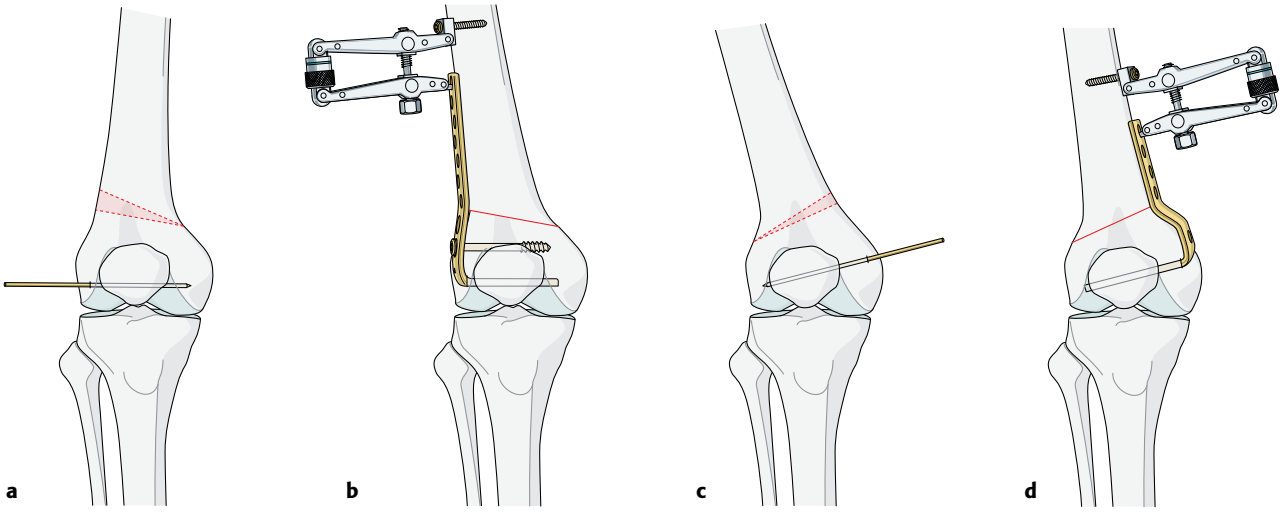

Fig 5.1-15a–d Correction osteotomies of the distal femur.

a–b Valgisation osteotomy. The patient is in a supine position, with sterile draping of the whole leg and the iliac crest. There is a possibility of bending the knee up to 90°. Lateral approach in the interval anterior to the lateral intermuscular septum. Positioning a K-wire through the joint and under the patella. Insertion of the seating chisel taking into consideration the planned correction with a 95° condylar blade plate. A long, oblique, closing wedge osteotomy is performed. Careful osteoclasis of the contralateral cortex with an oscillating saw, small drill holes, and chisels. The wedge is removed and the osteotomy is performed, secured with two pointed reduction forceps before introducing the plate. Full compression is achieved using the articulated compression device.

c–d Varisation osteotomy. The same positioning of the patient as in a valgisation osteomy, approach through the medial septum, identical oblique osteotomy and osteoclasis, and stabilization with a 90° hip plate.

Fig 5.1-16a–j A 22-year-old woman with malunion of the proximal tibia, years after a car injury she had sustained as a child.
a–c Preoperative clinical photograph and x-rays.
d–g Osteotomy and gradual correction of the axis were performed. For 3 months a ring fixator was used to lengthen the leg about 4.5 cm.
h–j At 8-month follow-up: consolidation and good function after removal of the ring fixator.
(With permission from Gerhard Schmidmaier).

The aim of all osteotomies is to correct deformity and slow the progress of arthritis and thus postpone arthrodesis or joint replacement.

4.5.2 Tibia, shaft

The decision to correct a diaphyseal malunion of the tibia depends upon the localization, bone configuration, and condition of the soft tissue. This also applies to the choice of fixation. A reamed intramedullary nail—to be inserted without using a tourniquet—can provide excellent stability and allows early weight bearing but tension band plating has clear advantages if the medullary canal is obliterated by sclerotic callus [1]. If the soft tissues are poor following open fracture, circular frames may be the method of choice.

4.5.3 Tibia, distal

Indications for surgery are:

- Symptomatic malalignment. This may occur after asymmetric closure of the growth plate following ankle fracture in children or following angulated extraarticular fractures of the distal tibia in adults.
- Malunion of pilon fractures with good ankle function.
- Rotational deformities after fractures of the lower leg.
- Intraarticular malunions can sometimes be an indication for joint reconstruction.

The usual method for correction of varus deformities is the open wedge osteotomy or single-plane osteotomy with plate fixation (**Fig 5.1-17**). However, circular frames may be useful if the soft tissues are poor, which is common at this site.

Fig 5.1-17a–e Single-plane distal tibial osteotomy for malunion correction.
a–c Eight years after malunited pilon fracture of the left distal tibia.
d–e At 8-year follow-up: lateral and AP x-rays.

Valgus deformities are easier to manage by closed wedge osteotomy because the fibula can usually remain untouched.

The alternative to this surgery is fusion or, rarely, prosthetic replacement.

In younger patients, make an attempt at reconstruction of distal tibial malunion. The results can be amazing: arthritic changes are well tolerated when there is perfect alignment.

4.6 Ankle

The diagnosis of malunion of a malleolar fracture requires careful observation of the lateral joint line and talar tilt (**Fig 5.1-18**).

Even in the presence of arthritic changes, malunited ankle fractures are a good indication for reconstruction and can often postpone secondary arthrodeses or prosthetic replacement for many years [14, 15].

Shortening of the fibula in type C fractures often leads to talar shift and tilt, and malrotation. This may be associated with malunion of the posterior malleolus. By correction of length and rotation of the fibula, and exceptionally by osteotomy of the posterior malleolus, the anatomy of the ankle mortise can be restored (**Fig 5.1-19**).

4.7 Calcaneus, midfoot, and Lisfranc area

There are a few indications to perform an osteotomy of a malunited fracture of the calcaneus, especially varus malposition or tuberosity malposition. The treatment of choice is a corrective arthrodesis of the damaged subtalar joint or in an extraarticular fashion. The same principle applies to deformation of the navicular bone, cuboid, and Lisfranc joint.

5 Combined malunions

Multiple shaft fractures of the same limb may lead to multiple malunions that compensate for each other. The centers of the hip, knee, and ankle may be in line. Especially in young individuals, the indication to perform a double correction osteotomy is based on the inclination of the knee joint in the sagittal and/or coronal plane, as well as in rotation. In preoperative planning, consider the level, type of osteotomy, and fixation while respecting the soft-tissue situation, function, and aesthetics.

6 Conclusion

The indication for a posttraumatic corrective osteotomy depends upon the associated disability in each individual patient as well as the natural history of the deformity.

The advantages and disadvantages of osteotomy should be discussed with the patient so that a decision can be reached on the balance of risks. The surgeon is responsible for precise planning and should be aware of technical limitations and complications, and be able to predict the end result.

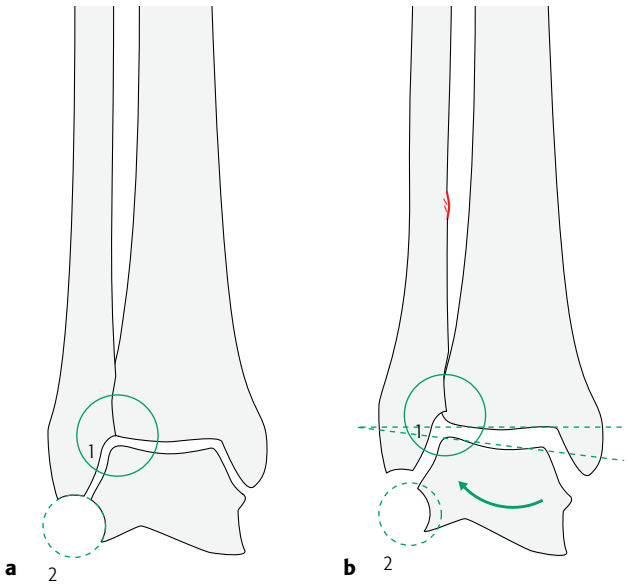

Fig 5.1-18a–b Shortening of the fibula after malleolar fracture.
a Characteristics of a normal ankle joint: (1) Regular joint line without interruption at the level of the syndesmosis, (2) a circle fits exactly at the tip of the lateral malleolus and the lateral process of the talus.
b After shortening and malrotation of the fibula, the joint line is interrupted (1), the circle (2) does not fit anymore. Lateral tilt and external rotation of the talus is usually the consequence (arrow).

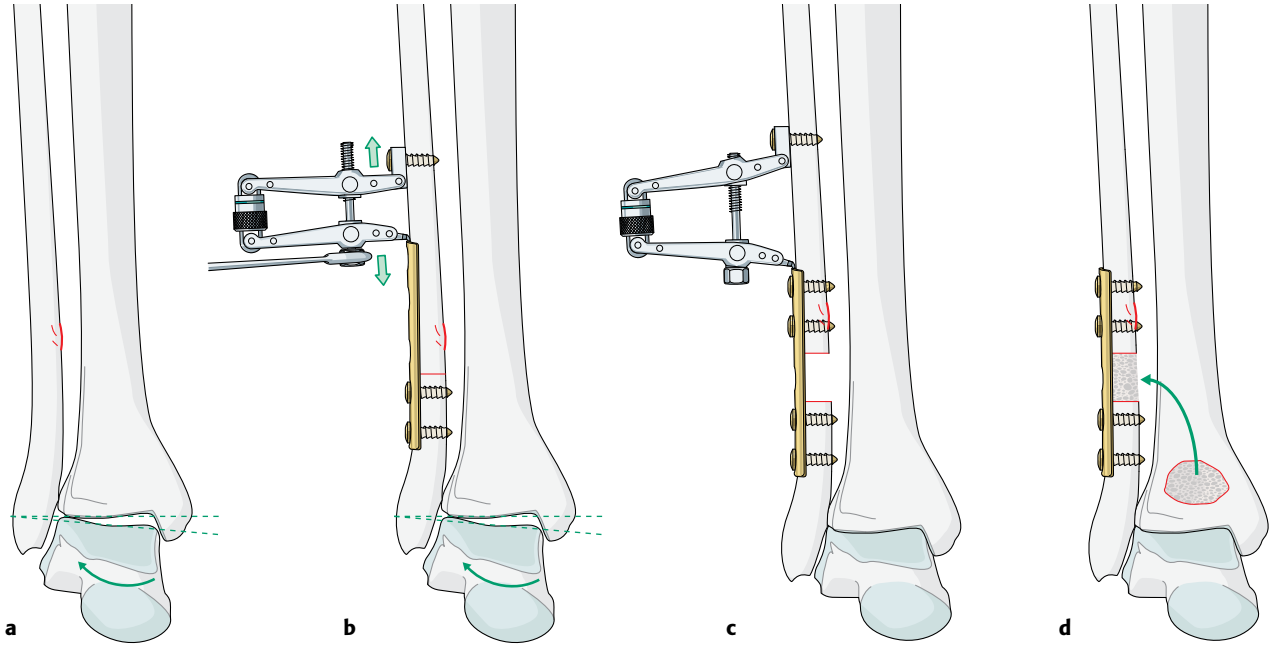

Fig 5.1-19a–d Correction osteotomy of a malunited fibula after ankle fracture.
a Malunion after type C fracture with shortening of the fibula, talar tilt, and shift. Lateral approach and capsulectomy. Exposure and excision of the syndesmotic scar tissue. Sometimes the medial joint space has to be cleared of interposed scar tissue.
b Transverse osteotomy of the fibula, fixation with a DCP 3.5 in slight valgus at the distal fibula. Lengthening and rotation of the fibula using the articulated tension device or the bone spreader as a distractor.
c Reduction of the lateral malleolus into the incisura tibiae until the articular cartilage of the distal tibia, fibula, and talus are congruous.
d Fixation of the plate and filling of the defect with corticocancellous bone. A malunited posterior malleolus can be inspected and osteotomized through the lateral arthrotomy, or by an osteotomy of the medial malleolus.

Classic references **Review references**

7 References

1. **Müller ME, Allgöwer M, Schneider R, et al.** Osteotomies. In: Müller ME, Allgöwer M, Schneider R, et al, eds. *Manual of Internal Fixation. Techniques Recommended by the AO-ASIF Group.* 2nd ed. Berlin Heidelberg New York: Springer-Verlag; 1979.
2. **Mast J, Jakob R, Ganz R.** Osteotomies. In: Mast J, Jakob R, Ganz R, eds. *Planning and Reduction Technique in Fracture Surgery.* 1st ed. Berlin Heidelberg New York: Springer-Verlag; 1989:12–15.
3. **Staubli A, De Simoni C, Babst R, et al.** TomoFix: a new LCP-concept for open wedge osteotomy of the medial proximal tibia—early results in 92 cases. *Injury.* 2003 Nov;34(Suppl 2):B55–62.
4. **Ilizarov GA.** *Transosseous Osteosynthesis.* Heidelberg, Springer- Verlag; 1991.
5. **Russell GV, Graves ML, Archdeacon MT, et al.** The clamshell osteotomy: a new technique to correct complex diaphyseal malunions. *J Bone Joint Surg Am.* 2009;91(2):314–324.
6. **Sangeorzan BJ, Sangeorzan BP, Hansen ST Jr, et al.** Mathematically directed single-cut osteotomy for correction of tibial malunion. *J Orthop Trauma.* 1989;3(4):267–275.
7. **Meyer DC, Siebenrock KA, Schiele B, et al.** A new methodology for the planning of single-cut corrective osteotomies of mal-aligned long bones. *Clin Biomech (Bristol, Avon).* 2005 Feb;20(2):223–227.
8. **Marti RK, Ochsner PE, Bernoski FP.** [Correction osteotomy of the distal humerus in adults. *Orthopade.* 1981 Sep;10(4):311–315. German.
9. **Fernandez DL, Jupiter JB.** Malunion of the distal end of the radius. In: Fernandez DL, Jupiter JB, eds. *Fractures of the Distal Radius: Diagnosis and Treatment.* Berlin Heidelberg New York: Springer-Verlag; 1995;263–315.
10. **Ring D.** Treatment of the neglected distal radius fracture. *Clin Orthop Relat Res.* 2005 Feb;(431):85–92.
11. **Schatzker J.** *The Intertrochanteric Osteotomy.* 1st ed. Berlin Heidelberg New York: Springer-Verlag; 1984.
12. **Bombelli R.** *Osteoarthritis of the Hip.* 1st ed. Berlin Heidelberg New York: Springer-Verlag; 1976.
13. **Marti RK.** Osteotomies in posttraumatic deformities following fractures of the proximal femur. In: Marti RK, Dunki Jakobs PB, eds. *Proximal Femoral Fractures, Operative Techniques and Complications..* 1st ed. London: Medical Press Ltd; 1993;2:573–587.
14. **Weber BG.** Lengthening osteotomy of the fibula to correct a widened mortice of the ankle after fracture. *Int Orthop.* 1981;4(4):289–293.
15. **Marti RK, Raaymakers EL, Nolte PA.** Malunited ankle fractures. *The late results of reconstruction. J Bone Joint Surg Br.* 1990 Jul;72(4):709–713.

8 Acknowledgments

We thank Rene Marti for his contribution to this chapter in the second edition of the *AO Principles of Fracture Management.*

5.2 Aseptic nonunion

R Malcolm Smith

1 Introduction

Nonunions result in major disability to the patient and a major challenge for the fracture surgeon. This chapter considers the nature, cause, and management of nonunion without infection, also known as an aseptic nonunion.

A nonunion is a failure of normal bone healing; it is diagnosed when a fracture has failed to heal within the normal time and will not heal without surgical intervention. The expected healing time for any fracture follows a normal distribution; accordingly some normal bone healing will be later within this range and can be considered as a "delayed union". Established nonunion should not be diagnosed until at least 6 months after injury when the residual potential to heal is small. In 1986 the US Food and Drug Administration suggested a definition of nonunion for diaphyseal fractures to be failure to heal at 9 months with no progress during the previous 3 months.

2 Definitions

- **Delayed union**—fracture healing delayed to the edge of the normal range for the injury and the patient but still progressing.
- **Nonunion**—fracture healing has stopped and the fracture will not unite without surgical intervention.
- **Atrophic nonunion**—nonunion characterized radiologically by lack of bone formation with some resorption of the fracture ends.
- **Hypertrophic nonunion**—nonunion characterized radiologically by excess bone formation, but failure of bridging callus at bone ends.
- **Pseudarthrosis**—nonunion is mobile and has persisted for a long period. The bone ends are sclerotic and the intervening soft tissues differentiate to form a synovial articulation.
- **Mechanical nonunion**—nonunion associated primarily with mechanical influences, such as high strain, which prevent bone from bridging the final gap.
- **Biological nonunion**—nonunion associated primarily with biological failure of healing usually due to poor vascular/cellular conditions.

2.1 Clinical presentation and diagnosis

Clinically, a nonunion will present with motion at the fracture site that may be associated with pain, poor function, and the development of deformity or gross mechanical instability. If an implant is present and still intact, no clinical motion may be detected. Failure of bone healing will cause repetitive strain on the implant that eventually will fail and cause gross instability. The radiological signs include persistent fracture lines, sclerosis at the fracture ends, a gap, and a range of callus responses from hypertrophic callus to absent callus. There may be osteolysis around implants due to loosening. However, overlapping bone, fracture deformity, and the presence of implants may obscure the radiological diagnosis. A computed tomographic (CT) scan is often required to define the lack of bridging bone. A CT scan with multiplanar reformatted images provides a clearer image and is the investigation of choice. Additional examinations

should include inflammatory markers (erythrocyte sedimentation rate, C-reactive protein, and white blood cell count) and elevation may suggest the presence of infection. Metabolic bone studies should be done to assess the biological influences on bone quality with a comprehensive biochemistry series including liver function tests, calcium, vitamin D, thyroid and parathyroid status, and when indicated a steroid and glucose profile [1]. At surgery, for an apparent aseptic nonunion, multiple bacteriological samples should be taken before prophylactic antibiotics are given as positive cultures may be expected in up to 30% of cases [2]. Samples for histological study should also be considered.

Infection is commonly associated with nonunion although the relationship between infection and mechanical instability of a nonunion is controversial [3].

3 Classification of nonunions

The most commonly used classification has developed from that described by Weber and Cech [4] and led to the descriptive terms atrophic, oligotrophic, and hypertrophic nonunion that are commonly used today. This classification considers nonunion with regard to its morphology and introduced descriptions of its specific appearance relating to the degree of callus response (**Fig 5.2-1**). It was believed that this related to the vascularity. A nonunion was considered to be vascularized and viable if there was some callus formation and was described with excess callus (hypertrophic—"elephant's foot"), a normal callus response (normotrophic—"horse hoof"), or with minimal callus (oligotrophic). In these three, some healing is observed although the persistence of a single fracture line diagnoses nonunion. A nonunion was considered to be avascular when there was no callus formation with resorption of the bone ends (atrophic nonunion). With atrophic nonunion, there may be interposition of tissue without osteogenic potential. Bone defects are a specific group and require specialized management techniques.

Thus, the concept of nonunion ranges from the "hypertrophic", which is vascularized and in need of stability, to "atrophic" which is avascular and in need of stability and biology. Nowadays, it is more appropriate to consider the causes and spectrum of nonunion related to the underlying mechanical and biological deficiencies rather than considering only the vascularity, as histological studies demonstrate that atrophic nonunion sites often have a good blood supply and immunohistochemistry indicates that the cells and growth factors required for bone healing are also present.

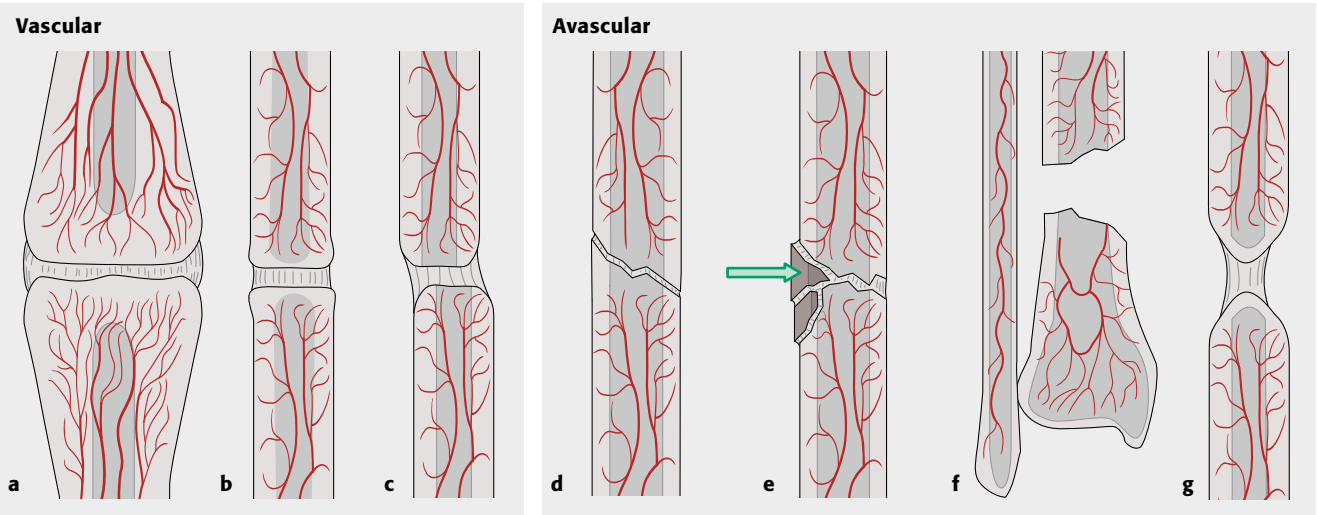

Fig 5.2-1a–g Weber's Classification of pseudarthrosis. Traditionally recognized appearances of nonunion and their presumed vascularity [4].
a Hypertrophic (elephant foot)
b Normotrophic (horse foot)
c Oligotrophic
d Torsion wedge
e Multifragmented (green arrow indicates avascular wedge)
f Bone gap
g Atrophic

4 Etiology of aseptic nonunion

In clinical practice the two main common pathways which result in bone-healing problems are mechanical and biological (**Table 5.2-1**).

One or both may contribute to the etiology of any nonunion but surgical experience suggests that mechanical issues are more common.

A number of biological factors influence the healing process [1, 4]. Since the earlier descriptions, additional factors have been recognized [1, 3–6] including subclinical infection. The improved survival rate after major trauma has led to an increased incidence of patients with much more severe bony injuries and their related problems. In addition, widespread surgical management of fractures has not always facilitated good bone healing and may have increased the incidence of nonunion. Failure of poorly applied or incorrect implants and poorly performed surgery is now an important factor in many nonunions. It is probably better to consider the two main common pathways along which bones fail to heal as due to mechanical and biological factors (with or without subclinical infection) [3].

4.1 Mechanical factors

The role of mechanical stability in bone healing has been discussed by many including Perren [7], Claes and Heigele [8] who illustrated the local mechanical requirements for tissue to form bone. The tissue that forms as a fracture heals naturally goes through a process of progressive differentiation through granulation tissue, fibrous tissue, and cartilage until bone is formed and bridges the fracture gap. The progression through these different tissue types functions to create a stiffer mechanical environment until the local strain becomes low enough for bone to form and the fracture heal [7]. Perren showed that cortical bone will fail to heal at a local tissue strain of around 2% and cancellous bone can tolerate up to 5%. Strain must be reduced to this level to allow bone healing to progress. The physiological response of bone to the mechanical environment accounts for the subsequent remodeling of the fracture and normal bone turnover. This phenomenon is well accepted and forms the essence of Woolf's law [7]. The tissue response during the healing process is stimulated by mechanical factors, as emphasized by Kenwright and Gardner [9], namely micromotion and strain. The healing process and the role of surgical interventions in creating different strain environments (the spectrum from absolute to relative stability) is described in chapter 1.2. Significant delay or failure of this stiffening process due to mechanical or biological factors leads to the persistence or development of a high-strain area resulting in delayed or nonunion [10]. In clinical practice, most nonunions are limited to a single fracture line, whatever the initial fracture pattern. When nonunion develops following multifragmentary fractures treated by relative stability, all the fragments unite leaving one fracture plane that fails to heal. This plane is commonly oblique suggesting the importance of persisting shear strain in the causation of nonunion (**Figs 5.2-2–3**).

Mechanical factors
• Lack of stabilization in unstable fractures
• Inadequate stabilization of the fracture (insufficient or excessive stabilization or inappropriate implants)
• Fractures treated nonoperatively (insufficient immobilization)
Biological factors
• Local: bone defects, open fractures, subclinical infection, injury to soft-tissue structures close to the fracture, extensive comminution, segmental fractures, pathological fractures, displaced and distracted fractures, soft-tissue interposition, iatrogenic soft-tissue injury
• Systemic: neuropathies, diabetes mellitus, malnutrition, chronic smoking, chronic alcoholism, anticoagulants, corticosteroids, previous radiation

Table 5.2-1 Factors in "pseudarthrosis" according to Weber and Cech [4]

4.2 Biological factors

Biological factors change the ability of local bone-healing tissue to form or respond normally after fracture. They act by restricting the general healing process or affecting specific steps required to create bone. Many factors were suggested by Weber and Cech [4] but have since been better clarified and more factors identified, including vitamin D deficiency, thyroid, parathyroid and adrenal dysfunction, smoking, antimetabolites, subclinical infection, nonsteriodal antiinflammatory drugs (NSAIDs) and drugs used to increase bone density by preventing bone reabsorption (bisphosphonates) [1, 3, 5, 6, 11].

Major biological influences include the effects of local ischemia, malnutrition, metastatic disease, severe neuropathy, and diabetes. From the surgical point of view, the most important factor is biological damage to the healing process associated with prior surgery. This may include inappropriate bony stabilization or surgery associated with poor soft-tissue handling and excessive bone stripping. Open surgical intervention facilitates healing in a reduced fracture position but does not speed healing. Conversely, it may delay some of the healing processes due to additional local devascularization. Development of minimally invasive osteosynthesis techniques

have reduced the surgical insult to the soft tissue and bone and may facilitate better bone healing. Recent concepts of fracture surgery emphasize meticulous surgical technique that limits any additional devascularization when fractures are exposed and implants applied. It is well recognized that open and higher-energy fractures carry a higher nonunion rate due to local soft tissue and bony devascularization (and subclinical infection) associated with the degree of trauma.

Fig 5.2-2a–g Two examples of multifragmentary fractures treated by necessity with bridge plating. Both show the development of a uniplanar nonunion, confirmed on computed tomographic (CT) scanning.
a Initial fracture stabilization of a severe open type C distal femoral fracture.
b Persistent pain at 8 months suggests nonunion.
c A CT scan confirms union of fragments but a persisting single plane nonunion.
d–e Initial fracture and stabilization of a type B tibial fracture.
f–g A CT scan confirms union of all fragments but a persisting single plane nonunion.

The aim of surgical fracture management is to reduce the fracture and provide the correct mechanical environment for appropriate bone healing and minimize additional damage that could cause complications and increase the nonunion rate.

It is important to recognize that with fracture fixation, it is the surgeon who determines the mechanical environment and not the patient or the implant.

4.3 Vascularity

Poor vascularity is the common thread among several biological factors and affects the speed and quality of bone formation. Clearly, any healing tissue requires a blood supply and all fractures disrupt the blood supply to the bone and soft tissue to some degree; the greater the energy, the greater the disruption. The location of the fracture can make this critical; bone well covered by muscle attachments tends to have more collateral blood supply than subcutaneous bone, eg, tibia. Bone segments covered by cartilage, eg, the femoral head, proximal scaphoid, or talar body have poorer potential for collateral blood supply and are prone to poor healing. The general health of the patient may also result in reduced tissue perfusion due to chronic or acute vascular disease, smoking, and diabetes.

Traditionally, the fundamental difference between atrophic and hypertrophic nonunion has been considered to be vascularity. Originally "wedge, twisted, comminuted, bone gap and atrophic" nonunions were considered avascular [4]. Current data suggest that this is rarely the dominant issue. In many fractures where bone fragments are clearly devascularized, clinical experience reveals that most fragments are incorporated into the healing process, surrounded or bypassed by new bone and revascularized. The radiographic appearance of atrophic nonunion suggests that "atrophic" nonunion is not avascular because there is resorption of both bone ends which can only occur if they are vascularized. Investigational studies [12, 13] have also shown consistent recovery of vascularization in experimental models reproducing an avascular, atrophic nonunion (**Fig 5.2-4**).

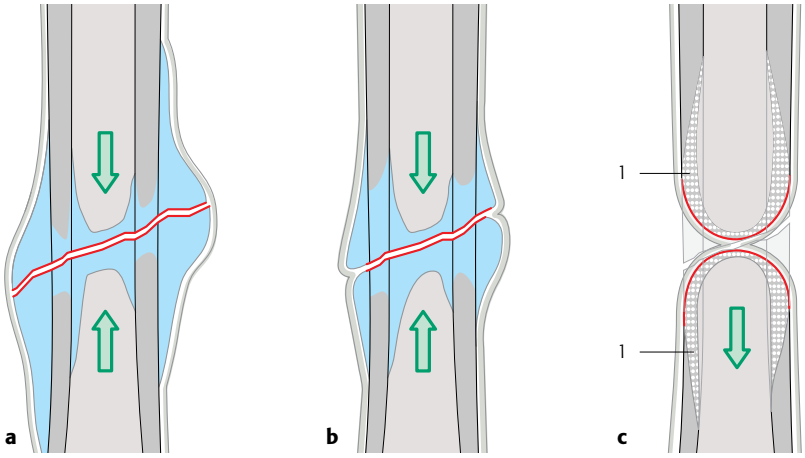

Fig 5.2-3a–c Well-vascularized nonunions: there are no areas of avascular bone.
a Hypertrophic nonunion (elephant foot), usually associated with some stability.
b Normotrophic nonunion (horse hoof), less prominent new bone formation in a less stable situation.
c Atrophic nonunion. Due to marked instability there is resorption (1) of original cortical bone leading to rounded ends.

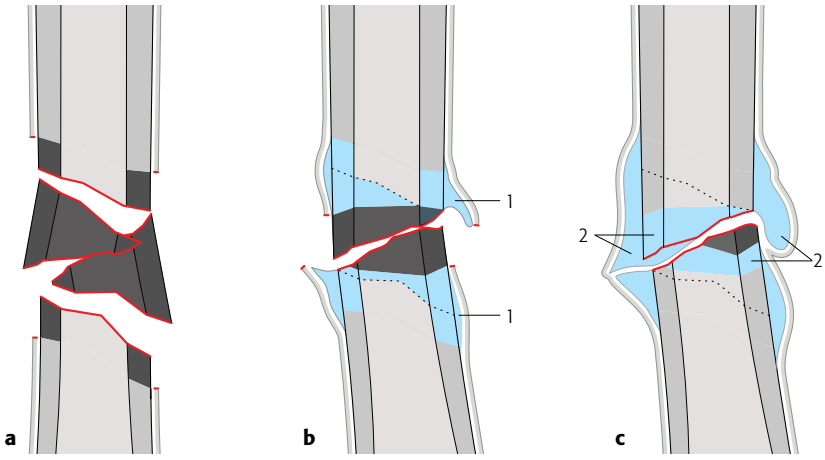

Fig 5.2-4a–c Avascular nonunion.
a Situation immediately following a complex fracture. The dark areas are avascular/necrotic.
b Months later, the two intermediate fragments have healed to each main fragment by callus (1), but there is no evidence of healing in the center of the fracture.
c Even after years and despite additional periosteal bone formation and some remodeling by creeping substitution (2), the nonunion persists.

4.4 Patient factors

The deleterious effect of smoking and NSAIDS on bone healing is important and avoidable, and must be emphasized to patients with fractures.

It is well established that patient factors are also associated with poor bone healing and the development of nonunion (**Fig 5.2-5**). These probably have their effects through the common mechanical and biological pathways noted above. They include smoking and diabetes (probably vascular/biological), neuropathy (mechanical), malnutrition, drug dependency, other endocrine disorders, and the provision of some drugs including NSAIDS (general and specific biological/cellular mechanisms). Given that specific deficiencies are rare [1] and many are not avoidable, cessation of smoking and the avoidance of NSAIDS may be the most important achievable biological modifications possible during the acute fracture (and nonunion) healing period and should be strongly advised [5]. Other evidence suggests that subclinical vitamin D deficiency is relatively common in developed societies and may be important [1]. Noncompliance with postoperative instructions with inappropriate weight bearing is an important factor in poor bone healing and has a similar effect to severe neuropathy.

4.5 Neuropathy

Fracture healing and appropriate neurological function of the extremity are related. Poor healing associated with a neurological defect is due to lack of protective sensation causing repetitive injury and high-strain concentration due to mechanical factors, although the precise pathophysiology is not understood. Diabetes, paraplegia, chronic alcoholism, spina bifida, syringomyelia, and leprosy all cause severe neuropathy. These diseases affect pain sensation and proprioception, thereby limiting the ability of the patient to control weight bearing and compromising an already impaired healing response (**Fig 5.2-5**).

5 Nonunion management—treatment modalities

5.1 Management of delayed union

The primary symptom of a delayed union is persisting pain toward the end of the expected normal healing time. Since bone healing is still progressing, management entails excluding specific problems, such as infection (with inflammatory markers), and avoiding factors that may delay healing (smoking and NSAIDs) and facilitating healing by maximizing functional rehabilitation with controlled loading and active motion. Active surgical management should be delayed until failure of healing is established and nonunion can be declared.

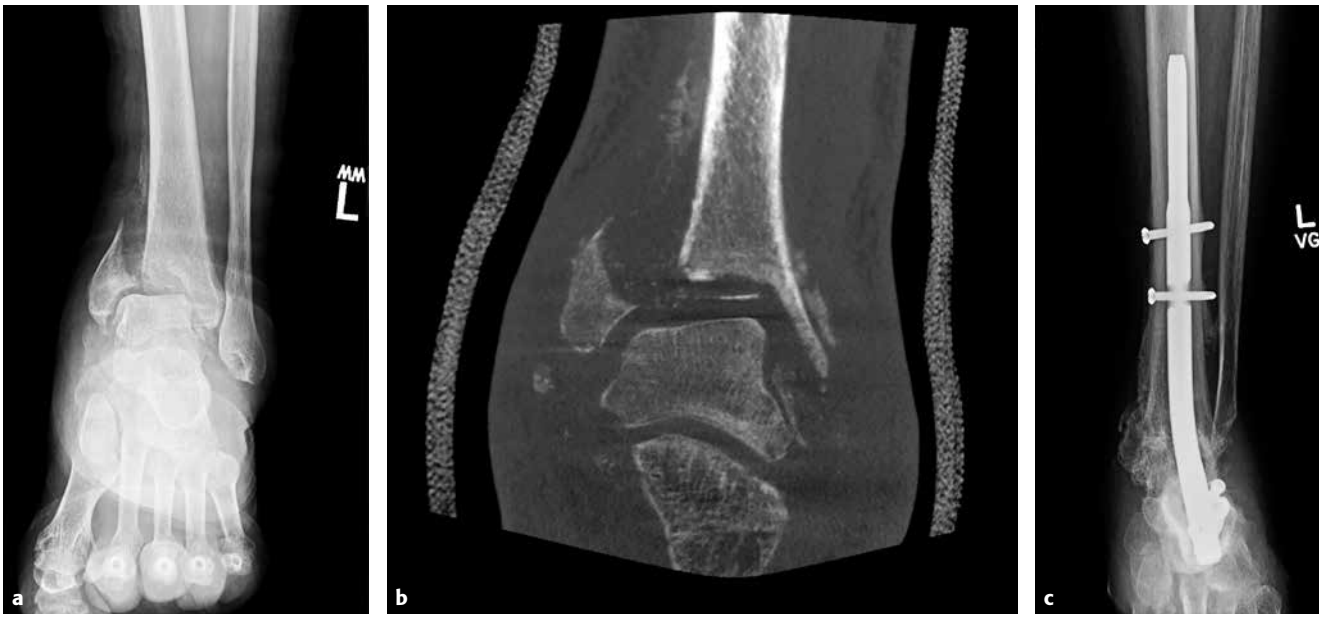

Fig 5.2-5a–c An intraarticular nonunion presenting with minimal pain in a patient with diabetes and severe neuropathy. In view of the severe neuropathy and poor residual joint quality, an arthrodesis with a nail was performed.

5.2 Management of established mechanical nonunion

Most established nonunions have some callus response suggesting that the problem is mainly a lack of mechanical stability. High-strain levels exceed the strain tolerance of bone-forming tissue and although the fracture has the potential to unite, there is insufficient mechanical stability for the nonunion to heal [10]. The most effective method of treating a mechanical nonunion is to neutralize high strain and shear forces by surgical stabilization (**Fig 5.2-6**) [14, 15]. This is best achieved by compression plating (with lag screw fixation if possible). This mechanical stability reduces the tissue strain to a level where calcification of the fibrocartilage can occur, allowing bony ingrowth across the nonunion site.

It should be noted that the fracture will now heal by remodeling (primary bone healing) under conditions of absolute stability. Thus, new callus will not form but preexisting tissues will ossify.

In this situation bone grafting is not necessary, although osteoperiosteal petaling (shingling or Judet decortication of the fracture site) is considered important and may help stimulate union (**Fig 5.2-7**) [15, 16]. In diaphyseal fractures, exchange nailing by insertion of a new reamed nail is effective, as the intramedullary device provides additional stability, corrects the mechanical axis, and neutralizes shear forces [14]. The reaming required for the insertion of a larger nail probably has an additional biological effect.

Resection of the nonunion site is also not necessary and may indeed be harmful, as this will remove the vital osteogenic tissue which is still able to heal if mechanical stability is obtained. Resection of the nonunion is only required when there is a synovial nonunion and the normal bone-healing tissue has been destroyed or when it is required to correct an unacceptable deformity (**Fig/Animation 5.2-8**). After a well-performed compression plating of a mechanical nonunion, pain-free functional motion can commonly be seen as quickly as 2 months after surgery with a > 95% healing rate [2, 15].

Fig 5.2-6 A typical fibular nonunion seen operatively, with fibrous tissue in the nonunion gap (arrow).

5.3 Management of biological nonunion

There are some biological factors present in all nonunions. Clearly, the management of these cases involves identifying and correcting any biological defect in addition to any mechanical problems present. The spectrum of biological problems range from gross cellular dysfunction, such as seen after radiotherapy, or in patients receiving cytotoxic drugs to those associated with nutrient/vitamin or hormonal deficiencies. As noted above, some deficiencies are commonly found in nonunion patients and need to be corrected but in all cases the mechanical issues also need to be considered. Rarely, with a stable implant in place, will an isolated biological modification allow a nonunion to heal. Babu et al [17] demonstrated the positive effect of parathyroid hormone in stimulating bone healing. However, in most cases, a nonunion will not have adequate stability and the additional biological stimulus from Judet decortication and correction of the mechanical environment will be sufficient treatment [15]. If biological factors are considered important, many surgeons will attempt to add an additional stimulus at surgery with autograft cancellous bone. Despite the commercial development of bone morphogenetic proteins and a wide number of bone graft substitute materials, these have not proven to be as effective as hoped and potential complications of manipulation of basic biological signaling processes are possible [18].

Autogenous bone grafting remains the gold standard for the provision of bone-stimulating tissue.

Normally, this is taken from cancellous bone within the patient's posterior or anterior iliac crest, where there is usually a reasonable reservoir of active, red cancellous bone (**Fig 5.2-9**).

5.4 Management of "atrophic" nonunion

Traditionally, atrophic nonunions are considered to be avascular, although as noted above this has been questioned and the radiographic appearance of bone resorption indicates vascularization. Currently, management includes stimulation using biological means with decortication and application of a compression plate (mechanical stability) with additional biological stimulation using autogenous bone graft. The decortication also provides a well-vascularized bleeding

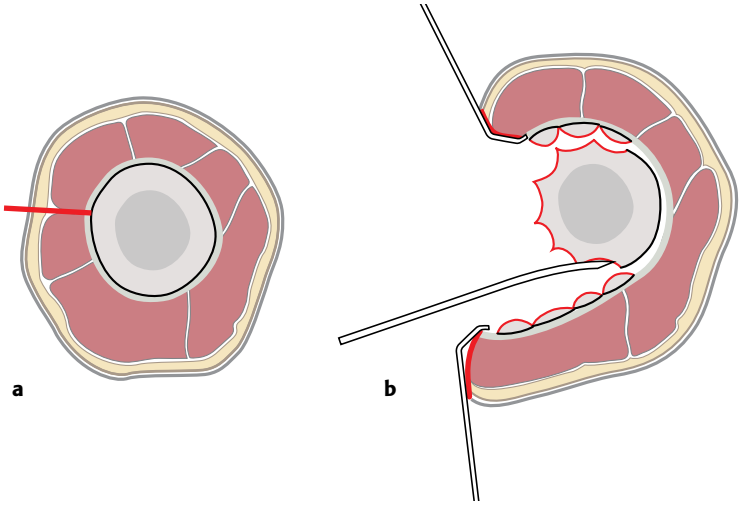

Fig 5.2-7a–d Musculo-periosteo-osteal decortication.
a In areas of nonunion, the vascularization of the external cortex and callus depends largely on periosteal blood supply.
b–c Decortication with a sharp osteotome or chisel creates vascular periosteal bone fragments (1) which must remain attached to the periosteum.
d The area of decortication should extend 2–4 cm into normal bone distal and proximal to the area to be bridged. Cancellous autograft (2) may be placed within the area of decortication.

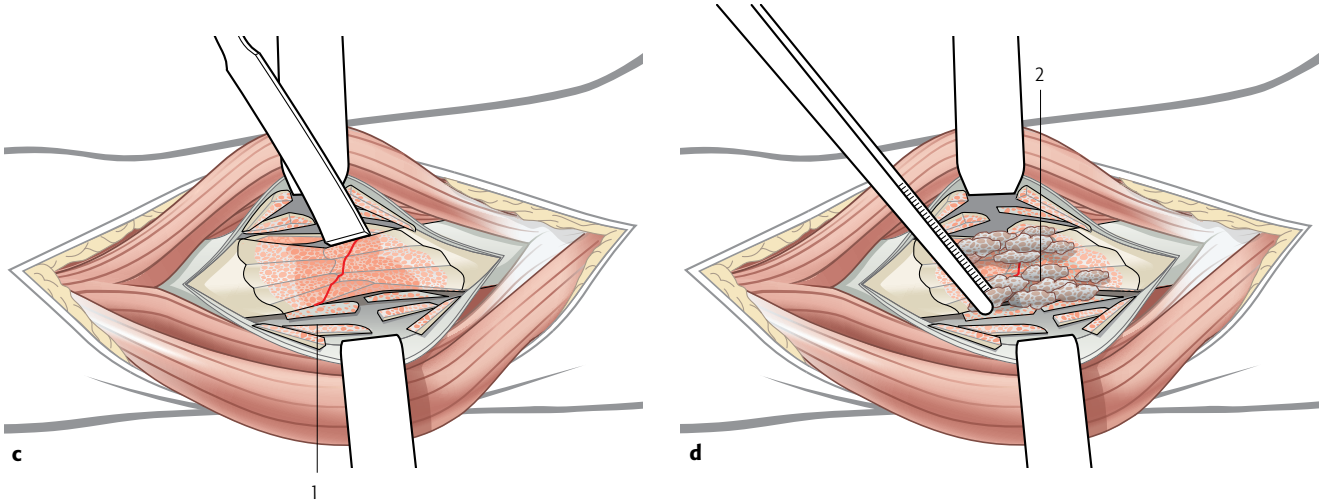

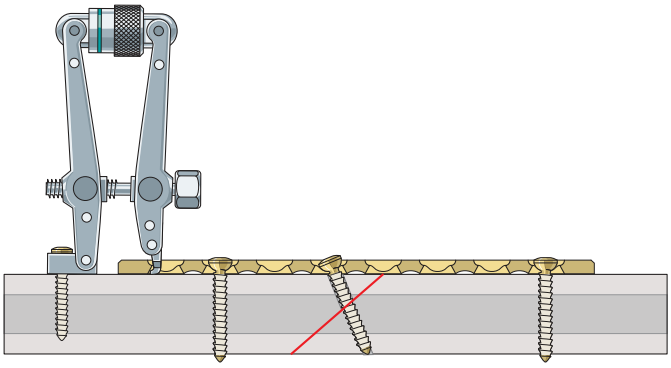

Fig/Animation 5.2-8 If bone resection is required to treat a synovial nonunion, the easiest approach is to perform transverse osteotomies. However, only limited compression can be obtained with a plate. A well-planned, trapezoidal bone resection will allow compression into the axilla with a plate and the articulated compression device followed by lag screw fixation to produce absolute stability.

bone bed to apply the bone graft. Another way to obtain bone graft is with the reamer irrigator aspirator (RIA) from the diaphysis of long bones [19, 20].

5.5 Management of the established synovial nonunion (pseudarthrosis)

Extreme persistent motion at a fracture site can destroy the original bone healing tissue in the nonunion site and result in the formation of a false joint with "synovial fluid" in the gap. The bone ends are sealed over with cortical bone and no normal bone-healing tissue is left between them. Such synovial pseudarthroses are most commonly seen in the humerus below a stiff shoulder (**Fig 5.2-10**) which results in high strain focused at the nonunion site. They are also associated with neuropathic nonunion in patients with paraplegia or diabetes. There is gross instability and marked deformity. Corrective surgery for pseudarthrosis consists of debridement of the associated synovium, decortication of the bone ends to healthy bleeding bone, opening of medullary canal, correction of the deformity, and fracture stabilization with compression. Bone graft may be required [2, 15].

If bone resection is required, planned, oblique osteotomies rather than transverse bone resection allows good compression using the "compression into the axilla" technique (see chapter 3.2.2) with a plate and a lag screw. This provides more stable fixation than can be achieved by compression of a transverse osteotomy with a plate alone (**Fig/Animation 5.2-8**).

6 Operative management of nonunion

6.1 General considerations

The primary objectives in the treatment of a nonunion are to eliminate pain and obtain bone healing in the correct alignment to restore function of the injured limb. Healing of an aseptic nonunion can usually be achieved by a single, well-planned operation to correct the mechanical alignment and stimulate bony consolidation by mechanical compression with a union rate approaching 95% [2, 15, 21, 22]. An important part of the procedure is considered to be the final approach to the bone, where periosteal stripping should be avoided. As the bone is approached, a longitudinal incision

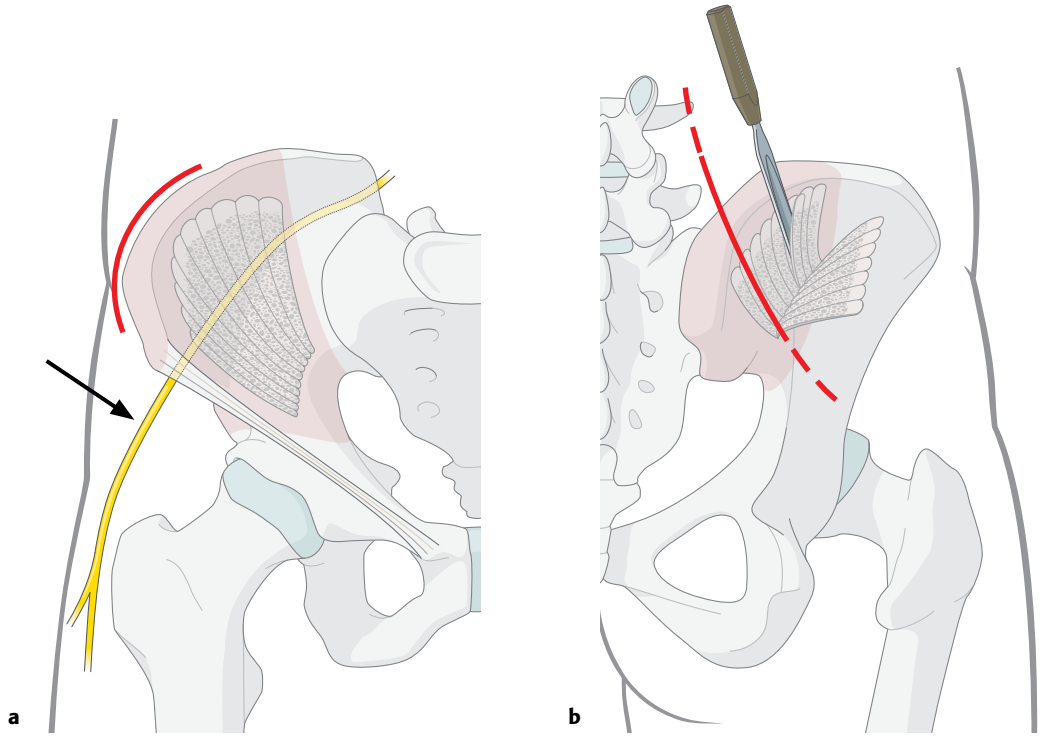

Fig 5.2-9a–b Harvesting of cancellous autograft from the pelvis.

a From the anterior iliac crest, an incision is made along the crest. Sharp dissection of the muscles of the abdominal wall is made, then lifting of the periosteum of the inner wall of the iliac bone with a sharp rasp and exposure with a retractor. Care should be taken to protect the lateral femoral cutaneous nerve (arrow).

b From the posterior iliac crest, the subcutaneous tissue is split. Then the periosteum and muscles are elevated from the outer surface of the iliac bone. The cortical layer is elevated with a curved chisel to harvest pure cancellous bone. The greatest amount of cancellous bone can be found in the vicinity of the iliosacral joint.

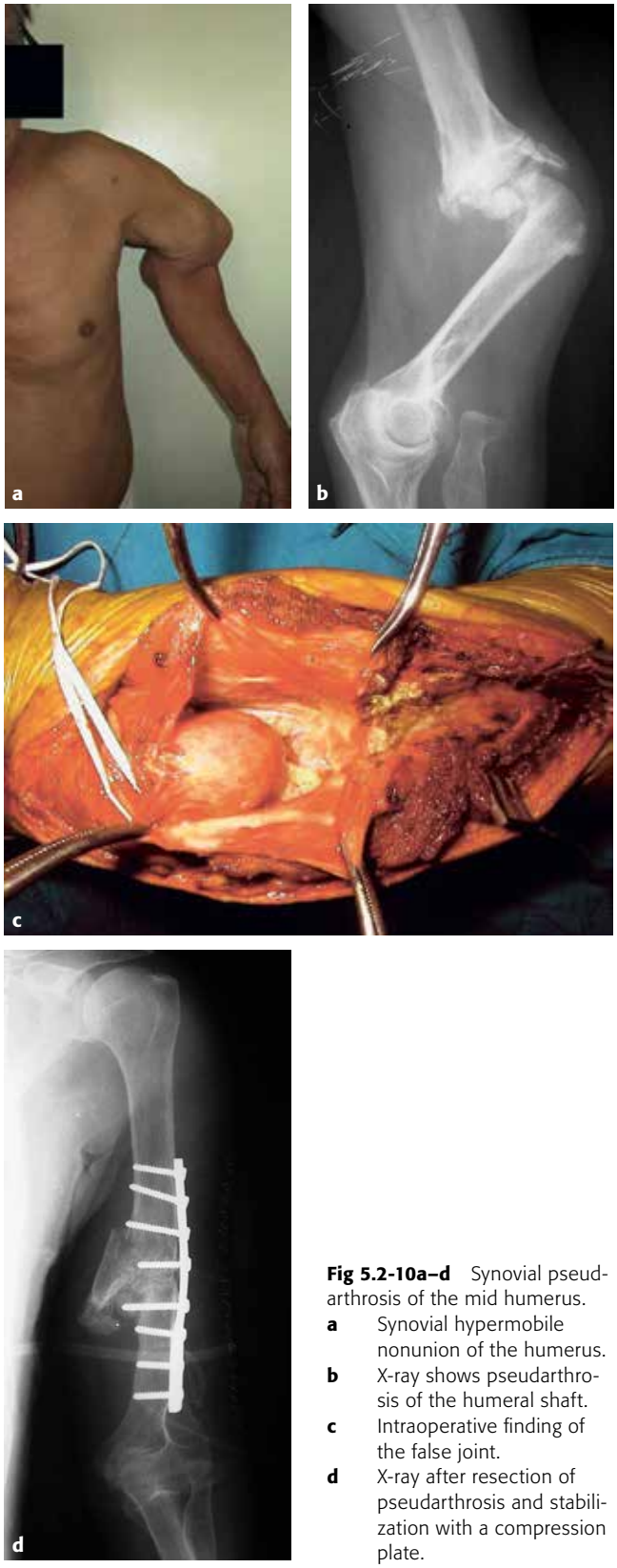

Fig 5.2-10a–d Synovial pseudarthrosis of the mid humerus.
a Synovial hypermobile nonunion of the humerus.
b X-ray shows pseudarthrosis of the humeral shaft.
c Intraoperative finding of the false joint.
d X-ray after resection of pseudarthrosis and stabilization with a compression plate.

in the periosteum should be followed by exposure of the bone with a Judet decortication leaving shingles of bone on the undersurface of the elevated periosteum and a raw bleeding bony surface on the bone itself [15, 16]. This leaves a viable bleeding bone surface all around the subsequent hematoma and above and below the fracture, and stimulates fracture healing (**Fig 5.2-7**). The tissue in the nonunion site does not need to be removed, as it has the potential to heal under the correct mechanical environment. The key is then to neutralize any persisting strain at the fracture site, particularly shearing forces, by compression either with a plate (and the articulating compression device) or a lag screw or, ideally, both.

6.2 Bone grafting/autograft

Cancellous autograft, often used in combination with decortication, is considered the gold standard to add a biological stimulus to bone healing. It can be applied as a morselized graft (osteogenic) or as a structural graft (tricortical or bicortical iliac crest) to replace a defect. Structural grafts need to be incorporated into any fixation with absolute stability and under significant compression to be stimulated to incorporate. Autograft has the advantages of being osteogenic (a source of vital bone cells), osteoinductive (recruitment of local mesenchymal cells), and osteoconductive (scaffold for ingrowth of new bone). Biologically, it is superior to allograft or currently available bone substitutes, although there can be morbidity associated with its harvest site (hematoma, fracture, nerve injury, blood loss requiring transfusion). Current data suggest that with good decortication realignment and appropriate fixation, particularly under compression, bone grafting is rarely required unless there is bone loss or biological failure [15].

The RIA technique was developed for bone graft harvesting from the medullary canal of the femur or tibia using the reamer and aspirating the reamed material from the canal and collecting it in a container. The autograft harvested using the RIA achieves similar union rates with significantly less donor-site pain. The RIA also yields a greater volume of graft compared with anterior iliac crest bone graft and has a shorter harvest time compared with posterior iliac crest bone graft [19, 20] (but there may be considerable blood loss).

6.3 Allografts, bone substitutes, and bone mesenchymal stem cells

Allograft and bone substitutes, such as demineralized bone matrix, hydroxyapatite, tricalciumphosphate as well as osteoinductive substances such as growth factors, bone morphogenetic proteins, etc, are currently being explored experimentally and clinically. To date they have not yet

proven to be superior to or able to replace cancellous autograft [20]. Due to their osteoinductive and/or conductive capacity, most of these substances can contribute to the reconstruction of bone but they all require a vital environment to be effective. The excess stimulation of cellular mechanisms with highly active biologically active molecules is still a source of concern.

Bone mesenchymal stem cells with growth factor injected at the nonunion or delayed union site has been reported to be a safe and effective method to treat these conditions [23].

6.4 Adjuvant treatments

Additional adjuvant treatments including electromagnetic fields, ultrasound, and biological manipulations have all been proposed.

Electromagnetic stimulation and ultrasound have been extensively applied and advocated to stimulate bone healing [24]. Both are probably not beneficial in the treatment of acute fractures regarding time to radiological and clinical union.

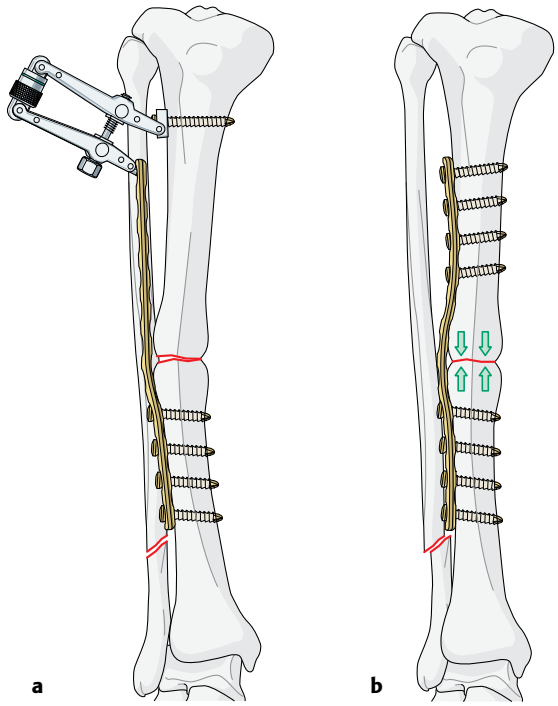

Fig 5.2-11a–b Using the articulated tension device to create maximum compression and stability at the nonunion site. Note the plate is on the convexity of the deformity, the tension side and prebent to equalize the compression over the whole nonunion site as the compression is applied.

7 Stabilization

7.1 Plating

The plate is the best option for stabilization of a nonunion. It allows compression, correction of any malalignment, and biological stimulation (decortication or grafting) in a single procedure.

Plates can be applied in metaphyseal and diaphyseal nonunions. In oblique nonunions, the absolute stability required can either be created by the initial placement of a lag screw with the plate used to protect the lag screw fixation or by a "compression into the axilla" technique described in chapter 3.2.2. If bone quality allows, the optimum axial compression for a transverse nonunion involves prebending the plate and the use of the articulated tension device (**Fig 5.2-11**), as the excursion for axial compression provided by the plate holes is usually too short to generate adequate compression. If soft tissue allows, optimum neutralization of excess strain will be achieved by placement of the plate on the tension side of the bone. On occasion a wave plate has been used to treat a nonunion and allow placement of a cancellous bone graft between the plate and the bone, which may enhance healing (**Fig 5.2-12**) [21]. However, it may be prominent and not possible in poor soft-tissue situations. The main disadvantage of plating is the need for restricted weight bearing for 2–3 months.

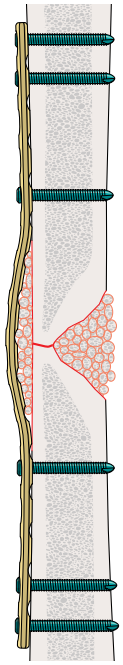

Fig 5.2-12 Wave plate principle with a locking compression plate. It consists of two components:
1. The distance between the narrow bony bridge between the two main fragments and the laterally lifted plate increases the functional diameter of the nonunion site and increases stability,
2. The distance between the plate and the nonunion allows placement of autograft in contact with bone, all around the nonunion site.

7.2 Intramedullary nailing

Intramedullary nailing has its main application in diaphyseal nonunion of the femur and tibia. A nail will realign the canal and neutralize asymmetric strain forces, and a tight fit in the canal will confer good but not absolute stability. The reaming required to place the nail has considerable biological effects that may include stimulating local blood supply, releasing numerous cytokines, and possibly bone morphogenetic proteins [6, 20]. Widening of the canal allows the use of a large, tight-fitting nail while dynamic interlocking provides axial compression by weight bearing as well as rotational stability (**Fig 5.2-13**). It is likely that these are all important factors in promoting union and have been shown to be effective if there is no bone loss.

Bisphosphanate fractures are especially prone to delayed union and nonunion and so a surgeon should use large reamed nails to anticipate extended periods of presumptive healing.

To introduce the guide wire for the reamer, the medullary cavity must usually be opened with the hand reamer. If an open approach is used to correct deformity, it is important to close the soft-tissue envelope around the nonunion site before reaming to keep the reaming debris locally. As power reaming of a sclerosed bone segment may generate excessive heat, the reamer heads must be sharp and regularly cleaned.

A major advantage of reamed locked nailing in the lower extremity is the ability to allow early weight bearing. Reamed nailing has few advantages in the upper extremity where insertion site morbidity remains a problem. Thin, unreamed, unlocked nails are not suitable as they provide insufficient stability.

For even more stability in recalcitrant femoral and tibial nonunions, supplemental compression plates have been used successfully to obtain union [25].

7.3 External fixation

In most aseptic nonunions, simple (uniplanar) external fixation has little benefit. Circular frame fixation using the Ilizarov method provides excellent stability and is an effective management method for diaphyseal nonunion. Circular frames can be used to correct deformity and also to transport bone segments to replace bone loss by osteogenesis. However, the process is time consuming, fraught with complications, and poorly tolerated by some patients. The most useful application of the Ilizarov technique is with poor soft tissues, especially if soft-tissue contractures also need gradual correction. The Ilizarov technique is also effective for complex multiplanar deformities when a single-stage correction may be difficult and hazardous and in cases of infected nonunion.

8 Treatment in specific situations

8.1 Articular nonunion

Nonunion of an intraarticular fracture is relatively rare, particularly when modern fixation methods are used to achieve anatomical reduction of articular fractures. Failure of accurate reduction leads to joint degeneration due to major articular step-offs, axial malalignment, and instability. An intraarticular nonunion is particularly damaging as persisting articular instability causes rapid joint degeneration. It is possible that constant synovial fluid in the fracture site is a factor preventing bony healing (**Fig 5.2-5**).

The surgical management of the unstable, intraarticular nonunion requires meticulous planning to recreate joint alignment and axis. Simple fracture patterns are easier to

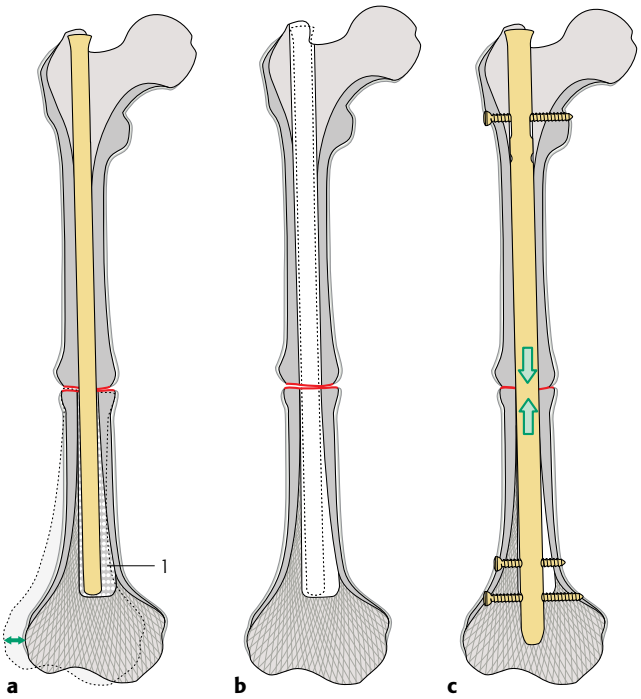

Fig 5.2-13a–c Hypertrophic nonunion after unlocked intramedullary nailing of the femur.
a Instability due to a short unlocked nail creating a resorption cavity (1) in the distal femur.
b–c After removal of the nail, additional stability can be gained by overreaming and insertion of a thicker and longer, dynamically locked nail.

manage but some degree of callus removal to allow recreation of the fracture line is always required and makes surgery much more difficult than a primary reduction. Joint surface reduction, axis realignment, and stabilization to the shaft are required. The possibility of correction depends upon the degree of damage to the joint surface and the feasibility of correcting both the bone deformity and any associated soft-tissue contracture. If significant degenerative change is present and correction is not possible, then joint arthrodesis or joint replacement may be a better alternative.

8.2 Metaphyseal nonunion

If nonunion develops in a complex periarticular fracture, it most commonly occurs in the metaphyseal area and usually has an oblique orientation with a single plane nonunion at the area of highest strain. In general, the articular fragments heal. Surgical management of the nonunion requires deformity correction (if required) and stabilization to neutralize the strain. At the hip, this usually involves correction of deformity with a valgus osteotomy and stabilization under compression with an angular stable device (**Fig 5.2-14**). Correction into valgus converts a tension moment (due to varus deformity) into a more stable situation with compression across the femoral neck nonunion.

Small periarticular segments with a nonunion create a difficult problem because of their size. The small articular fragment may limit options for fixation. Modern angular stable periarticular locking plates that provide strong fixation into the joint fragment are useful.

8.3 Diaphyseal nonunion

Without previous implants, correction of deformity, decortication and compression plating are the standard management principles for diaphyseal nonunion. The presence of previous implants complicates both the assessment and management and the surgeon must be wary of subclinical infection. Failure of bone healing results in persistent and

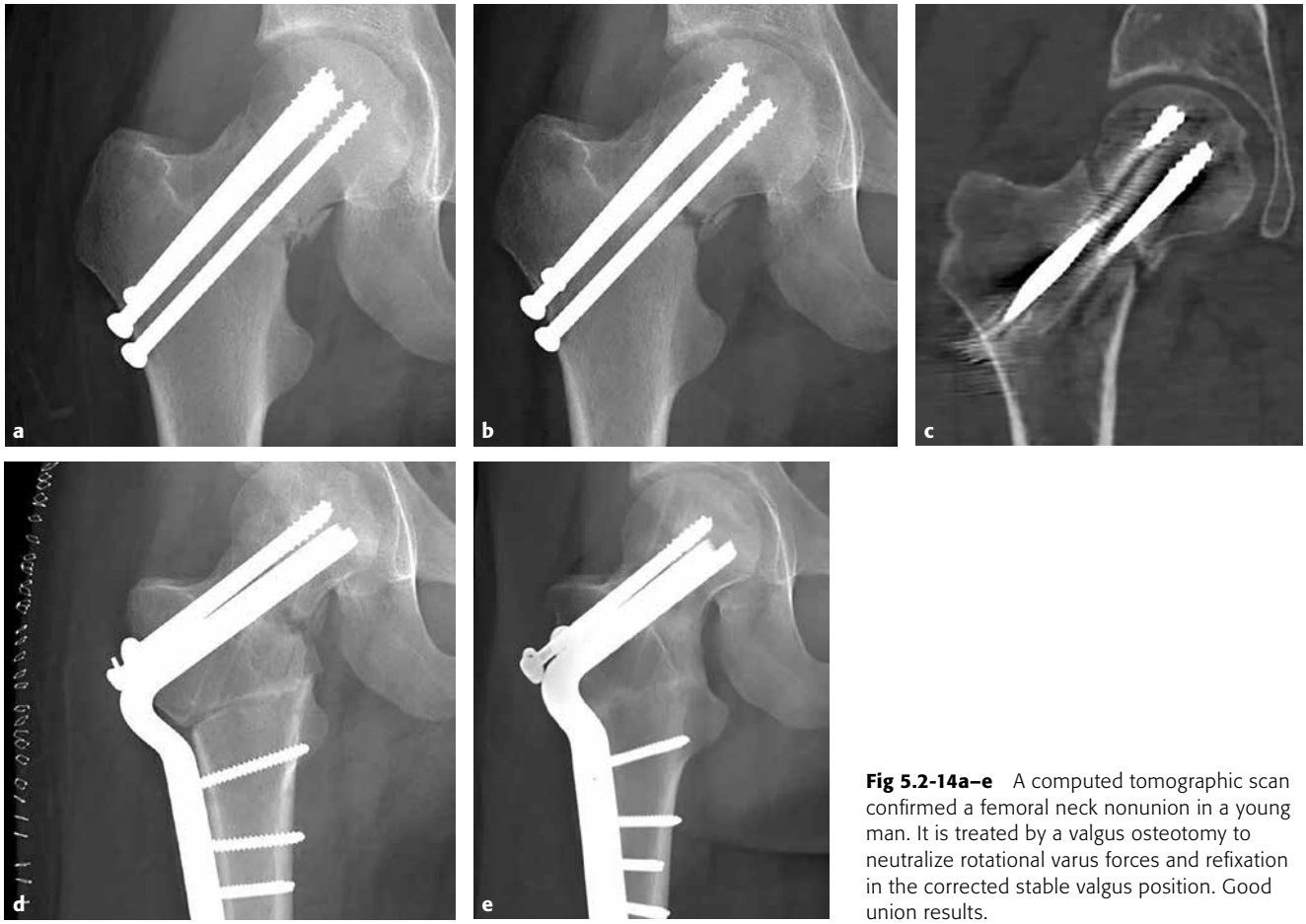

Fig 5.2-14a–e A computed tomographic scan confirmed a femoral neck nonunion in a young man. It is treated by a valgus osteotomy to neutralize rotational varus forces and refixation in the corrected stable valgus position. Good union results.

repetitive strain to an implant, which may eventually break or loosen. Intact implants in patients cause less pain and prevent motion on examination. They also obscure the radiographic assessment of the nonunion. Oblique x-rays or CT scan with multiplanar reformats may be required to confirm the diagnosis. The presence of the implant complicates surgical management and will need to be removed. In all nonunion surgery, multiple bacteriological samples should be taken to rule out infection.

Diaphyseal nonunion with a nail in situ provides a specific situation (**Fig 5.2-15**). The options to provide additional stability include:

- Simple screw removal for nail dynamization
- Exchange nailing
- Additional (small) locking compression plate fixation [25]
- Removal of the nail and standard compression plating
- Removal of the nail and circular frame fixation

Exchange nailing involves removal of the old nail, re-reaming of the canal, and placement of a new, slightly larger locked nail.

If the diaphyseal nonunion is malaligned without hardware in place, neutralization of the asymmetric strain across the nonunion by correction of the bony axis to normal is an essential part of surgical management. In some situations closing or opening wedge corrections may be used, while in others an elegant long oblique uniplanar osteotomy with lag screws and neutralization plate correction is effective.

8.4 Bone reconstruction/defects

A small wedge defect may be ignored in nonunion surgery and will not need special reconstruction. But as the defect gets larger (more than 4–6 cm), and segmental defects are present, special techniques are required [26]. These range from massive cancellous autografting to the Masquelet spacer/grafting technique, bone transport, or free microvascular bone (usually fibula) transfer. All techniques require application of the same principles: healthy soft tissues, good axial alignment, and stable fixation. Bone defects surrounded by healthy muscle coverage and held with stable fixation in good alignment may heal spontaneously.

8.5 Severe osteoporosis

Population demographics show that nonunion in elderly patients is an increasing clinical problem. In this age group, inadequate fracture fixation and pain can lead to disuse of the extremity, which in time will worsen the osteoporosis. Conventional plates may not provide enough stability to deal with this problem but locking plates provide more pullout resistance in poor bone. Additional techniques including intramedullary allograft cortical bone struts, double plating, intramedullary plating, and complex replacement arthroplasty can be effective but should be reserved for the expert.

Fig 5.2-15a–d Management of a nonunion after nailing by removal of the nail, correction of the valgus deformity with a uniplanar osteotomy through the apex of the deformity and nonunion site, as well as fixation with lag screw and neutralization plating. It leads to solid bone healing.

Classic references | Review references

9 References

1. **Brinker MR, O'Connor DP, Monla YT, et al.** Metabolic and endocrine abnormalities in patients with nonunions. *J Orthop Trauma.* 2007 Sep;21(8):557–570.
2. **Amorosa LF, Buirs LD, Bexkens R, et al.** A single-stage treatment protocol for presumptive aseptic diaphyseal nonunions: a review of outcomes. *J Orthop Trauma.* 2013 Oct;27(10):582–586.
3. **Westgeest J, Weber D, Dulai S, et al.** Factors associated with development of nonunion or delayed union after an open long bone fracture: a prospective cohort study of 736 subjects. *J Orthop Trauma.* 2016 Mar;30(3):149–155.
4. **Weber BG, Cech O.** *Pseudarthrosis. Pathophysiology, Biomechanics, Therapy, Results.* Bern: Huber; 1976.
5. **Scolaro JA, Schenker ML, Yannascoli S, et al.** Cigarette smoking increases complications following fracture: a systematic review. *J Bone Joint Surg Am.* 2014 Apr;16;96(8):674–681.
6. **Giannoudis PV, MacDonald DA, Matthews SJ, et al.** Nonunion of the femoral diaphysis: the influence of reaming and non-steroidal anti-inflammatory drugs. *J Bone Joint Surg Br.* 2000 Jul;82(5):655–658.
7. **Perren SM.** Evolution of the internal fixation of long bone fractures. The scientific basis of biological internal fixation: choosing a new balance between stability and biology. *J Bone Joint Surg Br.* 2002 Nov;84(8):1093–110.
8. **Claes LE, Heigele CA.** Magnitudes of local stress and strain along bony surfaces predict the course and type of fracture healing. *J Biomech.* 1999 Mar;32(3):255–266.
9. **Kenwright J, Gardner T.** Mechanical influences on tibial fracture healing. *Clin Orthop Relat Res.* 1998 Oct;(355 Suppl):S179–190.
10. **Elliott DS, Newman KJH, Forward DP, et al.** A unified theory of bone healing and nonunion: BHN theory. *Bone Joint J.* 2016 Jul;98-B(7):884–891.
11. **Schilcher J, Koeppen V, Aspenberg P.** Risk of atypical femoral fracture during and after bisphosphonate use. *N Engl J Med.* 2014 Sep 4;371(10):974–976.
12. **Reed AA, Joyner CJ, Isefuku S, et al.** Vascularity in a new model of atrophic nonunion. *J Bone Joint Surg Br.* 2003 May:85(4):604–610.
13. **Reed AA, Joyner CJ, Brownlow HC, et al.** Human atrophic fracture non-unions are not avascular. *J Orthop Res.* 2002 May;20(3):593–599.
14. **Hierholzer C, Glowalla C, Herrler M, et al.** Reamed intramedullary exchange nailing: treatment of choice of aseptic femoral shaft nonunion. *J Orthop Surg Res.* 2014 Oct 10;9:88.
15. **Ramoutar DN, Rodrigues J, Quah C, et al.** Judet decortication and compression plate fixation of long bone non-union: is bone graft necessary? *Injury.* 2011 Dec;42(12):1430–1434.
16. **Judet PR, Patel A.** Muscle pedicle bone grafting of long bones by osteoperiosteal decortication. *Clin Orthop Relat Res.* 1972 Sep;87:74–80.
17. **Babu S, Sandiford NA, Vrahas M.** Use of Teriparatide to improve fracture healing: what is the evidence? *World J Orthop.* 2015 Jul;18:6(6):457–461.
18. **Carragee EJ, Hurwitz EL, Weiner BK.** A critical review of recombinant human bone morphogenetic protein-2 trials in spinal surgery: emerging safety concerns and lessons learned. *Spine J.* 2011 Jun 11(6):471–491.
19. **Dawson J, Kiner D, Gardner W 2nd, et al.** The reamer-irrigator-aspirator as a device for harvesting bone graft compared with iliac crest bone graft: union rates and complications. *J Orthop Trauma.* 2014 Oct;28(10):584–590.
20. **Nauth A, Lane J, Watson JT, et al.** Bone graft substitution and augmentation. *J Orthop Trauma.* 2015 Dec;29 Suppl 12:S34–38.
21. **Ring D, Kloen P, Kadzielski J, et al.** Locking compression plates for osteoporotic nonunions of the diaphyseal humerus. *Clin Orthop Relat Res.* 2004 Aug;(425):50–54.
22. **Van Houwelingen AP, McKee MD.** Treatment of osteopenic humeral shaft nonunion with compression plating, humeral cortical allograft struts and bone grafting. *J Orthop Trauma.* 2005 Jan;19(1):36–42.
23. **Desai P, Hasan SM, Zambrana L, et al.** Bone mesenchymal stem cells with growth factors successfully treat nonunions and delayed unions. *HSS J.* 2015 Jul;11(2):104–111.
24. **Busse J, Bhandari M, Einhorn T, et al.** Reevaluation of low intensity pulsed ultrasound in treatment of tibial fractures (TRUST). *BMJ.* 2016;355:i5351.
25. **Nadkarni B, Srivastav S, Mittal V, et al.** Use of locking compression plates for long bone nonunions without removing existing intramedullary nail: review of literature and our experience. *J Trauma.* 2008 Aug;65(2):482–486.
26. **Molina C, Stinner D, Obremsky W.** Treatment of traumatic segmental long bone defects. *JBJS Rev.* 2014 Apr;2(4):e1.

10 Acknowledgments

We would like to thank Michael McKee and Peter Ochsner for their contributions to this topic in the second edition of the *AO Principles of Fracture Management.*

5.3 Acute infection

Olivier Borens, Michael S Sirkin

1 Introduction

Implant-associated infections occur in about 5% of surgically treated fractures [1]. Acute infections associated with fracture fixation devices are generally acquired from outside the body exogenously, ie, by microbial contamination. Contamination may occur during the trauma itself, eg, open fractures, during surgery and insertion of a fracture fixation device, or postoperatively following disturbed wound healing [2]. Less frequently, microorganisms from an endogenous source, eg, by hematogenous, by contiguous or lymphogenous spreading, may adhere to an implant. A distant infectious focus may be found in the skin or respiratory tract, or be of dental or urogenital origin [3]. Endogenous infections can occur at any time after device implantation, even years later. Late hematogenous infection is a major problem in periprosthetic joint infection but rare in infections following fracture fixation [4].

2 Onset of infection

The relatively high incidence of infection of fracture fixation devices is due to impaired host defense. Host proteins rapidly coat foreign devices after implantation. Several of these host proteins, such as fibronectin and laminin, favor the adherence of microorganisms (mainly bacteria) to foreign surfaces. Trauma or surgery will expose the body to bacterial invasion, and depending upon host defenses, the tissue surface exposed to the environment will be colonized. Rapidly during this "Race for the Surface" [1], adhering bacteria start producing a glycocalix of exopolysaccharides and after a couple of hours start to resemble a multicellular organism [5, 6]. This biofilm resists natural cellular and humoral host defenses and antibiotics [7].

The extent of trauma has a direct impact on the incidence of infection and guides the treatment options. If an infection occurs, remove necrotic and avascular tissue including bone and eradicate the biofilm, otherwise an acute infection may become chronic. Antibitotic treatment alone can only play an adjuvant or suppressive role.

With infection in the presence of a fracture fixation implant, the primary goals of treatment are fracture healing and the prevention of chronic osteomyelitis. The administration of antibiotics without concomitant surgery usually fails to eradicate an infection, which may then evolve into chronic osteomyelitis.

In contrast to prosthetic joint infections, complete eradication of infection is not always the primary goal, since the implant can be removed after fracture healing. The nature of the surgical intervention in patients with an infected implant [1, 8] depends on the following:

- Type of device
- Stability of the bone-implant interface
- Type and virulence of infecting organism
- Presence or absence of bone union
- Condition of soft tissues
- Health of the patient

2.1 Classification of infection

Infections after internal fixation are classified according to its onset which often relates to the route of infection (**Table 5.3-1**) [9]:

- Early (within 2 weeks)
- Delayed (in week 3–10)
- Late (after 10 weeks)

The first manifestation of infection may include clinical, laboratory, microbiological, or histological findings and does not reflect the time of contamination, which may precede the first manifestation of infection by days, months, or years. Delayed and late onset infections are usually grouped together, since their clinical presentation, treatment, and prognosis are similar. Not all early infections are acute; symptoms, such as wound discharge or erythema, may last for a variable period. Occasionally, progression of osteomyelitis is slow and may have been present from the time of osteosynthesis.

2.2 Early infection

Early infections occur less than 2 weeks after surgery. The leading clinical signs are persistent local pain, erythema, swelling, disturbed wound healing with or without drainage, and fever. Highly virulent organisms, eg, *Staphylococcus aureus*, Gram-negative bacilli, frequently cause early infection.

Early infections need to be distinguished from wound dehiscence and necrosis of the wound edges, as well as posttraumatic or postoperative hematoma.

Disturbed wound healing. Delayed wound closure is generally associated with microbial contamination. As long as the host is able to overcome these microorganisms, clinical signs of infection, eg, fever, swelling, and pain, are absent and laboratory parameters of inflammation remain normal (leukocytes, C-reactive protein [CRP], and erythrocyte sedimentation rate). Antiseptic dressings may prevent secondary wound infection. Wound treatment using prolonged vacuum-assisted closing techniques should be avoided [10] and definitive soft-tissue cover established as early as possible to reduce the risk of infection.

Wound edge necrosis. Devitalized wound edges become necrotic and local excision, sterile dressings and split-skin grafting may be needed for healing. As in the case of disturbed wound healing, flaps may be required for areas of exposed bone or hardware.

Time of onset of symptoms	Characteristics
Early infection (within 2 weeks after implantation)	Clinical picture: signs of wound infection such as persistent fever, pain, erythema, swelling, wound-healing disturbances, drainage
	Typical microorganisms: *Staphylococcus aureus,* group A streptococci, Gram-negative bacilli
Delayed infections (3–10 weeks after implantation)	Clinical picture: persistent pain, low-grade fever, mechanical instability, sinus tract
	Typical microorganisms: low virulence microorganisms such as coagulase-negative staphylococci or mixed skin flora in the case of a sinus tract
Late infection (>10 weeks after implantation)	Clinical picture: acute hematogenous infection, sepsis syndrome, local pain, and signs of inflammation; chronic delayed infection or recurrence of previously treated early infection; signs of infection after interval with bridging symptoms such as pain, wound-healing disturbances, delayed union/nonunion
	Typical microorganisms: *S aureus* and *Escherichia coli;* any microorganism, including polymicrobial infection and fungi

Table 5.3-1 Classification of infections after osteosynthesis according to the onset of symptoms [9].

Wound hematoma. These hematomas may be prevented by meticulous hemostasis and wound closure together with postoperative pressure dressings. Any large hematoma provides an ideal medium for growth of microorganisms. A painful or fluctuating hematoma requires immediate surgical drainage, debridement, and microbiological investigation.

We suggest avoiding the term "superficial wound infection," since it often minimizes a potentially serious complication. Neglecting these complications may lead to an acute infection. Simple measures, if performed early, may prevent infections in the postoperative course.

2.3 Delayed and late infection

The manifestation of delayed infection occurs later than 2 weeks and up to 10 weeks after surgery. It is often preceded by atypical systemic (eg, low-grade fever) or local symptoms (eg, persistent or increasing pain, implant loosening, mechanical instability, and development of a sinus tract or wound drainage). However, clinical manifestations of infection may be completely absent in some cases. The microorganisms that cause late infection may be introduced during penetrating trauma or during surgery. Delayed and late infections are caused by a small inoculum of microorganisms of low virulence, eg, coagulase-negative staphylococci, *Propionibacterium acnes*. Alternatively, inadequate initial antimicrobial treatment, especially without surgical intervention, can delay the manifestation of any infection. In contrast to infections after prosthetic joint replacement, hematogenous infections related to fracture fixation devices are rather rare [4]. The longer the duration of infection and the larger the area of infected and/or dead bone or damaged soft tissue, the more radical the intervention and the longer treatment is required.

2.4 Implant-associated infections

Implant-associated infections are typically caused by microorganisms growing in biofilms [2, 11]. These microorganisms live in clusters in a highly hydrated extracellular matrix attached to a surface.

The initial phase of microbial adherence is followed by an accumulative phase during which bacterial cells form a biofilm [13]. Whereas "free-living" planktonic microorganisms remain susceptible to antibiotics and immune defenses of the host (antibodies and phagocytes), biofilm microorganisms resist antibiotics and immune defenses and survive protected in the biofilm matrix (**Fig/Animation 5.3-1**).

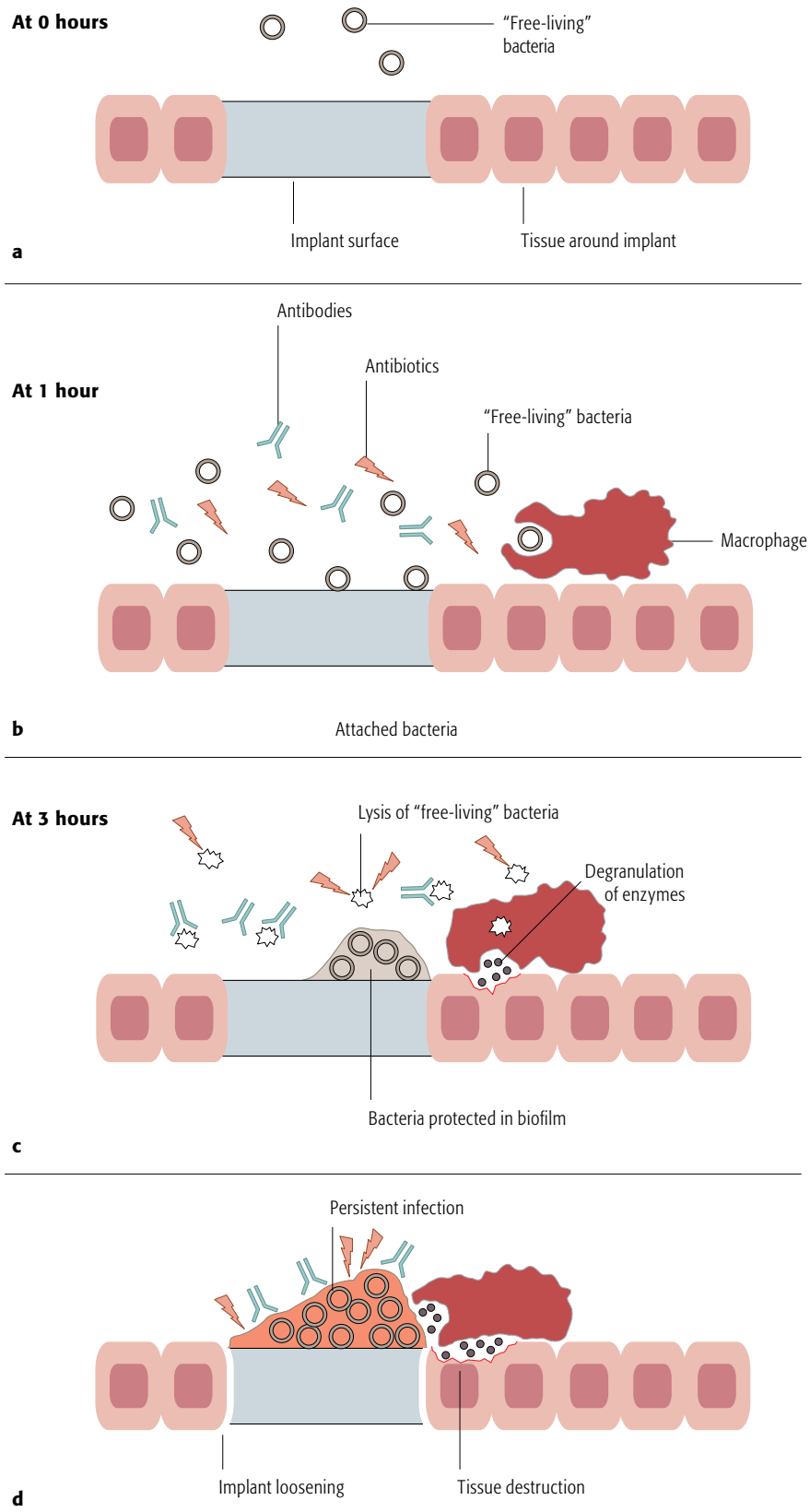

Fig 5.3-1a–d Pathogenesis of implant-associated infections.

a "Free-living" bacteria can contaminate the surgical site during the perioperative period.

b Within 1 hour, bacteria attach to the surface of the implant and change into the biofilm mode of growth.

c Biofilm bacteria produce extracellular matrix that protects embedded microorganisms, whereas free-living bacteria are eliminated by antibiotics and the immune system (ie, antibodies and phagocytes).

d Established microbial biofilm is responsible for persistent chronic infection, causing septic loosening of the implant.

Depletion of metabolic substances and/or accumulation of waste products in biofilms cause microbes to enter into a slow-growing or nongrowing (stationary) state, rendering them up to 1,000 times more resistant to most antimicrobial agents than their "free-living and replicating" counterparts [12].

Microbiological susceptibility tests to antibiotics are performed on growing planktonic microorganisms and not on "dormant" ones in the stationary phase of growth. This may explain the discrepancy between good in vitro susceptibility and poor clinical outcome in vivo. In addition, the presence of a foreign body significantly increases the susceptibility to infection. For example, the minimal infecting dose of *Staphylococcus aureus,* causing an abscess in guinea pigs, was more than 100,000-fold lower near subcutaneous devices than in skin without a foreign body [14]. The increased susceptibility to infection is at least partially due to a locally acquired granulocyte deficiency induced by frustrated phagocytosis.

Some antibiotics can eliminate non-growing microorganisms protected by a biofilm in the presence of stable implants. Examples include rifampin in staphylococcal and quinolones in Gram-negative infections.

2.5 Osteomyelitis, concomitant septic arthritis

Acute osteomyelitis: Bacteria can easily colonize necrotic bone as the empty Haversian canals or osteocyte cavities allow them to evade endogenous defense mechanisms. There is a need for a certain amount of space in order to build up a defense barrier [15]. The body can only eliminate infection by increased bone resorption and remodeling of vital areas. A dead, infected bone fragment that becomes loose, termed a sequestrum, has little chance of complete resorption. Such a sequestrum can only be rejected by fistulation or surgical excision, as it behaves like a foreign body. Defense mechanisms against infection are more successful within the bone marrow than in cortical bone. Cierny et al [16] observed that medullary infections have a more favorable prognosis than infections in the presence of extended bone necrosis. Four types of osteomyelitis are differentiated (**Fig 5.3-2**).

When considering exogenous posttraumatic osteomyelitis, we recommend defining the type of osteomyelitis in relation to the fracture fixation technique used, since this will aid in treatment rationale and decision making.

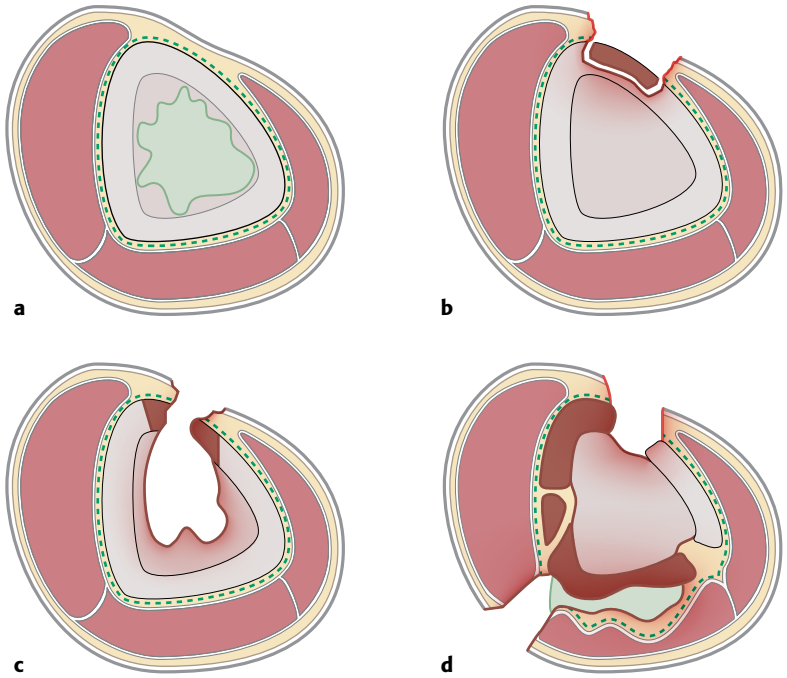

Fig 5.3-2a–d Anatomical classification of adult osteomyelitis according to Cierny and Mader [16].

a Type I: medullary osteomyelitis. Infection within the medullary cavity, usually without involvement of the epiphyseal area.

b Type II: superficial osteomyelitis involving the outer cortical area, the subcutaneous tissue, and the skin. The infection resides within an isolated area consisting of cortical sequestra and granulation tissue.

c Type III: localized osteomyelitis involving the whole cortex and the adjacent medullary canal. Pin-track infections and plate infections serve as examples.

d Type IV: diffuse osteomyelitis as a fully developed disease of the entire bone. It involves both the cortex and the medullary cavity, leading to extensive devitalization of bone.

Chronic osteomyelitis: This insidious condition can be diagnosed clinically by its slow progression and by its specific histology with a more lymphoplasmocytic picture [15]. The infection is often chronic at the time it is first recognized.

Neglected osteomyelitis: Posttraumatic osteomyelitis not treated by surgical means frequently leads to situations characterized by chronic fistulation, pain, and infected nonunion. Chronic osteomyelitis with fistulation can even lead to malignant transformation (Marjolin ulcer) [17].

Concomitant septic arthritis: Immediate recognition and treatment of periarticular posttraumatic infection is essential to prevent involvement of the joint. Late diagnosis and treatment may rapidly lead to chondrolysis and severe degenerative changes in the joint. Prompt treatment of acute osteomyelitis, on the other hand, may prevent infective arthritis.

3 Risk factors for osteomyelitis

3.1 General predisposing factors

The risk of an infection is increased by various factors, both general and local. Local factors include open fractures, wound contamination, venous stasis, occlusive arterial disease, extensive scarring, neuropathy, chronic lymphatic edema, chronic skin conditions (eg, psoriasis), vasculitis, and radiation fibrosis. General factors include diabetes mellitus, poor nutrition, renal and liver failure, chronic hypoxia, autoimmune diseases, malignancy, age, immunosuppressive treatment, agranulocytosis, and abuse of nicotine, alcohol, or drugs.

3.2 Bone and soft-tissue damage

Direct high-energy injuries to the limb may lead to extensive soft-tissue damage, whether fractures are closed or open. This is associated with greater risk of bone and soft-tissue necrosis and of microbial contamination with pathogenic organisms if open wounds are present. The more extensive the damage to bone and surrounding tissues, the greater the risk of local bone necrosis and contamination when osteosynthesis is performed (**Fig 5.3-3a**). Open fractures, especially with increasing severity, are particularly susceptible to infection.

3.3 Technique of fracture fixation

In general, the surgical approach for osteosynthesis should be planned to be as least invasive as possible. Incisions must be carefully positioned to avoid traumatic skin lesions and allow correct anatomical exposure so that surgery can take place without excessive traction on the skin. Indirect reduction, avoiding direct exposure of the fracture site, must be considered.

Vital muscle and periosteum must be preserved and left in contact with the bone whenever possible but all dead tissue must be excised.

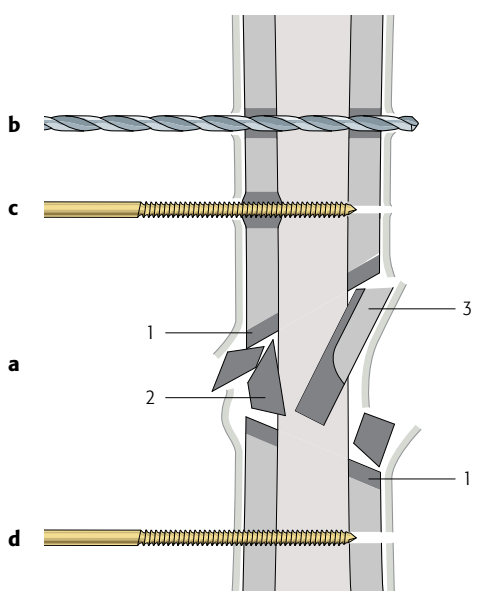

Fig 5.3-3a–d Consequences of incorrect/correct insertion of pins or screws for external fixation.

a Complex fracture caused by direct trauma.
1 Devitalized margins of the main fragments.
2 Devitalized intermediate fragments.
3 Partially vital intermediate fragments still attached to the periosteum.

b Drilling at excessively high speeds or with blunt drill bits produces heat necrosis in cortical bone.

c Insertion of the Schanz screws or Steinmann pins with no or inadequate predrilling produces considerable heat and small, necrotic fragments, or ring sequestrae.

d Correct predrilling, correct placement of the Schanz screw. This minimizes the risk of pin-track osteomyelitis.

3.3.1 External fixation

Although external fixation is considered the least invasive form of fracture fixation, erythema around external fixator pins is frequent and usually due to local irritation of the surrounding soft tissue. Rarely, osteomyelitis of cortical bone is observed as a consequence of heat necrosis after drilling with blunt drill bits or K-wires at excessive speed and power. Areas of necrotic bone may also result from forced insertion of Schanz screws or Steinmann pins into holes inadequately prepared or without predrilling (**Fig 5.3-3b–d**). Necrotic fragments in the form of ring sequestra provide an excellent medium for microorganisms, which can migrate along the percutaneously inserted implants. Bone resorption will cause loosening of the pins. Loose and mobile pins and pins that are not cleaned regularly are more susceptible to infection. Occasionally, chronic osteomyelitis reaching into the medullary canal may develop. Oral antibiotics are sometimes administered but will not eradicate the infection. Oral antibiotics may only help in decreasing local symptoms and may prevent spreading of infection. The exchange of a pin or screw with debridement of the pin site and insertion at a new site usually solves the problem and is preferred to suppressive antibiotics.

3.3.2 Plating

Even after correct application of a plate with preservation of the periosteum, devascularized areas will result at the interface between plate and bone (**Fig 5.3-4**). The circumscribed zone of bone necrosis that can be observed underneath a conventional compression plate will be remodeled by creeping substitution. Poor tissue handling with unnecessary periosteal stripping of the fracture can cause additional bone necrosis. Any contamination may lead to an infection that will spread along the surfaces of implants and exposed bone. Necrotic and infected bone fragments will eventually be demarcated and sequestrated, with subsequent loss of stability, leading to an infected nonunion [15]. Depending upon the location of a plate, subcutaneous or submuscular, the clinical symptoms of infection may differ considerably. Infection around a subcutaneous plate may develop after disturbed wound healing, skin breakdown, hematoma, etc. The diagnosis of infection can and should be made as early as possible. With a submuscular or subfascial plate position, eg, femur, an infection is often recognized late, as local clinical signs are rarely apparent except for pain and low fever. Prolonged wound drainage or the appearance of new discharge from a previously dry wound should raise suspicion. Ultrasound imaging may help to detect fluid, which can then be aspirated for culture, to be followed by thorough debridement.

3.3.3 Intramedullary nailing

Unreamed and reamed intramedullary nailing both lead to partial necrosis of the central parts of the cortex [9]. However, the periosteal blood supply mostly remains intact and contributes to cortical remodeling and fracture healing (**Fig 5.3-5**). Even if an infection has spread along the entire implant and medullary canal, periosteal bony bridging by external callus may occur during antibiotic suppression of the infection (**Fig 5.3-6**). In intramedullary nailing without reaming, cortical necrosis is somewhat less extensive than after a reaming procedure; however, the bone dust, which possibly enhances bony bridging, is absent. In open intramedullary nailing with surgical exposure of the fracture focus, additional periosteal stripping, loss of bone dust, and potential contamination must be considered. Dull, blunt reamers and heat necrosis from extensive reaming may lead to obstruction of the Haversian canals. Dead bone prevents normal fracture healing and in case of infection may lead to an infected nonunion which is especially difficult to salvage [18].

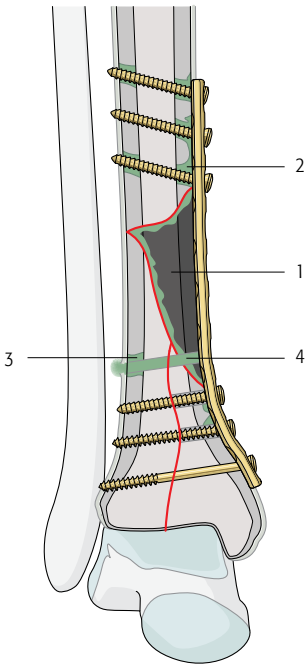

Fig 5.3-4 Osteomyelitis after plating.
Tibial shaft fracture extending into the joint, correctly fixed with two 3.5 mm lag screws and a 9-hole LC-DCP 4.5 without stripping the periosteum. An infection has spread along the implants and has its foci in the following:
1 Devitalized butterfly fragment.
2 Local areas of devascularized bone under the plate.
3 Necrotic areas resulting from incorrect drilling.
4 Empty drill holes.

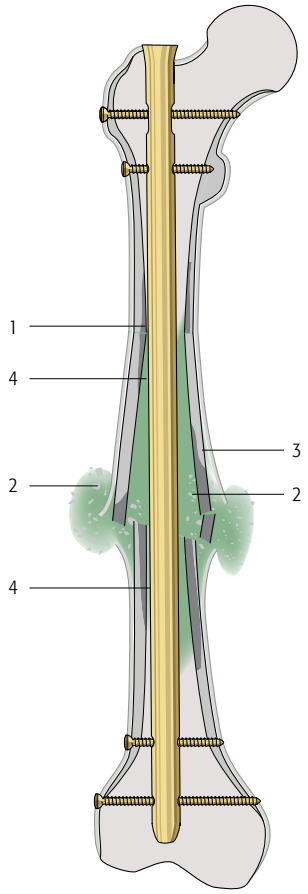

Fig 5.3-5 Osteomyelitis after intramedullary nailing. Complex femoral fracture stabilized by a closed, reamed, and locked intramedullary nail.

1 Devascularized inner cortex after reaming (dark).
2 Reaming dust mixed with fracture hematoma.
3 Fracture fragments partially stripped from periosteum.
4 Infection (green) spreading along the nail within the medullary cavity.

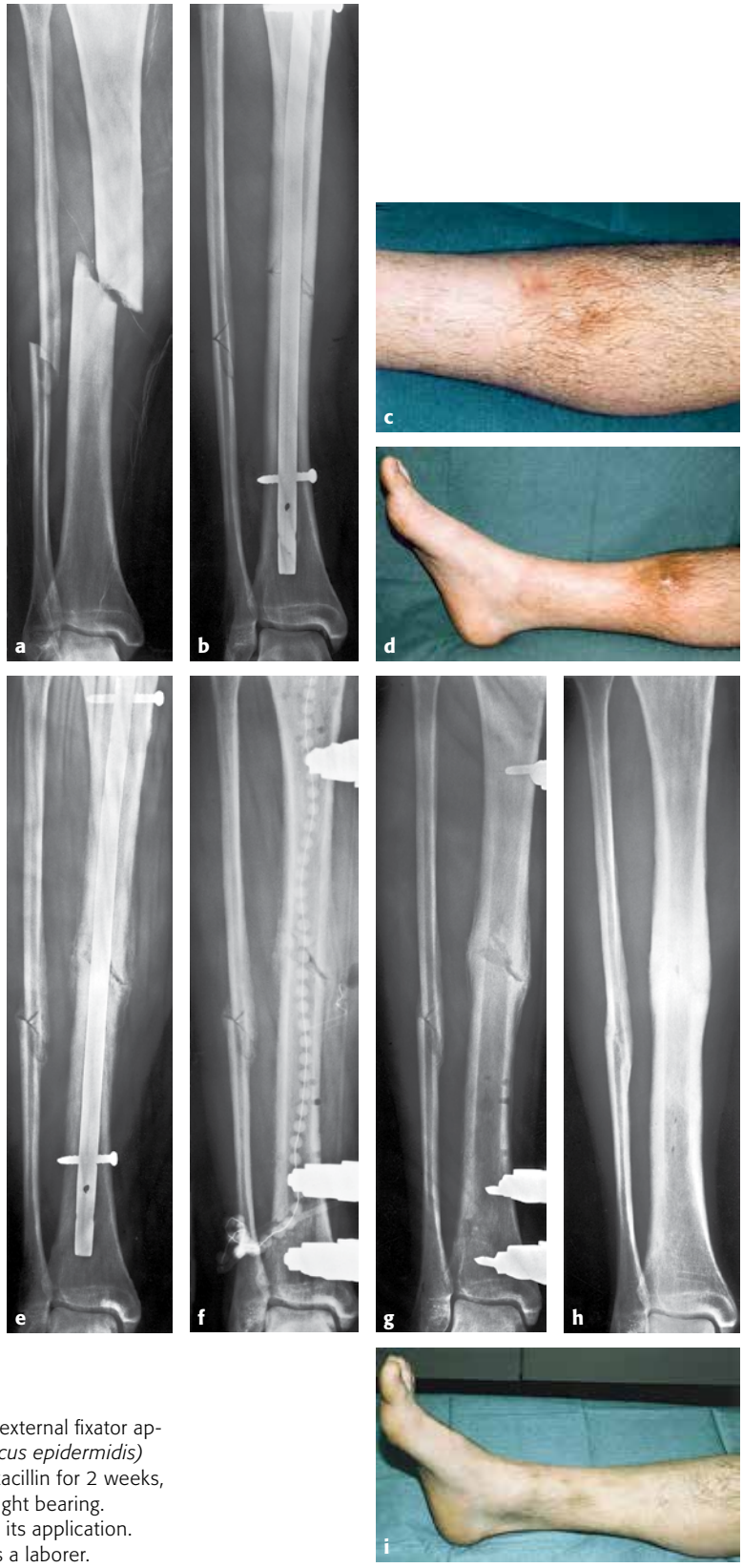

Fig 5.3-6a–i Osteomyelitis after intramedullary nailing.

a Simple oblique tibial fracture after being hit by a falling tree trunk.
b Fixation with a reamed universal nail, dynamically locked.
c Temporary redness after about 9 weeks.
d After 12 weeks, abscess formation and pain.
e Extensive callus bridging on the x-ray.
f Nail removed, medullary cavity reamed to 13.5 mm, external fixator applied, and antibiotic beads and abscess *(Staphylococcus epidermidis)* drainage placed. Intravenous administration of flucloxacillin for 2 weeks, followed by oral clindamycin for 4 weeks and full-weight bearing.
g External fixator is about to be removed 8 weeks after its application.
h–i At 2-year follow-up, the patient is working full time as a laborer.

4 Diagnosis of infection

4.1 Clinical and laboratory findings

Typical clinical symptoms, eg, erythema, pain, fever, and swelling, as well as pathological leukocyte count, CRP, and erythrocyte sedimentation rate often lead directly to the diagnosis. However, despite obvious local symptoms, there may be no corresponding abnormal laboratory values to support the clinical signs and this may delay decision making. A combination of clinical, laboratory, histopathological, microbiological, and imaging studies is usually required. After surgery, CRP usually remains elevated but should be decreasing by day 7. Therefore, repetitive measurements of CRP are more informative in the postoperative period than a single value. A secondary increase of CRP, after an initial postoperative decline, is highly suggestive of infection. Every surgeon has a tendency to underestimate unfavorable findings in their own cases. More experienced colleagues may need to be consulted and, if there is any doubt, the wound must be explored immediately. Occasionally, an acute posttraumatic infection may develop into septicemia. Such a serious situation must be treated aggressively, with intravenous antibiotics and surgery with wide exposure of the septic focus, which usually lies close to the metallic foreign body.

4.2 Imaging

In early infections, imaging procedures typically play a minor role. However, with delayed presentation imaging becomes important.

Ultrasound is useful to identify accumulations of fluid (hidden abscess, seroma, hematoma). The method is noninvasive and reaches deep layers, especially in the thigh. Ultrasound-guided aspiration of deep collections around a fracture fixation device can help make a diagnosis of infection and find the causative organism.

Plain x-rays remain the most important source of useful information. Examination of serial plain x-rays after implantation is helpful, but is neither sensitive nor specific for infection. Implant loosening may indicate either instability or infection, although in case of early loosening an infectious cause is more probable. The most important early sign is osteolysis around the screws. Widening of the fracture gap may be caused by infection or instability of the fixation. A lack of periosteal new bone formation may be a sign of infection or poor vascularity to the bone and subsequent failure of bone healing [19]. Importantly, overwhelming new bone formation can also be a sign of infection. Thus, there are no cardinal radiological signs and the clinician must maintain a high level of vigilance for infection.

Computed tomography (CT) is used to estimate the extent of soft-tissue involvement and gives additional information of the extent of bone necrosis. It is particularly helpful for identifying sequestra. Intravenous contrast may help to identify associated abscesses.

Magnetic resonance imaging (MRI) gives an improved resolution of soft-tissue abnormalities compared with CT or conventional radiography, and shows greater anatomical details than radionuclide scans. Another advantage is the ability to see the presence or absence of bone marrow edema and the extent of potential intramedullary involvement. The main disadvantages of CT and MRI are the artifacts related to metal implants, which are less with titanium than with stainless steel implants. However, new software, like MARS-MRI has improved the resolution of these images, even in the presence of metal implants.

Positron emission tomography (PET) and PET-CT appear to be valuable new techniques in the diagnosis of implant-associated osteomyelitis [20] but should be used only in selected cases in which more standardized techniques have not been helpful in diagnosing an infection.

Scintigraphic investigations include three-phase skeletal scintigraphy with 99mTc and scintigraphy with the patient's granulocytes labeled with indium or labeled antibodies against granulocytes. These nuclear medicine imaging techniques are sensitive but their specificity in the evaluation of implant-associated infection is poor and they are generally being replaced by MRI (and perhaps PET-CT in the future).

4.3 Microbiology and histopathology

Antibiotics should not be administered until tissue specimens have been obtained for microbiology unless the patient has signs of systemic infection, ie, septicemia. Even then, blood cultures must be obtained first.

Preoperative aspirate of fluid accumulation and intraoperative tissue harvesting (blocks of 5–10 mm) from several infected sites provide the most accurate specimens for detecting the infecting microorganism. At least three to five areas are sampled as close to the infected site and implant as possible, using clean instruments for each new sample. Especially in delayed infections with less aggressive organisms, the harvesting of the samples close to the focus gives the best chance of finding the causative organism. The samples are sent for microbiology and for histopathology with precise documentation from where the samples have been taken (so-called parallel sampling in chronic infections).

In low-grade infections, pediatric blood culture bottles are helpful in order not to miss anaerobic pathogens. Anaerobic bacteria should be considered in cases where there are dead spaces, extensive tissue necrosis, and tissue with poor vascularity [22]. The degree of infiltration with acute inflammatory cells may vary considerably between specimens from the same patient. Histological investigation can reveal a bacteriological etiology even if the bacteriological test results are negative. It is also possible to determine whether an acute infection is recent or has developed from a chronic infection. The histological analysis of a bone specimen is complex, takes a long time (decalcification), and is only of scientific significance [15]. Superficial swabs and the culturing of wound drainage must be avoided because of low sensitivity, wrong diagnosis, and frequent contamination by bacteria not responsible for the infection, eg, *Pseudomonas aeruginosa*. In chronic cases, prior to tissue sampling for culture it is important to discontinue any antimicrobial therapy for at least 2 weeks [23].

To increase the chance of finding the causative organism on infected hardware, it can be cultured in enrichment broth. A much more sensitive and specific way of diagnosing infection is the use of sonication. During sonication, the biofilm on the extracted implant is broken up and the bacteria become planktonic and can be cultured [24].

There are a multitude of new diagnostic techniques becoming available with the goal of making the diagnosis of infection in less than an hour and determining the organism in a couple of hours. One possible way is using calorimetry while another promising technique is the use of polymerase chain reactions [25, 26].

Perioperative antibiotic prophylaxis at revision surgery should not be started before tissue specimens have been collected for culture [24]. If the implanted material is removed, it can be cultured as well or even better be sent for sonication.

The most common microorganisms causing posttraumatic infection are staphylococci, followed by Gram-negative bacilli and anaerobes. In 25–30% of cases more than one pathogen is isolated and multiresistance is becoming a very important issue. In protracted infections, other pathogens may gain importance as a result of additional contamination and the possibility of fungal infection should be considered in injuries related to military conflict.

5 Treatment

If the first symptoms of infection appear early and are recognized, treatment according to some basic rules is usually successful. These rules include:

- Early and thorough wound debridement
- Microbiology to identify organism
- Wound lavage
- Adequate wound care and closure of dead space
- Soft tissue and bony stability often with a temporizing external fixator
- Treatment with appropriate antibiotics

The administration of antibiotics should be delayed until deep tissue samples for microbiology have been obtained unless the patient has life-threatening sepsis.

5.1 Debridement

Debridement is the surgical excision of all dead bone and infected tissue and requires exposure of the entire infected area (**Video 5.3-1**). In the presence of a sinus, instillation of methylene blue mixed with a radioopaque fluid helps to outline the extent of abscess formation by image intensifier intraoperatively. In early cases, debridement may be limited to the removal of an infected hematoma. Later it requires removal of:

- Abscess membrane
- Excessive granulation tissue
- Necrotic wound margins
- Dead bone splinters
- Sequestra

Video 5.3-1 Debridement of an infected tibia.

Tissue specimens are taken from multiple sites and sent for bacteriological and histological investigation. Clean instruments are used for each new specimen and it is recommended that operating rooms have an instrument pack that allows the surgeon to take each new specimen with a clean set of instruments to prevent cross-contamination.

After debridement, the surgical site should be thoroughly irrigated to decrease microbial counts. By decreasing microbial counts to less than 106 colony-forming units, the chances of successful treatment increase significantly, provided host defenses are intact and antibiotics appropriate. In cases with significant amounts of dead tissue or grossly purulent wounds, repeated debridement within 24–48 hours is indicated to decrease microbial load. After debridement, wounds may be closed over suction drains or covered by negative-pressure wound therapy (NPWT) and antibiotics started by empirical choice, while awaiting the results from antibiotic sensitivity tests. Alternatively, cement beads or biodegradable materials impregnated with antibiotics may be used and placed into the wounds but not at the expense of increased wound tension. If significant bone loss is present and bone grafting is expected, a cement block spacer may be inserted, as this will create and maintain a space for the subsequent graft. This space will become lined by an osteogenic membrane (Masquelet technique) which should not be removed at the time of definitive bone grafting [27].

5.2 Implant retention or removal

As long as an implant provides stable fixation, fracture healing can take place despite the presence of infection and a metallic foreign body. Carefully study the x-rays for signs of osteolysis around the screws and screw purchase should be tested at the time of debridement to determine whether these implants are providing the intended stability. Even an exposed plate can be left in place, only to be removed once bony bridging has occurred. If, however, implants have become loose, they must be removed and replaced by another kind of fixation, such as an external fixator to provide stability that is necessary for further fracture and soft-tissue healing. Occasionally, a plaster cast or orthotic device will be used but these often do not provide enough stability. If implants are left in place, antibiotic treatment must be carefully monitored.

Fracture healing will not take place in presence of infection without mechanical stability.

5.3 Infected intramedullary nails

The presence of an intramedullary nail may allow infection to spread along the medullary cavity (**Fig 5.3-6**). The intramedullary nail is removed and tissue biopsy specimens are taken for microbiology and histology and the nail is sent for sonication. A distal opening is created to allow debris from reaming to escape and the canal is then reamed to a diameter of 0.5–1.5 mm larger than the removed nail or until cortical contact occurs. This is based upon the assumption that there are areas of necrotic bone within the diaphysis (**Fig 5.3-5**). Using the reamer-irrigator-aspirator technique can prove even more helpful than standard reaming for cleaning out the medullary cavity and the infected endosteum [28]. A lavage is then performed.

Once the medullary canal is clean, there are a number of alternatives:

1. An antibiotic-loaded cement nail can be introduced for local antibiotic treatment and dead-space management [29] (**Video 5.3-2**). Next, this is exchanged to a standard locked nail when the infection is controlled (2-stage exchange nailing).
2. A standard locked solid nail can be used to provide stability where there is no bone loss and there is a known organism that is sensitive to antibiotics that penetrate biofilm. (**Fig 5.3-7**)
3. A standard external fixator can be applied [30].
4. A circular external fixator may be a useful alternative in the tibia.

In chronic infections, the reaming must be more radical and external fixation is usually required (**Fig 5.3-6**).

Video 5.3.2 Intraoperative manufacture of antibiotic-impregnated tibial intramedullary cement nail.

Fig 5.3-7a–s A 40-year-old man involved in a motorcycle crash sustained an open fracture of the tibia with no other medical comorbidities.

a–c Initial hospital management included emergent irrigation and debridement followed by reamed intramedullary tibial nail insertion with primary wound closure. Antibiotics included 48 hours of cefazolin. Preoperative (**a**) and postoperative x-rays (**b–c**).

d–e At 6 months he presented with drainage of the wound and x-rays showed no significant fracture healing.

f–h The patient was taken to the operating room for debridement, implant removal, irrigation, and placement of antibiotic rod for stability. Local and intramedullary debridement was performed. Flexible reamers were used to debride the canal and then the intramedullary canal was irrigated (**f**). Wound coverage was obtained from a hemigastrocnemius rotational flap on postoperative day 5. Cultures showed *Pseudomonas aeruginosa, Peptostreptococcus magnus*, and methicillin-resistant *Staphylococcus aureus*. He was administered vancomycin, tobramycin, rifampin, and imipenem. Antibiotic rod was placed in the distal tibia (**g–h**).

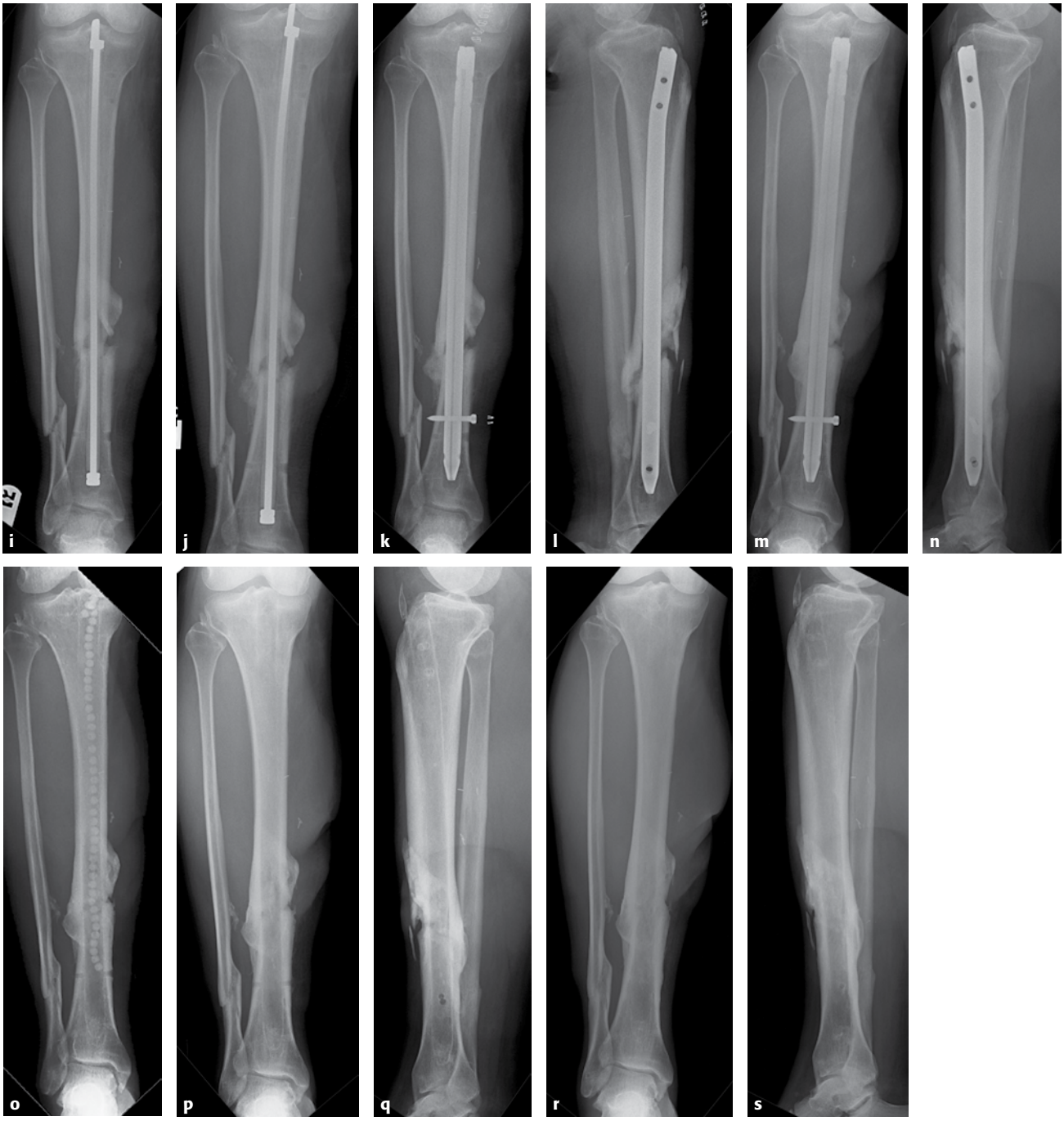

Fig 5.3-7a–s (**cont**) A 40-year-old man involved in a motorcycle crash sustained an open fracture of the tibia with no other medical comorbidities.

i 4-week postoperative x-ray after debridement, flap, and antibiotics.

j 8-week postoperative x-ray showing increased healing.

k–l At 10 weeks, the patient returned to the operating room for removal of antibiotic rod and biopsy and cultures were taken. All cultures were negative and the patient had a dynamic tibial nail inserted.

m–n The patient did well for 17 months, after which he returned with complaints of a draining sinus.

o–q The patient was taken to the operating room for removal of the nail. The intramedullary canal was debrided using a reamer irrigator aspirator. Cultures were positive for *Staphylococcus hominis* and *Staphylococcus epidermidis*. After his second debridement absorbable vancomycin-impregnated calcium sulfate beads were placed into the intramedullary canal. He was given oral levaquin.

r–s 10-year follow-up x-rays. No further problems were reported.

5.4 Open or closed wound treatment

Open wound treatment with NPWT is reliable, although rather slow. It prevents fluid retention and abscess formation and permits easy—even bedside—wound care.

Negative-pressure wound therapy should not be a surrogate for early flap cover of soft-tissue wounds.

Closed wound treatment is more risky but a more direct path to wound healing. Deep sutures should be omitted and efficient drainage with a wide-bore drain is necessary (**Fig 5.3-8**). Preferred options include nonresorbable or resorbable antibiotic or antiseptic carriers (eg, gentamicin beads, antibiotic impregnated calcium sulfate, resorbable collagen sponges with antibiotics) to raise the level of antibacterial agents in the debrided area.

5.5 Septic arthritis

At the slightest suspicion of septic arthritis, joint aspiration or arthroscopy should be performed to evaluate the involvement of the joint. Synovitis alone can be managed by antibiotic treatment. In the presence of fibrinous deposits and synovial tissue overgrowing cartilage, arthrosopic or open synovectomy may be indicated. Arthroscopic irrigation should be repeated every 2–3 days if clear clinical signs of ongoing infection persist and if two or three arthroscopic procedures have failed to control the infection, open synovectomy should be considered. In late arthritis with destroyed cartilage but proven asepsis, arthrodesis or delayed total joint prostheses may be unavoidable.

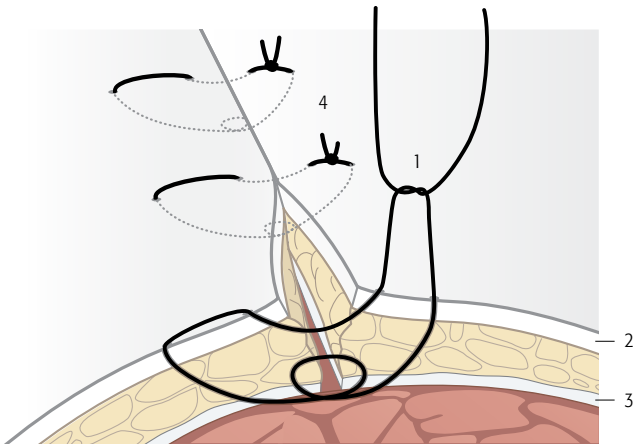

Fig 5.3-8 Suture technique in infected wounds.
Thick monofilament sutures (1) are used every 4–6 cm to secure the deeper levels of skin (2) and the fascia (3). Additional skin sutures (4) are placed in the spaces between the deep sutures.

5.6 Additional measures

In the absence of fracture healing, a change of fixation technique must be considered, usually to an external fixator. This may be combined with additional treatment of the bone (debridement and decortication). All necrotic tissue must be resected. If the resulting bone defect is small, delayed cancellous bone graft can be considered once repeat biopsies show no bacterial growth. Large and segmental defects may require distraction osteogenesis (as described by Ilizarov) or bridging by a vascularized bone graft (**Fig 5.3-9**).

5.7 The use of antibiotics and antiseptics

In posttraumatic osteomyelitis, antibiotics and antiseptics should only be considered as an adjuvant to radical operative treatment.

5.7.1 Antibiotics

The choice of the correct antibiotic regimen requires an interdisciplinary approach.

The choice of the ideal antibiotic regimen should be made together with the infectious disease specialist and microbiologist, as the treatment of infected fracture fixation devices is most successful with a multidisciplinary approach.

When the responsible microorganisms are not known, a broad-spectrum antibiotic is started immediately after intraoperative tissue specimens have been collected for microbiology. If a tourniquet is used, antibiotics are given intravenously 10 minutes before its release. This antibiotic is later replaced by a specific antibiotic according to the antibiotic sensitivity test. In contrast, if the pathogen is known before surgery, antimicrobial treatment is started 1–2 hours prior to the operation depending on the chosen antibiotic. The suggested duration of treatment is 3 months if the implant remains in place, and 6 weeks after removal or exchange of the fixation device [31]. Intravenous treatment should be administered for the first 2 weeks, followed by oral therapy if possible to complete the treatment course. Implantation of a tunneled catheter may facilitate long-term intravenous antibiotic therapy if there is no oral application available [32]. The resolution of clinical signs and normalization of the CRP, erythrocyte sedimentation rate, and the white cell count during treatment indicate the effectiveness of the treatment. The optimal antimicrobial therapy is evaluated for implant-related infections with staphyloccoci, and includes rifampin in susceptible staphylococcal strains [31]. Rifampin has excellent activity on the biofilm of staphylococci, and its efficacy is proven in several clinical studies [33]. It must always be combined with another drug to prevent

emergence of resistant strains. Rifampin combinations are used in Propionibacterium acnes infections as well [34]. For infections with Gram-negative organisms, quinolones are excellent combination drugs because of their good bioavailability, activity, and safety and efficacy against biofilm. Newer quinolones, such as moxifloxacin, levofloxacin, and gatifloxacin, have better in vitro activity against quinolone-susceptible staphylococci compared with ciprofloxacin.

If no antibiotic that is effective against the biofilm of adherent bacteria is available, antibiotic treatment with implant retention generally only suppresses the infection until the implants are removed.

In such cases, discontinue the antibiotics at least 2 weeks before removing the implants to collect reliable intraoperative tissue specimen for culture. If intraoperative cultures are positive, continue antimicrobial treatment for about 4–6 weeks after hardware removal to avoid development of chronic osteomyelitis.

5.7.2 Antiseptics

Antiseptics (originally carbolic spray) paved the way for modern surgery and their bactericidal properties are still indispensable for disinfecting surgeons' hands (eg, alcohol, iodine preparations, chlorhexidine) and the patient's skin. However, do not use these agents for the treatment of open wounds or bone because of their tissue toxicity. Alcoholic chlorhexidine is thought to be the best antiseptic for skin preparation [35]. A recent study [36] has proven that normal saline, and not soap, is the most efficacious fluid for irrigation solutions.

The use of antiseptics in joints is contraindicated, since the chondroblasts that are responsible for the regeneration of cartilage cells lie mainly on the joint surface. Due to the surface activity of antiseptics, these cells are destroyed.

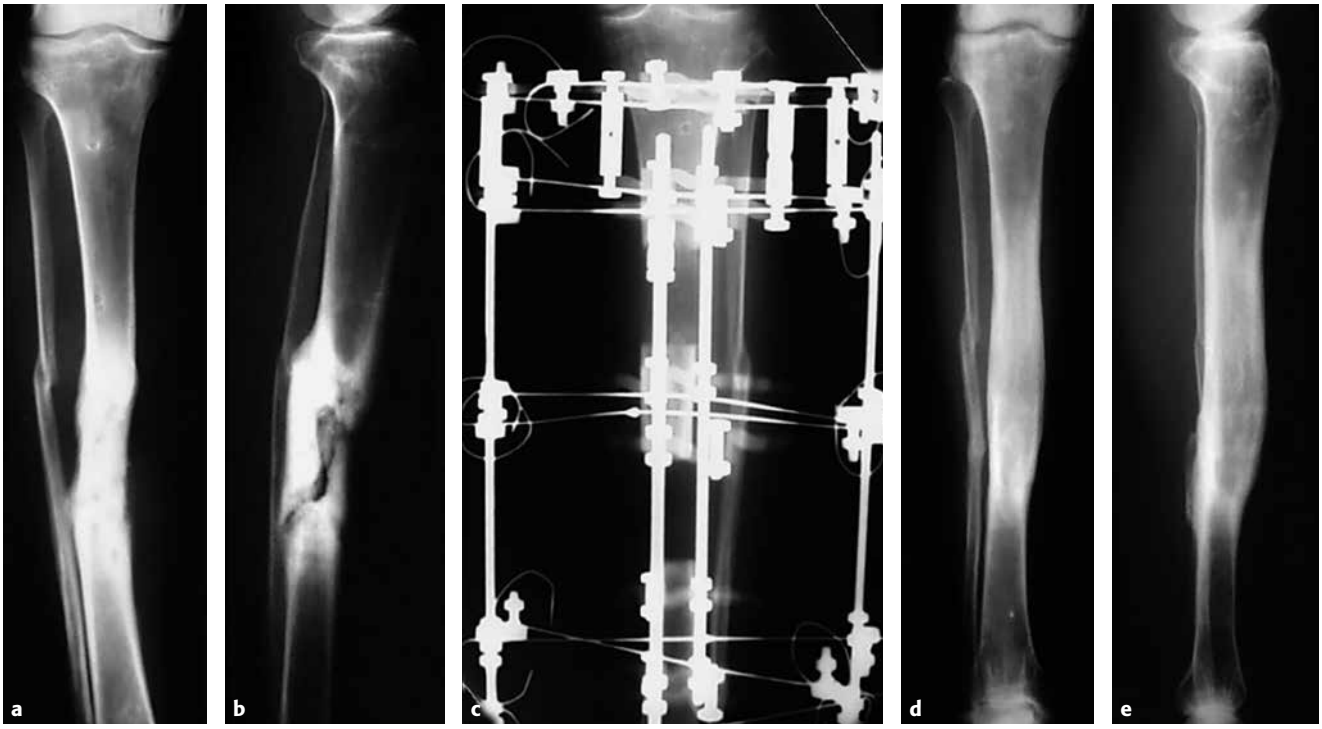

Fig 5.3-9a–e Reconstruction of an infected nonunion using bone transport and a circular frame. The infected nonunion and the segment of affected bone have been radically excised. Proximal corticotomy allows bone transport and regeneration. There is a massive hyperemic response in the bone to this treatment and this is believed to be an important factor in the eradication of infection. Final result after docking at the distal site and consolidation of the regenerated bone. The infection was eradicated and varus deformity corrected.

6 Treatment concepts in typical cases

6.1 Infection in cases of subcutaneous plate position

Debridement and assessment of stability, open wound treatment, and antiseptic dressing, or partial coverage and open drainage in the presence of adequate soft tissues (**Fig 5.3-10**) are possible. Implants are removed after 6 (eg, malleolar fractures) to 24 weeks (eg, olecranon, patellar fractures).

6.2 Infection in cases of submuscular plate position

Debridement is accompanied by assessment of the stability and function of the plate fixation. In the absence of non-viable bone fragments, irrigation and debridement and wound closure are followed by antibiotics for 6–12 weeks. A local antibiotic delivery vehicle may be used as well. The implant is removed as soon as solid bridging of the fracture has been confirmed.

6.3 Osteomyelitis after intramedullary nailing

If there are signs of bridging on the x-ray and the fixation appears stable, abscess drainage is followed by antibiotics until bridging is achieved. Having stopped the antibiotic therapy for 2 weeks, the nail is removed and the medullary cavity is reamed while antibiotics are continued for another 6 weeks according to new culture results. Without any signs of fracture bridging, the intramedullary nail and sequestra are removed, reaming of the medullary cavity is performed and followed by placement of an antibiotic nail (**Video 5.3-2**) with later removal and re-reaming and larger nail placement (two-stage revision).

Fig 5.3-10a–g Delayed first manifestation of infection after subcutaneous plating.
a–b Plate osteosynthesis of a multifragmentary malleolar fracture of the fibula.
c Day 21: Infection with *Staphylococcus aureus*, blood leukocyte count 18.5 x 109/L, serum C-reactive protein < 5 g/dL.
d Debridement and antiseptic dressing of the open wound. A cannula was inserted percutaneously to the deepest point of the infected region. Irrigation 4–5 times a day with an antiseptic via the cannula to keep the wound moist. Intravenous cefazolin was administered for 1 week, then ciprofloxacin for 4 weeks.
e Plate removal after 6 weeks, uneventful wound healing.
f–g Good functional result without osteomyelitis at 1-year follow-up.

6.4 Pin-track osteomyelitis in external fixation

If there is suppuration along Schanz screws, Steinmann pins, or percutaneous wires, x-rays help to identify possible ring sequestra (**Fig 5.3-3**). The following regimen is then followed: remove or replace the implant, perform curettage, remove sequestra, and irrigate. Antibiotics are needed only in cases of abscess drainage and/or positive cultures.

6.5 Concomitant septic arthritis

If findings from immediate joint aspiration are positive, sensitivity tests, arthroscopy to assess the degree of synovial changes, and antibiotics for 4–6 weeks are indicated. Depending on the clinical result, repeated arthroscopy is necessary but should not be repeated as a standard procedure.

7 Measures to prevent infection

Postoperative infections occur in about 1.5% of all orthopedic procedures. To decrease this number the surgeon has to know the risk factors that can lead to an infection and act accordingly. There are three types of risk factors (**Table 5.3-2**):

- Patient related
- Surgery related
- Operating room related

Many of these risk factors are well known but poorly managed.

Patient related	Surgery related	Operating room related
Not modifiable • Age • Severity of illness	**Preoperative patient preparation** • Showering • Nasal colonization • Exposed hair • Skin preparation • Surgical drapes • Perioperative antibiotics	• Ventilation and laminar flow • Number of people and amount of traffic
Modifiable • Hyperglycemia (diabetes) • Obesity • Malnutrition • Smoking • Immunosuppressive medications	**Preoperative surgeon preparation** • Surgical assistants • Surgical attire	
	Intraoperative • Surgical duration • Surgical techniques • Avoid hypothermia	

Table 5.3-2 Factors related to surgical site infections. Adapted from references 37 and 38.

Classic references **Review references**

8 References

1. **Darouiche RO.** Treatment of infections associated with surgical implants. *N Engl J Med.* 2004 Apr 1;350(14):1422–1429.
2. **Gristina A.** Biomaterial-centered infection: microbial adhesion versus tissue integration. *Science.* 1987 Sep 25;237(4822):1588–1595.
3. **American Dental Association, American Academy of Orthopedic Surgeons.** Antibiotic prophylaxis for dental patients with total joint replacements: advisory statement. *J Am Dent Assoc.* 2003;134:895–898.
4. **Murdoch DR, Roberts SA, Fowler VG Jr, et al.** Infection of orthopedic prostheses after Staphylococcus aureus bacteremia. *Clin Infect Dis.* 2001 Feb 15;32(4):647–649.
5. **Zimmerli W, Moser C.** Pathogenesis and treatment concepts of orthopaedic biofilm infections. *FEMS Immunol Med Microbiol* 2012;65(2):158–168.
6. **Moons P, Michiels CW, Aertsen A.** Bacterial interactions in biofilms. *Crit Rev Microbiol* 2009;35(3):157–168.
7. **Zimmerli W, Sendi P.** Pathogenesis of implant-associated infections: the role of the host. *Semin Immunopathol* 2011;33(3):295–306.
8. **Trampuz A, Widmer A.** Infections associated with orthopedic implants. *Current Opinions in Infectious Diseases.* 2006 19:349–356.
9. **Trampuz A, Zimmerli W.** Diagnosis and treatment of infections associated with fracture-fixation devices. *Injury.* 2006 37(Suppl 2):117–119.
10. **Yusuf E, Jordan X, Clauss M, et al.** High bacterial load in negative pressure wound therapy (NPWT) foams used in the treatment of chronic wounds. *Wound Repair Regen.* 2013;21(5):677–681.

11. **Trampuz A, Osmon DR, Hanssen AD, et al.** Molecular and antibiofilm approaches to prosthetic joint infection. *Clin Orthop Relat Res.* 2003;414:69–88.
12. **Stewart PS, Costerton JW.** Antibiotic resistance of bacteria in biofilms. *Lancet.* 2001;358(9276):135–138.
13. **Darouiche RO.** Device-associated infections: a macroproblem that starts with microadherence. *Clin Infect Dis.* 2001 Nov;33(9):1567–1572.
14. **Zimmerli W, Waldvogel FA, Vaudaux P, et al.** Pathogenesis of foreign body infection: description and characteristics of an animal model. *J Infect Dis.* 1982 Oct;146(4):487–497.
15. **Ochsner PE, Hailemariam S.** Histology of osteosynthesis associated bone infection. *Injury.* 2006 May;37 Suppl 2:S49–58.
16. **Cierny G 3rd, Mader JT, Penninck JJ.** A clinical staging system for adult osteomyelitis. *Clin Orthop Relat Res.* 2003 Sep;(414):7–24.
17. **Steinrücken J, Osterheld MC, Trampuz A, et al.** Malignancy transformation of chronic osteomyelitis: description of 6 cases of Marjolin's ulcers. *Eur J Orthop Surg Traumatol.* 2012(22):501–505.
18. **Ochsner PE, Baumgart F, Kohler G.** Heat-induced segmental necrosis after reaming of one humeral and two tibial fractures with a narrow medullary canal. *Injury.* 1998;29 Suppl 2:B1–10.
19. **Westgeest J, Weber D, Dulai S, et al.** Factors associated with development of nonunion or delayed healing after an open long bone fracture: a prospective cohort study of 736 subjects. *J Orthop Trauma.* 2016 Mar;30(3)149–155.
20. **Schiesser M, Stumpe KD, Trentz O, et al.** Detection of metallic implant-associated infections with FDG PET in patients with trauma: correlation with microbiologic results. *Radiology.* 2003 Feb;226(2):391–398.
21. **Gross T, Kaim AH, Regazzoni P, et al.** Current concepts in posttraumatic osteomyelitis: a diagnostic challenge with new imaging options. *J Trauma.* 2002 Jun;52(6):1210–1219.
22. **Larsen LH, Lange J, Xu Y, et al.** Optimizing culture methods for diagnosis of prosthetic joint infections: a summary of modifications and improvements reported since 1995. *J Med Microbiol.* 2012 Mar;61(Pt 3):309–316.
23. **Spangehl MJ, Masri BA, O'Connell JX, et al.** Prospective analysis of preoperative and intraoperative investigations for the diagnosis of infection at the sites of two hundred and two revision total hip arthroplasties. *J Bone Joint Surg Am.* 1999 May;81(5):672–683.
24. **Trampuz A, Piper KE, Jacobson MJ, et al.** Sonication of removed hip and knee prostheses for diagnosis of infection. *N Engl J Med.* 2007 Aug 16;357(7):654–663.
25. **Borens O, Yusuf E, Steinrücken J, et al.** Accurate and early diagnosis of orthopedic device-related infection by microbial heat production and sonication. *J Orthop Res.* 2013 Nov;31(11):1700–1703.
26. **Corvec S, Portillo ME, Pasticci BM, et al.** Epidemiology and new developments in the diagnosis of prosthetic joint infection. *Int J Artif Organs.* 2012 Oct;35(10):923–934.
27. **Masquelet AC, Begue T.** The concept of induced membrane for reconstruction of long bone defects. *Orthop Clin North Am.* 2010 Jan;41(1):27–37.
28. **Zalavras CG, Sirkin M.** Treatment of long bone intramedullary infection using the RIA for removal of infected tissue: indications, method and clinical results. *Injury.* 2010 Nov;41 Suppl 2:S43–47.
29. **Wasko MK, Borens O.** Antibiotic cement nail for the treatment of posttraumatic intramedullary infections of the tibia: midterm results in 10 cases. *Injury.* 2013 Aug;44(8):1057–1060.
30. **Thonse R, Conway JD.** Antibiotic cement-coated nails for the treatment of infected nonunions and segmental bone defects. *J Bone Joint Surg Am.* 2008 Nov;90 Suppl 4:163–174.
31. **Zimmerli W, Widmer AF, Blatter M, et al.** Role of rifampin for treatment of orthopedic implant-related staphylococcal infections: a randomized controlled trial. *Foreign-Body Infection (FBI) Study Group. JAMA.* 1998 May;279(19):1537–1541.
32. **Osmon DR, Berbari EF.** Outpatient intravenous antimicrobial therapy for the practicing orthopaedic surgeon. *Clin Orthop Relat Res.* 2002 Oct;(403):80–86.
33. **Trebse R, Pisot V, Trampuz A.** Treatment of infected retained implants. *J Bone Joint Surg Br.* 2005 Feb;87(2):249–256.
34. **Portillo ME, Corvec S, Borens O, et al.** Propionibacterium acnes: an underestimated pathogen in implant-associated infections. *Biomed Res Int.* 2013;804391.
35. **Harrop JS, Styliaras JC, Ooi YC, et al.** Contributing factors to surgical site infections. *J Am Acad Orthop Surg.* 2012 Feb;20(2):94–101.
36. **Bhandari M, Jeray KJ, Petrisor BA, et al.** A Trial of Wound Irrigation in the Initial Management of Open Fracture Wounds. *N Engl J Med.* 2015 Dec 31;373(27):2629–2641.
37. **Anderson DJ, Kaye KS, Classen D, et al.** Strategies to prevent surgical site infections in acute care hospitals. *Infect Control Hosp Epidemiol.* 2008 Oct;29 Suppl 1:S51–S61.
38. **Kapadia BH, Berg RA, Daley JA, et al.** Periprosthetic joint infection. *Lancet.* 2016 Jan 23;387(10016):386–394.

9 Acknowledgment

We thank Peter Ochsner and Andrej Trampuz for their contribution to this chapter in the second edition of the *AO Principles of Fracture Management.*

5.4 Chronic infection and infected nonunion

Stephen L Kates, Olivier Borens

1 Introduction

Chronic osteomyelitis and infected fracture nonunion remain serious problems in modern-day surgery. The emergence of multiple drug-resistant organisms has made treatment even more challenging than before. The etiology of osteomyelitis is often obvious when it follows an open fracture or other surgical procedures. In contrast, in children, osteomyelitis is usually of hematogenous nature and typically involves the medullary canal of a long bone. Early presentation is the rule and treatment is usually undertaken in the acute phase, rarely becoming chronic. Osteomyelitis becomes chronic when it is not eliminated in the acute phase and often persists for many years. Chronic osteomyelitis is frequently associated with an orthopedic implant and the implants are covered with biofilm, which inhibits both the human immune system and antibiotic agents from eliminating the bacteria.

The most common causative organisms are staphylococci, either *Staphylococcus aureus* or coagulase-negative staphylococci.

Less common are streptococcal infections and Gram-negative infections. In chronic infection states, there may be more than one infecting organism and this can make treatment more difficult.

In adults, medullary osteomyelitis typically occurs from an infected implant or open trauma to a long bone resulting in contamination of the medullary canal. Both the implant and the necrotic bony trabeculae caused by trauma create opportunities for bacteria to find a home in the medullary canal.

The organisms will form biofilm on the necrotic trabeculae and create micro-abscesses in the medullary canal.

An aggressive infection can penetrate the medullary canal either through a traumatic opening in the diaphysis or through septic penetration of the cortex.

Cortical osteomyelitis, on the other hand, is initiated when bacteria are introduced near the periosteal surface of the bone. The bacteria release toxins and other virulence factors that kill the fibroblasts, osteoblasts, and osteoclasts on the bone surface. Bacteria actually invade the osteocyte canaliculi and advance, likely by binary fission, up the canaliculus to the osteocyte lacuna, which they then occupy and become dormant. They can remain in this dormant state for many years only to be liberated by reduced immunity, or surgically by intramedullary reamer or drill bit (**Fig 5.4-1**).

When an orthopedic implant is in place, the organisms adhere to the implant using cell wall proteins known as adhesins.

Within 3 hours, an early biofilm has formed on the implant surface and by 2 weeks, the biofilm reaches the state of maturity that does not seem to change by 12 weeks or longer [1]. Bacteria emigrate from the biofilm progressively from 2 weeks onward and spread to surrounding tissues and perhaps into the bloodstream [1]. When the bacteria leave the biofilm, empty lacuna remain (**Fig 5.4-2**) [1].

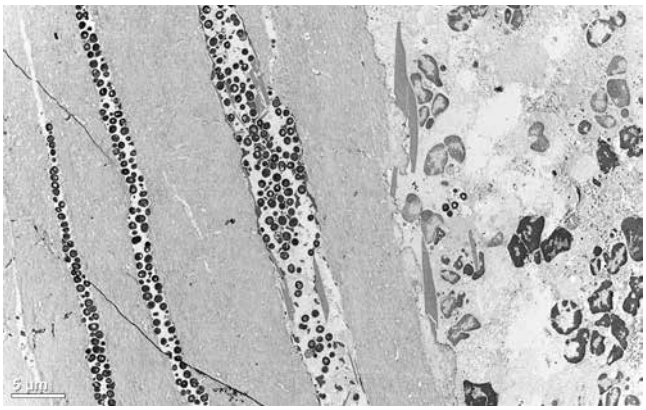

Fig 5.4-1 Electron micrograph demonstrating *Staphylococcus aureus* invading cortical bone. It has migrated up some cracks in the cortical bone and as such is not readily available to the surgeon or immune system for removal. (Photomicrograph courtesy of Karen deMesy Bentley.)

Most bacteria will form biofilm but staphylococci are notorious for resistant biofilm formation.

Many Gram-negative pathogens also possess a biofilm-forming capacity including *Pseudomonas aeruginosa, Escherichia coli, Klebsiella pneumoniae,* and *Acinetobacter baumannii*. The composition of the biofilm is complex, including polysaccharide, DNA from dead host cells, fibrin, and other local material from the fracture or surgical hematoma.

Antibiotics will penetrate biofilm but only with difficulty.

A notable exception is rifampin, which penetrates biofilm effectively [2]. As a consequence, chronic osteomyelitis with persistent drainage and sequestrum formation is resistant to eradication by antibiotics therapy alone.

The initial step in diagnosis of a chronic osteomyelitis is to obtain a bacteriological diagnosis.

This may be challenging and up to one third of chronic infections are culture negative. Infections typically become culture negative when antibiotic therapy is used before obtaining an actual culture [3].

Sinus tract cultures are unreliable. Options for obtaining a good culture include needle aspiration, open biopsy with tissue culture (at least three to five specimens), and polymerase chain reaction analysis. If possible, antibiotic therapy should be stopped for 2 to 3 weeks before obtaining a culture [3].

Surgical intervention combined with appropriate antibiotic therapy represents the only effective method to eliminate osteomyelitis, and the goal should be to eradicate the infection and promote healing.

2 Classification of osteomyelitis

2.1 Classification according to localization within the bone

Chronic osteomyelitis may be classified according to its localization within the bone [4, 5]. This classification (**Fig 5.3-2**) takes into consideration the importance of bone necrosis and vascularity, hence the more favorable prognosis of medullary infections.

The Cierny-Mader classification may help to direct surgical treatment. Four entities are differentiated:
- Type I (medullary)
- Type II (superficial)
- Type III (localized)
- Type IV (diffuse osteomyelitis causing instability of the bone)

2.2 Classification according to the implant

Classification of chronic osteomyelitis according to the implant involved has the advantage of being more specific for postoperative osteomyelitis. We can distinguish between pin-track osteomyelitis, plate osteomyelitis (either superficial or deep), and after intramedullary nailing (see chapter 5.3).

Typically, when one region of an implant becomes infected, the infection will spread over the length, width, and depth of an implant. The entire implant should be considered infected with a biofilm covering.

The surrounding osteomyelitis may affect the periosteal surface, medullary canal, or both.



Fig 5.4-2 Electron micrograph demonstrating *Staphylococcus aureus* biofilm. The small round spheres in the biofilm are staphylococci. Some empty lacunae are noted where the staphylococci have emigrated away from the biofilm. (Photomicrograph courtesy of Karen deMesy Bentley.)

3 Diagnosis of chronic infection and infected nonunion

3.1 Clinical and laboratory findings

Redness, warmth, pain, and localized swelling are classic findings. Additional findings include purulent drainage or culture-positive drainage from the surgical site. Discharge may be intermittent and localized in an area of scar tissue, limiting the possibilities of revision.

Laboratory values, such as erythrocyte sedimentation rate (ESR) and C-reactive protein (CRP), are usually elevated but may be normal depending on the virulence of the organism and activity level of the infection. Leukocyte counts are usually normal but may be elevated [6]. If positive, they are helpful in monitoring the treatment plan but negative findings do not mean that the disease is not present. Newer diagnostic tests are becoming available and are in the developmental phase to improve the speed and accuracy of diagnosis.

3.2 Bacteriology and histology

The bacteriological analysis should be based on a minimum of three to five deep-tissue samples of bone and granulation tissue from different areas affected by the infection.

Swabs should not be taken from either the fistula or the superficial discharge. They are not adequate and may be misleading in determining the agent, as there may be contamination with other bacteria. For implant-associated infections, to achieve maximum diagnostic yield, deep specimens should be obtained from a minimum of three to five sites around the implant at debridement. Sterile, unused instruments must be used to obtain each new sample. Microscopy with more than 5 neutrophils per high-power field suggests infection with a specificity of 93–97% [6]. Cultures should be incubated for up to 14 days to grow challenging organisms (eg, *Propionibacterium acnes*). The patient should stop antibiotic therapy for 2–3 weeks before culturing the site suspected of infection and perioperative antibiotics withheld until the specimens have been obtained.

3.3 Imaging techniques

A complete series of x-rays, from the original fracture to the current state, is helpful for the analysis of an infected nonunion.

Necrotic areas are usually recognized by a lack of adjacent, new bone formation, while sequestra may appear denser and often appear completely isolated (**Fig 5.4-3**) from the surrounding bone.

Currently, computed tomography (CT), magnetic resonance imaging (MRI), and positron-emission tomography (PET-CT) are the best methods to determine the extent of the disease and the location of sequestra. Consultation with an experienced radiologist is beneficial to decide which investigation is helpful, especially in the presence of metal implants.

A CT scan investigation may be preferred to demonstrate sequestration within periosteal new bone (**Fig 5.4-4**) [7], while MRI gives more information on soft-tissue involvement [6]. A PET-CT gives similar anatomical definition of bone infection to standard CT and also provides information about disease activity and has the highest sensitivity and specificity of all imaging modalities (**Fig 5.4-5**) [8].

Three-phase skeletal scintigraphy or special scintigraphy with, for example, radioactive indium or labeled antibodies against granulocytes are typically costly and less commonly used today. In special circumstances, they can be helpful [5, 7, 9–10].

Fig 5.4-3a–b The small dense fragment of necrotic bone seen adjacent to the tibial fracture is a sequestrum. It must be removed for successful treatment of the osteomyelitis.

Fig 5.4-4 A computed tomographic scan of a femoral nonunion that is infected with *Staphylococcus aureus*. The involucrum (1) and sequestrum (2) are readily seen.

3.4 Condition of the affected limb and of the patient

To evaluate the risks and benefits of any reconstruction, the limb distal to the infected focus must be carefully assessed. The vascularity and the sensibility of the limb and the function of the joints must be tested and correlated with the needs and expectations of the patient. The pros and cons of reconstruction of the limb or possible amputation, supported by a detailed treatment plan, must be discussed with the patient and relatives. It is essential that the surgeon gives the patient a realistic description of the treatment and potential outcomes. Note that prolonged limb salvage, which may take 2 or 3 years, may be psychologically debilitating for both the patient and their family.

Patient health and medical status (eg, obesity and diabetes mellitus) must be considered [11]. Smoking is a risk factor for infection and smoking reduction or cessation increase the likelihood of successful therapy of chronic infection and particularly infected nonunion [11]. Physical and psychological aspects must be considered. Patients may have been nonweight bearing for a long time and often require a further

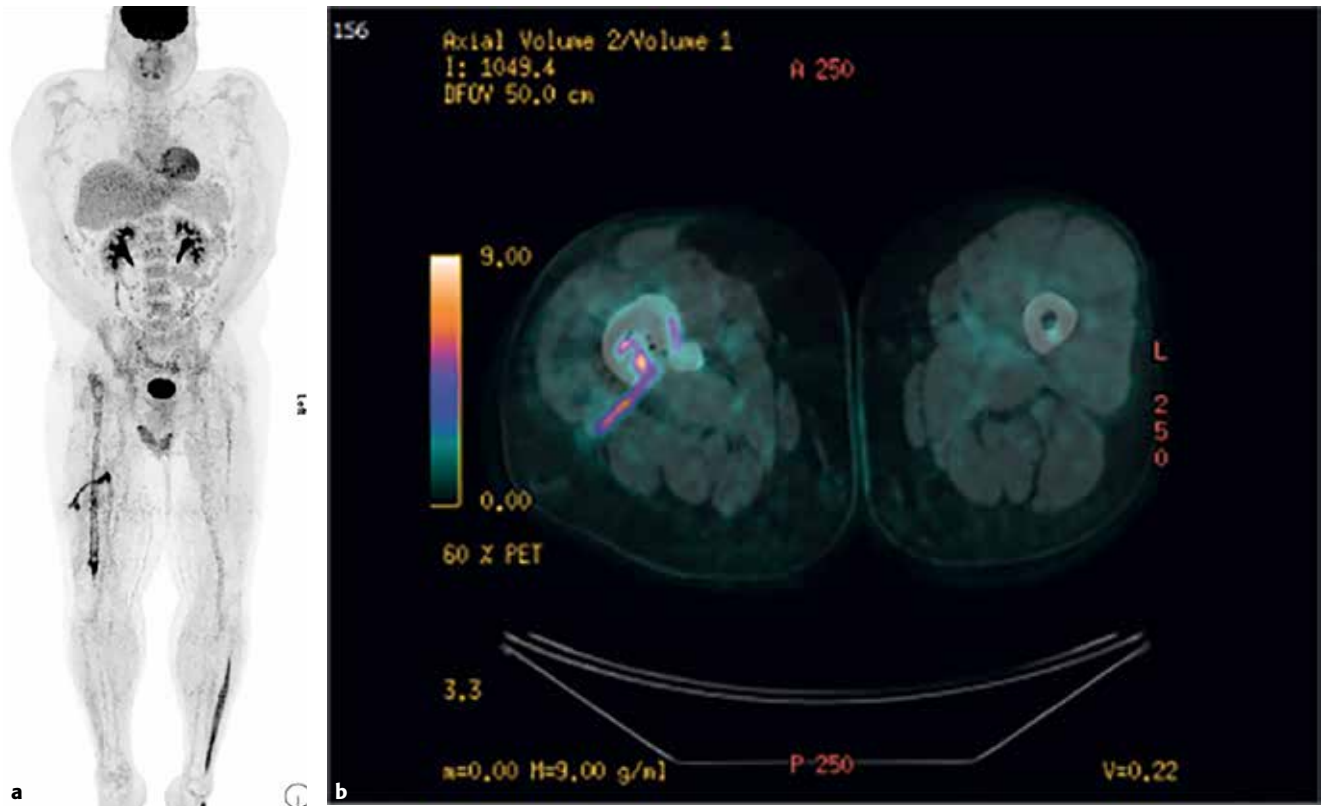

Fig 5.4-5a–b Positron emission tomogram (PET-CT) demonstrating a medullary infection with sinus formation following treatment of a femoral fracture with an intramedullary nail.

prolonged period of reconstruction. Disuse osteoporosis increases the difficulty of surgical fixation. Patients should be assessed nutritionally with serum albumin level and dietary assessment if possible to predict the ability to heal a fracture or wound [11]. Vitamin D levels should be adequate when dealing with cases of infected nonunion [12].

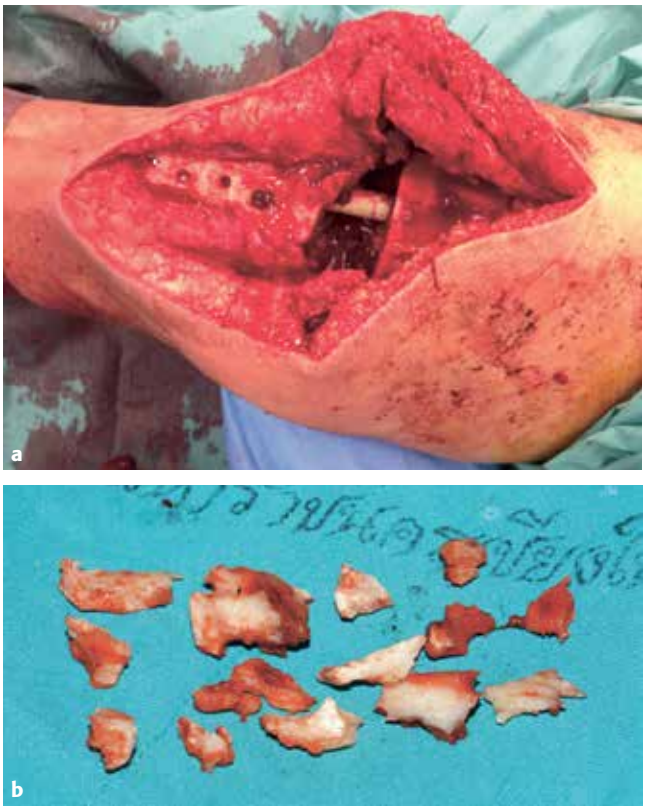

Fig 5.4-6a–b Photographs show the removal of dead bone from an infected fracture.

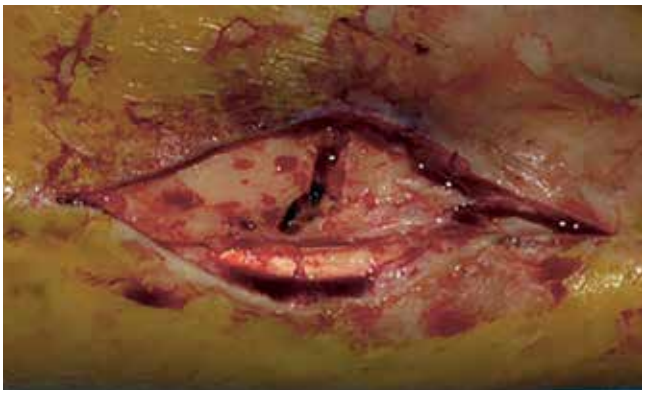

Fig 5.4-7 A paprika sign. The tiny red dots indicate bone that is now bleeding after debridement.

4 Principles of treatment

The principles of the management of chronic osteomyelitis and infected nonunions are:
- Identification of the causative organism(s)
- Treatment of the infection by surgical debridement
- Dead-space management
- Temporary bone stability
- Establishment of a viable and stable soft-tissue environment
- Organism-specific antibiotic therapy managed in cooperation with an infectious disease specialist
- Bony reconstruction and stabilization

Consider every case of osteomyelitis individually, since there is no standard procedure that can be routinely applied to every patient.

4.1 Debridement

All dead tissue, dead bone, all implants, old suture material, and sinuses must be removed.

To prevent the creation of additional necrotic bone, surgeons must be careful to avoid stripping of the vascularized periosteum. The resection of necrotic bone, which is in contact with vital bone, is the most difficult step. Dead bone does not show any bleeding points; it is brittle when removed (**Fig 5.4-6**).

Dead bone is best removed with a high-speed burr until bleeding is encountered (paprika sign) (**Fig 5.4-7**). Intramedullary debridement in the diaphysis is best done by intramedullary reaming. Sometimes, a second look debridement should be considered.

If there is mechanical instability, it is essential to stabilize the bone to help treat the infection.

4.2 Stabilization

Skeletal stability allows the following:
- Initiation of fracture healing
- Functional patient aftercare
- Easier wound care
- Stability for soft-tissue healing
- Maintains or restores length, alignment, and rotation
- Early weight bearing

Staged procedures may be required depending on the extent of infection, the degree of stability, and the condition of the patient.

4.2.1 External fixation

External fixation is a mainstay for stabilization of bone in infected nonunion. The external fixation may need to remain for a long period. To satisfy this demand, the chosen frame should be constructed more rigidly than with an acute fracture. The risk of pin-track infection is higher than usual. It may be necessary to replace one or more pins during the course of treatment. There are two fixation systems applicable: (1) a ring fixator with thin tensioned wires or half-pins or (2) a frame built from a tubular system with half pins, such as Schanz screws.

The tubular system (**Fig 5.4-8**) has the advantage of allowing easier access for wound care and soft-tissue reconstructive surgery. Its simplicity allows the system to be adapted to most clinical situations. Monotube systems may sometimes be easier to place but are less versatile.

Fig 5.4-8a–h The stages of care of an infected tibial fracture.
a–b Treatment begins with the external fixator and chains of beads to manage the infected fracture.
c–d Once the infection is under control, the fracture is managed with dual plating. Later however, the infection recurs and drainage occurs from the original open wound.
e–f At 3 years, the fracture has fully healed but still drains slightly.
g–h The implants are then removed, resulting in healing of the wound and functional extremity free of pain.

Ring fixators provide stable, circular arrangement of rings, which may be attached to the bone by multiple, thin pre-tensioned wires, as described by Ilizarov, or by half-pins or a combination of both. The circular construct provides excellent on-axis stability that allows immediate weight bearing. Circular frames can be used to provide compression or distraction and to lengthening bone segments, as well as the gradual correction of axial deformities [13, 14]. Tensioned wires with crusts of dried exudate intact are also reported to have fewer pin-related problems [15].

4.2.2 Plates and nails

It is essential with infected nonunion surgery to establish the level of stability still provided by an intact internal fixation. Loose, infected implants must be removed and preferably replaced by some other form of stable fixation.

Temporary fixation methods, such as an antibiotic cement nail or an antibiotic block spacer, are useful techniques to achieve stability, manage dead-space and administer some local antibiotic therapy.

4.3 Reconstruction of bone

As a rule, all measures for obtaining bony union are safer if carried out after a complete and meticulous debridement. In problematic cases, reconstruction of bone defects should be done in a staged manner (**Fig 5.4-8**).

Healing is more reliable if the reconstructive measures are pursued in an area of vital tissue with healthy skin and soft-tissue coverage.

4.3.1 Autogenous cancellous bone graft; decortication

Before use of bone graft, it is absolutely essential to perform meticulous debridement, remove infected implants, and establish there is no residual evidence of infection. Cancellous bone is harvested, preferably from the anterior or posterior iliac crest. Dense pieces of cancellous bone are morsellized, which allows for quicker vascularization with minimal risk of sequestration. Use of the bone graft to fill a bony void created by debridement is one reliable way of filling the void. It is essential to have healthy bleeding bone and a healthy vital soft-tissue bed in the area to be treated. Decortication of bone in some surgeon's hands is also a useful technique.

In the lower leg, posterolateral approaches for central placement of the graft into a vital bed avoids the infected wound in most cases (**Fig 5.4-9**) [15]. In the humerus or femur, the best position of the graft depends upon the defect and the soft-tissue envelope. Stable fixation with an external fixator, plate, or intramedullary nail is essential for healing of an infected nonunion. If an antibiotic spacer was utilized in a staged manner, the biological membrane around the spacer or beads should be carefully preserved and filled with bone graft.

If a bone graft must be applied to an area where the soft tissue is defective, the establishment of healthy soft-tissue cover (usually with a flap) should precede grafting.

In intramedullary infections (see chapter 5.3), the medullary canal should be thoroughly debrided with an intramedullary reamer and irrigated. A distal cortical window may be required (near the locking screw holes) for distal canal lavage.

4.3.2 The Masquelet procedure

The Masquelet procedure is a new and successful method for managing long-bone infections in a staged manner. Defects longer than 20 cm have been successfully treated with this procedure [16]. The first step in the Masquelet procedure is removal of infected implants if present. Meticulous debridement is then accompanied by placement of an antibiotic spacer or antibiotic beads in the void (dead-space) created by the bony debridement. After the infection is under control with use of systemic antibiotics, and the

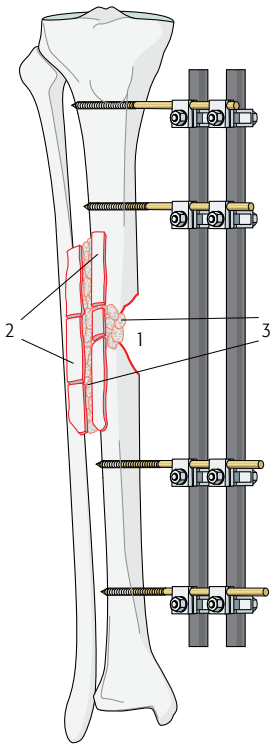

Fig 5.4-9 Infected nonunion without loss of length in a tibia. Decortication and cancellous bone graft in an infected nonunion.
1 Area debrided from medial aspect will be covered with muscle flap or free vascularized flap.
2 Decortication, from posterior or lateral aspects, of the fibula and the lateral and posterior aspects of the tibia.
3 Placement of autogenous cancellous bone graft. Be careful not to injure the anterior tibial artery, veins, and nerve.

inflammatory markers are returning toward normal, the extremity is reopened. Careful preservation of the membrane that forms around the spacer is essential (**Fig 5.4-10**): the biological membrane is incised to remove the cement spacer but the rest of the membrane with its blood supply is left intact. The void is then filled with bone graft (mixed with bone void filler if needed as an osteoconductive scaffold). Bony stability is achieved with an intramedullary nail or a plate at this stage. Healing occurs gradually and it can take 1–2 years to completely reconstitute the missing segment [17]. The Masqualet technique is more successful in the femur, with its excellent muscle cover, than the tibia.

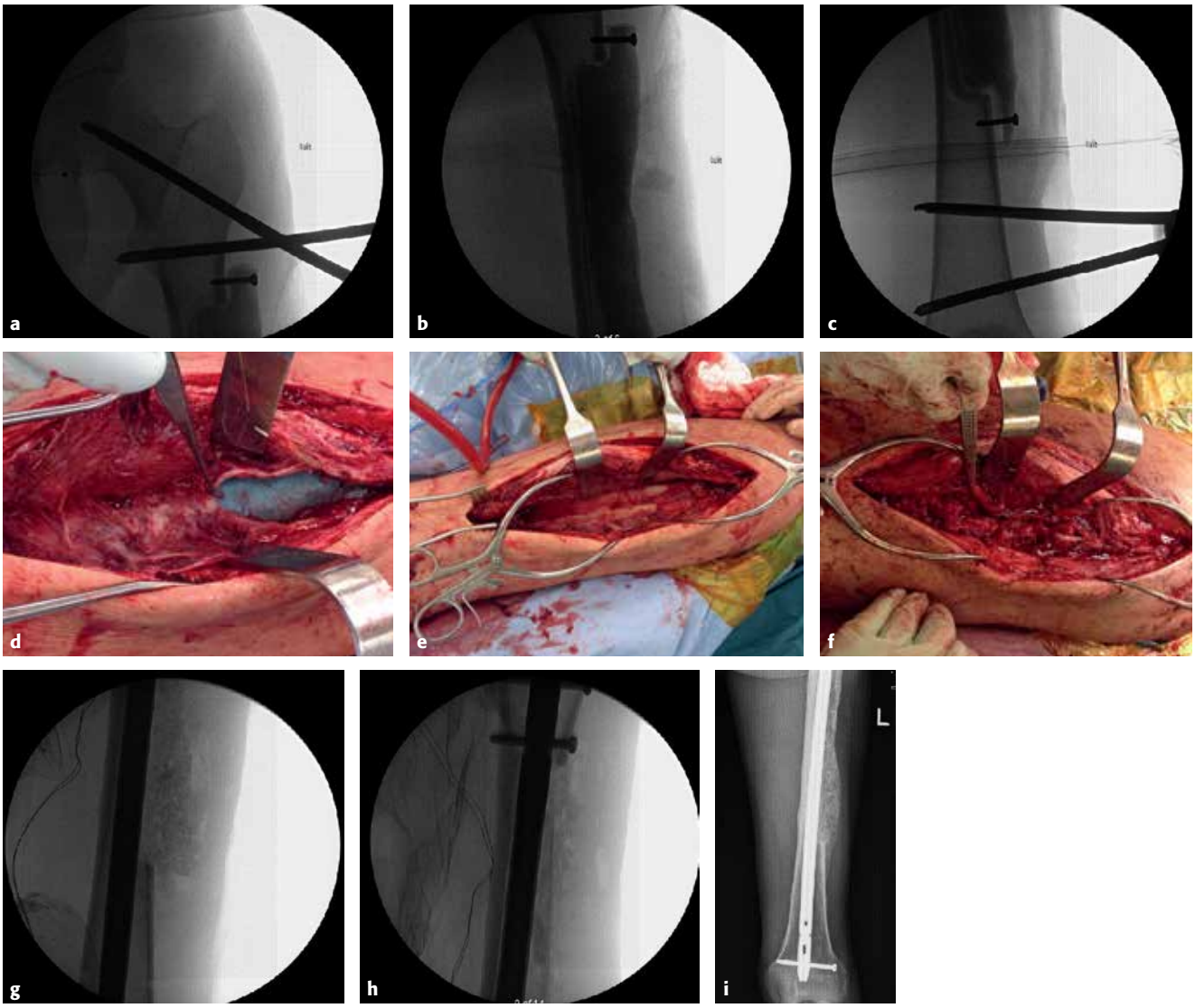

Fig 5.4-10a–i Two-stage Masquelet procedure with a 27 cm corticectomy of the left femoral cortices with intracortical abscesses.
a–c Intraoperative x-rays.
d Methylene blue impregnated cement spacer with a biomembrane 5 weeks after Masquelet procedure. The Vastus lateralis is at the top of the image.
e After cement spacer removal.
f Filling the space with graft and closing the membrane.
g–h External fixator was replaced with an intramedullary nail. Early bone formation after Masquelet procedure.
i 10-month postoperative follow-up with bone graft incorporated.
(With kind permission from Dr Jeremy Lamothe.)

4.3.3 Callus distraction (Ilizarov)

Ilizarov introduced the technique of gradual callus distraction following corticotomy to restore limb length or to bridge a defect (**Fig 5.3-9**, **Fig 5.4-11**) [13].

The great advantage of the Ilizarov method is that the frame can correct the length, rotation, and axial alignment of the bone while callus distraction and osteogenesis fills the bone defect. The soft tissues may be distracted as well, thereby minimizing the need for additional reconstruction.

After meticulous debridement of any devitalized bone and soft tissue, the tensioned wire ring external fixator is placed. A transverse corticotomy is performed away from the defect, close to a metaphysis. The corticotomy is performed either a week after the debridement or—in low-grade infections—simultaneously. Distraction begins 10 days later but during this time the gap is kept at a distance of 1 mm. Thereafter, the newly formed callus is slowly distracted at a rate of 1 mm per day in four steps, evenly distributed over 24 hours. Partial weight bearing is usually allowed. The progress of the distraction, callus maturation, and correction of any deformity are monitored by x-rays. When the planned length is reached, weight bearing is gradually increased. Full-weight bearing is usually achieved 4–6 months after closure of the defect. As the docking sites have a tendency to delayed union, decortication and bone grafting of these areas may be required or in some cases internal fixation is needed. Bone transport may be long and cumbersome; therefore, it requires a commitment by both the patient and the physician. The patient has to be seen regularly during the distraction period, and physiotherapy should be instituted early to mobilize the adjacent joints. In trauma cases, neurological problems due to overstretching of nerves can occur. Callus distraction over an intramedullary nail may reduce the period of external fixation but is not without hazards, especially in patients who have had previous infections [18].

Fig 5.4-11 Ilizarov frame for bone transport with foot plate to prevent equinus deformity.

4.3.4 Free vascularized bone graft

Free vascularized bone grafts (from the fibula or iliac crest) are especially suitable for the bridging of bone defects longer than 10 cm [19, 20].

The advantage of free vascularized bone grafts is that, after bone integration at the recipient site, gradual hypertrophy will occur, slowly adapting size and structure to the local mechanical needs. It may, however, take years until full loading is possible and this requires long-term protective measures, especially in the lower extremity. Because of the relatively small diameter of the grafts, they are more suitable for forearm and humerus. In the tibia, one has to consider double grafting, using the contralateral fibula first and, as a second step, the ipsilateral fibula [19, 20]. Because of the big difference in size (bone graft versus defect site) the method is of restricted value in the femur. The drawback of this technique is that it is technically demanding and there is donor-site morbidity.

4.4 Soft-tissue coverage

As a rule, soft-tissue coverage without complete debridement is useless.

The importance of a meticulous debridement of infected and devitalized bone and soft tissue cannot be overemphasized. Placement of a muscle flap or fasciocutaneous flap over an infected bed will result in necrosis of the flap. This approach must be avoided. In many cases, assistance from a skilled flap surgeon is beneficial. The choice of flap will depend on location, vascularity, patient health, donor-site availability, and surgeon experience.

In unexposed small defects with good granulation tissue covering the bone, split skin grafts may be sufficient. In more complex situations local muscle flaps (eg, gastrocnemius flap for proximal tibia defect), fasciocutaneous flaps or free vascularized flaps are needed. Some common free flaps are the rectus abdominus flap, antelolateral thigh flap, and latissimus dorsi flap.

Negative-pressure wound therapy (vacuum-assisted closure) (see chapter 4.3) is useful in other situations of open wounds or local soft-tissue defects [21].

Negative-pressure wound therapy combined with antibiotics will not cure bony infection and should not be used for that purpose.

4.5 Antibiotics

Always consider antibiotics as being complementary to surgery. It is essential to work collaboratively with an infectious diseases specialist in planning and monitoring antibiotic therapy. This specialist can help to select appropriate antibiotics to achieve a therapeutic concentration in the bone. In implant-related infections, especially with staphylococci, a robust biofilm will be present in all cases requiring implant exchange [1]; antibiotics are typically less effective when the organisms are in a biofilm low-activity state. For local delivery of antibiotics and dead space management, chains of beads impregnated with antibiotics or antibiotic impregnated bone substitutes may be useful. They offer a high concentration of antibiotics at the infection focus. Laboratory and clinical research has shown that local antibiotics in high concentrations do not kill the organisms in biofilm reliably—emphasizing the need for surgical debridement. They can also serve as spacers for further bone-grafting procedures [16, 17, 22]. After final surgical management of chronic osteomyelitis, adjunctive, systemic treatment with antibiotics should continue for 4–12 weeks with advice from the infection specialist [23].

5 Treatment concepts for typical cases

5.1 Hypertrophic infected nonunion

Hypertrophic infected nonunions have adequate biology or blood supply, as evidenced by excessive callus formation on x-rays.

Infected nonunions often have a draining sinus (**Fig 5.4-12**). There may be a lot of reactive bone and callus in the vicinity of the fracture site and implants. Patients are often able to use the affected part of the body well, although instability and infection are major problems. Hypertrophic infected nonunions frequently have an angular and/or rotational deformity due to muscle imbalance or weight bearing. The treatment consists of complete debridement of the infected bone and soft tissue. Definitive soft-tissue cover may be required and the timing is based on control of the infection, virulence of the organism(s), and anatomical location. Osteotomy combined with external or internal fixation will correct a deformity and provide stability, while a cancellous autograft may be performed after debridement and control of the infection. Healing takes 4–6 months or longer. Definitive fixation can be achieved with an intramedullary nail, plate, or ring fixator.

5.2 Avital and unstable infected nonunion

Instability and nonviable bone are the classic features of an infected nonunion. There is little or no evidence of healing, the bone is frequently necrotic, osteopenic or sclerotic, and often there is associated shortening, joint contracture, limb atrophy, and chronic pain.

The treatment of this more complex condition requires multiple stages. Thorough debridement of all devitalized bone, all implants, and infected soft tissue is combined with external or internal fixation. The resulting bone defect is measured to assist with planning for later reconstruction. Preoperative planning is essential in these cases. Some shortening may be acceptable to gain bony stability. The infection

Fig 5.4-12a–c These clinical photographs demonstrate a draining sinus from infected tibial (**a**), patellar (**b**), and femoral (**c**) fractures with retained hardware and nonunion. They required removal of hardware, debridement, and revision of fixation.

is controlled with the debridement, organism-specific systemic antibiotics, and progress is monitored with inflammatory markers and repeated biopsy if needed. Once the infection is controlled, reconstruction may be undertaken with the Masquelet technique, ring fixator or internal fixation with cancellous autograft. Repeated tissue cultures should be obtained at each subsequent procedure.

5.3 Avital infected nonunion with segmental bone defect

With segmental bone loss and avital bone ends, severe dystrophy of the bone and the soft tissues occurs due to disuse of the limb. For treatment, any attempt at reconstruction has to be preceded by a thorough debridement. Segmental bone loss exceeding 5–6 cm can usually not be bridged successfully by cancellous bone graft. Treatment options include the Masquelet procedure or the callus distraction method for defects 10–20 cm (**Fig 5.4-13**). The advantage of these techniques (Masquelet and callus distraction) is the creation

Fig 5.4-13a–f A 43-year-old woman sustained an open tibial fracture. She developed an infection of her intramedullary nail fixation with methicillin-resistant *Staphylococcus aureus.*

a–b After three attempts to fix the fracture, the initial x-rays show a nonunited and infected fracture.

c–d This was reconstructed using the Masquelet technique. In the first stage, the infected bone was resected a distance of 17 cm. Vancomycin-impregnated beads are placed in the void created by removal of the infected bone.

e–f After 3 months, the infection was controlled with intravenous antibiotics. The second stage of the Masquelet procedure was performed. Spinal cages were used to create a tubular structure. Autogenous bone graft was harvested from the ipsilateral femur with the reamer irrigator aspirator. The autogenous bone graft was mixed with calcium sulfate granules and placed around the cages and nail. At 1 year, reasonable healing had occurred. At 3 years, solid union and painless ambulation result.

of a new bone segment which, once matured, resembles the original bone in shape and strength. The problem of soft-tissue cover can usually be solved at the same time. On the other hand, these procedures may be painful and time-consuming. If the bone loss is situated in the forearm or humerus, vascularized grafts may be considered but occasionally also in the femur (**Fig 5.4-14**). In the lower extremity, the Masquelet technique or callus distraction are preferable methods [13, 16, 17, 24, 25].

5.4 Chronic infection

5.4.1 Chronic infection after plate osteosynthesis

In chronic infection after plate osteosynthesis, plate removal and thorough debridement are advocated once the bone has consolidated. Plain x-rays or CT scans are used to assess the bony union. During a secondary revision any remaining necrotic areas should be debrided. If union has been achieved, all implants should be removed and the plate bed and screw holes debrided. If bony union has not yet fully occurred, a staged procedure with temporary immobilization using a fixator or splint may be considered. Any devitalized bone or tissue should be removed and sinus tracts excised.

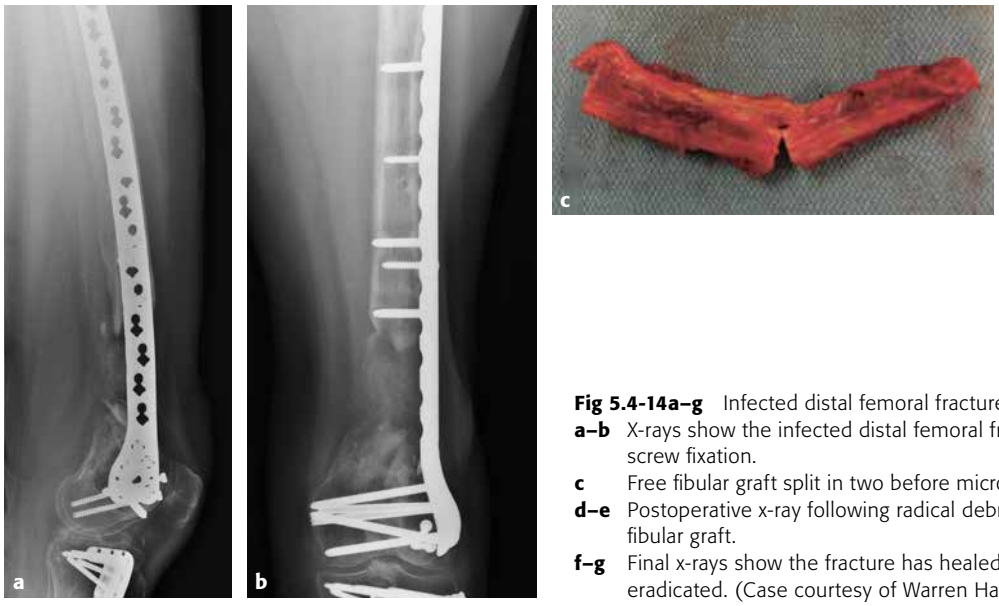

Fig 5.4-14a–g Infected distal femoral fracture.
a–b X-rays show the infected distal femoral fracture with plate and screw fixation.
c Free fibular graft split in two before microvascular anastomosis.
d–e Postoperative x-ray following radical debridement, refixation, and fibular graft.
f–g Final x-rays show the fracture has healed and infection has been eradicated. (Case courtesy of Warren Hammert, MD.)

5.4.2 Chronic infection after intramedullary nailing

Intramedullary nailing may lead to bone consolidation even in the presence of infection. However, there may remain an infected area within the medullary cavity, with or without a sinus. In such cases, the nail and locking screws must be removed accompanied by reaming, and thorough debridement of the medullary canal and screw holes, sinuses.

The best treatment for chronic infection after intramedullary nailing is reaming and flushing of the medullary canal using a deep fluting intramedullary reamers or the reamer irrigator aspirator device.

For fractures that have not healed, adjunctive treatment may include a long chain of gentamicin beads that may be inserted into the medullary canal for 2–3 weeks or/and intramedullary antibiotic-laden cement nail. Because vascularity mainly comes from the periosteum, there is little risk of permanent damage. Following infection, years after the removal of the nail, the medullary cavity is often filled with sclerotic endosteal new bone. Reaming can only then be performed with difficulty, often using the flame-tipped hand reamers to open the canal, followed by reaming as described before.

Once the infection is controlled, the antibiotic cement nail is removed and replaced using a standard intramedullary nail if bony consolidation is absent. Cultures should be obtained during the exchange procedure (**Video 5.3-2**).

5.4.3 Recurrence of osteomyelitis after several years

Osteomyelitis can recur years or even after decades of quiescence. In this case, organisms have remained in a dormant state within the cortex or medullary cavity of the bone. An insult to the immune system for other reasons or another procedure, such as arthroplasty, may reactivate the infection by liberating the dormant organisms which then return to a planktonic growth state re-infecting the surgical site. Clinical manifestations are pain, tenderness, swelling, fever, and abscess formation. It may be difficult to see any pathological changes on standard x-rays, but CT scans, scintigraphy, MRI, or PET-CT may demonstrate a sequestrum worthy of removal. Systemic antibiotics are necessary as an adjunct to definitive surgery (**Fig 5.4-15**). Occasionally, infection is not curable and an amputation becomes a good option for the patient.

Fig 5.4-15a–e A chronic case of osteomyelitis of the metaphyseal/diaphyseal region of the tibia. It occurred when the patient was run over by a motorboat and sustained a subtotal amputation of his leg by the propeller. He had intermittent drainage for 4 years.
a–b The initial x-rays reveal the void in the tibia.
c The sclerotic area represents a sequestrum. This is clearly seen on the computed tomographic (CT) scan.
d–e When considering surgical intervention in such a case, it is helpful to obtain a CT angiogram to assess vascularity. In this case, the vascularity is suboptimal.

Classic references | Review references

6 References

1. **Nishitani K, Sutipornpalangkul W, de Mesy Bentley KL, et al.** Quantifying the natural history of biofilm formation in vivo during the establishment of chronic implant-associated *Staphylococcus aureus* osteomyelitis in mice to identify critical pathogen and host factors. *J Orthop Res.* 2015 Sep;33(9):1311–1319.
2. **Monzon M, Oteiza C, Leiva J, et al.** Synergy of different antibiotic combinations in biofilms of Staphylococcus epidermidis. *J Antimicrob Chemother.* 2001 Dec;48(6):793–801.
3. **Parvizi J, Erkocak OF, Della Valle CJ.** Culture-negative periprosthetic joint infection. *J Bone Joint Surg Am.* 2014 Mar 5;96(5):430–436.
4. **Cierny G 3rd, Mader JT, Penninck JJ.** A clinical staging system for adult osteomyelitis. *Clin Orthop Relat Res.* 2003 Sep;(414):7–24.
5. **Lazzarini L, Mader JT, Calhoun JH.** Osteomyelitis in long bones. *J Bone Joint Surg Am.* 2004 Oct;86-A(10):2305–2318.
6. **Lew DP, Waldvogel FA.** Osteomyelitis. *Lancet.* 2004 Jul 24-30;364(9431):369–379.
7. **Ma LD, Frassica FJ, Bluemke DA, et al.** CT and MRI evaluation of musculoskeletal infection. *Crit Rev Diagn Imaging.* 1997 Dec;38(6):535–568.
8. **Glaudemans AW, Signore A.** FDG-PET/CT in infections: the imaging method of choice? *Eur J Nucl Med Mol Imaging.* 2010 Oct;37(10):1986–1991.
9. **Kaim A, Maurer T, Ochsner P, et al.** Chronic complicated osteomyelitis of the appendicular skeleton: diagnosis with technetium-99m labelled monoclonal antigranulocyte antibody-immunoscintigraphy. *Eur J Nucl Med.* 1997 Jul;24(7):732–738.
10. **Nepola JV, Seabold JE, Marsh JL, et al.** Diagnosis of infection in ununited fractures. Combined imaging with indium-111-labeled leukocytes and technetium-99m methylene diphosphonate. *J Bone Joint Surg Am.* 1993 Dec;75(12):1816–1822.
11. **Aggarwal VK, Tischler EH, Lautenbach C, et al.** Mitigation and education. *J Orthop Res.* 2014 Jan;32 Suppl 1:S16–25.
12. **Bukata SV, Kates SL, O'Keefe RJ.** Short-term and long-term orthopaedic issues in patients with fragility fractures. *Clin Orthop Relat Res.* 2011 Aug;469(8):2225–2236.
13. **Ilizarov GA.** Clinical application of the tension-stress effect for limb lengthening. *Clin Orthop Relat Res.* 1990 Jan(250):8–26.
14. **Britten S, Ghoz A, Duffield B, et al.** Ilizarov fixator pin site care: the role of crusts in the prevention of infection. *Injury.* 2013 Oct;44(10):1275–1278.
15. **Toh CL, Jupiter JB.** The infected nonunion of the tibia. *Clin Orthop Relat Res.* 1995 Jun(315):176–191.
16. **Giannoudis PV, Faour O, Goff T, et al.** Masquelet technique for the treatment of bone defects: tips-tricks and future directions. *Injury.* 2011 Jun;42(6):591–598.
17. **O'Malley NT, Kates SL.** Advances on the Masquelet technique using a cage and nail construct. *Arch Orthop Trauma Surg.* 2012 Feb;132(2):245–248.
18. **Kristiansen LP, Steen H.** Lengthening of the tibia over an intramedullary nail, using the Ilizarov external fixator. Major complications and slow consolidation in 9 lengthenings. *Acta Orthop Scand.* 1999 Jun;70(3):271–274.
19. **Zalavras CG, Femino D, Triche R, et al.** Reconstruction of large skeletal defects due to osteomyelitis with the vascularized fibular graft in children. *J Bone Joint Surg Am.* 2007 Oct;89(10):2233–2240.
20. **Tu YK, Yen CY.** Role of vascularized bone grafts in lower extremity osteomyelitis. *Orthop Clin North Am.* 2007 Jan;38(1):37–49.
21. **Herscovici D Jr, Sanders RW, Scaduto JM, et al.** Vacuum-assisted wound closure (VAC therapy) for the management of patients with high-energy soft tissue injuries. *J Orthop Trauma.* 2003 Nov-Dec;17(10):683–688.
22. **Citak M, Argenson JN, Masri B, et al.** Spacers. *J Orthop Res.* 2014 Jan;32 Suppl 1:S120–129.
23. **Trampuz A, Zimmerli W.** Diagnosis and treatment of implant-associated septic arthritis and osteomyelitis. *Curr Infect Dis Rep.* 2008 Sep;10(5):394–403.
24. **Keating JF, Simpson AH, Robinson CM.** The management of fractures with bone loss. *J Bone Joint Surg Br.* 2005 Feb;87(2):142–150.
25. **Oh CW, Baek SG, Kim JW, et al.** Tibial lengthening with a submuscular plate in adolescents. *J Orthop Sci.* 2015 Jan;20(1):101–109.

7 Acknowledgments

We thank Eric Johnson and Richard Buckley for their contribution to this chapter in the second edition of the *AO Principles of Fracture Management*.

Glossary

The glossary provides the working definitions for terms that have been used by authors within the book. We hope that the glossary will help readers to understand the text and also be useful for surgeons taking postgraduate examinations.

abduction	Movement of a part, in the coronal plane, away from the midline
absolute stability	See stability, absolute
adduction	Movement of a part, in the coronal plane, towards the midline.
aiming device	A device to guide a wire, or a drill bit, into the correct direction.
algodystrophy	See complex regional pain syndrome.
allograft	Bone, or tissue, transplanted from one individual to another individual of the same species
anatomical position	The reference position of the body: standing facing the observer, with the palms of the hands facing forwards
anatomical reduction	Reinstatement of the exact prefracture shape of the bone
anchor screw	A screw that serves as a point of fixation for a wire loop, strong suture, or instrument (eg, an articulated tension device).
ankylosis	Fusion of a joint by bony, or a tight fibrous, union, occurring spontaneously as a result of a disease process (eg, following septic arthritis)
antibiotic	Any biologically-derived drug, or naturally-occurring substance, that can inhibit the growth of, or destroy, microorganisms.
antiglide plate	Prevents shear displacement of a fragment by functioning as a buttress. Classically, it is only fixed to the main fragment.
appropriate total care	Definitive surgical stabilization of mechanically unstable fractures of the proximal and diaphyseal femur, pelvic ring, acetabulum, and thoracolumbar spine, within 36 hours of injury in hemodynamically stable patients with adequate resuscitation and normalizing physiological indices. Some trauma centers have extended this to include unstable fractures of the cervical spine and of the tibial diaphysis. Improvement of metabolic acidosis is the best physiological index—see early total care (ETC).
arthritis	An inflammatory condition of a synovial joint. It may be septic, or aseptic.
arthrodesis	Fusion of a joint by bone as a planned outcome of a surgical procedure.
articular fracture, complete	The entire articular block is separated from the diaphysis.
articular fracture, multifragmentary	A fracture in which part of the joint is depressed and there are more than one articular fracture fragments.
articular fracture, partial	Only part of the joint is involved in the fracture, while the remainder remains attached to the diaphysis. There are several varieties.

articular fracture, pure depression An articular fracture in which there is depression of the articular surface alone, without a split fracture. The depression may be central or peripheral—see impacted fracture.

articular fracture, pure split An articular fracture in which there is a longitudinal metaphyseal and articular split, without any additional osteochondral lesion.

articular fracture, split-depression An articular injury with a fracture line running into the metaphysis (split) and impaction of separate osteochondral joint fragments (depression).

autograft A graft of tissue from one site to another within the same individual.

avascular necrosis (AVN) Bone that has been deprived of its blood supply dies. In the absence of sepsis, this is called avascular necrosis. The dead bone retains its normal strength (but it is unable to heal) until the natural process of revascularization, by creeping substitution, starts to remove the dead bone, in preparation for the laying down of new bone. Loading of such areas may then result in bony collapse.

avulsion Pulling off. A bone fragment pulled off by a ligament, or muscle attachment, is an avulsion fracture.

bactericidal Capable of killing bacteria.

bicortical screw A screw that gains purchase in both the near cortex and the far cortex.

biocompatibility The ability to exist in harmony with, and not to injure, associated biological tissues, or processes.

biological internal fixation A technique of biologically-respectful surgical exposure, fracture reduction, and fixation, which favors the preservation of the blood supply at the fracture site and, thereby, optimizes the healing potential of the bone and soft tissues.

bone graft Bone removed from one skeletal site and placed into another. Bone grafts are used to stimulate bone union (osteoinduction) and also to restore skeletal continuity where there has been bone loss—see allograft, autograft, and xenograft.

bone healing See healing.

bone resorption Removal of bone by osteoclasts. This is an integral element of bone remodeling, either during normal bone turnover, growth, or after fracture. Pathological removal of bone by activated osteoclasts and giant cells occurs if bone is dead, when bone is infected, and around implants where there is excessive movement.

bone substitute Non-osseous biological, or inorganic, material that can be used in place of, or to augment, bone graft, in order to fill a defect.

bridging plate A plate that spans the fracture site and is attached to each main fragment of a multifragmentary fracture, maintaining axial and rotational alignment and length. It is not fixed to, nor does it disturb, the blood supply of intervening fragments.

butterfly fragment Where there is a fracture complex with a third fragment, which does not comprise a full cross section of the bone (ie, there is some contact between the two main fragments after reduction). A wedge-shaped fragment, due to a rotational mechanism, may be spiral, and is occasionally referred to as a butterfly fragment—see wedge fracture.

buttress A construction that resists axial load by applying force at 90° to the axis of potential deformity

calcar Meaning "spur" in Latin, the medial cortex of the femoral neck, proximal to the lesser trochanter, which transmits the majority of the compressive forces generated in the femoral neck during load-bearing (calcar femorale).

callus A tissue of immature bone and cartilage that is formed at the site of bony repair and which bridges a fracture—see healing, indirect.

cancellous bone Spongy trabecular bone, found mostly at the proximal and distal bone ends of diaphyseal bones, and the interiors of small bones, such as the carpal and tarsal bones.

chondrocytes The active cells of cartilage that produce the type II collagen and proteoglycans, which make up the chondral matrix.

classification process The method by which surgeons allocate fractures to unique categories.

coating A thin layer that is applied to the surface of an implant and which may contain different biologically active agents (eg, antibiotics, bone morphogenic protein, or hydroxapatite).

combination hole The plate hole of the locking compression plate (LCP) that consists of two parts: the nonthreaded dynamic compression unit (DCU; shaped like the holes of a dynamic compression plate), and the threaded part which has a reciprocal thread for the engagement of the head of a locking head screw (LHS).

compartment syndrome Raised pressure in a closed osteofascial compartment that results in local tissue ischemia—see muscle compartment, ischemia-reperfusion injury. It is a true surgical emergency

complex fracture A fracture with one, or more, intermediate fragment(s), in which there is no contact between the main fragments after reduction—see multifragmentary fracture.

complex regional pain syndrome (CRPS) Neuropathic pain with associated sudomotor and vasomotor disturbances, which develops after trauma, another inciting event, or a period of immobilization of the part. The diagnostic criteria are broad and there are no specific tests for the diagnosis of this condition. There are two types (CRPS I and CRPS II) that have the same signs and symptoms, the difference being that an identifiable peripheral nerve lesion is associated with CRPS II. CRPS is also known as fracture disease, algodystrophy, reflex sympathetic dystrophy, and Sudeck's atrophy.

compression The act, or effect, of pressing together, usually in order to achieve, or increase, stability.

compression, inter-fragmentary Bone fragments are pressed together, either with a lag screw, or a plate, in order to produce absolute stability.

compression screw See lag screw.

contact healing See healing, contact.

continuous passive motion (CPM) The use of an apparatus to provide periods of passive movement of a joint through a controlled range of motion.

conventional plate Any plate with smooth holes that can accommodate any unthreaded screw head of matching dimensions.

conventional screw Any screw with a smooth outer surface of the head (ie, without threads) that is used for fracture, or plate, fixation.

coronal plane The vertical plane of the body passing from side to side, so that a coronal bisection of the body would cut it into a front half and a back half. Also called the frontal plane.

corrosion This is an electrochemical process that results in the destruction of metal by the liberation of ionic metal.

cortical bone The dense bone forming the tubular element of the shaft, or diaphysis (middle part), of a long bone. The term is also applied to the dense, thin shell covering the cancellous bone of the metaphysis

corticotomy A special osteotomy where the cortex is surgically divided, but the medullary contents and the periosteum are not injured.

countersink The process of making a shallow recess around a screw hole to increase the contact area between the bone and the screw head. The term can also refer to the tool used for making such a recess.

creeping substitution The slow replacement of dead bone with living, vascular bone.

critical strain level The strain level at which a tissue disrupts, or ceases to perform its normal physiological function.

damage-control resuscitation (DCR) The early management of a trauma patient in hypovolemic shock, which aims to prevent the development of coagulopathy, hypothermia, and acidosis. DCR includes early control of hemorrhage, the use of massive transfusion protocols and active warming of the patient.

damage-control surgery (DCS) Rapid emergency surgery to save life and/or limb, while avoiding time-consuming and potentially traumatic definitive fracture fixation. DCS usually involves hemorrhage control, wound debridement and the rapid application of casts, splints, or temporary external fixators, to stabilize long-bone fractures and unstable fracture dislocations.

debridement The surgical excision from a wound injury zone, or area of other pathology, of foreign material and all avascular, contaminated, or infected tissue.

deep infection Bacterial, or fungal, infection involving fascia and/or muscles and/or bone and/or implants with an associated inflammatory response.

deformation, elastic A temporary change in length, or shape, of a material that will return to its former state when the deforming force is released.

deformation, plastic A change in length or shape of a material of such magnitude that it is permanent and will not recover when the deforming force is released.

deformity Any abnormality of the form of a body part.

delayed union Fracture healing is not taking place by the expected time that is expected for healing of a particular fracture in a particular patient—see nonunion.

diaphysis The cylindrical, or tubular, part of a long bone between the metaphyseal ends, often referred to as the shaft.

diastasis screw A positioning screw that is inserted into the fibula and tibia in order to maintain their normal anatomical relationship at the distal tibiofibular syndesmosis. The screw thread must gain purchase in both bones as compression must not be applied.

dislocation A displacement of a joint such that no part of one articular surface remains in contact with the other articular surface. Sometimes used incorrectly to denote fracture displacement.

displacement The condition of being out of place. A fracture is displaced if the fragments are not perfectly anatomically aligned.

distal Away from the center of the body, more peripheral.

distraction osteogenesis The induction of bone formation by the application of tension to soft tissue that has the potential to form bone, eg, organized hematoma, periosteum, and endosteum at the site of an osteotomy, corticotomy, or osteoclasis. This phenomenon was first described by August Bier (1927) and scientifically investigated by the Russian surgeon, Ghavriil Ilizarov.

dorsal Pertaining to the back—or dorsum—of the body in the anatomical position. An exception is the foot; the top of the foot, even though it faces forwards in the anatomical position, is called the dorsum. In this publication dorsal is only used to describe the dorsum of the hand and foot. For all other parts the adjective "posterior" is used.

ductility The degree of permanent (plastic) deformation that a material tolerates before it breaks. The ductility of a material determines the degree to which an implant, such as a plate, can be contoured without breaking.

dynamic compression plate (DCP) A plate with chamfered oval holes through which eccentrically placed screws can be inserted to create compression across a fracture site.

dynamic compression unit (DCU) The nonthreaded part of an LCP combination hole that is shaped like the hole of a dynamic compression plate (DCP).

dynamic locking When an interlocking screw is inserted into the oval locking hole of an intramedullary nail, it controls rotation and alignment, but allows some (controlled) impaction of the fracture during weight bearing—see dynamization.

dynamization Diverting some or all of the mechanical load away from a fixation device in order to load the fracture site, with a view to enhancing bone formation.

early total care (ETC) Definitive treatment, in polytrauma patients, of all injuries, including major long-bone fractures, within 24 hours of injury.

endosteum A single-layered membrane that lines the interior surface of the bone, ie, the wall of the medullary cavity. Its cells have osteogenic potential.

end segment This term has been created for the AO/OTA classification of articular fractures in the adult. It is defined by drawing a line across the widest part of the metaphysis on an x-ray. This line is then used to create a square with one side placed along the articular surface. The bone lying within the square is defined as the end segment. In children, the end segment is further divided into epiphysis and metaphysis, which are separated by the growth plate (physis).

energy transfer When tissues are injured, the damage caused is due to external energy being transferred to the tissues. This is most commonly due to the transfer of kinetic energy from a moving object (car, missile, falling object, etc) but can also be due to thermal energy transfer—see kinetic energy.

epiphysis The end of a long bone that bears the articular component. The epiphysis develops from the cartilaginous element between the joint surface and the growth plate (physis)—see metaphysis.

evidence-based medicine The conscientious, explicit, and judicious use of current best evidence in making decisions about the care of individual patients. The practice of evidence-based medicine means integrating individual clinical expertise with the best available external clinical evidence from systematic research.

external fixation Skeletal stabilization using pins, wires, or screws that protrude through the skin and are linked externally by bars, or other devices.

extraarticular fracture The fracture does not involve the articular surface, but is within the end segment of a long bone and may be within the joint capsule.

far cortex The cortex more distant from the operator—see near cortex. Sometimes referred to as the trans-cortex

fasciocutaneous flaps Soft-tissue flaps, based on a perforating artery, which include the skin, the subcutaneous tissues, and the deep fascia

fasciotomy The surgical division of the fascial wall of an osteo-fascial muscle compartment, usually to release high intracompartmental pressure—see compartment syndrome.

fatigue failure If any material is subjected to multiple loading cycles, it may develop microscopic cracks and eventually fail at a stress well below its tensile strength, and often below the yield strength of the pristine material.

fibrocartilage Tissue consisting of elements of cartilage and of fibrous tissue. It is the normal constituent of the menisci of the knee and the triangular fibrocartilage at the wrist. It also forms as a repair tissue after injury to articular cartilage.

fixed-angle device An implant with two or more parts that are solidly connected at a given angle so that it will resist forces tending to angulate one part with respect to the other. Such devices are used to prevent angular displacement of fractures. Fixed angle devices may be manufactured as a single, solid device (eg, 95°-angled blade plate), or produced by mechanically coupling two implants (eg, a locking compression plate with a locking head screw).

fracture classification system A set of organized fracture categories with its structure based on a defined fracture diagnosis.

fracture disease A condition characterized by disproportionate pain, soft-tissue swelling, patchy bone loss, and joint stiffness—see complex regional pain syndrome.

fracture fixation Application of a mechanical device to a broken bone to allow healing in a controlled position and (usually) to facilitate early functional rehabilitation. The surgeon determines the degree of reduction required and the mechanical environment at the fracture locus, which in turn influence the mode of bone healing.

fracture treatment, goal According to Müller et al, the goal of fracture treatment is to restore optimal function of the limb in respect to mobility and load-bearing capacity, while avoiding complications.

fragility fracture A fracture that occurs through bone weakened by osteopenia or osteoporosis during normal daily activities or following a fall from standing height or less.

fragmentary depression fracture A partial articular fracture in which part of the joint is depressed and there are more than three articular fracture fragments

frailty syndrome Impairment of multiple, interrelated physiological systems, usually as a result of ageing and comorbidities, which result in an increased vulnerability to external and internal stress factors.

free vascularized graft/ flap Soft tissue and/or bone that is transplanted to a separate anatomical site in the same individual, and then revascularized using microsurgical, anastomotic techniques to attach its vascular pedicle to vessels at the recipient site.

gap healing See healing, gap.

glide hole The cortex under the screw head is drilled to the size of the outside thread diameter, so that the thread gains no purchase. This is used for the lag screw technique.

guide wire A wire inserted into bone to allow precise positioning of a drill, reamer, or implant. The wire can act as a visual aid for the direction of insertion of an instrument, or implant, or can physically direct it, eg, cannulated drill.

hemostatic resuscitation See damage-control resuscitation

Haversian system Cortical bone is composed of a system of small channels (osteons) about 0.1 mm in diameter. Each osteon consists of concentric layers, or lamellae, of compact bone tissue that surround a central canal, the haversian canal. These channels contain the blood vessels and are remodeled after a disturbance of the blood supply to bone. There is a natural turnover of the Haversian system by continuous osteonal remodeling; this process is part of the dynamic and metabolic nature of bone. It is also involved in the adaptation of bone to an altered mechanical environment.

haptic Relating to the sense of touch, in particular relating to the perception and manipulation of objects using the senses of touch and proprioception. The science of haptics applies tactile sensation and control to interaction with computer applications.

healing The biological process that returns an injured part to its preinjury condition. Bone healing is regarded as complete when bone has regained normal stiffness and strength.

healing, contact One form of direct bone healing that occurs between two fragments of bone maintained in motionless contact (absolute stability). The fracture is repaired by direct osteonal remodeling.

healing, direct It is observed following internal fixation with absolute stability. It is characterized by the absence of callus; there is no resorption of bone at the fracture site. Bone forms by osteonal remodeling without intermediate repair tissue, the osteons proceeding directly across the fracture contact areas. Direct fracture healing was formerly called primary healing.

healing, gap One form of direct bone healing in which there is absolute stability, but a very small gap remains between the fracture fragments. Lamellar bone forms in the gap and is then remodeled by penetrating osteons.

healing, indirect Bone healing by callus formation in fractures treated either with relative stability, or left untreated.

heterotopic (ectopic) ossification (HTO) Formation of abnormally-sited new bone in soft tissues, secondary to trauma or other pathology.

hook plate A plate that is bent so that it captures a fracture fragment, which can then be reduced by applying tension to the plate. The hook can be part of a specially designed plate for a specific anatomical site, or improvised by cutting and bending the end of a conventional plate.

impacted fracture A fracture in which the opposing bony surfaces are driven into each other, with the effect that they behave as a single unit. This is a combined clinical and radiological diagnosis.

infix (pelvic) A pelvic ring fracture is stabilized by inserting bilateral supra-acetabular fixator pins and linking these with a bar and connectors that are buried beneath the skin so that no metalwork is left exposed. The construct is an internal fixator.

injury severity score (ISS) An anatomical scale that was developed to ascribe a numerical value to the extent and severity of trauma in patients with injuries to multiple systems. The highest abbreviated injury scale, or AIS, (range 0 to 5) is calculated for a maximum of three systems (eg, head trauma, musculoskeletal trauma, abdominal injuries). Each AIS is then squared and the three squared scores added together to calculate the ISS (maximum = 3 x 52 = 75)—see polytrauma.

interlocking screw Also called (inter)locking bolt. It couples an intramedullary nail to the bone to maintain length and alignment, and to control rotation.

internal fixator/infix Mechanical device that remains deep to the skin and bridges a fracture zone—similar to external fixation—providing an angularly locked, extramedullary splint resulting in relative stability. This can be achieved with a LCP or LISS.

interprosthetic fracture A fracture that occurs in a bone between two prosthetic implants.

intertrochanteric fracture A fracture of the proximal femur that passes between the greater and lesser trochanters.

ischemia Reduction in blood flow resulting in tissue hypoxia.

ischemia-reperfusion injury Prolonged tissue hypoxia results in the activation of superoxide enzymes, which produce free oxygen radicals when the circulation is restored. These free radicals cause cell membrane damage, resulting in increased permeability that may lead to cell swelling and edema. Ultimately, this can result in cell death and, in a closed anatomical compartment, compartment syndrome can be the outcome.

joystick A Schanz screw, or threaded pin, with an attached handle, inserted into a fracture fragment to allow direct manipulation of the fragment during fracture reduction.

kinetic energy The energy stored by a body by virtue of the fact that it is in motion. Kinetic energy is calculated according to the formula E = 1/2 mv2, where m is the mass of the moving object and v its velocity.

lag screw A screw that passes across a fracture plane through a glide hole in the near fragment, to grip the opposite fragment in a threaded hole, thereby producing interfragmentary compression when it is tightened.

LC-DCP See limited-contact plate.

LCP See locking plate and internal fixator.

ligament reconstruction A ruptured, or stretched, ligament is replaced by a soft-tissue graft, or biomaterial, to restore stability to an injured joint.

ligament repair In order to restore stability to an injured joint, a ruptured ligament is directly sutured, or reattached to bone using sutures or anchors.

ligamentotaxis Traction is applied across a fractured joint so that tension in capsular and ligamentous attachments tends to reduce the fracture fragments.

limited-contact plate A plate designed to limit contact with the underlying bone, which preserves the maximum possible periosteal blood supply. The most common variety is the limited-contact dynamic compression plate (LC-DCP).

locking compression plate (LCP) See locking plate and internal fixator.

locking head screw (LHS) A screw with a thread cut into its head, providing a mechanical coupling, or linkage, to a compatibly threaded screw hole in a plate, thereby creating a fixed-angle combination device.

locking plate A plate with threaded screw holes that allow mechanical coupling to a locking head screw (LHS). The less invasive stabilization system (LISS) will accept only this type of screw, while locking compression plates (LCPs) have combination holes that will accept either conventional screw heads, or threaded screw heads.

lung-protective ventilation A strategy used in polytrauma that reduces airway pressure to avoid iatrogenic barotrauma to the alveoli.

malunion Fracture healing in a position of deformity.

Masquelet technique A method for managing acute bone defects by stabilizing a fracture and then filling the bone defect with acrylic cement. After 6-8 weeks a vascular biomembrane forms between the cement and the related tissues. Second-stage surgery then removes the cement, but preserves the biomembrane. Autogenous bone graft is used to replace the cement and growth factors produced by the biomembrane promote incorporation of the graft and fracture healing.

massive transfusion protocols Used for the treatment of severe hemorrhage to allow the replacement of lost blood with packed red cells, platelets and fresh frozen plasma. Current evidence suggests that a 1:1:1 transfusion ratio gives the best outcomes.

metaphysis In the adult, this is the segment of a long bone located between the articular surface and the shaft. It consists mostly of cancellous bone within a thin cortical shell.

minimally invasive osteosynthesis (MIO) Any fracture fixation undertaken using small skin incisions and designed to limit surgical trauma to the deeper soft-tissues. Examples include percutaneous K-wiring, external fixator and “closed” intramedullary nailing, as well as minimally invasive plate osteosynthesis (MIPO).

minimally invasive plate osteosynthesis (MIPO)	Reduction and fixation with a plate of any design, without direct surgical exposure of the fracture site, using small skin incisions and subcutaneous or submuscular, insertion of the plate.
minimally invasive surgery (MIS)	Any surgical procedure undertaken using small skin incisions. Examples include laparoscopic abdominal surgery, arthroscopy, MIPO, and "closed" intramedullary nailing.
modulus of elasticity	Ratio of stress to strain in the linear region of a stress-strain curve. Also called Young's modulus.
monocortical screw	A screw that purchases only in the near cortex.
multifragmentary fracture	A fracture with more than one fracture plane so that there are three, or more, pieces. The proximal and distal fragments will not have direct contact following anatomical reduction. The term is used in the AO/OTA Fracture and Dislocation Classification as a fracture type.
muscle compartment	An anatomical space, bounded on all sides by either bone, or deep fascia, and which contains one or more muscle bellies.
negative-pressure wound therapy (NPWT)	See vacuum-assisted wound therapy
near cortex	The cortex nearer the operator and on the side of insertion of an implant: sometimes called the cis-cortex.
nonunion	The fracture remains mobile and healing has stopped. The fracture will not unite without surgical intervention. A nonunion is usually due to inadequate mechanical, or biological, conditions–see union, pseudarthrosis, and delayed union.
orthosis	An external device that is applied to the body in order to protect and/or stabilize a body part, prevent or correct scarring and deformities, or aid movement.
osteoarthritis	A degenerative condition of synovial joints which is characterized by loss of articular cartilage, subchondral bone sclerosis, bone cysts, and the formation of osteophytes. It is now more commonly referred to as degenerative joint disease (DJD).
osteoconduction	The physical property of a material that provides the microstructure for the ingrowth of cells that produce bone.
osteogenesis	The formation of new bone from osteoprogenitor tissue.
osteoinduction	The property of stimulating new bone formation (osteogenesis).
osteomyelitis	An acute, or chronic, inflammatory condition affecting bone and the contents of its medullary cavity, usually the result of infection.
osteon	The name given to the small channels and their surrounding concentric lamellae of bone, which combine to make up the Haversian system in cortical bone – see Haversian system.
osteopenia	A reduction in bone mass of between 1 and 2.5 standard deviations below the mean for a young adult (ie, a T score of -1 to -2.5)—see osteoporosis.
osteoporosis	A reduction in bone mass of more than 2.5 standard deviations below the mean for a young adult (ie, a T score of less than -2.5)—see osteopenia, fragility fracture, and pathological fracture.
osteosynthesis	A term coined by Albin Lambotte to describe the "synthesis" (derived from the Greek for making together, or fusing) of a fractured bone by a surgical intervention using implants. It includes external fixation.
osteotomy	Controlled surgical division of a bone

overbending (of a plate) An exactly contoured plate is given a slight extra bend at the level of a transverse fracture, so that its central portion stands slightly off the underlying cortex of the anatomically reduced fracture. As fracture site compression is generated by tensioning the plate, the far cortex is compressed first, then the near cortex, resulting in even compression across the transverse diameter of the bone. Without the overbend, the plate will only compress the near cortex, resulting in an unstable fixation, the risk of cyclical loading of the plate and eventual fatigue failure

pathological fracture A fracture through abnormal bone, which occurs at normal physiological load, or stress.

perioperative The period of time around the operation, including the immediate preoperative assessment, anesthesia and the first 24 hours following surgery.

periosteum The fibrovascular membrane covering the exterior surface of a bone. The deep cell layer (cambium) has osteogenic potential.

periprosthetic fracture A fracture that occurs in close relationship to a component of a joint prosthesis, most commonly the intramedullary stem of a joint replacement.

pertrochanteric fracture A fracture of the proximal femur that involves the greater trochanter.

"personality" of the fracture A term coined by EA Nichol (1965) to express the combination of attributes of a fracture that determine its outcome after treatment. There are three key factors: the patient, the soft tissues, and the fracture itself.

pilot hole A drill hole that is the same diameter as the core of the screw. This can then be used to guide the insertion of screws that cut their own thread (self-tapping screws), or a tap that will cut the threads and produce a threaded hole.

pin loosening Bone resorption at a pin-bone interface, usually the pins of an external fixator

plate screw A screw inserted through a plate to compress the plate to the bone. The preload created and friction hold the plate in place.

Poller screw A blocking screw across the intramedullary canal inserted to redirect an intramedullary nail during its insertion.

polytrauma A syndrome of multiple injuries to one or more body systems, or cavities, with sequential systemic reactions that may lead to dysfunction, or failure, of remote uninjured organs and vital systems. It can also be defined as an injury severity score (ISS) of ≥ 15.

position screw A position screw is placed between two adjacent bones, or fracture fragments, to maintain their normal, relative anatomical relationship without applying compression. After restoration of the normal relationship of the bones, a pilot hole is drilled and tapped through both the near and far cortices of each bone. A fully threaded screw is then inserted and the absence of a glide hole means that no compression is generated between the head of the screw and the far cortex. The syndesmotic diastasis screw used in type C ankle fractures is an example of a position screw—see diastasis screw.

positron emission tomography – computed tomography (PET-CT) A nuclear medicine technique that combines, in a single gantry, a positron emission tomography scanner and an x-ray CT scanner to acquire sequential images from both techniques in the same session.

prebending (precontouring) of a plate Preoperative, or intraoperative, contouring of a plate to the shape of the bone.

preload The application of interfragmentary compression keeps the fragments together until a tensile force is applied which exceeds the compressive force (preload).

preshaped plate A plate that is designed and shaped during manufacture to fit a specific anatomical site, so that intraoperative contouring of the plate is usually not needed.

protection (plate) A plate, or other implant, that reduces the load exerted on a lag screw fixation, thereby protecting it from overload. This was formerly referred to as a neutralization device (plate).

pseudarthrosis It literally means false joint. When a nonunion is mobile and allowed to persist for a long period, the bone ends become sclerotic and the intervening soft tissues differentiate to form a type of synovial articulation—see delayed union, union.

pure depression fracture An articular fracture in which there is a depression of the articular surface due to impaction, but without a split. The depression may be central, or peripheral.

push-pull screw A temporary anchor screw that provides a point of fixation for an instrument to reduce a fracture by distraction and/or compression.

push-pull technique An implant (usually a plate) is applied to one side of a fracture. An instrument (eg, bone spreader) is attached between an anchor point (usually a temporary push-pull screw) on the other side of the fracture and the implant. The instrument is then used to distract (push) or appose (pull) the fracture and obtain reduction.

raft screws A group of position screws placed parallel to the joint surface and just beneath the subchondral bone to maintain reduction of a depressed joint fracture.

reconstruction plate A notched plate that can be bent on the flat as well as in the conventional manner, producing complex 3-D shapes for fixation of fractures in irregularly-shaped bones, such as the pelvis, or the distal humerus.

reduction The realignment of a displaced fracture.

reduction, direct Hands, or instruments, directly manipulate fracture fragments under vision.

reduction, indirect Fragments are manipulated by applying corrective forces at a distance from the fracture zone, by distraction, or by other means, without exposing the fracture site.

reduction screw A conventional screw used through a plate to pull a fracture fragment towards the plate. The screw may be removed or exchanged once alignment is obtained and secured.

refracture A reoccurrence of a fracture after it has been solidly bridged by bone, at a level of load otherwise tolerated by normal bone. The resulting fracture line may coincide with the original fracture line, or be within the area of bone that has undergone changes as a result of the fracture and its treatment.

relative stability See stability, relative.

remodeling (of bone) The process of transformation of external bone shape (external remodeling), or of internal bone structure (internal remodeling, or remodeling of the Haversian system).

rigidity See stiffness.

sagittal plane This is a vertical plane of the body passing from front to back, so that a sagittal bisection of the body would cut it into a right half and a left half.

safe zone A surgeon must be familiar with the anatomy of the different cross sections of a limb in order to avoid injuries to nerves, vessels, tendons, and muscles whilst inserting percutaneous wires, or external fixator pins. This must only be carried out via the zones recognized to be safe for pin placement.

sarcopenia The loss of skeletal muscle mass and strength, as a result of ageing.

Schanz screw A partially threaded pin that is inserted into bone as part of external fixation construct. Standard Schanz screws have a trocar-shaped tip and require predrilling. There are also self-drilling Schanz screws.

screw Any device exploiting helical geometry for converting rotational movement into rectilinear longitudinal motion.

second look Surgical inspection of a wound, or injury zone, 24–72 hours after the initial management of the injury.

segmental If the shaft of a bone is broken at two levels, leaving a separate shaft segment between the two fracture sites, it is called a "segmental" fracture complex.

self-drilling and self-tapping screw A screw with a sharp, pointed drill tip bearing cutting flutes, which drills its own pilot hole and cuts its own thread.

sequestrum A piece of dead bone lying alongside, but separated from, the osseous bed from which it came. Infected sequestra are formed in chronic osteomyelitis.

shear A shearing force is one which tends to cause one segment of a body to slide upon another, as opposed to tensile forces, which tend to elongate a body.

simple fracture There is a single fracture plane producing two fracture fragments.

single-photon emission computed tomography (SPE-CT) A nuclear medicine imaging technique using gamma rays and a detector to produce tomograms and 3-D information.

splint, gliding The linkages (couples) between the bone and the splinting device allow (controlled) axial movement, so that the distance between the couples can change (eg, a dynamically locked nail).

splinting A splint is made of stiff material that is applied to a fractured body region to reduce motion at the fracture site. It can be applied externally (plaster cast, functional brace, external fixator) or internally (plate, intramedullary nail, internal fixator).

splint, locked There is a fixed linkage (couple) between the bone and splinting device, above and below the fracture zone, so that the working length between the couples cannot change (eg, a statically locked nail).

split-depression See articular fracture, split-depression.

split fracture A partial articular fracture in which there is a longitudinal metaphyseal and articular split, without any additional osteochondral lesion, or articular impaction.

spontaneous fracture A fracture that occurs as a result of physiological load or strain, usually in abnormal bone—see pathological fracture, fragility fracture.

stability, absolute Fixation of fracture fragments so that there is effectively no interfragmentary displacement of the fracture surfaces under physiological load. This allows direct bone healing.

stability, relative A fixation, or support construction, that allows small amounts of interfragmentary motion in proportion to the load applied. This results in indirect healing by external callus formation.

stable fixation Fixation of a fracture that allows early motion of the adjacent joints and provides a mechanical environment that allows fracture healing before failure of the implant.

stiffness The ability of a material to resist deformation. It is defined as the relationship between load applied and the resulting elastic deformation. The inherent stiffness of a material is expressed by its modulus of elasticity (Young's modulus).

stiffness, bending The bending stiffness of an intramedullary nail is inversely proportional to the square of the working length, to the diameter of the nail and to the elastic modulus of the metal. The nail design, hollow or solid, is also an important factor.

stiffness, torsional Torsional stiffness of an intramedullary nail is inversely proportional to the working length, and is proportional to the diameter of the nail and the elastic modulus of the metal. The nail design, hollow or solid, is also an important factor.

strain Change in length of a material when a given force is applied. Normal strain is the ratio of deformation (lengthening or shortening) to original length. It has no dimensions, but is often expressed as a percentage

strain theory by Perren With a small fracture gap, any interfragmentary motion will result in a relatively large change in length (ie, high strain). If this exceeds the strain tolerance of the intervening tissue, healing will not take place. If a larger fracture gap is subjected to the same amplitude of movement, the relative change in length of each intervening tissue component will be smaller (ie, less strain). If the critical strain level is not exceeded, there will be normal tissue function and indirect healing by callus.

strain tolerance The ability of tissue to undergo deformation due to an applied force and continue to perform its normal physiological function. The maximum strain tolerance is the maximum amount of deformation at which a tissue can still perform its normal physiological function. No tissue can function normally when a deforming force causes the tissue to disrupt. This is the critical strain level.

strength The ability of a material to resist the application of force without deformation. The strength of a material can be expressed as ultimate tensile strength, ultimate bending strength or ultimate torsional strength. Strength determines the level of load that an implant can resist.

stress concentration The build-up of stresses in an implant, or bone, where there is a defect, a change in cross section, a hole, or a scratch—see stress distribution.

stress distribution If bending stresses are distributed over a long, unsupported segment of a plate, the stress per unit area is correspondingly low, which reduces the risk of fatigue failure.

stress protection Using a plate to reduce peak loads applied to a screw fixation—see protection (plate). In older texts, this term may be applied to the concept that a rigid implant, such as a plate, applied firmly to bone, protects the underlying bone from stress and, thereby, induces bone resorption. This observed phenomenon is now understood to be due to the vascular impact of the tightly applied plate on the underlying cortex—see stress shielding.

stress riser A defect (eg, empty screw hole in a plate, or an empty drill hole in a bone) that brings about a concentration of stress—see stress concentration.

stress shielding Bone deprived of functional stimulation by having its physiological stresses reduced by a load-sharing implant may react by becoming less dense, according to Wolff's law (1872).

subluxation A displacement of a joint with partial contact residual between the two articular surfaces.

Sudeck's atrophy See complex regional pain syndrome.

surgical site infection (SSI) Occurs in the operative field within 30–90 days of the procedure. The infection can involve just the skin (superficial SSI) or the fascia, muscles, bone or implants (deep SSI).

syndesmosis screw See diastasis screw and position screw.

tap The process by which a thread is cut in a predrilled hole. It also refers to the instrument used to cut the thread.

tension band The principle by which an implant, attached to the tension side of a bending fracture, converts the tensile force into a compressive force at the cortex beneath the implant. While wires, cables, and sutures are often used for tension band fixation, plates and external fixators, when appropriately placed, can also function as tension bands.

thread(ed) hole A pilot hole is drilled and a tap is used to cut the helical groove that receives the thread of the screw. The result is a threaded hole.

toggling Slight movement at the couple between a screw and a plate, or an intramedullary nail. Implants may be designed to allow toggle (eg, intramedullary nails) where the tolerances of the assembly do not permit an exact fit. Toggle between plates and screws may occur during plate failure with loosening of the implant.

torque The moment produced by a rotational force. As an example, torque is applied to drive home and tighten a screw. The moment is equal to the product of lever arm (unit meter) and force (unit Newton) producing torsion and rotation about an axis (the unit of torque is a Newton-meter).

traction table An operating table with attachments that allow safe and precise positioning of the patient and the application of tension, or compression, through a limb to reduce a fracture, whilst allowing access for surgery and radiological imaging. Also known as a fracture table.

translation Displacement of one bone fragment in relation to another, usually at right angles to the long axis of the bone, or in the plane of the fracture.

union Union strictly means "as one". The bone has healed and regained its normal stiffness and strength. In clinical terms, this means there is no movement or tenderness at the fracture site and no pain on stressing the fracture site. Radiologically, there should be evidence of bone trabeculae bridging the fracture site.

vacuum-assisted wound closure An open wound is sealed with an impervious, adherent dressing and low pressure suction is applied beneath the dressing to remove any exudates and to encourage the formation of granulation tissue.

valgus Angulation of the distal part away from the midline in the anatomical position.

varus Angulation the distal part towards the midline in the anatomical position.

wave plate The central section of a wave plate is contoured to stand off the near cortex over a distance of several holes. This leaves a gap between the plate and the bone, which preserves the biology of the underlying bone, provides a space for the insertion of bone graft, and increases the stability because of the distance of the waved portion of the implant from the neutral axis of the shaft. Such plating is useful in nonunion treatment.

wedge fracture A fracture complex with a third fragment, mostly due to a direct trauma, in which, after reduction, there is some residual direct contact between the two main fragments—see butterfly fragment.

working length The distance across a fracture site between the two nearest points where the implant (usually an intramedullary nail, or bridging plate) and the bone are coupled.

xenograft Tissue transplanted from one species to another—also known as a heterograft.

zone of injury The entire volume of bone and soft tissue damaged by energy transfer during trauma. The microcirculation is disturbed and this may endanger tissue viability.

Index

Volume 1 pages 1–562
Volume 2 pages 563–1000

Page references with an "*f*" refer to figures.
Page references with a "*t*" refer to tables.

A

Abbreviated Injury Scale (AIS), 311, 318*t*
Abductor muscle weakness, with intramedullary nailing, 226
ABI. *See* Ankle-brachial index (ABI)
Absolute stability. *See* Stability
Accuracy, in fracture classification, 48
Acetabulum fracture
· anatomy in, 745–746, 745*f*, 746*f*
· anterior column, 766–767, 767*f*
·· posterior hemitransverse, 768, 768*f*
· anterior intrapelvic approach in, 758–759, 758*f*–759*f*
· anterior surgical hip dislocation in, 760–761, 760*f*
· both columns, 768*f*, 769
· classification of, 745–746, 745*f*–749*f*
· complex, 767–769, 767*f*, 768*f*
· complications in, 770
· decision making in, 750–751
· deep vein thrombosis in, 770
· diagnosis of, 746–750, 746*f*–750*f*
· early mobilization in, 769–770
· epidemiology of, 745
· evaluation of, 746–750, 746*f*–750*f*
· examination in, 746, 749
· extended iliofemoral approach in, 761, 762*f*
· fixation of, 98, 761–767, 763*f*–767*f*
· iliac oblique view in, 748*f*, 749
· ilioinguinal approach in, 752, 752*f*, 755, 756*f*–757*f*
· imaging in, 748*f*, 748*f*–750*f*, 749–750
· implant selection in, 751
· instrument selection in, 751
· Kocher-Langenbeck approach in, 745*f*, 752, 752*f*, 753–755–769, 789 (femur)
· Letournel classification of, 747*f*, 748*f*
· malalignment in, 93
· modified Stoppa approach in, 758–759, 758*f*–759*f*
· neurologic examination in, 749
· obturator oblique view in, 748*f*, 749
· open reduction and internal fixation in, 763–767, 763*f*–767*f*
· operating room set-up in, 752, 752*f*
· osteoporosis and, 769
· outcomes in, 770
· pediatric, 382
· periprosthetic, 837–838
· in polytrauma, 320*f*, 323*f*
· posterior column, 764, 765*f*
· posterior wall, 764, 764*f*, 765*f*
· postoperative care in, 769–770
· preoperative planning in, 751–752, 752*f*
· prognosis in, 770
· rectal examination in, 746
· reduction in, 761–767, 763*f*–767*f*
· rehabilitation in, 769–770
· sciatic nerve compromise in, 749
· surgical approaches in, 753–761, 754*f*, 756*f*–760*f*, 762*f*
· surgical indications in, 750–751
· timing of surgery in, 100, 751
· transverse, 766, 766*f*
· transverse T-shaped, 767
· vaginal examination in, 746
· venous thromboembolism in, 431, 433
· wall, 766–767, 767*f*
Acetaminophen, 437, 440*t*
Acetylsalicylic acid (ASA), 440*t*
ACL. *See* Anterior cruciate ligament (ACL)
Acromioclavicular joint dislocation, 581–583, 582*f*, 583*f*
Activated protein C resistance, 431*t*
Active molecule delivery, 33
Additive manufacturing (AM), 35
Additives, biological, in materials, 35
A frame, in external fixation, 263
Age, of patient, decision making and, 76
AIS. *See* Abbreviated Injury Scale (AIS)
Alarmins, 313
Allergic reactions
· to antibiotics, 422, 423, 424, 427*t*
· to implant materials, 32, 448
Allgöwer, Martin, 4
Allgöwer-Donati suture, 145, 145*f*, 146*f*
Allman classification, 575
Allografts
· in fragility fracture, 475, 477*f*
· in knee dislocation, 870, 871, 872–873, 873*f*
· in nonunion, 522–523
· in periprosthetic fractures, 846
AM. *See* Additive manufacturing (AM)
Amitriptyline, 440, 446
Amputation
· in bone loss, 353
· in damage-control surgery, 75
· in knee dislocation, 869
· limb salvage vs., 326, 349, 361–364, 361*f*–363*f*
· in osteomyelitis, 560
· pain management with, 440
· in pediatric patients, 392
· phantom limb pain with, 440
· in pilon fracture, 930
· subtotal, 59, 67*f*
· in tibial fracture, 910
· tissue banking and, 367
· traumatic, 51*t*
Analgesics, 437–442, 441*t*, 442*t*. *See also* Pain management
Anchor screw
· mechanism of, 179*t*
· in tibial fracture, 416*f*
Anderson, Roger, 3
Angiogenesis, 12
Angiosomes, 372, 914, 916*f*
Angled blade plate, reduction with, 132*f*, 133, 206, 206*f*
Angled pelvic reduction forceps, 123*t*, 126
Angular stable locking system (ASLS), 218
Ankle. *See* Malleolar fracture
Ankle-brachial index (ABI), 54
Anterior cruciate ligament (ACL)
· in knee dislocation, 865, 866, 870, 872
· in tibial fracture, proximal, 880, 880*f*
Anterior humeral circumflex artery, 591*f*
Anterior interosseous nerve palsy, 670
Anterior intrapelvic approach, 758–759, 758*f*–759*f*
Anterior sacroiliac ligament, 719*f*
Anterior surgical hip dislocation, 760–761, 760*f*
Anterior talofibular ligament, 837*f*, 937, 941
Antibiotic bead-pouch techniques
· in chronic infection, 556
· in closure, 146, 147*f*
· in open fracture, 338–339, 347
Antibiotic prophylaxis
· antibiotic resistance and, 425
· breadth of spectrum in, 424
· in closed fracture, 424
· *Clostridium difficile* and, 425, 427*t*
· controversial issues with, 424–426
· and decolonization of *S. aureus* nasal carriage, 425
· drugs in, 422–423
· duration of, 424, 424*t*
· glycopeptides in, 424
· guidelines, 426, 427*t*
· indications for, 421
· local delivery in, 426
· in open fracture, 424, 427*t*
· timing of, 423
Antibiotic resistance, 423, 425
Antibiotic therapy
· in acute infection, 541–542
· biofilms and, 532
· in chronic infection, 556
· in open fracture, 338–339

Anticoagulant therapy, in fragility fracture patients, 462–463
Antiglide plate, 203, 203*f*. *See also* Buttress plate
· lag screws in, 203, 203*f*
· reduction with, 133, 133*f*
· tubular plate as, 191, 191*f*
Antiplatelet agents, 432
Antiseptics, 542
Antithrombin deficiency, 431*t*
AO (Arbeitsgemeinschaft für Osteosynthesefragen/ Association for the Study of Internal Fixation)
· contemporary principles of, 6–7
· original principles of, 5
· philosophy of, 3, 6–7
· role of, 4
Arterial embolization, in pelvic ring fracture, 723
Arthritis. *See* Osteoarthritis; Septic arthritis
Arthrodesis
· external fixation in, 265
· in femoral fracture, 786
· and intraarticular malunion, 494
· in malunion, 518*f*
· in talar fracture, 972
· in tibial fracture, 930
Articular fracture
· clinical evaluation of, 96–98, 97*f*
· complete, defined, 42*t*, 43
· computed tomography in, 98, 99*f*
· continuous passive motion in, 98
· with diaphyseal extension, 101*f*, 102
· from direct application of force, 96, 97*f*
· early mobilization in, 98
· evaluation of, 96–98, 97*f*
· external fixation in, 253–254, 263, 263*f*
· femoral, 819, 827–832, 827*f*–833*f*
· fixation of, 94*f*
·· with diaphyseal extension, 101*f*, 102
·· indications for, 98
·· with metaphyseal extension, 101*f*, 102
·· techniques, 101–102, 101*f*
· functional considerations in, 94–96, 94*f*, 95*f*
· incision and, 144
· incongruity of articular surface in, 94, 94*f*
· from indirect application of force, 96, 97*f*
· instability in, 95, 95*f*
· ligament injury in, 96
· ligamentotaxis in, 101
· locking compression plates in, 291, 291*f*–293*f*, 305
· malalignment in, 94
· malunion in, 494, 494*f*
· mechanism of injury in, 96
· with metaphyseal extension, 101*f*, 102
· metatarsal, 996, 997*f*
· nonoperative treatment of, 100
· nonunion in, 524–525
· open, 353
· in osteoporosis, 98
· partial, defined, 42*t*, 43, 45, 45*t*
· patellar, 855*f*
· phalangeal, 710–712, 711*f*, 712*f*
· postoperative treatment in, 102
· posttraumatic osteoarthritis in, 95, 95*f*
· preoperative planning with, 100–101
· principles in, 93–104, 94*f*, 95*f*, 97*f*, 99*f*, 101*f*, 103*f*
· radiological evaluation of, 98, 99*f*
· reduction of, 101, 101*f*
·· aim of, 119
·· imperfect, 95*f*
·· surgical timing and, 100
·· techniques, 101–102, 101*f*
· scapula, 569, 569*f*
· soft-tissue envelope in, 96
· soft-tissue repair in, 102
· tension band concept in, 210–211, 211*f*
· timing of surgery for, 100
· traction in, 101, 120–121, 121*f*
· vascular status in, 96
· X-rays in, 98, 99*f*
Articulated tension device
· absolute stability and, 199–200, 199*f*, 200*f*
· in femoral fracture, 794
· in humeral fracture, 619
· with limited-contact dynamic compression plate, 188
· in malunion, 511*f*
· in nonunion, 523, 523*f*
· in reduction, 132*f*
ASA. *See* Acetylsalicylic acid (ASA)
ASLS. *See* Angular stable locking system (ASLS)
Aspirin, 432
Autodynamization, of intramedullary nails, 238
Avascular necrosis
· in acetabular fracture, 770
· in femoral fracture, 404*f*, 408, 411, 774, 780, 786
· in fragility fracture, 476*f*
· in humeral fracture, 604, 605
· in nonunion, 517*f*
· in talar fracture, 980
Axillary artery, 591*f*
Axillary nerve, 150

B

Ball spike, 129
Beanbag reduction, 228
Bennett fracture, 704–705, 705*f*
Beta-lactamase inducers, 422, 424
Beta tricalciumphosphate (β-TCP), 34
Biceps femoris flap, 375*f*
Bilateral frame, in external fixation, 263
Biochemical effects, of fracture, 10. *See also* Mechanical effects
Biocompatibility properties, 29–32, 30*f*, 32*f*
Biodegradable polymeric implants, 33
Biofilm, 53, 366, 530, 531*f*, 532, 548, 548*f*, 556
Biological additives, in materials, 35
Biological plating. *See* Bridging plate
Biomechanics. *See also* Mechanobiology
· and bone healing, 15–24, 15*f*–24*f*
· of bridging plate, 21, 204–205, 205*f*
· of callus, 17–18, 18*f*
· in cancellous bone fracture, 23
· of external fixation, 22, 254–255, 255*f*
· external splinting and, 16
· of fixation with absolute stability, 19–24, 20*f*–24*f*
· of fixation with relative stability, 16–19, 17*f*–19*f*
· of fracture healing, indirect, 17–19, 17*f*–19*f*
· of implants, 20–22, 21*f*, 22*f*
· of intramedullary nails, 17
· of lag screws, 20–21, 21*f*
· of locking compression plate, 21–22, 192–194, 193*f*, 194*f*, 288–289, 288*t*
· of multifragmentary fracture, 19
· of nonoperative fracture management, 15–16, 15*f*, 16*f*
· of nonoperative fracture treatment, 15–16, 16*f*
· in patellar fracture, 853
· in periprosthetic fracture, 839
· of plates, 17, 21–22, 22*f*, 186*t*
· in radial fracture, 676
· of screws, 175–176, 175*f*–177*f*
· of soft-tissue injury, 51, 51*t*
· of tension bands, 209–211, 209*f*–211*f*
· traction and, 15, 16*f*
Bipartite patella, 854–855
Bisphosphonate-associated femoral fracture, 811, 811*f*, 812*f*
Blast injury, 325–326, 327*f*, 333
Blisters, fracture, 54, 54*f*, 140
Blood supply
· absolute stability and, 23–24, 24*f*
· in articular fracture, 96
· comorbidities and, 10
· dynamic compression plate and, 11, 185
· in femoral shaft, 790–791, 790*f*
· fracture and, 10–12, 11*f*, 12*f*
· in humerus, proximal, 591, 591*f*
· implant and, 11
· incision and, 142
· and initial patient management, 10
· limited-contact dynamic compression plate and, 11, 11*f*, 185
· and mechanism of injury, 10
· in open fracture, 337–338, 338*f*
· in pelvic trauma, 718, 723, 725, 730–731, 730*f*
· in polytrauma, 74, 315–316
· reaming and, 12, 218
· recovery of, 23–24, 24*f*
· resuscitation and, 10, 315–316
· to skin, 137–138, 138*f*
· to soft tissue, 137–139, 138*f*
· in soft-tissue injury, 54, 357*f*
· surgical approach and, 11
· and traumatic sequelae, 11
BMPs. *See* Bone morphogenic proteins (BMPs)
Böhler, Lorenz, 4, 4*f*
Böhler's angle, 962*f*, 973*f*

Bone cement
· in antibiotic beads, 147*f*, 339, 426
· in femoral fracture, 832
· in fragility fracture, 474, 474*f*
· spacers, 353, 354*f*
Bone characteristics, and bone healing, 10
Bone density, defined, 454
Bone grafts
· in chronic infection, 553, 553*f*, 556
· in fragility fracture, 475, 476*f*
· in navicular fracture, 987
· in nonunion, 519, 521*f*, 522
Bone graft substitutes, 34–35
Bone healing
· angiogenesis in, 52
· biology of, 12–14, 14*f*
· biomechanics and, 15–24, 15*f*–24*f*, 17–19, 17*f*–19*f*
· bone morphogenic proteins in, 13
· callus perfusion and, 12
· in cancellous bone, 14
· and characteristics of bone, 10
· in cortical bone, 14
· direct, 12, 22–24, 23*f*, 24*f*
· in fixation with absolute stability, 19–20
· in fragility fracture, 475
· growth factors in, 13
· hard callus formation in, 13, 14*f*
· indirect, 12, 13, 14*f*, 17–19, 17*f*–19*f*
· inflammation in, 13, 14*f*
· mechanobiology of, 17–19, 17*f*–19*f*, 22–24, 23*f*, 24*f*
· patient characteristics in, 9
· primary, 12, 22–24, 23*f*, 24*f*
· reaming and, 218
· reduction and, 119
· remodeling in, 13, 14*f*
· secondary, 13, 14*f*, 17–19, 17*f*–19*f*
· soft callus formation in, 13, 14*f*
· types of, 12
· without treatment, 15, 15*f*
Bone holding forceps, 122*t*, 125, 125*f*
Bone hook, 129
Bone impactor, 129
Bone morphogenic protein-2
· adverse effects, 35
· recombinant, 35
Bone morphogenic proteins (BMPs), in fracture healing, 13
Bone quality. *See also* Osteoporosis
· defined, 454
· locking compression plates and, 272–277, 272*t*, 273*f*–277*f*
Bone regeneration, 34–35
Bone spreader, 122*t*, 125, 125*f*
Bone transport, external fixation in, 266
Bradykinin, 52
Brain injury. *See* Traumatic brain injury (TBI)
Bridging plate, 204–205, 205*f*
· biological, 241
· biomechanics of, 17, 21, 204–205, 205*f*
· callus and, 242, 242*f*, 243*f*
· in clavicular fracture, 578
· in diaphyseal fracture, 241, 242, 242*f*
· dynamic compression plate as, 245
· implant considerations with, 245–247, 245*f*–247*f*
· locking compression plate as, 247, 247*f*, 301, 302*f*–304*f*
· Masquelet technique and, 250
· in metaphyseal fracture, 244
· in minimally invasive plate osteosynthesis, 249*f*
· in multifragmentary fracture, 241, 241*f*, 242, 242*f*, 243*f*
· Perren strain theory and, 242, 242*f*
· in pilon fracture, 923
· in radial fracture, 694, 694*f*
· reduction with, indirect, 244–245, 244*f*
· relative stability of, 17
· in simple fracture, 242, 242*f*
· soft-tissue considerations with, 248–250, 249*f*
· stability and, 241
· in subtrochanteric fracture, 6*f*
· of subtrochanteric fracture, 6*f*
· in tibial fracture, 85*f*, 248, 249*f*, 251*f*
Bryan-Morrey approach, 630, 630*f*
Buttress plate, 203, 203*f*. *See also* Antiglide plate
· biomechanics of, 21
· in femoral fracture, 829–830, 829*f*
· lag screws in, 203, 203*f*
· limited-contact dynamic compression plate as, 189
· limited contact dynamic compression plate as, 189
· limited-contact dynamic compression plate as, 189*f*
· limited contact dynamic compression plate as, 189*f*
· in malleolar fracture, 951, 952*f*
· in pilon fracture, 927, 927*f*
· reduction with, 133, 133*f*
· tubular plate as, 191, 191*f*

C

Calcaneofibular ligament, 937
Calcaneus fracture
· anatomy in, 963
· arthritis in, 972
· Böhler's angle in, 962*f*, 973*f*
· classification of, 964, 964*f*
· complications in, 972
· diagnosis of, 961–963, 962*f*
· etiology of, 961
· evaluation of, 961–963, 962*f*
· extraarticular displacement in, 966
· fixation of, 969
· imaging of, 962–963, 963*f*
· intraarticular displacement in, 964*f*, 966
· malunion in, 510, 972
· minimally invasive plate osteosynthesis in, 154
· open reduction and internal fixation of, 140
· operating room set-up in, 966, 966*f*
· outcomes in, 972–974
· plating in, 970*f*
· postoperative care in, 439*t*, 972
· preoperative planning in, 965
· prognosis in, 972–974
· reduction of, 968, 968*f*
· secondary fracture lines in, 964*f*, 966, 967*f*
· surgical indications in, 965
Calcium therapy, 465–466
Callus
· biomechanics of, 17–18, 18*f*
· blood supply of, 12, 12*f*
· bone healing and perfusion of, 11, 12
· bridging plates and, 242, 242*f*, 243*f*
· formation of hard, in fracture healing, 13, 14*f*
· formation of soft, in fracture healing, 13, 14*f*
· in primary healing, 12
· strain and formation of, 19
Callus distraction, in chronic infection, 555, 555*f*
Cancellous bone
· biomechanics of fracture in, 23
· healing in, vs. cortical, 14
· osteoporosis in, 455, 456*f*
Cancellous bone screws, thread in, 177
Capillary refill, 359, 359*f*
Cardiorespiratory problems
· decision making and, 76
· fragility fracture and, 457–458
C-arm, 483–485, 483*f*–485*f*, 486–488, 487*f*
Carpal tunnel syndrome, 694
Carpometacarpal joint anatomy, 699
Carpometacarpal joint fracture
· finger, 706
· thumb, 704–706, 704*f*–707*f*
CARS. *See* Counter antiinflammatory response syndrome (CARS)
Catheterization, in pelvic ring fracture, 724
CCD. *See* Central column diaphyseal (CCD) angle
Cefoxitin, 422
Ceftazidime, 422, 423
Cefuroxime, 424*t*
Cement
· in antibiotic beads, 147*f*, 339, 426
· in femoral fracture, 832
· in fragility fracture, 474, 474*f*
· spacers, 353, 354*f*
Central column diaphyseal (CCD) angle, in humerus, 590
Cephalosporin, 427*t*
Cerclage, in minimally invasive plate osteosynthesis, 152
Cerclage wires, 130, 131*f*
Chest injury, in polytrauma, 324–325, 325*f*
Chevron osteotomy, in distal humeral fracture, 629, 629*f*
Children. *See* Pediatric fracture
Chopart joint, 983, 983*f*
Ciprofloxacin, 423
Circular ring fixator, 262, 262*f*
Clamps, in external fixation, 260, 261*f*

Clavicular fracture
· acromioclavicular joint dislocation in, 581–583, 582*f*, 583*f*
· Allman classification for, 575
· anatomy in, 574, 574*f*
· bridging plate in, 578
· case history in, 573
· classification of, 575
· complications in, 585
· diagnosis of, 573–574, 573*f*, 574*f*
· Edinburgh Classification in, 575
· epidemiology of, 573
· evaluation of, 573–574, 573*f*, 574*f*
· fixation of, 578–584, 578*f*–583*f*
· imaging in, 574, 574*f*
· implant selection in, 576–577, 576*f*
· intramedullary nails in, 223, 579
· lateral-end, 575, 580–583, 580*f*–583*f*
· locking compression plate in, 576
· malunion in, 501, 585
· medial-end, 575, 584
· minimally invasive plate osteosynthesis in, 155, 155*f*, 579, 579*f*
· nonunion in, 585
· operating room set-up in, 577, 577*f*
· osteoarthritis with, 585
· outcomes in, 585
· physical examination in, 573, 573*f*
· plating in, 578, 578*f*, 580–583, 580*f*–583*f*
· postoperative care in, 584
· preoperative planning in, 576–577, 576*f*, 577*f*
· prognosis in, 585
· reduction of, 578
· shaft fracture in, 575
· special characteristics of, 573
· sternoclavicular joint dislocation in, 584
· suprascapular nerve in, 574, 574*f*
· surgical approaches in, 577*f*, 578
· surgical indications in, 575
· timing of surgery in, 576
Clindamycin, 423, 427*t*
Clopidogrel, 432, 462
Closed skin degloving, 54
Clostridium difficile, 422, 423, 425, 427*t*
Closure, 144–146, 145*f*–147*f*, 862. *See also* Incision
· Allgöwer-Donati suture in, 145, 145*f*
· antibiotic bead-pouch techniques in, 146, 147*f*
· compartment syndrome and, 144
· importance of, 144
· in preoperative planning, 109
· silastic vessel loops in, 146, 147*f*
Cloxacillin, 423
Coagulopathy, in polytrauma, 314–315, 314*f*, 318*t*
Co-amoxiclav, 427*t*
Coatings, on implants, 33
Codeine, 441, 441*t*
Coding system, 40*f*
Colinear reduction forceps, 123*t*, 126, 126*f*, 151*f*
Collateral ligament complexes, in malleolar fracture, 837*f*, 937
Communication
· decision making and, 80
· in postoperative care, 444
Comorbidities
· blood supply and, 10
· with open fracture, 334
· with osteoporosis, 457–458
Comorbidity Construct, 459, 459*f*
Compartment syndrome
· clinical manifestation of, 55–56, 56*f*
· closure and, 144
· diagnosis of, 56–57
· in diaphyseal fracture, 84
· effects of, 56
· fasciotomy in, 57, 57*f*
· in forearm fracture, 670
· in humeral fracture, 623
· management of, 57, 57*f*
· pathophysiology of, 55
· in soft tissue injury, 55–57, 55*f*–57*f*
· in tibial fracture, shaft, 899
· tissue pressure measurement in, 56–57
Complex regional pain syndrome (CRPS), 10, 445–447, 446*f*, 670, 694
Complications
· in acetabular fracture, 770
· in calcaneal fracture, 972
· in clavicular fracture, 585
· in femoral fracture
·· distal, 834
·· proximal, 786
·· shaft, 813
· in forearm fracture
·· proximal, 655
·· shaft, 670–671
· in humeral fracture
·· distal, 635
·· proximal, 604–605
·· shaft, 620
· in knee dislocation, 874
· in malleolar fracture, 957–959, 958*f*
· in minimally invasive osteosynthesis (MIO), 170
· in open fracture, 348
· in pelvic ring fracture, 743
· in pilon fracture, 928–930
· in radial fracture, 694, 695*f*
· in scapular fracture, 570
· in talar fracture, 979–980
· in tension banding, 215
· in tibial fracture, proximal, 896
Compressive preload, 20, 20*f*
Computed tomography (CT). *See also* Imaging
· in acetabular fracture, 750, 750*f*
· in articular fracture, 98, 99*f*
· in calcaneal fracture, 963, 963*f*
· in clavicular fracture, 574
· in humeral fracture, 590, 590*f*
· in infection diagnosis, 536, 549, 550*f*
· in malleolar fracture, 935, 935*f*
· in pelvic ring fracture, 723
· in periprosthetic fracture, 840, 840*f*
· in pilon fracture, 914
· in preoperative planning, 106
· in radial fracture, 674–676, 675*f*, 676*f*
· in tibial fracture, proximal, 878
Condylar fracture, in pediatric patients, 398, 399*f*
Content validity, in fracture classification, 48
Continuous passive motion (CPM), in articular fracture, 98
Contouring, of plates, 202, 202*f*
· absolute stability and, 198
· ductility and, 28
· fixation and, 109
· limited-contact dynamic compression, 153, 153*f*
· locking compression, 153
· in minimally invasive plate osteosynthesis, 155, 160, 162, 166, 167*f*
· reconstruction, 192
· soft-tissue handling and, 152
· tubular, 191, 191*f*
Coronoid fracture
· elbow dislocation in, 653, 653*f*
· surgical approaches in, 644–645, 644*f*, 645*f*
Corrective osteotomy, external fixation in, 265
Corrosion resistance, 29–30, 29*f*
Cortex screws, thread in, 177
Cortical bone
· healing in, vs. cancellous, 14
· osteoporosis in, 455, 455*f*
Coumarins, 463
Counter antiinflammatory response syndrome (CARS), 312
Countersink, 176, 176*f*
COX-2 inhibitors, 440
CPM. *See* Continuous passive motion (CPM)
"Cripple cast," 694, 695*f*
CRPS. *See* Complex regional pain syndrome (CRPS)
Crush injury, 332
CT. *See* Computed tomography (CT)
Cubitus varus, 398
Cuboid fracture
· anatomy in, 988, 988*f*
· compression, 990
· fracture patterns in, 988–990, 989*f*, 990*f*
· nonoperative management of, 988
· plating in, 989*f*
· treatment of, 988–990, 989*f*, 990*f*
Cutaneous vessels, 137–138
Cytokines, 52

D

Damage-associated molecular patterns (DAMPs), 313
Damage-control orthopedics (DCO), 220, 311–312, 317–319, 318*t*, 319*t*
Damage-control surgery, in polytrauma, 75, 75*f*
DAMPs. *See* Damage-associated molecular patterns (DAMPs)

Danis, Robert, 3, 4, 4*f*
DCO. *See* Damage-control orthopedics (DCO)
DCP. *See* Dynamic compression plate (DCP)
DDD. *See* Degenerative disc disease (DDD)
Debridement
· in open fracture, 339–340, 340*f*
· of soft-tissue injury, as diagnostic, 54
· in soft-tissue reconstruction, 366
· in treatment of acute infection, 537–538
· in treatment of chronic infection, 551, 551*f*
Decision making
· in acetabular fracture, 750–751
· cardiorespiratory problems and, 76
· communication and, 80
· diabetes and, 76
· fracture factors in, 78
· healthcare environment and, 80
· health status and, 76–77
· interdisciplinary, 364–366, 365*f*
· joint disease and, 77
· liver disease and, 77
· malignant disease and, 77
· in malunion, 497, 497*f*
· medications and, 77
· mental health and, 77
· neurological conditions and, 77
· obesity and, 77
· patient occupation and, 77
· in pelvic ring fracture, 721–725, 722*f*, 725*f*–729*f*, 731–732, 731*t*
· peripheral arterial disease and, 76
· in periprosthetic fracture, 844, 848
· "personality" of injury and, 73, 73*f*, 76–78
· in polytrauma, 74–76, 74*f*, 75*f*
· in preoperative planning, 108–109
· renal disease and, 76–77
· social factors and, 77–78
· in soft-tissue loss, 364–366, 365*f*
· soft tissues and, 78
· on timing of surgery, 78–79, 79*t*
· venous disease and, 76
Deep vein thrombosis (DVT), 429–430, 770. *See also* Thromboembolic prophylaxis
Degenerative disc disease (DDD), bone morphogenic protein-2 in, 13
Degloving
· in articular fracture, 100
· closed skin, 54, 62*f*, 141, 141*f*
· skin grafts in, 370
Delirium, 463–464
Deltoid split, in proximal humeral fracture, 596, 596*f*
Deltopectoral approach
· in humeral fracture, proximal, 594, 595*f*
· in scapular fracture, 567
Dementia, fragility fracture and, 458, 463–464
Destot sign, 717
DEXA. *See* Dual-energy X-ray absorptiometry (DEXA)
Dextromethorphan, 440
DHS. *See* Dynamic hip screw (DHS)
Diabetes
· decision making and, 76
· fragility fracture and, 458
· infection and, 76
· malleolar fracture in, 956, 959
· nonunion and, 518, 518*f*
Diaphyseal malunion, 496, 496*f*
Diclofenac, 440*t*
Dihydromorphine, 462
DIOM. *See* Distal interosseous membrane (DIOM)
Direct oral anticoagulants (DOAC), 463
Dislocations
· anterior surgical hip, 760–761, 760*f*
· in clavicular fracture
·· acromioclavicular joint, 581–583, 582*f*, 583*f*
·· sternoclavicular joint, 584
· distal radioulnar joint, 657
· elbow, 651–652, 651*f*, 653, 653*f*
·· in coronoid fracture, 653, 653*f*
· hip
·· in acetabular fracture, 749
·· anterior surgical, 760–761, 760*f*
· knee
·· anatomy in, 866–868, 866*f*–868*f*
·· anterior cruciate ligament in, 865, 866, 870, 872
·· central pivot in, 866
·· collateral ligaments in, 872, 872*f*, 873*f*
·· complications in, 874
·· cruciate ligaments in, 872–873
·· decision making in, 870
·· epidemiology of, 865–866
·· evaluation in, 868–870, 869*f*
·· examination under anesthesia in, 871
·· extensor mechanism in, 868
·· meniscal preservation in, 871, 871*f*
·· neurovascular assessment in, 868–869
·· open, 869, 869*f*
·· outcomes in, 874
·· peroneal nerve palsy in, 869
·· popliteal fossa, 868, 868*f*
·· posterior capsule repair in, 871
·· posterior cruciate ligament in, 865, 866, 870, 871, 872–873
·· posterolateral corner in, 866*f*, 867, 867*f*, 872, 872*f*
·· posteromedial corner in, 866, 866*f*, 872, 873*f*
·· postoperative care in, 873, 873*f*
·· preoperative planning in, 870–871
·· primary treatment in, 868–870
·· surgical indications in, 870
·· timing of surgery in, 870
·· treatment of, 870–871
· posterior Monteggia fracture, 652–653, 652*f*–653*f*
· timing of surgery and, 79*t*
· transolecranon fracture, 651–652, 651*f*
Displacement
· in articular fracture, 98
· compressive preload and, 20*f*
· external fixation and, 16, 17
· friction and, 20
· imaging of, 117
· reduction and, 117, 117*f*
· rotational, 117*f*
· secondary, nonoperative treatment and, 87
· stabilization and, 15, 16
· translational, 117*f*
Distal interosseous membrane (DIOM), 695–696, 696*f*
Distal lateral fasciocutaneous thigh flap, 374*f*
Distal medial fasciocutaneous thigh flap, 374*f*
Distal radioulnar joint (DRUJ) dislocation, 657
Distraction osteogenesis, external fixation in, 266
DOAC. *See* Direct oral anticoagulants (DOAC)
Drains, 146
Dressings
· in open fracture, 346–347, 347*f*
· in postoperative care, 442
Dual-energy X-ray absorptiometry (DEXA), 456, 840
Ductility, of materials, 28
DVT. *See* Deep vein thrombosis (DVT)
Dynamic compression plate (DCP). *See also* Limited-contact dynamic compression plate (LC-DCP)
· blood supply and, 11, 11*f*, 185
· as bridge plate, 245
· in humeral fracture, shaft, 610
· in pelvic ring fracture, 735*f*
Dynamic hip screw (DHS)
· design of, 196*f*
· in femoral fracture, proximal, 778, 778*f*
· in minimally invasive plate osteosynthesis, 160
Dynamization, of intramedullary nails, 238

E

Early appropriate care, in polytrauma, 76, 312
Early mobilization, 443, 443*f*
· of acetabular fracture patients, 769–770
· of articular fracture patients, 98
· of diaphyseal fracture patients, 87
Early total care (ETC), in polytrauma, 75–76, 220, 311–312, 319, 319*t*
Edinburgh Classification, 575
Elbow capsule, 640
Elbow dislocation, 651–652, 651*f*, 653, 653*f*
Electrocautery, 142
Embolization, in pelvic ring fracture, 723
Environment, healthcare, decision making and, 80
Epiphysis, in fracture classification, 41
Equipment
· in preoperative planning, 109, 109*f*
· in reduction, 121–131, 122*t*, 123*t*, 124*f*–131*f*
Erosion, 30
Essex-Lopresti injury, 654, 654*f*, 660, 660*f*
ETC. *See* Early total care (ETC)
EUA. *See* Examination under anesthesia (EUA), in pelvic ring fracture

Examination under anesthesia (EUA)
· in knee dislocation, 871
· in pelvic ring fracture, 731, 736
· in tarsometatarsal joint injury, 994
Extended iliofemoral approach, 761, 762*f*
External fixation. *See also* Fixation
· advantages of, 253
· in arthrodesis, 265
· in articular fracture, 253–254, 263, 263*f*
· bilateral frame in, 263
· biomechanics of, 16–17, 22, 254–255, 255*f*
· bone loss and, 254, 353
· in bone transport, 266
· circular ring fixator in, 262, 262*f*
· clamps in, 260, 261*f*
· in closed fracture, 253
· in corrective osteotomy, 265
· in diaphyseal fracture, 90–91
· diaphysis in, 256
· in distraction osteogenesis, 266
· dynamization in, 267
· elements of, 260–262, 260*f*–262*f*
· external fixation in, 795, 795*f*
· in femoral fracture, 257*f*, 795, 795*f*, 831, 831*f*
· frame construction in, 263–265, 263*f*–265*f*
· A frame in, 263
· hinged external fixator in, 262
· in humeral fracture, 259*f*, 619, 619*f*
· hybrid external fixator in, 261, 261*f*
· indications for, 253–254, 254*f*
· infection after, 266–267
· infection and, 265
· infection susceptibility and, 31–32
· in joint reduction, 266
· lengthening frame in, 263
· in malunion, 499
· metaphysis in, 256
· modular reduction technique in, 264–265, 264*f*, 265*f*
· monolateral system in, 261, 261*f*
· nonunion and, 524
· in open fracture, 253, 344–345, 345*f*, 353
· osteomyelitis and, 533*f*, 534, 544
· in pediatric fracture, 392, 393*f*, 396, 397*f*
· in pelvic ring fracture, 742, 742*f*
· pin insertion technique in, 255
· pin-track care in, 266
· in polytrauma, 253
· postoperative management in, 266–267
· principles of, 254–256, 257*f*–259*f*
· in radial fracture, 686–690, 687*f*–691*f*
· in reduction, 121, 254
· relative stability of, 16–17
· rods in, 260, 260*f*
· safe zones in, 256, 257*f*–259*f*
· Schanz screws in, 255, 260, 260*f*, 264, 264*f*
· screws in, 255, 255*f*
· soft-tissue loss and, 254
· spanning frame in, 263, 263*f*
· special applications of, 265–266
· stability in, 255
· Steinmann pin in, 255, 260
· stiffness in, 255, 255*f*
· in supracondylar fracture, 396, 397*f*
· in tibial fracture, 256, 258*f*, 345*f*
·· shaft, 905, 905*f*, 909
· timeframe for, 267
· transition to internal, 267
· in treatment of chronic infection, 552–553, 552*f*
· tube-rod system in, 260, 260*f*
· unilateral frame in, 263

F

Factor VIII excess, 431*t*
Falls, fragility fracture and, 456, 465
Farabeuf forceps, 123*t*, 127, 127*f*
Fasciocutaneous groin flap, 374*f*
Fasciocutaneous instep flap, 375*f*
Fasciocutaneous radial forearm flap, 377*f*
Fasciocutaneous saphenous flap, 374*f*
Fasciocutaneous vascular system, 137
Fasciotomy, in compartment syndrome, 57
FAST. *See* Focused Abdominal Sonography for Trauma (FAST)
Fecal contamination, in open pelvic fracture, 724–725
Femoral bowing, 817
Femoral fracture. *See also* Intramedullary nails
· atypical, in fragility fracture, 469
· distal
·· anatomy in, 815–817, 816*f*, 817*f*
·· challenges with, 832
·· classification of, 817, 817*f*
·· complications in, 834
·· condylar buttress in, 829–830, 829*f*
·· diagnosis of, 815
·· displaced, lag screws in, 7*f*
·· evaluation of, 815
·· external fixation of, 831, 831*f*
·· extraarticular, 826, 826*f*
·· fixation of, 826–832, 826*f*–833*f*
·· implant selection in, 818–819, 819*f*
·· intraarticular, 819, 827–832, 827*f*–833*f*
·· intramedullary nailing in, 830–831, 830*f*, 831*f*, 834
·· less invasive stabilization system in, 829–830, 829*f*
·· locking compression plate in, 196*f*, 829–830, 829*f*
·· malalignment in, 834
·· medial subvastus approach in, 824, 824*f*
·· minimally invasive plate osteosynthesis in, 162–164, 163*f*, 822, 822*f*
·· modified standard lateral approach in, 822, 822*f*
·· muscle groups and, 817, 817*f*
·· nonunion in, 834
·· operating room set-up in, 820, 820*f*
·· outcomes in, 834
·· parapatellar approach in, 823, 823*f*
·· patient positioning in, 821, 821*f*
·· periprosthetic, 832, 832*f*, 833*f*
·· plate malposition in, 834
·· postoperative care in, 834
·· preoperative planning in, 818–820, 818*f*–820*f*
·· prognosis in, 834
·· reduction of, 826–832, 826*f*–833*f*
·· retrograde nailing approach in, 825, 825*f*
·· with shaft fracture, 807
·· standard lateral approach in, 822
·· surgical approaches in, 821–825, 821*f*–825*f*
·· surgical indications in, 818
·· timing of surgery in, 818, 818*f*
·· vascular injury in, 817
· external fixation in, 257*f*
· intramedullary nailing in, 221–222
· length discrepancies after, 493*f*
· malunion in, 496, 496*f*, 498*f*, 500*f*, 504–506, 506*f*, 507*f*
· in osteoporosis, 467*f*–468*f*, 472*f*
· pediatric, 381*t*, 404–413, 404*f*–414*f*
· periprosthetic, 467*f*–468*f*, 837–838, 847*f*, 848–851, 849*f*–850*f*
· in polytrauma, 220–221
· postoperative care in, 438*t*, 439*t*
· proximal
·· algorithm for, 779
·· anatomy in, 774, 775*f*
·· case history in, 773
·· challenges with, 782, 784, 786
·· classification of, 43, 43*t*, 774–776, 775*f*
·· complications in, 786
·· diagnosis of, 773–774
·· displaced subcapital, 780–782, 781*f*–783*f*
·· dynamic hip screws in, 778, 778*f*
·· epidemiology of, 773
·· evaluation of, 773–774
·· examination in, 773
·· femoral head, 785–786, 785*f*
·· fixation of, 782, 783*f*, 784, 784*f*, 785, 785*f*
·· imaging in, 774
·· implant considerations with, 776–779, 777*f*–779*f*
·· intertrochanteric, 782–784, 784*f*
·· intramedullary nailing in, 779, 779*f*
·· minimally invasive plate osteosynthesis in, 160, 160*f*–161*f*
·· nondisplaced subcapital, 780
·· operating room set-up for, 780, 780*f*
·· outcomes in, 786
·· pertrochanteric, 777*f*
·· postoperative care in, 786
·· preoperative planning for, 776–780, 777*f*–780*f*
·· prognosis in, 786
·· reduction of, 782, 782*f*, 784, 784*f*, 785, 785*f*
·· special characteristics of, 773
·· surgical approaches in, 780, 781*f*, 785
·· surgical indications in, 776
·· timing of surgery in, 776
· reduction of
·· with intramedullary nailing, 228
·· with Schanz screws, 245*f*

· shaft
·· acceptable malalignment in, 381*t*
·· anatomy in, 790–791, 790*f*
·· atypical, 811, 811*f*, 812*f*
·· bilateral, 789
·· bisphosphonate-associated, 811, 811*f*, 812*f*
·· blood supply in, 790–791, 790*f*
·· case history in, 789–790
·· challenges with, 805–811, 805*f*–812*f*
·· classification of, 791, 791*f*
·· complications in, 813
·· diagnosis of, 789–790
·· with distal fracture, 807
·· epidemiology of, 789
·· evaluation of, 789–790
·· examination in, 789–790
·· external fixation in, 795, 795*f*
·· fixation of, 802–805, 802*f*–804*f*
·· general condition of patient in, 790
·· imaging in, 790
·· implant selection in, 793–795, 794*f*, 795*f*
·· infections in, 813
·· intramedullary nailing in, 792*f*, 793, 799–800, 799*f*, 800*f*, 808, 808*f*
·· laboratory tests in, 789
·· lag screws in, 806, 806*f*
·· malunion in, 813
·· minimally invasive plate osteosynthesis in, 151, 162, 162*f*, 794, 794*f*
·· neck, 805–807, 805*f*–807*f*
·· nonunion in, 813
·· open, 789
·· operating room set-up for, 795, 796*f*
·· outcomes in, 813
·· patient positioning in, 797, 798*f*
·· plating in, 792, 793–794, 794*f*, 800–801, 800*f*, 801*f*, 809, 809*f*
·· postoperative care in, 813
·· preoperative planning with, 793–795, 794*f*, 796*f*
·· prognosis in, 813
·· reaming in, 804
·· reduction of, 802–805, 802*f*–804*f*
·· Schanz screws in, 795, 795*f*, 803*f*
·· special characteristics of, 789
·· subtrochanteric, 807–808, 808*f*
·· surgical approaches for, 797–801, 798*f*–801*f*
·· surgical indications for, 791–792, 792*f*
·· timing of surgery in, 793
· tension band concept in, 210, 210*f*, 212*f*
· trochanteric 2-part, 778*f*
Fentanyl, 441, 441*t*
Fernandez classification, 677, 677*t*
Fibrous capsule formation, surface properties and, 31, 32*f*
Fibular fracture. *See also* Malleolar fracture
· bone graft in, 553*f*
· buttress plate in, 191*f*
· classification of, 43*f*, 49
· external fixation of, 345*f*
· infection in, 543*f*
· intramedullary nailing in, 343*f*
· limited-contact dynamic compression plate in, 187
· in malleolar fracture, 938*f*, 940*f*, 941*f*–942*f*, 945, 950, 950*f*, 951, 952*f*, 954, 954*f*, 955*f*
· nonunion of, 519
· open, 334, 346*f*
· pediatric, 417, 418*f*
· posterolateral approach in, 923*f*
Finger carpometacarpal joint fracture, 706
Fixation. *See also* Open reduction and internal fixation (ORIF); Plate(s)
· in acetabular fracture, 98, 761–767, 763*f*–767*f*
· in articular fracture, 94*f*
·· with diaphyseal extension, 101*f*, 102
·· indications for, 98
·· with metaphyseal extension, 101*f*, 102
·· techniques, 101–102, 101*f*
· biomechanics of, 16–19, 17*f*–19*f*
· blood supply and, 12
· bone healing and, 19–20
· in calcaneal fracture, 969
· in clavicular fracture, 578–584, 578*f*–583*f*
· compressive preload and, 20, 20*f*
· in diaphyseal fracture
·· indications for, 86–87
·· techniques, 90–91
· in early total care for polytrauma, 76
· external
·· advantages of, 253
·· in arthrodesis, 265
·· in articular fracture, 253–254, 263, 263*f*
·· bilateral frame in, 263
·· biomechanics of, 16–17, 22, 254–255, 255*f*
·· bone loss and, 254, 353
·· in bone transport, 266
·· circular ring fixator in, 262, 262*f*
·· clamps in, 260, 261*f*
·· in closed fracture, 253
·· in corrective osteotomy, 265
·· in diaphyseal fracture, 90–91
·· diaphysis in, 256
·· in distraction osteogenesis, 266
·· dynamization in, 267
·· elements of, 260–262, 260*f*–262*f*
·· external fixation in, 795, 795*f*
·· in femoral fracture, 257*f*, 795, 795*f*, 831, 831*f*
·· frame construction in, 263–265, 263*f*–265*f*
·· A frame in, 263
·· hinged external fixator in, 262
·· in humeral fracture, 259*f*, 619, 619*f*
·· hybrid external fixator in, 261, 261*f*
·· indications for, 253–254, 254*f*
·· infection after, 266–267
·· infection and, 265
·· infection susceptibility and, 31
·· in joint reduction, 266
·· lengthening frame in, 263
·· in malunion, 499
·· metaphysis in, 256
·· modular reduction technique in, 264–265, 264*f*, 265*f*
·· monolateral system in, 261, 261*f*
·· nonunion and, 524
·· in open fracture, 253, 344–345, 345*f*, 353
·· osteomyelitis and, 533*f*, 534, 544
·· in pediatric fracture, 392, 393*f*, 396, 397*f*
·· in pelvic ring fracture, 742, 742*f*
·· pin insertion technique in, 255
·· pin-track care in, 266
·· in polytrauma, 253
·· postoperative management in, 266–267
·· principles of, 254–256, 257*f*–259*f*
·· in radial fracture, 686–690, 687*f*–691*f*
·· in reduction, 121, 254
·· relative stability of, 16–17
·· rods in, 260, 260*f*
·· safe zones in, 256, 257*f*–259*f*
·· Schanz screws in, 255, 260, 260*f*, 264, 264*f*
·· screws in, 255, 255*f*
·· soft-tissue loss and, 254
·· spanning frame in, 263, 263*f*
·· special applications of, 265–266
·· stability in, 255*f*
·· Steinmann pin in, 255, 260
·· stiffness in, 255, 255*f*
·· in supracondylar fracture, 396, 396*f*
·· in tibial fracture, 256, 258*f*, 345*f*
··· shaft, 905, 905*f*, 909
·· timeframe for, 267
·· transition to internal, 267
·· in treatment of chronic infection, 552–553, 552*f*
·· tube-rod system in, 260, 260*f*
·· unilateral frame in, 263
· in femoral fracture
·· distal, 826–832, 826*f*–833*f*
·· femoral head, 785, 785*f*
·· pediatric, 404, 405*f*–406*f*
·· proximal, 782, 783*f*, 784, 784*f*
·· shaft, 802–805, 802*f*–804*f*
· in forearm fracture, 645–650, 646*f*–659*f*, 668, 668*f*, 669*f*
· in fragility fracture, 470, 471–475, 472*f*–474*f*
· friction and, 20, 20*f*
· in hand fracture, 699, 704
· history of, 3–4
· in humeral fracture
·· distal, 632–634, 633*f*, 634*f*
·· proximal, 597–604, 597*f*–602*f*
·· shaft, 619, 619*f*
· with intramedullary nails, 237–238, 237*f*
· main goal of, 9
· in malleolar fracture, 949–956, 950*f*, 952*f*–955*f*
· in malunion, 498–499, 498*f*, 500*f*
· in open fracture, 341–346, 342*f*–346*f*
· osteomyelitis and, 533–534, 533*f*, 534*f*
· osteoporosis and, 456
· in patellar fracture, 858–860, 859*f*–861*f*
· in pelvic ring fractures, 731–742, 731*t*, 733*f*–742*f*
· in periprosthetic fracture, 846–848, 847*f*, 848, 849*f*

· in pilon fracture, 925–928, 926*f*, 927*f*
· in preoperative planning, 108*f*, 109
· provisional, in preoperative planning, 109
· of pubic rami, 736–737, 736*f*
· in radial fracture, distal, 682–684, 683*f*, 686, 687*f*
· with relative stability, 16–19, 17*f*–19*f*
· in rib fracture, 325
· in scapular fracture, 570, 571*f*
· soft-tissue reconstruction and, 366
· surgical
·· with absolute stability, 19–24, 20*f*–24*f*
·· biomechanics of, 19–24, 20*f*–24*f*
· in tibial fracture
·· proximal, 887–893, 887*f*–894*f*
·· shaft, 907–909
Flail chest, 325
Flaps
· axial pattern, 372
· biceps femoris, 375*f*
· classification of, 370, 371*t*
· defined, 372
· distal lateral fasciocutaneous thigh, 374*f*
· distal medial fasciocutaneous thigh, 374*f*
· distant, 376, 377*f*
· fasciocutaneous groin, 374*f*
· fasciocutaneous instep, 375*f*
· fasciocutaneous radial forearm, 377*f*
· fasciocutaneous saphenous, 374*f*
· gluteus maximus muscle, 375*f*
· gracilis muscle, 374*f*
· lateral fasciocutaneous supramalleolar, 374*f*
· lateral gastrocnemius, 375*f*
· local, 372, 373*f*
· medial fasciocutaneous foot, 375*f*
· medial gastrocnemius muscle, 375*f*
· microvascular, 376, 377*f*
· osteoseptocutaneous fibula, 374*f*
· pedicled, 372, 373*f*, 374*f*
· rectus abdominis, 374*f*
· regional, 372, 374*f*
· in soft-tissue reconstruction, 370–376, 371*t*, 373*f*–375*f*
· soleus muscle, 375*f*
· sural fasciocutaneous, 375*f*
· tensor fasciae latae musculocutaneous, 374*f*
· vastus lateralis muscle, 374*f*
Floating knee injury, 227
Floating shoulder, 570
Flucloxacillin, 424*t*, 427*t*
Focused Abdominal Sonography for Trauma (FAST), 723
Foot, mangled, 998, 999*f*
Forceps
· bone holding, 122*t*, 125, 125*f*
· colinear reduction, 123*t*, 126, 126*f*, 151*f*
· Farabeuf, 123*t*, 127, 127*f*
· Jungbluth, 123*t*, 127, 127*f*
· Matta, 123*t*, 126
· reduction
·· colinear, 123*t*, 126, 126*f*, 151*f*
·· pelvic, 123*t*, 126, 126*f*, 127, 127*f*
·· with points, 122*t*, 124, 124*f*
·· toothed, 122*t*, 125, 125*f*
· soft-tissue considerations with, 142
· Verbrugge, 122*t*, 125, 125*f*
· Weber, 122*t*, 124, 124*f*
Forearm fracture. *See also* Olecranon fracture; Radial fracture
· acceptable malalignment in, 381*t*
· Essex-Lopresti injury in, 654, 654*f*
· intramedullary nailing in, 222
· limited-contact dynamic compression plates in, 187
· locking compression plate in, 289
· malunion in, 504, 504*f*
· pediatric, 399–402, 400*f*–402*f*
· postoperative management of, 438*t*
· proximal
·· anatomy in, 637, 637*f*, 638–640, 639*f*
·· case history in, 637
·· challenges with, 655
·· classification of, 640, 640*f*
·· complications in, 655
·· diagnosis of, 637–638, 638*f*
·· epidemiology of, 637
·· evaluation of, 637–638, 638*f*
·· fixation of, 645–650, 646*f*–659*f*
·· imaging in, 637, 637*f*
·· implant selection in, 641
·· nonoperative care for, 641
·· operating room set-up for, 642*f*, 642–643, 643*f*
·· outcomes in, 655
·· patient positioning in, 641–642, 642*f*
·· physical examination in, 637
·· preoperative planning in, 641–643, 642*f*, 643*f*
·· prognosis in, 655
·· prone position in, 642, 642*f*
·· reduction of, 645–650, 646*f*–659*f*
·· supine position in, 642, 642*f*
·· surgical approaches in, 643–645, 643*f*–645*f*
·· surgical indications for, 641
·· timing of surgery in, 641
· shaft
·· anatomy in, 657–658
·· case history in, 657
·· challenges with, 670
·· classification of, 658–660, 658*f*–660*f*
·· compartment syndrome in, 670
·· complex regional pain syndrome in, 670
·· complications in, 670–671
·· diagnosis of, 657
·· epidemiology of, 657
·· Essex-Lopresti lesion in, 660, 660*f*
·· evaluation of, 657
·· fixation of, 668, 668*f*, 669*f*
·· Galeazzi fracture in, 659, 659*f*
·· Henry approach in, 664, 664*f*, 665*f*
·· imaging in, 657
·· implant selection in, 661
·· nerve palsy in, 670
·· nonunion in, 671
·· operating room set-up in, 661–662, 661*f*, 662*f*
·· outcomes in, 671
·· physical examination in, 657
·· posterolateral approach for, 666, 666*f*
·· postoperative care for, 670
·· preoperative planning in, 661–662, 661*f*, 662*f*
·· prognosis in, 671
·· reduction in, 667, 667*f*
·· refracture in, 671
·· special characteristics of, 657
·· surgical approaches in, 662–666, 663*f*–666*f*
·· surgical indications for, 661
·· synostosis in, 670–671
·· Thompson approach in, 666, 666*f*
·· timing of surgery in, 661
Fracture. *See also* Articular fracture; Bone healing; Fragility fracture; Open fracture; Pediatric fracture; Periprosthetic fracture; *specific bones*
· biochemical effects of, 10
· blood supply and, 10–12, 11*f*, 12*f*
· contamination and, in polytrauma, 312
· decision making and, 78
· diaphyseal
·· arterial injury in, 84
·· associated injuries with, 86
·· bridge plating in, 241, 242, 242*f*
·· case history in, 84
·· casting in, 87
·· classification process in, 46, 46*t*
·· compartment syndrome in, 84
·· early mobilization after, 87
·· fixation of
··· as gold standard, 90–91
··· indications for, 86–87
··· techniques, 90–91
·· functional considerations with, 83–84, 83*f*
·· groups in, 44, 44*t*
·· incidence of, 84
·· incision and, 143
·· initial evaluation of, 84–86
·· intramedullary nails in, 90
·· load transmission in, 91
·· malunion in, 496, 496*f*
·· mechanism of, 84
·· mechanobiology of healing in, 22–23, 23*f*
·· nonoperative treatment of, 87–89, 88*f*
·· nonunion in, 525–526, 526*f*
·· oblique, 44, 44*t*
·· operative treatment principles in, 89–91, 89*f*
·· patient status in, 84
·· patterns of injury in, 84, 85*f*
·· physiotherapy in, 91
·· plates in, 90
·· postoperative care in, 91
·· preoperative planning in, 90
·· radiographic evaluation in, 84–86
·· reduction of, 83*f*, 85*f*, 88*f*, 120
··· surgical timing and, 89
··· techniques, 90–91

·· residual deformity with, 83
·· screws in, 90, 91*f*
·· soft-tissue injury in, 84, 85*f*, 86
·· spiral, defined, 44, 44*t*, 84
·· tension band in, 212
·· timing of surgery in, 89, 89*f*
·· transverse, 44, 44*t*, 84
·· types of, 42
·· valgus deformity in, 83
·· varus deformity in, 83
·· X-rays in, 84–86
· extraarticular, defined, 42, 42*t*
· fragmentary, 49
· fragmentary depression, 49
· hemorrhage and, in polytrauma, 312
· hypoxic zones and, in polytrauma, 312
· impacted, 49
· ischemia-reperfusion and, in polytrauma, 312
· mechanical effects of, 10
· metaphyseal
·· bridge plating in, 244
·· in classification, 47, 47*f*, 47*t*
·· defined, 42
·· intramedullary nailing in, 230
·· locking compression plates in, 272*t*, 288*t*, 289, 290*f*
·· malunion in, 495, 495*f*
·· minimally invasive plate osteosynthesis in, 150
·· nonunion in, 525
·· Poller screws in, 230, 230*f*
·· reduction of, 133, 133*f*
·· types of, 45, 45*t*
· multifragmentary, 45, 45*t*, 85*f*
·· biomechanics of, 19
·· bridge plating in, 241, 241*f*, 242, 242*f*, 243*f*
·· defined, 42, 42*t*, 49
·· locking compression plates in, 288*t*
·· patellar, 856*f*, 860, 860*f*
·· radial, 650
· nonoperative treatment of, 15–16, 16*f*
· periarticular, locking compression plates in, 278, 278*f*, 291, 291*f*–293*f*
· in polytrauma, importance of, 311–312
· pure depression, 49
· simple, 42, 42*t*
· split, 49
Fracture blisters, 54, 54*f*, 140
Fracture classification
· accuracy in, 48
· attributes in, 39, 40*f*
· bones and segments in, 40*f*, 41, 41*f*
· coding system in, 40*f*
· content validity in, 48
· epiphysis in, 41
· groups in, 44–45, 44*t*, 45*t*
· interobserver reliability in, 48
· location in, 39, 40*f*, 41, 41*f*
· in malleolar segment, 43, 43*t*
· metaphysis in, 41
· morphology in, 39, 40*f*, 42–45, 42*t*–45*t*
· observation in, 46
· open, 335, 335*t*
· process of, 46–47, 46*t*, 47*t*, 49
· revision process, 48–49
· structure in, 39, 40*f*
· subgroups in, 44–45, 44*t*, 45*t*
· system, 49
· terminology, 49
· Tscherne, 59
· types in, 42–43, 42*t*, 43*t*
· validation of, 48
· visualization in, 46
Fragility fracture. *See also* Osteoporosis
· allografts in, 475, 477*f*
· anesthesia in patients with, 466–467
· anesthesiologist in, 460
· anticoagulant therapy in patients with, 462–463
· blood transfusion management and, 464
· bone cement in, 474, 474*f*
· bone deformation in, 469
· bone grafts and, 475, 476*f*
· bone healing in, 475
· cardiac disease and, 457
· cardiologist in, 461
· comorbidities with, 457–458
· Comorbidity Construct and, 459, 459*f*
· co-ownership in, 459–461
· in cortical bone, 455, 455*f*
· defined, 451
· delirium and, 463–464
· dementia and, 458, 463–464
· diabetes and, 458
· dietitian in, 461
· electrolyte management and, 462
· epidemiology of, 451–454, 454*f*
· etiology of, 454–457, 455*f*–457*f*
· facilities considerations with, 459
· falls and, 456, 465
· fast-tracking of patients with, 461
· femoral fracture in, atypical, 469
· fixation of, 470, 471–475, 472*f*–474*f*
· fluid management and, 462
· frailty and, 458
· functional disabilities and, 458
· geriatrician in, 460
· goal setting in patients with, 459
· guidelines, 461
· immobilization and, 458–459
· immobilization in, 462
· lifelong assistance in, 461–462
· malnutrition and, 465
· mechanisms of injury in, 456, 457*f*
· medical treatment in, 462–463
· mortality in, 475
· occupational therapist in, 461
· orthogeriatric management of, 459–462, 459*f*, 475
· orthopedic nurses in, 460
· orthopedic surgeon in, 460
· outcomes in, 475
· pain management and, 462
· patient, 457–459
· pharmacist in, 461
· physiotherapist in, 460–461
· plating in, 471, 472*f*
· postoperative management in, 463–466
· preexisting conditions and, 457–458
· protocols, 461
· psychiatrist in, 461
· pulmonary disease and, 458
· rehabilitation and, 465
· relative stability with, 471, 472*f*
· renal dysfunction and, 458
· sarcopenia and, 458
· secondary fracture prevention in, 465–466
· social worker in, 461
· soft-tissue concerns with, 467, 467*f*, 468*f*
· speech therapist in, 461
· splinting in, 473
· surgical treatment principles in, 467–475, 467*f*–470*f*, 472*f*–474*f*
· team approach with, 459–461
· thromboprophylaxis in, 464–465
· trauma surgeon in, 460
· weight bearing after surgery for, 471
Frailty, 458
Frame construction, in external fixation, 263–265, 263*f*–265*f*
Friction, 20, 20*f*

G

Gabapentin, 440
Galeazzi fracture, 657, 659, 659*f*
Gatifloxacin, 542
Gentamicin, 423, 424*t*, 427*t*
Glasses, leaded, 486
Gluteus maximus muscle flap, 375*f*
Glycopeptides, 424
Gracilis muscle flap, 374*f*
Grafts
· allografts
·· in fragility fracture, 475, 477*f*
·· in knee dislocation, 870, 871, 872–873, 873*f*
·· in nonunion, 522–523
·· in periprosthetic fractures, 846
· bone
·· in chronic infection, 553, 553*f*, 556
·· in fragility fracture, 475, 476*f*
·· in navicular fracture, 987*f*
·· in nonunion, 519, 521*f*, 522
· skin, in soft-tissue reconstruction, 368–370, 369*f*
Growth and development, with pediatric fracture, 379–381, 381*t*
Growth factors
· in fracture healing, 13
· in materials, 35
· in soft-tissue healing, 52
Gunshot injuries, 53, 352, 352*f*
Gustilo-Anderson classification of open fracture, 335*t*
Gustilo classification of open fracture, 58, 59*t*, 335*t*

H

HA. *See* Hydroxyapatite (HA)
Hand fracture
· anatomy in, 699–701, 700*f*, 701*f*
· Bennett fracture in, 704–705, 705*f*
· carpometacarpal joint anatomy in, 699, 700*f*
· finger carpometacarpal joint fracture in, 706
· fixation of, 699, 704
· goals of treatment in, 699
· implant selection in, 701–702, 701*t*, 702*f*
· interphalangeal joint anatomy in, 700, 700*f*, 701*f*
· lag screw in, 704
· metacarpal anatomy in, 699
· metacarpal fracture in, 707–708, 708*f*
· metacarpophalangeal joint anatomy in, 700, 700*f*
· operating room set-up in, 702, 703*f*
· outcome in, 714
· phalangeal anatomy in, 700, 700*f*
· phalangeal fracture in, 709–712, 709*f*–713*f*
· plates in, 704
· postoperative care in, 714, 714*f*
· preoperative planning in, 701–702, 701*f*, 701*t*, 702*f*
· prognosis in, 714
· reduction of, 703
· Rolando fracture in, 706, 706*f*
· specific fractures in, 704–712, 705*f*–712*f*
· surgery, 703–704, 703*f*, 704*f*
· thumb carpometacarpal joint fracture in, 704–706, 704*f*–707*f*
Hawkins classification, 975*t*
Hazards, radiation exposure, 481–482, 482*t*
Healing
· bone
·· angiogenesis in, 12
·· biology of, 12–14, 14*f*
·· biomechanics and, 15–24, 15*f*–24*f*, 17–19, 17*f*–19*f*
·· bone morphogenic proteins in, 13
·· callus perfusion and, 12
·· in cancellous bone, 14
·· and characteristics of bone, 10
·· in cortical bone, 14
·· direct, 12, 22–24, 23*f*, 24*f*
·· in fixation with absolute stability, 19–20
·· in fragility fracture, 475
·· growth factors in, 13
·· hard callus formation in, 13, 14*f*
·· indirect, 12, 14, 14*f*, 17–19, 17*f*–19*f*
·· inflammation in, 13, 14*f*
·· mechanobiology of, 17–19, 17*f*–19*f*, 22–24, 23*f*, 24*f*
·· patient characteristics in, 9
·· primary, 12, 22–24, 23*f*, 24*f*
·· reaming and, 218
·· reduction and, 119
·· remodeling in, 13, 14*f*
·· secondary, 13, 14*f*, 17–19, 17*f*–19*f*
·· soft callus formation in, 13, 14*f*
·· types of, 12
·· without treatment, 15, 15*f*
· soft tissue
·· inflammatory phase in, 52
·· pathophysiological responses in, 52
·· phases of, 51
·· proliferative phase in, 52
·· reparative phase in, 52
Healthcare environment, decision making and, 80
Hemostasis, importance of, 142. *See also* Blood supply
Henry approach, 664, 664*f*, 665*f*
Heparin, 432
Hinged external fixator, 262
Hip dislocation
· in acetabulum fracture, 749
· anterior surgical, 760–761, 760*f*
Hip fracture. *See also* Acetabulum fracture; Femoral fracture; Pelvic fracture; Pelvic ring fracture
· epidemiology of, 451–454, 454*f*
· periprosthetic, 837–838, 838*t*
· thromboembolic prophylaxis in, 433, 433*t*
Hip protectors, 466
Hoffmann, Raoul, 3
Hohmann retractor, 128–129, 128*f*, 129*f*, 142
Holstein-Lewis fracture, 609
Hotchkiss over-the-top approach, 644, 644*f*
Humeral fracture
· distal
·· anatomy in, 624, 624*f*
·· articular, 628–629
·· Bryan-Morrey approach, 630, 630*f*
·· case history in, 623
·· challenges with, 634
·· chevron osteotomy in, 629, 629*f*
·· classification of, 624, 624*f*
·· compartment syndrome in, 623
·· complications with, 635
·· diagnosis of, 623
·· epidemiology of, 623
·· evaluation of, 623
·· fixation in, 632–634, 633*f*, 634*f*
·· imaging in, 623
·· implant selection in, 625
·· limited-contact dynamic compression plate in, 625
·· locking compression plate in, 196*f*, 197*f*, 291*f*, 293*f*, 625, 633–634, 633*f*
·· operating room set-up in, 626, 626*f*
·· in osteoporosis, 623
·· outcomes in, 635
·· physical examination in, 623
·· postoperative care in, 634–635
·· preoperative planning in, 625–626, 625*f*, 626*f*
·· prognosis in, 635
·· reduction of, 631–632, 631*f*, 632*f*
·· surgery, 626–634, 626*f*–634*f*
·· surgical approaches for, 626–630, 626*f*–630*f*
·· surgical indications for, 624
·· ulnar nerve in, 627
· epidemiology of, in osteoporosis, 454
· external fixation of, 259*f*
· intramedullary nails in, 222
· locking compression plate in, 307*f*
· malunion in, 501–504, 501*f*–503*f*, 605
· in osteoporosis, 469*f*, 470*f*, 476*f*, 477*f*
· pediatric, 381*t*, 394–398, 395*f*–398*f*
· PHILOS in, 157*f*, 158*f*, 307*f*, 476*f*, 602, 611
· postoperative care for, 438*t*
· proximal
·· acceptable malalignment in, 381*t*
·· anatomy in, 590–591, 591*f*
·· avascular necrosis in, 605
·· blood supply in, 591, 591*f*
·· case history in, 587
·· challenges with, 603
·· classification of, 43, 43*t*, 592, 592*f*
·· complications in, 604–605
·· deltopectoral approach in, 594, 595*f*
·· diagnosis of, 587–590, 588*f*–590*f*
·· epidemiology of, 587
·· evaluation of, 587–590, 588*f*–590*f*
·· fixation of, 597–604, 597*f*–602*f*
·· imaging in, 588–590, 588*f*–590*f*
·· implant selection in, 593
·· indirect reduction of, 598, 599*f*
·· intramedullary nailing in, 601, 601*f*, 603
·· joystick reduction in, 597–598, 598*f*
·· lag screws in, 600, 600*f*
·· LEGO classification of, 592
·· locking compression plate in, 302*f*, 601, 602*f*
·· locking head screws in, 286*f*
·· malunion in, 605
·· minimally invasive plate osteosynthesis in, 150, 156, 156*f*–157*f*, 602
·· Neer classification of, 592
·· nonunion in, 605
·· operating room set-up in, 593, 593*f*
·· outcomes in, 605
·· physical examination in, 587
·· postoperative care with, 604, 604*t*
·· preoperative planning in, 593, 593*f*
·· prognosis in, 605
·· reduction of, 597–604, 597*f*–602*f*
·· screw penetration in, 604
·· special characteristics of, 587
·· surgical approach in, 594–596, 595*f*, 596*f*
·· surgical indications for, 592
·· timing of surgery in, 593
·· traction sutures in, 597, 597*f*
·· transdeltoid approach in, 596, 596*f*
· shaft
·· acceptable malalignment in, 381*t*
·· anatomy in, 607–608, 608*f*
·· anterior approach to, 611, 611*f*, 612–615, 613*f*
·· anterior extensile approach to, 608*f*
·· bracing in, 609, 609*f*
·· classification of, 609, 609*f*
·· complications with, 620
·· diagnosis of, 607

·· dynamic compression plate in, 610
·· epidemiology of, 607
·· evaluation of, 607
·· external fixation in, 619, 619*f*
·· imaging of, 607
·· implant selection in, 610–611, 610*f*
·· intramedullary nailing in, 609, 617–618, 617*f*, 618*f*, 619
·· limited-contact dynamic compression plate in, 610*f*
·· locking compression plate in, 610
·· medial approach to, 617
·· minimally invasive plate osteosynthesis in, 151, 158–160, 158*f*, 159*f*, 615–617, 616*f*, 617*f*
·· operating room set-up in, 611–612, 611*f*, 612*f*
·· outcomes in, 620–621
·· PHILOS in, 611
·· posterior approach to, 612, 612*f*, 614*f*, 615, 615*f*
·· postoperative care in, 620
·· preoperative planning with, 610–612, 610*f*–612*f*
·· prognosis in, 620–621
·· reduction of, 619
·· surgery, 612–620, 613*f*–619*f*
·· surgical approach to, 608*f*, 612–618, 613*f*–618*f*
·· surgical indications for, 609, 609*f*
·· timing of surgery with, 610
· timing of surgery with, 140
Hybrid external fixator, 261, 261*f*
Hydrocodone, 441, 441*t*
Hydromorphone, 441, 441*t*
Hydroxyapatite (HA) coating, 33
Hyperhomocysteinemia, 431*t*
Hypotension, in pelvic fracture, 723
Hypothermia, in polytrauma, 74

I

Ibuprofen, 440*t*
Iliac wing fracture, reduction of, with Hohmann retractor, 128–129, 129*f*
Iliofemoral approach, extended, 761, 762*f*
Ilioinguinal approach, 752, 752*f*, 755, 756*f*–757*f*
Iliolumbar ligament, 719*f*
Ilizarov technique, 555, 555*f*
Imaging
· in acetabulum fracture, 748*f*, 748*f*–750*f*, 749–750
· in articular fracture evaluation, 98, 99*f*
· in calcaneus fracture, 962–963, 963*f*
· in clavicular fracture, 574, 574*f*
· in diaphyseal fracture evaluation, 84–86
· displacement in, 117
· documentation of, 488–489
· in femoral fracture
·· proximal, 774
·· shaft, 790
· in forearm fracture, 637, 637*f*, 657
· in fracture classification, 46
· future of, 489
· hardcopies in, 489
· in humeral fracture
·· distal, 623
·· proximal, 588–590
·· shaft, 607
· in humeral fracture, proximal, 588*f*–590*f*
· in infection diagnosis, 536
· in malleolar fracture, 934–935, 934*f*, 935*f*
· memory modes in, 488
· in minimally invasive plate osteosynthesis, 154
· mobile imaging intensifier in, 483–485, 483*f*–485*f*
· in patellar fracture, 854
· in pediatric fracture, 382–383
· in pelvic ring fracture, 717, 718*f*, 723
· in periprosthetic fracture, 839–840, 840*f*
· in pilon fracture, 914
· in postoperative management, 444, 447–448
· in preoperative planning, 106, 107
· in radial fracture, distal, 673–676, 674*f*–676*f*
· radiation exposure hazards in, 481–482, 482*t*
· role of, 481, 481*t*
· in scapular fracture, 565
· in tarsometatarsal joint injury, 991, 992*f*
· in tibial fracture
·· proximal, 878, 878*f*
·· shaft, 900
Implants. *See also* Periprosthetic fracture; Plate(s)
· absolute stability and, 20–22, 21*f*, 22*f*
· in acetabulum fracture, 751
· allergic reactions and, 32
· biomechanics of, 16, 20–22, 21*f*, 22*f*
· in bridge plating, 245–247, 245*f*–247*f*
· in clavicular fracture, 576–577, 576*f*
· coatings on, 33
· early removal of, 448
· in femoral fracture
·· distal, 818–819, 819*f*
·· proximal, 776–779, 777*f*–779*f*
·· shaft, 793–795, 794*f*, 795*f*
· in forearm fracture, 661
· in hand fracture, 701–702, 701*t*, 702*f*
· in humeral fracture
·· distal, 625
·· proximal, 593
·· shaft, 610–611, 610*f*
· infection associated with, 530–532, 531*f*
· infection susceptibility with, 31–32
· in malleolar fracture, 946
· in malunion, 498–499, 498*f*
· metals in, 27
· in minimally invasive plate osteosynthesis, 153
· MRI compatibility and, 33
· in patellar fracture, 857
· in pilon fracture, 919, 919*f*, 920*f*
· polymeric, 33–34
· in reduction, 132–134, 132*f*, 133*f*, 134*f*, 153
· relative stability of, 16
· removal of, 448, 538
· in tibial fracture
·· proximal, 882
·· shaft, 901
· tumor induction and, 32
Incision. *See also* Closure
· diaphyseal fracture and, 143
· reduction and, 143–144, 143*f*, 144*f*
· soft-tissue handling and, 142, 142*f*
Indomethacin, 440*t*
Induction of tumors, implant materials and, 32
Infection. *See also* Antibiotics; Osteomyelitis
· acute
·· antibiotic therapy in, 541–542
·· classification of, 529, 530*t*
·· closed treatment of, 541
·· debridement in, 537–538
·· delayed, 530, 530*t*
·· diagnosis of, 536–537
·· in disturbed wound healing, 530
·· early, 530, 530*t*
·· histopathology in, 536–537
·· imaging in, 536
·· implant-associated, 530–532, 531*f*
·· implant removal in, 538
·· implant retention in, 538
·· irrigation in, 538
·· late, 530, 530*t*
·· microbiology in, 536–537
·· negative-pressure wound therapy in, 541
·· onset of, 529–533, 530*t*, 531*f*, 532*f*
·· open treatment of, 541
·· treatment of, 537–542, 537*f*–542*f*
·· in wound edge necrosis, 530
·· in wound hematoma, 530
· after external fixation, 266–267
· chronic
·· antibiotic therapy in, 556
·· in avital nonunion, 557–558
·· bacteriology in, 549
·· bone grafts in treatment of, 553, 553*f*, 556
·· bone reconstruction in, 552*f*–555*f*, 553–556
·· callous distraction in treatment of, 555, 555*f*
·· debridement in, 551, 551*f*
·· diagnosis of, 549–551, 549*f*, 550*f*
·· external fixation in treatment of, 552–553, 552*f*
·· histology in, 549
·· in hypertrophic nonunion, 557, 557*f*
·· Ilizarov technique in treatment of, 555, 555*f*
·· imaging in, 549, 549*f*, 550*f*
·· in intramedullary nailing, 560
·· intramedullary nailing in treatment of, 553
·· Masquelet technique in treatment of, 553–554, 554*f*
·· in plating, 559
·· plating in treatment of, 553
·· soft-tissue coverage in treatment of, 556
·· stabilization in, 551–553, 552*f*
·· treatment of, 551–560, 552*f*–555*f*, 557*f*, 560*f*
· diabetes and, 76
· external fixation and, 265
· fracture types and, 422

· implant materials and, 31–32
· material coatings and, 33
· microbiology of bone-implant, 422
· in minimally invasive osteosynthesis, 170
· in Morel-Lavallée lesion, 140–141
· in open fracture, 334, 338
· prevention of, 544, 544*t*
· risk factors for, 421*t*
· surgical procedure types and, 422
· timing of surgery and, 78
Inferior tibiofibular complex, 936, 936*f*
Inferior venal caval filter (IVCF), 432
Inflammation
· in fracture healing, 13, 14*f*
· in polytrauma, 312–313
· in soft tissue healing, 52
Interfragmentary compression
· lag screws in, 179–180, 180*f*, 181*f*
· plates and, 198
Interlocking screw
· intramedullary nails and, 17, 237–238, 237*f*
· mechanism of, 179*t*
Interobserver reliability, in fracture classification, 48
Interphalangeal joints, anatomy of, 700, 700*f*, 701*f*
Intraarticular malunion, 494, 494*f*
Intramedullary nails. *See also* Reaming
· abductor muscle weakness with, 226
· alignment control with, 233–236, 233*f*–236*f*
· angular stable locking system with, 218
· in antegrade femoral nailing, 226–227, 226*f*
· in antegrade tibial nailing, 227, 227*f*
· autodynamization of, 238
· axial alignment of, 234, 234*f*
· biomechanics of, 17
· cable technique with, 234, 234*f*
· cannulated, 218
· chronic infection with, 560
· in clavicle, 223, 579
· contraindications for, 238
· current aspects of, 220–221
· in delayed cases, 237
· diameter selection, 224, 224*f*
· in diaphyseal fracture, 90
· dynamization of, 238
· entry point preparation with, 225, 225*f*, 226–227, 226*f*
· in femoral fracture, 221–222
·· distal, 830–831, 830*f*, 831*f*, 834
·· neck, 808, 808*f*
·· pediatric, 407, 408, 408*f*–410*f*
·· proximal, 779, 779*f*
·· shaft, 791, 792*f*, 793, 799–800, 799*f*, 800*f*
· fixation techniques with, 237–238, 237*f*
· in floating knee injury, 227
· in forearm, 222
· in humeral fracture, 222, 601, 601*f*, 603, 609, 617–618, 617*f*, 618*f*, 619
· implant selection with, 223–224, 244*f*
· insertion techniques, 225–228, 225*f*–227*f*
· interlocking screws with, 17, 237–238, 237*f*
· Küntscher, 217, 217*f*
· in lateral malleolus, 223
· length in alignment of, 233, 233*f*
· length selection with, 223–224, 244*f*
· local response to, 218–219
· locking sequence with, 231–232, 232*f*
· malalignment with, 231*f*, 237
· in malunion, 499
· in metaphyseal fracture, 230, 230*f*
· in nonunion, 524, 524*f*
· nonunion and, 237
· in olecranon fracture, 648
· in open fracture, 343–344, 343*f*, 344*f*
· osteomyelitis and, 534, 535*f*, 538, 538*f*, 539*f*–540*f*, 543
· pathophysiology of, 218–221
· patient positioning with, 223
· in pediatric fracture, 392, 393*f*, 394, 395*f*
· in periprosthetic fracture, 846, 847*f*
· Poller screws with, 229–230, 230*f*
· in polytrauma, 220–221
· preoperative planning with, 223–224, 244*f*
· pulmonary embolism and, 219
· reaming, irrigation, and aspiration system with, 219
· in reduction, 132
· reduction techniques with, 228–237, 228*f*–236*f*
· relative stability of, 17
· in retrograde femoral nailing, 227
· rotation of, 234–236, 235*f*, 236*f*
· surgical approach with, 225, 225*f*
· systemic response to, 219
· tibial, 221, 222, 227, 227*f*
· in tibial fracture, 343*f*
·· proximal, 889–890, 889*f*
·· shaft, 902–904, 903*f*, 904*f*, 905–906, 906*f*, 907–909
· in treatment of chronic infection, 553
· types of, 217–218, 217*f*
· universal, 217
· unreamed solid, 218
· without locking, 218
· without reaming, 218, 219
· without reaming but with locking, 218
IVCF. *See* Inferior venal caval filter (IVCF)

J

Joint disease, decision making and, 77
Joint fracture. *See* Articular fracture
Joint replacement, fragility fracture and, 475
Joystick reduction, 130, 130*f*, 597–598, 598*f*
Jungbluth forceps, 123*t*, 127, 127*f*

K

Kallikrein, 52
Kapandji reduction, 130
Ketamine, 440
Ketorolac, 440*t*
Kidney disease, decision making and, 76–77
King tong clamp, 126, 126*f*
Knee dislocation
· anatomy in, 866–868, 866*f*–868*f*
· anterior cruciate ligament in, 865, 866, 870, 872
· central pivot in, 866
· collateral ligaments in, 872, 872*f*, 873*f*
· complications in, 874
· cruciate ligaments in, 872–873
· decision making in, 870
· epidemiology of, 865–866, 865*f*
· evaluation in, 868–870, 869*f*
· examination under anesthesia in, 871
· extensor mechanism in, 868
· meniscal preservation in, 871, 871*f*
· neurovascular assessment in, 868–869
· open, 869, 869*f*
· outcomes in, 874
· peroneal nerve palsy in, 869
· popliteal fossa, 868, 868*f*
· popliteal fossa in, 868, 868*f*
· posterior capsule repair in, 871
· posterior cruciate ligament in, 865, 866, 870, 871, 872–873
· posterolateral corner in, 866*f*, 867, 867*f*, 872, 872*f*
· posteromedial corner in, 866, 866*f*, 872, 873*f*
· postoperative care in, 873, 873*f*
· preoperative planning in, 870–871
· primary treatment in, 868–870, 869*f*
· surgical indications in, 870
· timing of surgery in, 870
· treatment of, 870–871
Knee fracture, periprosthetic, 838. *See also* Femoral fracture, distal; Patellar fracture
Kocher approach, 643–644, 644*f*
Kocher-Langenbeck approach, 752, 752*f*, 753–755
König, Fritz, 3
Küntscher, Gerhard, 3, 4, 4*f*, 149
Küntscher nail, 217, 217*f*
K-wire, 101, 109
· backout, 215
· in clavicle fracture, 580, 582*f*
· in condylar fracture, 398, 399*f*
· in external fixation, 261, 262, 397*f*, 534
· in femoral fracture, 404, 413, 413*f*, 505*f*
· in humeral fracture, 593, 598, 598*f*, 599*f*, 625
· in intramedullary nailing, 227
· in joystick reduction, 130, 130*f*
· in Kapandji reduction, 130
· with locking compression plates, 303*f*
· in malleolar fracture, 950*f*, 951
· in minimally invasive plate osteosynthesis, 157*f*, 161*f*, 168*f*
· in olecranon fracture, 645–648, 647*f*
· in patellar fracture, 858
· in pediatric fracture, 392
· in PHILOS, 302*f*
· in radial fracture, 402, 403*f*
· in scapular fracture, 569*f*
· screws with, 283*f*
· in single-plane osteotomy, 499, 500*f*
· in supracondylar fracture, 396, 396*f*

· in tarsometatarsal joint injury, 994, 995*f*
· in tension banding, 213*f*
· in tibial fracture, 101*f*, 417
· in valgisation osteotomy, 505*f*, 507*f*

L

Lag screws
· absolute stability and, 20–21, 21*f*, 173, 198–199, 198*f*, 199*f*
· biomechanics of, 20–21, 21*f*
· in buttress plates, 203, 203*f*
· clinical applications of, 183–184, 183*f*, 184*f*
· compression with, 20, 20*f*
· in diaphyseal fracture, 90
· in epiphyseal region, 184, 184*f*
· in femoral fracture, 7*f*
· in femoral neck fracture, 806, 806*f*
· fully threaded screws as, 179–180, 180*f*
· in hand fracture, 704
· in humeral fracture, 600, 600*f*
· in interfragmentary compression, 179–180, 180*f*, 181*f*
· locking head screws as, 282*t*
· in malleolar fracture, 950*f*
· mechanism of, 179*t*
· in metaphyseal region, 184, 184*f*
· in navicular fracture, 986, 986*f*
· one vs. two, 177*f*
· partially threaded screws as, 180, 181*f*
· in patellar fracture, 861*f*
· in pediatric tibial fracture, 415*f*, 416*f*
· in pelvic ring fracture, 737*f*
· positioning of, 183, 183*f*
· in talus fracture, 977, 977*f*
Lambotte, Alain, 3, 3*f*, 4, 149
Lambotte, Elie, 3
Lane, William Arbuthnot, 3
Lateral ascending branch of anterior humeral circumflex artery, 591*f*
Lateral collateral ligament complex, 639*f*, 640
Lateral distal femoral angle (LDFA), 815, 816*f*
Lateral fasciocutaneous supramalleolar flap, 374*f*
Lateral gastrocnemius flap, 375*f*
Lateral malleolus, intramedullary nails in, 223
Lateral ulnar collateral ligament (LUCL), 640
LCP. *See* Locking compression plate (LCP)
LDFA. *See* Lateral distal femoral angle (LDFA)
Leaded glasses, 486
LEGO classification, 592
Length discrepancies, in malunion, 493, 493*f*
Lengthening frame, 263
Less invasive stabilization system (LISS)
· bridge plating and, 249*f*
· development of, 270
· in femoral fracture, distal, 829–830, 829*f*
· locking compression plate vs., 192
· in minimally invasive plate osteosynthesis, 163*f*, 249*f*
· screws in, 175*f*
· in tibial fracture, 249*f*
"Lethal triad," 314, 314*f*
Letournel classification, 747*f*, 748*f*
Levofloxacin, 542
LHS. *See* Locking head screws (LHS)
Life expectancy, 451
Ligamentotaxis, in articular fracture, 101
Limb salvage, amputation vs., 326, 361–364, 361*f*–363*f*
Limited-contact dynamic compression plate (LC-DCP). *See also* Dynamic compression plate (DCP)
· application technique, 188–190, 189*f*, 190*f*
· articulated tension device with, 188
· blood supply and, 11, 11*f*, 185
· as buttress plate, 189, 189*f*
· compression with, 202
· contouring of, 153, 153*f*
· design of, 186–188, 186*f*–189*f*
· drill guides in, 189, 189*f*
· footprint of, 186
· in forearm fracture, 187
· functions, 186
· functions of, 186
· in humeral fracture, 610*f*, 625
· in minimally invasive plate osteosynthesis, 153, 153*f*
· in pelvic ring fracture, 735*f*, 740
· screw holes in, 187–188, 187*f*
· sizes of, 187
Linezolid, 424
Lisfranc area, 990
Lisfranc malunion, 510
LISS. *See* Less invasive stabilization system (LISS)
Liver disease, decision making and, 77
LMWH. *See* Low-molecular weight heparin (LMWH)
Load transmission, in diaphyseal fracture, 91
Locking compression plate (LCP)
· absolute stability with, 289–294, 290*f*–294*f*, 305
· application technique, 194–195
· in articular fracture, 291, 291*f*–293*f*, 305
· biomechanics of, 17, 21–22, 192–194, 193*f*, 194*f*, 288–289, 288*t*
· blood supply and, 11, 11*f*
· in bridge plating, 247, 247*f*
· as bridging plate, 247, 247*f*, 301, 302*f*–304*f*
· characteristics of, 287
· in clavicle fracture, 576
· combination holes in, 192, 193*f*
· contouring of, 153
· design of, 192–194, 193*f*, 194*f*
· in diaphyseal fracture, 90
· evolution of, 5
· failure modes of, 305
· in femoral fracture, 196*f*, 829–830, 829*f*
· in forearm fracture, 289
· history of, 270, 270*f*, 271
· in humeral fracture, 196*f*, 197*f*, 291*f*, 293*f*, 302*f*, 307*f*, 601, 602*f*, 610, 625, 633–634, 633*f*
· hybrid, 287, 294*f*, 295*f*
· hybrid application of, 287, 294*f*, 295*f*
· indications for, 272–279, 272*t*, 273*f*–279*f*
· infection susceptibility with, 31
· length of, 297–300, 298*f*–301*f*
· in malunion, 498
· metaphyseal, 196*f*
· in metaphyseal fracture, 272*t*, 288*t*, 289, 290*f*
· in minimally invasive plate osteosynthesis, 153, 272*t*, 278, 279*f*, 294, 294*f*, 302*f*
·· in clavicle, 155
· in multifragmentary fracture, 288*t*
· olecranon, 196*f*
· in osteoporosis, 272, 272*t*, 273*f*–276*f*, 288*t*, 289, 290*f*
· in pediatric femoral fracture, 404, 405*f*–406*f*
· in periarticular fracture, 278, 278*f*, 291, 291*f*–293*f*
· in periprosthetic fracture, 272*t*, 277, 277*f*, 846, 847*f*
· in pilon fracture, 926*f*
· polyaxial screws in, 194, 194*f*
· in poor bone stock, 272–277, 272*t*, 273*f*–277*f*
· preoperative planning with, 195
· in radial fracture, 197*f*
· relative stability of, 17, 294–305, 295*f*–307*f*
· in revision surgery, 277
· screws in, 192, 193*f*
· in small bones, 277, 277*f*
· in soft bones, 277, 277*f*
· in tibial fracture, 196*f*, 292*f*, 295*f*, 296*f*, 303*f*, 304*f*, 306*f*, 908
· variable angle, 271, 271*f*, 846
Locking head screws (LHS)
· application principles, 280–286, 280*f*, 281*f*, 282*t*, 283*f*–287*f*
· bicortical, 284, 284*f*
· characteristics of, 280, 280*f*, 281*f*
· in fragility fracture, 473
· functions of, 282, 282*t*, 283*f*
· in history of locking plates, 269*f*, 270
· in humeral fracture, 286*f*, 625
· as lag screws, 282*t*
· in locking compression plates, 193*f*, 195
· mechanism of, 175*f*, 179*t*
· in minimally invasive plate osteosynthesis, 167*f*
· monocortical, 286, 287*f*
· number of, 286
· in osteoporosis, 284, 284*f*
· in periprosthetic fracture, 846
· as position screws, 282, 282*t*
· as reduction screws, 282*t*
· stability with, 173
· subcortical, 285, 285*f*
· threads in, 177
· in tibial fracture, 283*f*
· torque-limiting attachments with, 282
· types of, 282, 282*t*, 283*f*
Low-molecular weight heparin (LMWH), 432
Lucas-Championnière, 4
LUCL. *See* Lateral ulnar collateral ligament (LUCL)

M

Macrophages, 52
Magnesium, 440
Magnetic resonance imaging (MRI)
· compatibility, implant materials and, 33
· in infection diagnosis, 536
· in periprosthetic fracture, 840
· in tibial fracture, proximal, 878
Malleolar fracture. *See also* Fibular fracture
· anatomy in, 936–938, 936*f*, 937*f*
· buttress plate in, 951, 952*f*
· case history in, 933
· challenges with, 956
· classification of, 938–945, 938*f*–945*f*
· collateral ligament complexes in, 937
· complex regional pain syndrome in, 446*f*
· complications in, 957–959, 958*f*
· in diabetes, 956, 959
· diagnosis of, 933
· epidemiology of, 933
· evaluation of, 933
· fibular fracture in, 938*f*, 940*f*, 941, 942*f*, 945, 950, 950*f*, 951, 952*f*, 954, 954*f*, 955*f*
· fibular reconstruction in, 949
· fibular shortening after, 511*f*
· fibulotibial syndesmotic position screw in, 955–956, 955*f*
· fixation of, 949–956, 950*f*, 952*f*–955*f*
· imaging in, 934–935, 934*f*, 935*f*
· implant selection in, 946
· infection in, 543*f*
· inferior tibiofibular complex in, 936, 936*f*
· infrasyndesmotic, 938*f*, 943, 945, 950–951, 950*f*
· K-wire in, 950*f*, 951
· lag screws in, 950*f*
· lateral approach in, 948, 948*f*
· malunion in, 510, 511*f*
· mechanisms of, 939*f*, 940*f*, 941*f*, 942*f*, 943–945, 943*f*–945*f*
· medial approach in, 948, 948*f*
· medial exploration in, 951–952, 952*f*
· mortise congruity in, 937–938
· mortise displacement in, 934, 935
· open fracture, 957
· operating room set-up in, 946–947, 947*f*
· in osteoporosis, 956, 957
· outcomes in, 959
· pediatric, 386
· peripheral neuropathy and, 956
· physical examination in, 933
· pilon fracture vs, 943
· posterior, 952*f*, 953, 953*f*
· posterolateral, 952*f*, 953, 953*f*
· posterolateral approach in, 948, 949*f*
· posteromedial approach in, 949, 949*f*
· postoperative care for, 439*t*, 956–957
· preoperative planning in, 946–947, 946*f*, 947*f*
· protection plate in, 951, 952*f*
· reduction of, 102, 949–956, 950*f*, 952*f*–955*f*
· soft tissue loss in, 377*f*
· soft tissue problems with, 946*f*, 957
· special characteristics of, 933
· suprasyndesmotic, 938*f*, 942*f*, 945, 954–955, 954*f*
· surgical approaches in, 948–949, 948*f*, 949*f*
· surgical indications for, 945
· talocrural angle in, 934, 935*f*
· tibia-fibula joint in, 957, 958*f*
· timing of surgery in, 946, 946*f*
· transsyndesmotic, 938*f*, 940*f*, 944, 944*f*, 945, 945*f*, 951–953, 952*f*
Malleolar segment, fracture classification of proximal, 43, 43*t*
Malnutrition, 465
Malunion
· angled blade plate in, 132*f*, 133
· angular stable locking system and, 218
· in ankle, 510, 511*f*
· autodynamization and, 238
· bridge plating and, 241, 301
· in calcaneus, 510, 972
· classification, 493–496, 493*f*–496*f*
· in clavicle, 501, 585
· combined, 510
· decision making in, 497, 497*f*
· defined, 493
· diaphyseal, 496, 496*f*
· diaphyseal osteotomy in, 499
· external fixation in, 499
· in femur, 504–506, 506*f*, 507*f*, 813
· fixation in, 498–499, 498*f*, 500*f*
· in forearm, 504, 504*f*
· in humerus, 501–504, 501*f*–503*f*, 605
· implant choice in, 498–499, 498*f*
· infected, external fixation and, 265
· intraarticular, 494, 494*f*
· intramedullary nailing and, 219, 220
· intramedullary nailing in, 499
· length discrepancies with, 493, 493*f*
· locking compression plates in, 287, 498
· in malleolar fracture, 510, 511*f*
· metaphyseal, 495, 495*f*
· metaphyseal osteotomy in, 499
· in minimally invasive osteosynthesis, 170
· minimally invasive osteosynthesis and, 160, 170
· neuropathic, with diabetes, 76
· in radial fracture, 694
· reduction in, 237, 498–499, 498*f*, 500*f*
· single-plane osteotomy in, 499, 500*f*
· in talus fracture, 980
· tension bands and, 212, 212*f*
· terminology, 493–496, 493*f*–496*f*
· in tibia, 506–510, 508*f*, 509*f*
Mangled extremity severity score (MESS), 361
Mangled foot, 998, 999*f*
Mason Classification of Radial Head Fractures, 640, 641*f*
Masquelet technique, 250, 348, 553–554, 554*f*, 928, 929*f*
Materials, 27
· allergic reactions and, 32
· biocompatibility properties of, 29–32, 30*f*, 32*f*
· coatings on, 33
· corrosion resistance of, 29–30, 29*f*
· ductility of, 28
· infection susceptibility and, 31–32
· mechanical properties of, 27–29, 28*t*
· MRI compatibility and, 33
· stiffness of, 27–28
· strength of, 28, 28*t*
· surface properties of, 30–31, 30*f*, 32*f*
· torsional properties of, 29
· tumor induction and, 32
Matta forceps, 123*t*, 126
Mechanical effects, of fracture, 10. *See also* Biomechanics
Mechanobiology. *See also* Biomechanics
· of direct healing, 22–24, 23*f*, 24*f*
· of indirect healing, 17–19, 17*f*–19*f*
Medial collateral ligament complex, 639, 639*f*
Medial epicondylar fracture, in pediatric patients, 398, 399*f*
Medial fasciocutaneous foot flap, 375*f*
Medial gastrocnemius muscle flap, 375*f*
Medial malleolus, minimally invasive plate osteosynthesis in, 151
Medial subvastus approach, 824, 824*f*
Medications, decision making and, 77
Meniscal preservation, in knee dislocation, 871, 871*f*
Mental health, decision making and, 77
Meperidine, 441, 441*t*
Meropenem, 427*t*
MESS. *See* Mangled extremity severity score (MESS)
Metacarpal bone anatomy, 699
Metacarpal fracture
· intraarticular, 708
· plating in, 701*t*
· shaft, 707
· simple, 708, 708*f*
· surgical approach for, 708, 708*f*
Metacarpophalangeal joint anatomy, 700, 700*f*
Metamizole, 462
Metaphyseal malunion, 495, 495*f*
Metaphysis, in fracture classification, 41
Metatarsal fracture. *See also* Tarsometatarsal joint injury
· intraarticular, 996, 997*f*
· multiple-ray, 996, 997*f*
· principles of management in, 994
· proximal fifth, 998
· single-ray, 996, 996*f*
· treatment of, 996–998, 996*f*, 997*f*
· unstable, 996, 997*f*
Methicillin-resistant *S. aureus* (MRSA), 423, 424, 425
Metronidazole, 424*t*
Minimally invasive osteosynthesis (MIO)
· colinear reduction forceps in, 123*t*
· complications of, 170

· defined, 149
· delayed union in, 170
· education in, 171
· implant failure in, 170, 171*f*
· implant removal in, 171
· infection in, deep, 170
· malunion in, 170
· nonunion in, 170
· skin break down with, 170
· soft tissue considerations in, 141
· stability in, 149
· wire passer set in, 131*f*
Minimally invasive plate osteosynthesis (MIPO). *See also* Minimally invasive osteosynthesis (MIO)
· absolute stability in, 153
· alternative plan in, 154
· angled blade plate in, 206*f*, 207*f*
· bridge plating in, 249*f*
· cerclage in, 152
· in clavicle, 155, 155*f*, 579, 579*f*
· danger zones in, 150–151
· in femoral shaft, 151, 162, 162*f*, 794, 794*f*
· in femur, distal, 162–164, 163*f*, 822, 822*f*
· in femur, proximal, 160, 160*f*–161*f*
· in humeral shaft, 151, 158–160, 158*f*, 159*f*, 615–617, 616*f*, 617*f*
· in humerus, proximal, 150, 156, 156*f*–157*f*, 602
· imaging in, 154
· implants in, 153
· indications for, 150
· limited-contact dynamic compression plates in, 153, 153*f*
· locking compression plates in, 153, 272*t*, 278, 279*f*, 294, 294*f*, 302*f*
· in medial malleolus, 151
· postoperative management in, 154
· preoperative planning in, 150–154, 151*f*–153*f*
· reduction in, 151–152, 151*f*, 152*f*
· relative stability in, 153
· soft-tissue handling in, 152
· in specific bone segments, 154–170, 155*f*–169*f*
· stability in, 149, 153
· in tibia, distal, 168–170, 168*f*–169*f*
· in tibia, proximal, 164, 165*f*
· in tibial shaft, 166, 166*f*–167*f*
· in tibial shaft, distal, 151
Miniplates, in reduction, 134
MIO. *See* Minimally invasive osteosynthesis (MIO)
MIPO. *See* Minimally invasive plate osteosynthesis (MIPO)
Mobile imaging intensifier, 483–485, 483*f*–485*f*, 486–488, 487*f*
Mobilization, early, 443, 443*f*
· of acetabulum fracture patients, 769–770
· of articular fracture patients, 98
· of diaphyseal fracture patients, 87
Modified Stoppa approach, 758–759, 758*f*–759*f*
Modular reduction technique, in external fixation, 264–265, 264*f*, 265*f*
Monolateral external fixation system, 261, 261*f*
Monteggia fracture
· defined, 657, 658
· pediatric, 401, 401*f*
· posterior, dislocation, 652–653, 652*f*–653*f*
Morel-Lavallée lesion, 54, 140–141, 141*f*
Morphine, 441, 441*t*, 462
Morphology, in fracture classification, 42–45, 42*t*, –45*t*
Mortise congruity, 937–938. *See also* Malleolar fracture
Moxifloxacin, 542
MRI. *See* Magnetic resonance imaging (MRI)
MRSA. *See* Methicillin-resistant *S. aureus* (MRSA)
Müller, Maurice E., 4, 5*f*
Multifragmentary fracture, biomechanics of, 19
Muscle assessment, in soft tissue injury, 53–54
Muscle viability, 359
Musculocutaneous vascular system, 137

N

Nails. *See* Intramedullary nails
Naproxen, 440*t*
Navicular fracture
· anatomy in, 983–984, 983*f*
· cortical avulsion, 984, 984*f*
· fracture patterns, 984–987, 984*f*–987*f*
· grafting in, 987
· lag screws in, 986, 986*f*
· tension banding in, 987*f*
· treatment, 984–987, 984*f*–987*f*
· tuberosity, 986, 986*f*
Necrosis, in bone healing, 13
Necrotic tissue, blood supply and, 11
Neer classification, 592
Negative pressure wound therapy (NPWT), 347, 347*f*, 541, 556, 922, 922*f*
Nerve blocks, 442
Nerve injury, ischemia, soft-tissue injury, skeletal injury, shock, and age of patient score (NISSSA), 361
Neuroaxial anesthesia, 466
Neurological status assessment, in soft tissue injury, 54–55
Neuromodulating drugs, 440
NISSSA. *See* Nerve injury, ischemia, soft-tissue injury, skeletal injury, shock, and age of patient score (NISSSA)
Nonoperative fracture treatment, 15–16, 15*f*, 16*f*
· in articular fracture, 100
· in cuboid fracture, 988
· in diaphyseal fracture, 87–89, 88*f*
· in periprosthetic fracture, 845
· in tibial fracture, 901
Nonsteroidal antiinflammatory drugs (NSAIDs), 77, 440, 440*t*, 462, 518
Nonunion
· adjuvant treatments in, 523
· allografts in, 522–523
· articular, 524–525
· articulated tension device in, 523, 523*f*
· atrophic
·· defined, 513
·· management of, 519–521
· avital infected, 557–558
· biological
·· defined, 513
·· management of, 519, 521*f*
· biological factors in, 515–517, 515*t*
· bone grafts in, 519, 521*f*, 522
· bridge plating and, 516*f*
· classification of, 514, 514*f*
· clinical presentation of, 513–514
· defects in, 526
· defined, 513
· definitions in, 513
· diabetes and, 518, 518*f*
· diagnosis of, 513–514
· diaphyseal, 525–526, 526*f*
· etiology of, 515–517, 515*t*, 516*f*
· external fixation and, 524
· in femoral fracture
·· distal, 834
·· shaft, 813
· in forearm fracture, 671
· in humeral fracture, 605
· hypertrophic
·· defined, 513
·· external fixation and, 22
·· in open fractures, 373*f*
· hypertrophic infected, 557, 557*f*
· intramedullary nailing in, 524, 524*f*
· management of, 518–521, 519*f*–522*f*
· mechanical
·· defined, 513
·· management of, 519, 519*f*, 520*f*
· mechanical factors in, 515, 515*t*, 516*f*
· metaphyseal, 525
· neuropathy and, 518, 518*f*
· nonsteroidal antiinflammatory drugs and, 77, 518
· in open fracture, 348, 349
· open soft-tissue injuries and, 58
· operative management of, 521–523, 522*f*
· in osteoporosis, 526
· patient factors in, 518, 518*f*
· plating in, 523, 523*f*
· renal disease and, 76
· stabilization in, 523–524, 523*f*, 524*f*
· in tibial fracture, shaft, 910
· vascularity and, 517, 517*f*
NPWT. *See* Negative pressure wound therapy (NPWT)
NSAIDs. *See* Nonsteroidal antiinflammatory drugs (NSAIDs)

O

Occupation, of patient, decision making and, 77
Olecranon fracture. *See also* Forearm fracture
· intramedullary nailing in, 648
· K-wires in, 645–648, 646*f*
· plating in, 647–648, 647*f*
· postoperative care in, 438*t*

· reduction of, 645–648, 646*f*, 647*f*
· surgical approaches in, 643
· tension band wire in, 645–648, 647*f*
Olecranon osteotomy, 293*f*, 625, 626, 627*f*, 628–629
Open fracture
· antibiotic prophylaxis in, 424, 427*t*
· antibiotic therapy with, 338–339, 347
· articular, 353
· in blast injury, 333
· bone loss in, 353, 354*f*
· care, 336–346, 336*t*, 338*f*–340*f*, 339*t*, 342*f*–346*f*
· classification of, 335–336, 335*f*, 335*t*
· comorbidities with, 334
· complications with, 348
· in crush injury, 332
· debridement in, 339–340, 340*f*
· epidemiology of, 334, 334*t*
· etiology in, 332–333, 332*f*, 333*f*
· external fixation in, 253, 344–345, 345*f*, 353
· in gunshot injuries, 352, 352*f*
· Gustilo-Anderson classification of, 335*t*
· Gustilo classification of, 58, 59*t*, 335*t*
· historical perspective on, 331
· infection in, 334
· initial assessment of, 336*t*, 337–338, 338*f*
· intramedullary nails in, 343–344, 343*f*, 344*f*
· irrigation in, 339–340, 340*f*
· locations of, 334, 334*t*
· malleolar, 957
· mechanism of injury, 332–333, 332*f*, 333*f*
· microbiology of, 334
· negative pressure wound therapy in, 347, 347*f*
· outcomes with, 348
· in pediatric patients, 392
· pelvic, 724–725, 725*f*–729*f*
· in penetrating injury, 332, 332*f*
· pitfalls with, 348
· plating in, 342, 342*f*
· primary surgery in, 339–346, 339*f*, 340*f*, 342*f*–346*f*
· reaming in, 344, 344*f*
· soft tissue injury in, 54
· soft tissue reconstruction in, 348, 348*f*
· specialist referrals with, 337
· special situations with, 349–353, 349*f*–352*f*, 354*f*
· stabilization of, 341–346, 342*f*–346*f*
· talus, 978*f*
· timing of surgery in, 79*t*, 339, 339*t*
· treatment goals in, 336
· vascular injuries in, 349–350, 349*f*–351*f*
· wound dressing in, 346–347, 347*f*
· "zone of injury" in, 339, 339*f*
Open reduction and internal fixation (ORIF)
· in acetabular fracture, 763–767, 763*f*–767*f*
· in condylar fracture, 398
· in diaphyseal fractures, 89
· in femoral fracture, 160
· in forearm fracture, 635
· in Galeazzi fracture, 659
· in hand fracture, 704, 706, 708
· in humeral fracture, 103*f*, 594, 615*f*, 633*f*, 635
· in intraarticular fractures, 100
· in open fractures, 342, 342*f*, 343*f*, 345*f*
· in patellar fracture, 213*f*
· in pelvic ring fracture, 734, 734*f*
· in periprosthetic fractures, 844–844*f*
· in pilon fracture, 918
· in polytrauma, 322*f*, 323*f*, 327*f*
· postoperative management and, 438*t*
· in radial fracture, 696
· in scapular fracture, 569, 570
· in tibial fracture, 168*f*
·· proximal, 882
· timing of, 140
Opioid analgesics, 440–441, 441*t*, 462
ORIF. *See* Open reduction and internal fixation (ORIF)
Osteoarthritis, posttraumatic
· in articular fracture, 95, 95*f*
· in calcaneal fracture, 972
· in patellar fracture, 864
· in pilon fracture, 930
· in talar fracture, 980
Osteomyelitis. *See also* Infection
· acute, 532, 532*f*
· chronic, 533
· classification of, 548
· with concomitant septic arthritis, 532–533, 532*f*
· cortical, 547, 547*f*
· diffuse, 532*f*
· external fixation and, 533*f*, 534, 544
· fixation techniques and, 533–534, 533*f*, 534*f*
· intramedullary nailing and, 534, 535*f*, 538, 538*f*, 539*f*–540*f*, 543
· localized, 532*f*
· medullary, 532*f*
· neglected, 533
· plating and, 534, 534*f*
· recurrence of, 560, 560*f*
· risk factors for, 533–534, 533*f*, 534*f*
· soft-tissue damage and, 533
· superficial, 532*f*
Osteoporosis
· acetabular fracture in, 769
· in cancellous bone, 455
· common fracture in, 451
· comorbidities with, 457–458
· in cortical bone, 455, 455*f*
· defined, 451
· epidemiology of, 451–454, 454*f*
· falls and, 456
· fixation and, 456
· fixation of articular fracture in, 98
· humeral fracture in, 623
· locking compression plates in, 272, 272*t*, 273*f*–276*f*, 288*t*, 289, 290*f*
· locking head screws in, 284, 284*f*
· malleolar fracture in, 956, 957
· measurement of, 456
· medication, 466
· multiple fracture in, 451, 452*f*–453*f*
· nonunion in, 526
· pilon fracture in, 928
· screws in, 273*f*, 274*f*, 276*f*
Osteoseptocutaneous fibula flap, 374*f*
Osteosynthesis. *See also* Minimally invasive osteosynthesis (MIO)
· history of, 149
· stiffness and, 27
· surface properties and, 30
Osteotomy
· in ankle malunion, 510, 511*f*
· blood flow and, 11
· bone transport and, 266
· in clavicular malunion, 501
· diaphyseal, 499
· in diaphyseal malunion, 496, 496*f*
· distraction osteogenesis and, 266
· external fixation in, 265
· in femoral malunion, 504–506, 506*f*, 507*f*
· in forearm malunion, 504, 504*f*
· in humeral malunion, 501–504, 501*f*–503*f*
· intraarticular, in malunion, 494, 494*f*
· intramedullary nailing with, in malunion, 499
· lag screws in, 21*f*
· for length discrepancy, 493, 493*f*
· in malunion, 493, 493*f*, 497*f*
· metaphyseal, 499
· in metaphyseal malunion, 495, 495*f*
· in minimally invasive plate osteosynthesis, 154
· olecranon, 293*f*, 625, 626, 627*f*, 628–629
· plating with, in malunion, 498, 498*f*
· in preoperative planning, 111, 111*f*
· screw biomechanics in, 176, 177*f*
· single-plane, in malunion, 499, 500*f*
· in tibial malunion, 506–510, 508*f*, 509*f*
Overbending, compression by, 201, 201*f*
Oxycodone, 441, 441*t*

P

Packing, pelvic, 730–731
Pain management. *See also* Complex regional pain syndrome (CRPS)
· acetaminophen in, 437
· analgesics in, 437–442, 441*t*, 442*t*
· codeine in, 441, 441*t*
· in complex regional pain syndrome, 445, 446–447, 446*f*
· COX-2 inhibitors in, 440
· fentanyl in, 441, 441*t*
· in fragility fracture patients, 462
· hydrocodone in, 441, 441*t*
· hydromorphone in, 441, 441*t*
· meperidine in, 441, 441*t*
· morphine in, 441, 441*t*
· nerve blocks in, 442

· neuromodulating drugs in, 440
· nonsteroidal antiinflammatory drugs in, 440, 440*t*
· opioid analgesics in, 441, 441*t*
· oxycodone in, 441, 441*t*
· in postoperative care, 437–442, 437*f*, 438*t*–439*t*, 440*t*, 441*t*
Palmar inclination, 674, 674*f*
Palmar plating, in radial fracture, 679–684, 680*f*–683*f*
PAMPs. *See* Pathogen-associated molecular patterns (PAMPs)
Paprika sign, 551, 551*f*
Paracetamol, 462
Parapatellar approach, 823, 823*f*
Patella alta, 854, 864, 854*f*
Patella baja, 864
Patellar fracture
· anatomy in, 854–855, 854*f*
· avulsion, 856*f*
· bipartite patella vs., 854–855
· case history in, 853
· challenges with, 862
· classification of, 855, 855*f*, 856*f*
· complete articular, 855*f*
· complications in, 863–864
· diagnosis of, 853
· epidemiology of, 853
· evaluation of, 853–854, 854*f*
· extraarticular, 855*f*
· fixation in, 858–860, 859*f*–861*f*
· history of, 853
· imaging in, 854
· implant selection in, 857
· infection in, 557*f*, 863
· lateral, 856*f*
· loss of motion in, 863
· loss of reduction in, 863
· medial, 856*f*
· multifragmentary, 856*f*, 860, 860*f*
· operating room set-up in, 857, 857*f*
· outcomes in, 864
· partial articular, 855*f*
· partial patellectomy in, 862, 863*f*
· patella alta in, 864
· patella baja in, 864
· patellectomy in, 862
· physical examination in, 853
· postoperative care in, 439*t*, 862
· posttraumatic arthritis in, 864
· preoperative planning with, 857, 857*f*
· prognosis in, 864
· reduction of, 858, 863
· simple, 856*f*
· sleeve fractures in, 862
· special characteristics of, 853
· surgical approaches in, 858, 858*f*
· surgical indications for, 855
· tension band concept in, 210–211, 211*f*, 213, 213*f*, 214*f*, 215
· wedge, 856*f*
· wound closure in, 862
· wound healing in, 863
Patellar tendon rupture, 862
Patellectomy, 862, 863*f*
Pathogen-associated molecular patterns (PAMPs), 313
Patient characteristics
· in bone healing, 9
· in decision making, 76–78
Pauwels, Frederic, 209
PC-Fix, 5, 270
PCL. *See* Posterior cruciate ligament (PCL)
PE. *See* Pulmonary embolism (PE)
Pediatric fracture
· in AO Pediatric Classification of Long-Bone Fractures, 386–387, 386*f*, 387*f*, 388*t*–390*t*
· case history in, 382
· classification of, 383–387, 384*t*–385*t*, 386*f*, 387*f*, 388*t*–390*t*
· clinical examination in, 382
· closed treatment of, 391
· condylar, 398, 399*f*
· diaphysis in, 380
· epidemiology of, 379
· epiphyseal growth in, 380
· femoral, 381*t*, 404–413, 404*f*–414*f*
· forearm, 381*t*, 399–402, 399*f*–403*f*
· growth and development considerations in, 379–381, 381*t*
· and growth disturbances, 380
· humeral, 381*t*, 394–398, 395*f*–398*f*
· imaging of, 382–383
· intramedullary nails in, 392, 393*f*, 395*f*
· medial epicondylar, 398, 399*f*
· Monteggia, 401, 401*f*
· open, 392
· open treatment of, 391
· physis in, 380
· plates in, 392
· in polytrauma, 382
· radial, 399–400, 400*f*, 402, 402*f*, 403*f*
· remodeling potential in, 381, 381*t*
· in Salter-Harris classification, 383, 384*t*–385*f*
· salvage in, 392
· stabilization of, 391
· supracondylar, 396–398, 396*f*–398*f*
· surgical stabilization of, 392, 393*f*
· tibial, 381*t*, 415–419, 415*f*, 416*f*, 418*f*, 419*f*
· treatment of, 391–392, 393*f*
· ulnar, 401*f*
Pedicled flap, 372, 374*f*
PEEK. *See* Polyetheretherketone (PEEK)
PEKK. *See* Polyetherketoneketone (PEKK)
Pelvic binder, 717, 721–723, 722*f*, 730, 730*f*
Pelvic fracture. *See also* Acetabulum fracture; Pelvic ring fracture
· hemorrhage control in, 324
· intraabdominal bleeding and, 723
· "log rolling" in, 723
· thromboembolic prophylaxis in, 433–434, 433*t*
Pelvic packing, 730–731
Pelvic reduction forceps, 123*t*, 126, 126*f*, 127, 127*f*
Pelvic ring fracture
· anatomy in, 718, 718*f*, 719*f*
· anterior, 734–736, 734*f*, 735*f*, 736–737, 736*f*
· anterior posterior compression in, 720, 720*t*
· arterial embolization in, 723
· catheterization in, 724
· causative force vectors in, 720, 720*t*
· classification of, 720–721, 720*t*, 721*f*, 721*t*
· complications in, 743
· computed tomography in, 723
· decision making in, 721–725, 722*f*, 725*f*–729*f*, 731–732, 731*t*
· diagnosis of, 717
· dynamic compression plate in, 735*f*
· embolization in, 723
· emergency algorithm for, 730*f*
· epidemiology of, 717
· examination under anesthesia in, 731, 736
· external fixation in, 742, 742*f*
· fecal contamination in, 724–725
· fixation of, 731–742, 731*t*, 733*f*–742*f*
· with hemodynamic instability, 725, 730–731, 730*f*
· hypotension in, 723
· iliac wing instability in, 737, 737*f*
· imaging of, 717, 718*f*, 723
· indications for surgery in, 731–732, 731*t*
· instability in
·· with hemodynamic instability, 725, 730–731, 730*f*
·· with hemodynamic stability, 731–742, 731*t*, 733*f*–742*f*
· lag screws in, 737*f*
· lateral, 737, 737*f*
· lateral compression in, 720, 720*t*
· limited-contact dynamic compression plate in, 735*f*, 740
· long-term assessment in, 743–744
· open, 724–725, 725*f*–729*f*
· operating room set-up in, 732, 733*f*
· outcomes in, 743–744
· pelvic packing in, 730–731
· pitfalls with, 743
· posterior, 737–740, 738*f*–741*f*, 742, 742*f*
· postoperative care in, 743
· primary evaluation in, 721–725, 722*f*, 725*f*–729*f*
· pubic rami fixation in, 736–737, 736*f*
· pubic symphysis disruption in, 734–736, 734*f*, 735*f*
· sacral, 741*f*, 742, 742*f*
· sacroiliac disruption in, 737–740, 738*f*–741*f*
· signs of, 717
· Tile classification in, 720, 721*f*, 721*t*
· timing of surgery in, 732
· urethral injury in, 724
· vertically unstable, 742
· vertical shear in, 720, 720*t*
· Young-Burgess classification in, 720, 720*t*

Pelvis
· neurovascular structures in, 718
· osteoligamentous structure in, 718, 719*f*
· soft tissues in, 718
Penetrating injury, 332, 332*f*
Perforating vessels, 137
Peripheral arterial disease, decision making and, 76
Peripheral neuropathy, malleolar fracture and, 956
Periprosthetic fracture
· acetabulum, 837–838
· apophyseal, 841
· around implant, 843, 843*f*
· arthroplasty technique in, 839
· biomechanics in, 839
· case demonstration in, 848–851, 849*f*–850*f*
· case history, 839
· causes of, 838–839
· classification of, 841–843, 841*t*, 842*f*–844*f*
· clear of implant, 843
· complications with, 851
· decision making in, 844, 848
· diagnosis of, 839–840, 840*f*
· distant from implant, 843
· epidemiology of, 837–838, 838*t*
· evaluation of, 839–840, 840*f*
· extraarticular, 841
· femoral, 837–838, 847*f*, 848–851, 849*f*–850*f*
·· distal, 832, 832*f*, 833*f*
· in femoral fracture, distal, 832, 832*f*, 833*f*
· fixation in, 848, 849*f*
· in hemiarthroplasty, 843
· in hip, 837–838, 838*t*
· imaging in, 839–840, 840*f*
· in implant bed, 843, 843*f*
· internal fixation of, 846–848, 847*f*
· interprosthetic, 843
· intramedullary nailing in, 846, 847*f*
· knee, 838
· locking compression plates in, 272*t*, 277, 277*f*, 847*f*
· locking head screws in, 846
· nonoperative treatment of, 845
· operating room set-up in, 845, 845*f*
· orthogeriatric medical conditions in, 838–839
· outcomes with, 851
· periarticular, 841
· physical examination in, 839
· polyperiprosthetic, 843
· preoperative planning in, 844–845, 844*f*, 845*f*, 848
· reduction of, 846, 848, 849*f*
· rehabilitation in, 848, 850*f*
· revision arthroplasty and, 848
· risk factors for, 838–839
· Unified Classification System in, 841–843, 841*t*, 842*f*–844*f*
· upper limb, 838
· Vancouver classification of, 841, 841*t*, 842*f*
Perkins, George, 4
Peroneal nerve palsy, 869
Perren, Stephen, 5
Perren's strain theory, 18, 242, 242*f*
"Personality," of injury, 73, 73*f*, 76–78
Phalange fracture
· diaphyseal, 709, 709*f*
· intraarticular, 710–712, 711*f*, 712*f*
· plating in, 701*t*, 702*f*
· surgical approach for, 709–710, 709*f*–712*f*, 712, 712*f*
Phalanges, anatomy of, 700, 700*f*
PHILOS, 196*f*
· in humeral fracture, 157*f*, 158*f*, 307*f*, 476*f*, 602, 611
· locking head screws in, 473
Philosophy, of AO, 3
Physiotherapy, in diaphyseal fracture, 91
Physis, in pediatric fracture, 380
Pilon fracture
· anatomy in, 914, 915*f*–917*f*
· angiosomes in, 914, 916*f*
· anterior approach in, 924
· anterolateral fragment in, 914, 915*f*, 924, 924*f*
· bridge plate in, 923
· buttress plate in, 927, 927*f*
· case history in, 914
· central comminution in, 914
· challenges with, 928, 929*f*
· classification of, 918
· complications in, 928–930
· diagnosis of, 914
· epidemiology of, 913
· evaluation of, 914
· fibular approach in, 923
· fixation of, 925–928, 926*f*, 927*f*
· foot position and, 913, 913*f*
· fragments in, 914, 915*f*
· history of, 913
· imaging in, 914
· implant selection in, 919, 919*f*, 920*f*
· joint comminution in, 914
· lateral comminution in, 914
· locking compression plate in, 926*f*
· malleolar fracture vs., 943
· medial comminution in, 914
· medial malleolar fragment, 914, 915*f*
· negative pressure wound therapy in, 922, 922*f*
· open, 922, 922*f*
· open reduction and external fixation in, 918
· operating room set-up in, 921, 921*f*
· in osteoporosis, 928
· outcomes in, 930
· physical examination in, 914
· plating in, 920*f*, 923, 927, 927*f*
· posterolateral approach in, 923, 923*f*, 925
· posterolateral fragment in, 914, 915*f*, 924
· postoperative care in, 928
· posttraumatic arthritis in, 930
· preoperative planning in, 918–921, 919*f*, 920*f*, 923
· prognosis in, 930
· reduction of, 925, 925*f*
· screws in, 927, 927*f*
· special characteristics of, 913
· surgical approaches in, 922–924, 923*f*, 924*f*
· surgical indications in, 918
· timing of surgery in, 918
Piperacillin, 424*t*, 427*t*
Piritamide, 462
Plain radiography. *See* X-rays
Planning. *See* Preoperative planning
Plastic surgeon, in soft-tissue loss, 365
Plate(s). *See also* Fixation; Implants; Minimally invasive plate osteosynthesis (MIPO); Screws
· absolute stability of, 21–22, 22*f*, 198–202, 198*f*–202*f*
· anatomical contoured, in reduction, 134, 134*f*
· angled blade, reduction with, 132*f*, 133, 206, 206*f*
· antiglide, 203, 203*f*
·· lag screws in, 203, 203*f*
·· reduction with, 133, 133*f*
·· tubular plate as, 191, 191*f*
· biomechanics of, 21–22, 22*f*, 186*t*
· blood supply and, 11
· -bone interface, 269, 269*f*
· bridging, 204–205, 205*f*
·· biological, 241
·· biomechanics of, 17, 21, 204–205, 205*f*
·· callus and, 242, 242*f*, 243*f*
·· in clavicular fracture, 578
·· in diaphyseal fracture, 241, 242, 242*f*
·· dynamic compression plate as, 245
·· implant considerations with, 245–247, 245*f*–247*f*
·· locking compression plate as, 247, 247*f*, 301, 302*f*–304*f*
·· Masquelet technique and, 250
·· in metaphyseal fracture, 244
·· in minimally invasive plate osteosynthesis, 249*f*
·· in multifragmentary fracture, 241, 241*f*, 242, 242*f*, 243*f*
·· Perren strain theory and, 242, 242*f*
·· in pilon fracture, 923
·· in radial fracture, 694, 694*f*
·· reduction with, indirect, 244–245, 244*f*
·· relative stability of, 17
·· in simple fracture, 242, 242*f*
·· soft tissue considerations with, 248–250, 249*f*
·· stability and, 241
·· in subtrochanteric fracture, 6*f*
·· of subtrochanteric fracture, 6*f*
·· in tibial fracture, 85*f*, 248, 249*f*, 251*f*
· buttress, 203, 203*f*
·· biomechanics of, 21
·· in femoral fracture, 829–830, 829*f*
·· lag screws in, 203, 203*f*
·· limited-contact dynamic compression plate as, 186–190

·· in malleolar fracture, 951, 952*f*
·· in pilon fracture, 927, 927*f*
·· reduction with, 133, 133*f*
·· tubular plate as, 191, 191*f*
· in calcaneus fracture, 970*f*
· in chronic infection, 559–560
· in clavicle fracture, 576–577, 576*f*, 578, 578*f*, 580–583, 580*f*–583*f*
· compression by overbending with, 201, 201*f*
· contouring of, 202, 202*f*
·· absolute stability and, 198
·· ductility and, 28
·· fixation and, 109
·· limited contact dynamic compression, 179*t*
·· locking compression, 153
·· in minimally invasive plate osteosynthesis, 155*f*, 160, 162, 165*f*, 166
·· reconstruction, 192
·· soft-tissue handling and, 152
·· tubular, 191, 191*f*
· in cuboid fracture, 989*f*
· designs, 185–197, 186*f*–194*f*, 186*t*, 196*f*, 197*f*
· in diaphyseal fracture, 90, 91*f*
· dynamic compression
·· blood supply and, 11, 185
·· as bridge plate, 245
·· in humeral fracture, shaft, 610
·· in pelvic ring fracture, 735*f*
· evolution of, 270*f*
· in femoral fracture, shaft, 792, 793–794, 794*f*, 800–801, 800*f*, 801*f*, 809, 809*f*
· in fragility fracture, 471, 472*f*
· functions of, 186*t*, 202
· in hand fracture, 704
· interfragmentary compression and, 198
· limited-contact dynamic compression
·· application technique, 188–190, 189*f*, 190*f*
·· articulated tension device with, 188
·· blood supply and, 11, 11*f*, 185
·· as buttress plate, 189, 189*f*
·· compression with, 202
·· contouring of, 153, 153*f*
·· design of, 186–188, 186*f*–189*f*
·· drill guides in, 189, 189*f*
·· footprint of, 186
·· in forearm fracture, 289, 402, 637
·· functions, 186
·· functions of, 186
·· in humeral fracture, 610*f*, 625
·· in minimally invasive plate osteosynthesis, 153, 153*f*
·· in pelvic ring fracture, 735*f*, 740
·· screw holes in, 187–188, 187*f*
·· sizes of, 187
· locking compression
·· absolute stability with, 289–294, 290*f*–294*f*, 305
·· application technique, 194–195
·· in articular fracture, 291, 291*f*–293*f*, 305
·· biomechanics of, 17, 21–22, 192–194, 193*f*, 194*f*, 288–289, 288*t*
·· blood supply and, 11, 11*f*
·· in bridge plating, 247, 247*f*
·· as bridging plate, 247, 247*f*, 301, 302*f*–304*f*
·· characteristics of, 287
·· in clavicle fracture, 576
·· combination hole in, 192, 193*f*
·· combination holes in, 192, 193*f*
·· contouring of, 153
·· design of, 192–194, 193*f*, 194*f*
·· in diaphyseal fracture, 90
·· evolution of, 5
·· failure modes of, 305
·· in femoral fracture, 196*f*, 829–830, 829*f*
·· in forearm fracture, 289
·· history of, 270, 270*f*, 271
·· in humeral fracture, 196*f*, 197*f*, 291*f*, 293*f*, 302*f*, 307*f*, 601, 602*f*, 610, 625, 633–634, 633*f*
·· hybrid, 287, 294*f*, 295*f*
·· hybrid application of, 287, 294*f*, 295*f*
·· indications for, 272–279, 272*t*, 273*f*–279*f*
·· infection susceptibility with, 31
·· length of, 297–300, 298*f*–301*f*
·· in malunion, 498
·· metaphyseal, 196*f*
·· in metaphyseal fracture, 272*t*, 288*t*, 289, 290*f*
·· in minimally invasive plate osteosynthesis, 153, 272*t*, 278, 279*f*, 294, 294*f*, 302*f*
··· in clavicle, 155
·· in multifragmentary fracture, 288*t*
·· olecranon, 196*f*
·· in osteoporosis, 272, 272*t*, 273*f*–276*f*, 288*t*, 289, 290*f*
·· in pediatric femoral fracture, 404, 405*f*–406*f*
·· in periarticular fracture, 278, 278*f*, 291, 291*f*–293*f*
·· in periprosthetic fracture, 272*t*, 277, 277*f*, 846, 847*f*
·· in pilon fracture, 926*f*
·· polyaxial screws in, 194, 194*f*
·· in poor bone stock, 272–277, 272*t*, 273*f*–277*f*
·· preoperative planning with, 195
·· in radial fracture, 197*f*
·· relative stability of, 17, 294–305, 295*f*–307*f*
·· in revision surgery, 277
·· screws in, 192, 193*f*
·· in small bones, 277, 277*f*
·· in soft bones, 277, 277*f*
·· in tibial fracture, 196*f*, 292*f*, 295*f*, 296*f*, 303*f*, 304*f*, 306*f*, 908
·· variable angle, 271, 271*f*, 846
· in metacarpals, 701*t*
· in nonunion, 523, 523*f*
· in olecranon fracture, 647–648, 647*f*
· in open fracture, 342, 342*f*
· osteomyelitis and, 534, 534*f*
· in pediatric fracture, 392
· in phalanges, 701*t*, 702*f*
· in pilon fracture, 920*f*
· protection
·· absolute stability and, 198–199, 198*f*, 199*f*
·· defined, 21
·· in minimally invasive osteosynthesis, 149
·· in reduction, 90
· in radial fracture, 648–650, 648*f*, 649*f*, 679–684, 680*f*–683*f*, 684–686, 687*f*
· reconstruction
·· design of, 192, 192*f*
·· in minimally invasive plate osteosynthesis, 155
· reduction, 165*f*, 206, 206*f*, 207*f*
· reduction onto, 132–134, 132*f*–134*f*
· in scapula fracture, 570, 571*f*
· special, 195, 196*f*, 197*f*
· in talus fracture, 977
· tension band
·· criteria for, 203
·· in femur, 212*f*, 498*f*
·· function of, 204
·· in malunion, 498*f*
·· in navicular fracture, 987*f*
·· in olecranon fracture, 645–648, 647*f*
· in thumb metacarpal, 701*t*, 702*f*
· in tibial fracture, shaft, 904–905, 905*f*, 906–907, 907*f*, 908
· transient porosis with, 11
· in treatment of chronic infection, 553
· tubular
·· as buttress plate, 191, 191*f*
·· design of, 190–192, 190*f*, 191*f*
·· in minimally invasive plate osteosynthesis, 164, 165*f*
·· stacking of, 191
Plate screw, mechanism of, 179*t*
PMC. *See* Posteromedial corner (PMC)
PMMA. *See* Polymethylmethacrylate (PMMA) beads, aminoglycoside-impregnated
PMN. *See* Polymorphonuclear neutrophils (PMNs)
POL. *See* Posterior oblique ligament (POL)
Poller screw
· mechanism of, 179*t*
· in metaphyseal fracture, 230, 230*f*
· in reduction with intramedullary nailing, 229–230, 230*f*
Polyaxial screws, in locking compression plates, 194, 194*f*
Polyetheretherketone (PEEK), 34
Polyetherketoneketone (PEKK), 34
Polymethylmethacrylate (PMMA) beads, aminoglycoside-impregnated
· in closure, 146, 147*f*
· in open fracture, 338–339, 347
Polymorphonuclear neutrophils (PMNs), 52, 313
Polypharmacy, 461
Polytrauma
· in blast injury, 325–326, 327*f*
· cardiovascular system in, 312, 382
· chest injury in, 324–325, 325*f*
· coagulopathy in, 314–315, 314*f*, 318*t*
· damage-control orthopedics in, 220, 311–312, 317–319, 318*t*, 319*t*

· damage-control surgery in, 75, 75*f*
· decision making in, 74–76, 74*f*, 75*f*
· defined, 311
· definitive care in, 75–76, 75*f*
· early appropriate care in, 76, 312, –312
· early total care in, 75–76, 211, 220, 311–312, 319, 319*t*
· external fixation in, 253
· femoral shaft fracture in, 220–221
· hypothermia in, 74
· importance of fracture in, 311–312
· intramedullary nails in, 220–221
· isolated injuries in, 76
· "lethal triad" in, 314, 314*f*
· pathophysiology in, 312–315, 314*f*, 315*t*
· in pediatric patients, 382
· primary survey in, 74
· reactions to, 313
· reaming and, 219
· resuscitation in, 74, 315–316
· secondary survey in, 74
· specific injury patterns in, 320–326, 320*f*–323*f*, 325*f*, 327*f*
· surgery as "second hit" in, 220, 314–315, 314*f*, 315*t*
· systemic inflammatory response syndrome in, 312, 313
· systemic reactions to, 313
· thromboembolic prophylaxis in, 433
· timing of surgery in, 79*t*
· traumatic brain injury in, 324
Position screw
· locking head screw as, 282, 282*t*
· mechanism of, 179*t*
· in reduction, 102
Positron emission tomography (PET), in infection diagnosis, 536, 549, 550*f*
Posterior approaches, in scapula fracture, 567, 568*f*
Posterior cruciate ligament (PCL)
· in knee dislocation, 865, 866, 870, 871, 872–873
· in tibial fracture, proximal, 880, 880*f*
Posterior humeral circumflex artery, 591*f*
Posterior interosseous nerve palsy, 670
Posterior Monteggia fracture dislocation, 652–653, 652*f*–653*f*
Posterior oblique ligament (POL), 866, 866*f*
Posterior sacroiliac ligament, 719*f*
Posterior talofibular ligament, 837*f*, 937, 941
Posterolateral corner (PLC), 866*f*, 867, 867*f*, 872, 872*f*
Posteromedial corner (PMC), 866, 866*f*, 872, 873*f*
Postoperative care and management
· in acetabulum fracture, 769–770
· activity in, 444, 444*f*
· in articular fracture, 102
· in calcaneus fracture, 439*t*, 972
· in clavicle fracture, 584
· in clinical care outside hospital, 445
· communication in, 444
· complex regional pain syndrome in, 445–447, 446*f*
· in diaphyseal fracture, 91
· dressings in, 442
· early implant removal in, 448
· early mobilization in, 443, 443*f*
· elevation of injured limb in, 438*t*–439*t*, 442–443, 443*f*
· in external fixation, 266–267
· in femoral fracture, 438*t*, 439*t*
·· distal, 834
·· proximal, 786
· in forearm fracture
·· proximal, 655
·· shaft, 670
· in fragility fracture patients, 463–466
· in hand fracture, 714, 714*f*
· in humeral fracture, 438*t*, 604, 604*t*, 620, 634–635
· in immediate postoperative phase, 437–444, 437*f*, 438*t*–439*t*, 440*t*, 441*t*, 443*f*, 444*f*
· implant removal in, 448
· in knee dislocation, 873, 873*f*
· in malleolar fracture, 439*t*, 956–957
· in minimally invasive plate osteosynthesis, 154
· monitoring in, 447–448
· in olecranon fracture, 438*t*
· pain management in, 437–442, 437*f*, 440*t*, 441*t*
· in patellar fracture, 439*t*, 862
· in pelvic ring fracture, 743
· in pilon fracture, 928
· in preoperative planning, 109
· in radial fracture, 438*t*
· radiographic assessment in, 444, 447–448
· in scapula fracture, 570
· second phase of, 445–448, 445*f*, 446*f*
· in soft-tissue reconstruction, 376
· support of injured limb in, 438*t*–439*t*, 442–443, 443*f*
· in talus fracture, 979
· in tarsometatarsal joint injury, 994
· third phase of, 448
· in tibial fracture, 439*t*, 894, 909
· weight bearing in, 444, 444*f*
Postthrombotic syndrome (PTS), 429–430
Posttraumatic osteoarthritis
· in articular fracture, 95, 95*f*
· in calcaneus fracture, 972
· in patellar fracture, 864
· in pilon fracture, 930
· in talus fracture, 980
Posttraumatic radioulnar synostosis, 670–671
Pregabalin, 440
Pregnancy, radiation exposure in, 482
Preloading, screws and, 173
Preoperative planning
· in acetabulum fracture, 751–752, 752*f*
· in articular fracture, 100–101
· assessment in, 106
· in calcaneus fracture, 965
· in clavicle fracture, 576–577, 576*f*, 577*f*
· closure in, 109
· completion of, 111, 111*f*
· decision making in, 108–109
· in diaphyseal fracture, 90
· equipment in, 109, 109*f*
· in femoral fracture
·· distal, 818–820, 818*f*–820*f*
·· proximal, 776–780, 777*f*–780*f*
·· shaft, 793–795, 794*f*, 796*f*
· fixation in, 108*f*, 109
· in forearm fracture, 641–643, 642*f*, 643*f*, 661–662, 661*f*, 662*f*
· in hand fracture, 701–702, 701*f*, 701*t*, 702*f*
· in humeral fracture
·· distal, 625–626, 625*f*, 626*f*
·· proximal, 593, 593*f*
·· shaft, 610–612, 610*f*–612*f*
· imaging in, 106, 107
· with intramedullary nails, 223–224, 244*f*
· in knee dislocation, 870–871
· with locking compression plates, 195
· in malleolar fracture, 946–947, 946*f*, 947*f*
· in malunion, 497, 497*f*
· materials for, 107
· method, 106–111, 107*f*–111*f*
· in minimally invasive plate osteosynthesis, 150–154, 151*f*–153*f*
· in patellar fracture, 857, 857*f*
· in periprosthetic fracture, 844–845, 844*f*, 845*f*, 848
· in pilon fracture, 918–921, 919*f*, 920*f*, 923
· postoperative regimen, 109
· problems of inadequate, 105
· in radial fracture, 678, 678*f*
· reasons for, 105
· reconstruction in, 107–108, 107*f*, 108*f*
· reduction in, 109
· in scapula fracture, 566
· surgical tactic in, 109–110, 109*f*, 110*f*, 112*f*
· in talus fracture, 975–976
· in tarsometatarsal joint injury, 993
· in tibial fracture
·· proximal, 881–882, 882*f*
·· shaft, 901–902, 902*f*
Primary survey, in polytrauma, 74
Prophylaxis. *See* Antibiotic prophylaxis; Thromboembolic prophylaxis
Prostheses. *See* Periprosthetic fracture
Protection plate
· absolute stability and, 198–199, 198*f*, 199*f*
· defined, 21
· in minimally invasive osteosynthesis, 149
· in reduction, 90
Protective equipment, for radiation exposure, 486
Protein C deficiency, 431*t*
Protein S deficiency, 431*t*
Prothrombin mutation, 431*t*
Proximal radioulnar joint (PRUJ), 658–659, 659*f*
PRUJ. *See* Proximal radioulnar joint (PRUJ)
Pseudarthrosis, 513, 514*f*, 520*f*, 521. *See also* Nonunion

PTS. *See* Postthrombotic syndrome (PTS)
Pubic rami fixation, 736–737, 736*f*
Pubic symphysis, 719*f*
Pubic symphysis disruption, in pelvic ring fracture, 734–736, 734*f*, 735*f*
Pulmonary embolism (PE), 219, 429, 430. *See also* Thromboembolic prophylaxis
Push-pull screw, mechanism of, 179*t*

Q

Queen tong clamp, 126, 126*f*
Quinolones, 532, 542

R

Radial collateral ligament (RCL), 640
Radial fracture. *See also* Forearm fracture
· distal
·· anatomy in, 676, 677*f*
·· associated injuries in, 676, 676*f*
·· biomechanics in, 676
·· bridge plating in, 694, 694*f*
·· carpal tunnel syndrome in, 694
·· case history in, 673
·· challenges with, 692–694, 692*f*–693*f*
·· classification in, 677, 677*f*, 677*t*
·· complex, 692, 692*f*–693*f*
·· complex regional pain syndrome in, 694
·· complications in, 694, 695*f*
·· computed tomography in, 674–676, 675*f*, 676*f*
·· diagnosis of, 673–676, 674*f*–676*f*
·· epidemiology of, 673
·· evaluation of, 673–676, 674*f*–676*f*
·· external fixation in, 686–690, 687*f*–691*f*
·· Fernandez classification of, 677, 677*t*
·· fixation in, 682–684, 683*f*, 686, 687*f*
·· imaging in, 673–676, 674*f*–676*f*
·· implant selection in, 678
·· malunion in, 694
·· operating room set-up in, 678, 678*f*, 679*f*
·· outcomes in, 695
·· physical examination in, 673
·· plating in
··· bridge, 694, 694*f*
··· dorsal, 684–686, 687*f*
··· palmar, 679–684, 680*f*–683*f*
·· preoperative planning in, 678, 678*f*
·· prognosis in, 695
·· reduction of, 681–682, 681*f*, 682*f*, 686, 687*f*
·· special characteristics of, 673
·· surgical indications in, 678
·· tendon rupture in, 694
·· tenosynovitis in, 694
·· timing of surgery in, 678
·· triangular fibrocartilage complex injury in, 676, 676*f*
·· X-rays in, 673
· elbow dislocation in, 653, 653*f*
· epidemiology of, in osteoporosis, 454
· malunion, 504, 504*f*
· multifragmentary, 650
· neck, 650
· pediatric, 399–400, 400*f*, 402, 402*f*, 403*f*
· plating in, 648–650, 648*f*, 649*f*
· posterolateral approach in, 666, 666*f*
· postoperative care in, 438*t*
· reduction of, 667, 667*f*
· surgical approaches in, 643–644, 643*f*, 644*f*, 664, 664*f*, 665*f*, 666, 666*f*
· Thompson approach in, 666, 666*f*
Radial head replacement, 650
Radial head resection, 650
Radial height, 674, 674*f*
Radial inclination, 674, 674*f*
Radial nerve
· in Holstein-Lewis fracture, 609
· in humeral shaft anatomy, 608, 608*f*
Radial styloid, 676
Radiation exposure hazards, 481–482, 482*t*
Radiation safety, 484*f*, 485–488, 486*f*–488*f*
Radiographic evaluation. *See* Imaging
Radiosensitivity, 482, 482*t*
Radioulnar joint injury, distal, 695–696, 696*f*
Radius, proximal, anatomy of, 638
RCL. *See* Radial collateral ligament (RCL)
Reaming. *See also* Intramedullary nails
· advantages of, 218
· blood supply and, 12, 218
· bone healing and, 218
· distal venting with, 219, 228
· in femoral fracture, shaft, 804
· intramedullary nails without, 218, 219
· with Küntscher nails, 217
· local response to, 218–219
· in open fracture, 344, 344*f*
· in polytrauma patients, 219
· pulmonary embolism and, 219
· systemic response to, 219
· techniques, 227
· thermal necrosis and, 227
Reaming, irrigation, and aspiration (RIA) system, 219
Reconstruction, in preoperative planning, 107–108, 107*f*, 108*f*. *See also* Soft-tissue reconstruction
Reconstruction plate
· design of, 192, 192*f*
· in minimally invasive plate osteosynthesis, 155
Reconstructive ladder, 367–368, 367*f*
Rectal examination, in acetabulum fracture, 746
Rectus abdominis flap, 374*f*
Red-man syndrome, 423
Reduction
· in acetabulum fracture, 761–767, 763*f*–767*f*
· aids, 228–231, 228*f*–231*f*
· aim of, 119, 119*f*
· anatomical contoured plates in, 134, 134*f*
· with angled blade plate, 132*f*, 133, 206, 206*f*
· with antiglide plate, 133, 133*f*
· in articular fracture, 101, 101*f*
·· aim of, 119
·· imperfect, 95*f*
·· surgical timing and, 100
·· techniques, 101–102, 101*f*
· articulated tension device in, 132*f*
· assessment of, 135, 135*t*
· ball spike in, 129
· beanbag, 228
· blood supply and, 24
· with bone holding forceps, 125, 125*f*
· bone hook in, 129
· bone impactor in, 129
· with bone spreader, 125, 125*f*
· with bridge plating, 244–245, 244*f*
· with buttress plate, 133, 133*f*
· in calcaneus fracture, 968, 968*f*
· cerclage wires in, 130, 131*f*, 153
· in clavicle fracture, 578
· with colinear reduction forceps, 126, 126*f*
· defined, 118
· in diaphyseal fracture, 83*f*, 85*f*, 88*f*, 120
·· surgical timing and, 89
·· techniques, 90–91
· direct, 120, 120*t*
· displacement and, 117, 117*f*
· distractor in, 229, 229*f*
· external fixation in, 121, 254
· in external splinting, 16
· with Farabeuf forceps, 127, 127*f*
· in femoral fracture
·· distal, 826–832, 826*f*–833*f*
·· femoral head, 785, 785*f*
·· intertrochanteric, 784, 784*f*
·· with intramedullary nailing, 228
·· proximal, 782, 782*f*
·· shaft, 802–805, 802*f*–804*f*
· in forearm fracture
·· pediatric, 402, 402*f*
·· proximal, 645–650, 646*f*–659*f*
·· shaft, 667, 667*f*
· fracture classification and, 46
· in hand fracture, 703
· healing and, 119
· with Hohmann retractor, 128–129, 128*f*, 129*f*
· in humeral fracture
·· distal, 631–632, 631*f*, 632*f*
·· proximal, 597–604, 597*f*–602*f*
·· shaft, 619
· implants in, 132–134, 132*f*, 133*f*, 134*f*, 153
· incision and, 143–144, 143*f*, 144*f*
· indirect, 120, 120*t*, 244–245, 244*f*, 254, 598, 599*f*, 846
· instruments for, 121–131, 122*t*, 123*t*, 124*f*–131*f*
· with intramedullary nails, 228–237, 228*f*–236*f*
· intramedullary nails in, 132
· joystick, 130, 130*f*, 597–598, 598*f*
· with Jungbluth forceps, 127, 127*f*
· Kapandji, 130
· in malleolar fracture, 102, 949–956, 950*f*, 952*f*–955*f*

· in malunion, 498–499, 498*f*, 500*f*
· in minimally invasive plate osteosynthesis, 151–152, 151*f*, 152*f*
· miniplates in, 134
· modular, in external fixation, 264–265, 264*f*, 265*f*
· in Monteggia fracture, 401, 401*f*
· in olecranon fracture, 645–648, 646*f*, 647*f*
· in patellar fracture, 858, 863
· with pelvic reduction forceps, 126, 126*f*
· in periprosthetic fracture, 846, 848, 849*f*
· in pilon fracture, 925, 925*f*
· plates in, 132–134, 132*f*–134*f*
· in preoperative planning, 109
· protection plates in, 90
· in radial fracture
·· distal, 681–682, 681*f*, 682*f*, 686, 687*f*
·· pediatric, 400, 400*f*
·· shaft, 667, 667*f*
· in scapula fracture, 568–570, 569*f*
· Schanz screws in, 228, 228*f*, 245*f*
· stabilization and, 15, 119
· in supracondylar fracture in pediatric patients, 396, 396*f*
· techniques, 119–134, 120*t*, 121*f*, 122*t*, 123*t*, 124*f*–134*f*
· in tibial fracture
·· with intramedullary nailing, 228
·· pediatric, 417
·· proximal, 885–887, 885*f*, 886*f*
·· shaft, 905–907, 906*f*–908*f*
· towel-sling, 228
· in traction, 16*f*
· traction in, 120–121, 121*f*
· in ulnar fracture, 667, 667*f*
· unicortical screws in, 134
· with Weber forceps, 124, 124*f*
Reduction forceps
· colinear, 123*t*, 126, 126*f*, 151*f*
· pelvic, 123*t*, 126, 126*f*, 127, 127*f*
· with points, 122*t*, 124, 124*f*
· toothed, 122*t*, 125, 125*f*
Reduction plate, 165*f*, 206, 206*f*, 207*f*
Reduction screw
· locking head screw as, 282*t*
· mechanism of, 179*t*
· in minimally invasive plate osteosynthesis, 159*f*, 162*f*, 165*f*, 167*f*
Regeneration, bone, 34–35
Regional flap, 372, 374*f*
Regional trauma networks (RTN), 312
Rehabilitation. *See also* Postoperative care and management
· in acetabulum fracture, 769–770
· fragility fracture and, 465
· in periprosthetic fracture, 848, 850*f*
Reinhold, Paul, 270
Relative stability. *See* Stability
Remodeling
· in fracture healing, 13, 14*f*
· Haversian, 11
· internal, 11
· necrosis and, 11
Renal disease
· decision making and, 76–77
· fragility fracture and, 458
Residual deformity, in diaphyseal fracture, 83
Resistance, antibiotic, 423, 425
Resuscitation
· blood supply and, 10, 315–316
· in polytrauma, 74, 315–316
Revision surgery
· locking compression plates in, 277
· periprosthetic fractures and, 848
RIA. *See* Reaming, irrigation, and aspiration (RIA) system
Rib fracture, fixation of, 325
Rifampin, 532, 541–542
Ring fixator, 262, 262*f*
Rolando fracture, 706, 706*f*
RTN. *See* Regional trauma networks (RTN)

S

Sacral fracture, 741*f*, 742, 742*f*
Sacroiliac disruption, 737–740, 738*f*–741*f*
Sacrospinous ligament, 719*f*
Sacrotuberous ligament, 719*f*
Safety, radiation, 484*f*, 485–488, 486*f*–488*f*
Safe zones, in external fixation, 256, 257*f*–259*f*
Salter-Harris classification, 383, 384*t*–385*f*
Sarcopenia, 458
Scapula anatomy, 565
Scapula fracture
· anatomy in, 565
· articular, 569, 569*f*
· challenges with, 570
· classification of, 566
· complications with, 570
· deltopectoral approach in, 567
· diagnosis of, 565
· epidemiology of, 565
· evaluation of, 565
· fixation of, 570, 571*f*
· hematoma in, 570
· history of, 565
· imaging in, 565
· implant selection in, 566
· infection with, 570
· and ipsilateral clavicle, 570
· minimally invasive plate osteosynthesis in, 154
· operating room set-up in, 566, 567*f*
· outcomes in, 572
· plating in, 570, 571*f*
· posterior approaches in, 567, 568*f*
· postoperative care in, 570
· preoperative planning with, 566
· prognosis in, 572
· reduction of, 568–570, 569*f*
· scapular neck in, 569
· scapular process in, 568–569
· special characteristics of, 565
· stiffness after, 570
· superior approach in, 567
· suprascapular nerve palsy in, 570
· surgical approaches in, 567–568, 568*f*
· surgical indications in, 566
· timing of surgery in, 566
Schanz screws
· in external fixation, 255, 255*f*, 260, 260*f*, 264, 264*f*, 266
· in femoral fracture, 795, 795*f*, 803*f*, 818, 827, 829–831, 831*f*
· in modular reduction, 264, 264*f*
· in reduction, 228, 228*f*, 245*f*
Schneider, Robert, 4
Sciatic nerve injury, in acetabulum fracture, 749, 751
Scintigraphy, in infection diagnosis, 536, 549
Screwdrivers, torque-limiting, 181, 272*t*, 282, 283*t*
Screws. *See also* Fixation; Plate(s)
· anchor
·· mechanism of, 179*t*
·· in tibial fracture, 415*f*, 416*f*
· axial force produced by, 175, 175*f*
· biomechanics of, 175–176, 175*f*–177*f*
· cancellous bone, thread in, 177
· compression applied by, 176, 177*f*, 181, 181*f*, 182, 182*f*
· conventional, 173
· countersinks with, 176, 176*f*
· design features of, 173, 174*f*
· dynamic hip
·· design of, 196*f*
·· in femoral fracture, proximal, 778, 778*f*
·· in minimally invasive osteosynthesis, 160
· failure modes, 183
· function, 179, 179*t*
· heat generated by, 175
· insertion of, 182–183, 182*f*, 183*f*
· interlocking
·· intramedullary nails and, 17, 217, 237–238, 237*f*
·· mechanism of, 179*t*
· lag
·· absolute stability and, 20–21, 21*f*, 173, 198–199, 198*f*, 199*f*
·· biomechanics of, 20–21, 21*f*
·· in buttress plates, 203, 203*f*
·· clinical applications of, 183–184, 183*f*, 184*f*
·· compression with, 20, 20*f*
·· in diaphyseal fracture, 90, 91*f*
·· in epiphyseal region, 184, 184*f*
·· in femoral fracture, 7*f*
·· in femoral neck fracture, 806, 806*f*
·· fully threaded screws as, 179–180, 180*f*
·· in hand fracture, 704
·· in humeral fracture, 600, 600*f*
·· in interfragmentary compression, 179–180, 180*f*, 181*f*
·· locking head screws as, 282*t*
·· in malleolar fracture, 950*f*

·· mechanism of, 179*t*
·· in metaphyseal region, 184, 184*f*
·· in navicular fracture, 986, 986*f*
·· one vs two, 177*f*
·· partially threaded screws as, 180, 181*f*
·· in patellar fracture, 861*f*
·· in pediatric tibial fracture, 415*f*, 416*f*
·· in pelvic ring fracture, 737*f*
·· positioning of, 183, 183*f*
·· in talus fracture, 977, 977*f*
· in limited-contact dynamic compression plates, 187–188, 187*f*
· in locking compression plates, 192, 193*f*
· locking head
·· application principles, 280–286, 280*f*, 281*f*, 282*t*, 283*f*–287*f*
·· bicortical, 284, 284*f*
·· characteristics of, 280, 280*f*, 281*f*
·· in fragility fracture, 473
·· functions of, 282, 282*t*, 283*f*
·· in history of locking plates, 269*f*, 270
·· in humeral fracture, 286*f*, 625
·· as lag screws, 282*t*
·· in locking compression plates, 193*f*, 195
·· mechanism of, 175*f*, 179*t*
·· in minimally invasive plate osteosynthesis, 167*f*
·· monocortical, 286, 287*f*
·· number of, 286
·· in osteoporosis, 284, 284*f*
·· in periprosthetic fracture, 846
·· as position screws, 282, 282*t*
·· as reduction screws, 282*t*
·· stability with, 173
·· subcortical, 285, 285*f*
·· thread in, 177
·· in tibial fracture, 283*f*
·· torque-limiting attachments with, 282
·· types of, 282, 282*t*, 283*f*
· loosening of, 182, 182*f*
· in malleolar fracture, 179*t*
· naming of, 173, 174*f*
· in osteoporotic bone, 273*f*, 274*f*, 276*f*
· in pilon fracture, 927, 927*f*
· plate, mechanism of, 179*t*
· Poller
·· mechanism of, 179*t*
·· in metaphyseal fracture, 230, 230*f*
·· in reduction with intramedullary nailing, 229–230, 230*f*
· polyaxial, in locking compression plates, 194, 194*f*
· position
·· locking head screws as, 282, 282*t*
·· mechanism of, 179*t*
·· in reduction, 102
· preloading and, 173
· push-pull, mechanism of, 179*t*
· reduction
·· locking head screws as, 282*t*
·· mechanism of, 179*t*
·· in minimally invasive plate osteosynthesis, 159*f*, 162*f*, 165*f*, 167*f*
· Schanz
·· in external fixation, 255, 260, 260*f*, 264, 264*f*
·· in femoral fracture, 795, 795*f*, 803*f*
·· in modular reduction, 264, 264*f*
·· in reduction, 228, 228*f*, 245*f*
· self-drilling, 178, 179*f*, 283*f*
· self-tapping, 178, 178*f*, 283*f*
· in talus fracture, 965, 968*f*
· tangential force with, 174*f*, 175
· in tarsometatarsal joint injury, 994, 995*f*
· thermal necrosis with, 175
· threads of, 177
· in tibial fracture, shaft, 908
· tips of, 177–179, 178*f*, 179*f*
· torque-limiting screwdrivers and, 181
· torque with, 175–176
· unicortical, in reduction, 134
Secondary survey, in polytrauma, 74, 317*f*
"Second hit," 220, 314–315, 314*f*, 315*t*
Segmental arteries, 137, 138*f*
Self-drilling screws, 178, 179*f*, 283*f*
Self-tapping screws, 178, 178*f*, 283*f*
Septic arthritis, 532–533, 532*f*, 541, 544
Sequential compression pumps, in thromboembolic prophylaxis, 432
Sequestrum, 532, 548, 549*f*, 550*f*, 560
Sherman, William O'Neill, 3
Shock, 318*t*
Silastic vessel loops, 146, 147*f*
SIRS. *See* Systemic inflammatory response syndrome (SIRS)
Skin, blood supply to, 137–138, 138*f*
Skin assessment, in soft tissue injury, 53–54
Skin break down, in minimally invasive plate osteosynthesis, 170
Skin grafts, in soft-tissue reconstruction, 368–370, 369*f*
Social factors, decision making and, 77–78
Soft tissue
· bridge plating and, 248–250, 249*f*
· external fixation and loss of, 254
· in fragility fracture surgery, 467, 467*f*, 468*f*
· incision and, 142, 142*f*
· in minimally invasive plate osteosynthesis, 152
· in pelvis, 718
· surgical approach and, 139, 139*f*
· timing of surgery and, 140–141, 141*f*
Soft-tissue anatomy, 137–139, 138*f*
Soft-tissue blood supply, 137–139, 138*f*
Soft-tissue envelope, in articular fracture, 96
Soft tissue factors, in decision making, 78
Soft-tissue injury. *See also* Soft-tissue loss
· AO grading system for, 60, 61*f*–67*f*
· in articular fracture, 102
· biomechanics of, 51, 51*t*
· blood supply in, 54, 357*f*
· case history in, 53
· classification of, 58–68, 59*t*, 60*t*, 61*f*–67*f*
· closed skin degloving in, 54
· compartment syndrome in, 55–57, 55*f*–57*f*
· diagnosis of closed, 53–57, 53*f*–57*f*
· in diaphyseal fracture, 84, 85*f*, 86
· edema in, 53, 53*f*
· evaluation of, 53–55, 54*f*
· examination in, 53–55
· fracture assessment in, 55
· fracture blisters in, 54, 54*f*
· in Gustilo classification, 58, 59*t*
· healing of
·· inflammatory phase in, 52
·· pathophysiological responses in, 52
·· phases in, 51, 51*t*
·· proliferative phase in, 52
·· reparative phase in, 52
· muscle assessment in, 53–54
· neurological status assessment in, 54–55
· open, 58
· osteomyelitis and, 533
· pathophysiology of, 51, 51*t*
· in polytrauma, 318*t*
· secondary damage in, 53, 53*f*
· skin assessment in, 53–54
· systemic response to, 53
· treatment of closed, 53–57, 53*f*–57*f*
· in Tscherne classification, 59
· vascular status assessment in, 54
· and "zone of injury" concept, 51
Soft-tissue loss. *See also* Soft-tissue injury
· blue coloration in, 359
· capillary refill in, 359, 359*f*
· challenge of, 357
· early management in, 364
· evaluation of defects in, 358–360, 358*f*, 359*f*, 360*t*
· fracture evaluation in, 360
· grey coloration in, 359
· interdisciplinary decision making in, 364–366, 365*f*
· limb salvage vs early amputation in, 361–364, 361*f*–363*f*
· in lower extremity, 363
· muscle viability in, 359
· organizational aspects of initial care in, 364
· orthopedic surgeon in, 364
· patient evaluation in, 358, 358*f*
· plastic surgeon, 365
· pulse in, 360
· reconstruction in, 366–376, 367*f*, 369*f*, 371*t*, 373*f*–375*f*
· skin perfusion in, 359, 359*t*
· soft-tissue evaluation in, 358–360, 359*f*, 360*t*
· staging of procedures in, 366
· trauma surgeon on, 364
· in upper extremity, 362, 362*f*, 363*f*
Soft-tissue reconstruction
· back-up plan in, 367
· debridement in, 366
· fixation and, 366
· flaps in, 370–376, 371*t*, 373*f*–375*f*, 377*f*

· functional aspects in, 367
· "like with like" principle in, 367
· in open fracture, 348, 348*f*
· postoperative care in, 376
· in preoperative planning, 107–108, 107*f*, 108*f*
· principles of, 366–367
· "reconstructive ladder" concept in, 367–368, 367*f*
· secondary surgery in, 376
· skin grafts in, 368–370, 369*f*
· staging of treatment in, 366
· timing in, 366
· "tissue bank" principle in, 367
· types of, 368–376, 369*f*, 371*t*, 373*f*–375*f*
Soleus muscle flap, 375*f*
Spanning external fixation frame, 263, 263*f*
Stability
· absolute
·· articulated tension device and, 199–200, 199*f*, 200*f*
·· biomechanics and, 15, 19–24, 20*f*–24*f*
·· blood supply and, 23–24, 24*f*
·· and cancellous bone fracture, 23
·· compressive preload and, 20, 20*f*
·· defined, 15
·· in diaphyseal fracture, 22–23, 23*f*
·· direct healing and, 12
·· external fixators and, 22
·· in external fixation, 255
·· of external splints, 16
·· friction and, 20, 20*f*
·· in history of fracture management, 9
·· implants and, 20–22, 21*f*, 22*f*
·· indirect healing and, 12
·· lag screws and, 20–21, 21*f*, 173, 198–199, 198*f*, 199*f*
·· with locking compression plates, 289–294, 290*f*–294*f*, 305
·· with locking head screws, 173
·· mechanics of, 20, 20*f*
·· in minimally invasive osteosynthesis, 149
·· in minimally invasive plate osteosynthesis, 153
·· plates and, 21–22, 22*f*, 198–202, 198*f*–202*f*
·· protection plates and, 198–199, 198*f*, 199*f*
·· surgical fixation with, 19–24, 20*f*–24*f*
· in articular fracture, 95, 95*f*
· relative, 9
·· biomechanics and, 15
·· bone characteristics and, 10
·· of external fixation, 16–17
·· with fragility fracture, 471, 472*f*
·· of implants, 16
·· indirect healing and, 12
·· of intramedullary nails, 17
·· with locking compression plates, 17, 294–305, 295*f*–307*f*
·· in minimally invasive osteosynthesis, 149
·· in minimally invasive plate osteosynthesis, 153
·· surgical fixation with, 16–19, 17*f*–19*f*
· soft callus formation and, 13
Static tension band, 213, 213*f*
Steel
· allergic reactions to, 32
· corrosion resistance of, 29
· electropolished stainless, 27
· erosion of, 30
· fibrous capsule formation with, 30–31, 32*f*
· strength of, 28*t*
· surface properties of, 30–31, 30*f*, 32*f*
Steinmann pin, in external fixation, 255, 260
Sternoclavicular joint dislocation, 584
Stiffness
· in external fixation, 255, 255*f*
· of materials, 27–28
Stoppa approach. *See* Modified Stoppa approach
Strain, Perren's theory of, 18, 242, 242*f*
Strength, of materials, 28, 28*t*
Subscapularis tendon, 590, 591*f*
Subtrochanteric fracture, 6*f*
Suction drains, 146
Superior approach, in scapula fracture, 567
Supraclavicular nerve, in clavicle fracture, 574, 574*f*
Supracondylar fracture, pediatric, 396–398, 396*f*–398*f*
Suprascapular nerve palsy, 570
Sural fasciocutaneous flap, 375*f*
Surface properties, 30–31, 30*f*, 32*f*
Surgical approach
· in acetabular fracture, 753–761, 754*f*, 756*f*–760*f*, 762*f*
· in clavicle fracture, 577*f*, 578
· in coronoid fracture, 644–645, 644*f*, 645*f*
· in femoral fracture
·· distal, 821–825, 821*f*–825*f*
·· femoral head, 785
·· proximal, 780, 781*f*
·· shaft, 797–801, 798*f*–801*f*
· in forearm fracture, 643–645, 643*f*–645*f*, 662–666, 663*f*–666*f*
· in humeral fracture
·· distal, 626–630, 626*f*–630*f*
·· proximal, 594–596, 595*f*, 596*f*
·· shaft, 608*f*, 612–618, 613*f*–618*f*
· with intramedullary nails, 225, 225*f*
· in malleolar fracture, 948–949, 948*f*, 949*f*
· in metacarpal fracture, 708, 708*f*
· in olecranon fracture, 643
· in patellar fracture, 858, 858*f*
· in phalangeal fracture, 709–710, 709*f*–713*f*, 712
· in pilon fracture, 922–924, 923*f*, 924*f*
· in radial fracture, 643–644, 643*f*, 644*f*, 645*f* 664, 664*f*, 665*f*, 666, 666*f*
· in scapular fracture, 567–568, 568*f*
· soft-tissue considerations and, 139, 139*f*
· in talus fracture, 976, 976*f*
· in thumb metacarpophalangeal joint fracture, 706, 707*f*
· in tibial fracture
·· distal, *see* in pilon
·· proximal, 882–885, 883*f*–885*f*
·· shaft, 902–905, 903*f*–905*f*
Surgical hip dislocation, anterior, 760–761, 760*f*
Surgical planning. *See* Preoperative planning
Suture, Allgöwer-Donati, 145, 145*f*
Suture, traction, in humeral fracture, 597, 597*f*
Systemic inflammatory response syndrome (SIRS), 312, 313

T

Talocrural angle, 934, 935*f*
Talar fracture
· anatomy in, 974
· anterolateral approach in, 976, 976*f*
· anteromedial approach in, 976, 976*f*
· arthritis in, 980
· avascular necrosis in, 980
· classification of, 974, 975*t*
· complications in, 979–980
· diagnosis if, 974
· evaluation of, 974
· Hawkins classification of, 975*t*
· lag screws in, 977, 977*f*
· malunion in, 980
· open, 978*f*
· operating room set-up in, 966*f*, 976
· outcomes in, 980
· plating in, 977
· in polytrauma, 323*f*
· postoperative care in, 979
· preoperative planning in, 975–976
· prognosis in, 980
· screws in, 979
· surgical approaches in, 976, 976*f*
· surgical indications in, 975
TAN. *See* Titanium aluminum niobium (TAN)
Tarsometatarsal joint injury
· anatomy in, 990
· assessment in, 991–993, 991*f*–993*f*
· complete lateral divergent, 993*f*
· divergent, 993*f*
· fracture patterns in, 991–993, 991*f*–993*f*
· imaging in, 991, 992*f*
· K-wires in, 994, 995*f*
· medial divergent, 993*f*
· operative treatment of, 994
· physical examination in, 994
· postoperative care in, 994
· preoperative planning in, 993
· screws in, 994, 995*f*
· timing of surgery in, 993
Tazobactam, 424*t*, 427*t*
TBI. *See* Traumatic brain injury (TBI)
Teardrop angle, 674, 674*f*
Teicoplanin, 423, 424, 424*t*, 427*t*
Tension band concept
· application of, 212–213, 211*f*, 212*f*
· in articular fracture, 210–211, 211*f*
· biomechanics of, 209–211, 209*f*–211*f*
· complications with, 215
· compression side in, 209, 209*f*
· in curved bones, 212

· in diaphyseal fracture, 212
· in femur, 210, 210*f*
· in malleolar fracture, 950*f*
· materials for, 212, 212*f*
· operative technique with, 211*f*, 214–215, 214*f*
· in patellar fracture, 213, 213*f*
· pitfalls with, 215
· prerequisites for, 215
· static, 213, 213*f*
· tension side in, 209, 209*f*
Tension band plate
· criteria for, 203
· in femur, 212*f*, 498*f*
· function of, 204
· in malunion, 498*f*
· in navicular fracture, 987*f*
· in olecranon fracture, 645–648, 647*f*
Tensor fasciae latae musculocutaneous flap, 374*f*
Tepic, Slobodan, 5
TFCC. *See* Triangular fibrocartilage complex (TFCC)
Thompson approach, 666, 666*f*
Thromboembolic prophylaxis
· chemical, 432
· in fragility fracture patients, 464–465
· in hip fracture, 433, 433*t*
· in isolated lower extremity fracture, 433*t*, 434
· in pelvic and acetabular fractures, 433–434, 433*t*
· inferior vena cava filter, 432
· mechanical, 432
· methods of, 432
· in polytrauma, 433
· rationale for, 431
· sequential compression pumps in, 432
· in spinal injuries, 433, 433*t*
Thumb carpometacarpal joint fracture, 704–706, 704*f*–707*f*
· complete articular, 706, 706*f*
· extraarticular, 704
· partial articular, 704–705, 705*f*
Thumb metacarpal fracture, plating in, 701*t*, 702*f*
Thyroid shields, 486, 486*f*
Tibial fracture. *See also* Pilon fracture
· articular, 94*f*
· bridge plating in, 85*f*, 248, 249*f*, 251*f*
· case history in, 877–878, 877*f*
· distal (*See also* Pilon fracture)
·· history of, 913
·· minimally invasive plate osteosynthesis in, 168–170, 168*f*–169*f*
· external fixation of, 256, 258*f*, 345*f*
· intramedullary nailing in, 221, 222, 227, 227*f*, 343*t*
· locking compression plates in, 196*f*, 292*f*, 295*f*, 296*f*, 303*f*, 304*f*, 306*f*
· locking head screws in, 283*f*
· malleolar segment, 43, 43*t*
· malunion in, 494*f*, 495*f*, 506–510, 508*f*, 509*f*
· multifragmentary, 85*f*
· pediatric, 381*t*, 415–419, 415*f*, 416*f*, 418*f*, 419*f*
· physical examination in, 877–878, 877*f*
· postoperative care in, 439*t*
· proximal
·· anatomy in, 878–880, 879*f*–881*f*
·· anterior cruciate ligament in, 880, 880*f*
·· anterolateral approach in, 882, 883*f*
·· challenges with, 893, 895*f*
·· classification of, 880, 881*f*
·· complete articular, 893, 893*f*, 894*f*
·· complications in, 896
·· depressed articular, 893
·· diagnosis of, 877–878, 877*f*–879*f*
·· evaluation of, 877–878, 877*f*–879*f*
·· extraarticular, 887–890, 887*f*–889*f*
·· fixation in, 887–893, 887*f*–894*f*
·· imaging in, 878, 878*f*
·· implant selection in, 882
·· intramedullary nailing in, 889–890, 889*f*
·· inverted L-shaped approach in, 885, 885*f*
·· ipsilateral tibial plateau, 893
·· lateral column, 890–891, 890*f*, 891*f*
·· medial column, 891
·· minimally invasive plate osteosynthesis in, 164, 165*f*
·· operating room set-up in, 882, 882*f*
·· outcome in, 896
·· partial articular, 890–893, 890*f*–892*f*
·· posterior column, 891–892, 892*f*
·· posterolateral approach in, 883, 884*f*
·· posteromedial approach in, 883, 884*f*
·· postoperative care in, 439*t*, 894
·· preoperative planning in, 881–882, 882*f*
·· prognosis in, 896
·· reduction of, 885–887, 885*f*, 886*f*
·· surgical approaches in, 882–885, 883*f*–885*f*
·· surgical indications in, 881
·· timing of surgery in, 881
· reduction of, pediatric, 417
· reduction of, with intramedullary nailing, 228
· shaft
·· acceptable malalignment in, 381*t*
·· anatomy in, 900, 900*f*
·· case history in, 899
·· challenges in, 909
·· classification of, 900, 901*f*
·· compartment syndrome in, 899
·· complication sin, 910
·· diagnosis of, 899–900
·· epidemiology of, 899
·· evaluation of, 899–900
·· external fixation in, 905, 905*f*, 909
·· fixation of, 907–909
·· history of, 899
·· imaging in, 900
·· implant selection in, 901
·· infection in, 910
·· intramedullary nailing in, 902–904, 903*f*, 904*f*, 905–906, 906*f*, 907–909
·· locking compression plate in, 908
·· minimally invasive plate osteosynthesis in, 151, 166, 166*f*–167*f*
·· neurovascular examination in, 899
·· nonoperative treatment of, 901
·· nonunion in, 910
·· operating room set-up in, 902, 902*f*
·· outcome in, 910
·· physical examination in, 899
·· plating in, 904–905, 905*f*, 906–907, 907*f*, 908
·· postoperative care in, 439*t*, 909
·· preoperative planning in, 901–902, 902*f*
·· prognosis in, 910
·· reduction of, 905–907, 906*f*–908*f*
·· screws in, 908
·· special characteristics of, 899
·· surgical approaches in, 902–905, 903*f*–905*f*
·· surgical indications in, 900–901
·· timing of surgery in, 901
· timing of surgery in, 140
Tibiofibular ligaments, 936, 936*f*
Tile classification, 720, 721*f*, 721*t*
Tillaux-Chaput fragment, 914, 924, 924*f*
Timing of surgery, 78–79, 79*t*
· in acetabular fracture, 100, 751
· in articular fracture, 100
· in clavicular fracture, 576
· in diaphyseal fracture, 89, 89*f*
· in femoral fracture
·· distal, 818, 818*f*
·· proximal, 776
·· shaft, 793
· in forearm fracture, 641, 661
· in fragility fracture, 467
· in humeral fracture
·· proximal, 593
·· shaft, 610
· in knee dislocation, 870
· in malleolar fracture, 946, 946*f*
· in open fracture, 79*t*, 339, 339*t*
· in pelvic ring fracture, 732
· in pilon fracture, 918, 919*f*
· in radial fracture, 678
· in scapular fracture, 566
· soft-tissue considerations with, 140–141, 141*f*
· in soft-tissue reconstruction, 366
· in tarsometatarsal joint injury, 993
· in tibial fracture
·· proximal, 881
·· shaft, 901
Tissue pressure measurement, 56–57
Titanium
· allergic reactions and, 32
· corrosion resistance of, 29*f*
· ductility of, 28
· erosion of, 30
· fibrous capsule formation with, 31, 32*f*
· as material, 27
· strength of, 28*t*
· surface properties of, 30–31
Titanium alloys, 27
· allergic reactions and, 32
· erosion of, 30
· surface properties of, 30–31
· torsional properties of, 29

Titanium aluminum niobium (TAN)
· as material, 27
· strength of, 28*t*
Titanium screws, 21
Torque-limiting attachment (TLA), with locking head screws, 282
Torque-limiting screwdrivers, 181
Torsional properties, 29
Total elbow arthroplasty, 625, 631
Towel-sling, 228
Toxicity, corrosion resistance and, 29–30, 29*f*
Traction
· in articular fracture, 101, 120–121, 121*f*
· in diaphyseal fracture, 87
· as nonoperative fracture treatment, 15, 16*f*
· in reduction, 120–121, 121*f*
· reduction in, 16*f*
Traction sutures, in humeral fracture, 597, 597*f*
Tranexamic acid, 74
Transdeltoid approach, in proximal humeral fracture, 596, 596*f*
Transolecranon fracture dislocation, 651–652, 651*f*
Trauma. *See* Fracture; Polytrauma; Soft tissue
Traumatic brain injury (TBI), 324
Triangular fibrocartilage complex (TFCC), 676, 676*f*
Tricalcium phosphate coating, 33
Triceps-splitting exposure, in distal humeral fracture, 627–628
True muscle perforators, 137
Tscherne classification, of open soft tissue injury, 59
Tube-rod system, in external fixation, 260, 260*f*
Tubular plate
· as buttress plate, 191, 191*f*
· design of, 190–192, 190*f*, 191*f*
· in minimally invasive plate osteosynthesis, 164, 165*f*
· stacking of, 191
Tumor induction, implant materials and, 32

U

Ulna, proximal, anatomy of, 639
Ulnar fracture. *See also* Forearm fracture
· distal, 695–696, 696*f*
· nonoperative treatment of, 641
· pediatric, 401, 402, 402*f*
· reduction of, 667, 667*f*
· shaft, 658, 659, 659*f*
· surgical approaches in, 663, 663*f*
Ulnar nerve, in distal humeral fracture, 627
Ulnar variance, 674, 674*f*
Ultrasound, in infection diagnosis, 536
Unified Classification System, 841–843, 841*t*, 842*f*–844*f*
Unilateral frame, in external fixation, 263
Urethral injury, in pelvic ring fracture, 724
Urist, Marshall, 13

V

VA. *See* Variable-angle (VA) locking compression plate
Vacuum drains, 146
Vaginal examination, in acetabulum fracture, 746
Valgus deformity, 83, 506, 506*f*, 507, 507*f*
Vancomycin, 424
Vancomycin resistance, 423, 424
Vancouver classification, 841, 841*t*, 842*f*
Variable-angle (VA) locking compression plate, 271, 271*f*, 846
Varus deformity, 83, 506*f*, 507*f*, 509
VAS. *See* Visual Analog Scale (VAS)
Vascular injury, in open fracture, 349–350, 349*f*–351*f*
Vascular status assessment
· in articular fracture, 96
· in soft-tissue injury, 54
Vastus lateralis muscle flap, 374*f*
Velpeau view, 588, 589*f*
Venous disease, decision making and, 76
Venous thromboembolism (VTE), 429–431, 431*t*. *See also* Thromboembolic prophylaxis
Venting, in reaming, 219
Verbrugge forceps, 122*t*, 125, 125*f*
Vertebral fracture, epidemiology of, with osteoporosis, 454
Visual Analog Scale (VAS), 437, 437*f*
Vitamin D, 465–466
Vitamin K antagonists, 432, 463
Volkmann fragment, 914, 915*f*, 923, 924, 935
Volkmann triangle, 938, 940*f*, 951
VTE. *See* Venous thromboembolism (VTE)

W

Warfarin, 432, 463
Weber ankle fracture classification, 41
Weber forceps, 122*t*, 124, 124*f*
Willenegger, Hans, 4, 4*f*
Wolff's law, 455
Wound closure, 144–146, 145*f*–147*f*
Wound dressing, in open fracture, 346–347, 347*f*
Wrist. *See* Forearm fracture; Radial fracture

X

X-rays. *See also* Imaging
· in articular fracture, 98, 99*f*
· in clavicular fracture, 574, 574*f*
· in diaphyseal fracture, 84–86
· in infection diagnosis, 536
· in preoperative planning, 106, 107, 112
· in radial fracture, 673

Y

Young-Burgess classification, 720, 720*t*

Z

Zone of injury, 51, 75, 75*f*, 78, 96, 140, 263, 264, 332, 341, 339, 349